

# Transvenous approach as rescue during arterial curative treatment of a ruptured brain AVM

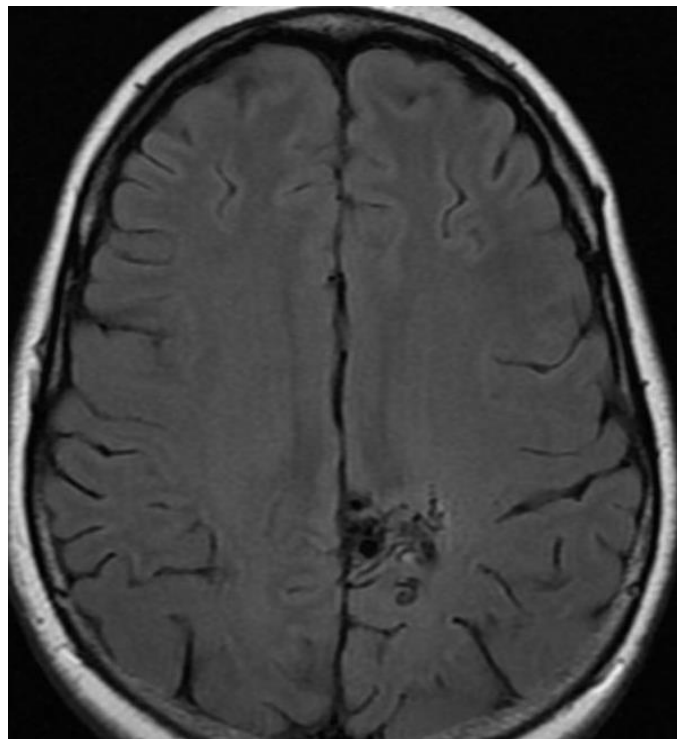
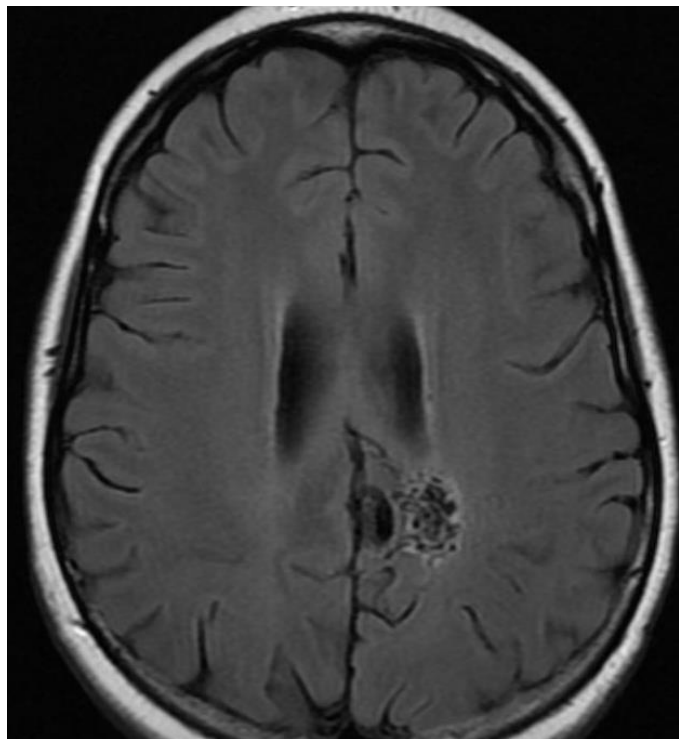
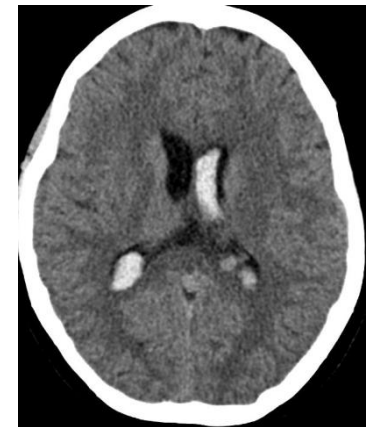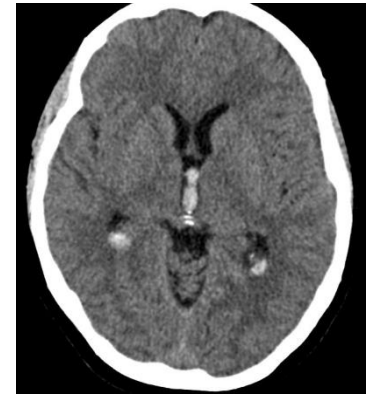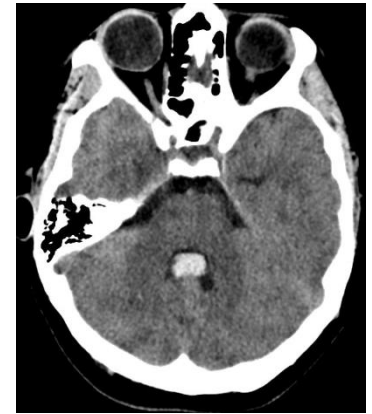
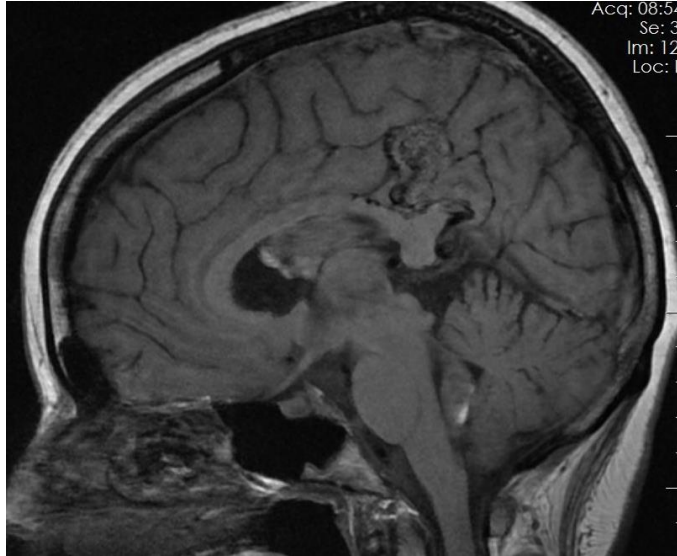
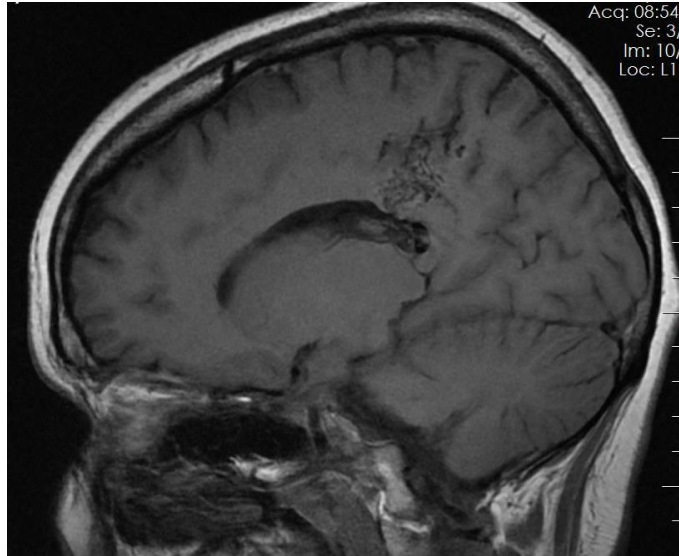
***Vitor Mendes Pereira MD MSc***

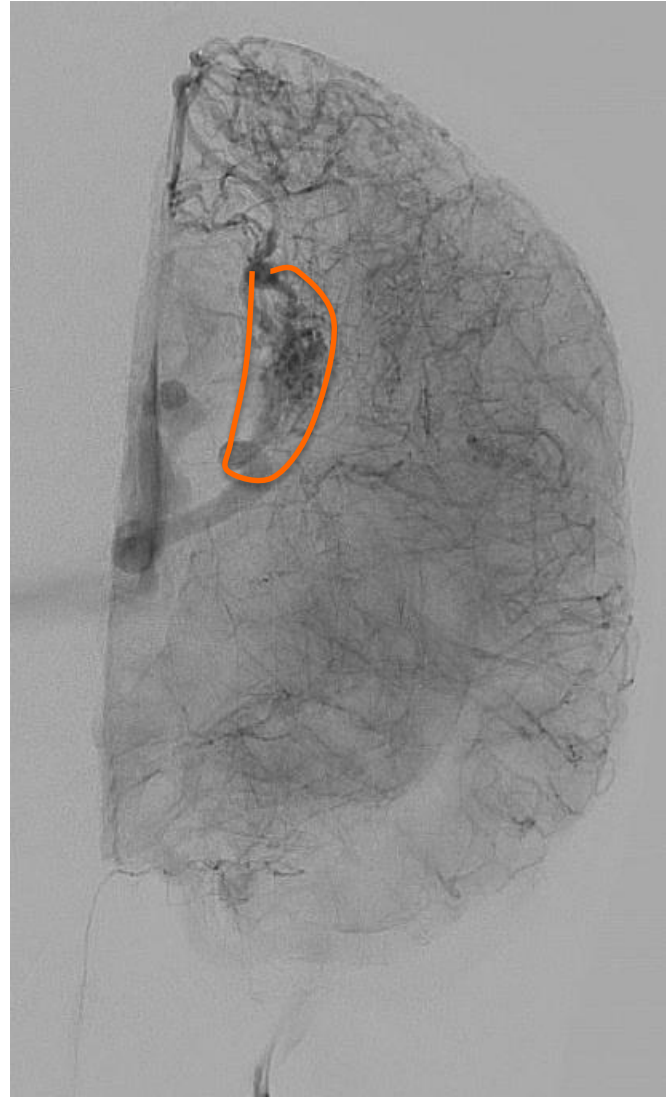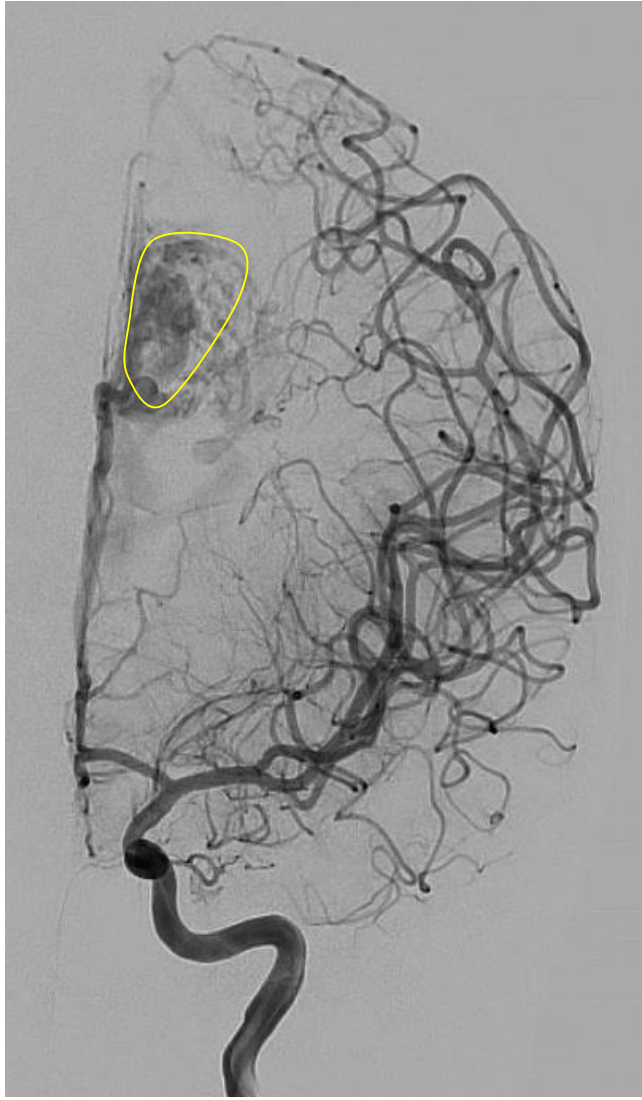***Timo Krings MD PhD***

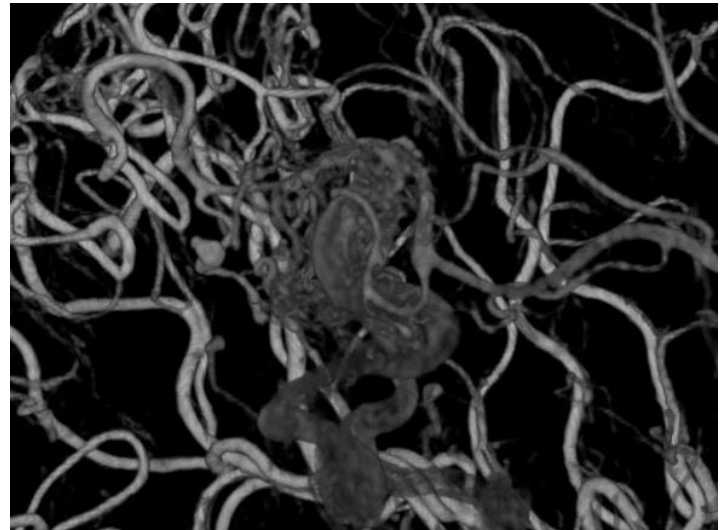
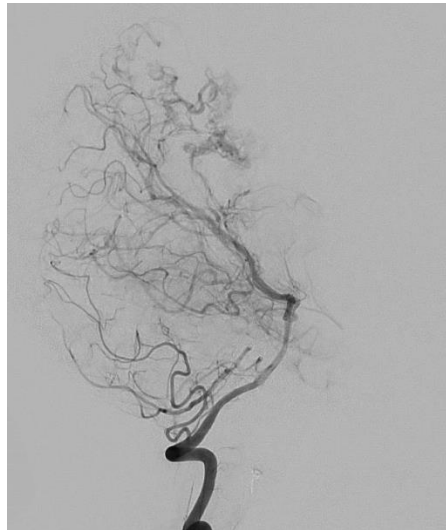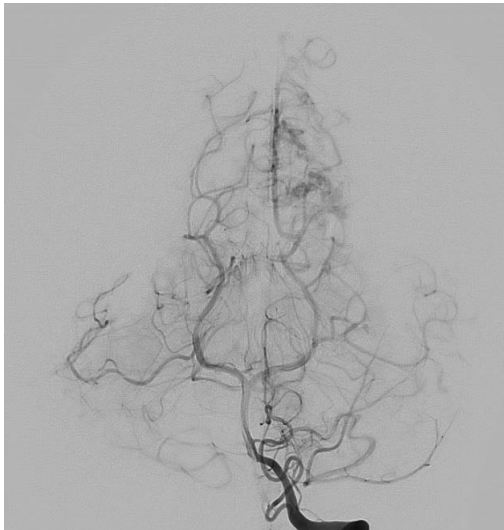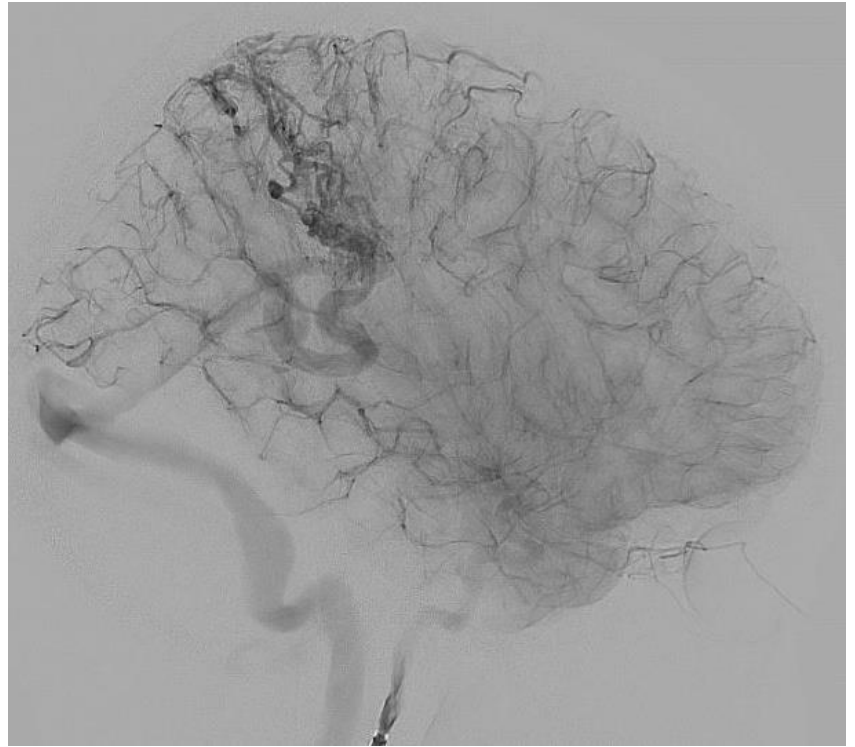
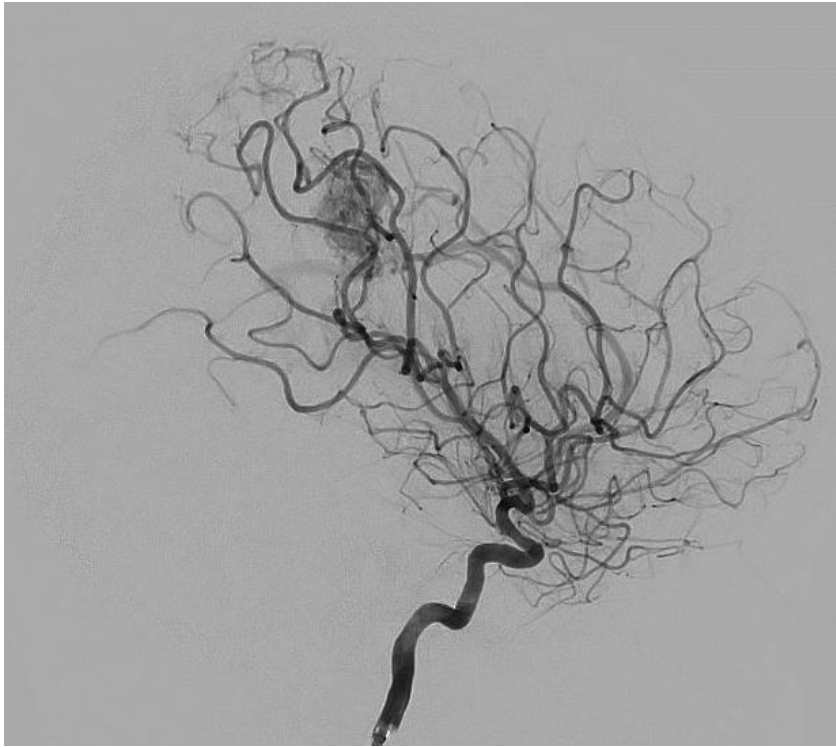***Ivan Radovanovic MD PhD***

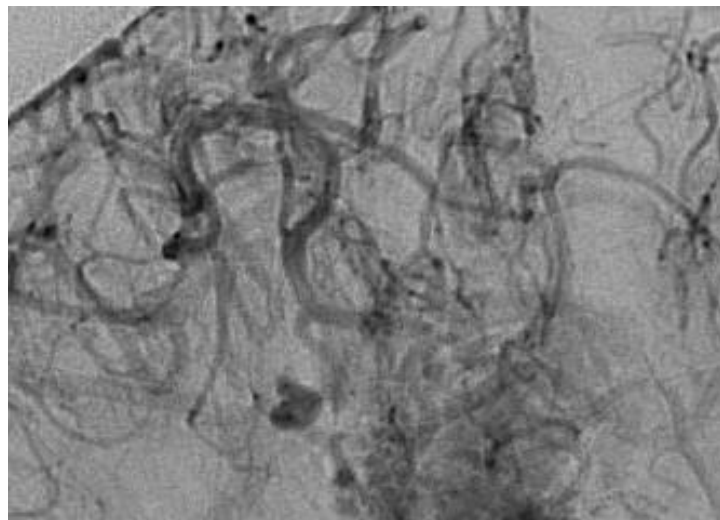
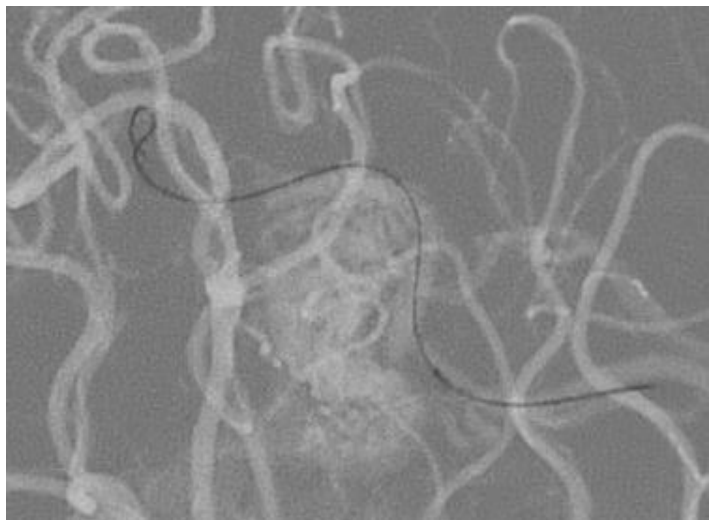
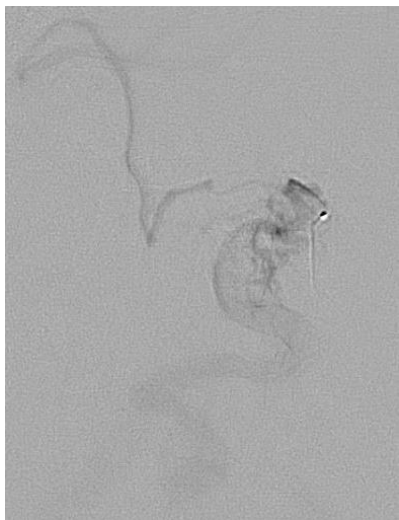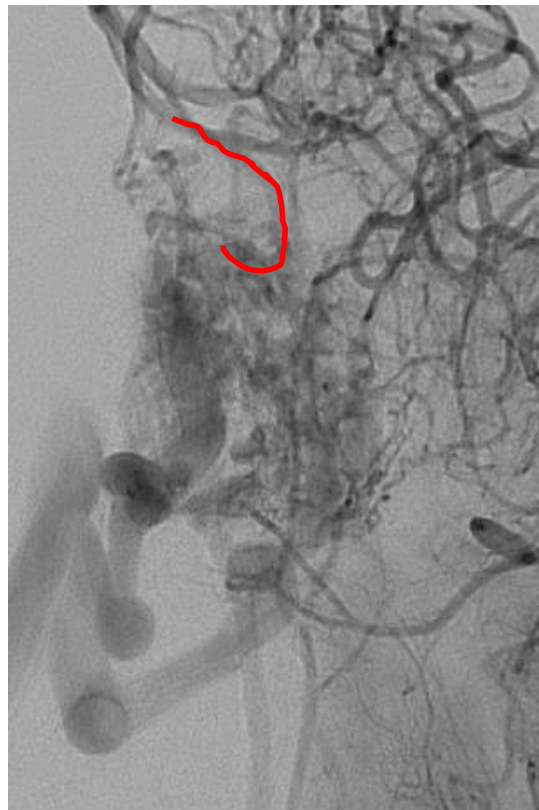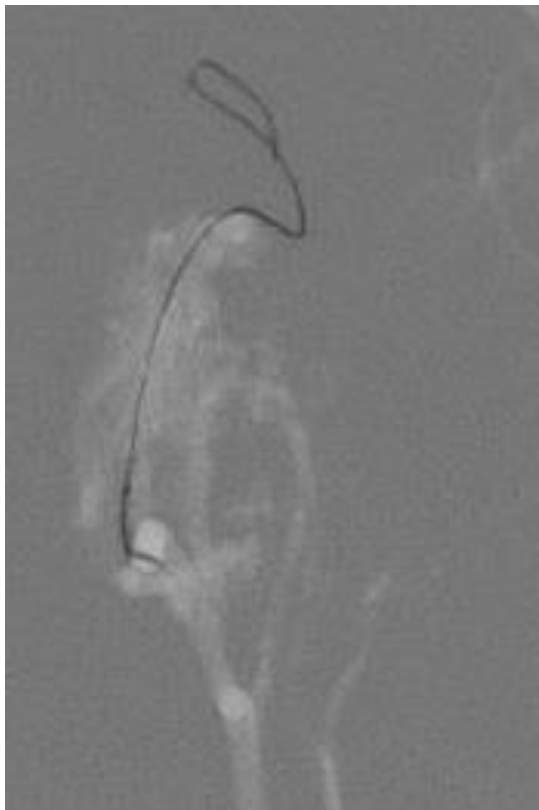
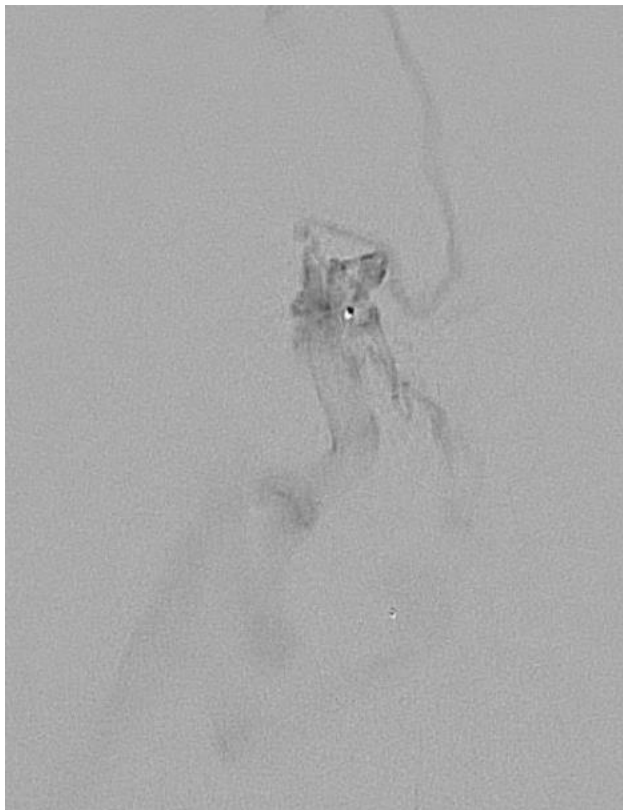
Associate Professor of Radiology and Surgery  
Division of Neuroradiology and Neurosurgery  
University Health Network – University of Toronto, Canada

29-year-old female with ruptured periventricular AVM. GCS 15

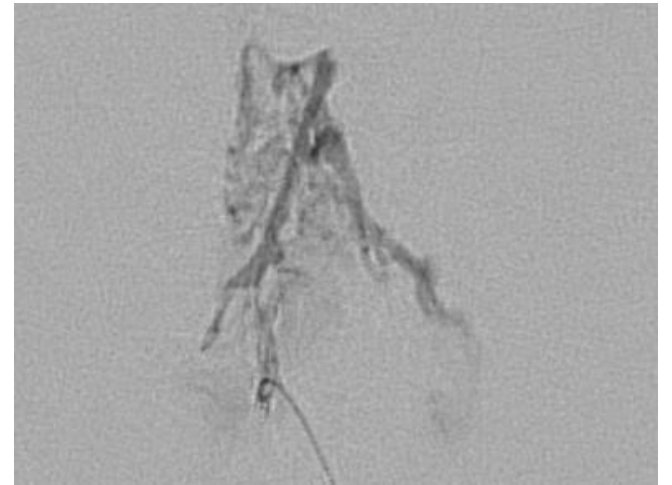
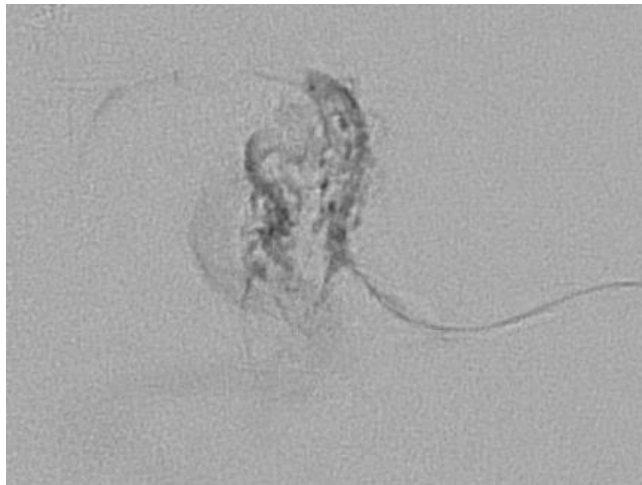
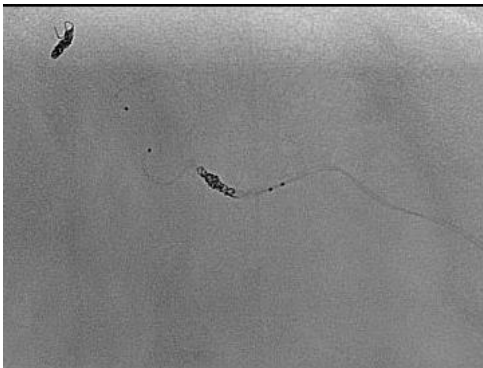
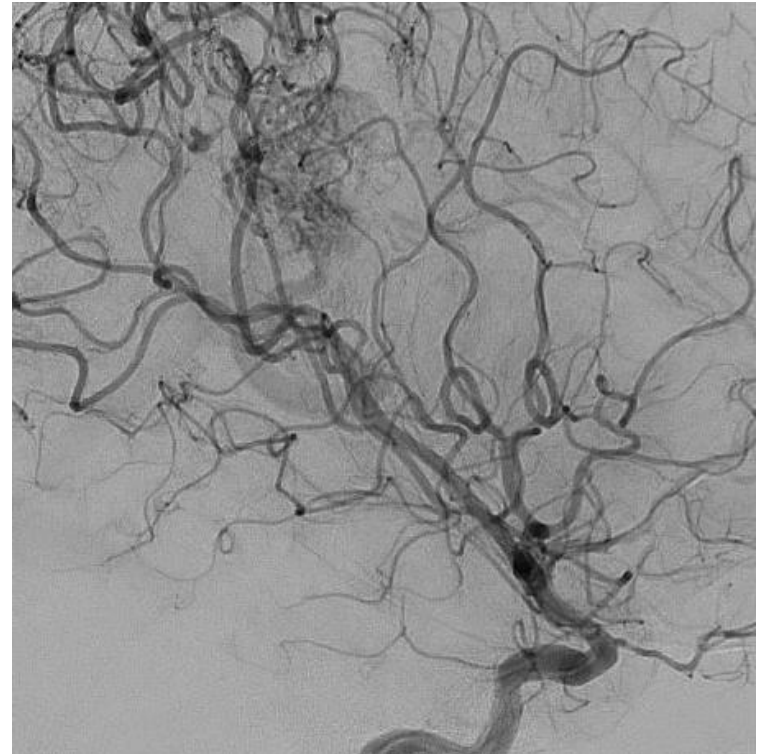
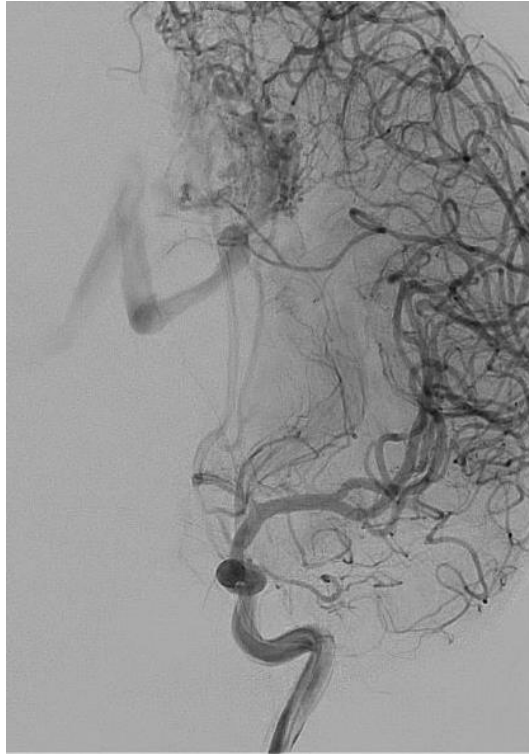
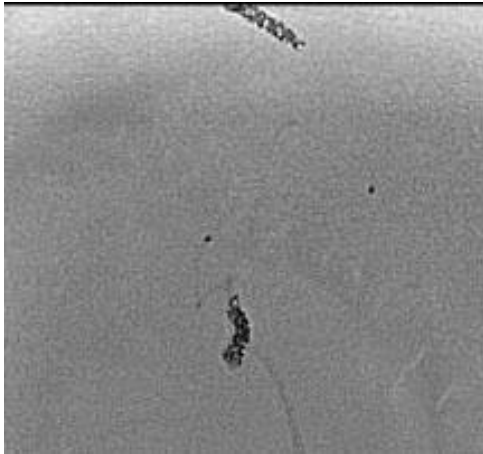


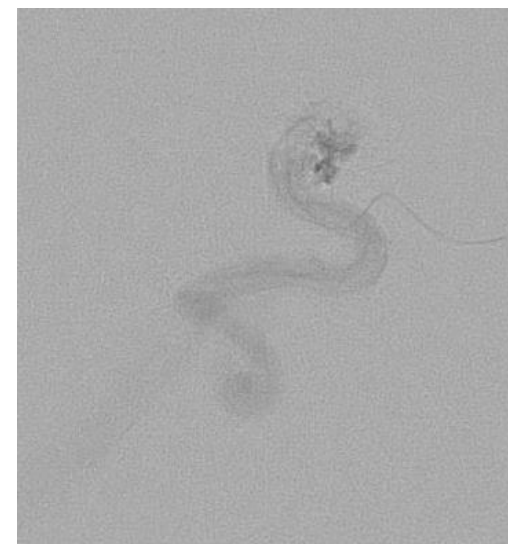
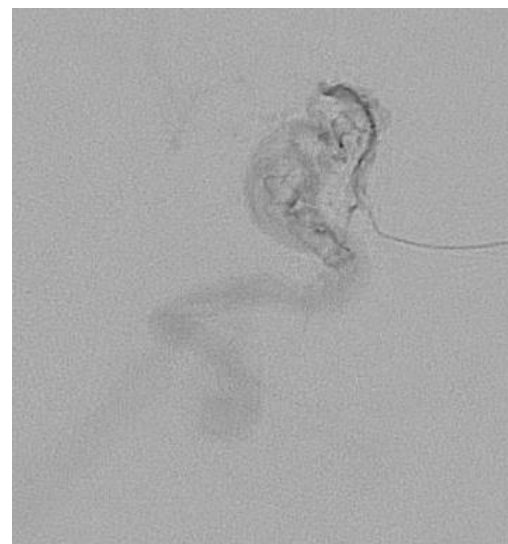
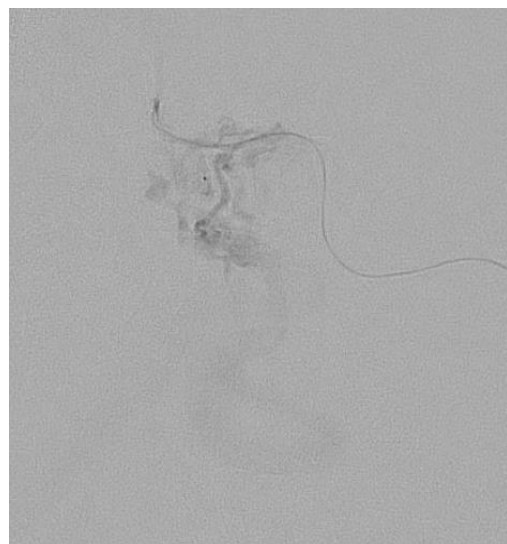
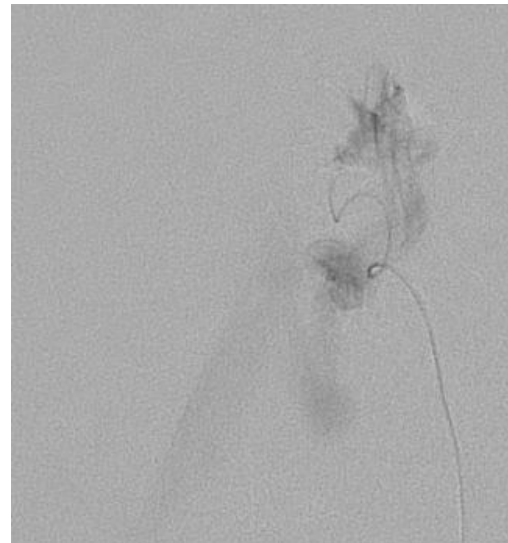
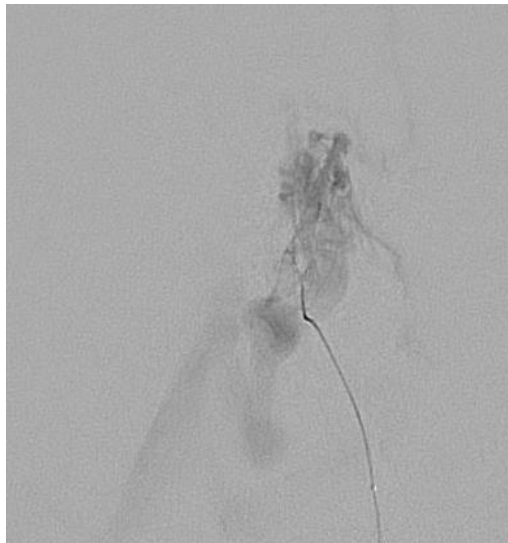
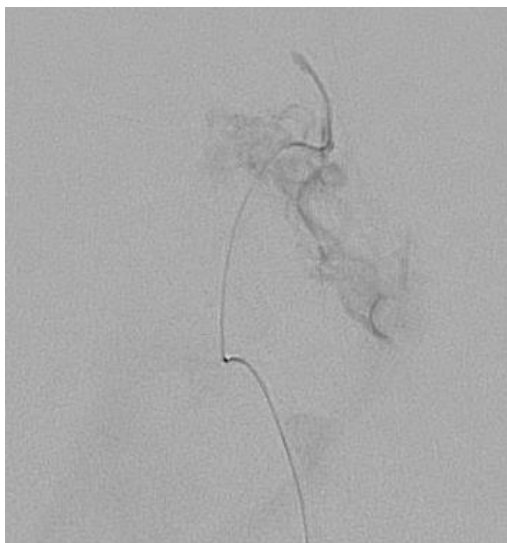






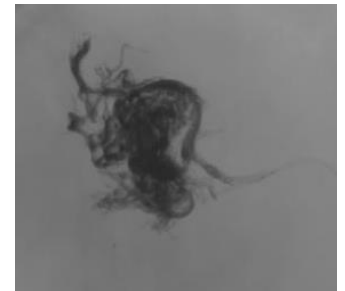
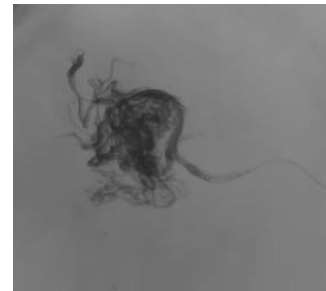
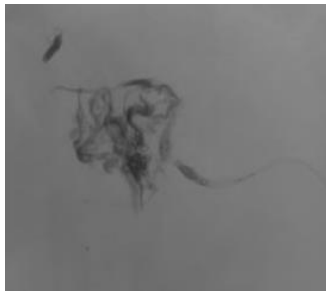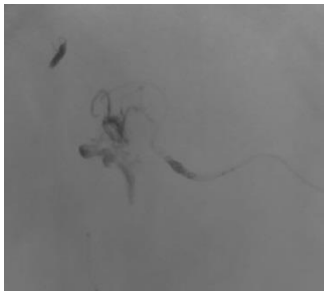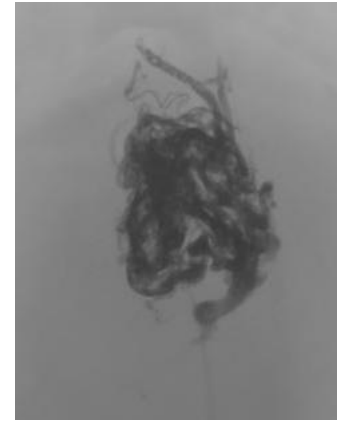
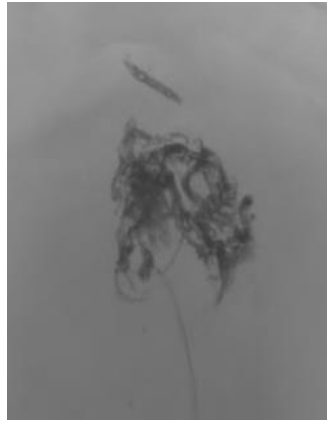
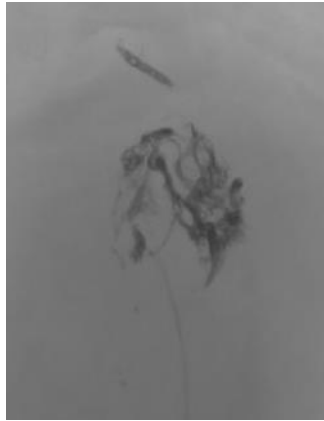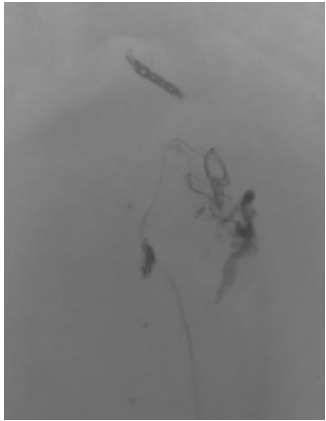
# Post coiling and glue of the micro catheters





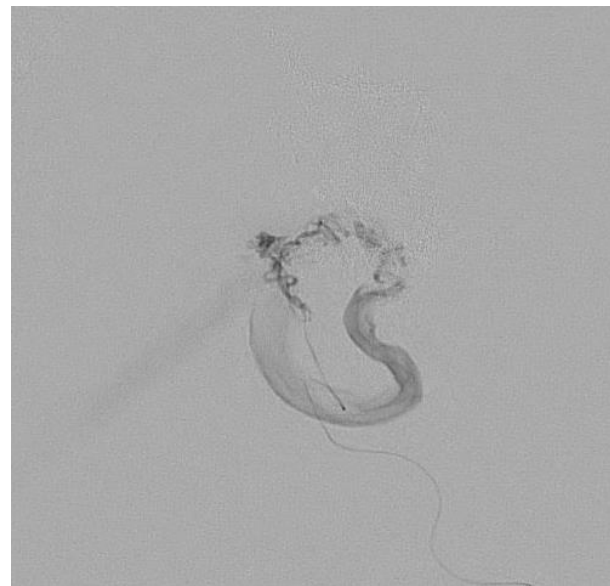
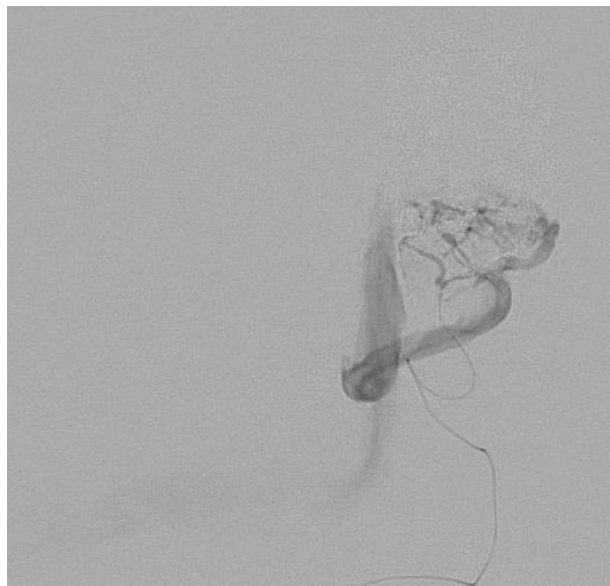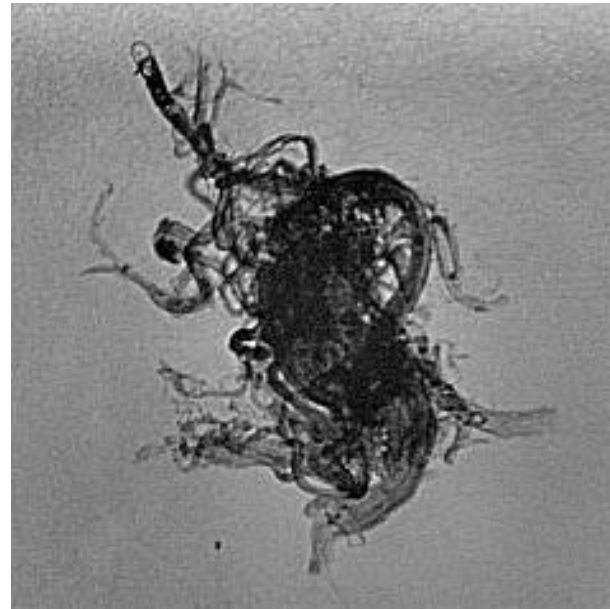
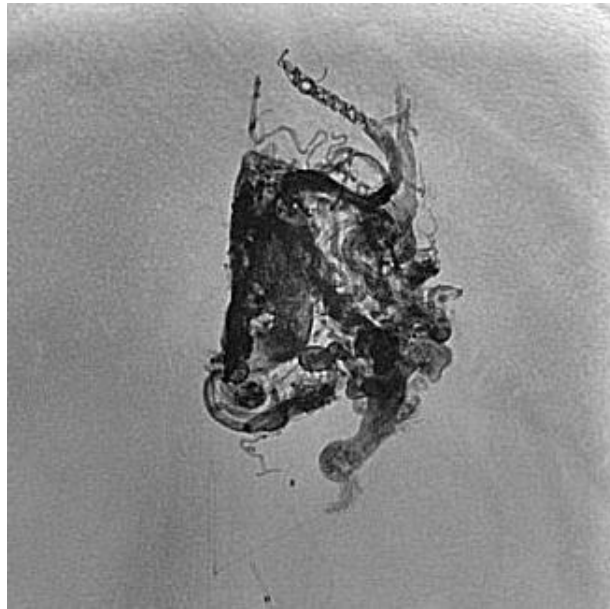
# Onyx progression

---

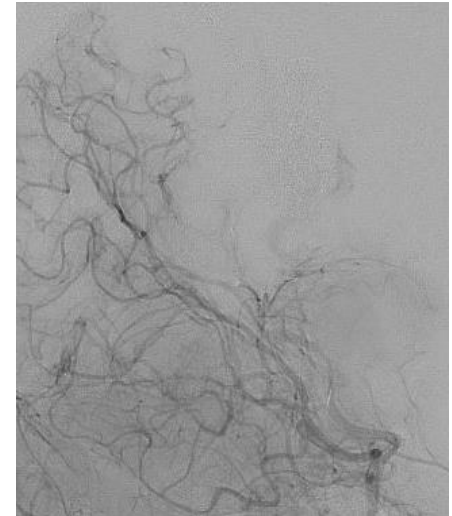
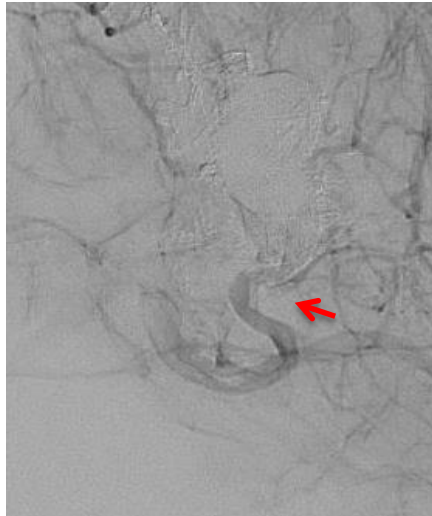
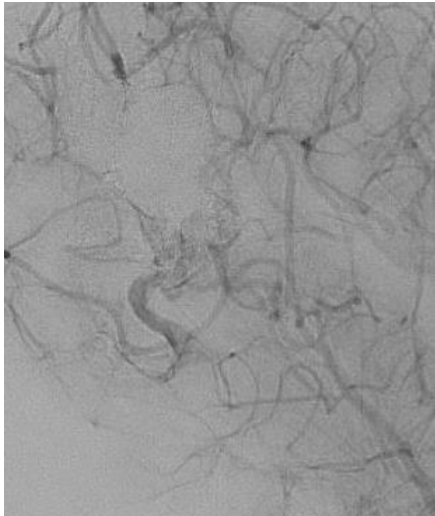
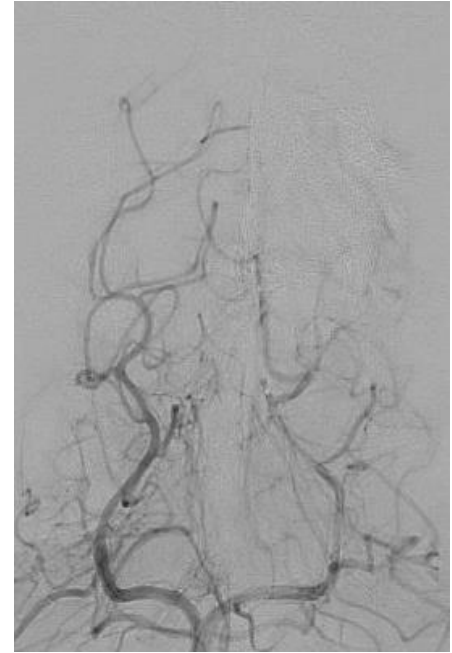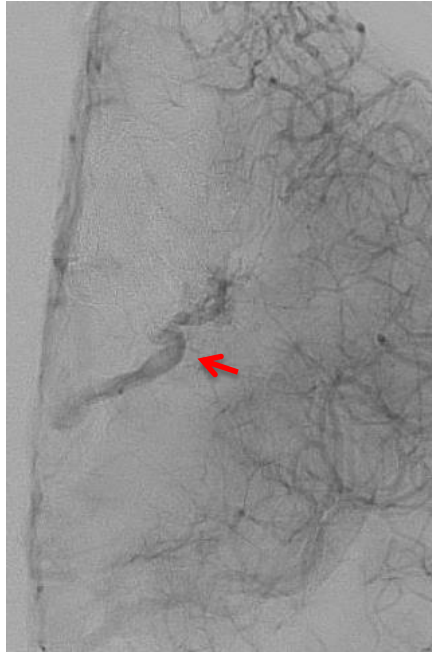
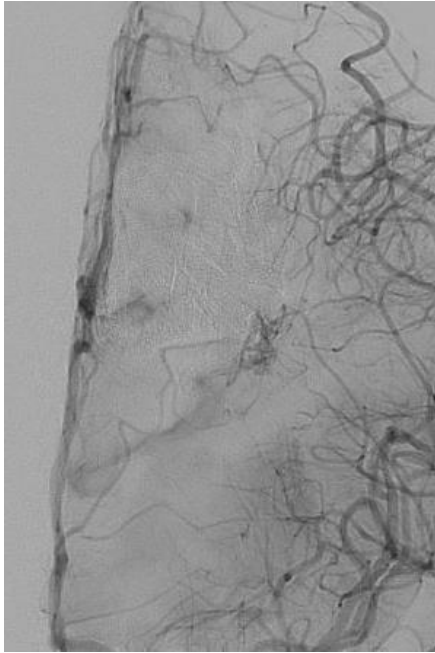




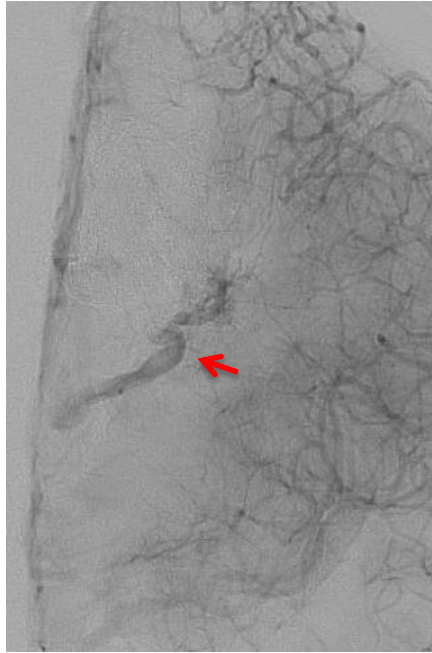
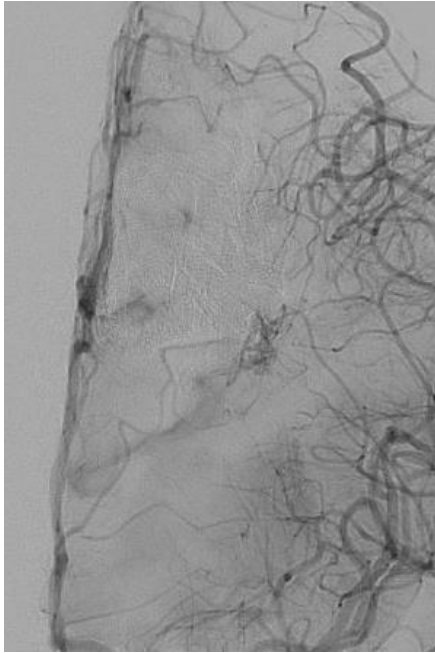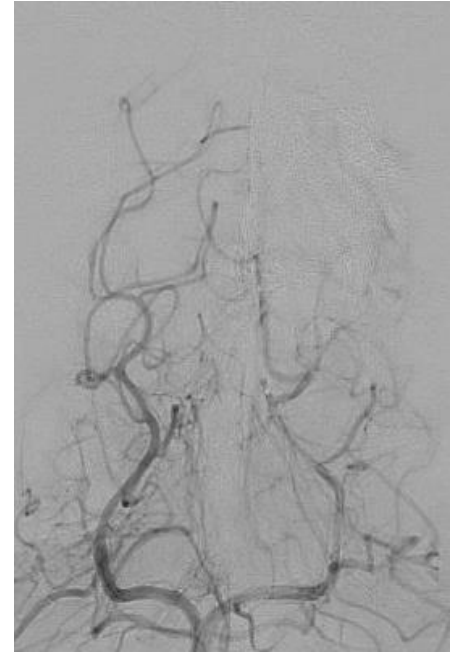
# Cast of Onyx after ACA embolization and microcatheter injection from PChA



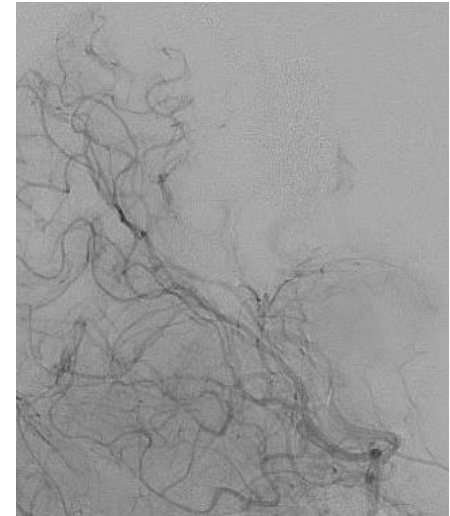
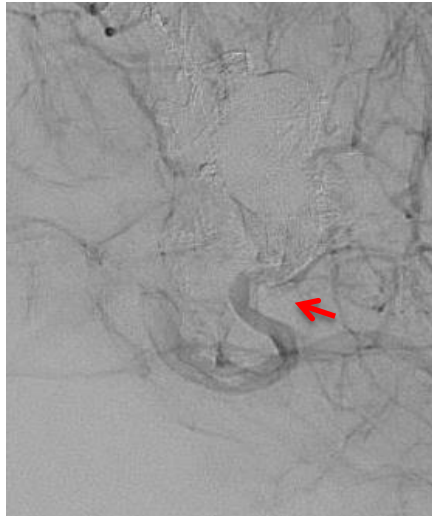
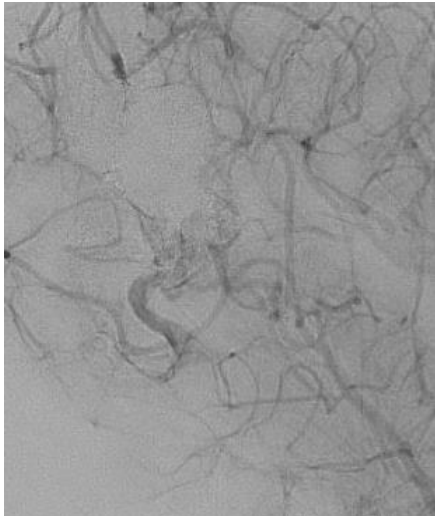
Injection after embolization from PChA – Residual AVM – What to do???



Injection after embolization from PChA – Residual AVM – What to do???



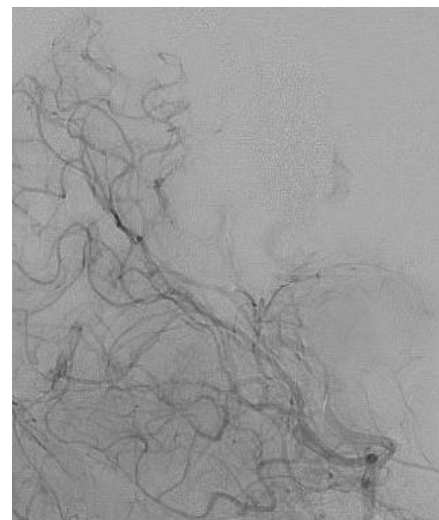
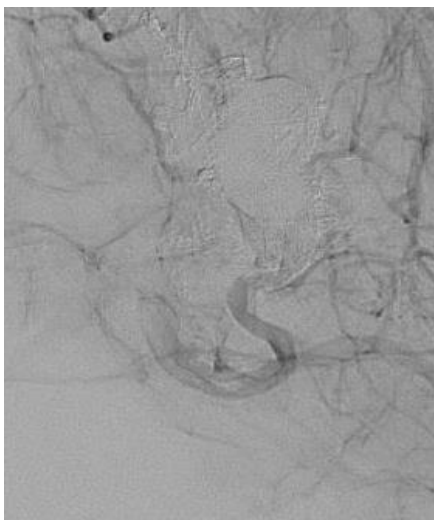
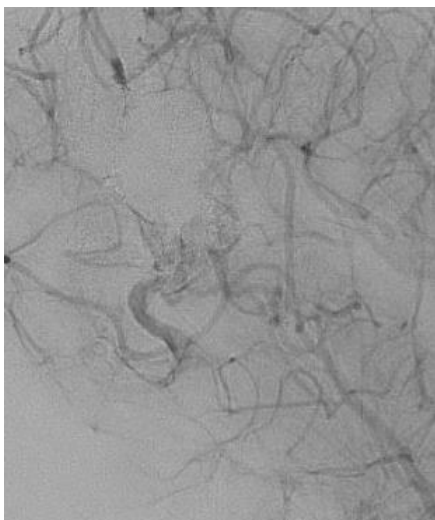
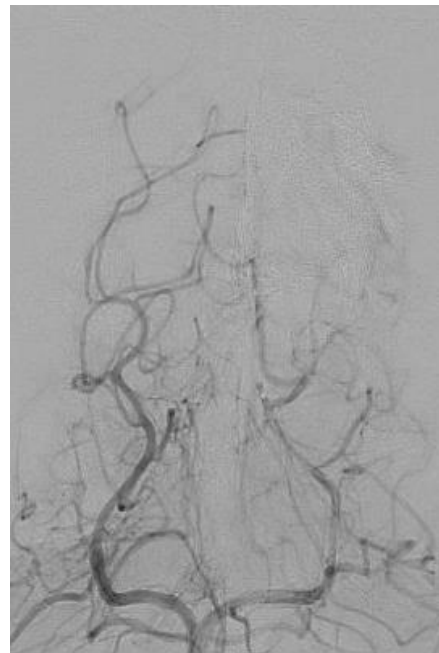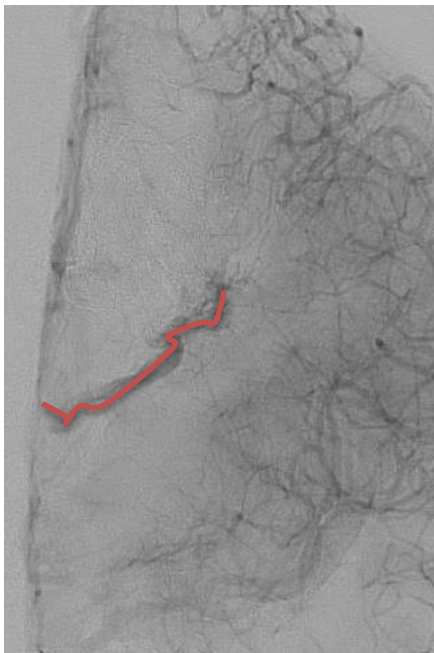
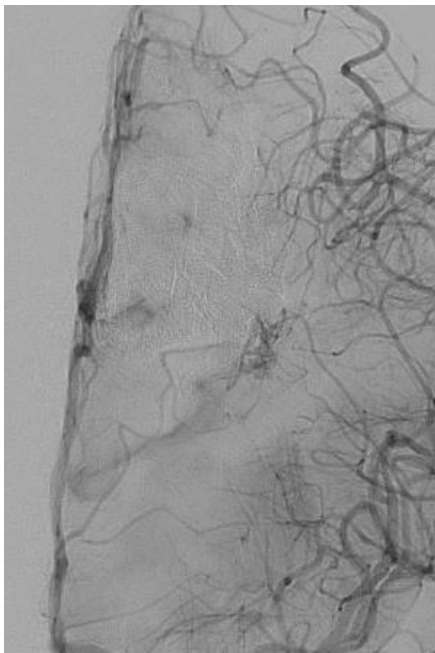
Deep vein partially thrombosed



# Alternatives

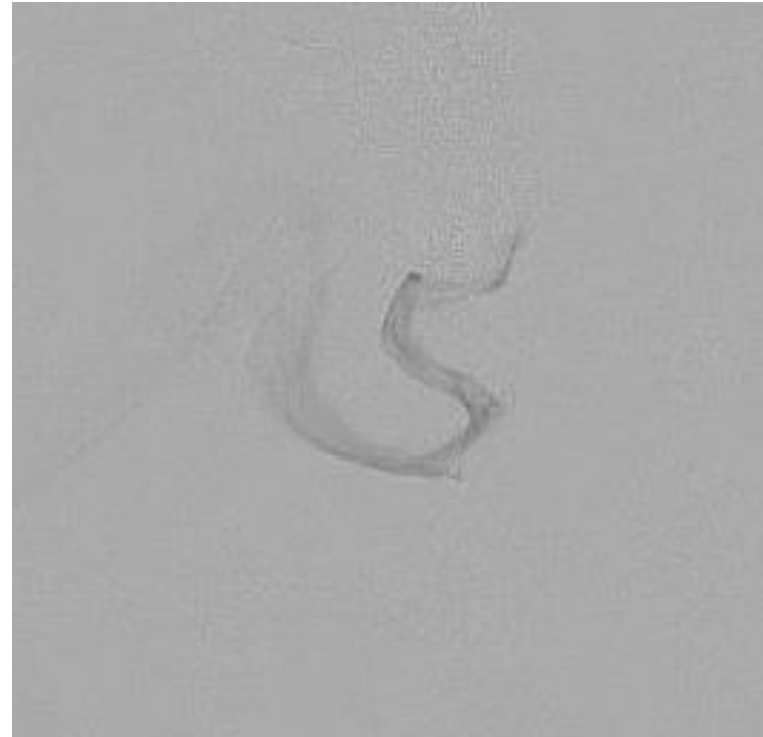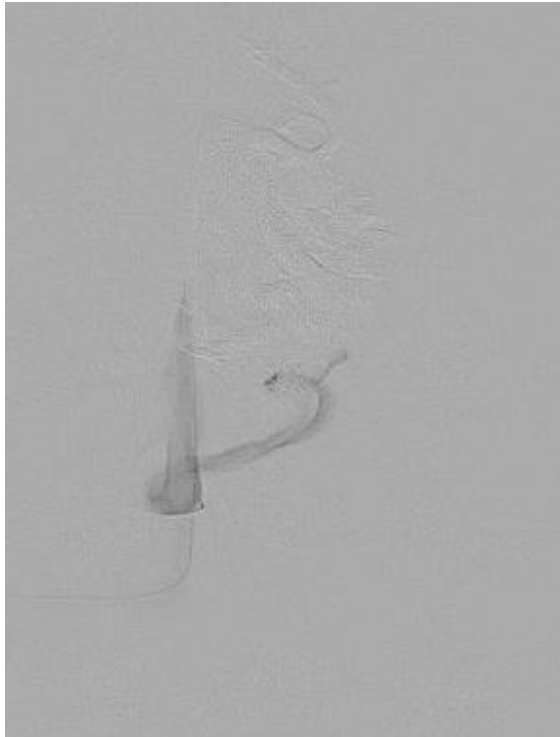
- A – Continue embolization through the thalamic perforators and choroidal arteries
- B – Leave it and complement with radiosurgery
- C – Leave it
- D – Finish the treatment transvenous

# Injection after embolization from PChA



# Transvenous approach


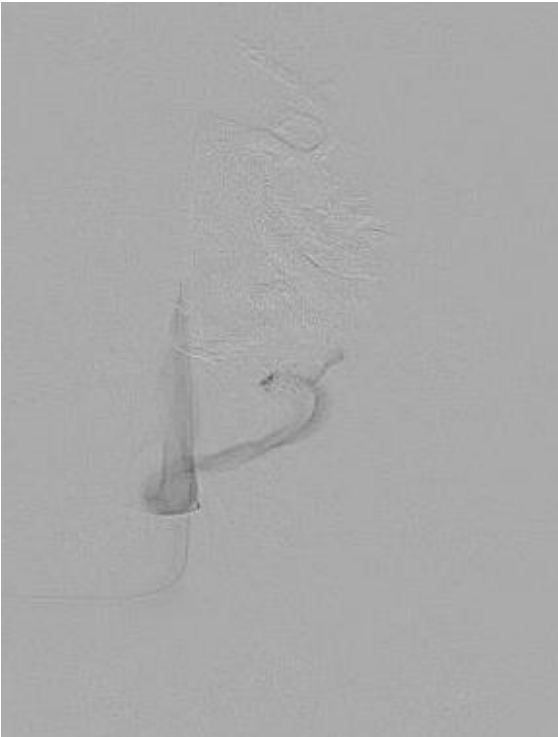
---



Venous injection before final embo

# Transvenous approach

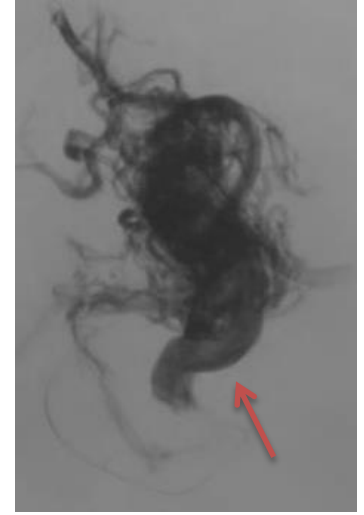
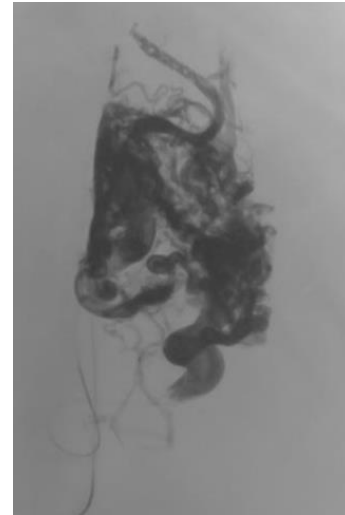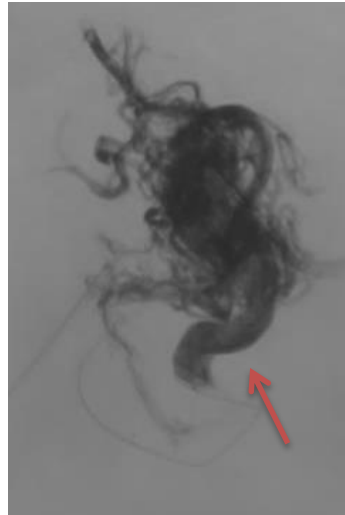
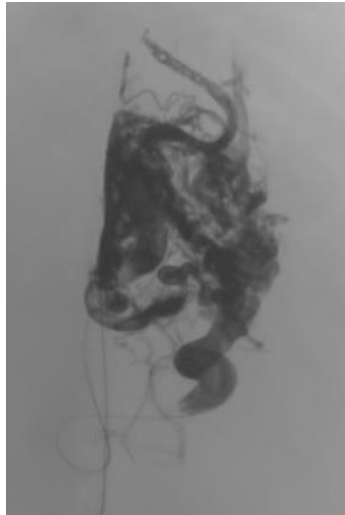
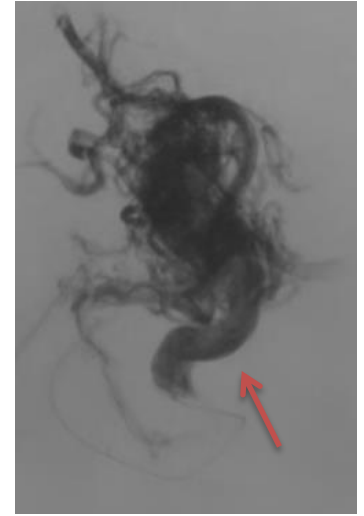
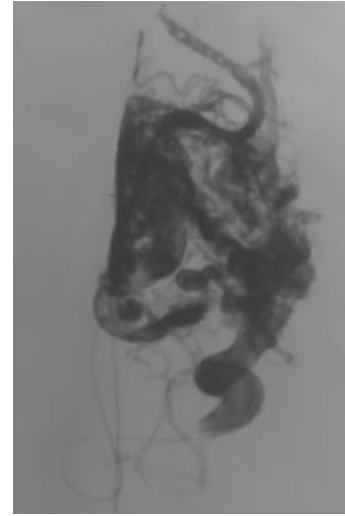
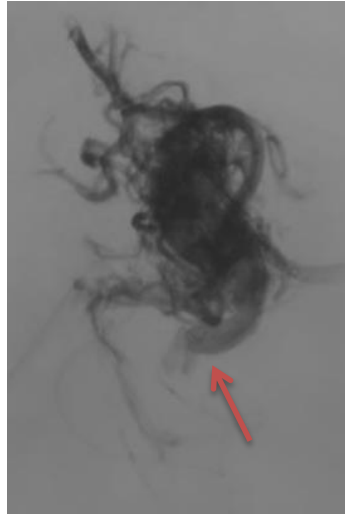
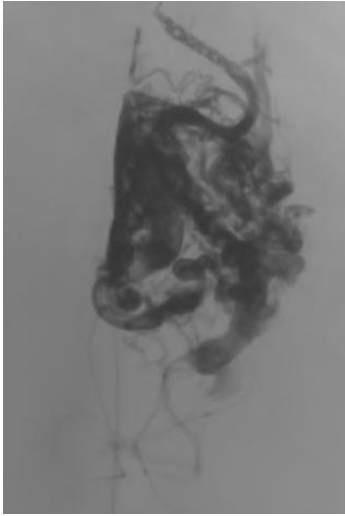
---



Venous injection before final embo

# Transvenous approach

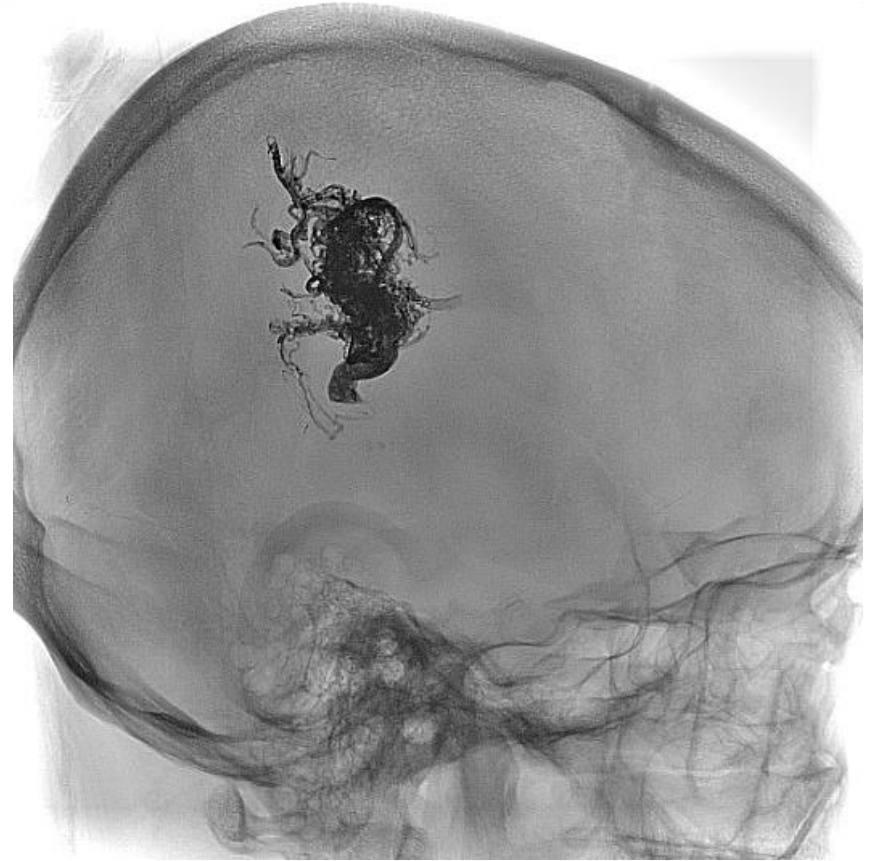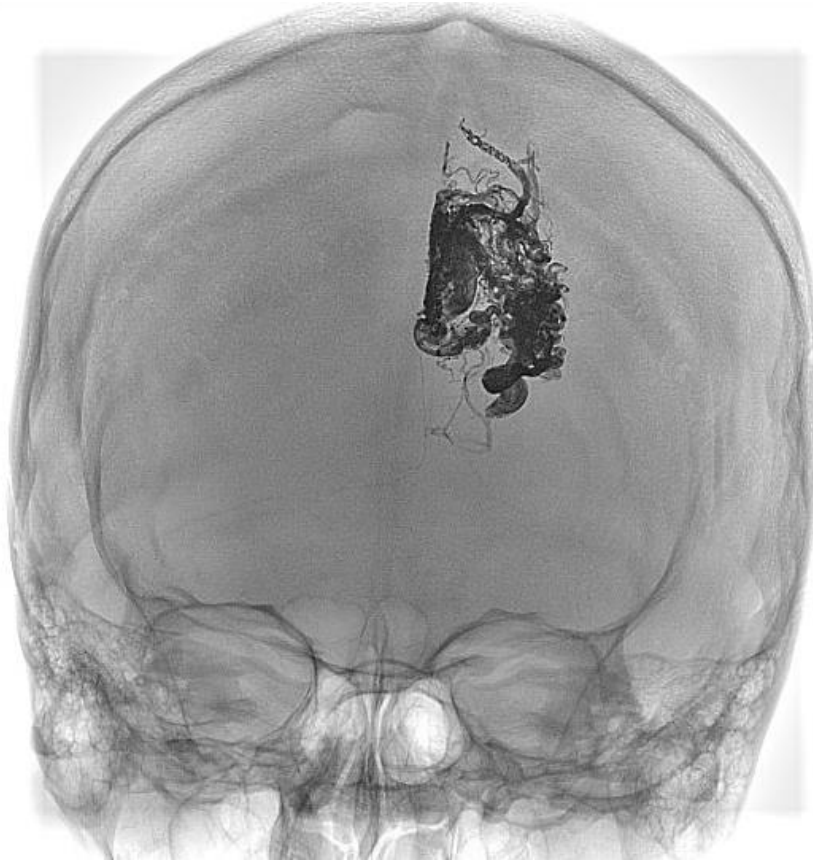
---

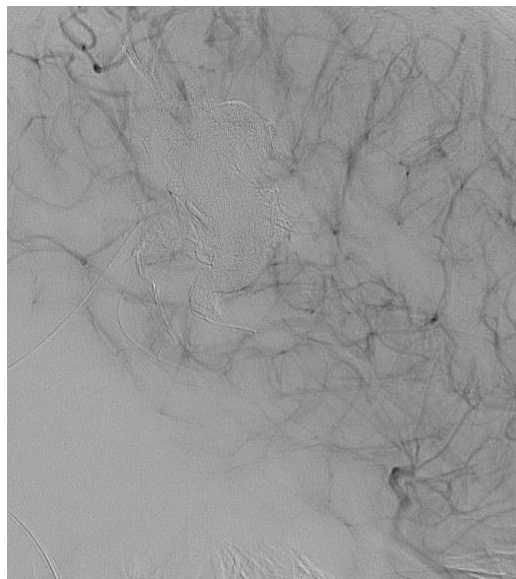
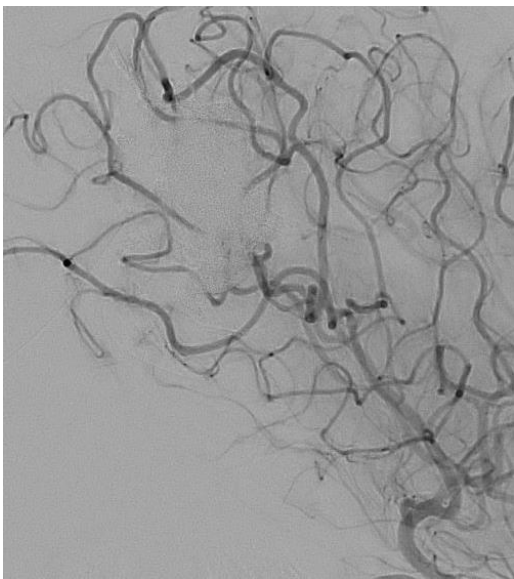
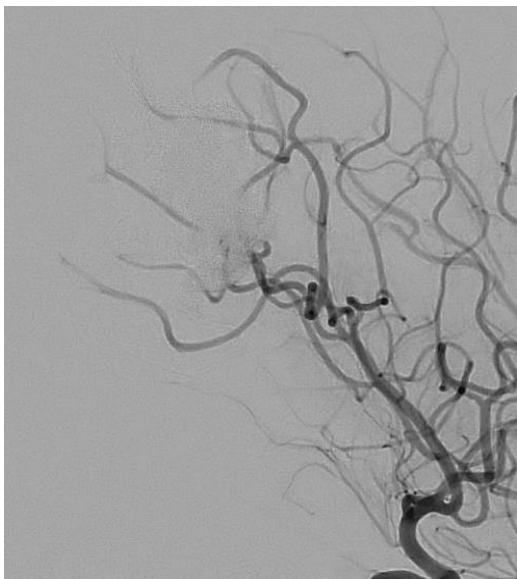
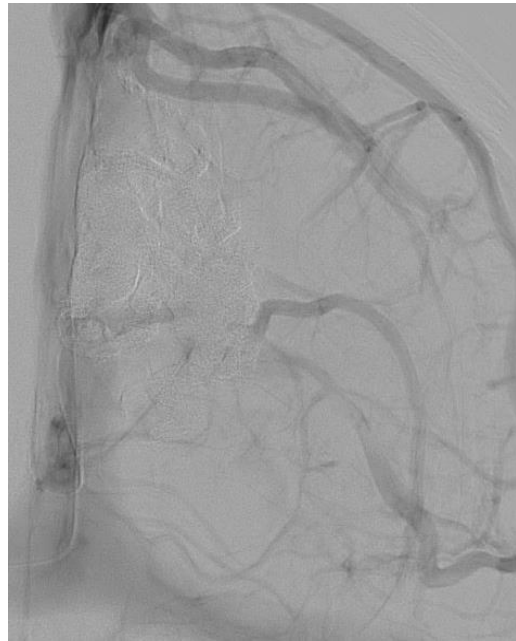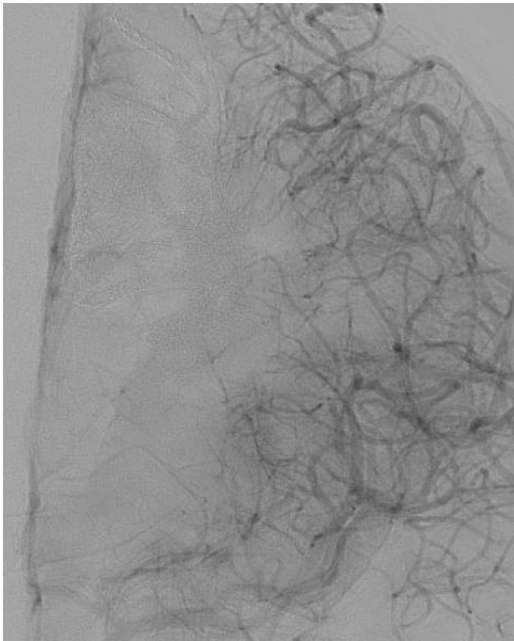
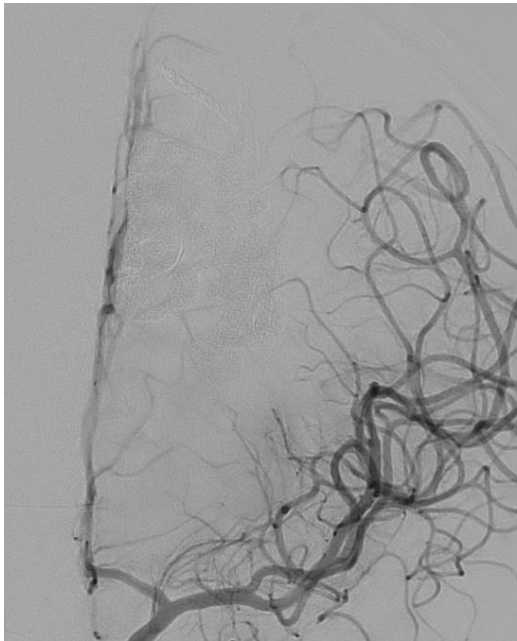


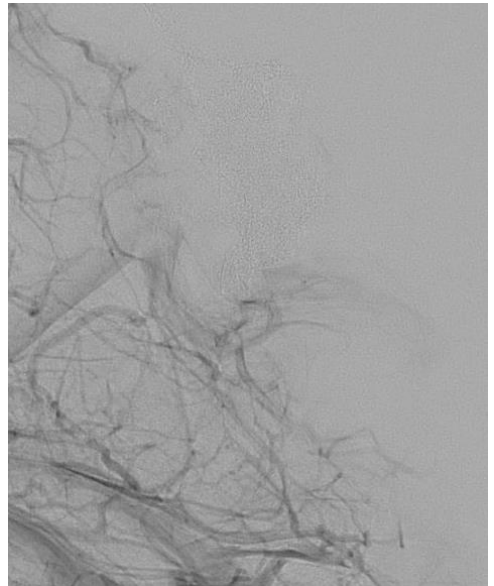
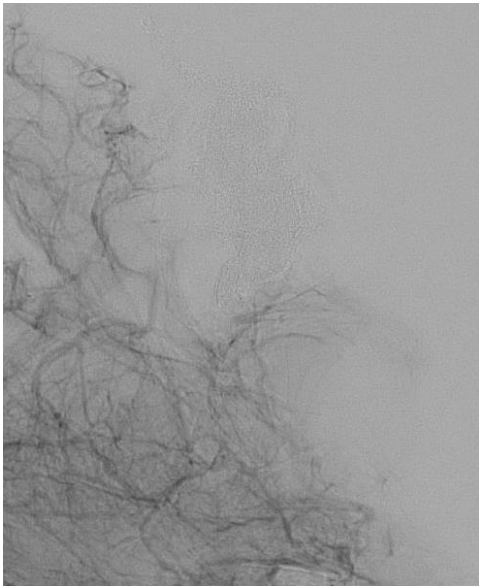
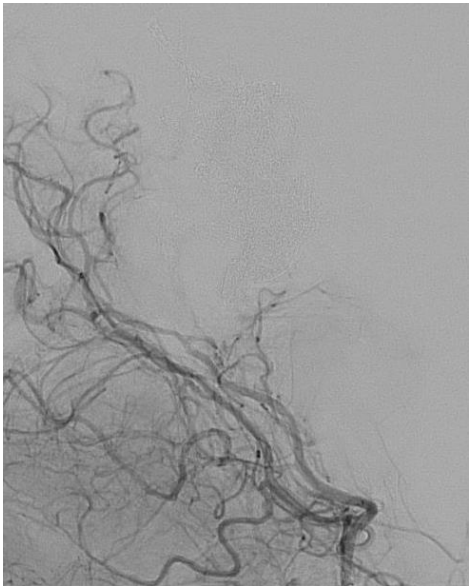
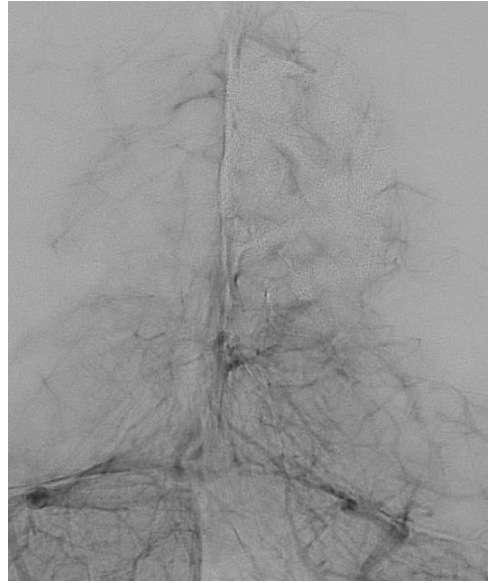
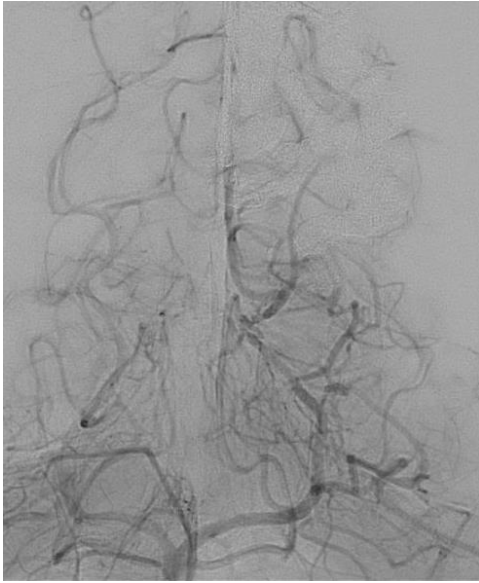

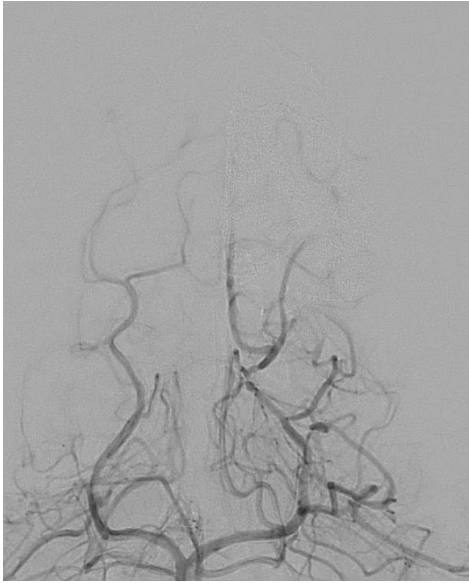
# Final Onyx cast

---



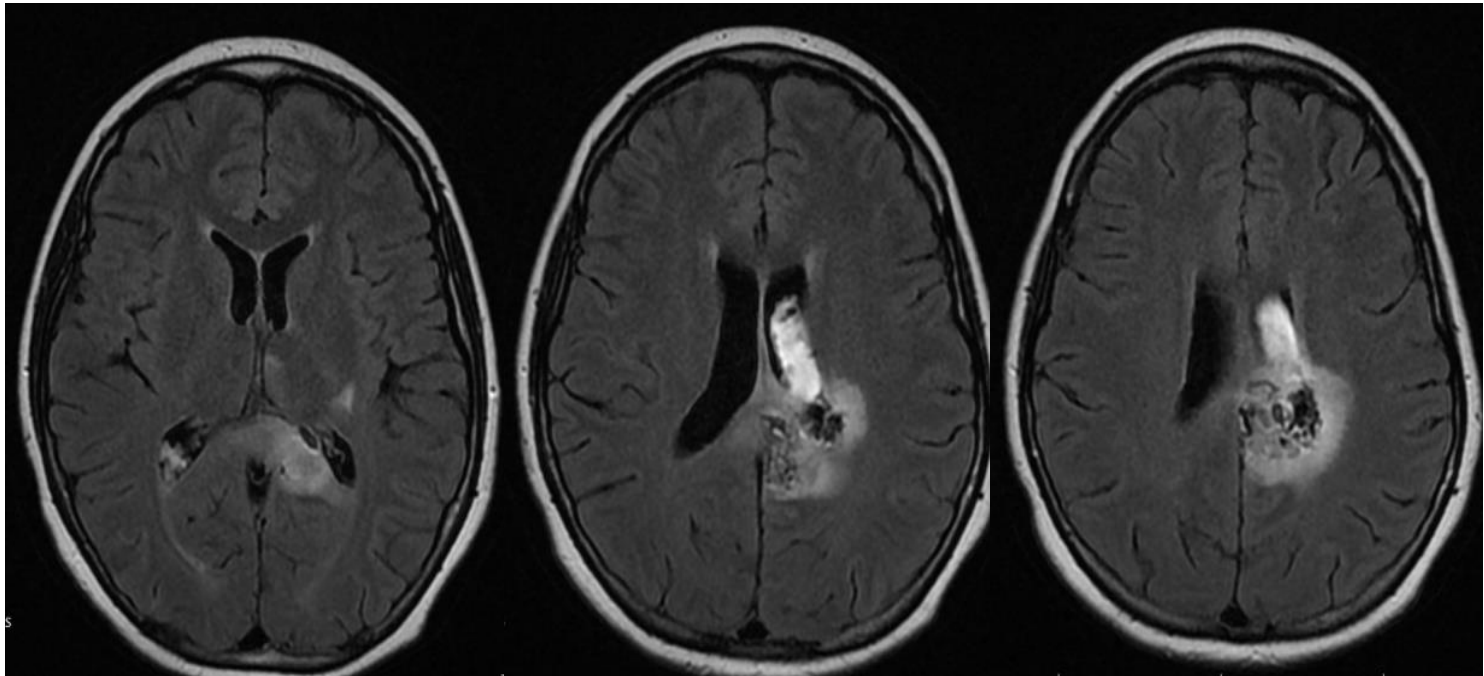




# Follow up

---

## 5-day MRI



Discharged home after 7 days. MRS 1

# Thanks for your attention

[vitor.pereira@uhn.ca](mailto:vitor.pereira@uhn.ca)

[vitormpbr@hotmail.com](mailto:vitormpbr@hotmail.com)

I. Radovanovic M. Tymianski K. terBrugge T. Krings R. Agid M Schwartz



