

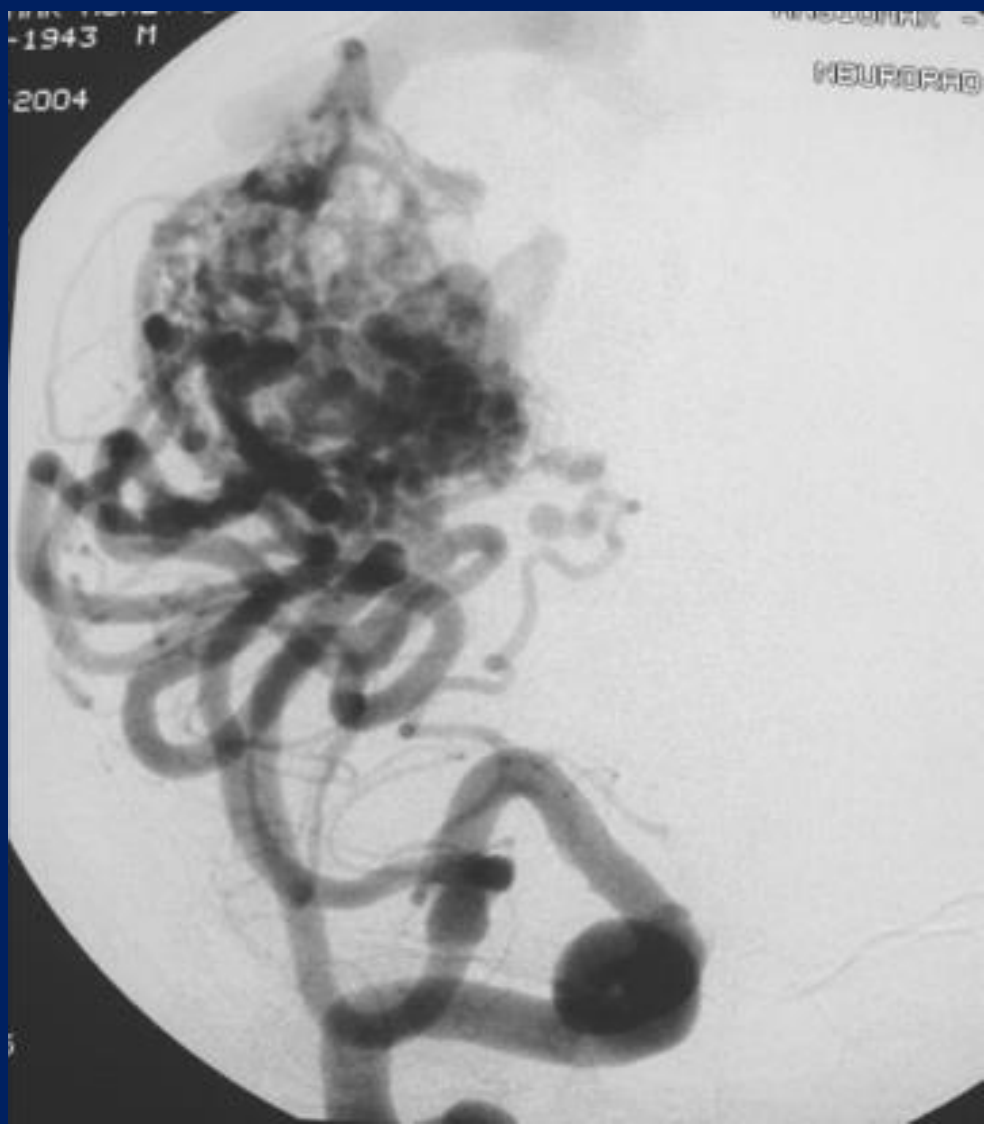
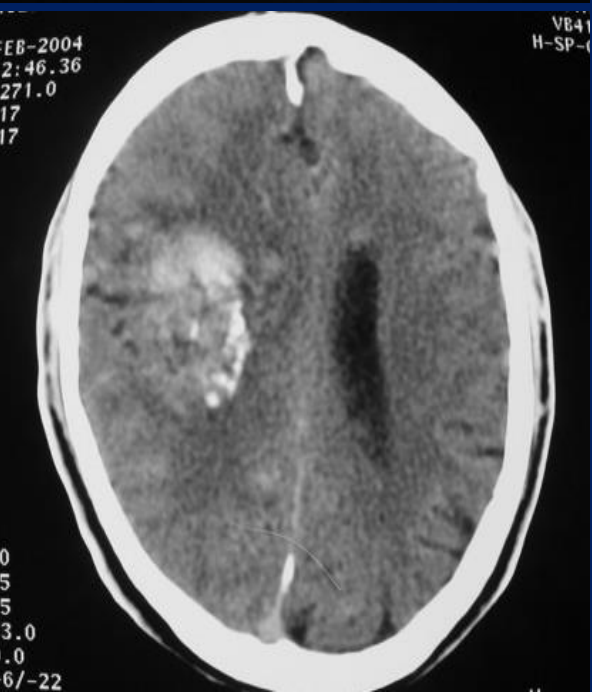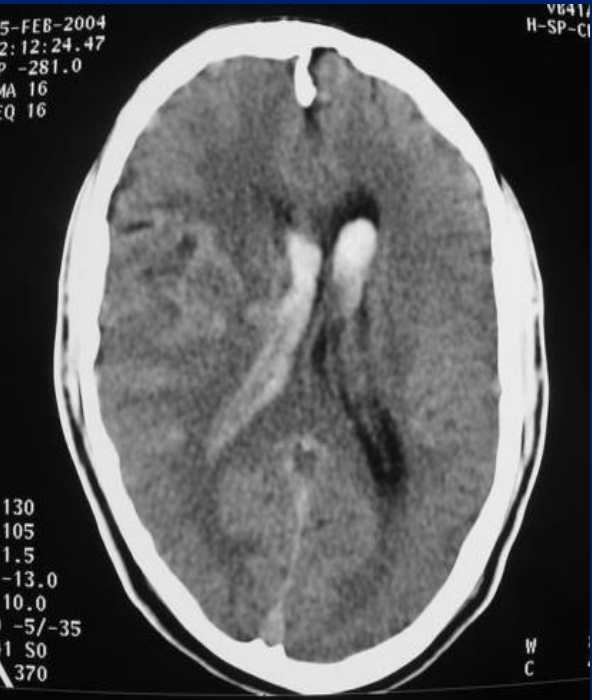BAVM – ruptured LEA hyperflow aneurysm

How manage it?

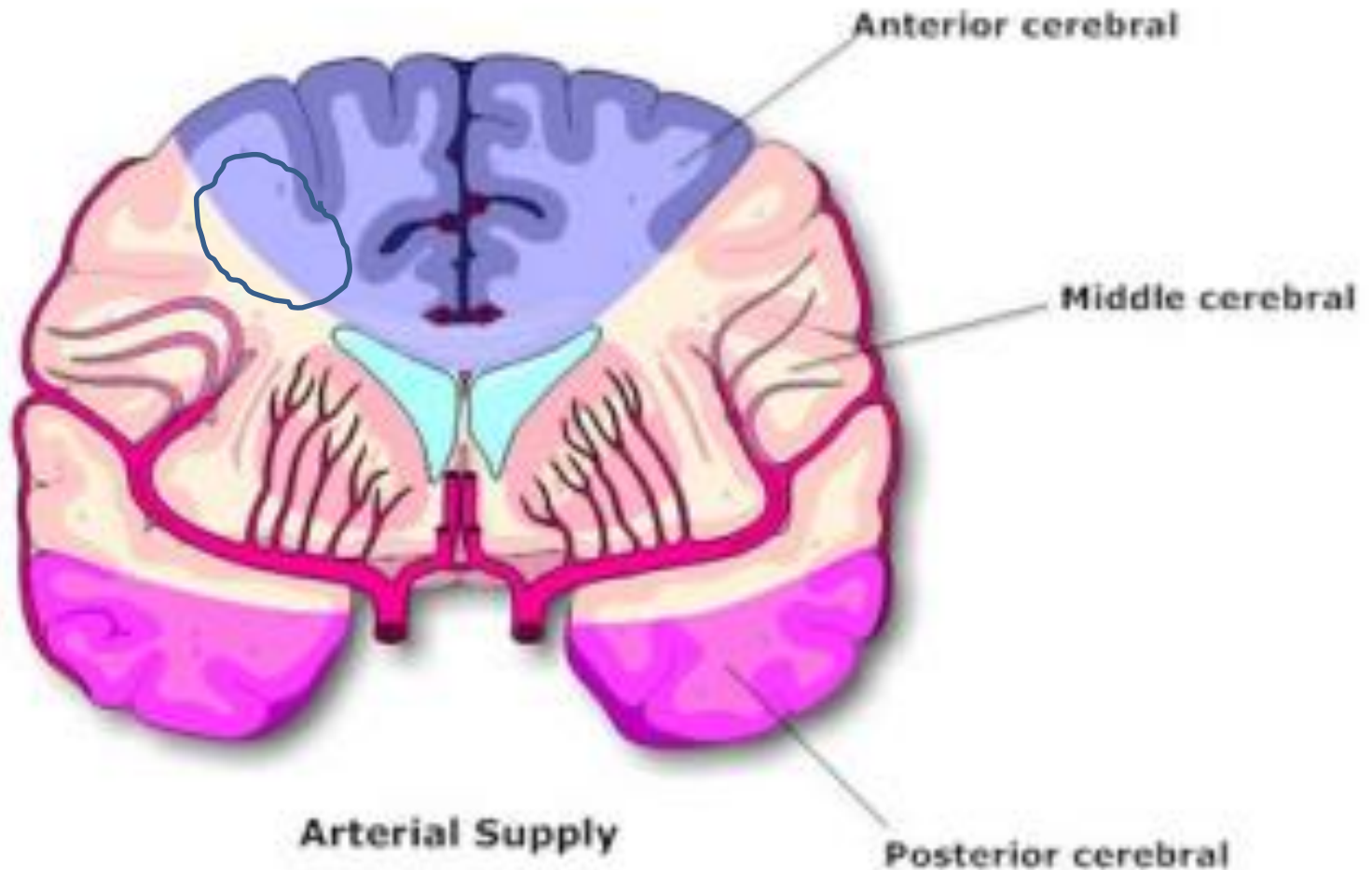
Ronie Leo Piske, MD, PhD

Hospital Beneficiencia Portuguesa de São Paulo, Brazil

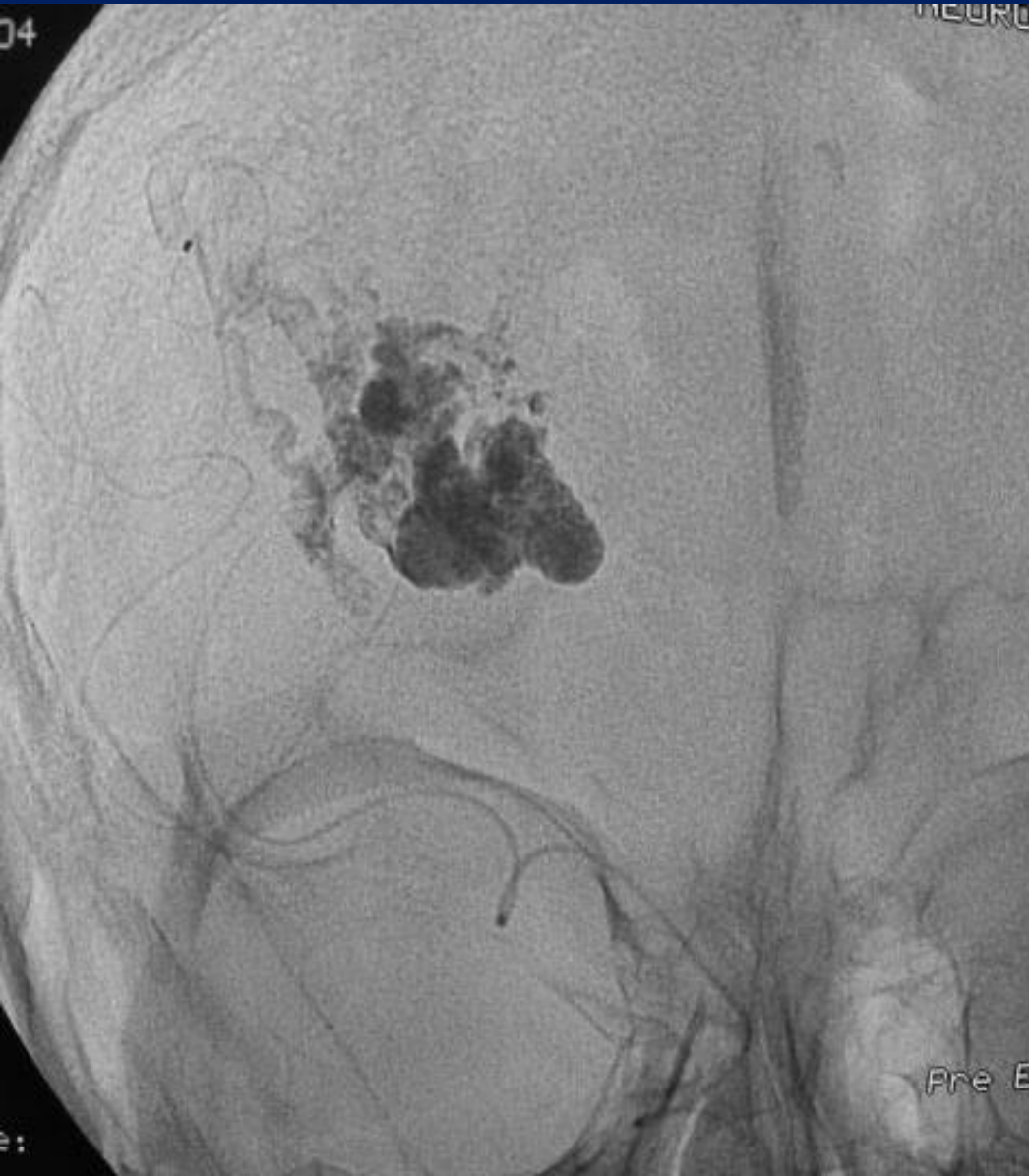61 yom, cardiac failure.



LEA give collateral circulation to the deepest part of the nidus

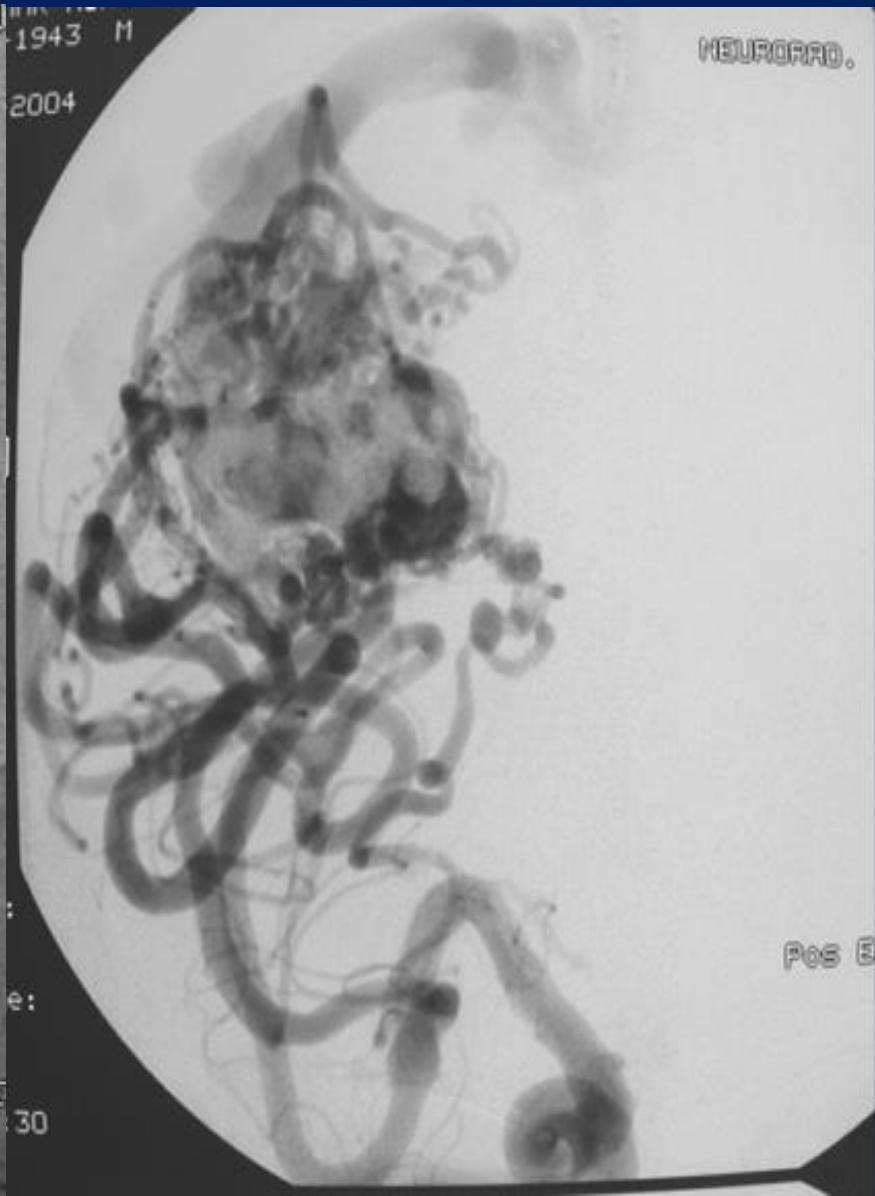


04



NEURO 1943 H

2004



NEURORAD.

Pos E

Pre E 30

Regression of the collateral circulation and the aneurysm
by occluding the deep part of the nidus

