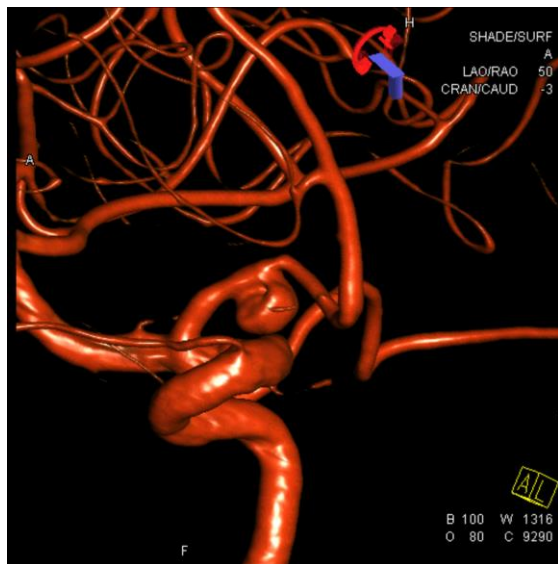
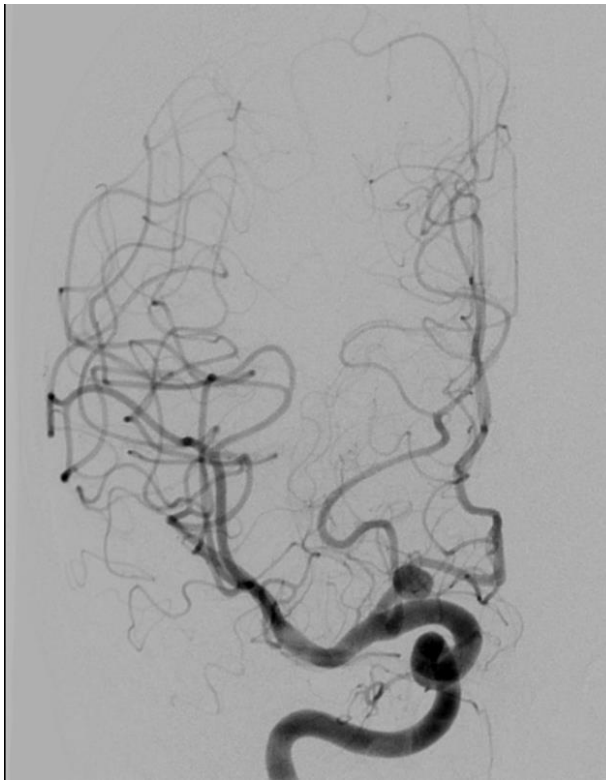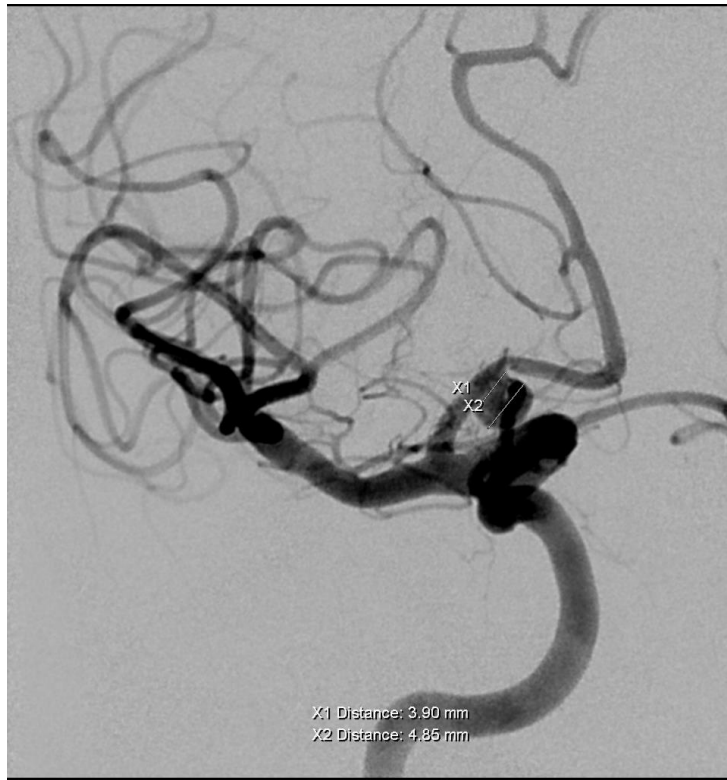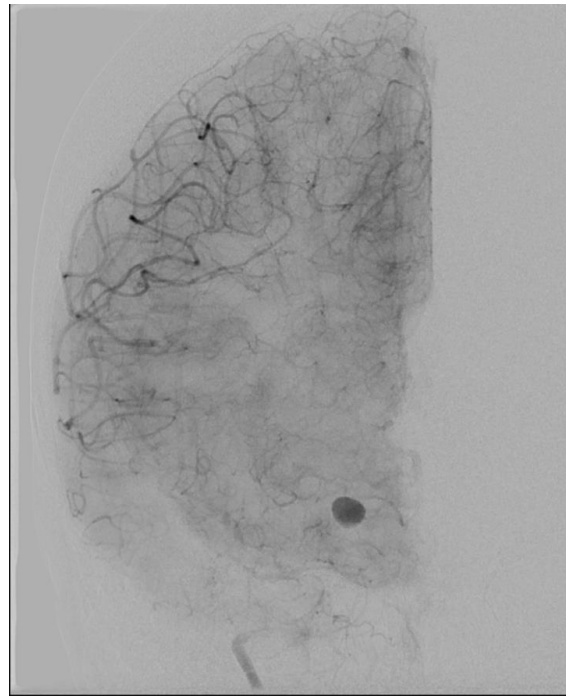
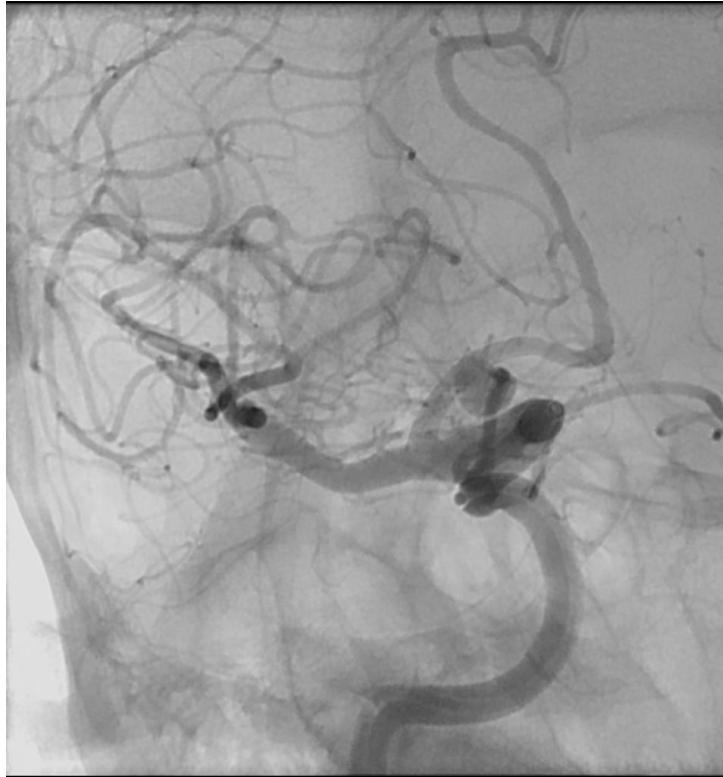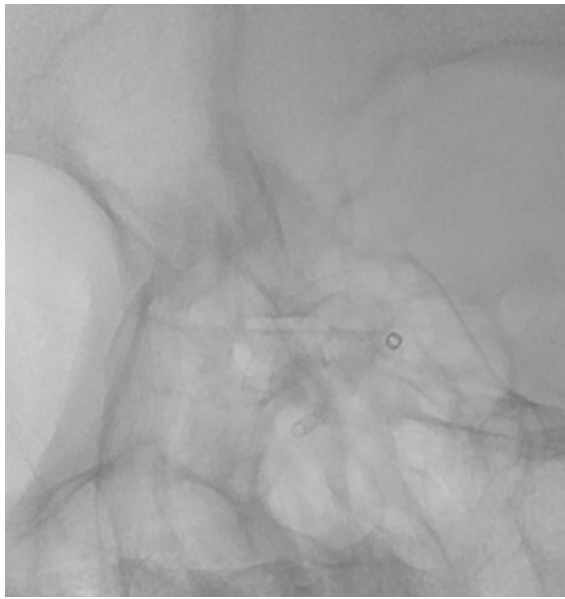


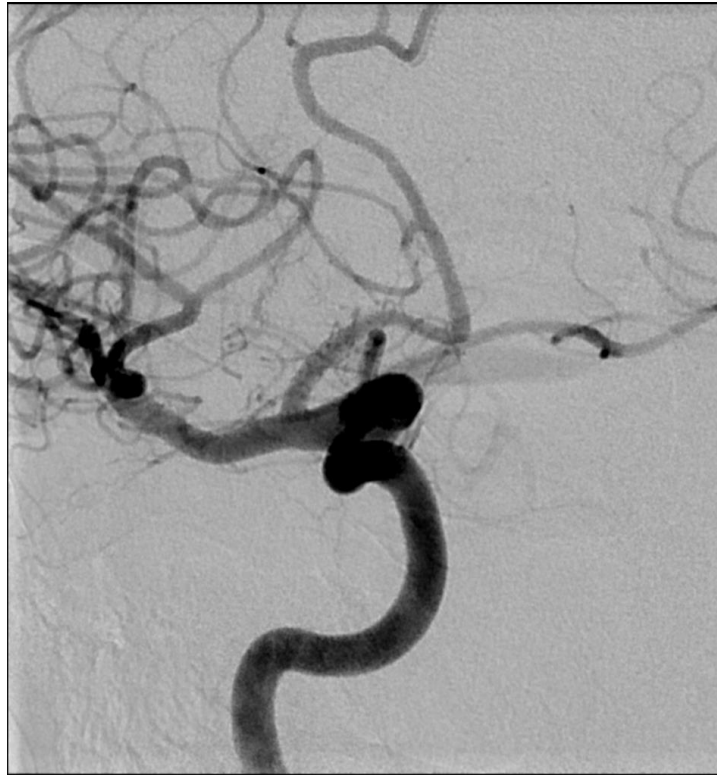
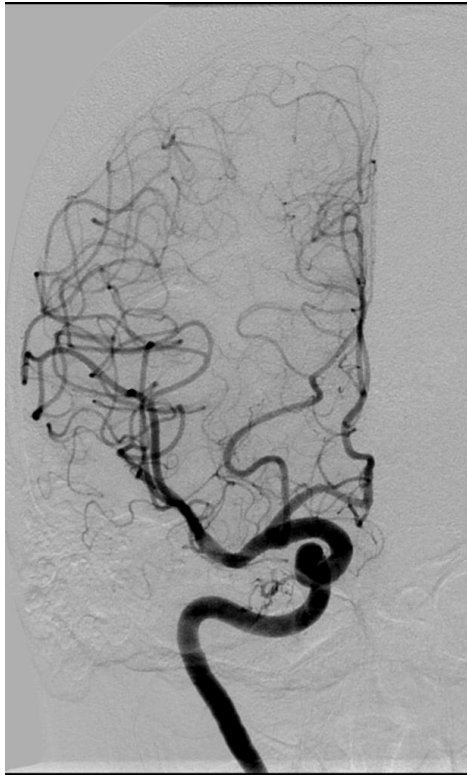
74 y.o. woman

Hx of Right parietal for pituitary
lesion





3 month follow-up



1 year follow-up

< 3.303 - 303 (ALL) >

