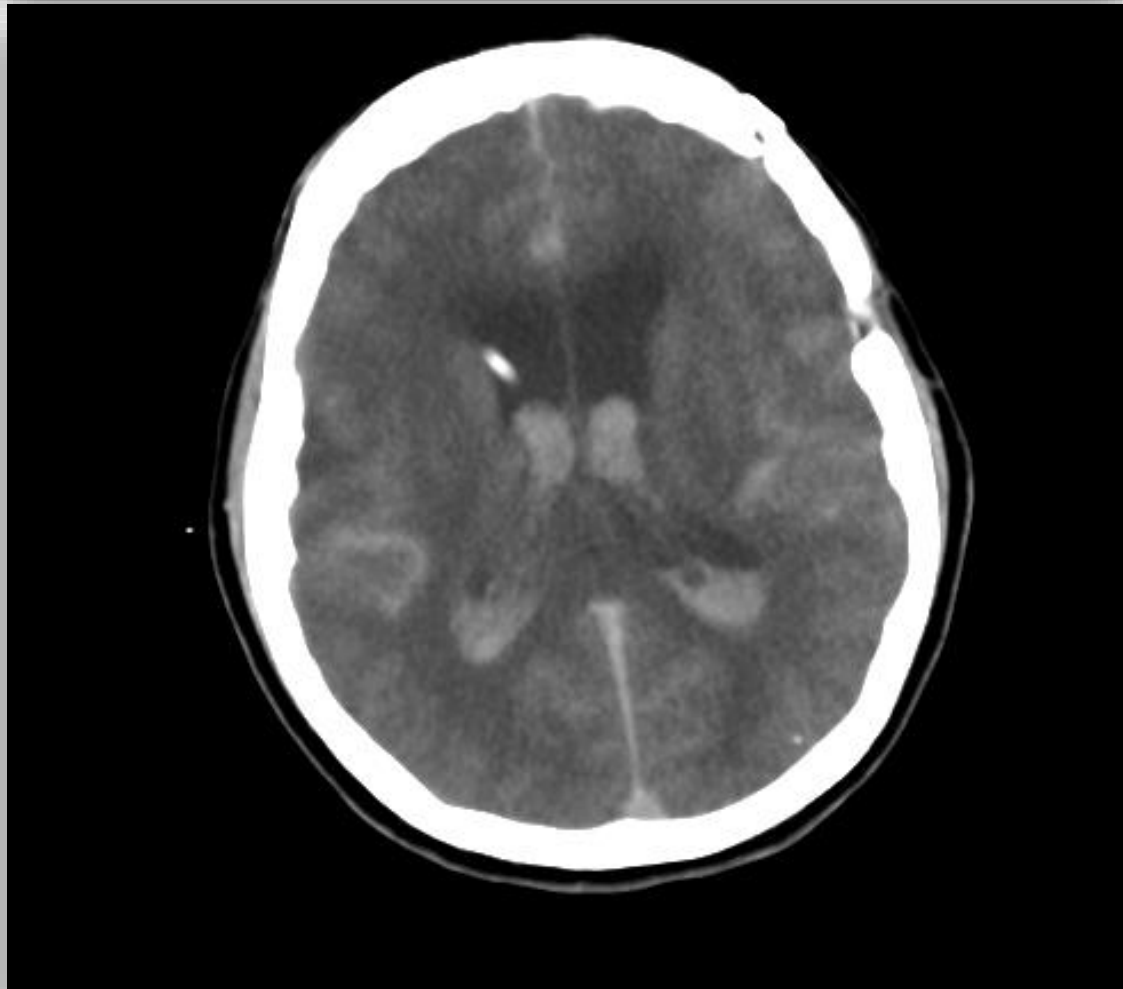
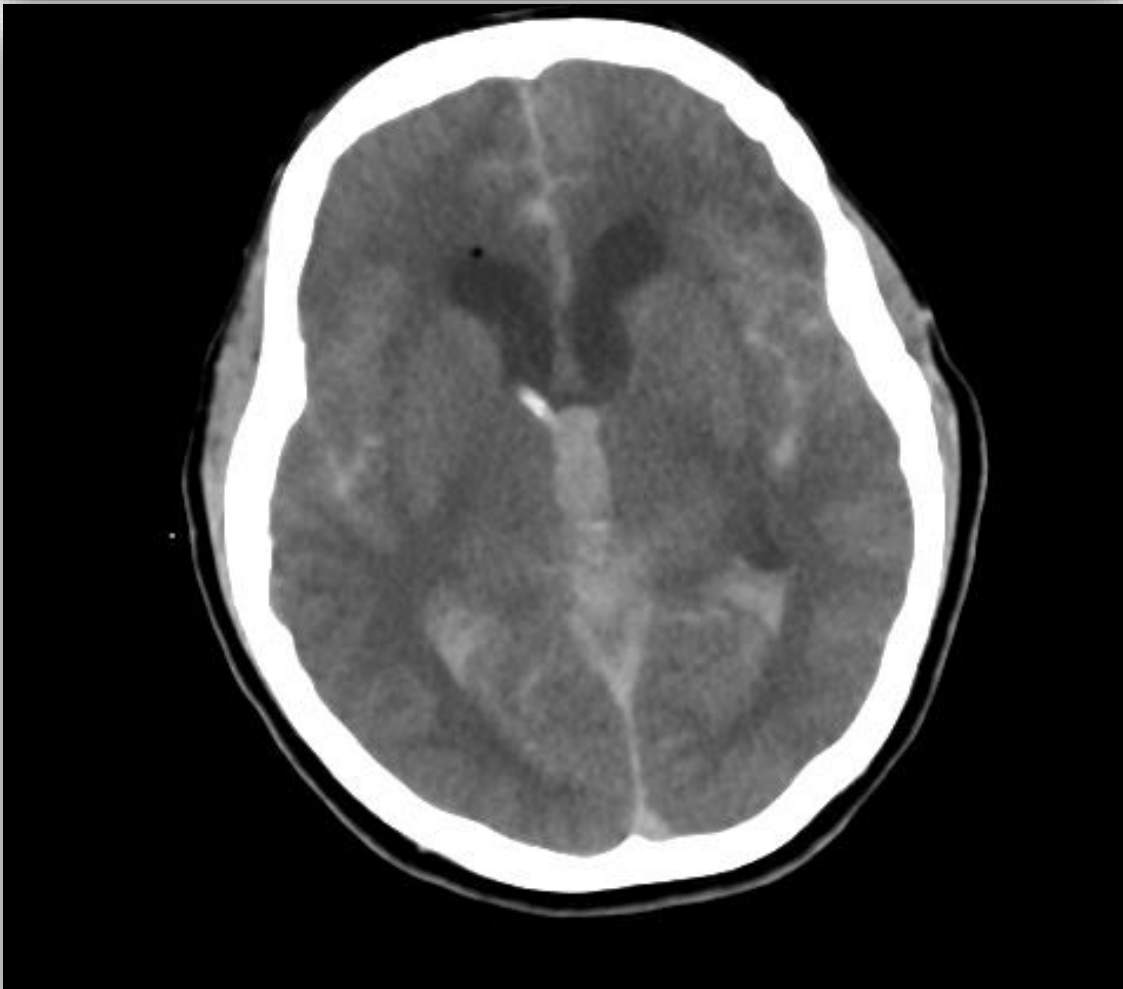
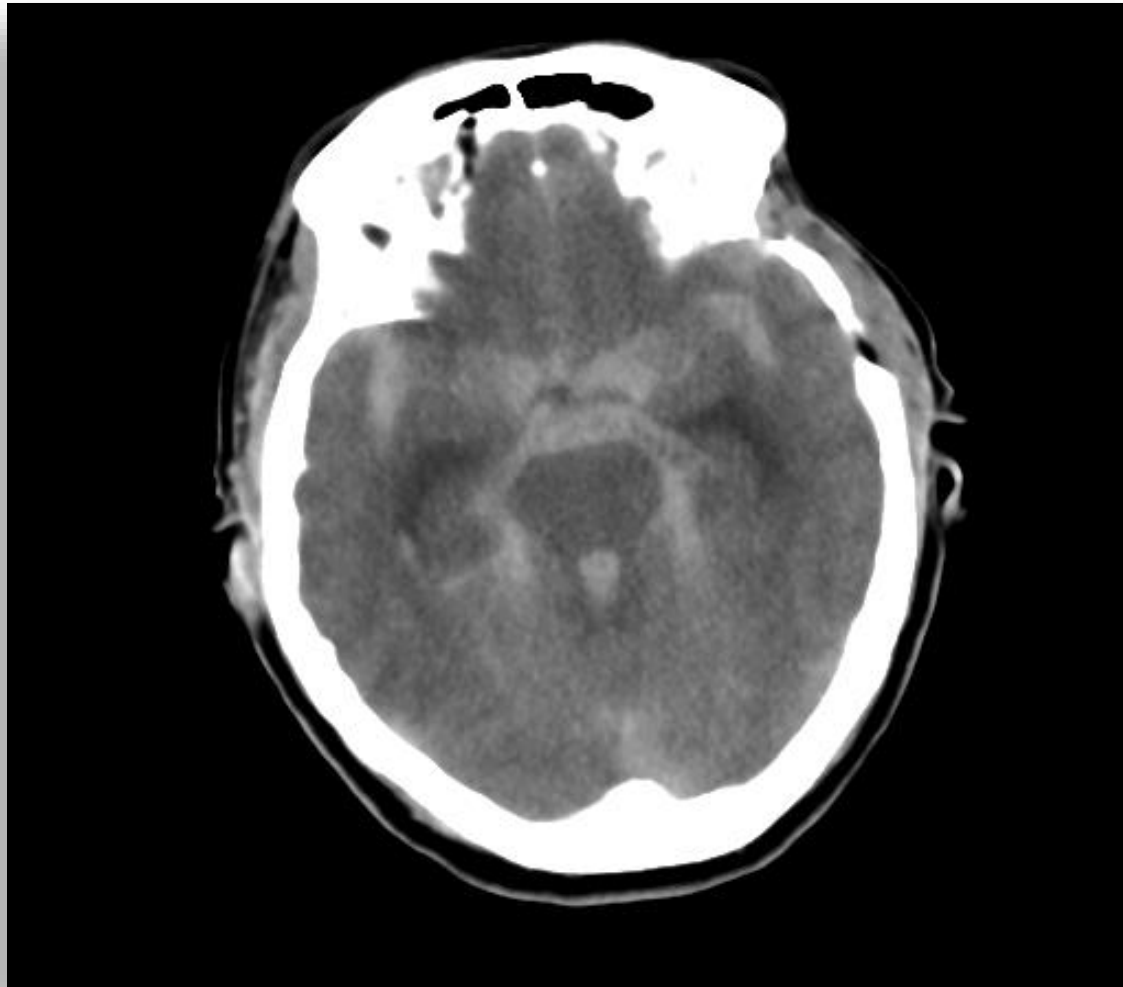
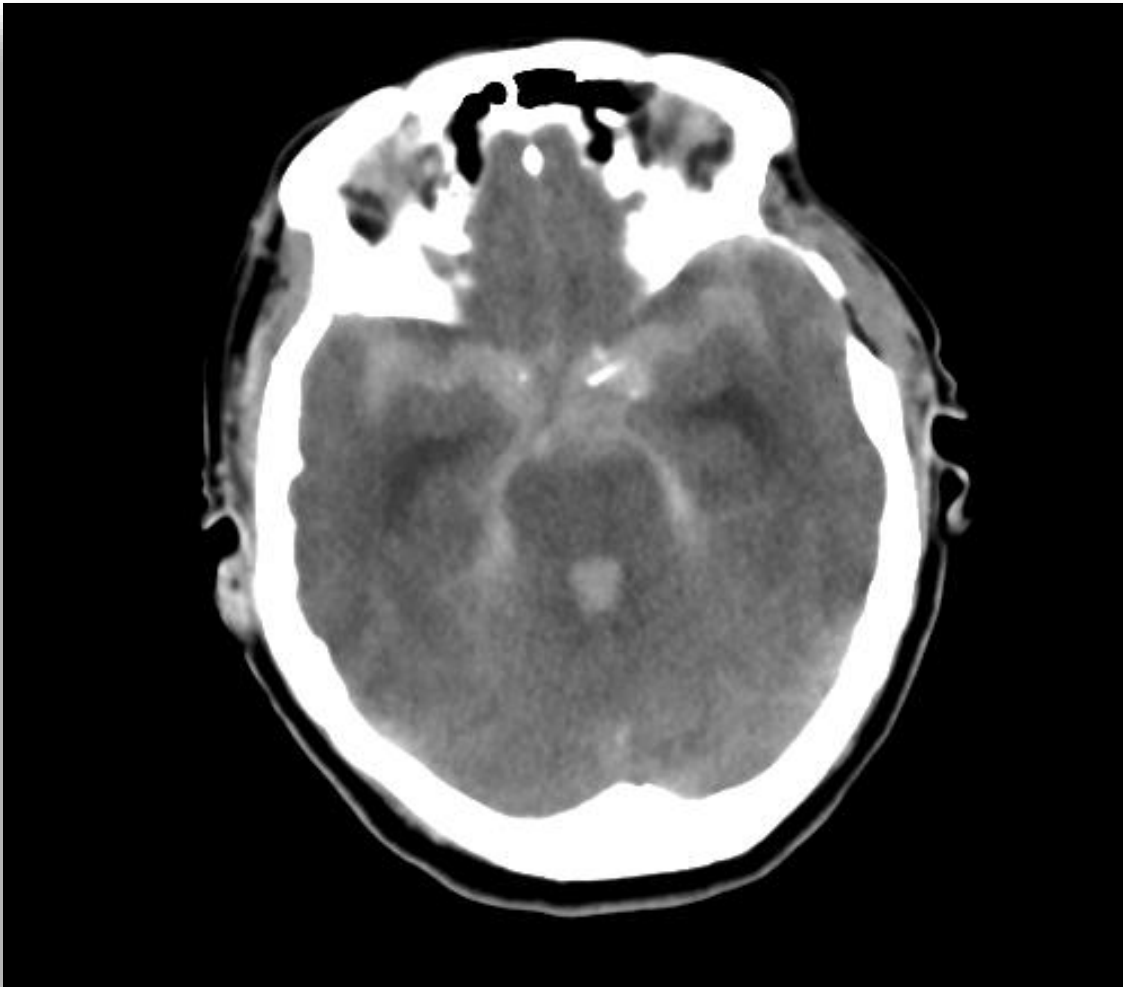
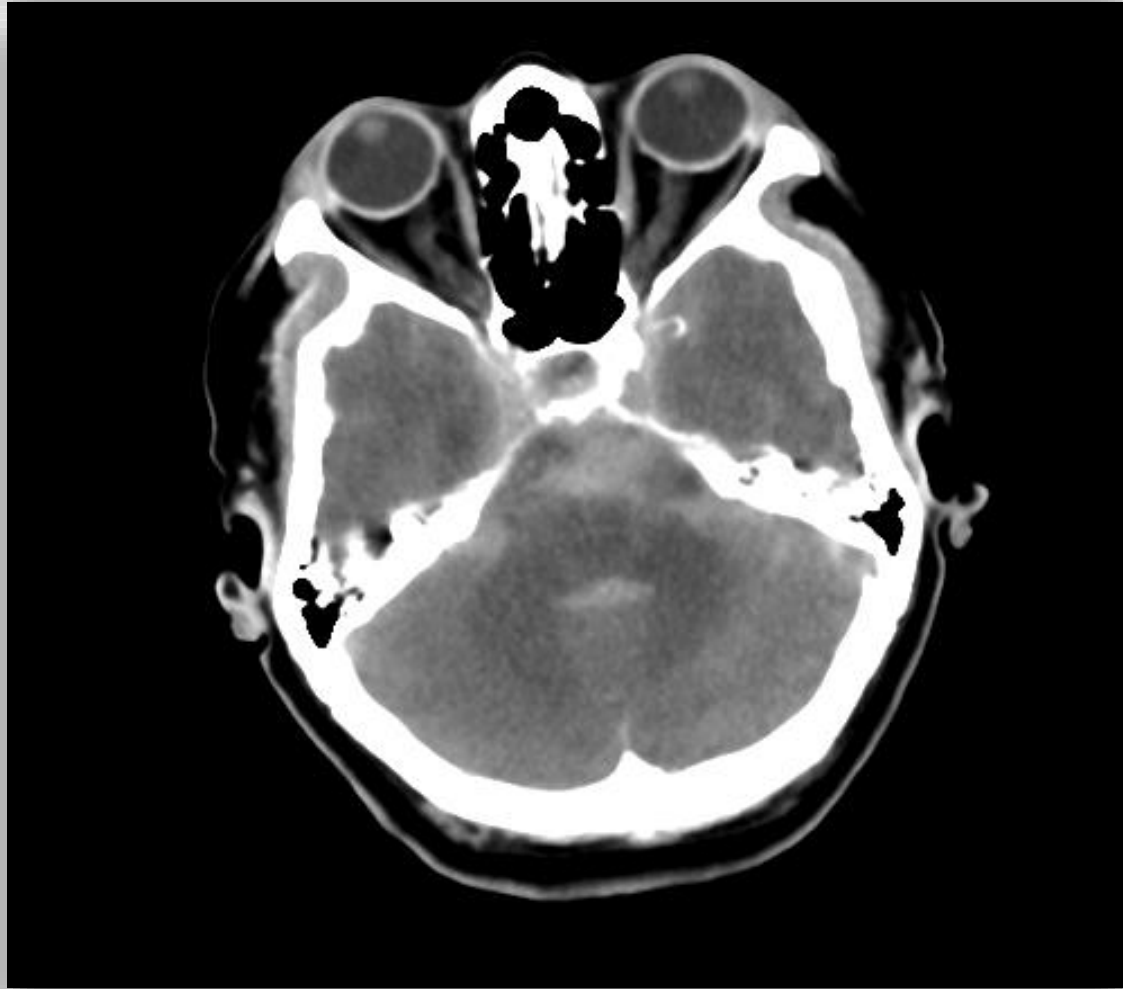
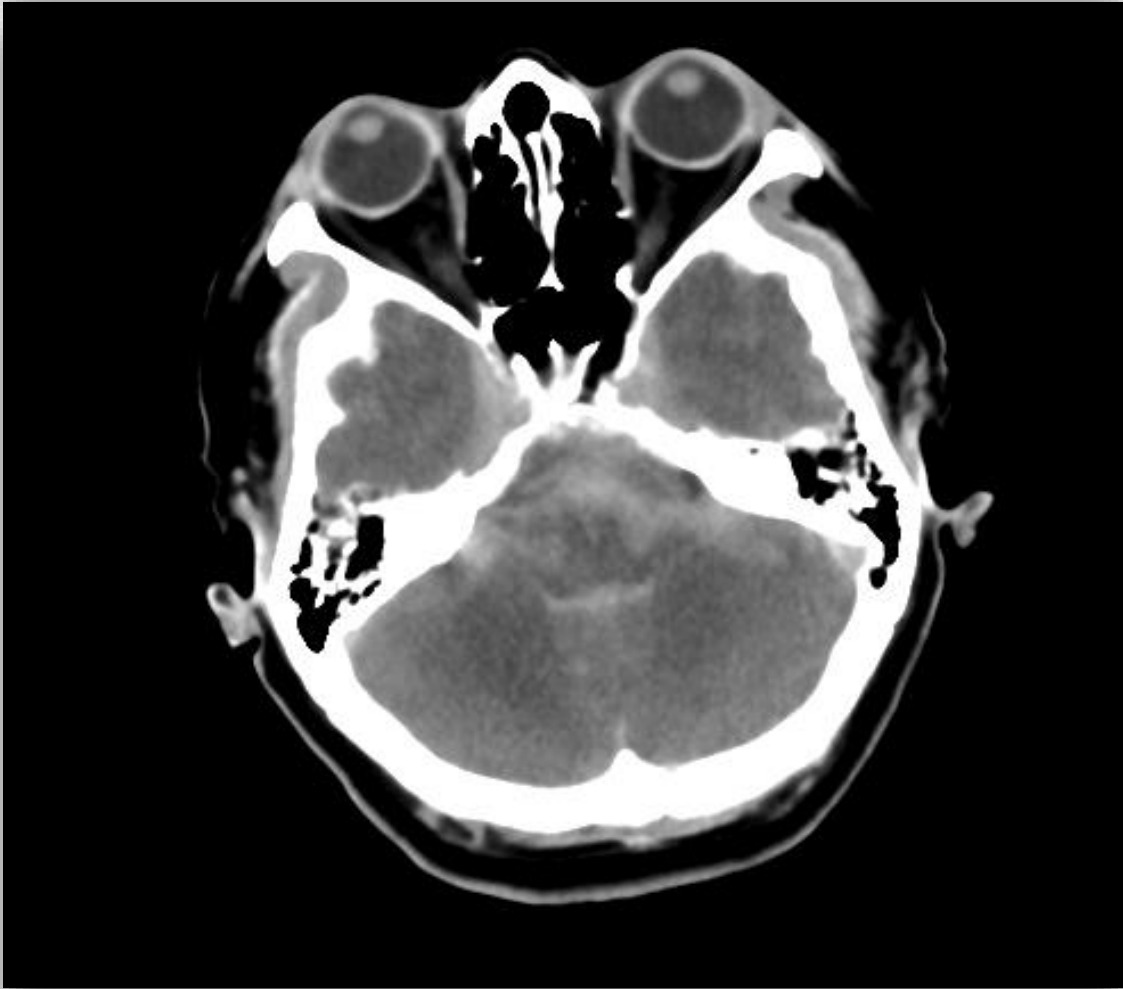
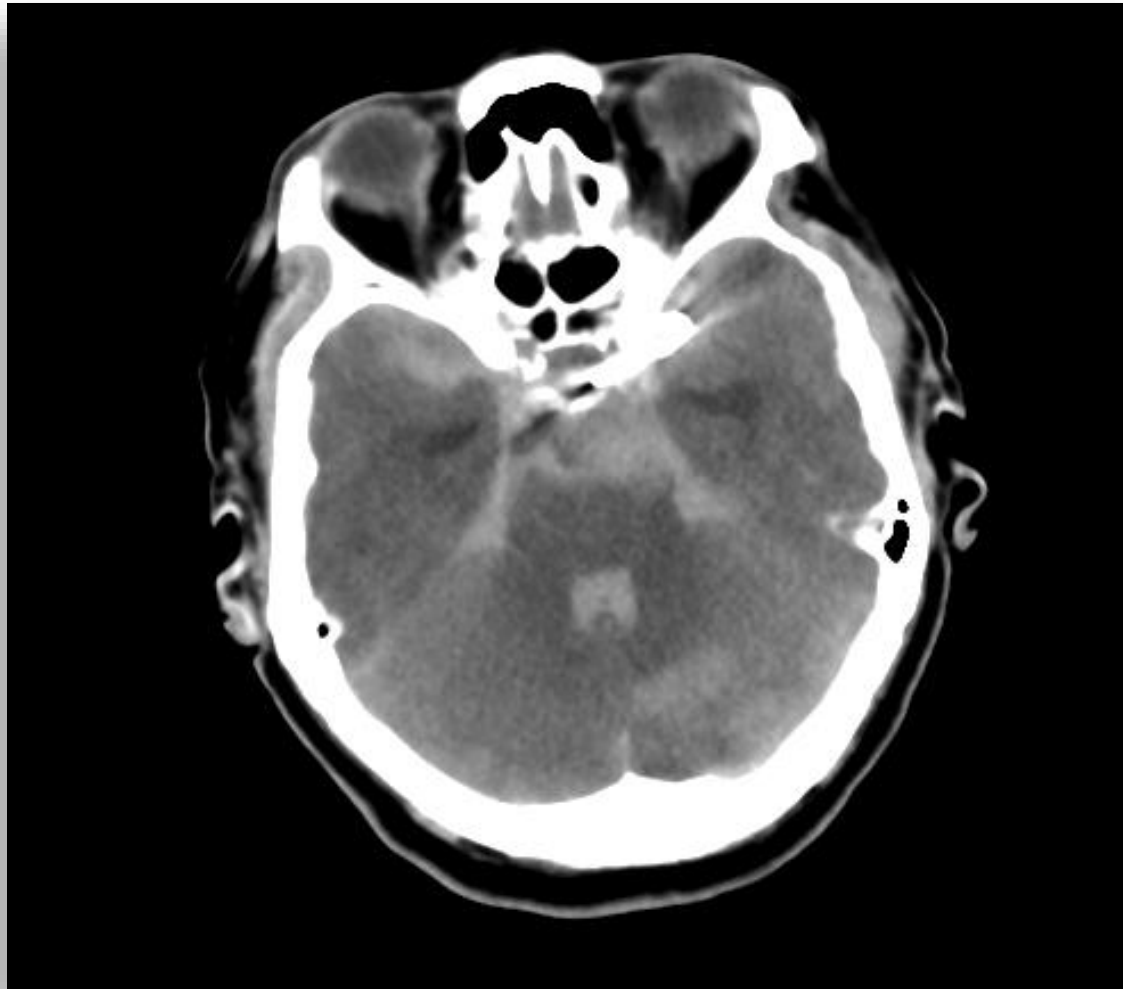
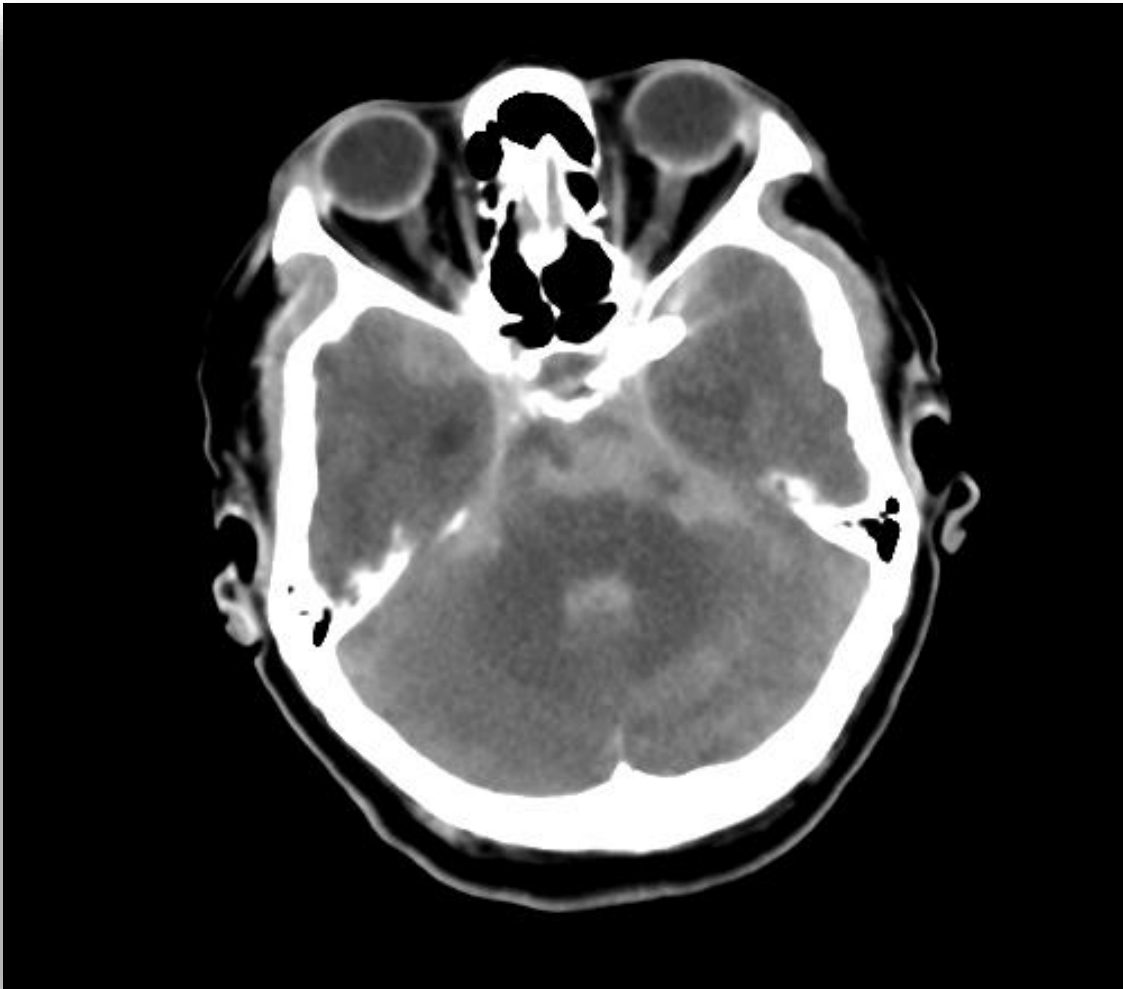


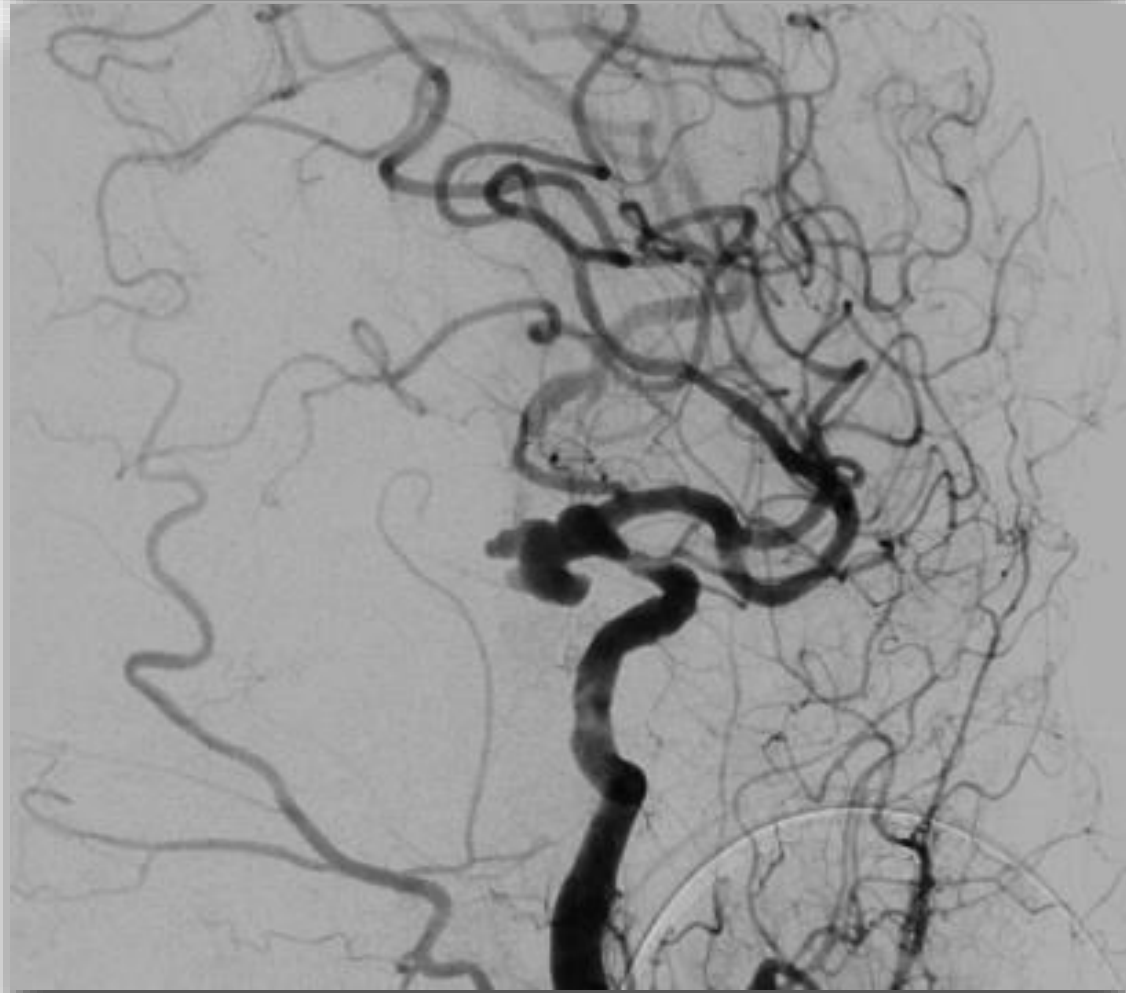
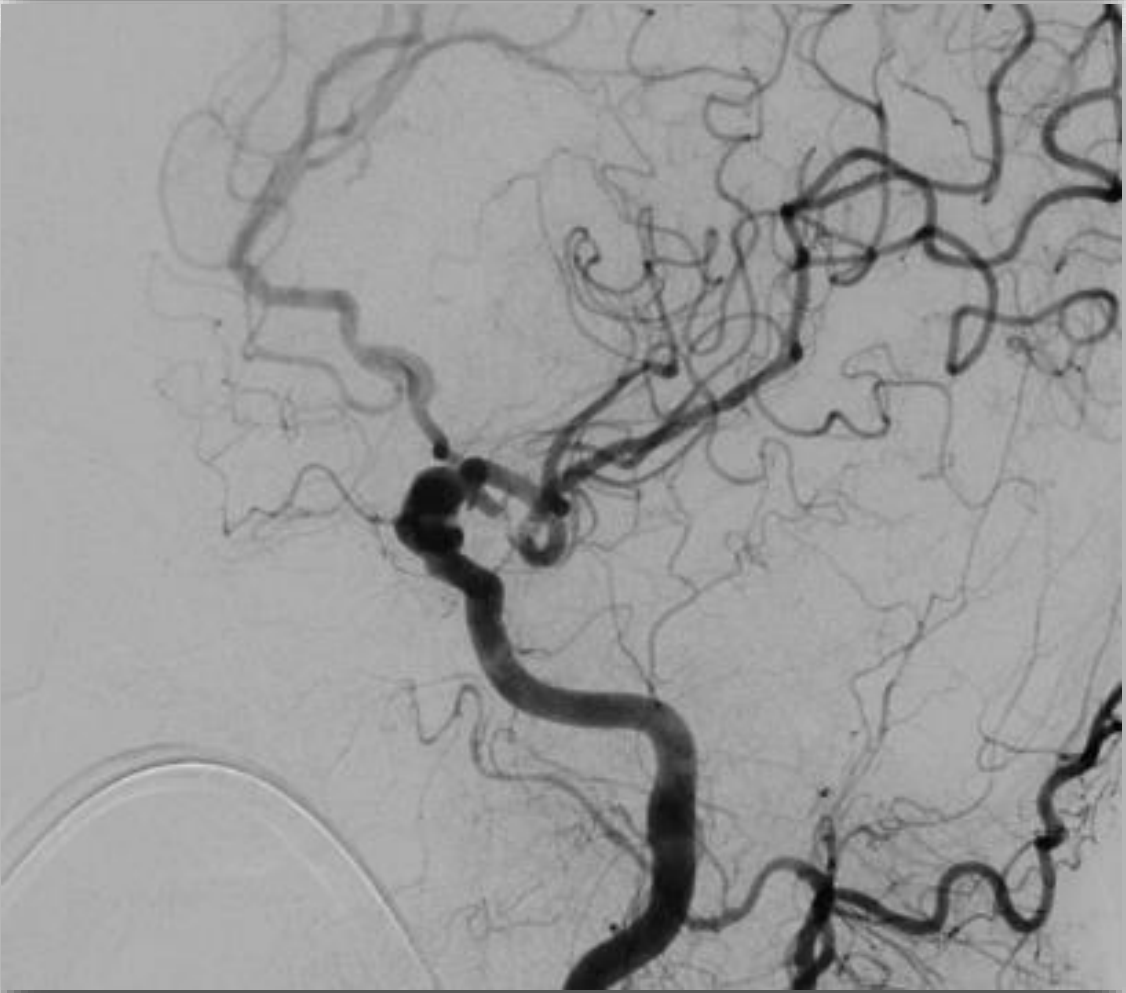
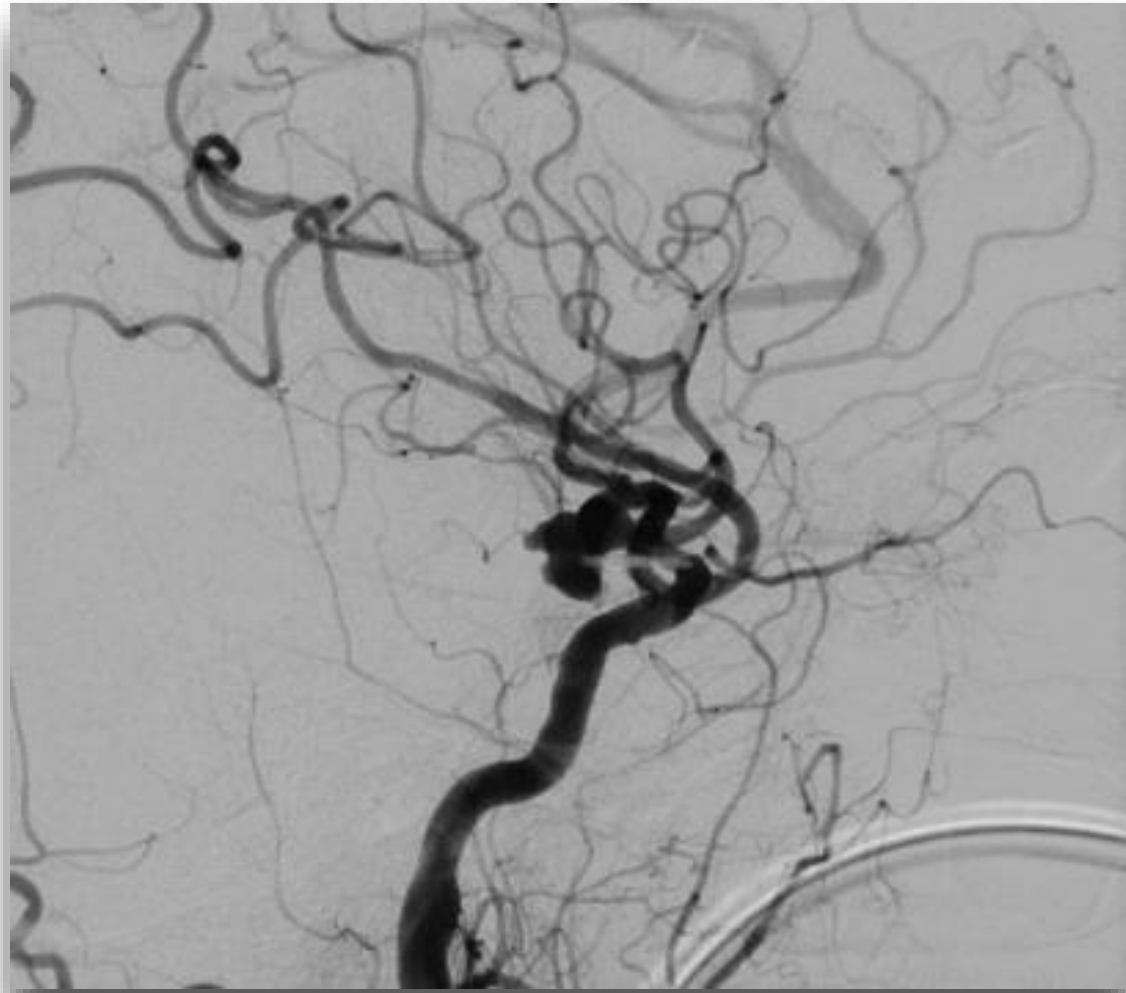
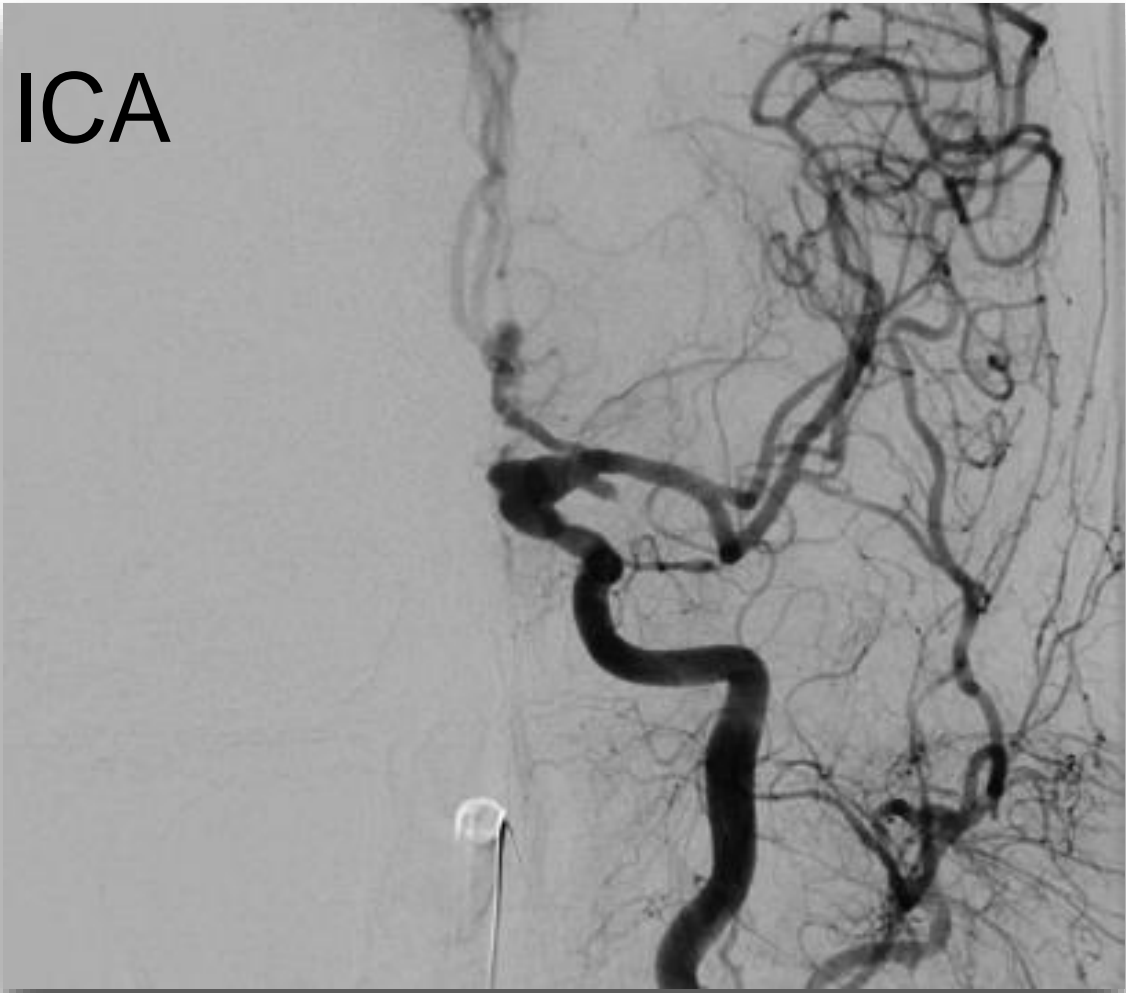
- 67 y/o F
- H&H Grade 5
- GCS:6
- Previously clipped left ICA aneurysm (4 years ago)

Reza Dashti, M.D, Ph.D.  
Department of Neurosurgery  
University of Illinois at Chicago

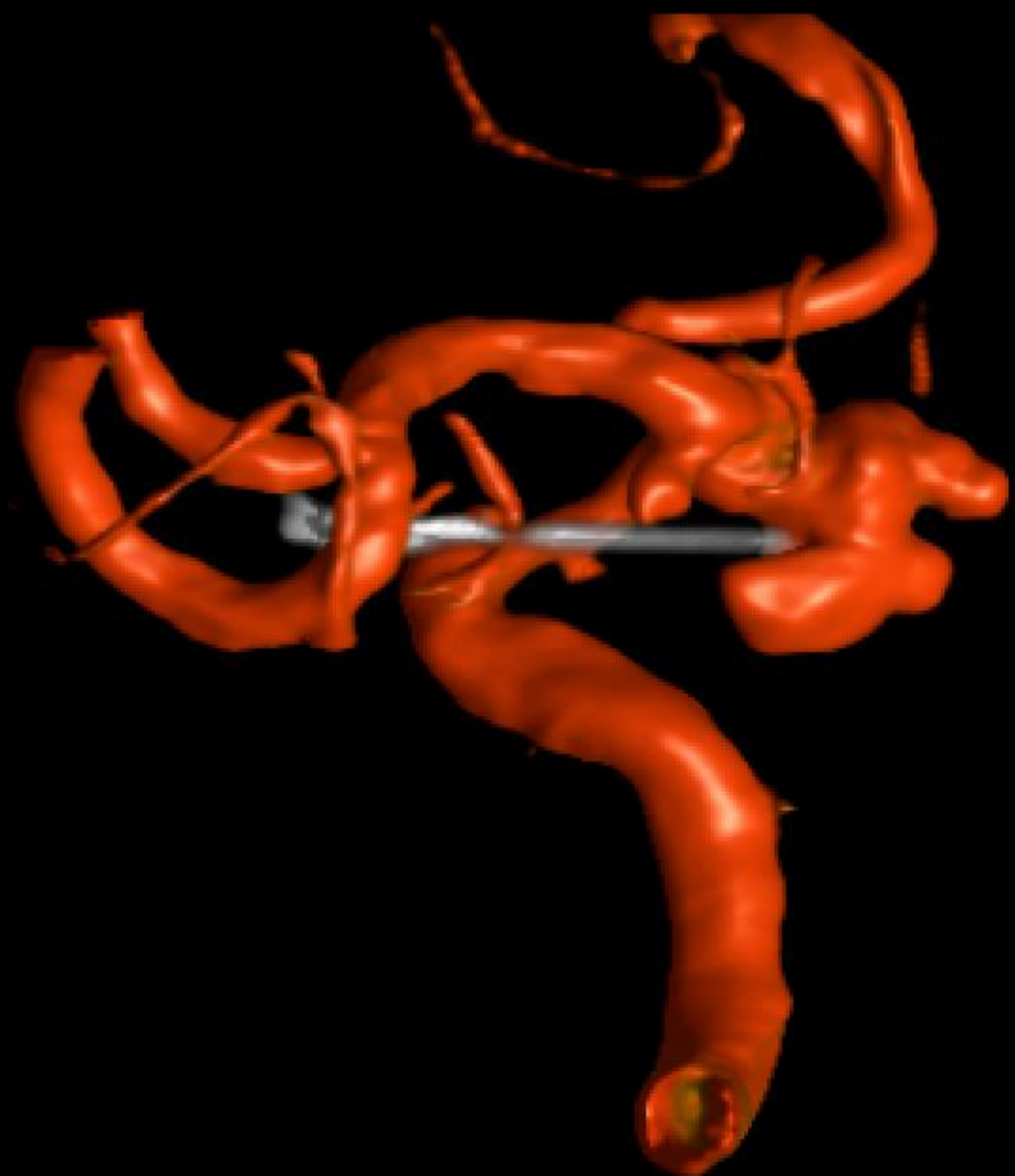




Left ICA



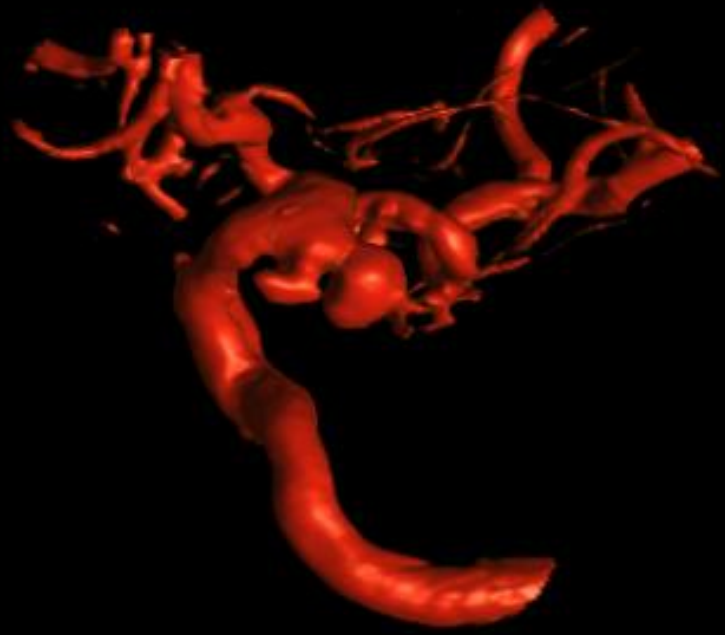
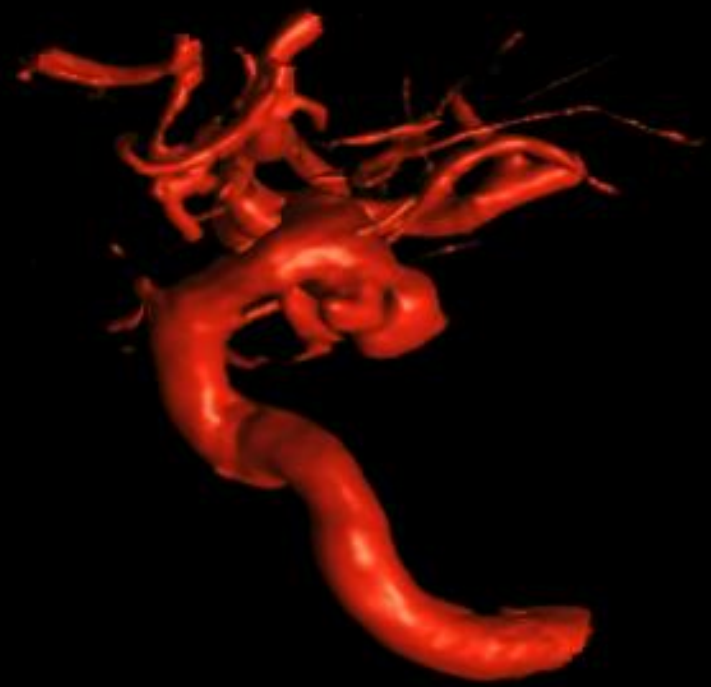
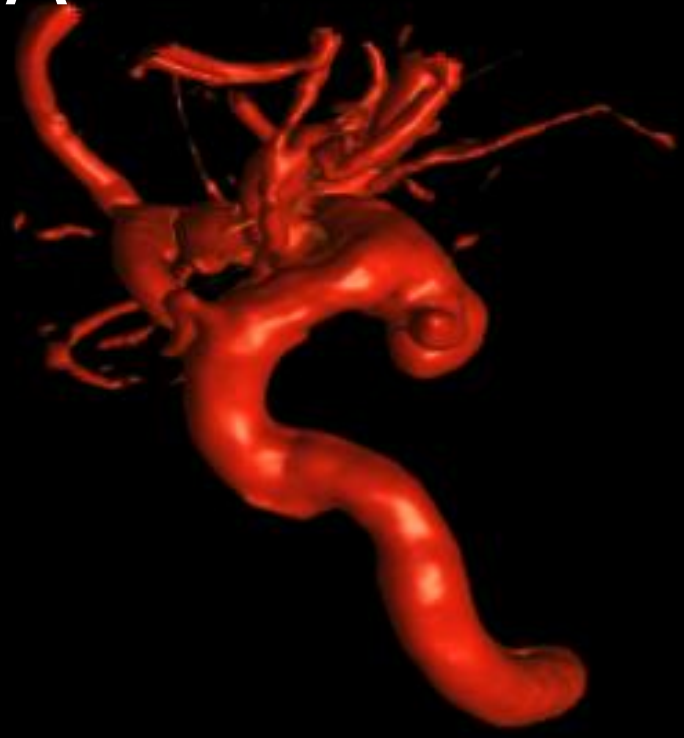
Ust g\_H\_#00R\_#00I\_000L\_200\_+100\_L\_480\_150\_2x2



LP

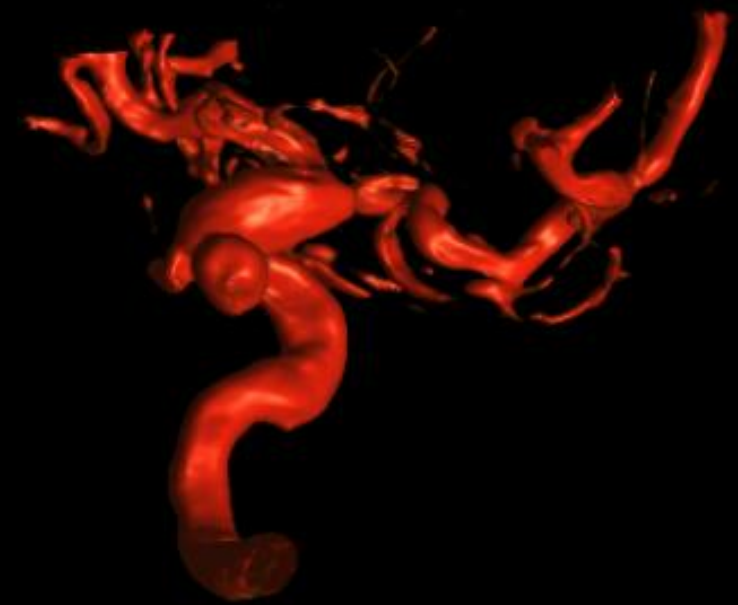


R ICA



1

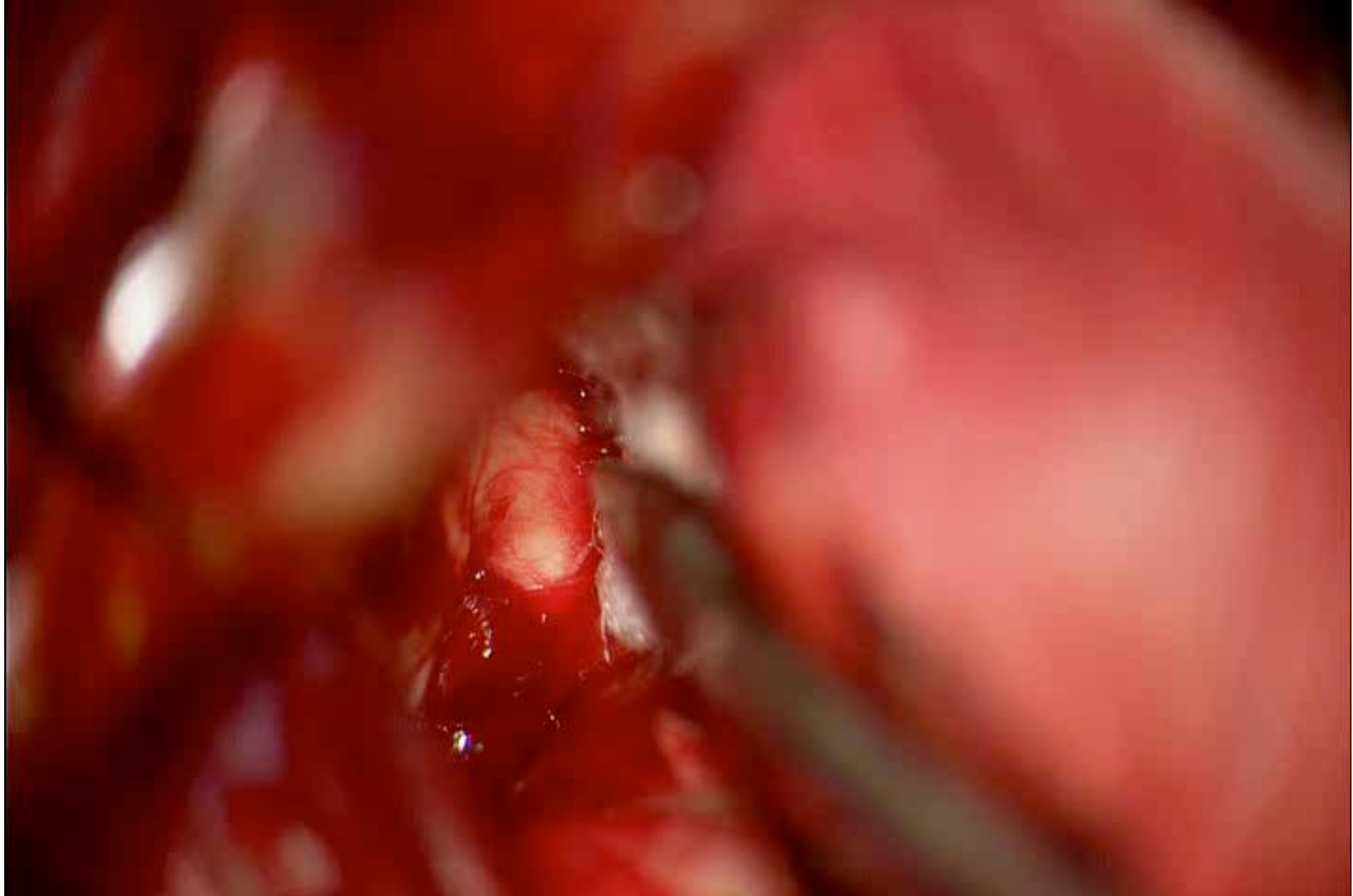L



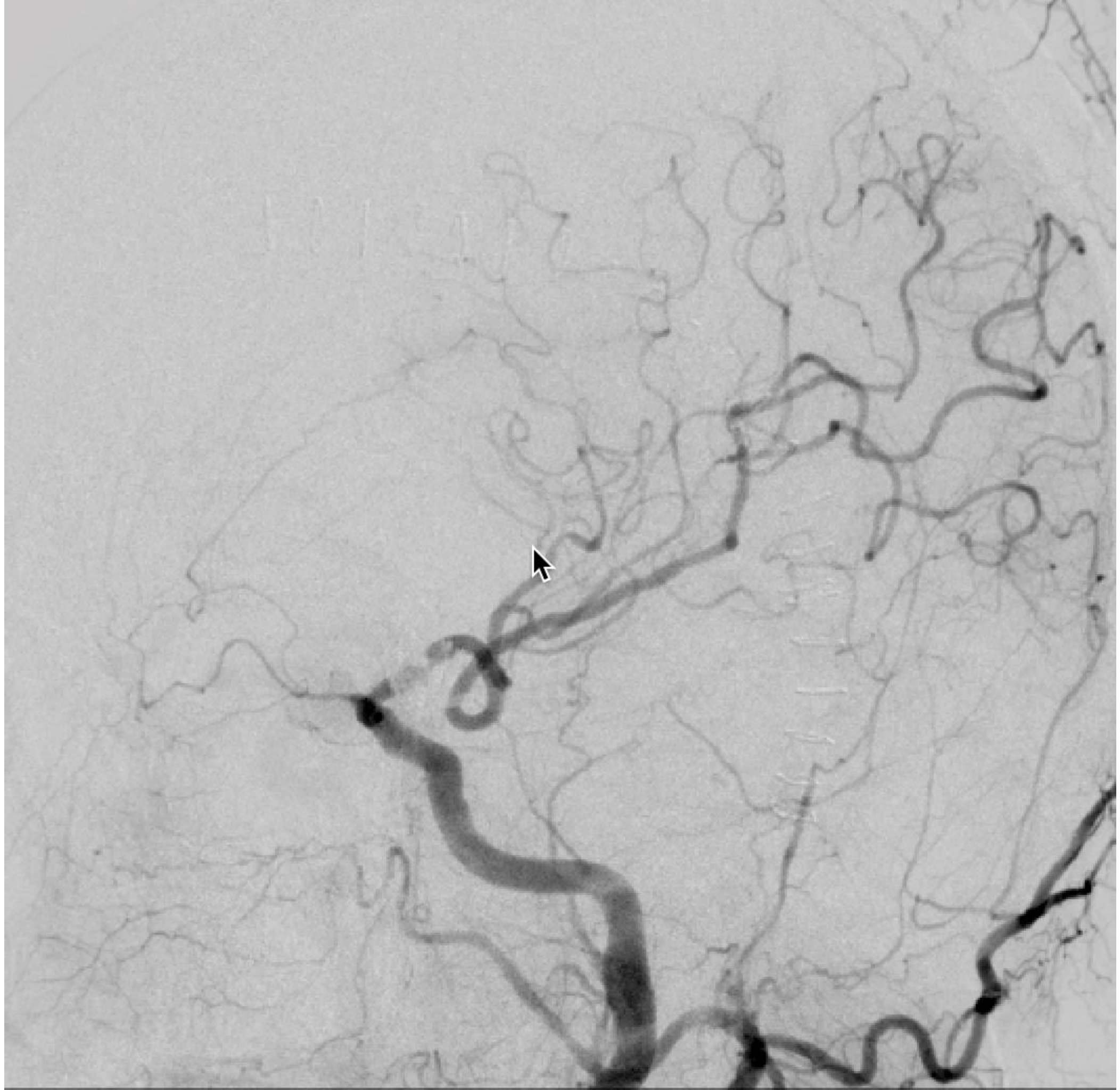
1 cm

PR

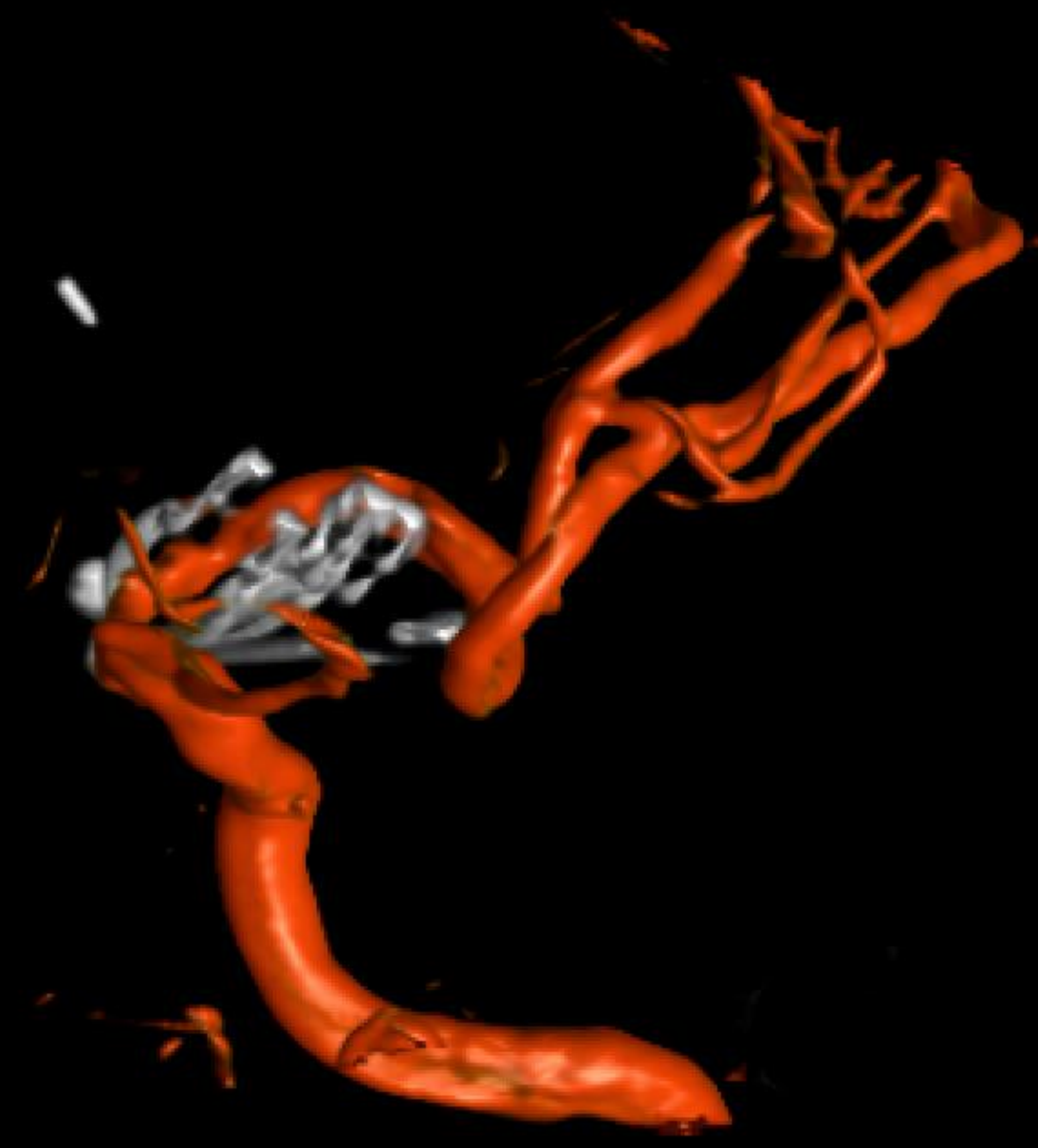
# Treatment Options







OR31 g\_11\_400R\_400I\_000L\_200\_+100\_L\_400\_130\_zxz



A