

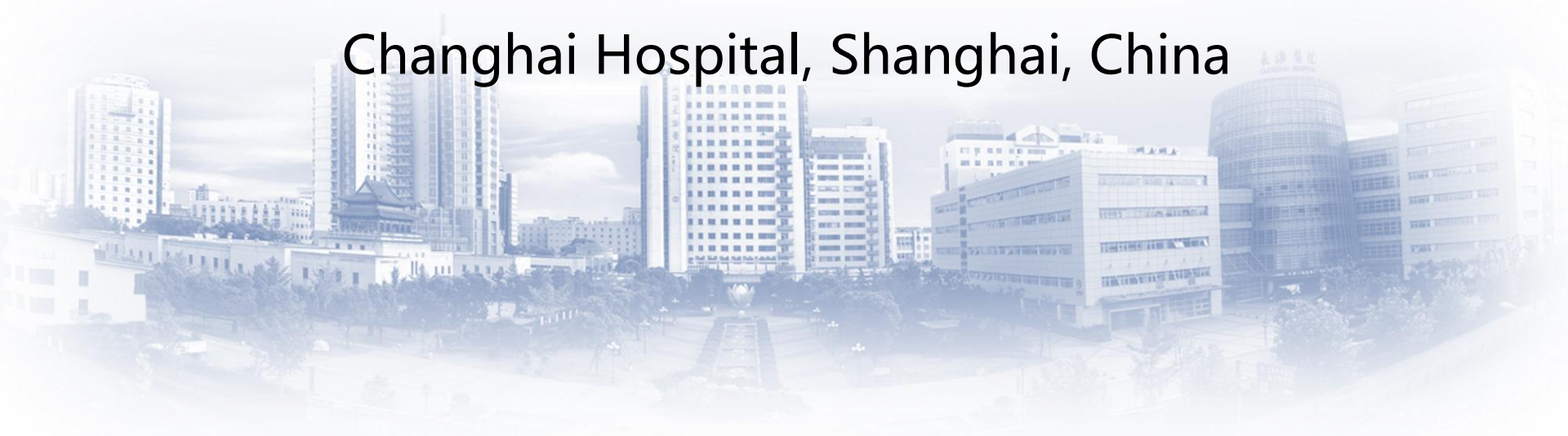

Changhai Hospital | OCIN

X-Stent in Endovascular Treatment of Anterior Communicating Artery Aneurysm

Jianmin Liu

Changhai Hospital, Shanghai, China



Case

Male , 73yrs

CC : Headache for 10 Days

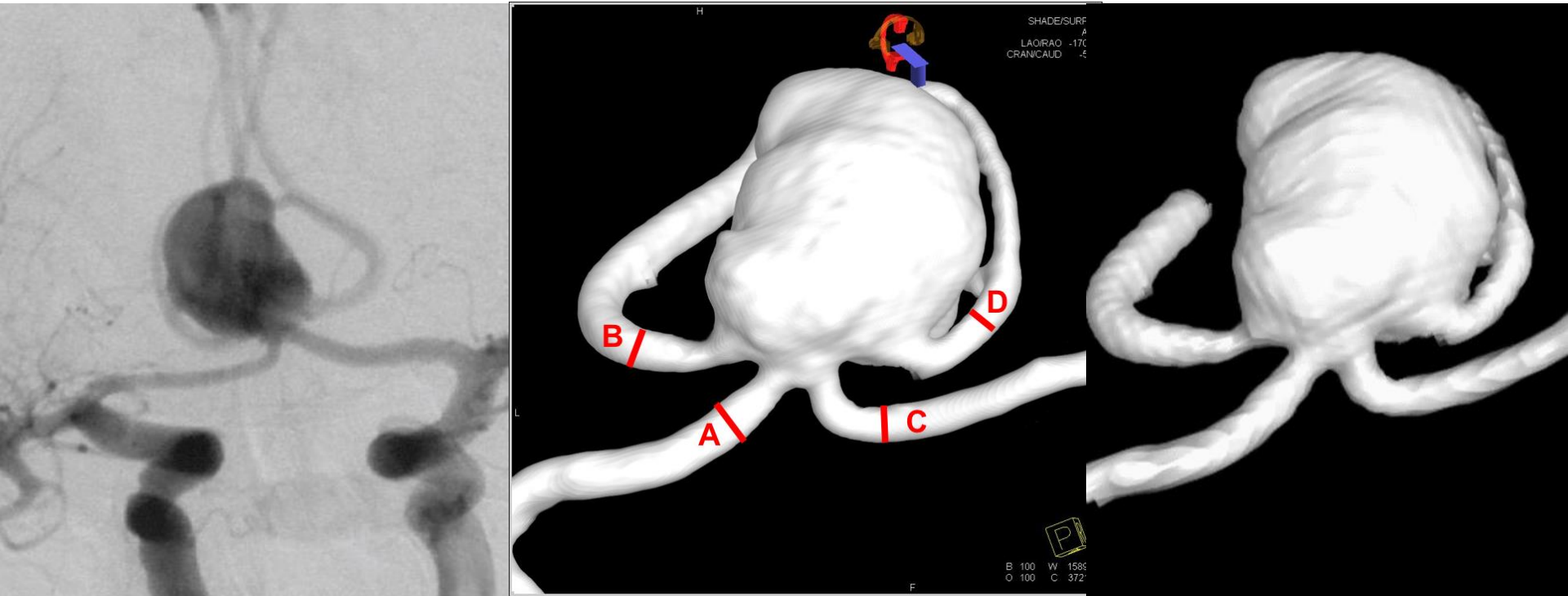
PE : Negative

PH : Negative

Imp : Acoma AN



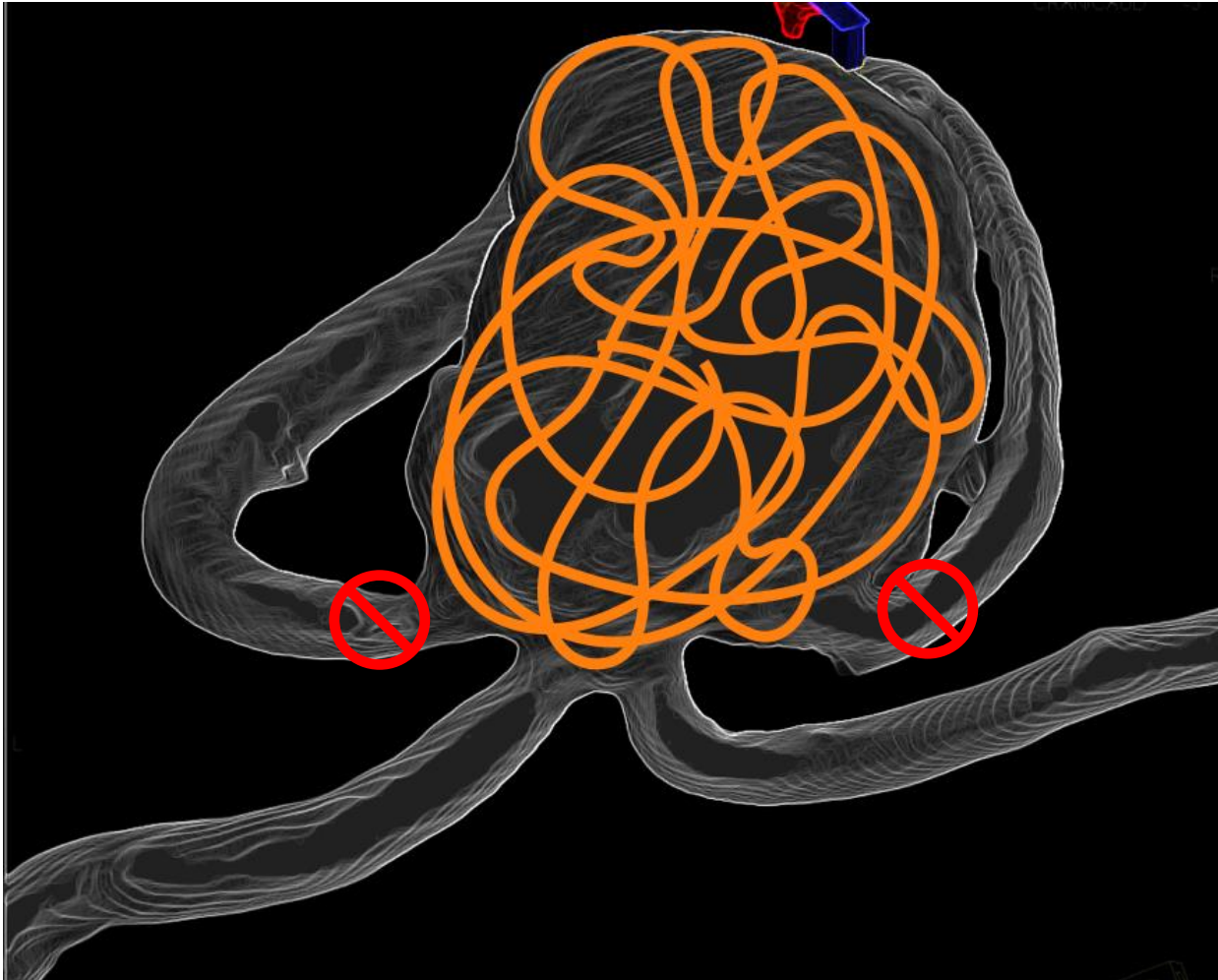
DSA 06/13/2016



Size: 11mm Neck: 6.6mm A: 1.8mm B: 1.6mm C: 1.3mm D: 1.6mm

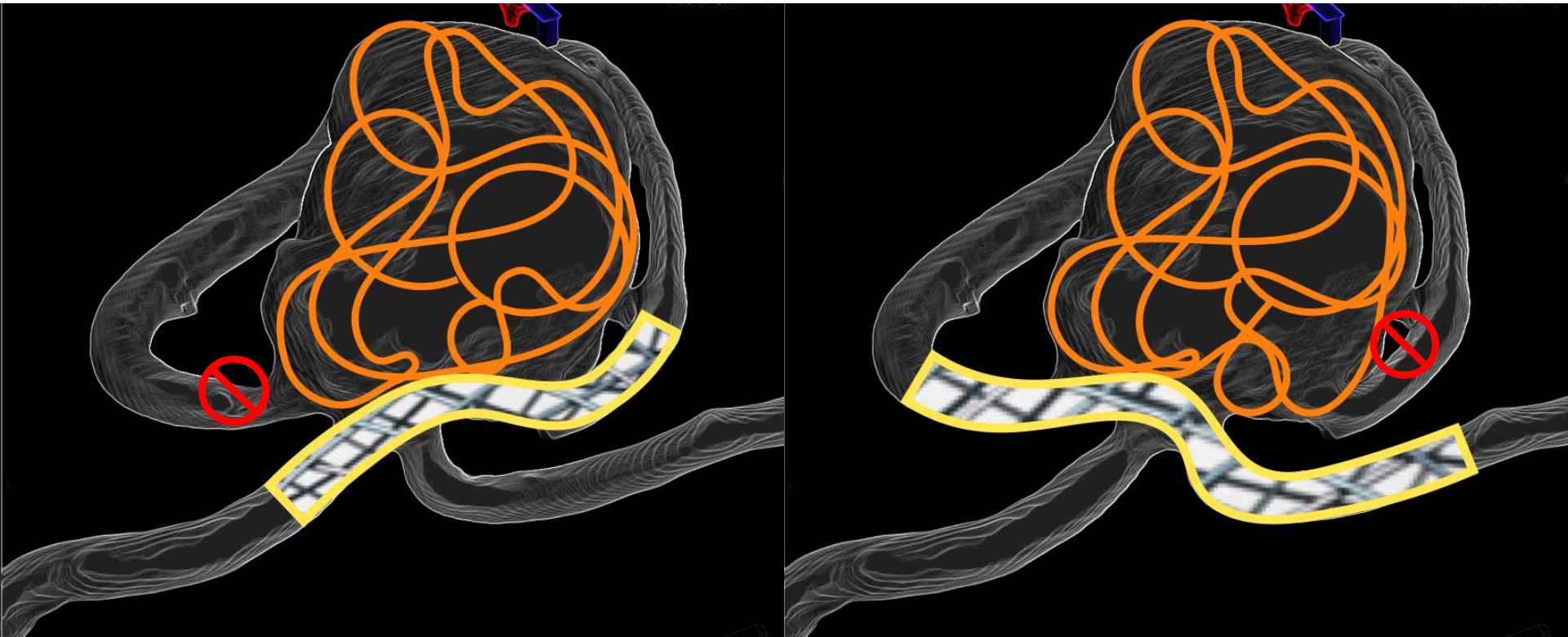
Strategy Options

Plan A Coiling without Stent



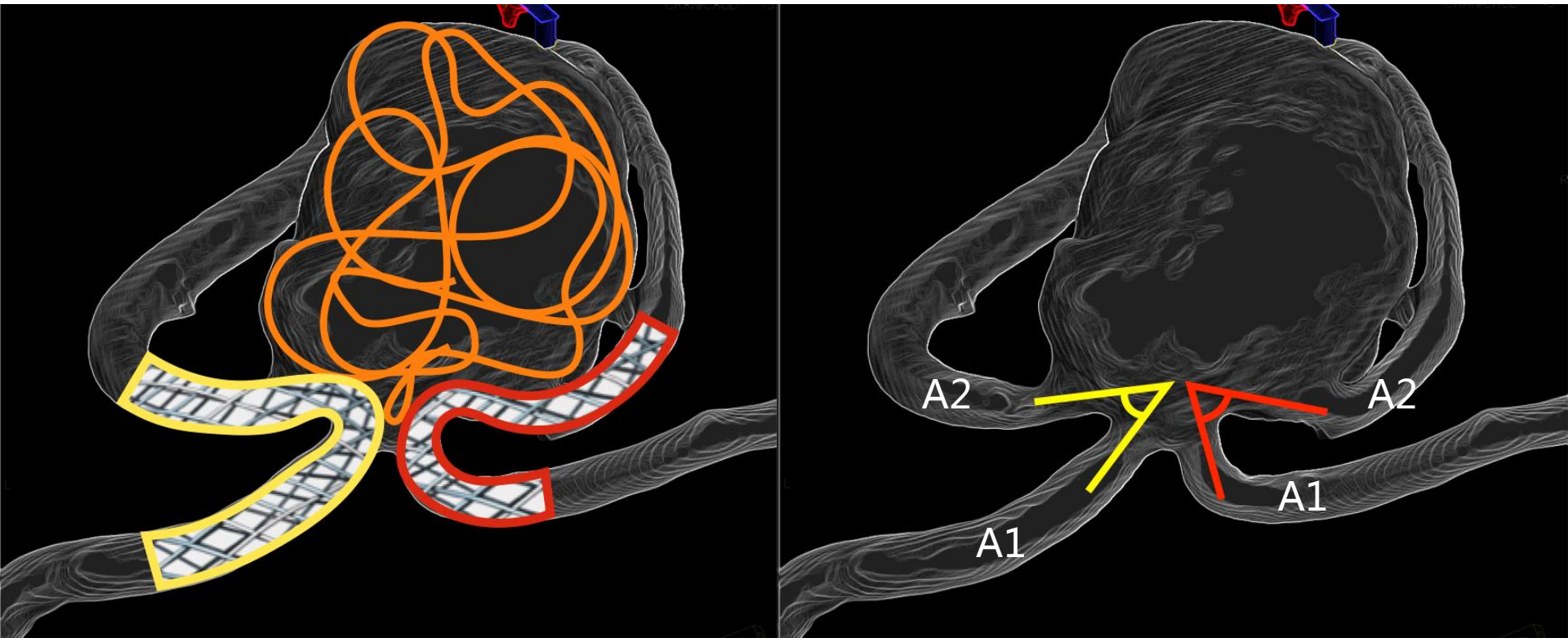
Strategy Options

Plan B Single Stent + Coiling



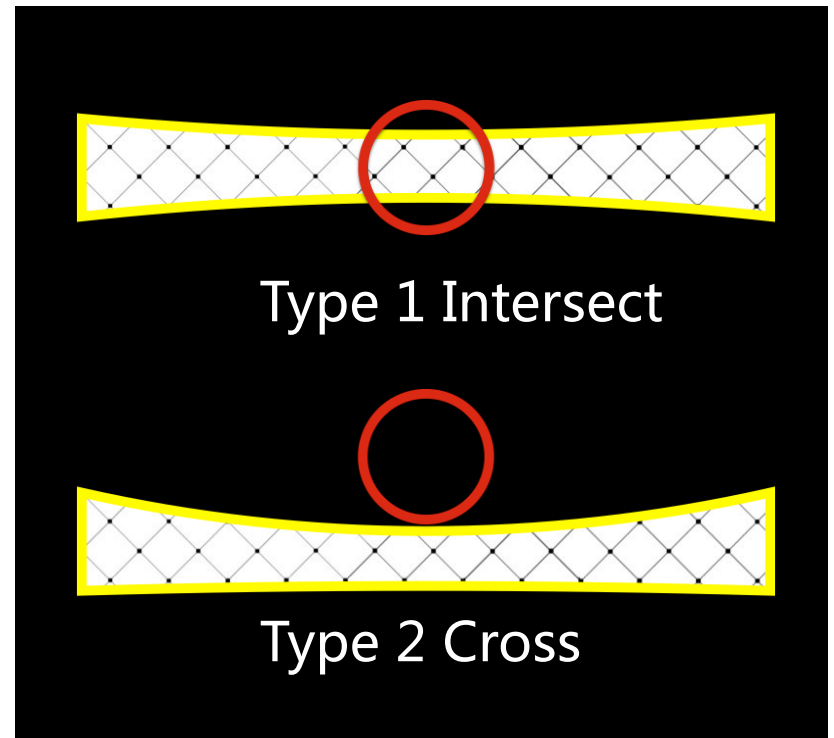
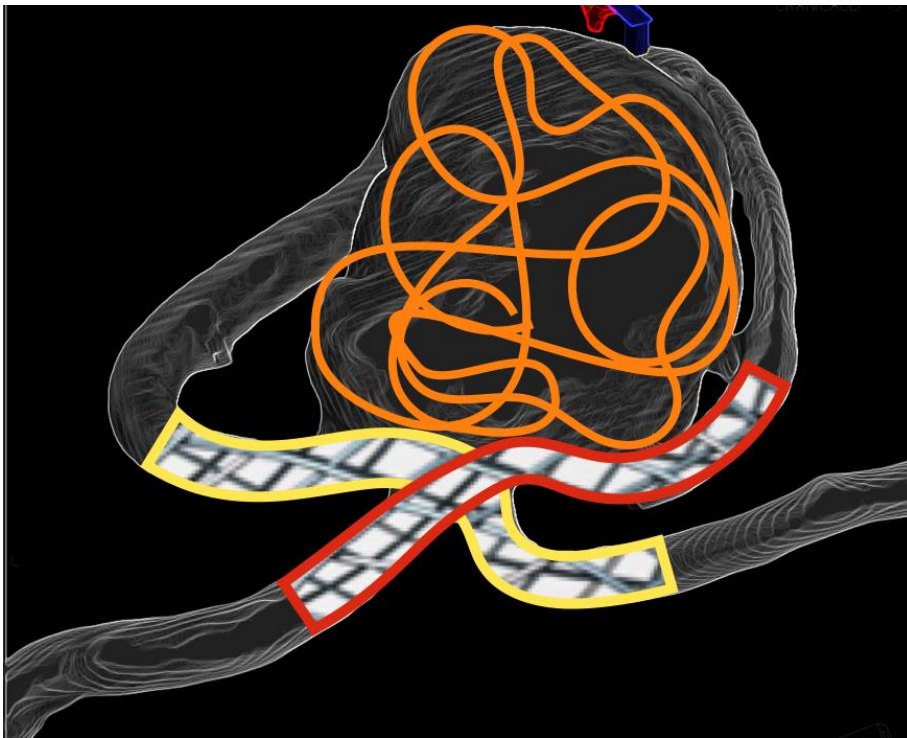
Strategy Options

Plan C "H" Stent + Coiling



Strategy Options

Plan D "X" Stent + Coiling

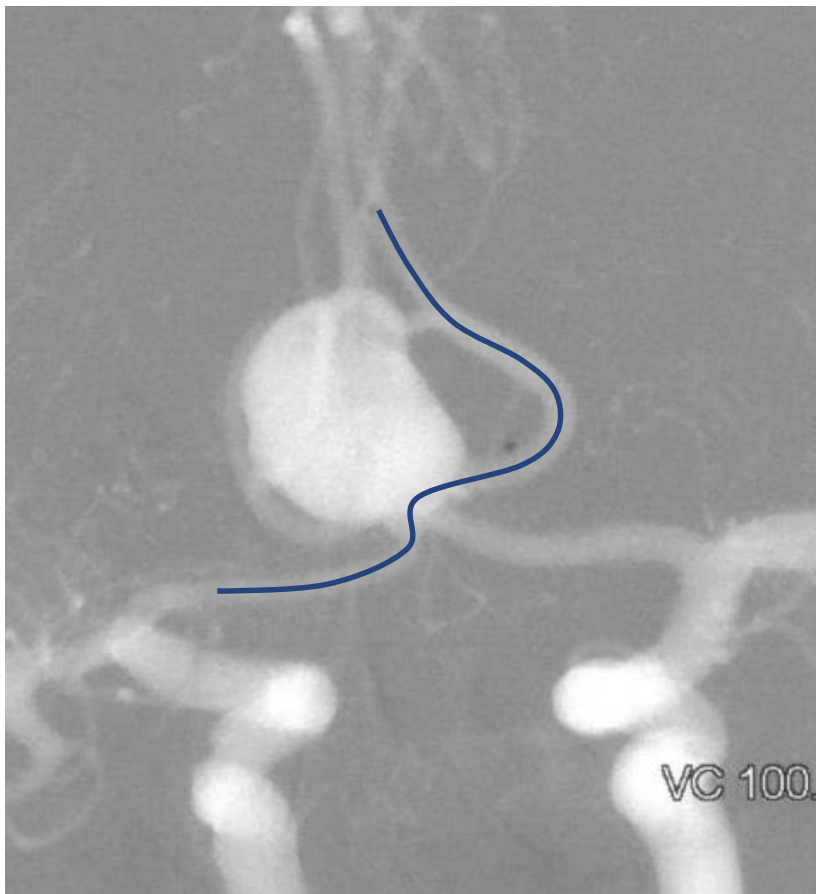


Materials

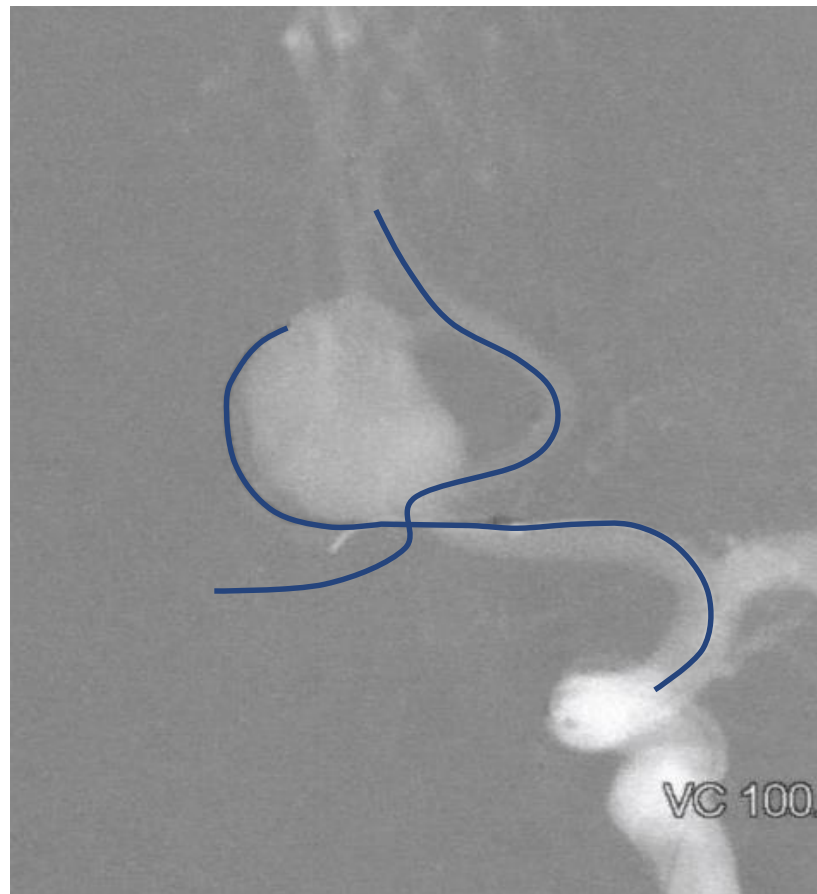
- 6F Long Sheath * 2
- 105cm Navien Support Catheter * 2
- Microwire : Traxcess 14
- Stent Microcatheter : Headway 17 * 2
- Coil Microcatheter : Echelon 10
- Stents : LVIS Junior 2.5/17 * 2



DSA 06/13/2016



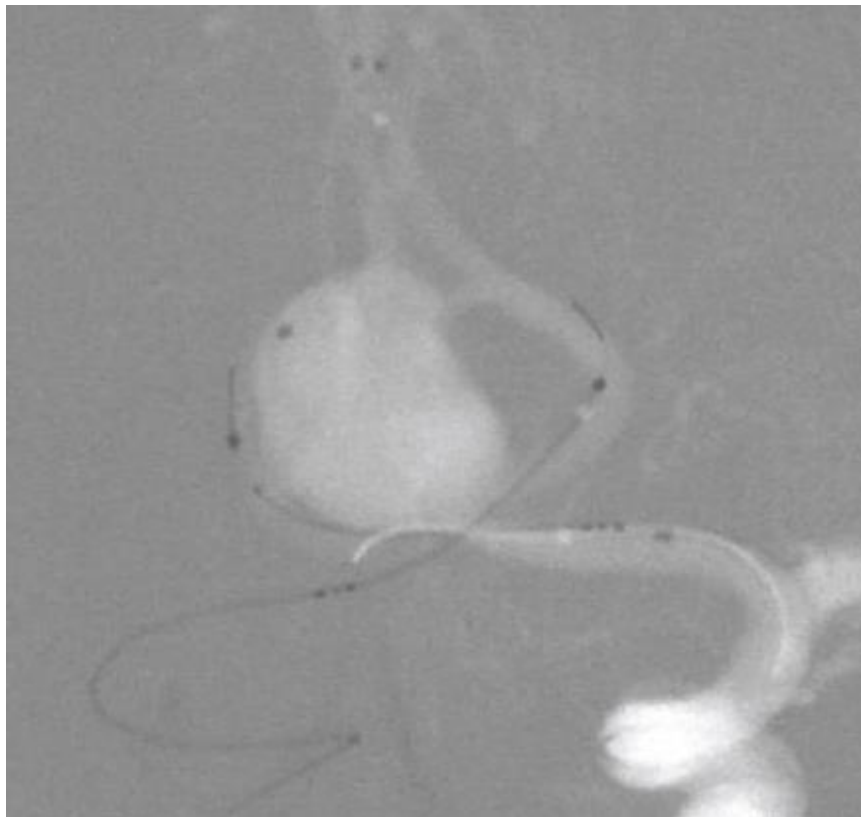
1st Headway 17



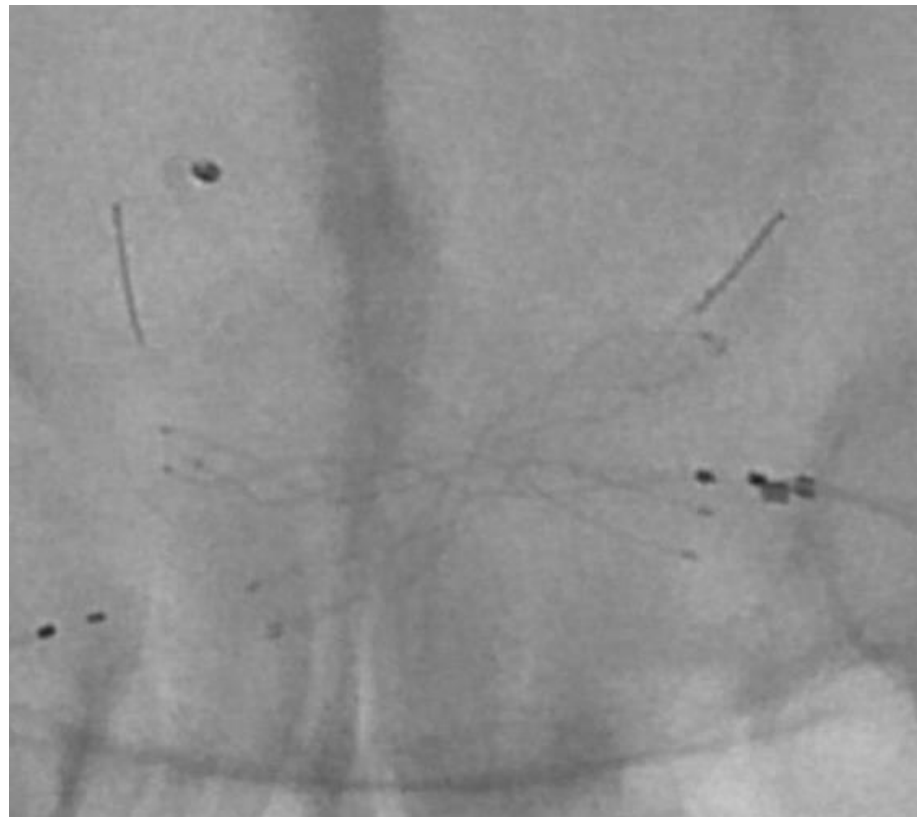2nd Headway 17



DSA 06/13/2016



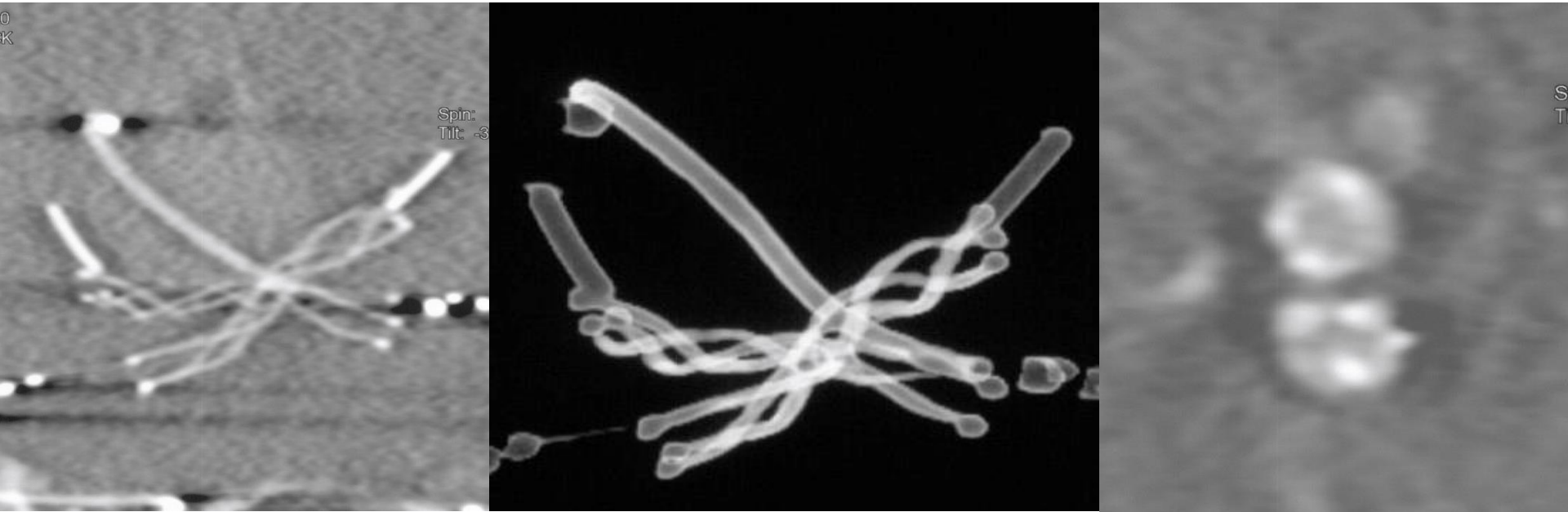
Echelon 10 in place



LVIS Jr 2.5/17 * 2



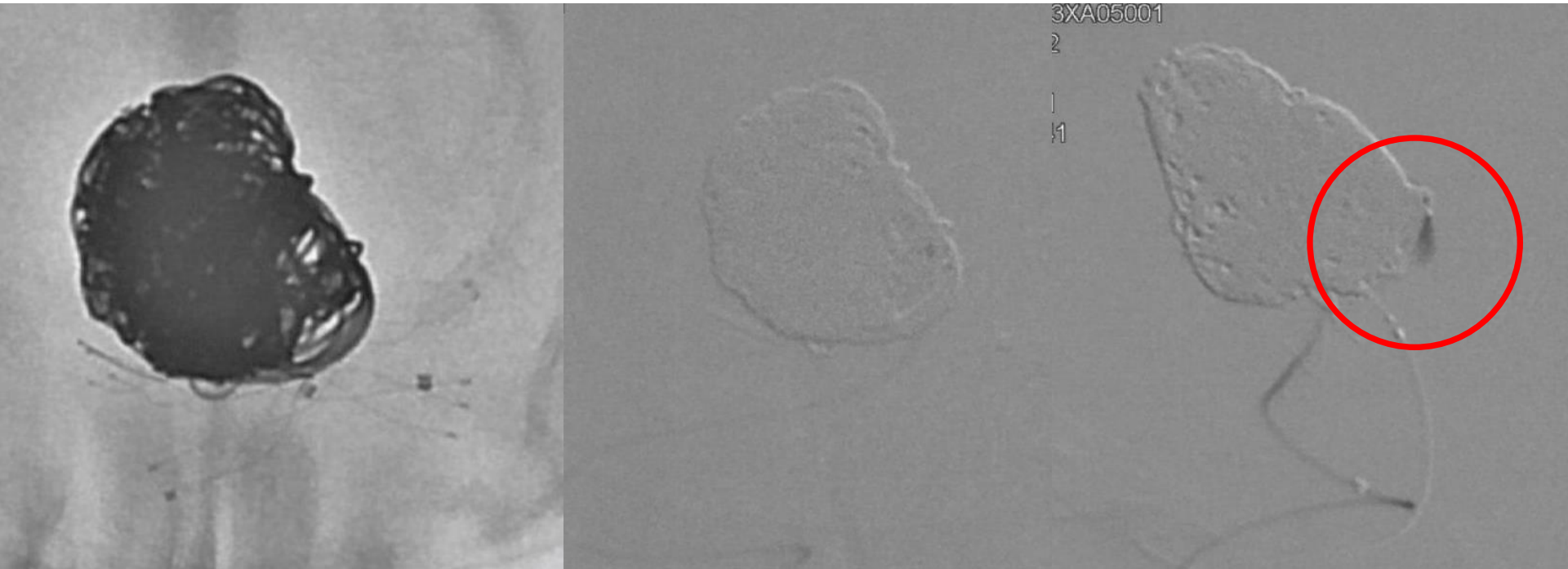
DSA 06/13/2016



Reconstruction of Stents



DSA 06/13/2016

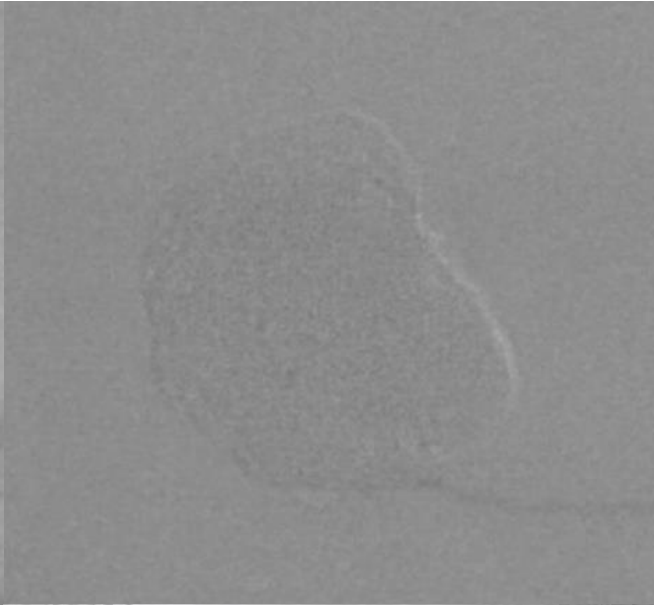
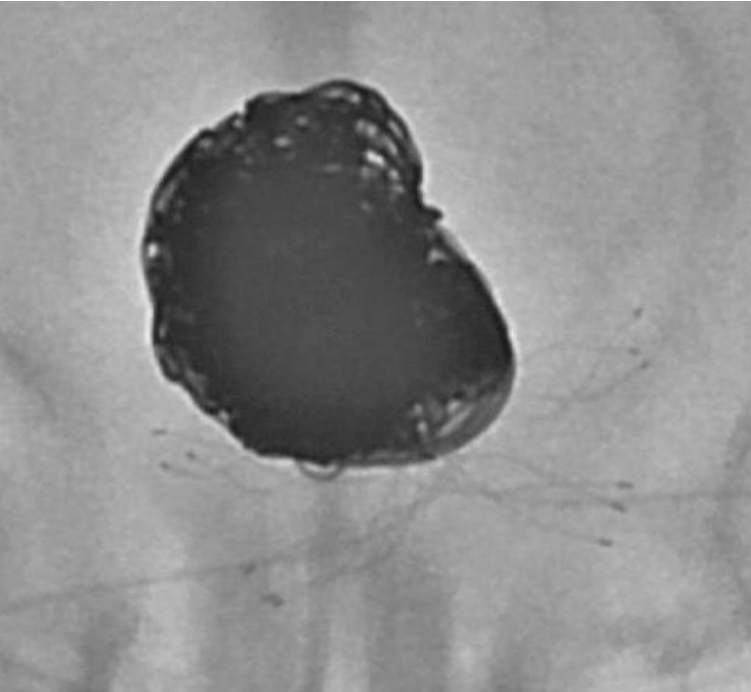


Coiling

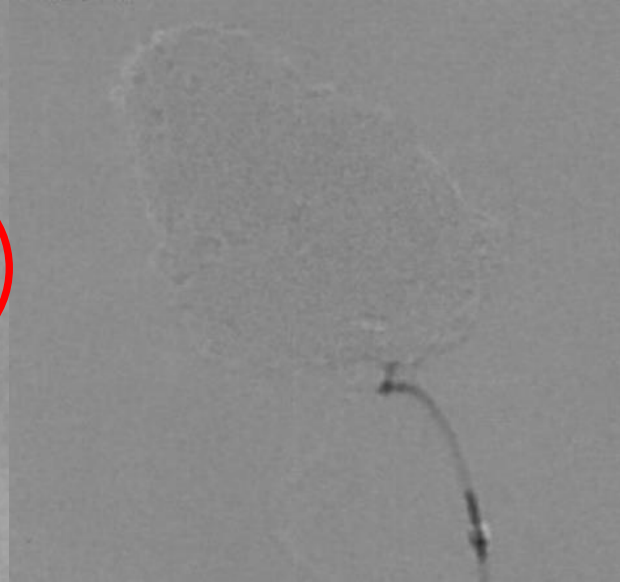
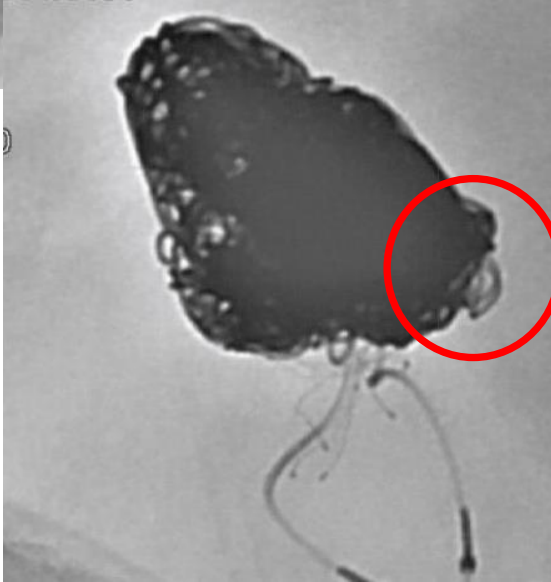

Changhai Hospital | Shanghai, China

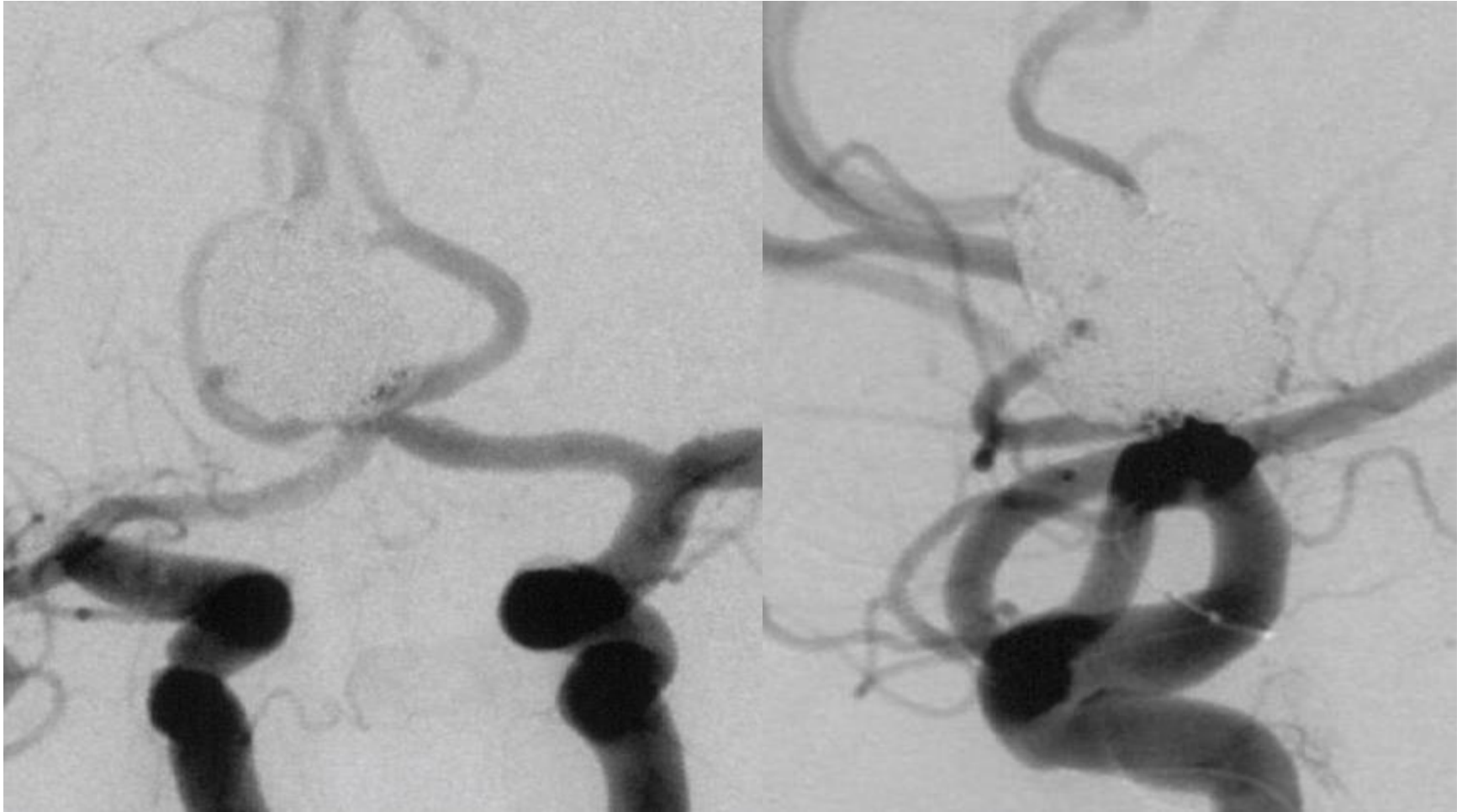
DSA 06/13/2016



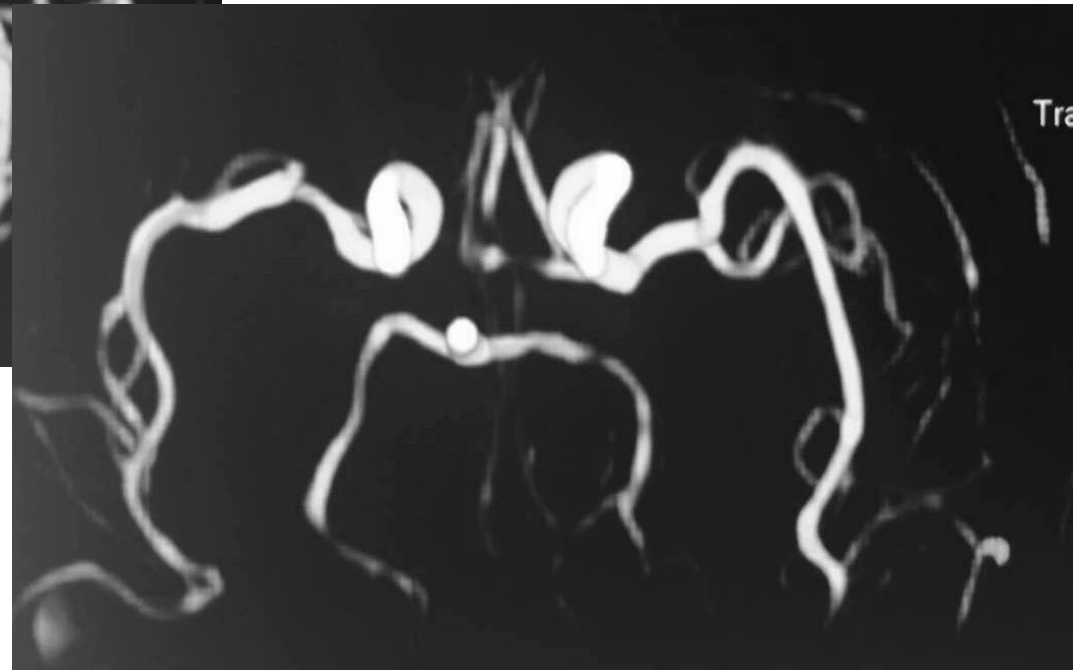
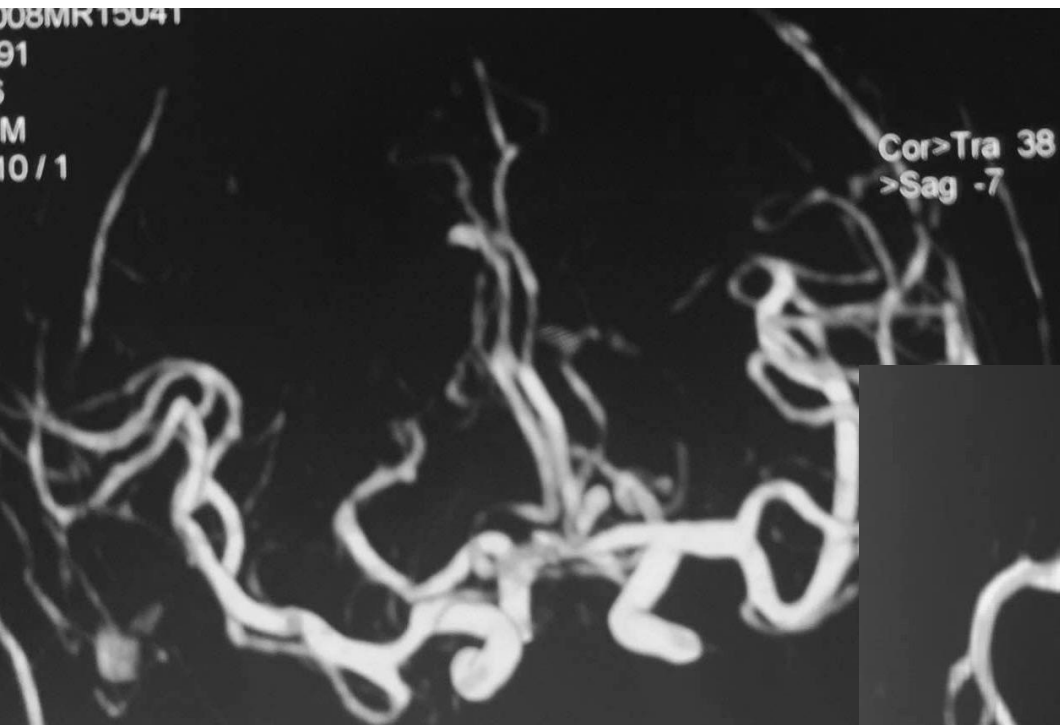
Re-navigate Microcatheter
to remnant part then coiling



Immediate Result



3-month Follow-up



Thanks !



Changhai Hospital | Shanghai, China