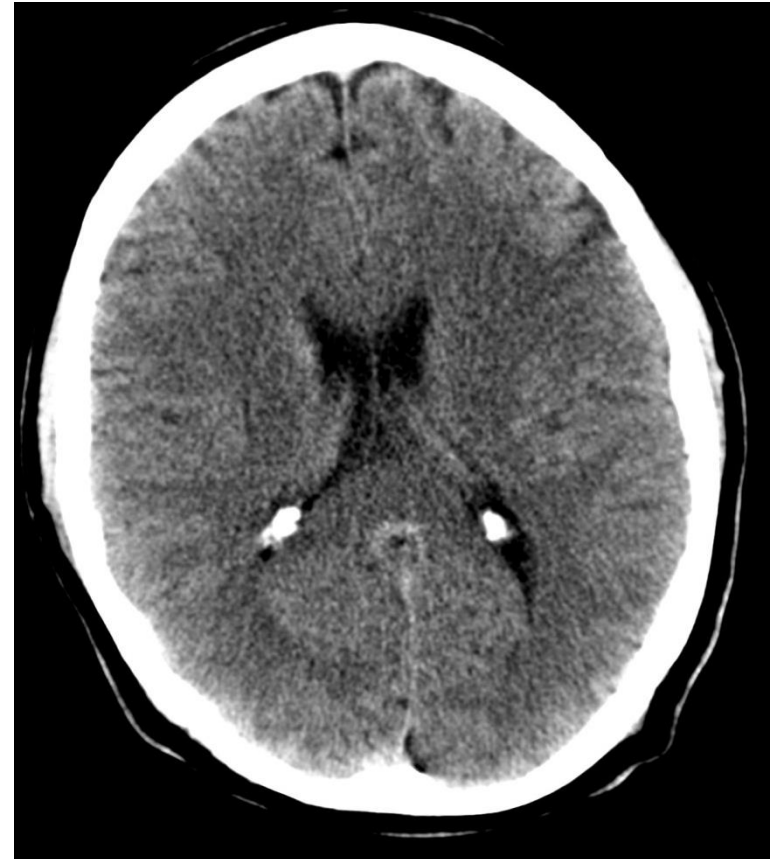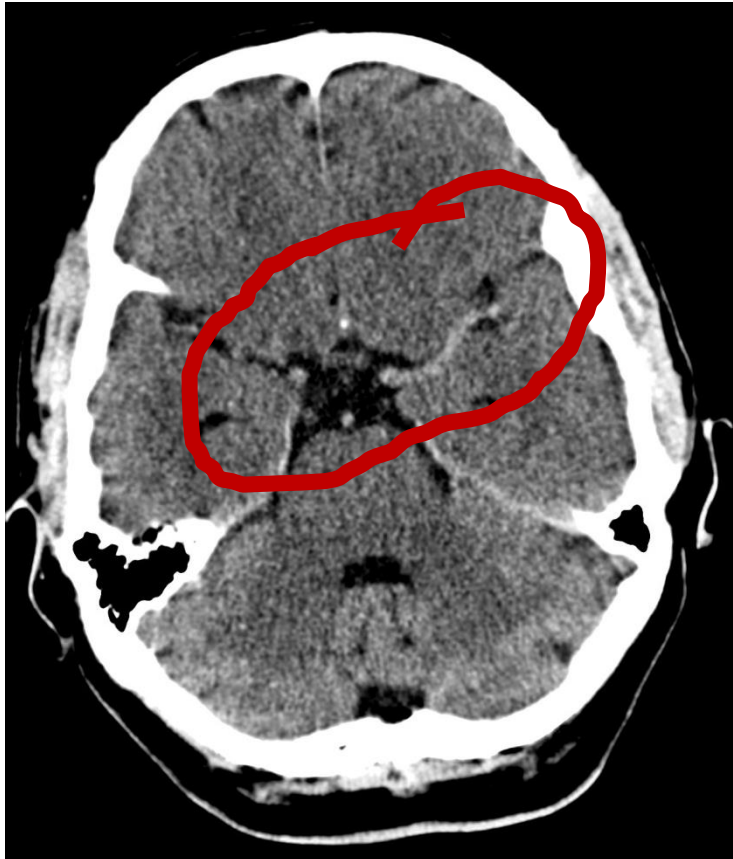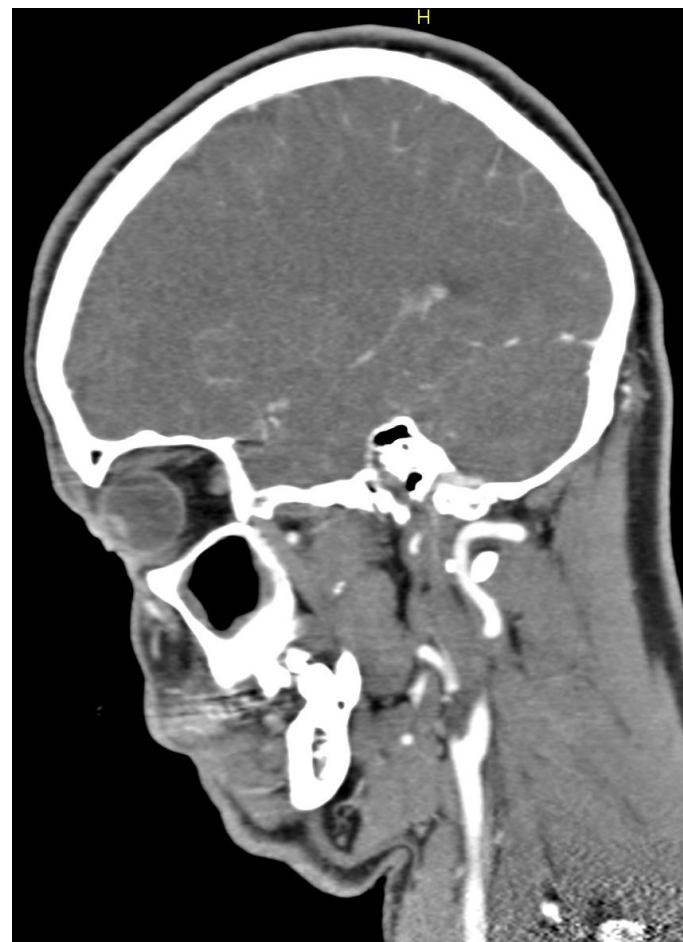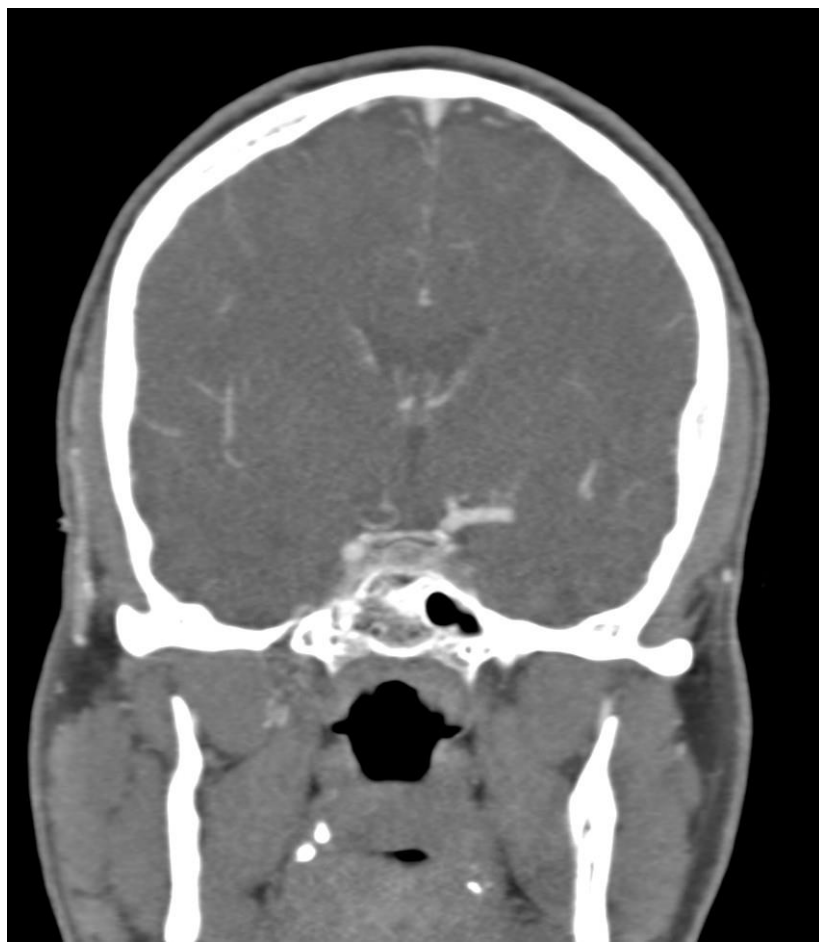


18.04.2013, 9:03

47 y/o man, 2h aphasia, hemiparesis right



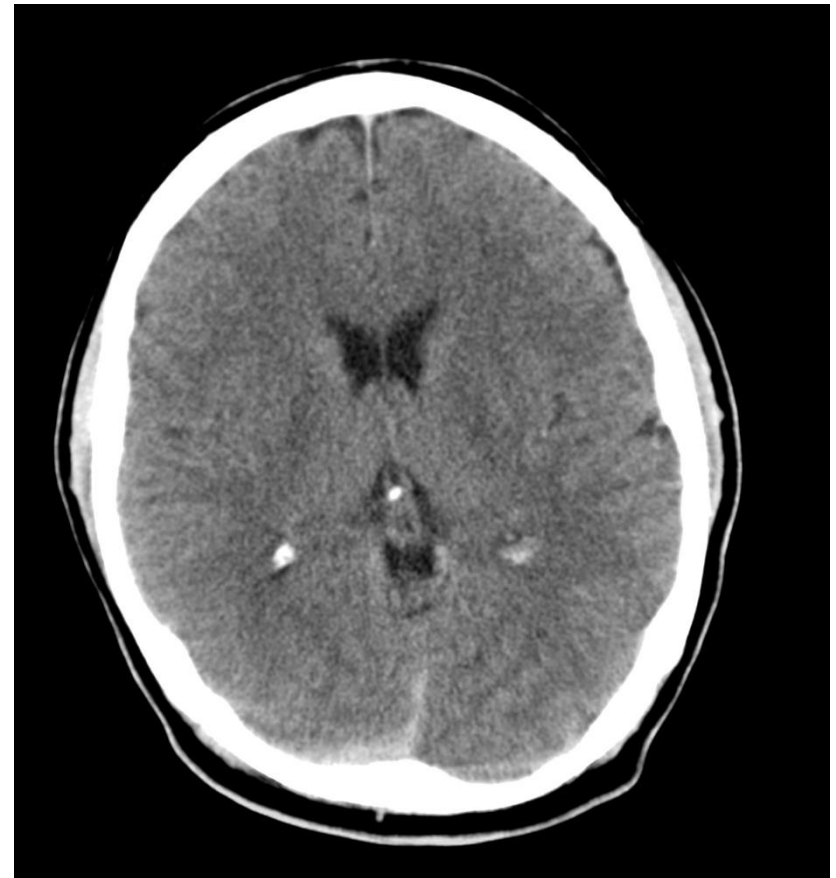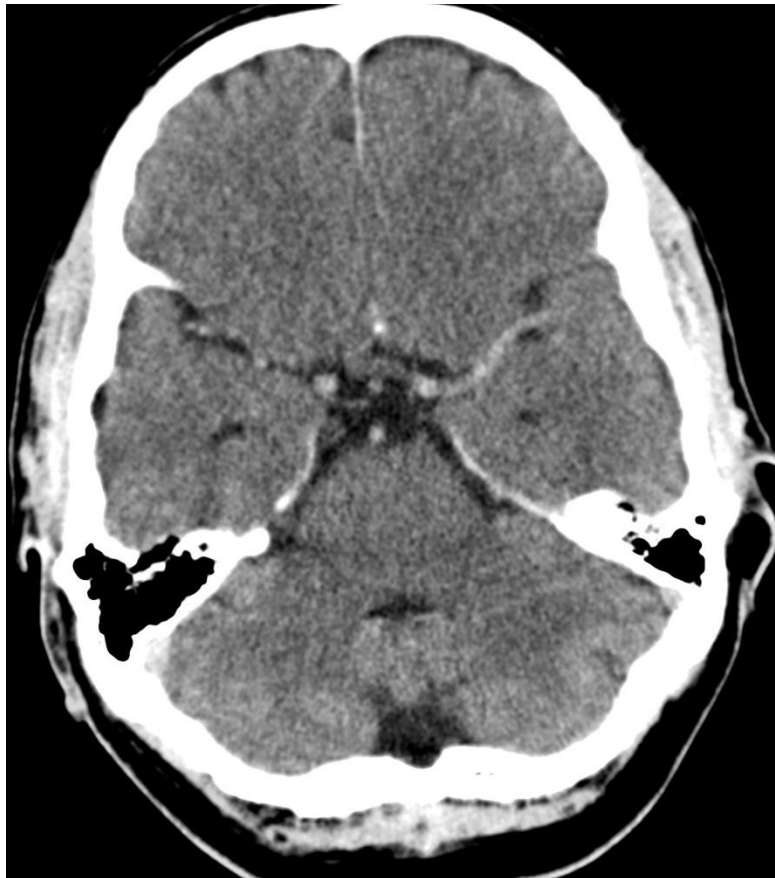
18.04.2013, 9:03



18.04.2013, 10:17



Auswärtiges Krankenhaus:
No improvement after IV tPA
Mechanical recanalisation in UKE (my hospital)



Some things are just not fibrinolysable ...

