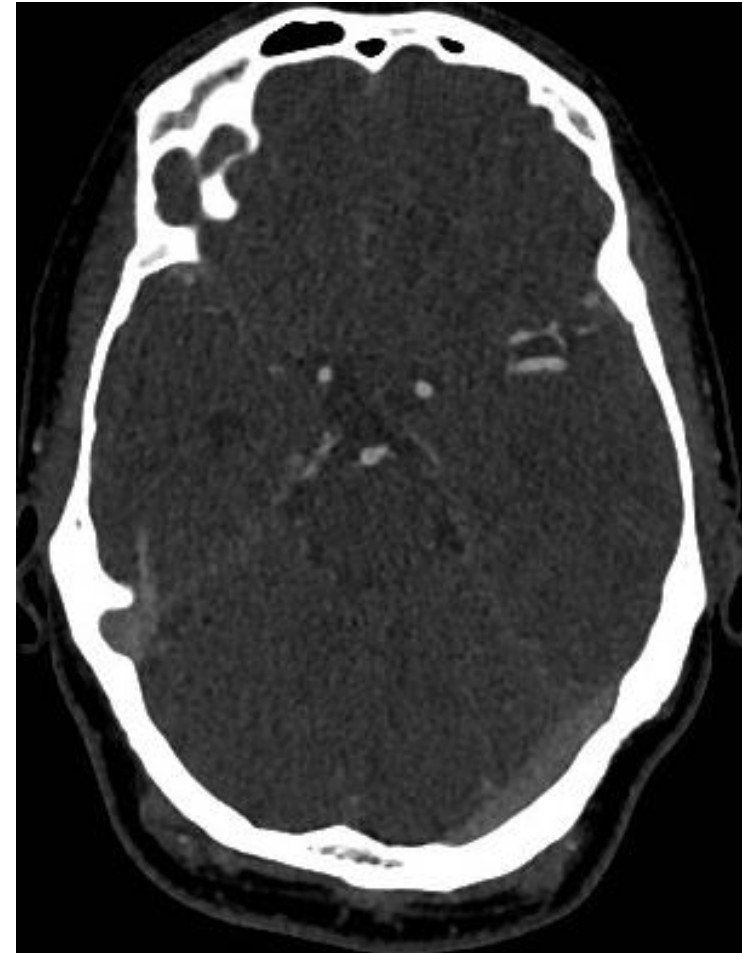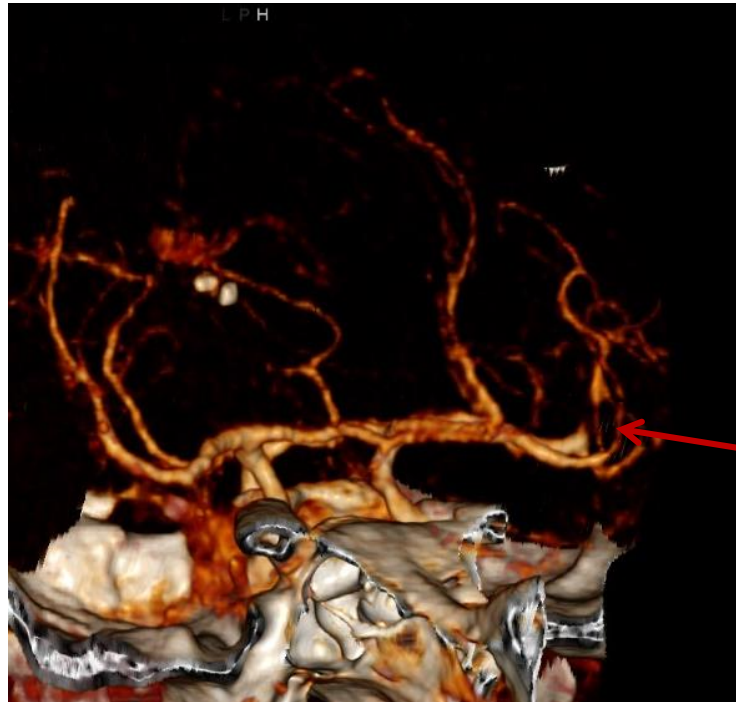


Case 20

48 yo male

NIHSS 4 at admission (aphasia, drift right arm)

CTA



Case 20

48 yo male

NIHSS 4 at admission (aphasia, drift right arm)

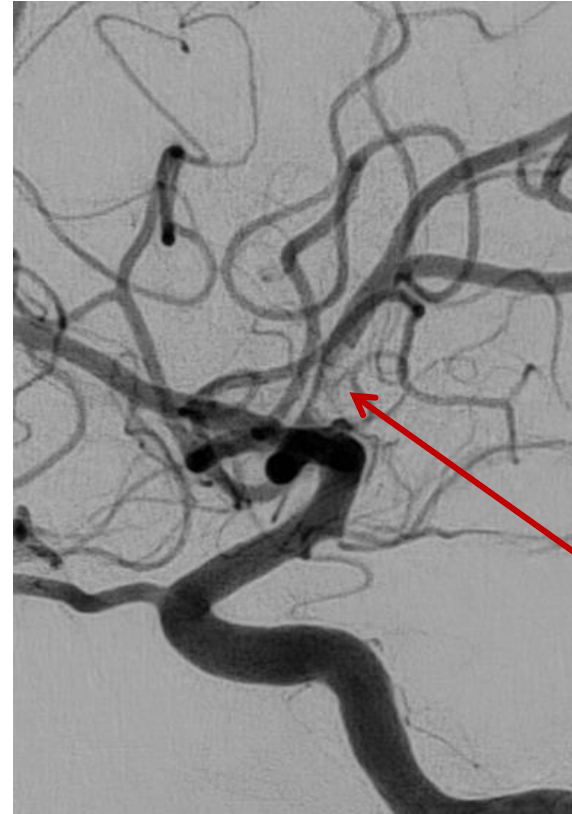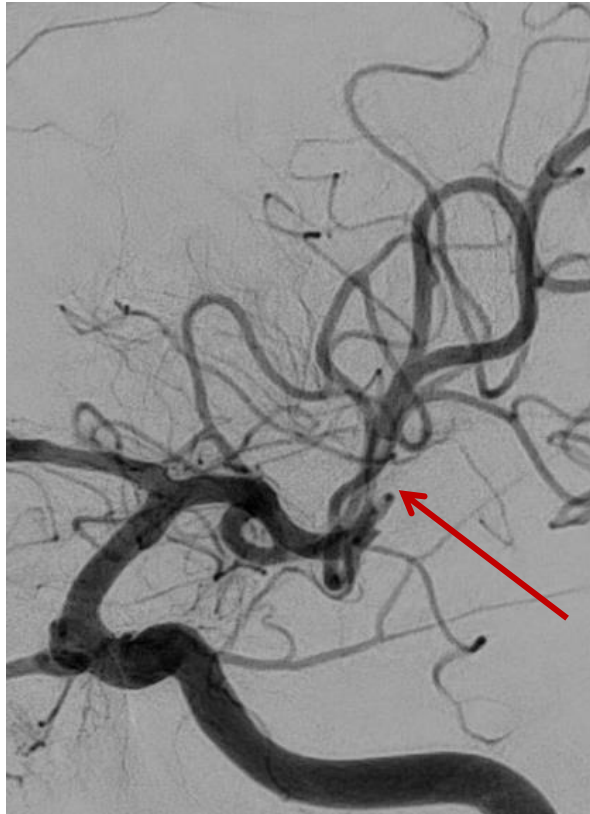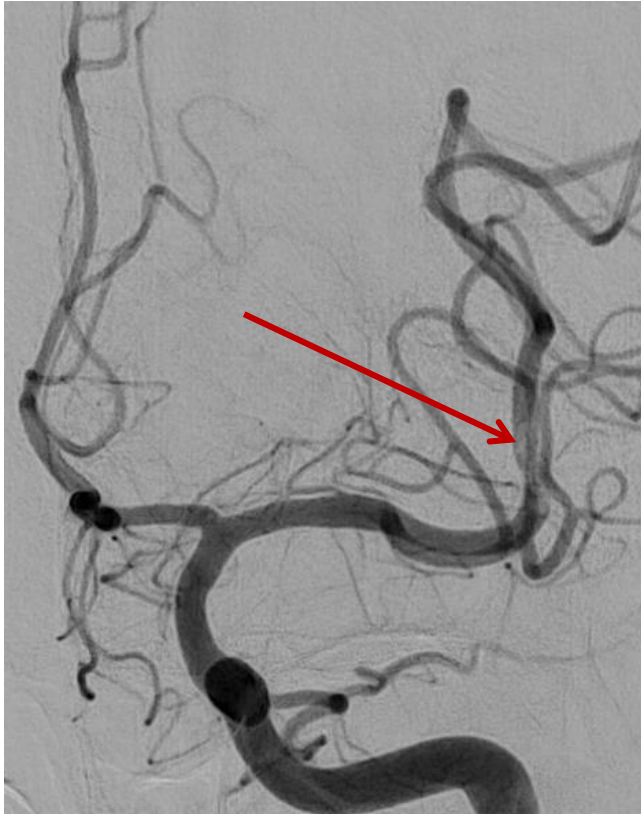
CTA

=> NIHSS 0 after CTA

What to do??

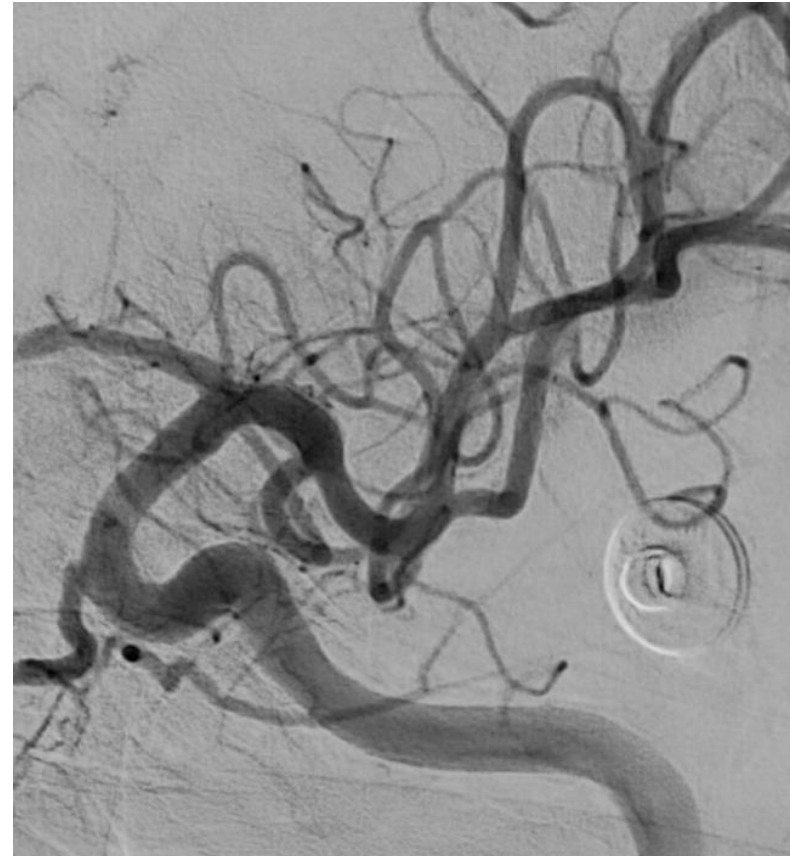
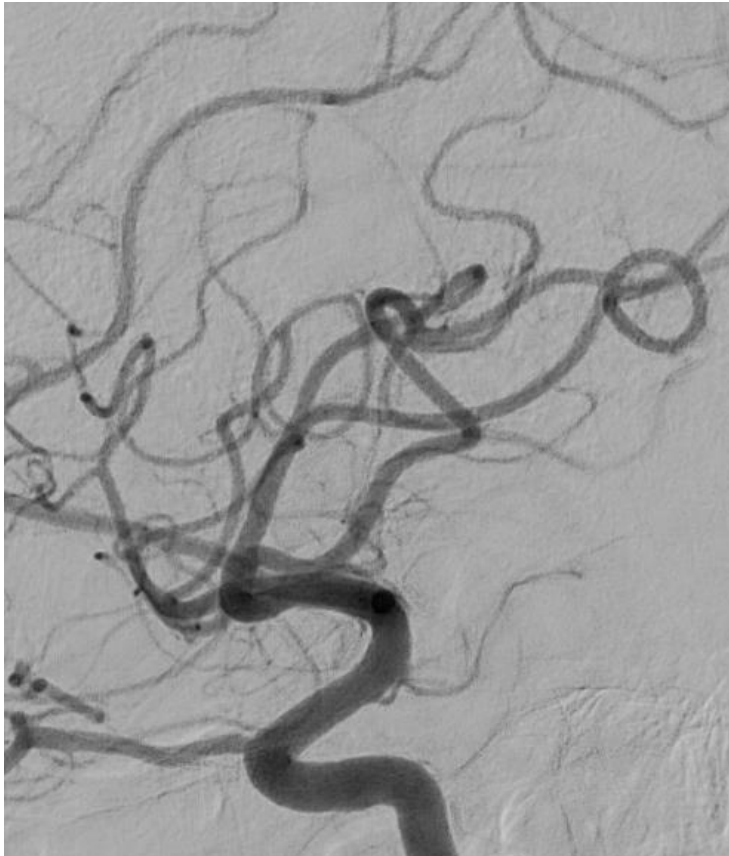
Case 20



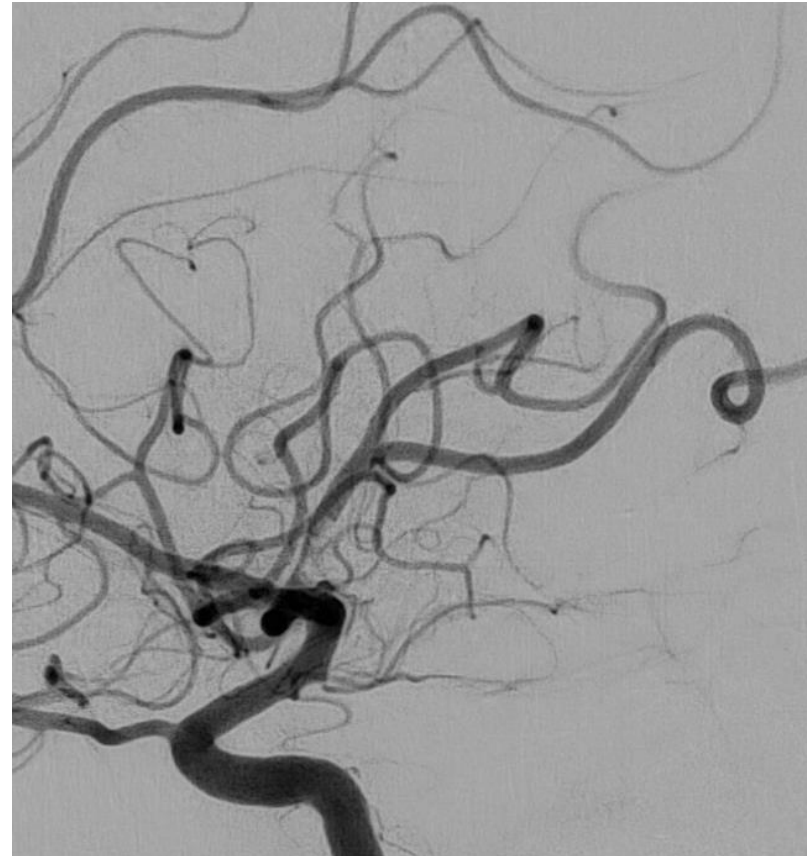
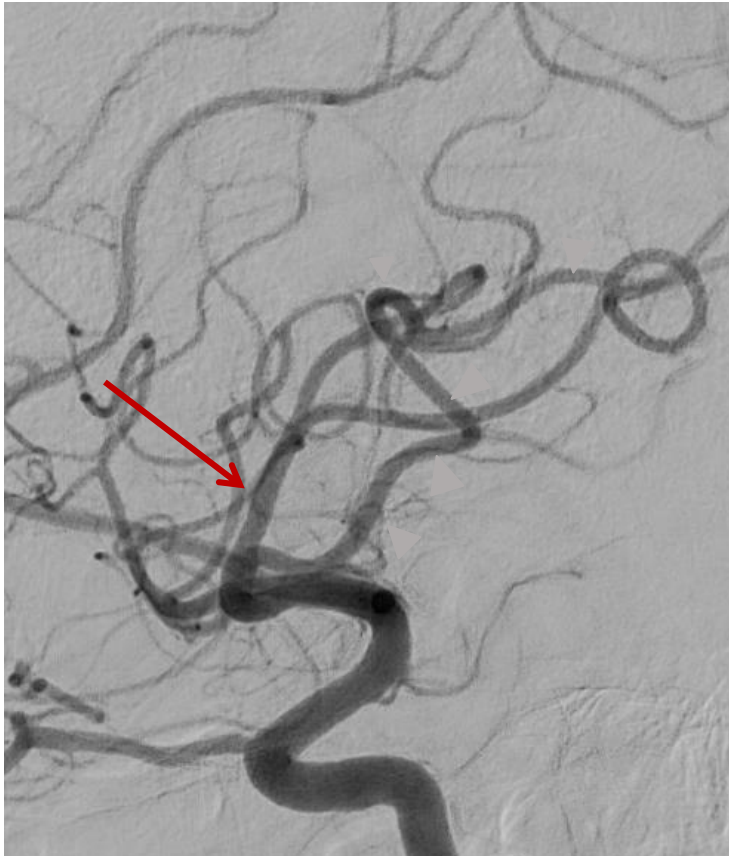
Case 20

Thrombus aspiration with Sofia 5Fr



Case 20

Thrombus aspiration with Sofia 5Fr



Pre treatment

Case 20

48 yo male

NIHSS 0

mRS 0

Discharged after 2 days

Too good to intervene? Thrombectomy for large vessel occlusion strokes with minimal symptoms: an intention-to-treat analysis

Diogo C Haussen, Mehdi Bousslama, Jonathan A Grossberg, Aaron Anderson, Samir Belagage, Michael Frankel, Nicolas Bianchi, Leticia C Rebello, Raul G Nogueira

J NeuroIntervent Surg 2016;0:1–5. doi:10.1136/neurintsurg-2016-012633