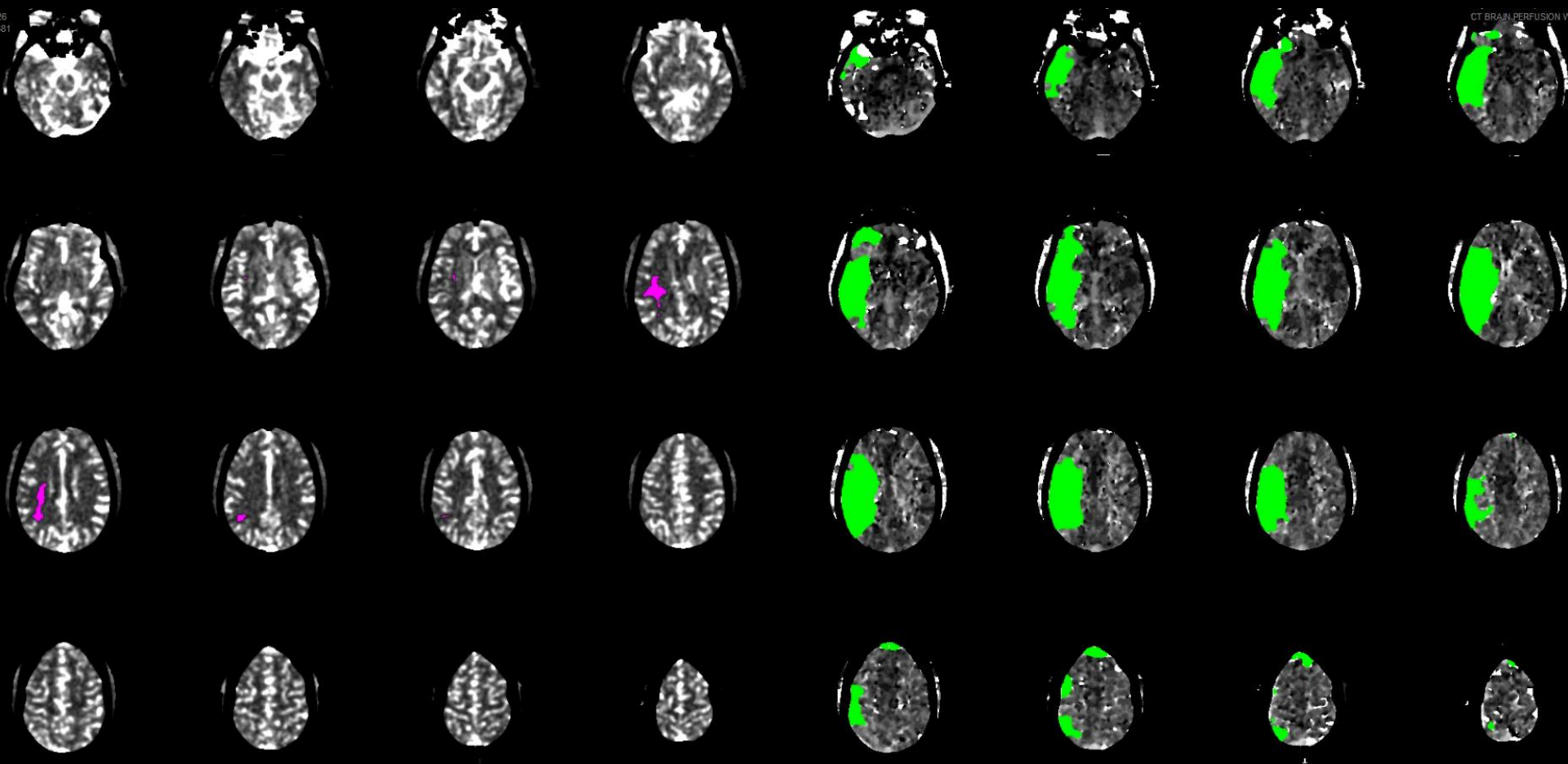


CASE #1

48yo HTN and DM. NIHSS 16. IV tPA.

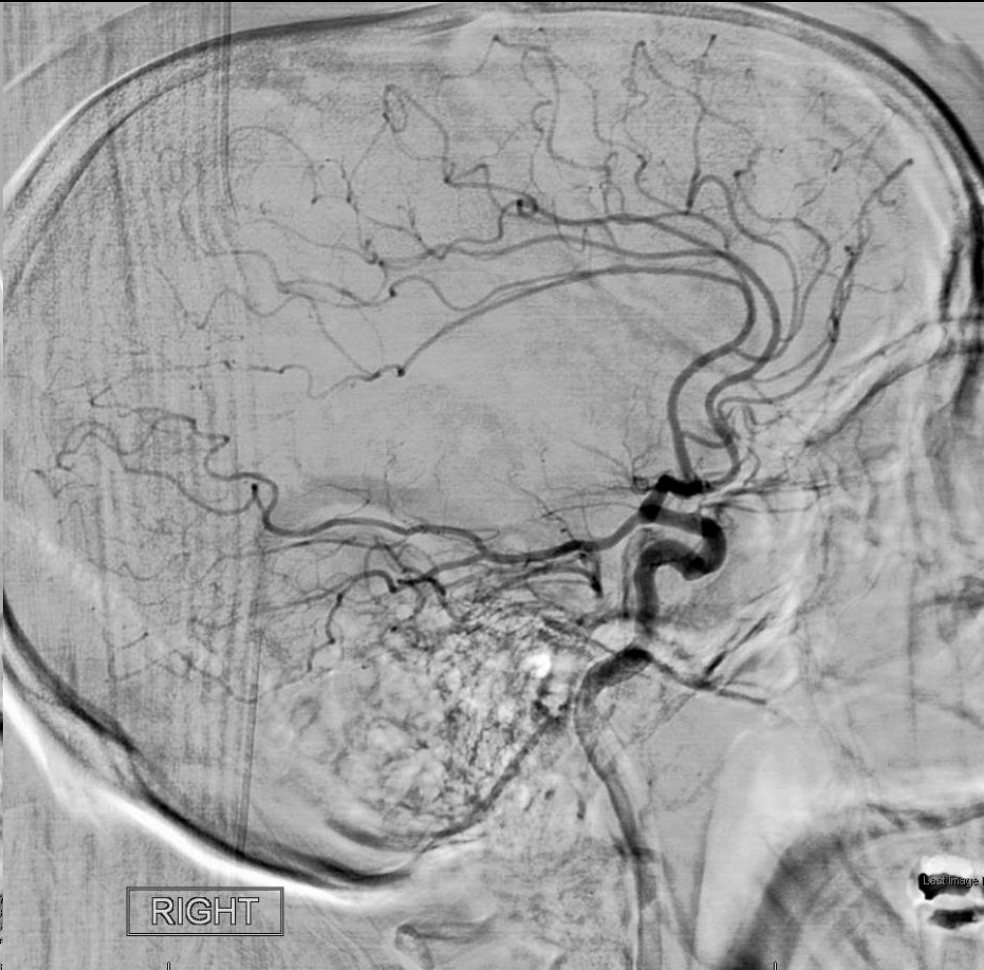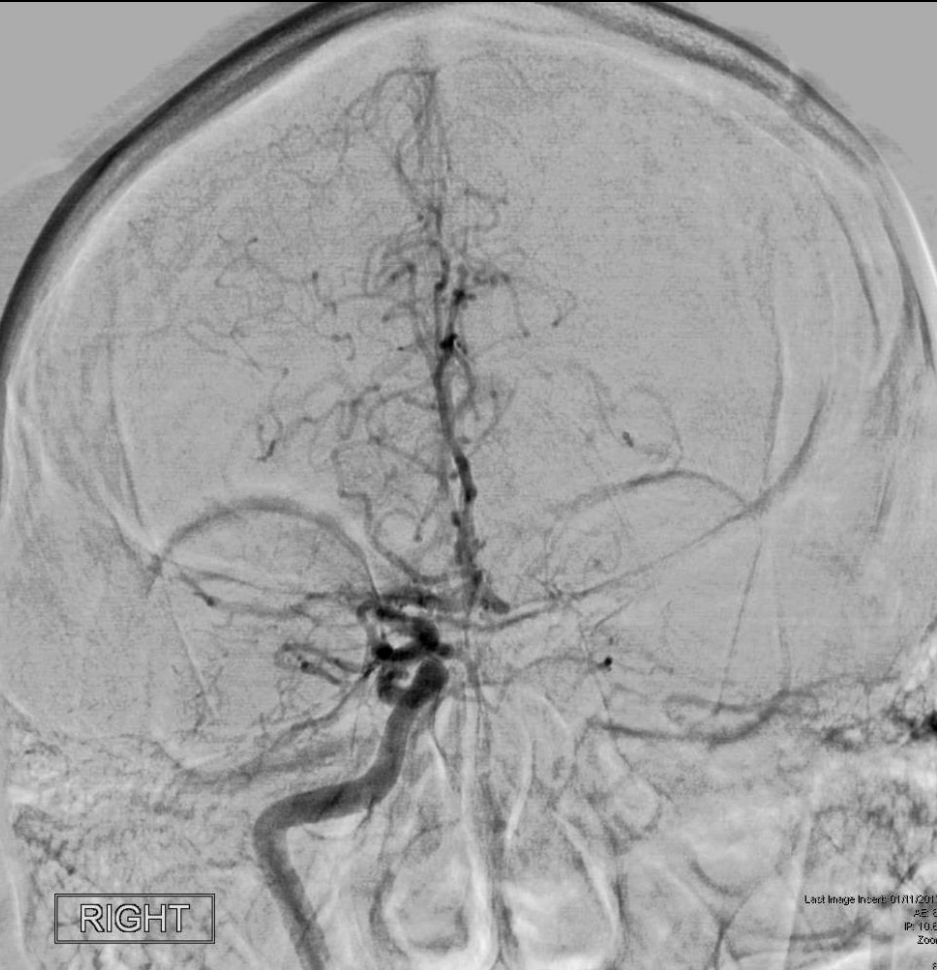


CBF (<30%) volume: 4.3 ml

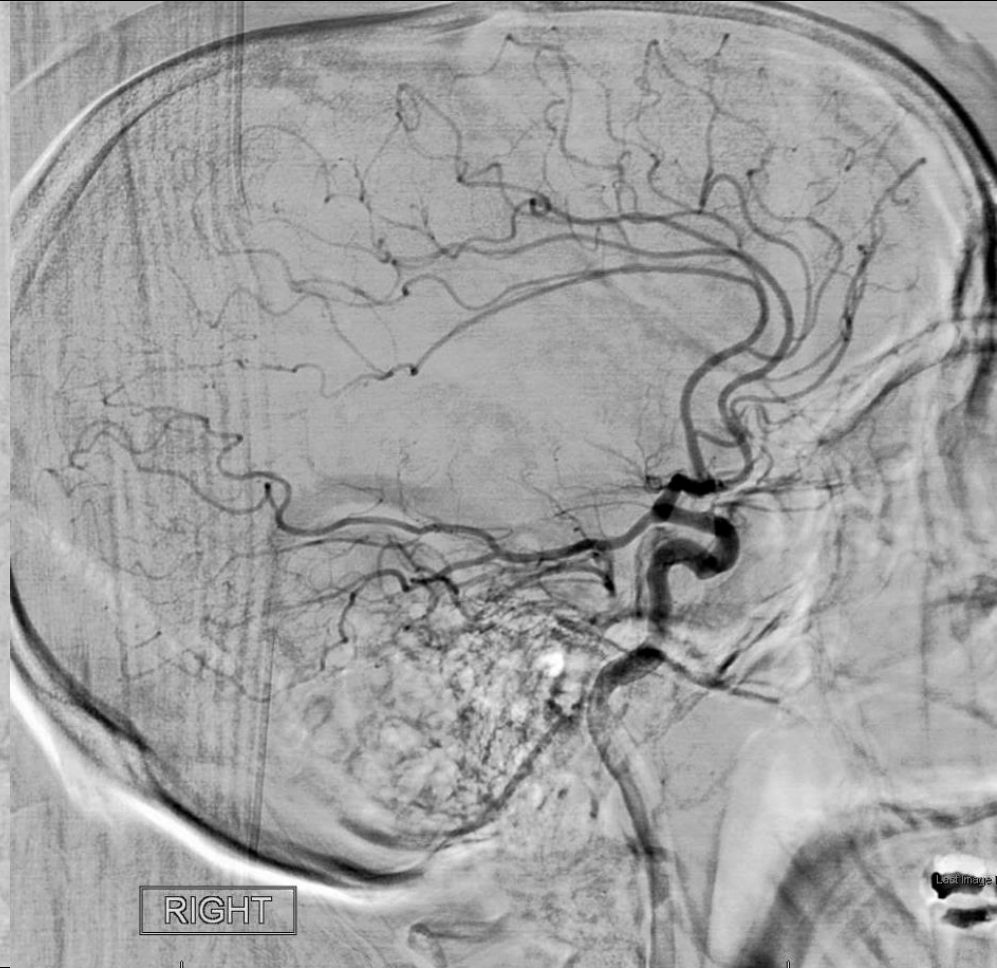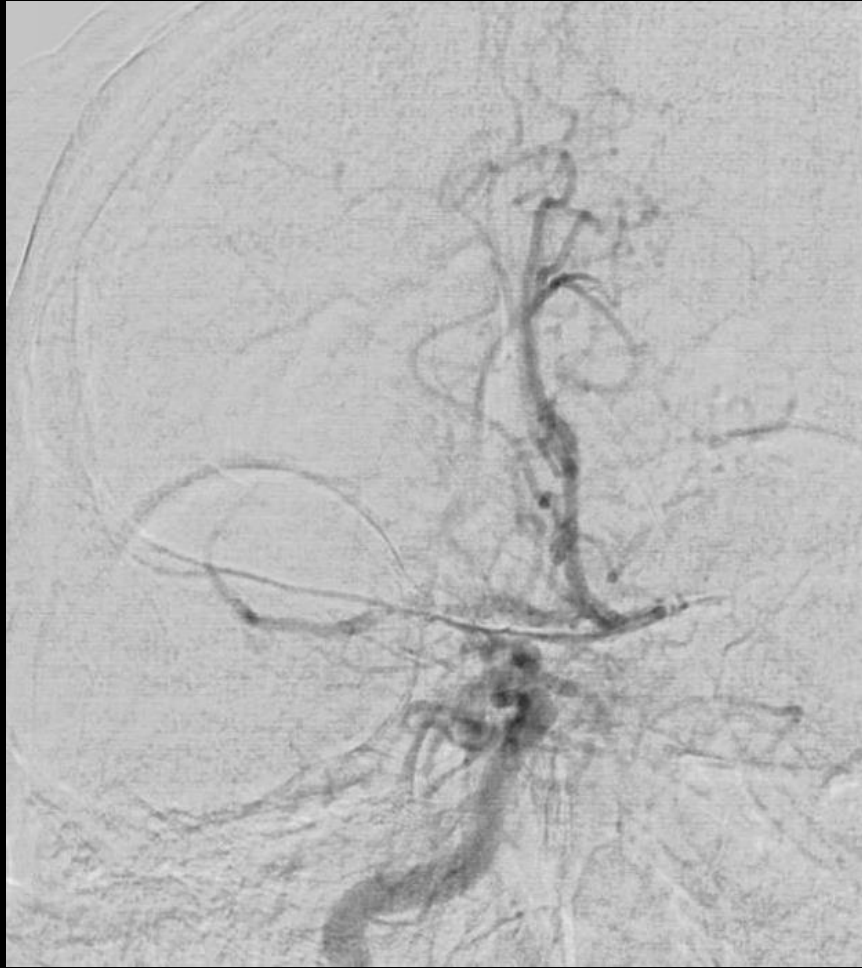Perfusion (Tmax>6.0s) volume: 168.1 ml

Last Image Insert: 01/11/2

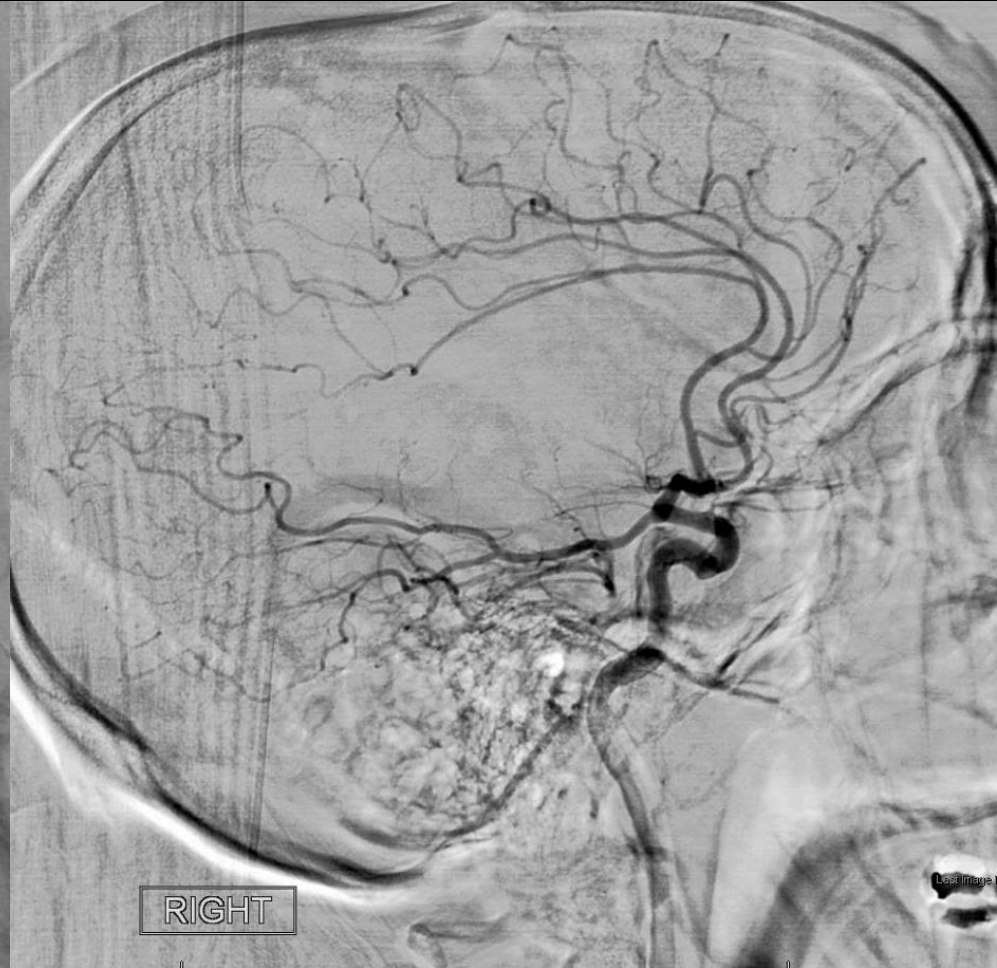
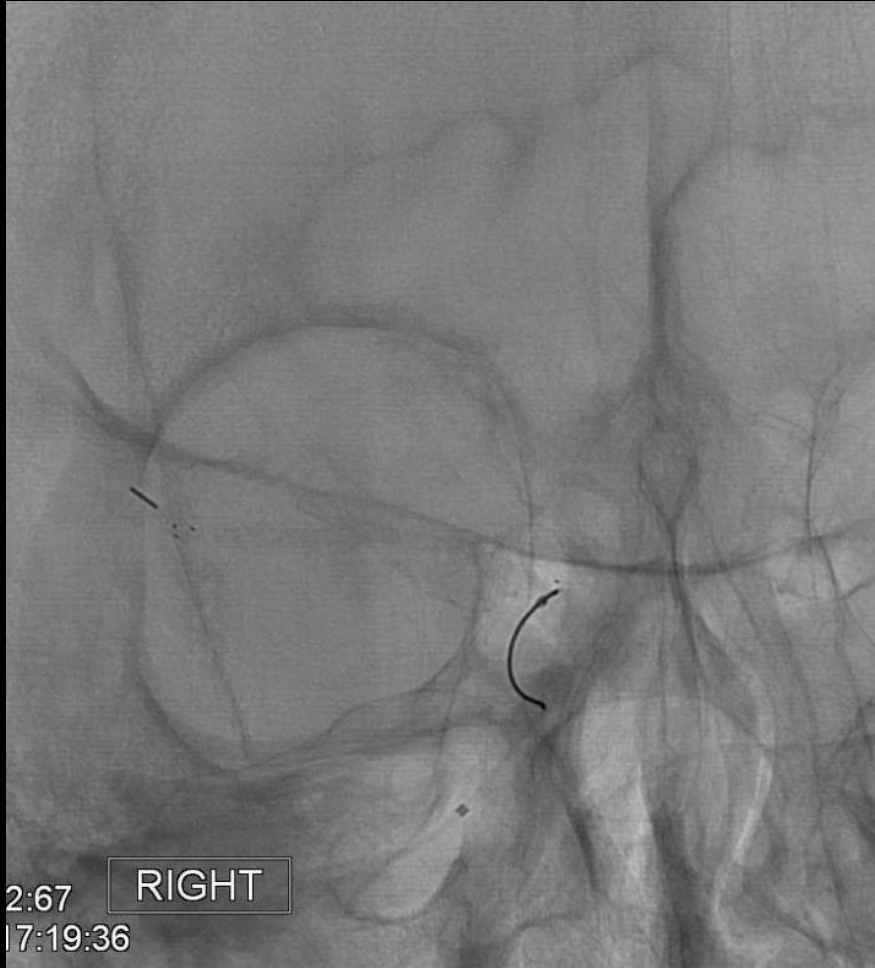Baseline (TICI1)



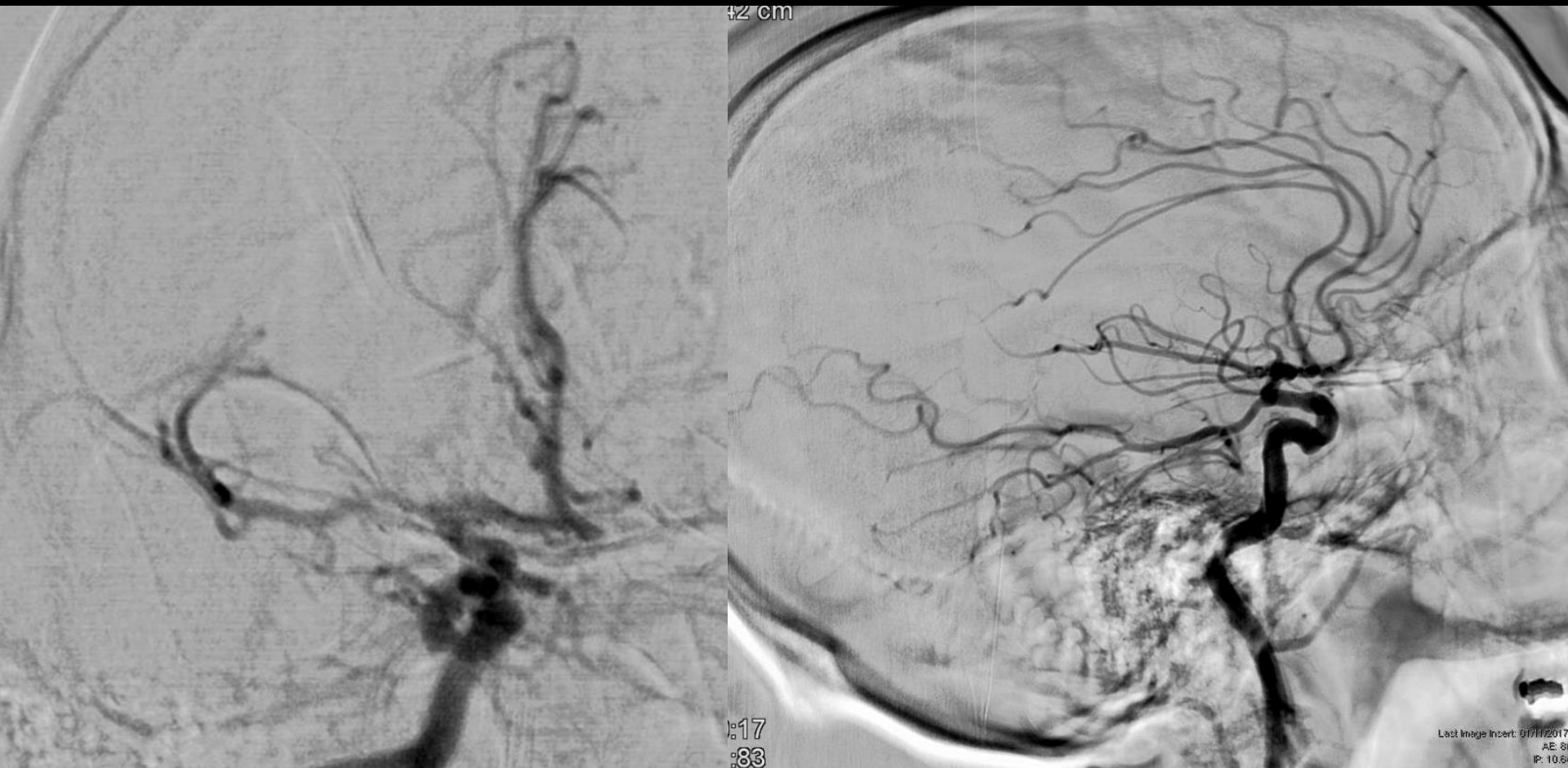Baseline (AP LAO)



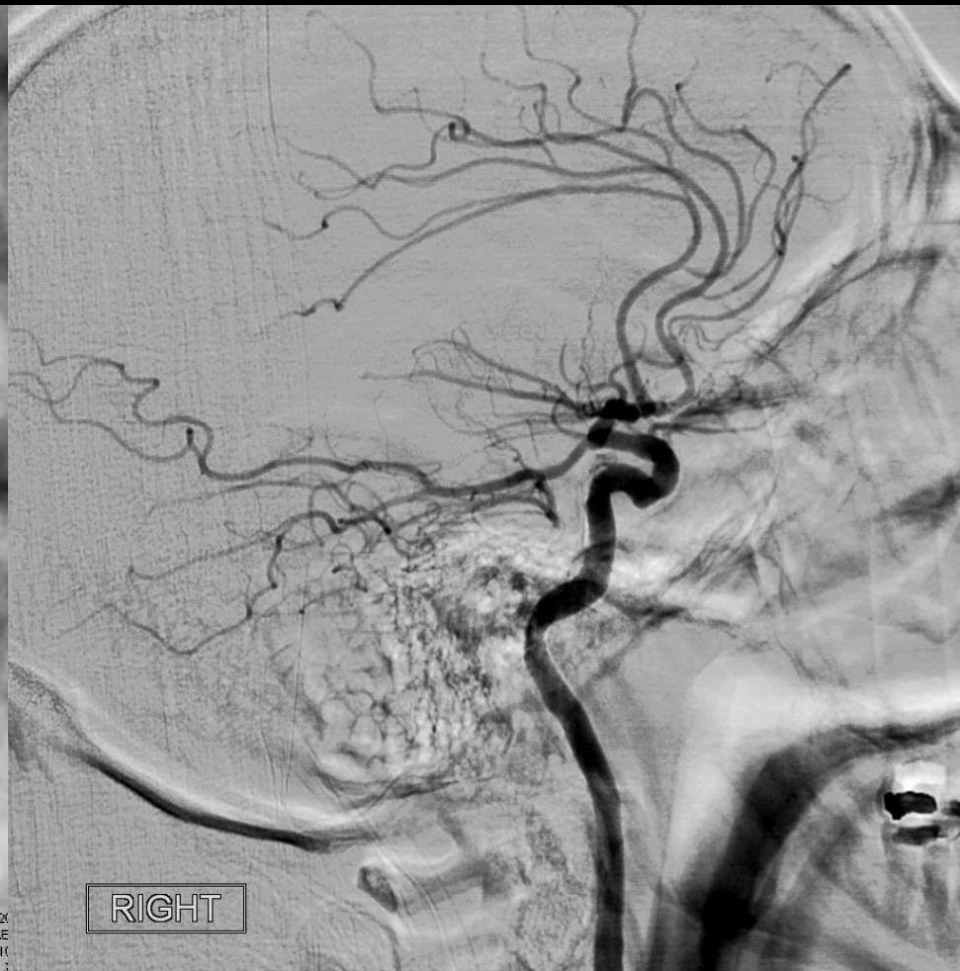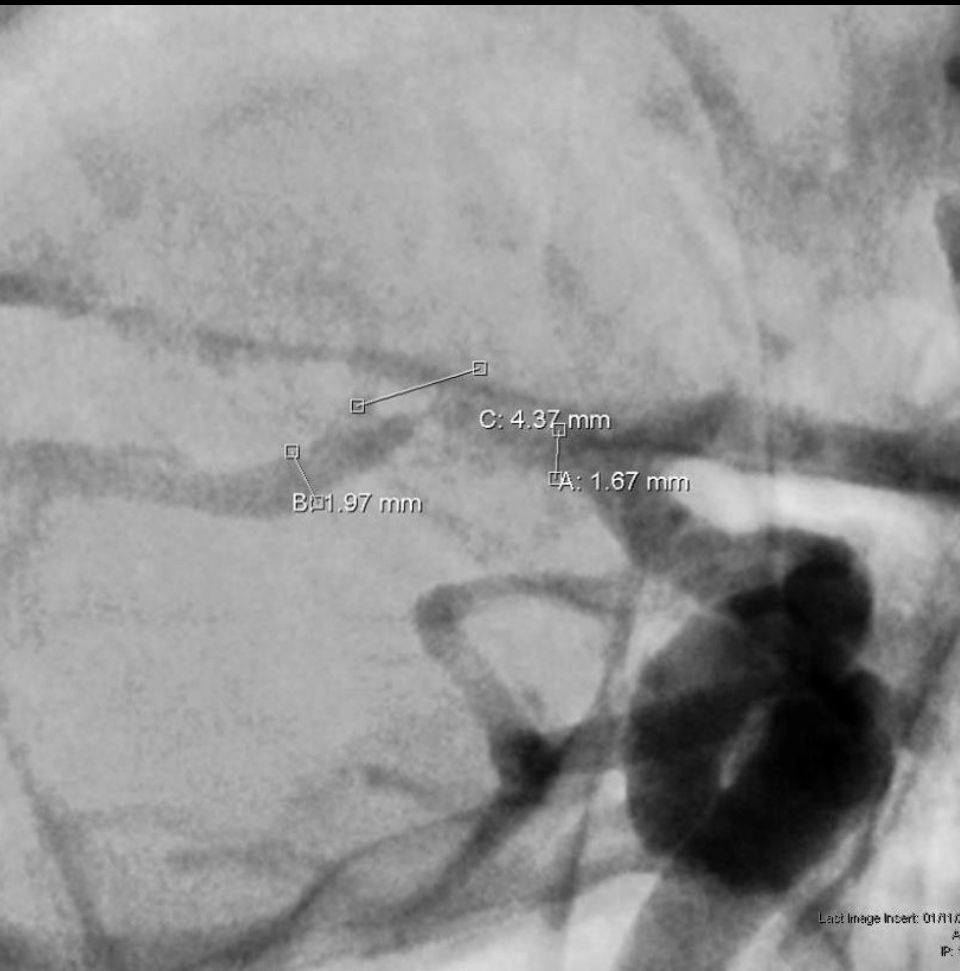
Embotrap



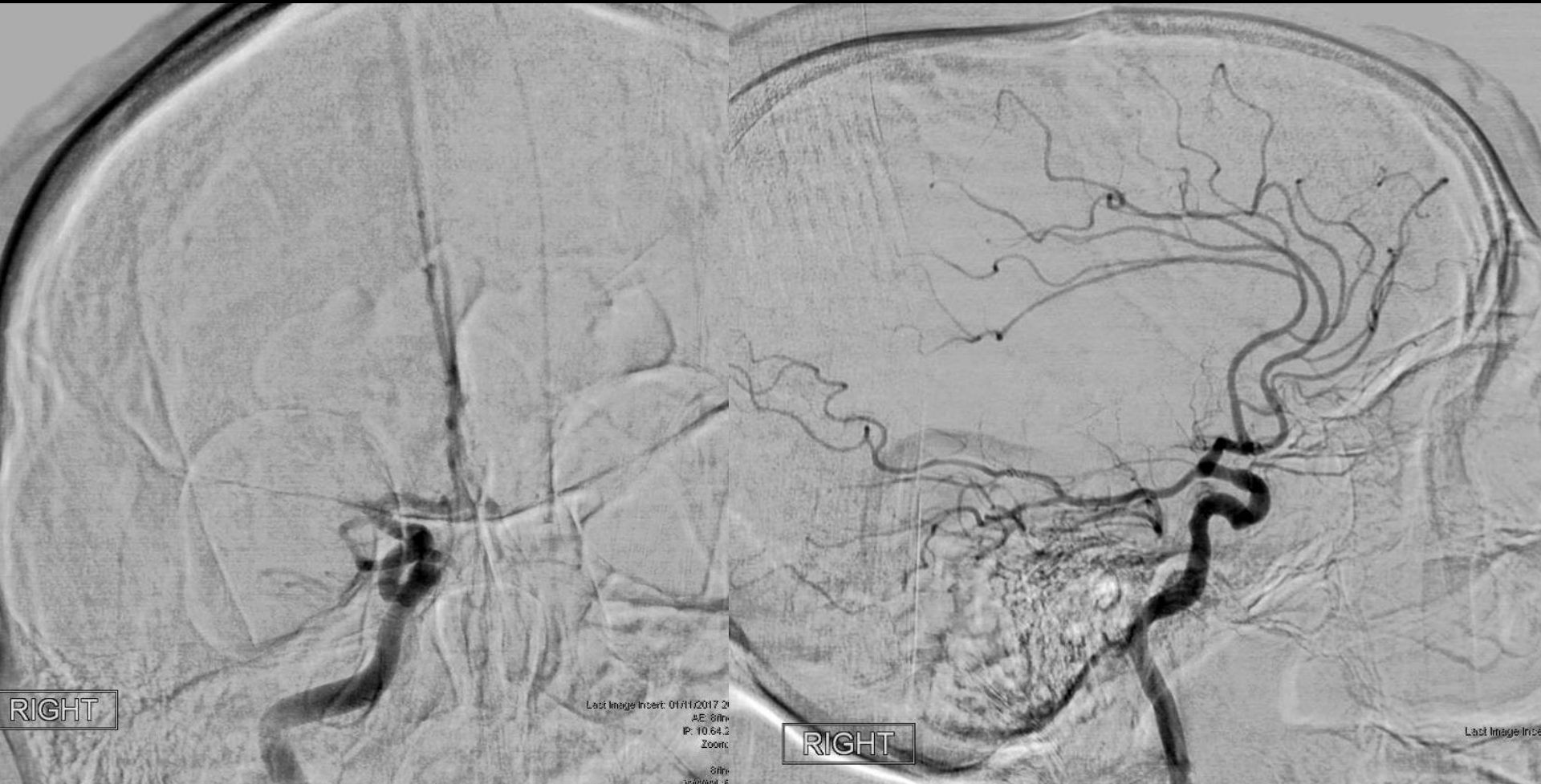Embotrap – First Pass (TICI2c)



Repeat LAO: ?ICAD / Worsening Flow Heparin 3,000 + ASA 300mg PR

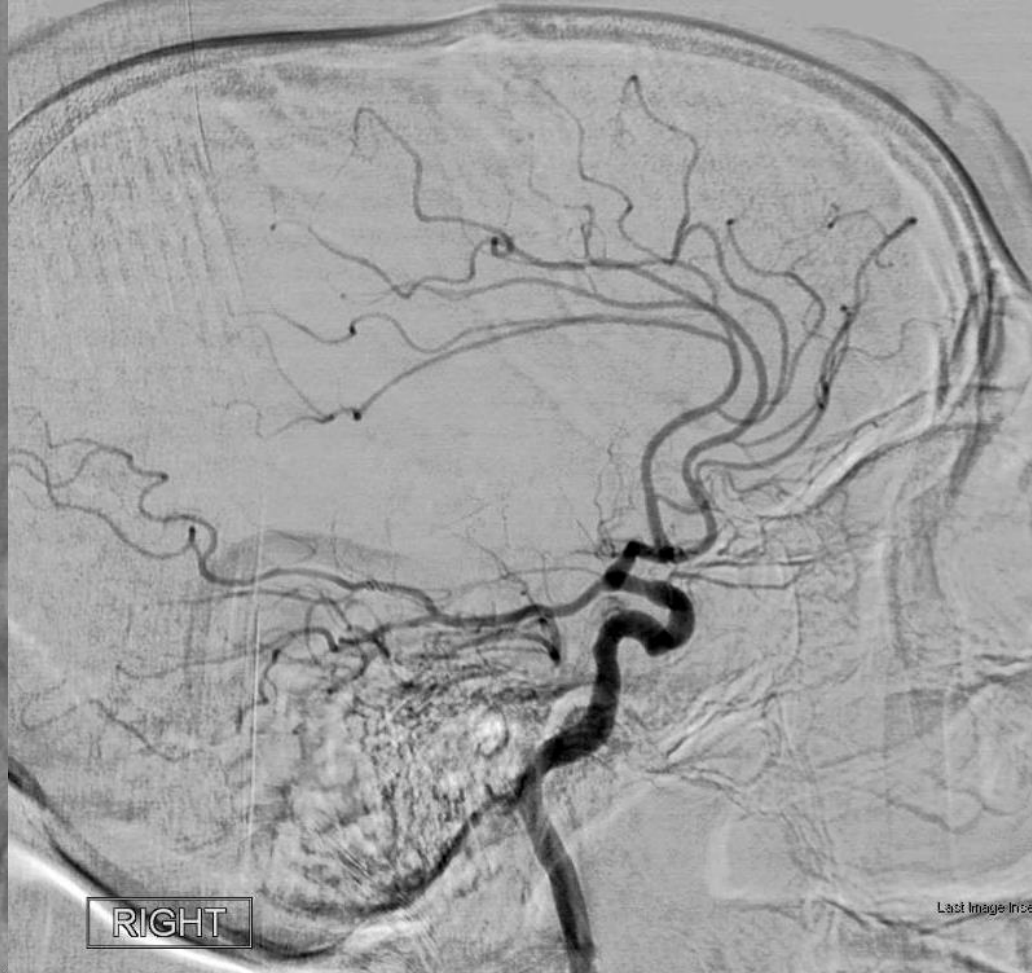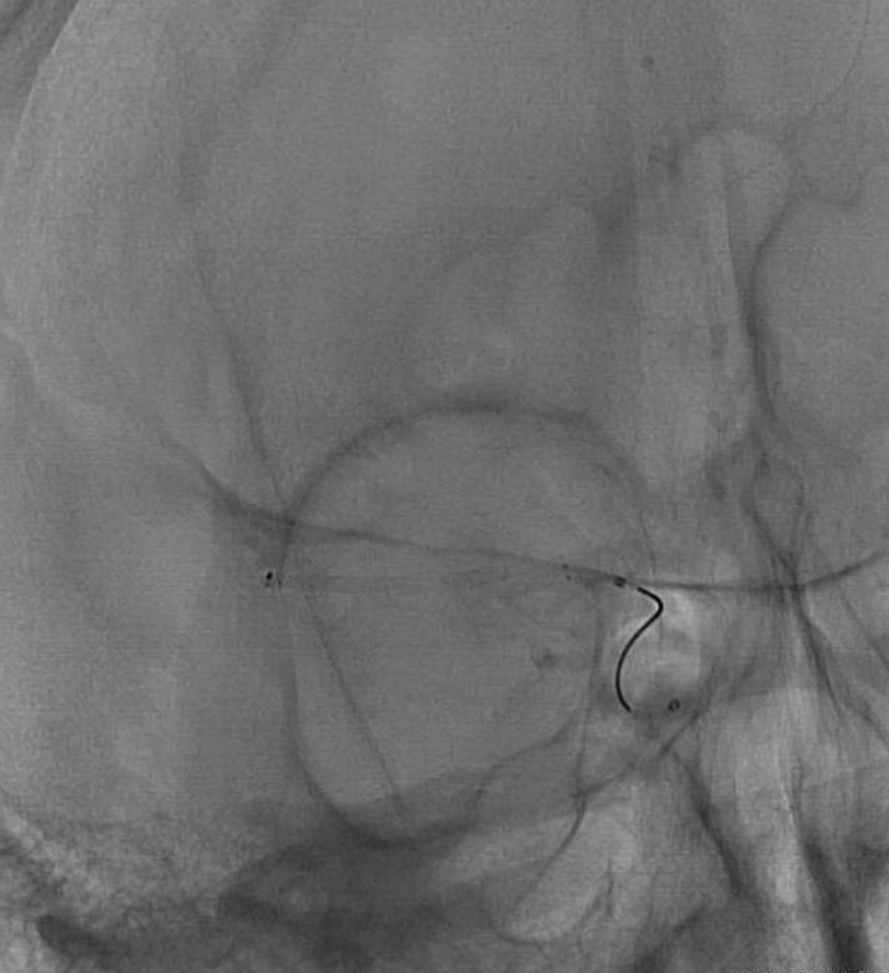


Repeat Run = TIC10

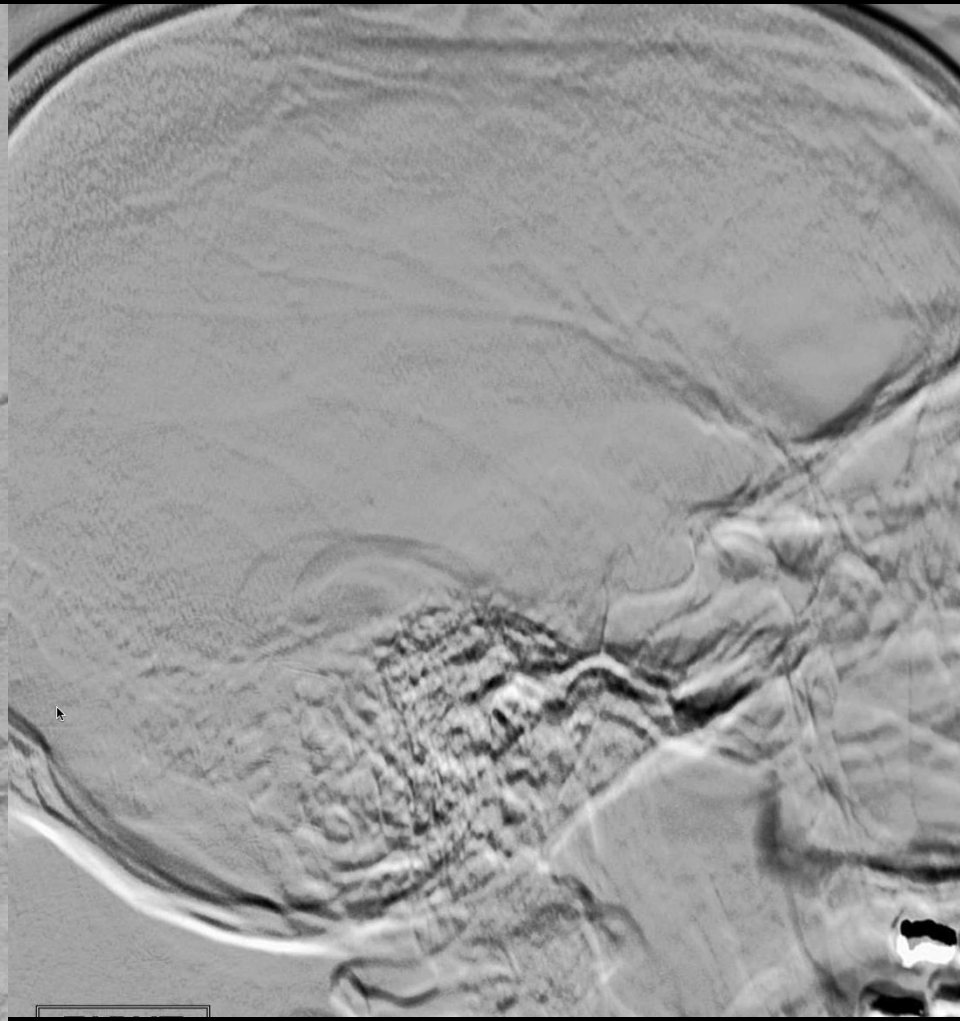
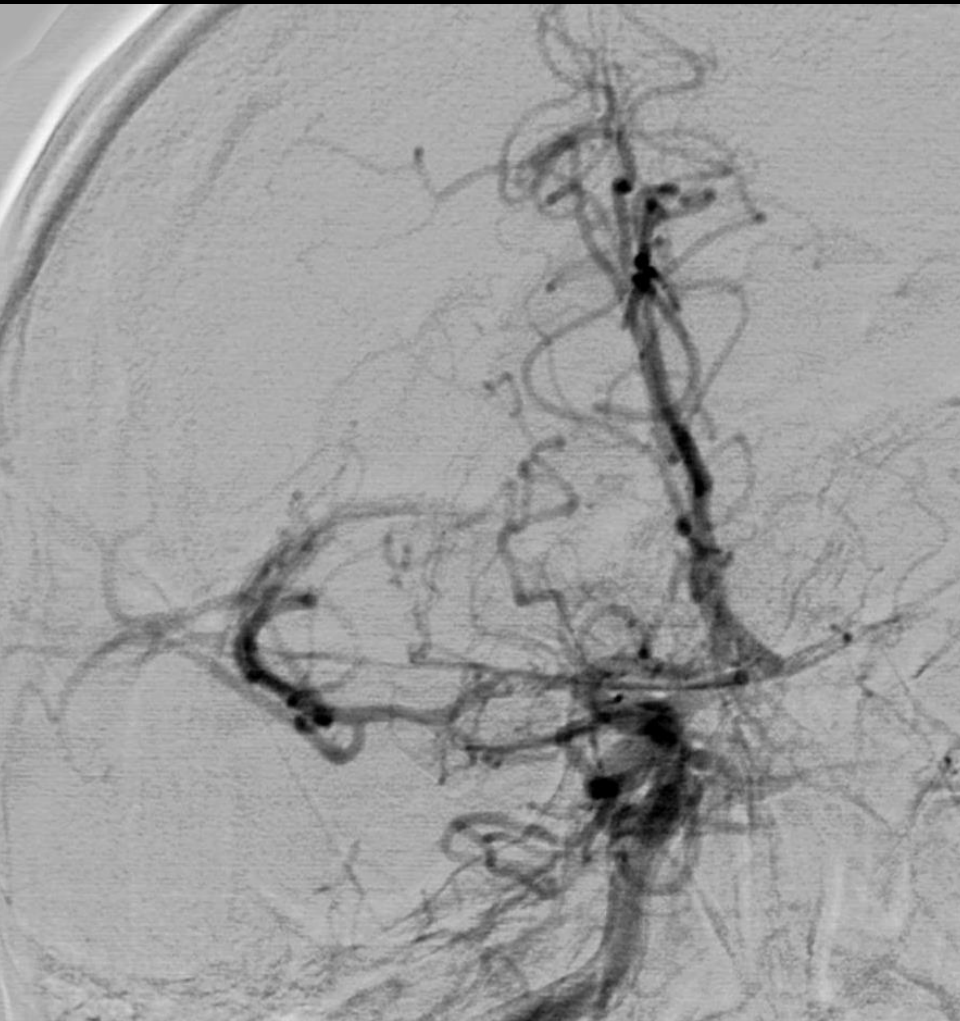

Embotrap 2nd Pass

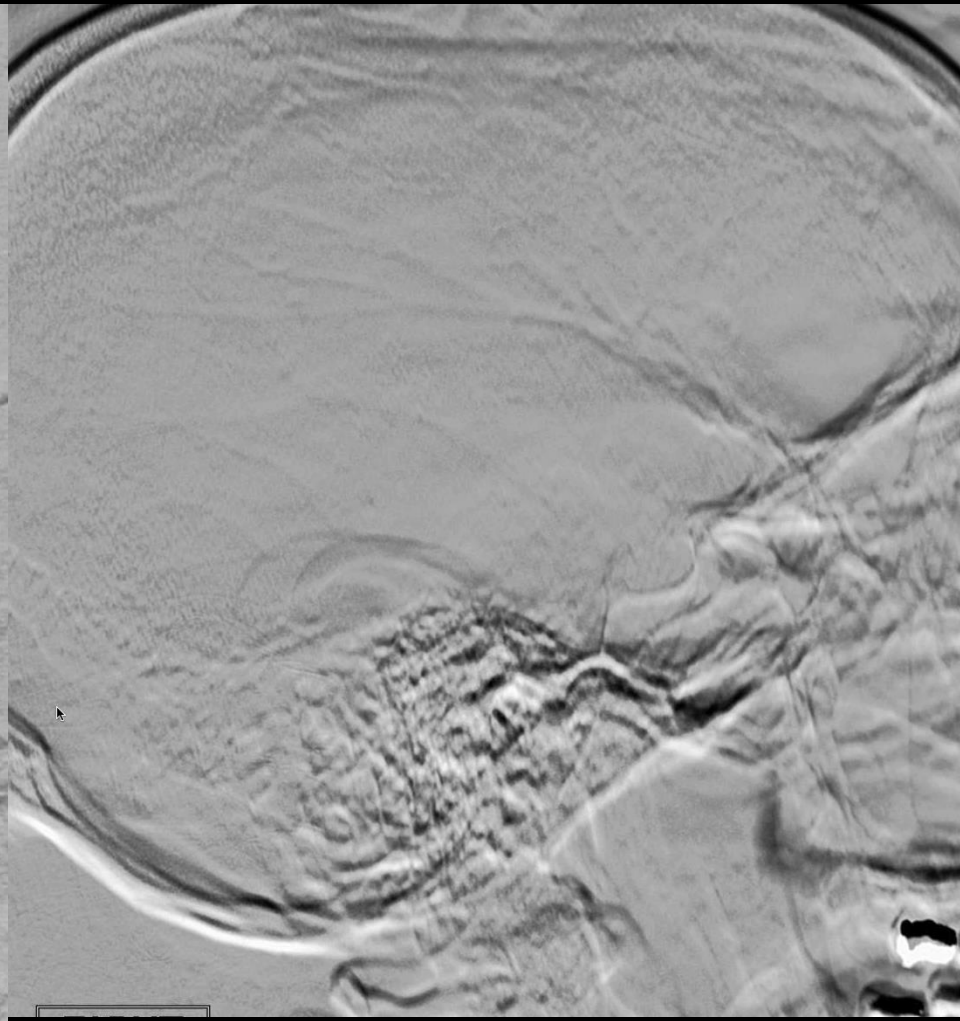
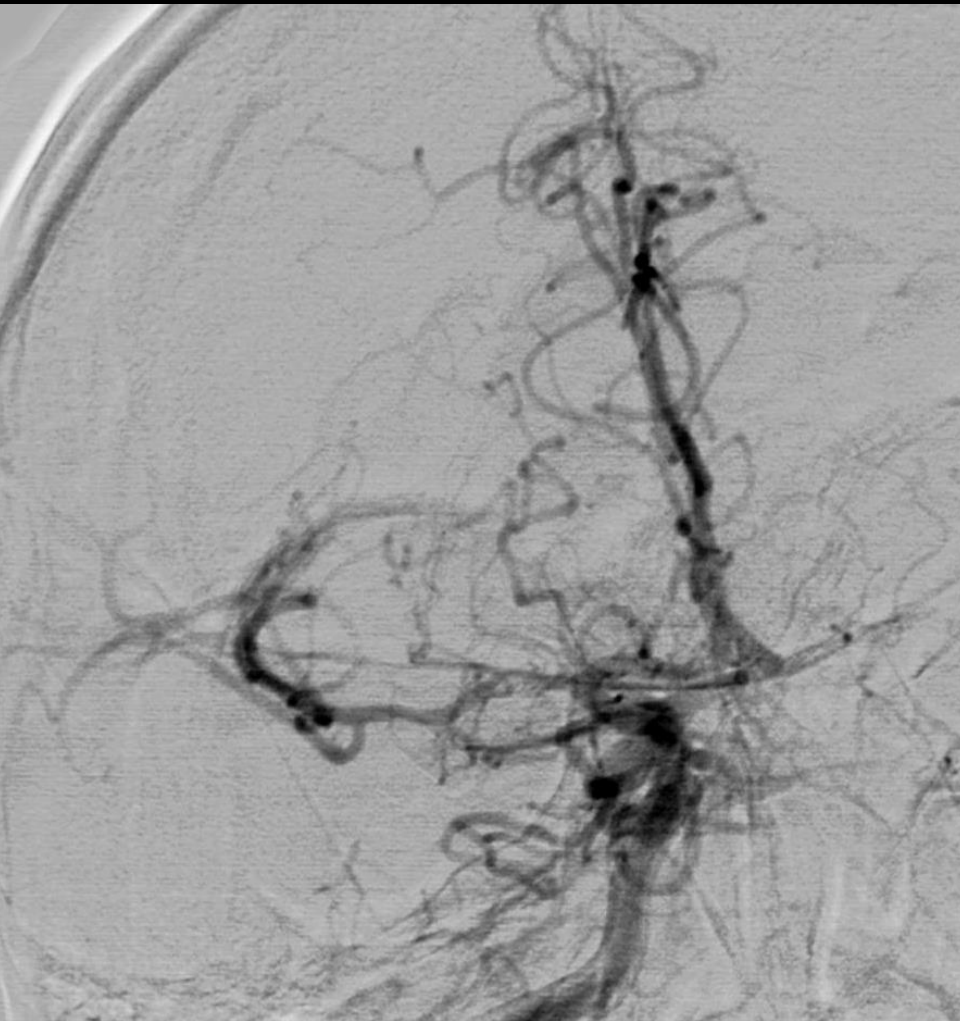
Reopro 8mg IA given via MC during deployment



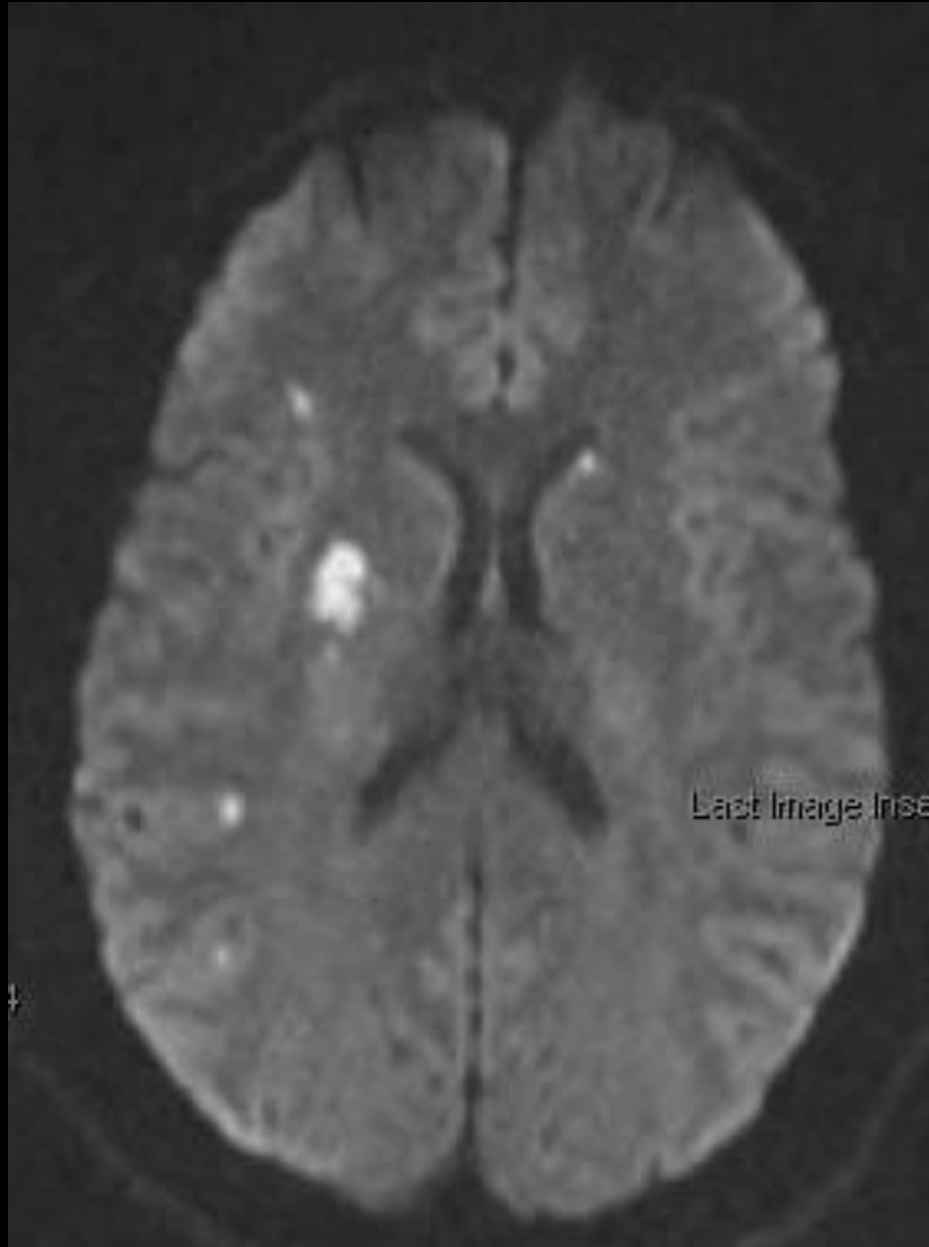
Embotrap 2nd Pass



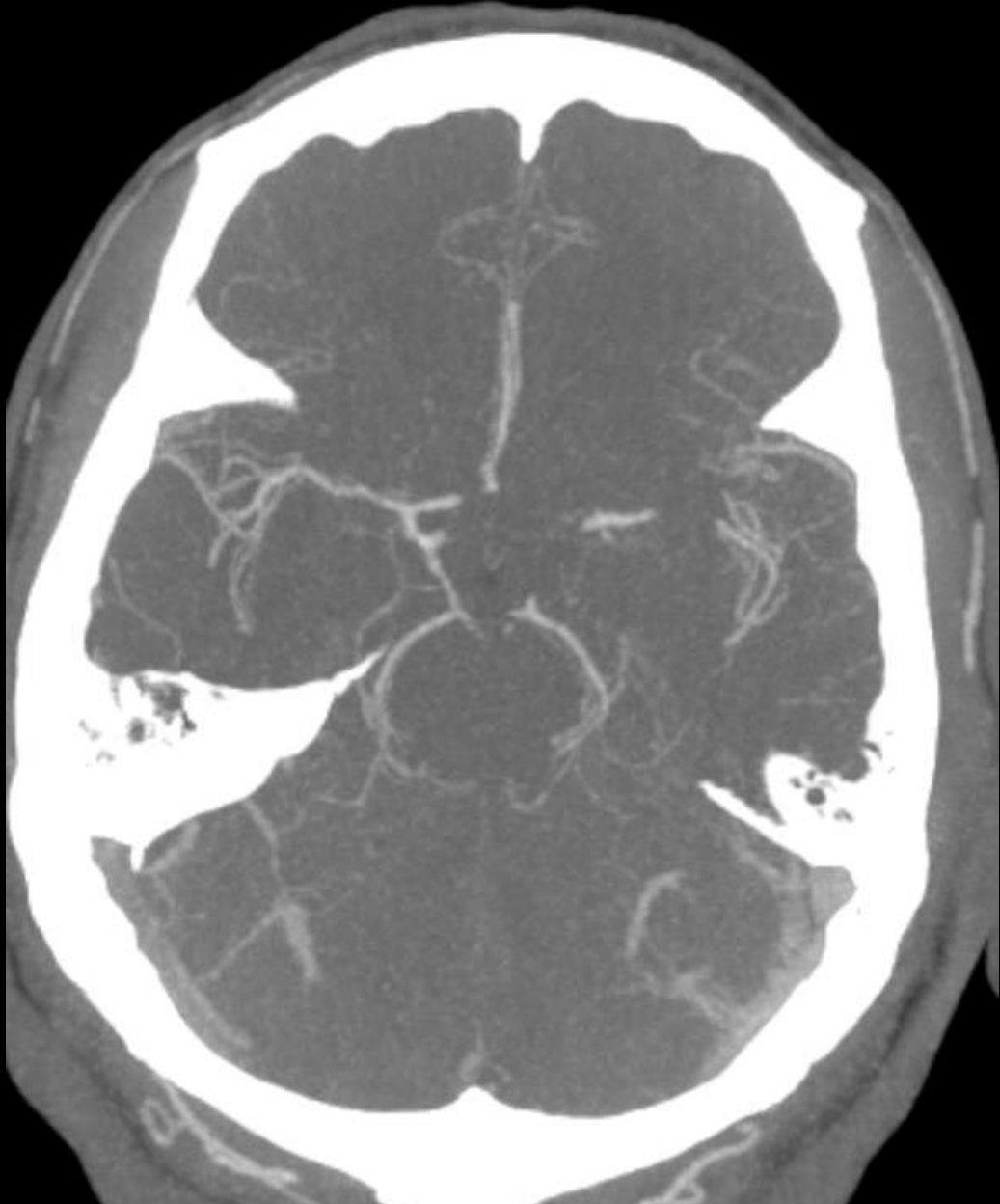Repeated runs x20 min = Stable



MRI DWI D3

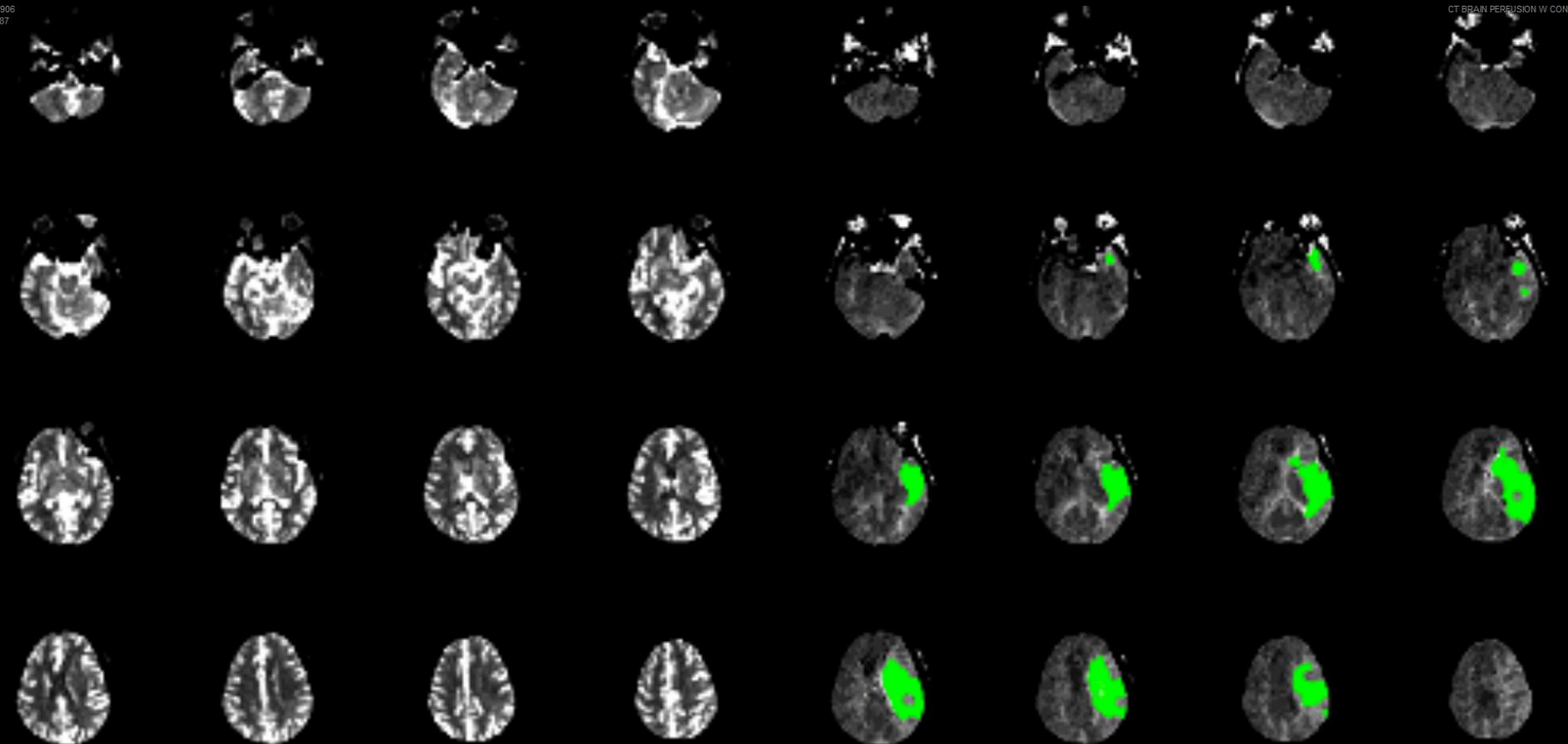


CTA 3 months



CASE #2

53yo HTN. ASPECTS 7. NIHSS 20. No tPA (no clear onset).

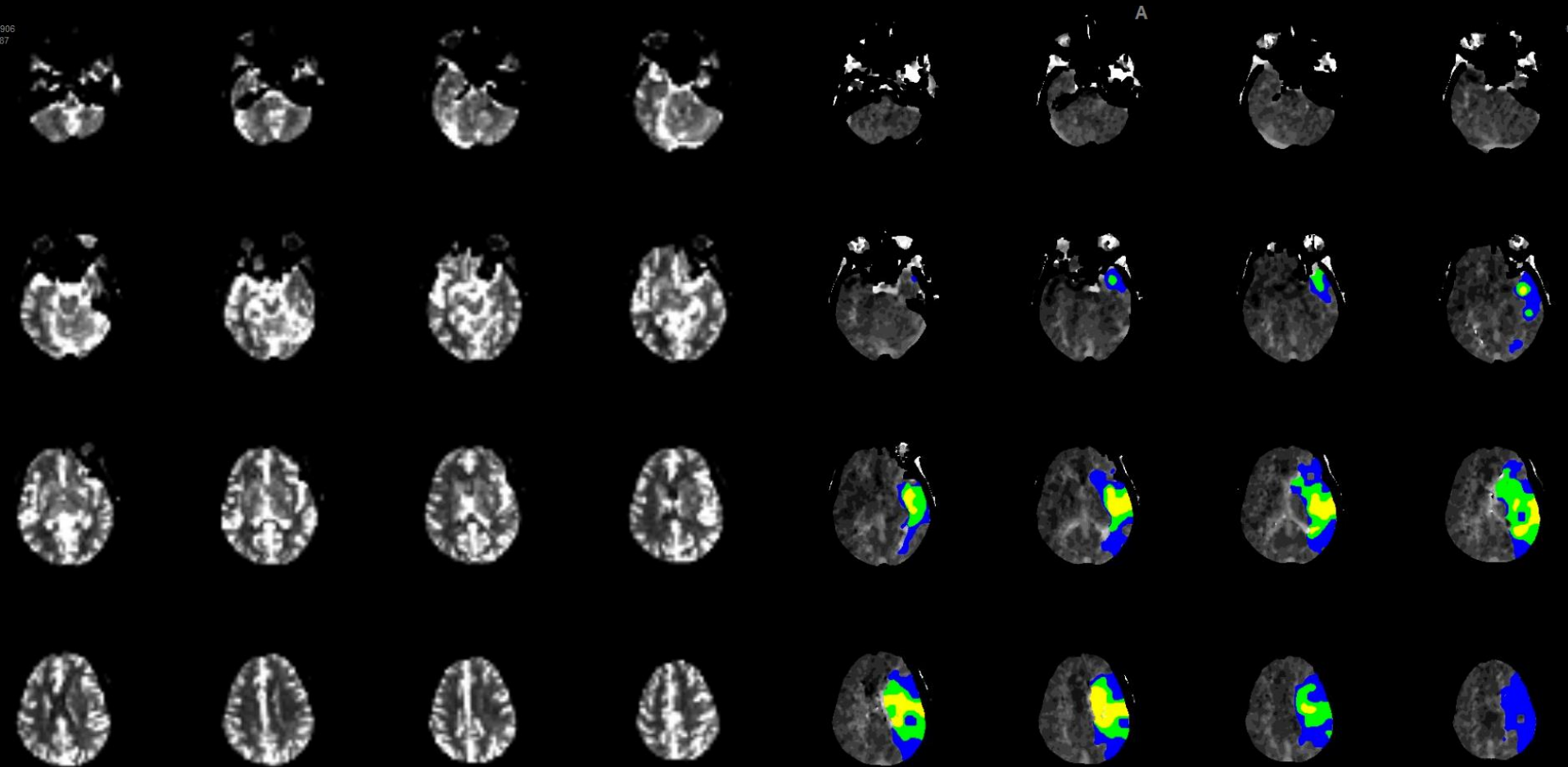


CBF (<30%) volume: <1.0 ml or none

Perfusion (Tmax>6.0s) volume: 67.5 ml

Last Image Insert: 10/26/2016 10:10

53yo HTN. ASPECTS 7. NIHSS 20. No tPA (no clear onset).

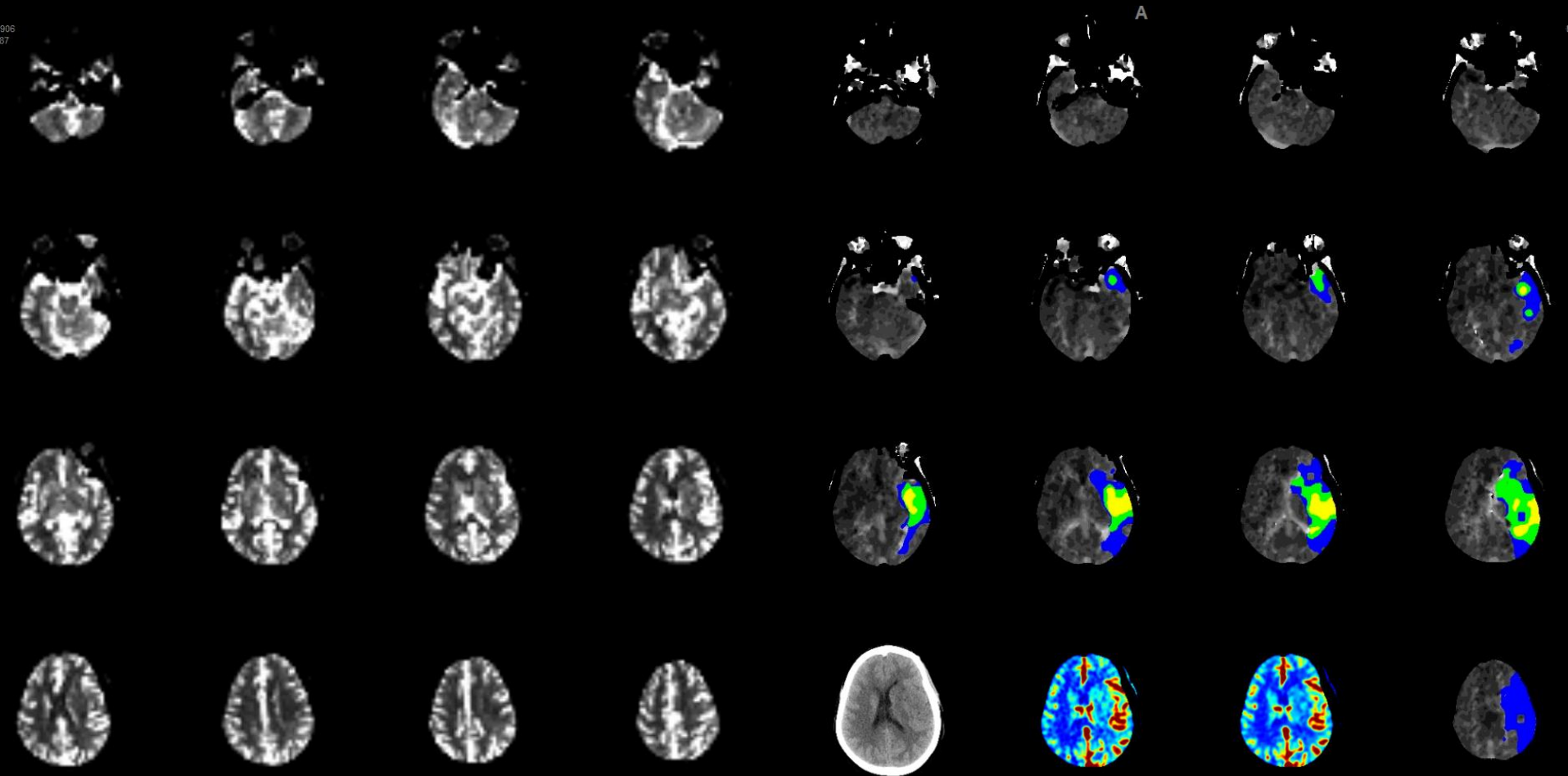


CBF (<30%) volume: <1.0 ml or none

Perfusion (Tmax>6.0s) volume: 67.5 ml

Last Image Insert: 10/26/2016 11

53yo HTN. ASPECTS 7. NIHSS 20. No tPA (no clear onset).

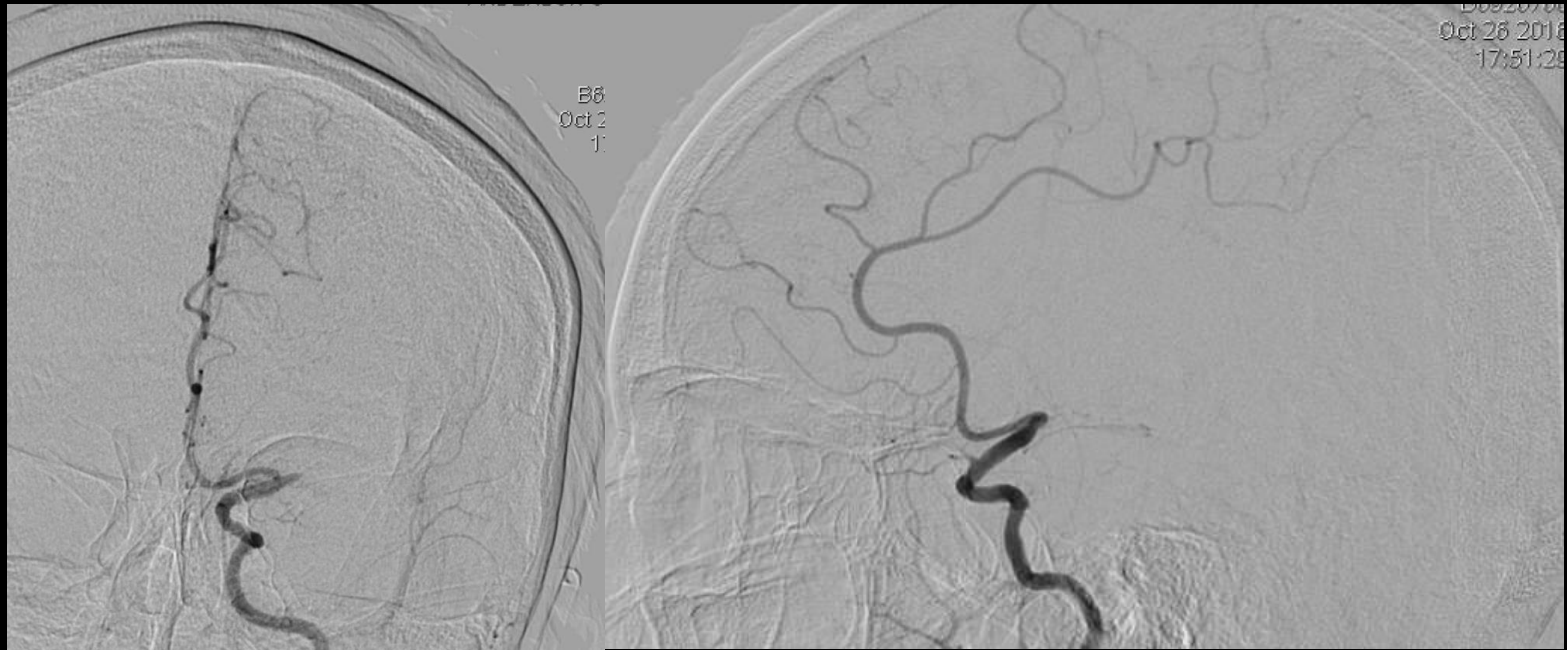

CBF (<30%) volume: <1.0 ml or none

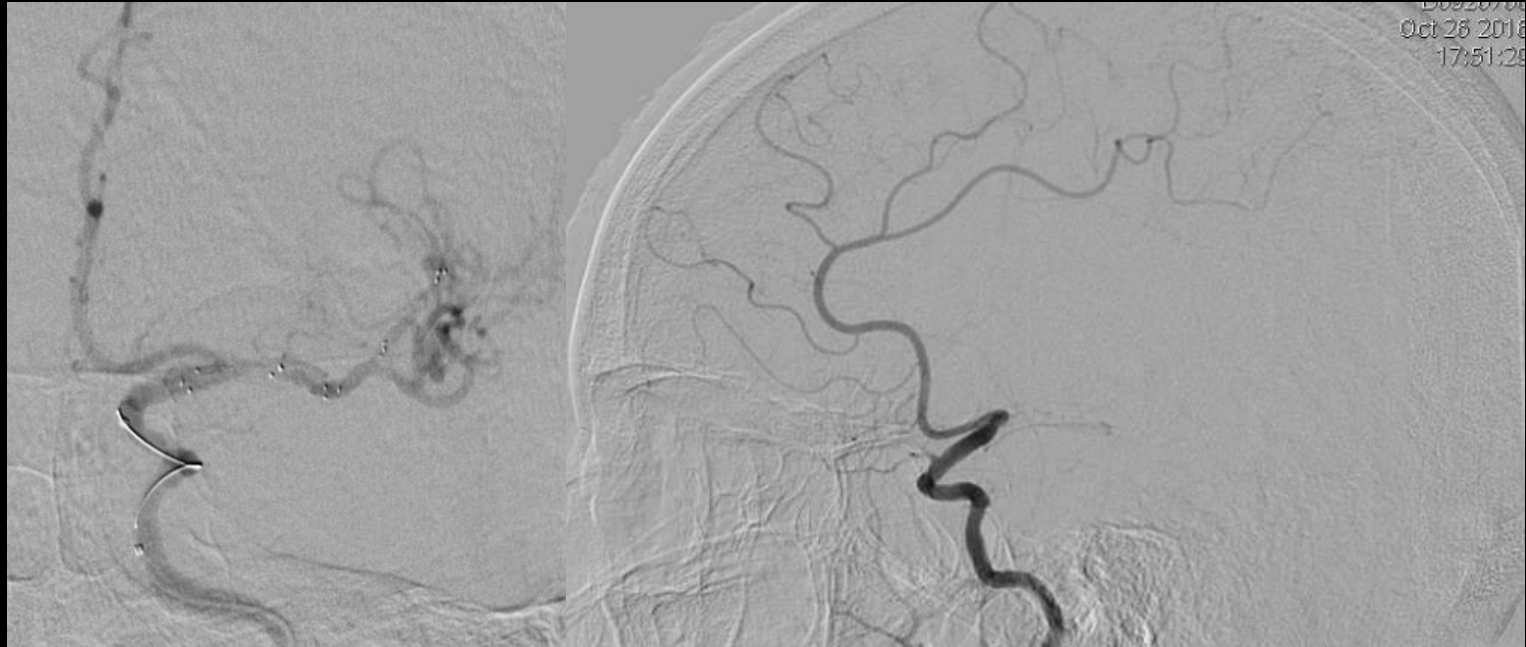Perfusion (Tmax>6.0s) volume: 67.5 ml

Last Image Insert: 10/26/2016 16:10

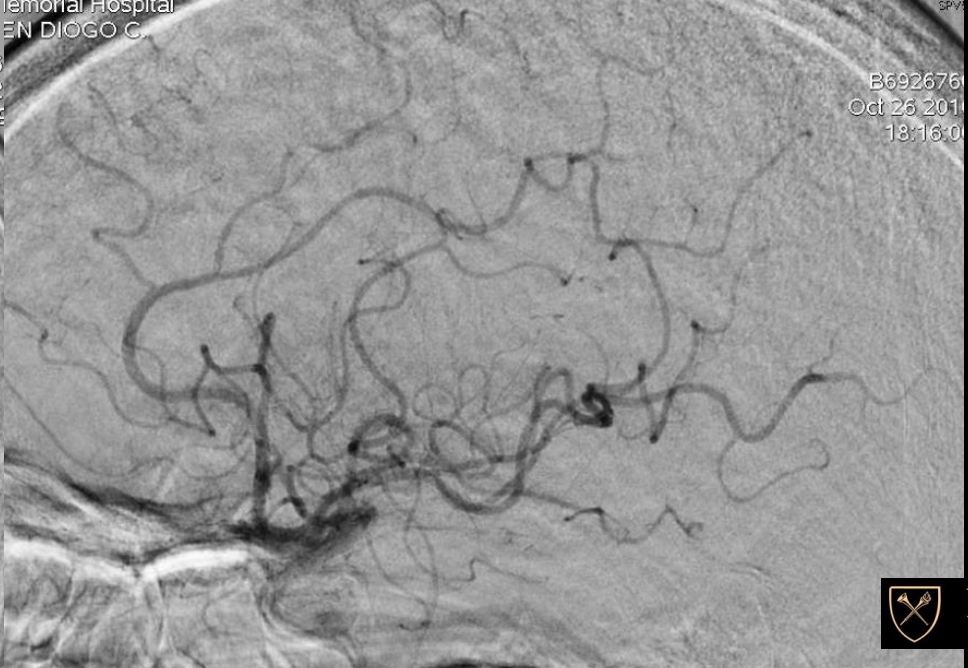
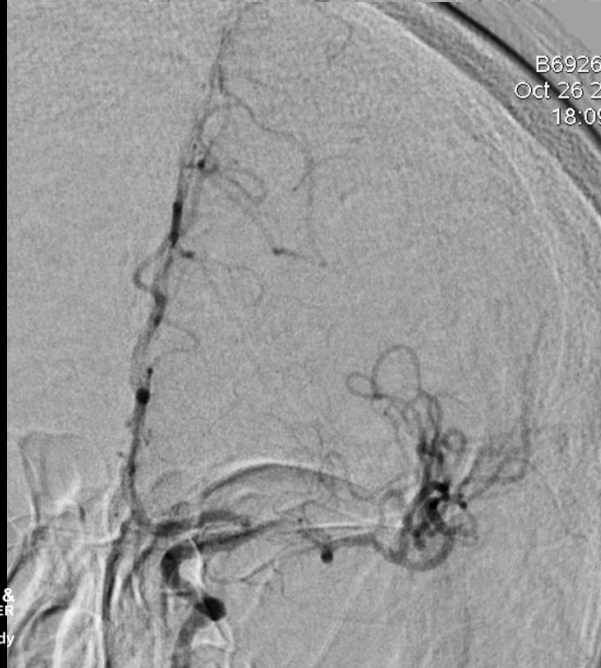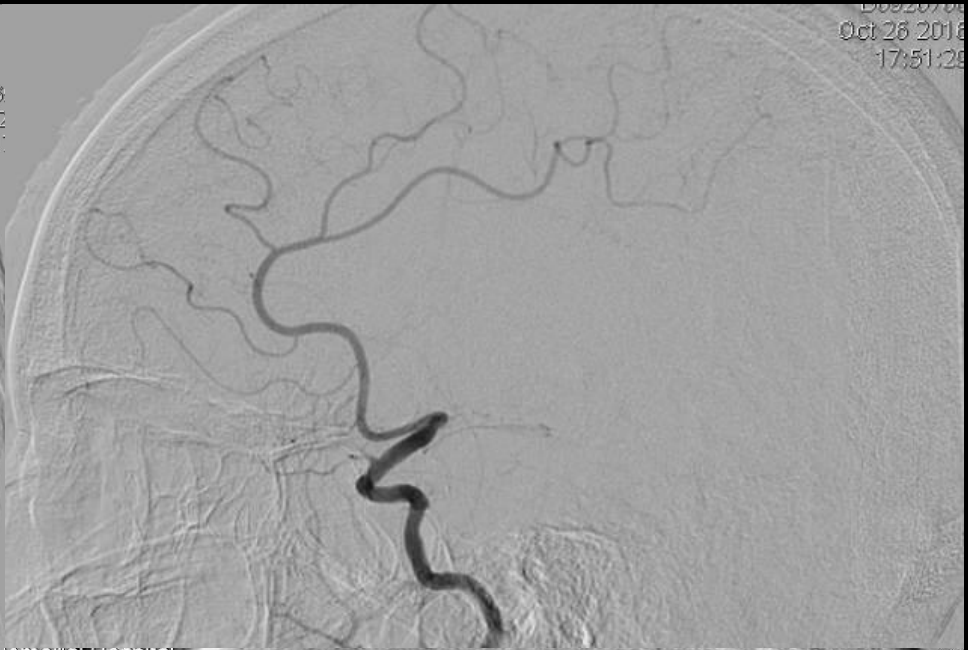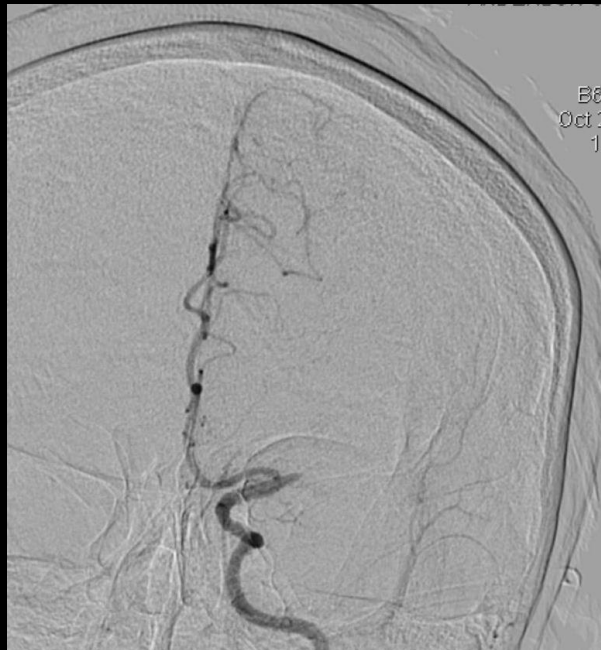TICI 0



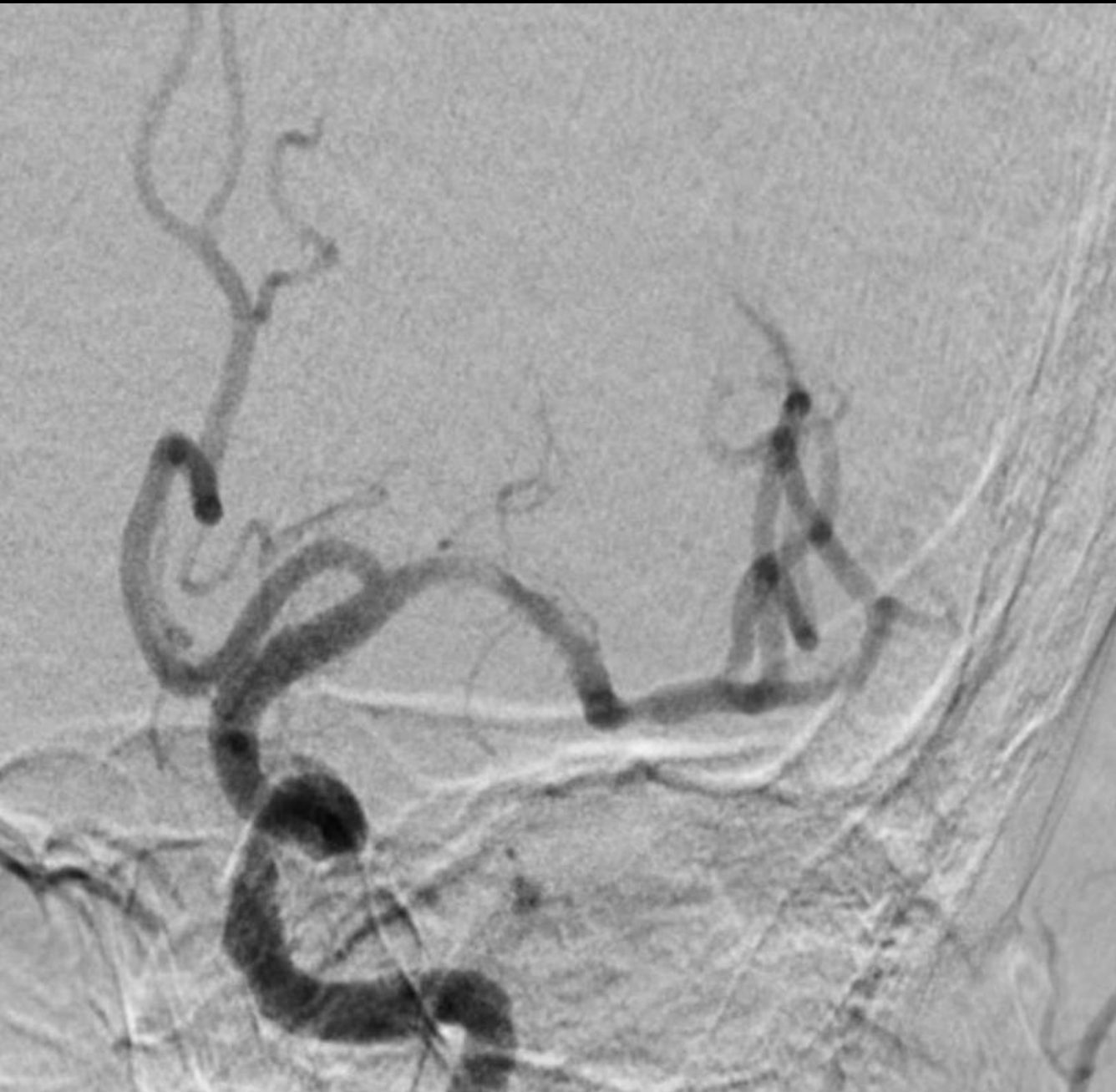Solitaire Platinum 4x40



TICI 3.

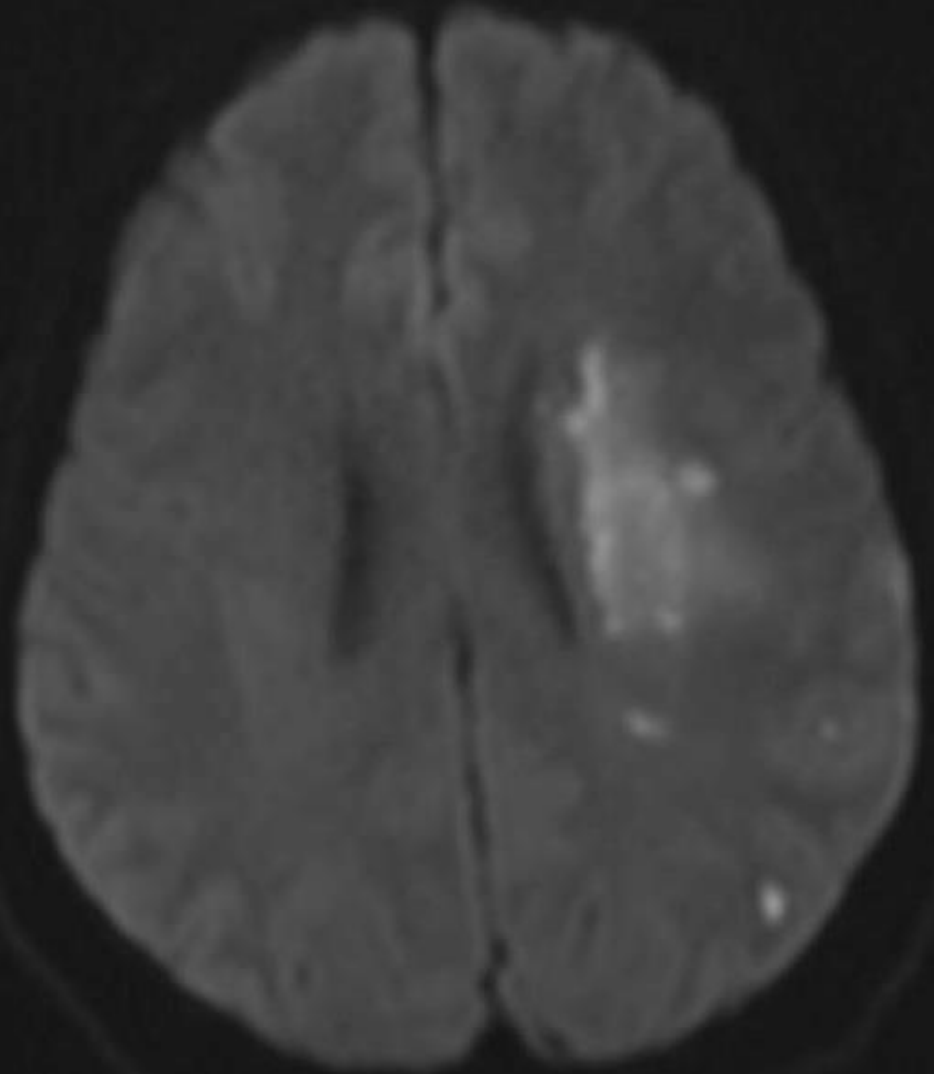
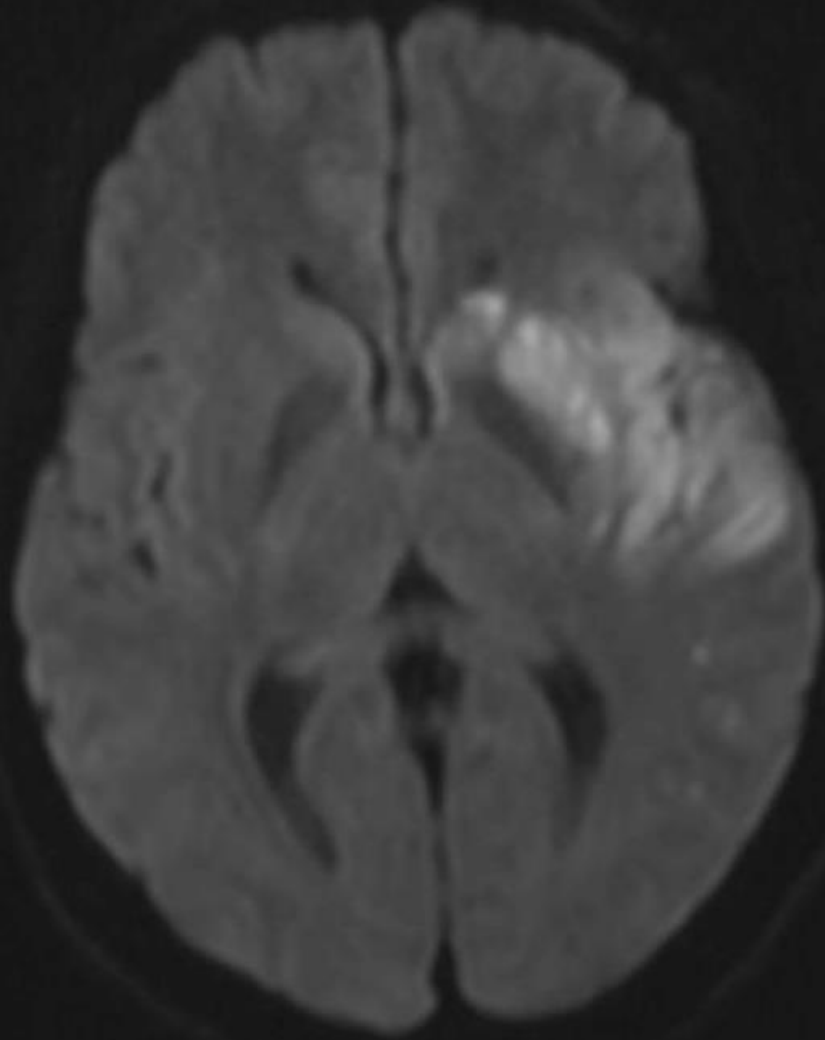


In-situ Thrombosis



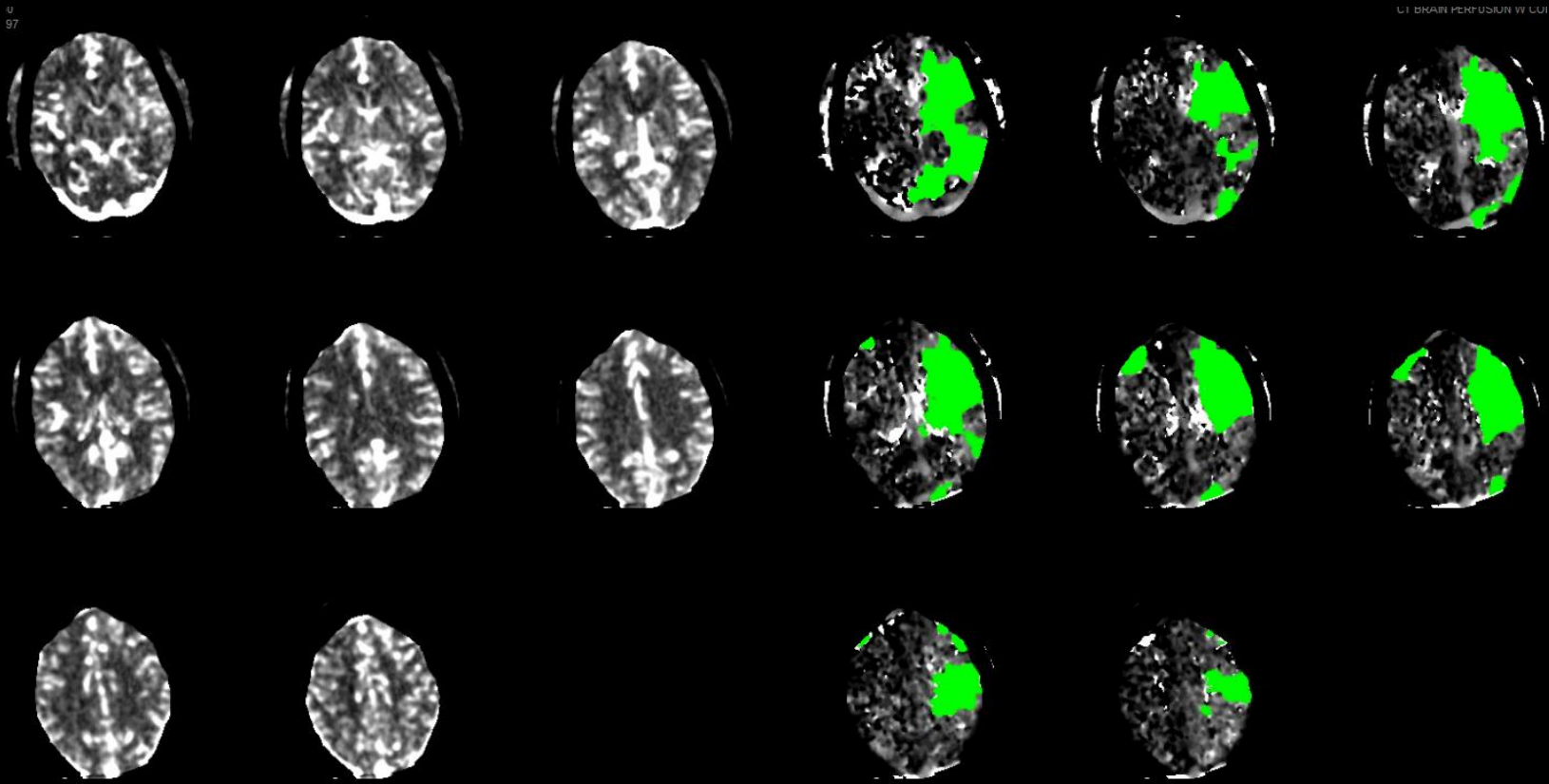
Heparin 3,000 units
ASA 300mg PR
Brillinta 120mg
Angiograms q10m x 3

NIHSS 1 at DC

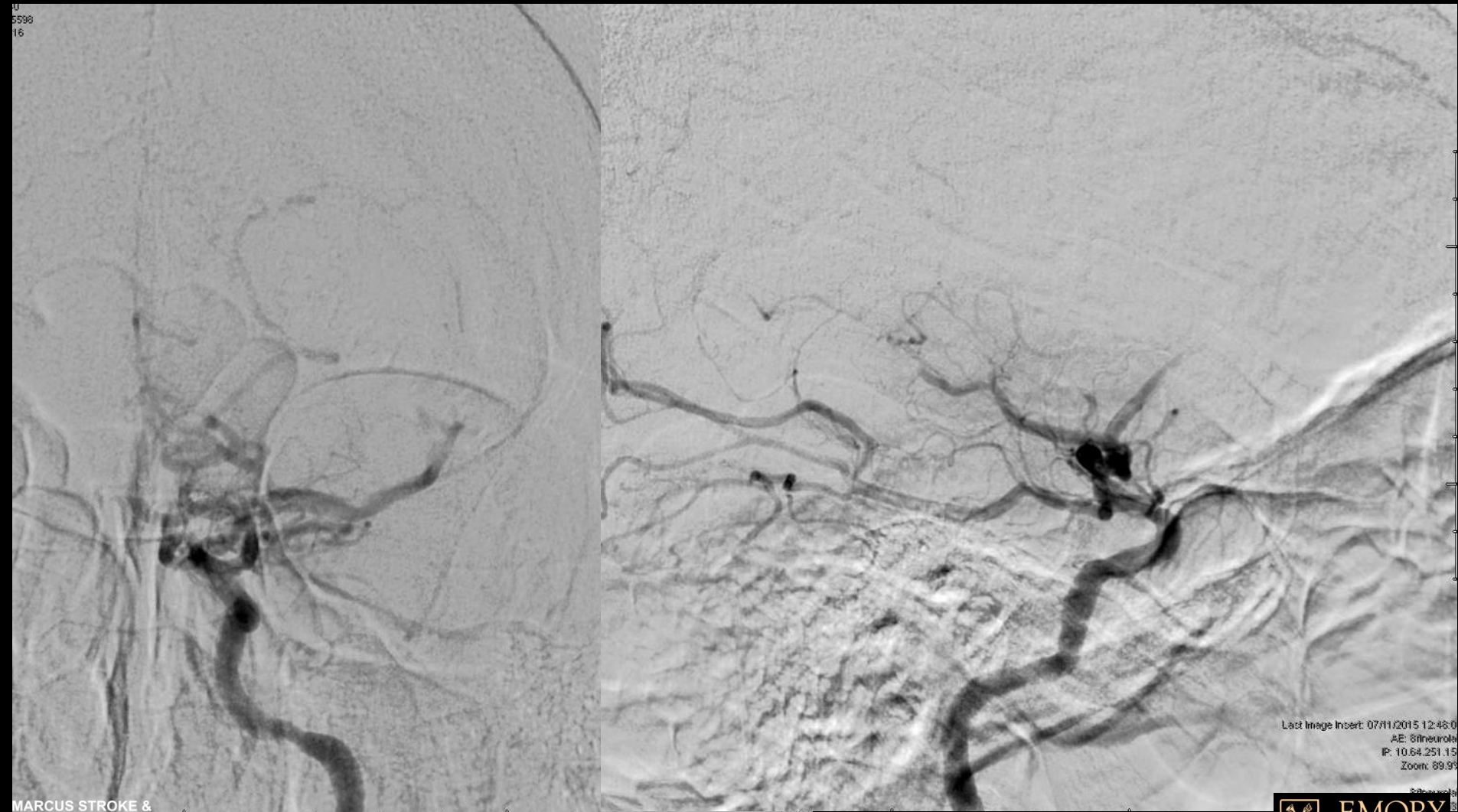


CASE #3

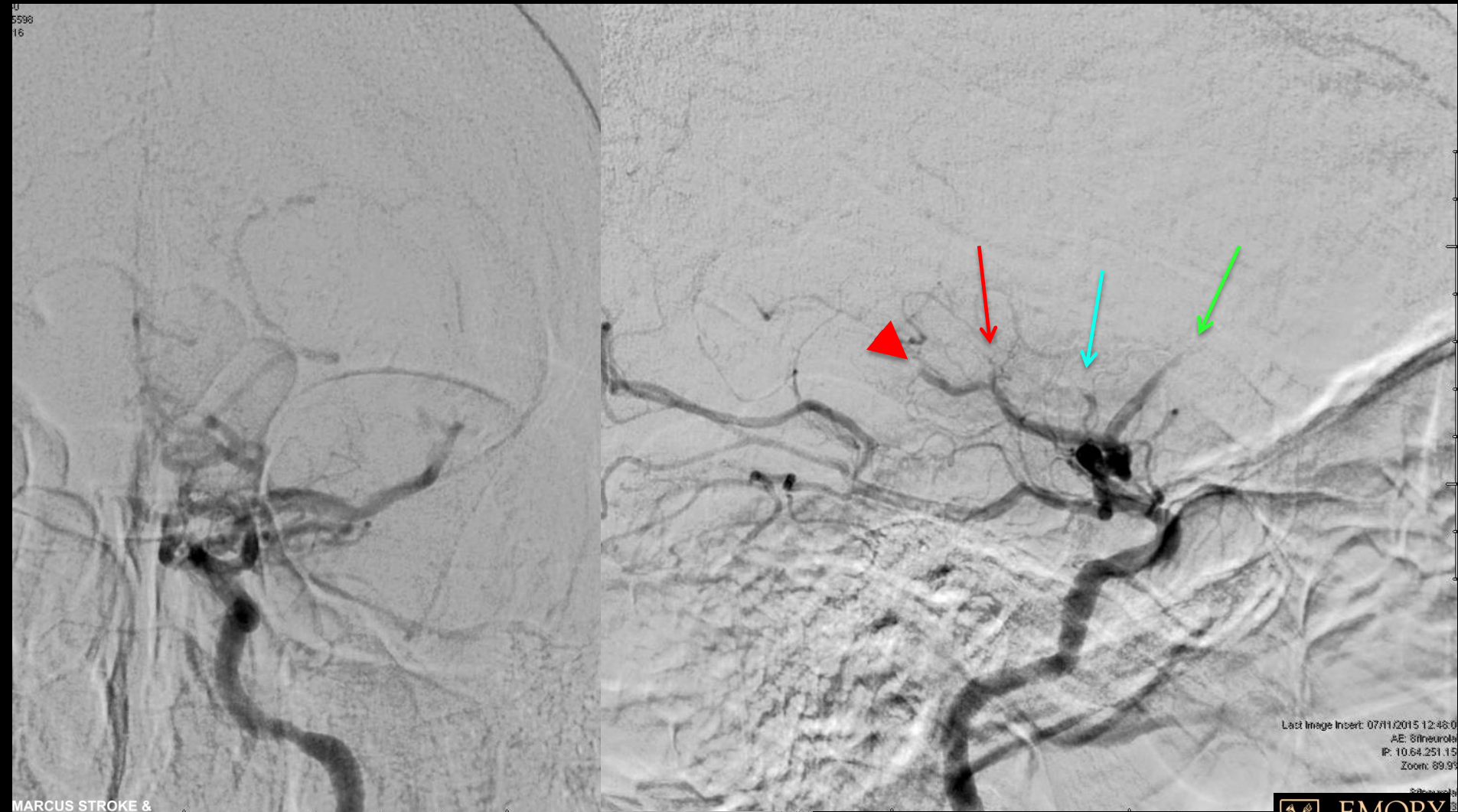52yo cocaine user. NIHSS 18.
10h after stroke onset. OSH CTA ICA-T.



52yo. NIHSS 18.



52yo. NIHSS 18.



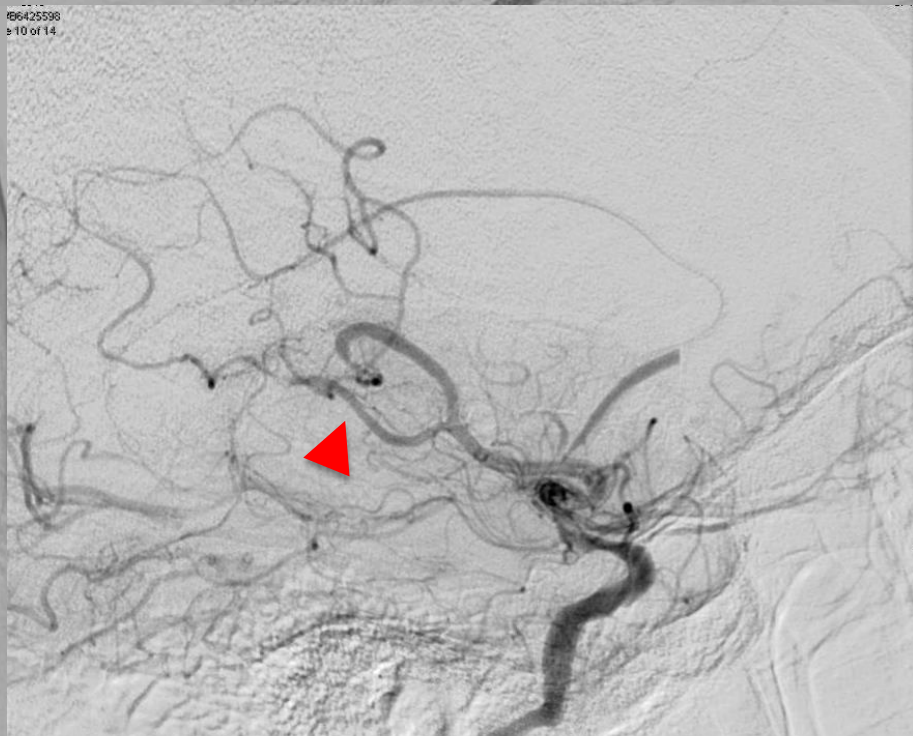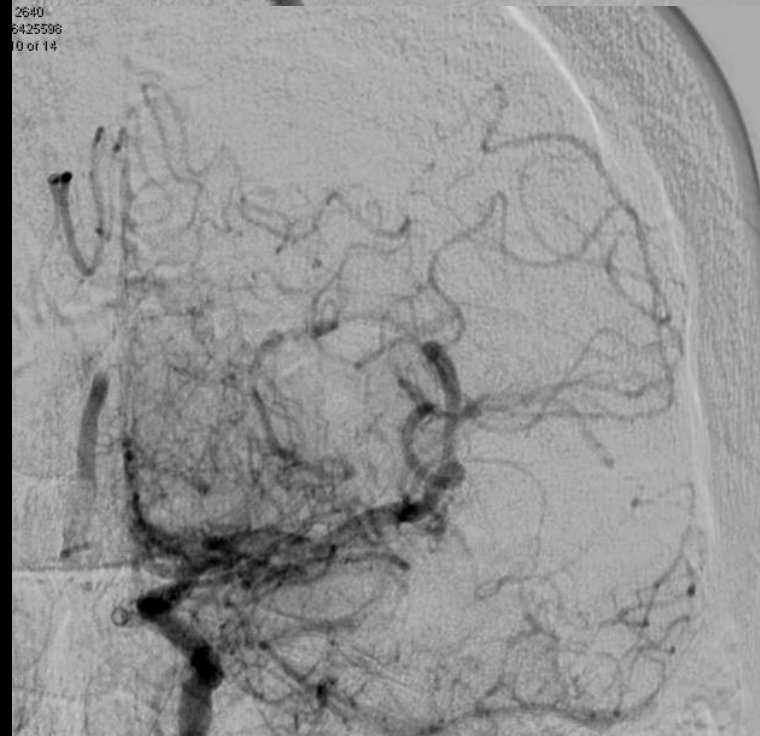0040))

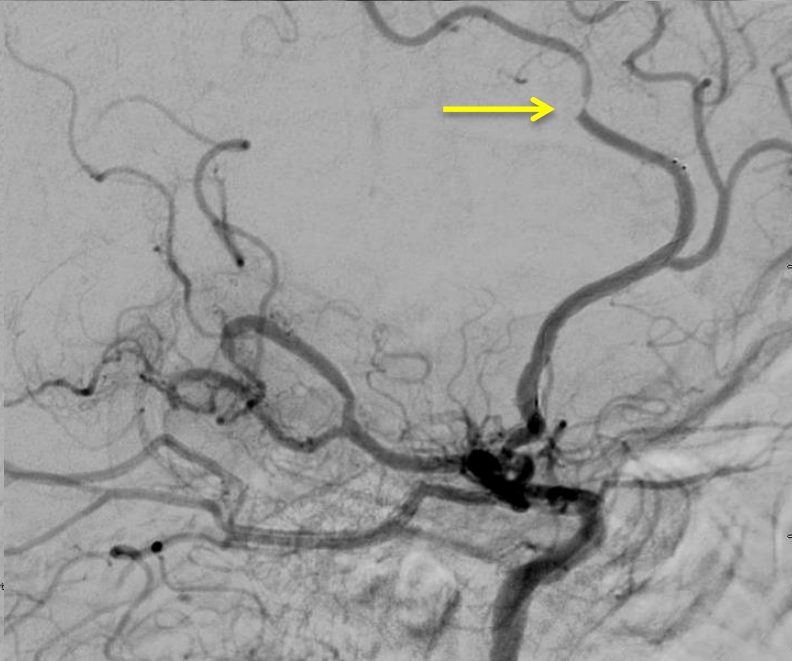
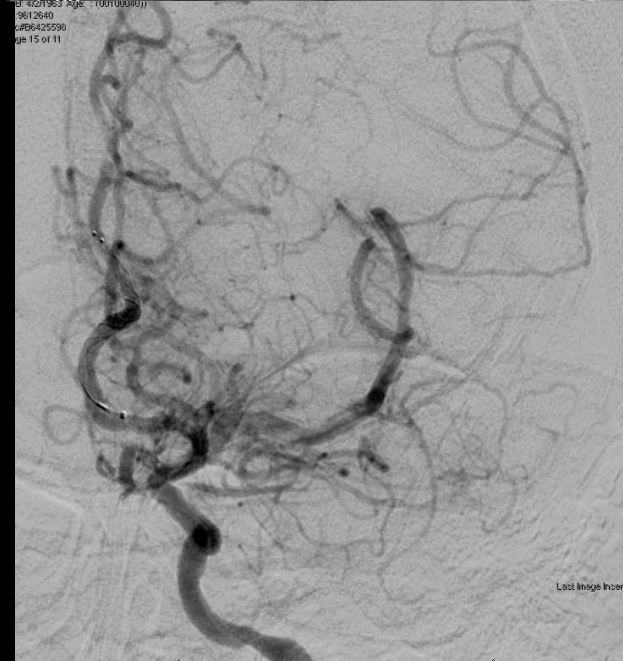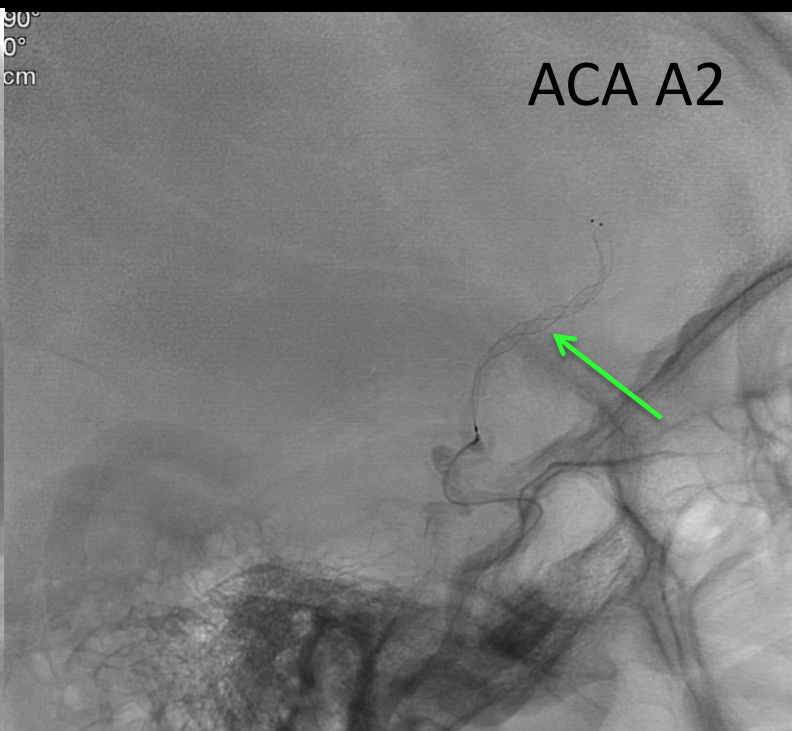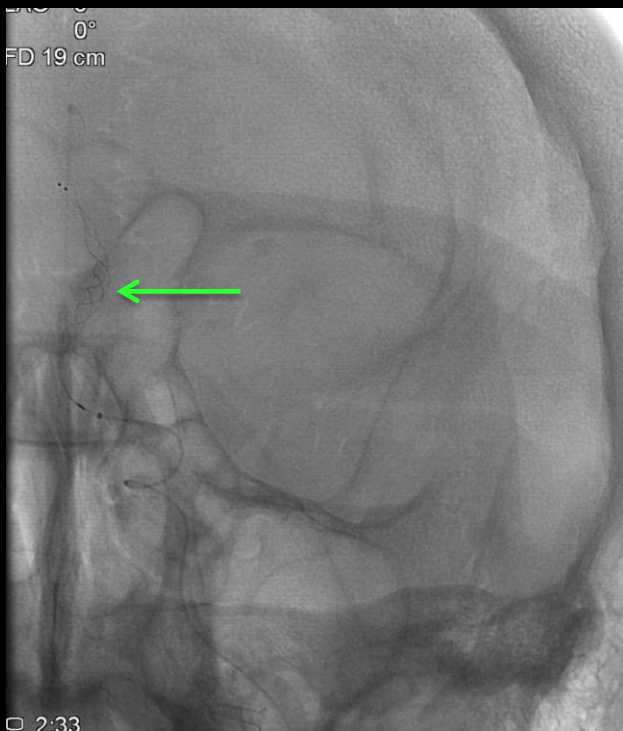127303 Page 1 (00100000))
12640
6425598
9 of 11

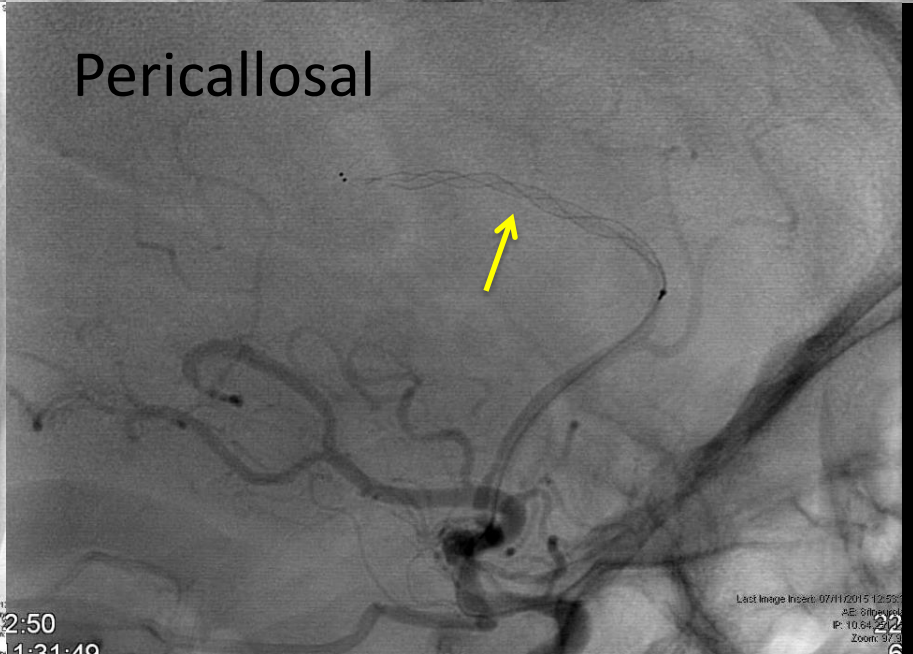
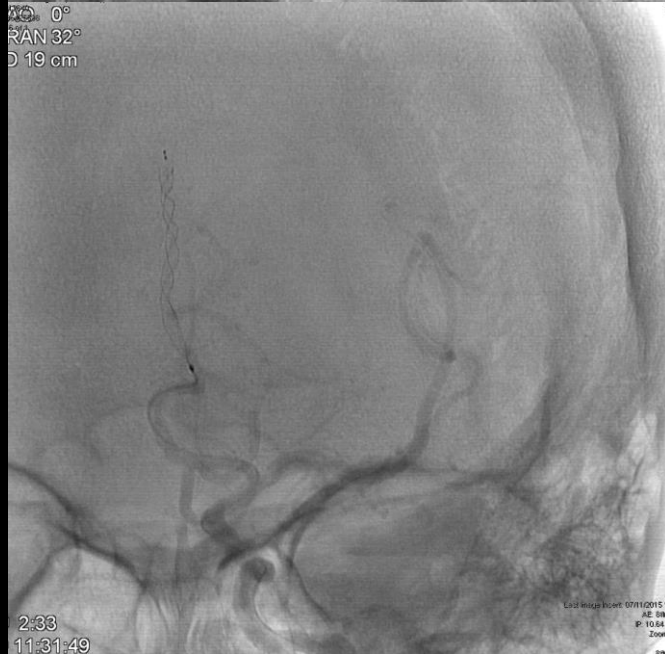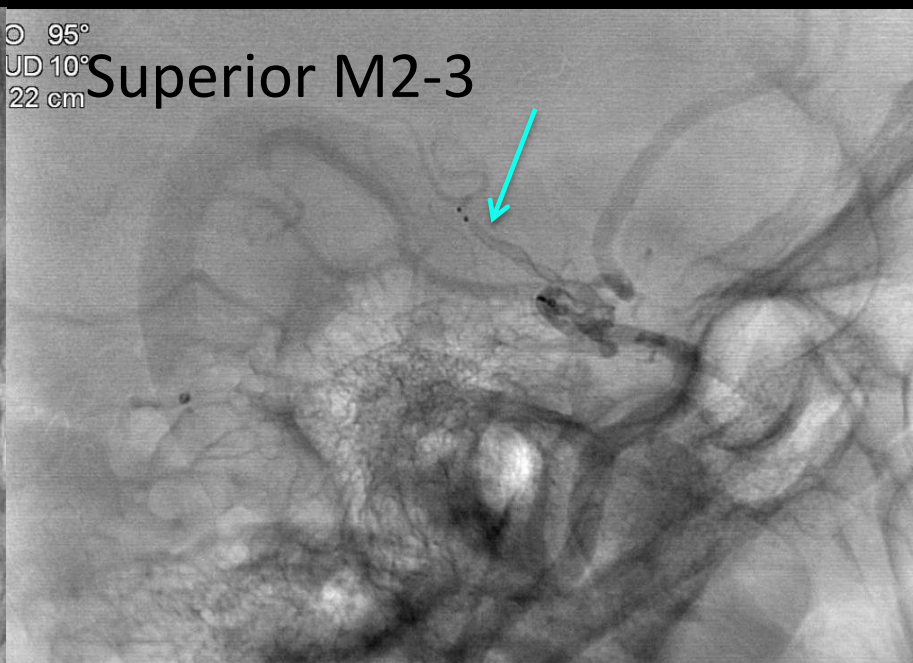
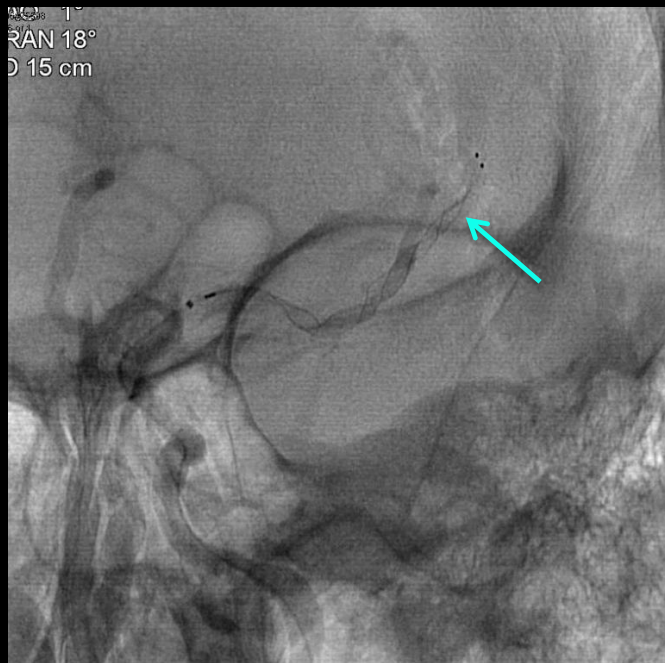
MCA M3

2640
6425598
10 of 14

127303
6425598
9 of 14





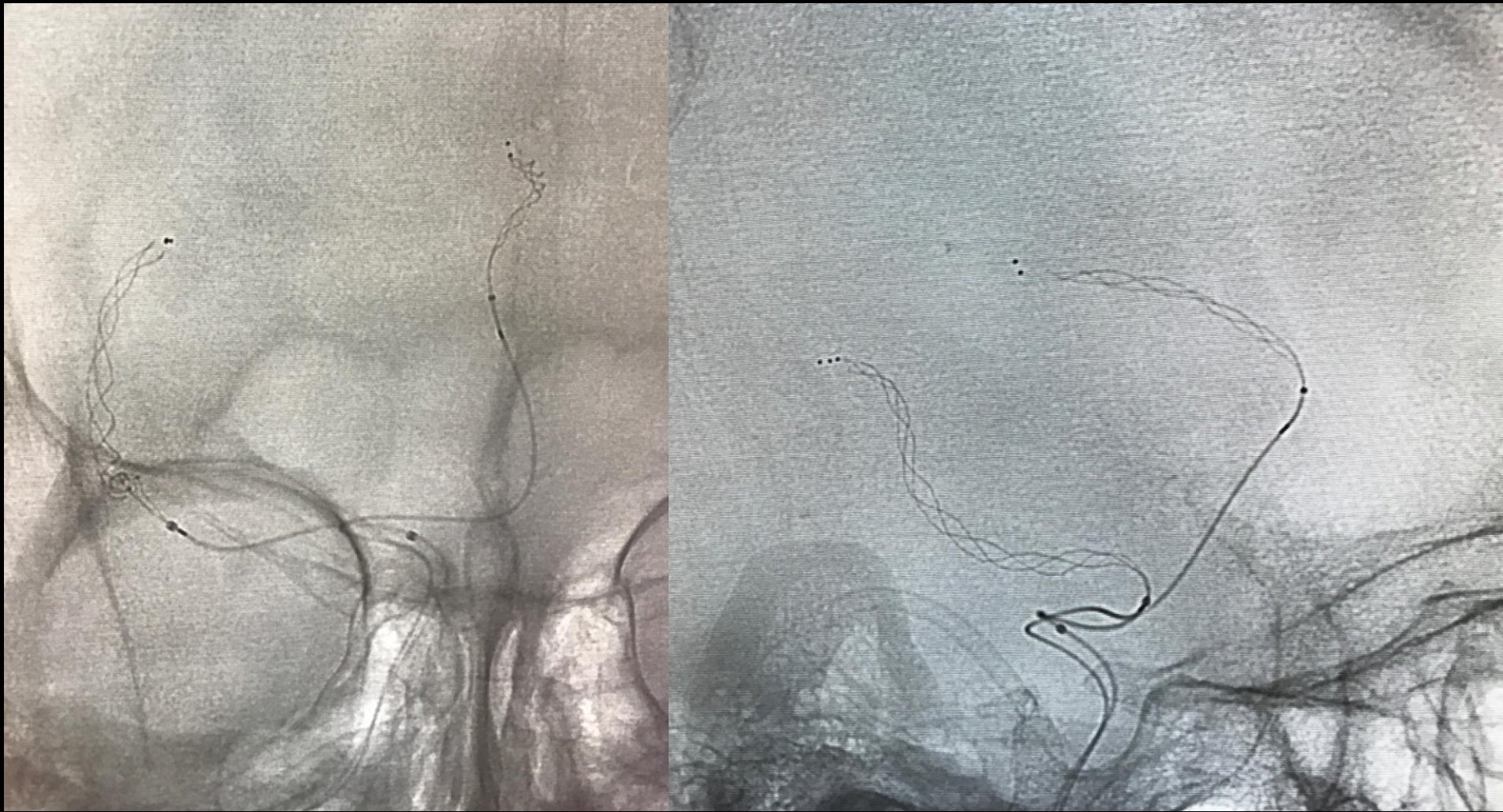


2:33
11:31:49

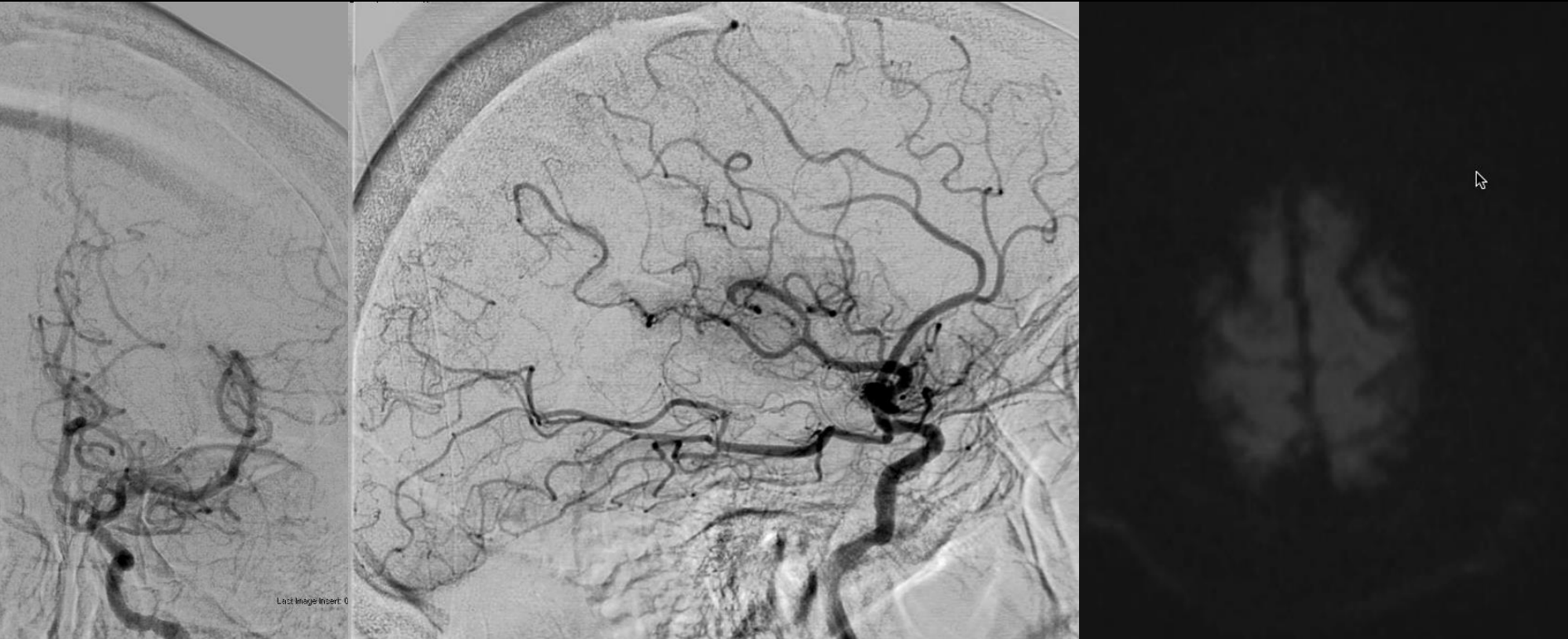Last Image Inset: 07/11/2015 12:50
AE: 810444
P: 10.64
Zoom: 3.2
2:50
1:31:49

Last Image Inset: 07/11/2015 12:50
AE: 810444
P: 10.64
Zoom: 3.2

Illustration

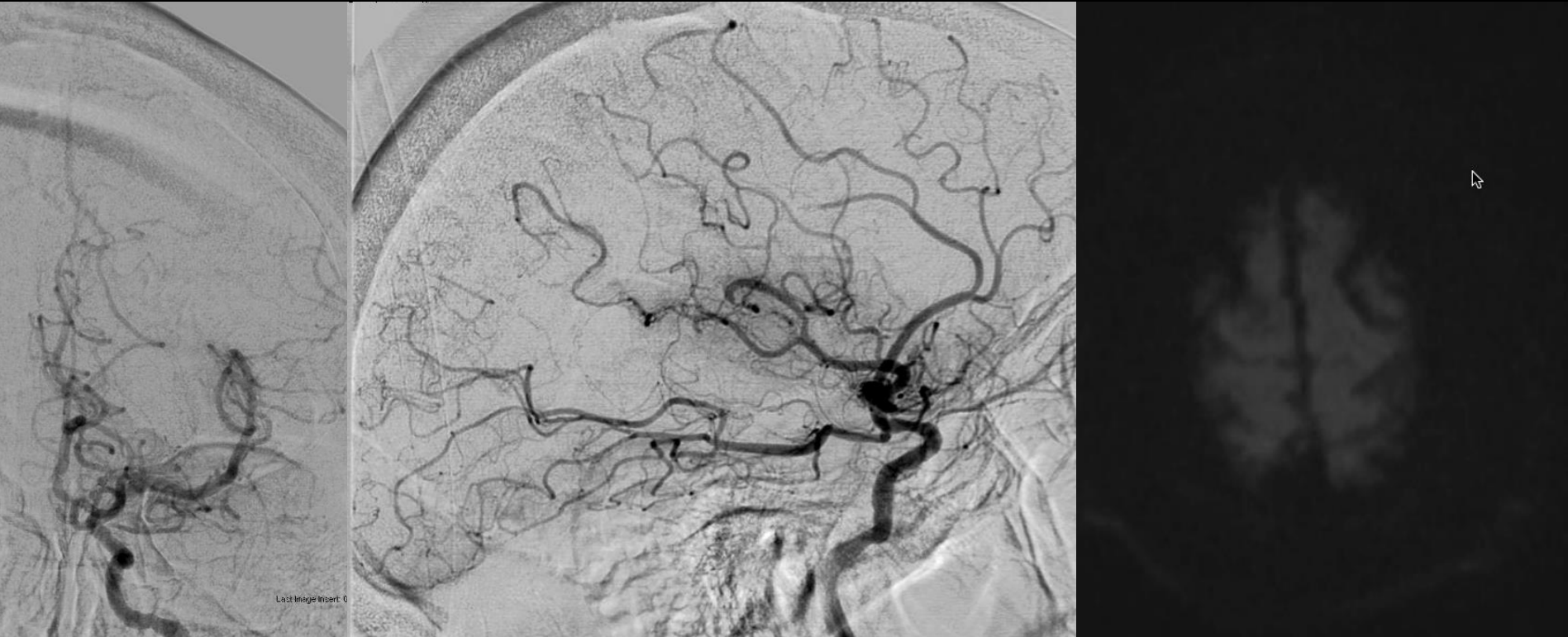

NIHSS 3 at Discharge

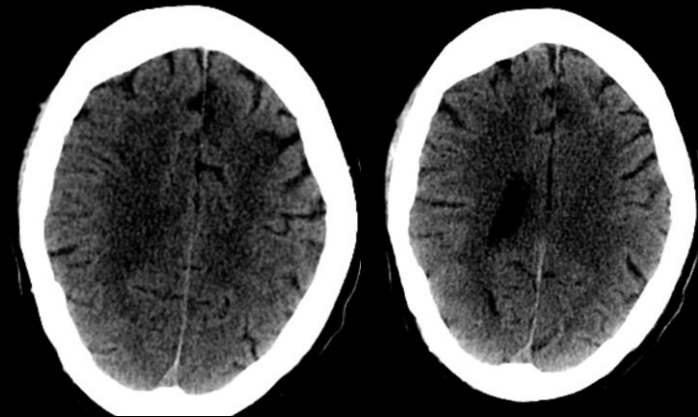


Apical left ventricle thrombus on 2DEcho

NIHSS 3 at Discharge

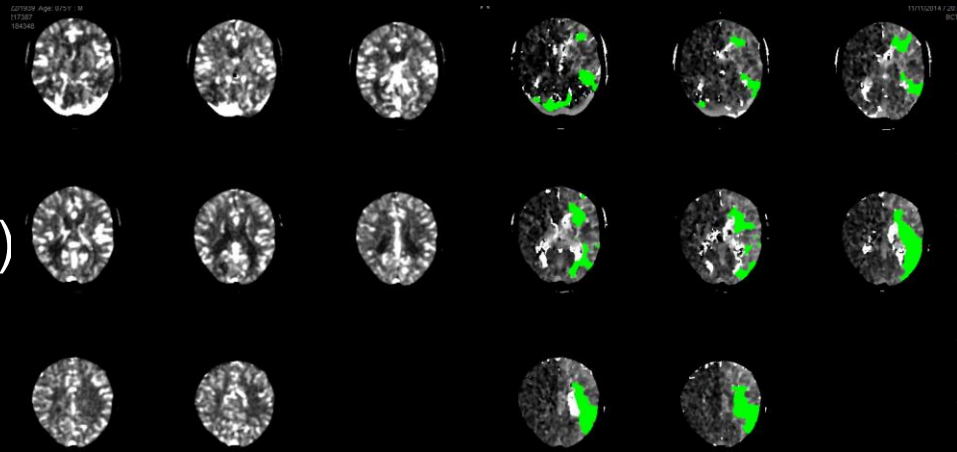


Apical left ventricle thrombus on 2DEcho



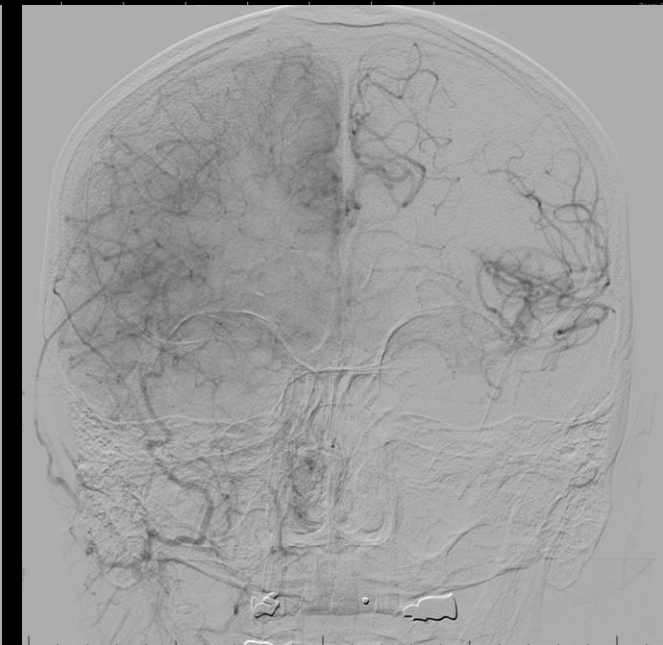
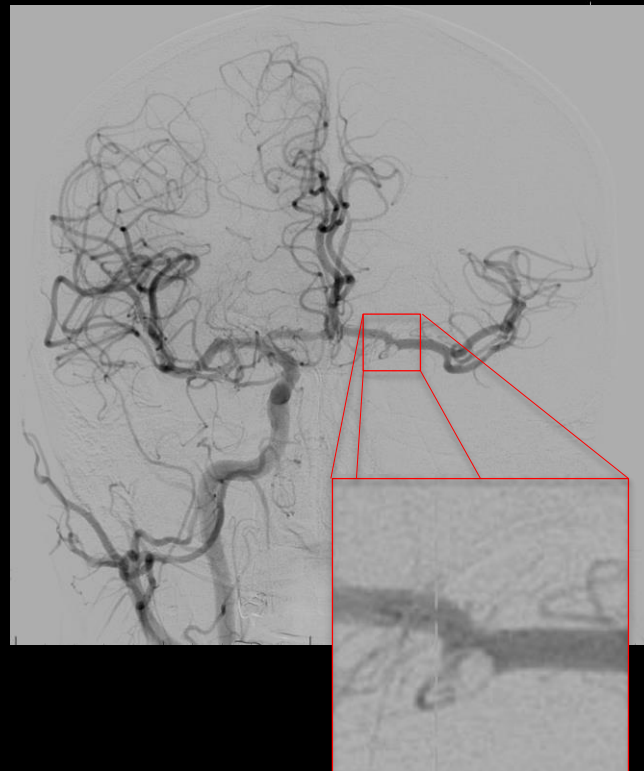
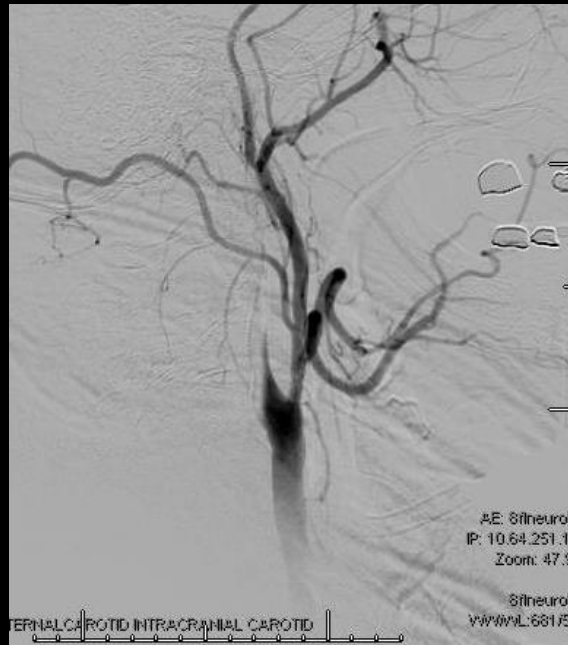CASE #4

75-year-old M
Acute aphasia & hemiplegia.
Transferred to Grady.
After CTP, NIHSS =1 (mild aphasia)
SBP 180mmHg
Angiogram at 11pm

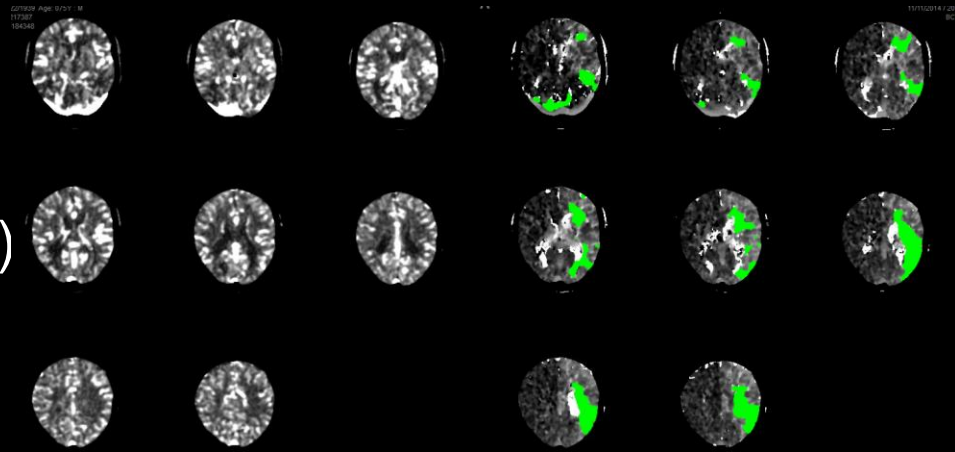


CBF (<30%) volume: <1.0 ml or none Perfusion (Tmax>6.0s) volume: 63.5 ml
Mismatch volume: 63.5 ml
Mismatch ratio: infinite

1.5 SWIFT FRAME PERFUSION

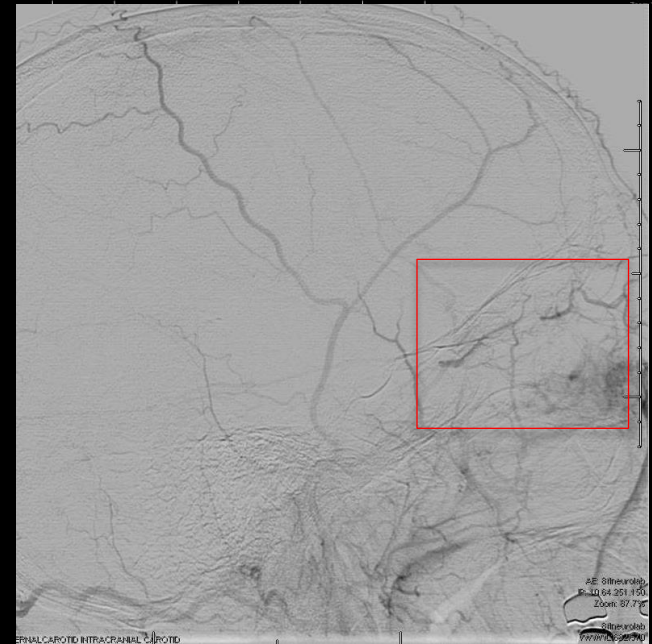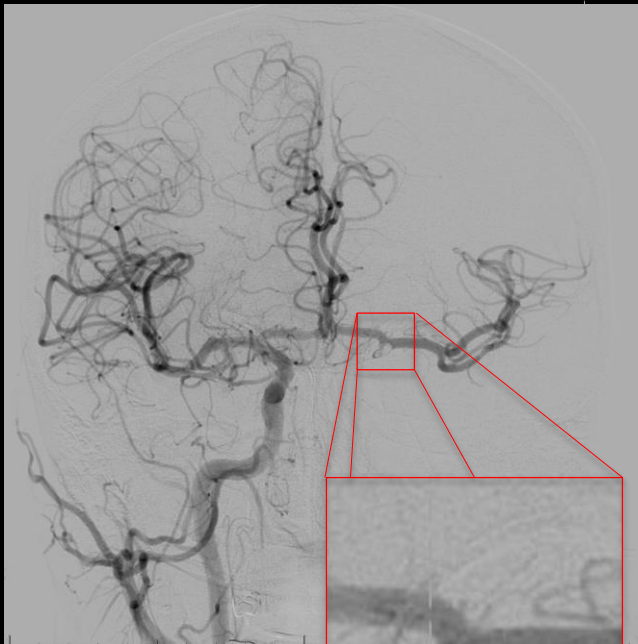

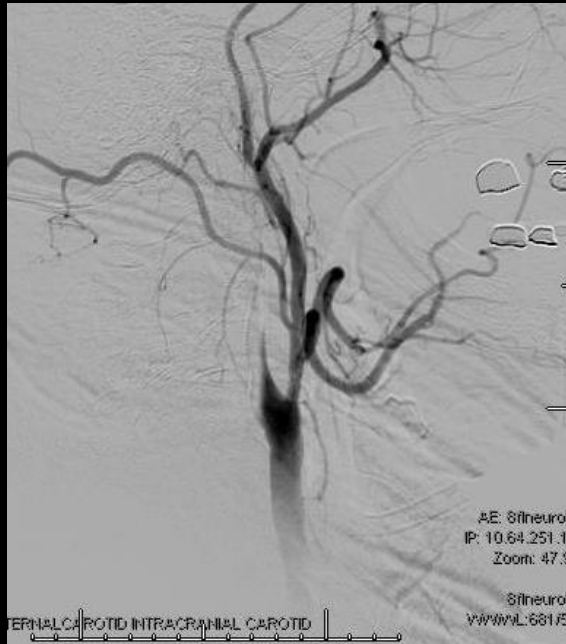
75-year-old M
 Acute aphasia & hemiplegia.
 Transferred to Grady.
 After CTP, NIHSS =1 (mild aphasia)
 SBP 180mmHg
 Angiogram at 11pm



CBF (<30%) volume: <1.0 ml or none Perfusion (Tmax>6.0s) volume: 63.5 ml
 Mismatch volume: 63.5 ml
 Mismatch ratio: infinite

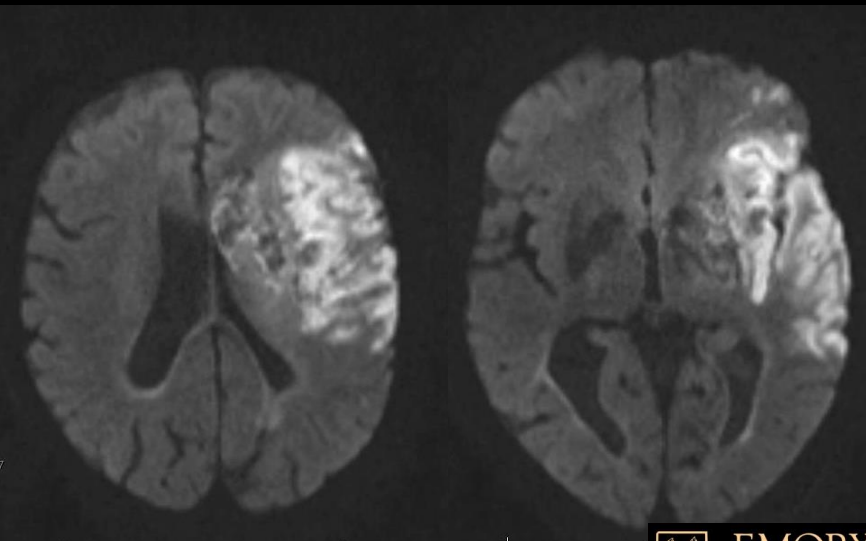
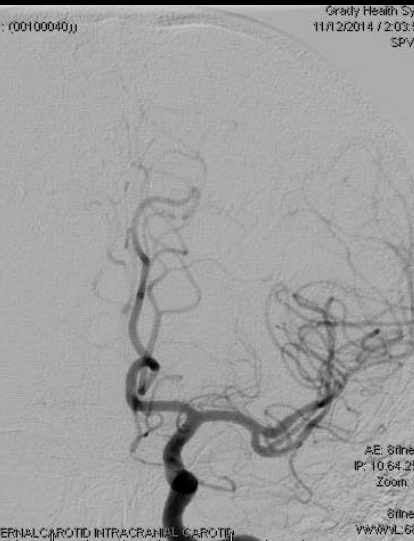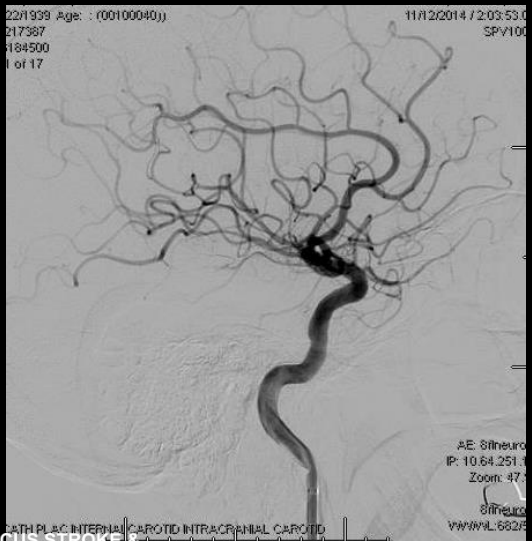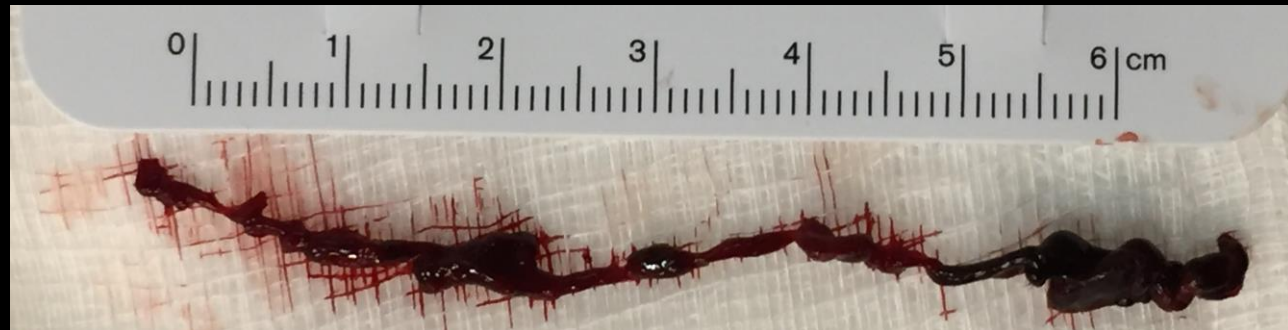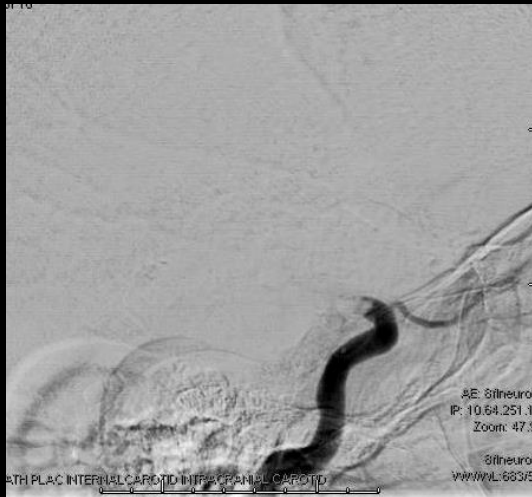
1.5 SWIFT PRIME PERFUSION



2:30am deterioration: flaccid/globally aphasic (SBP190).

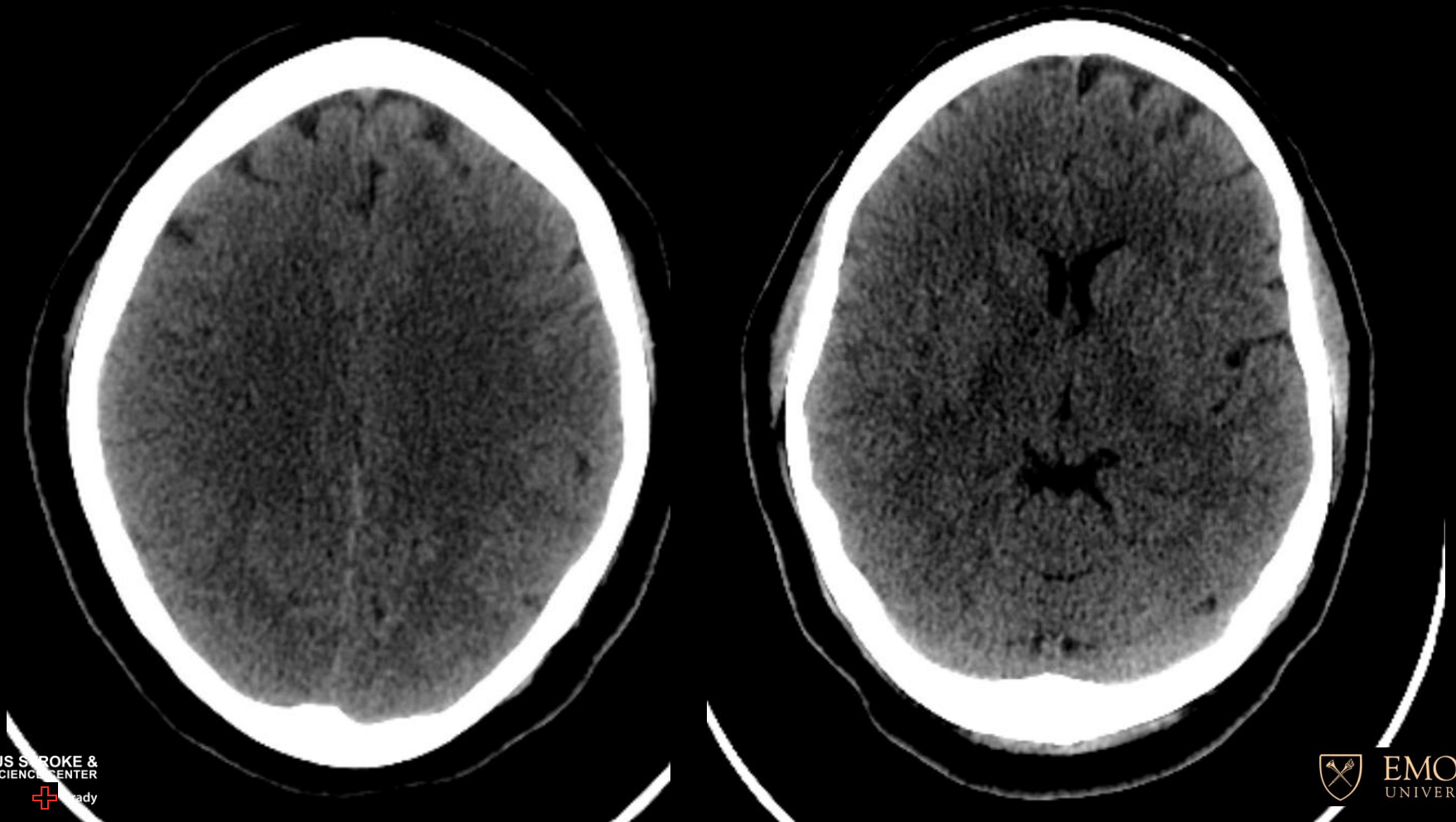
3:30am new angiogram.

3:50am full reperfusion (1 pass)



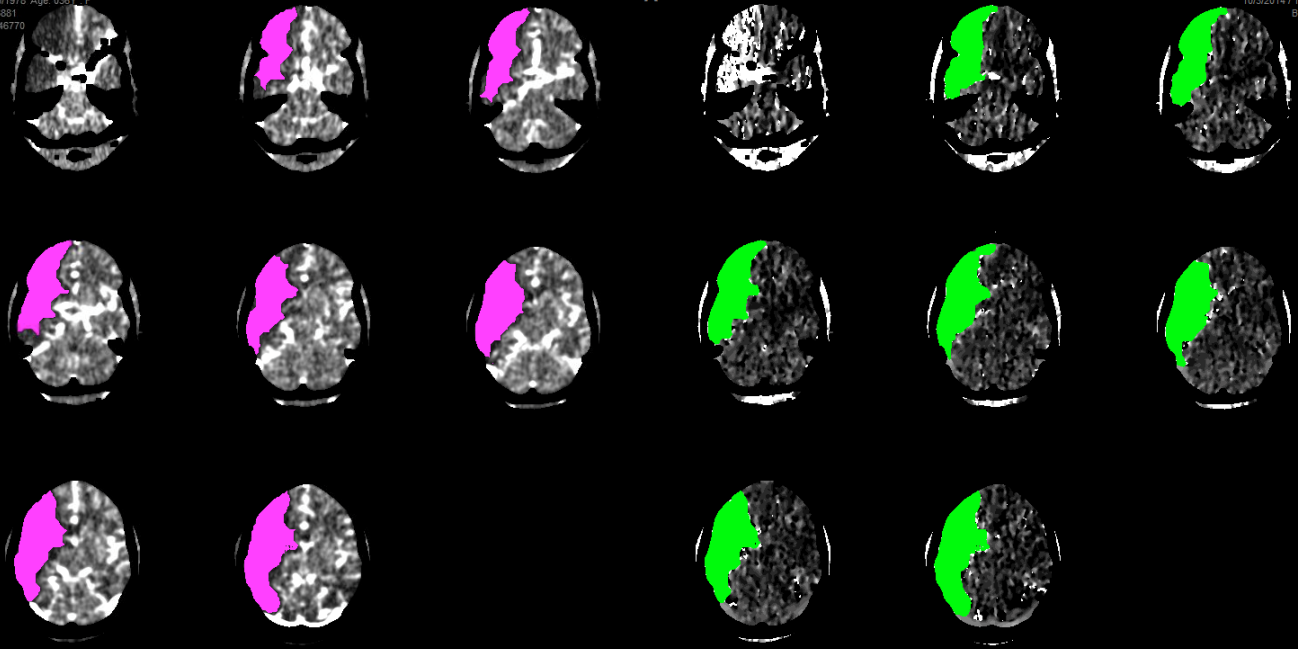
CASE #5

- 36yo
- Elective surgery
- Upon recovery from general anesthesia, 3 hours after induction, hemiplegia detected.



01/1978 Age: 036Y : F
4881
3148770

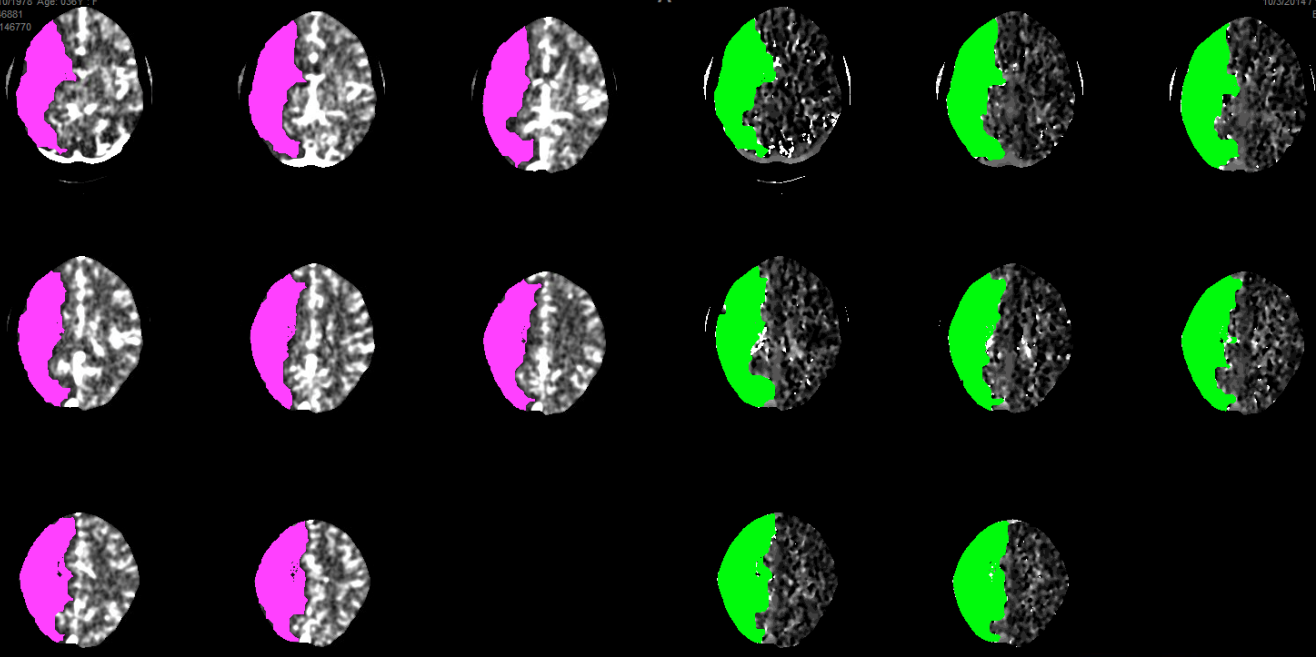
10/3/2014 / 15:04:4
BCT637



CBF (<30%) volume: 105.6 ml

10/1978 Age: 036Y : F
4881
3148770

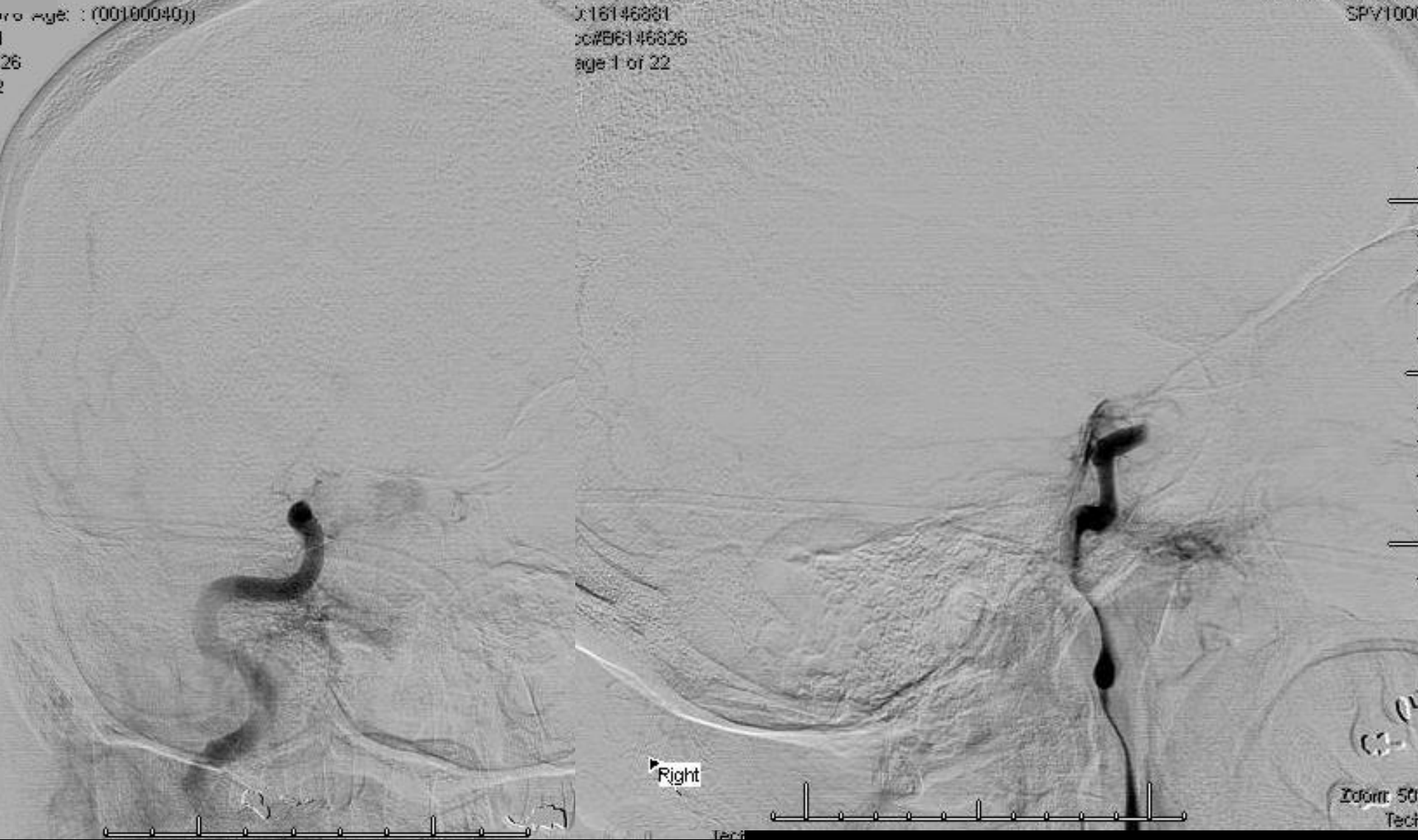
10/3/2014 / 15:04:4
BCT637



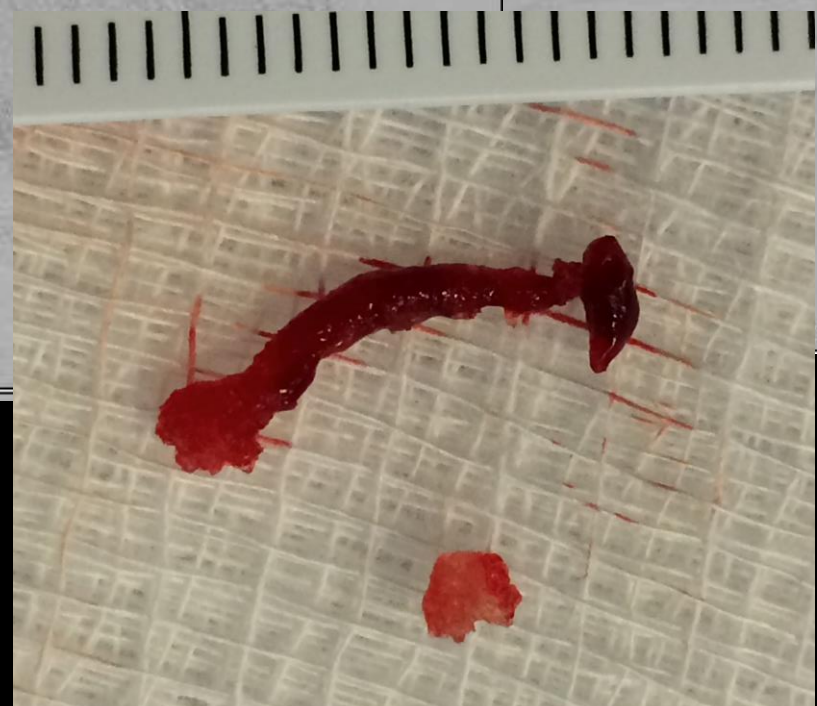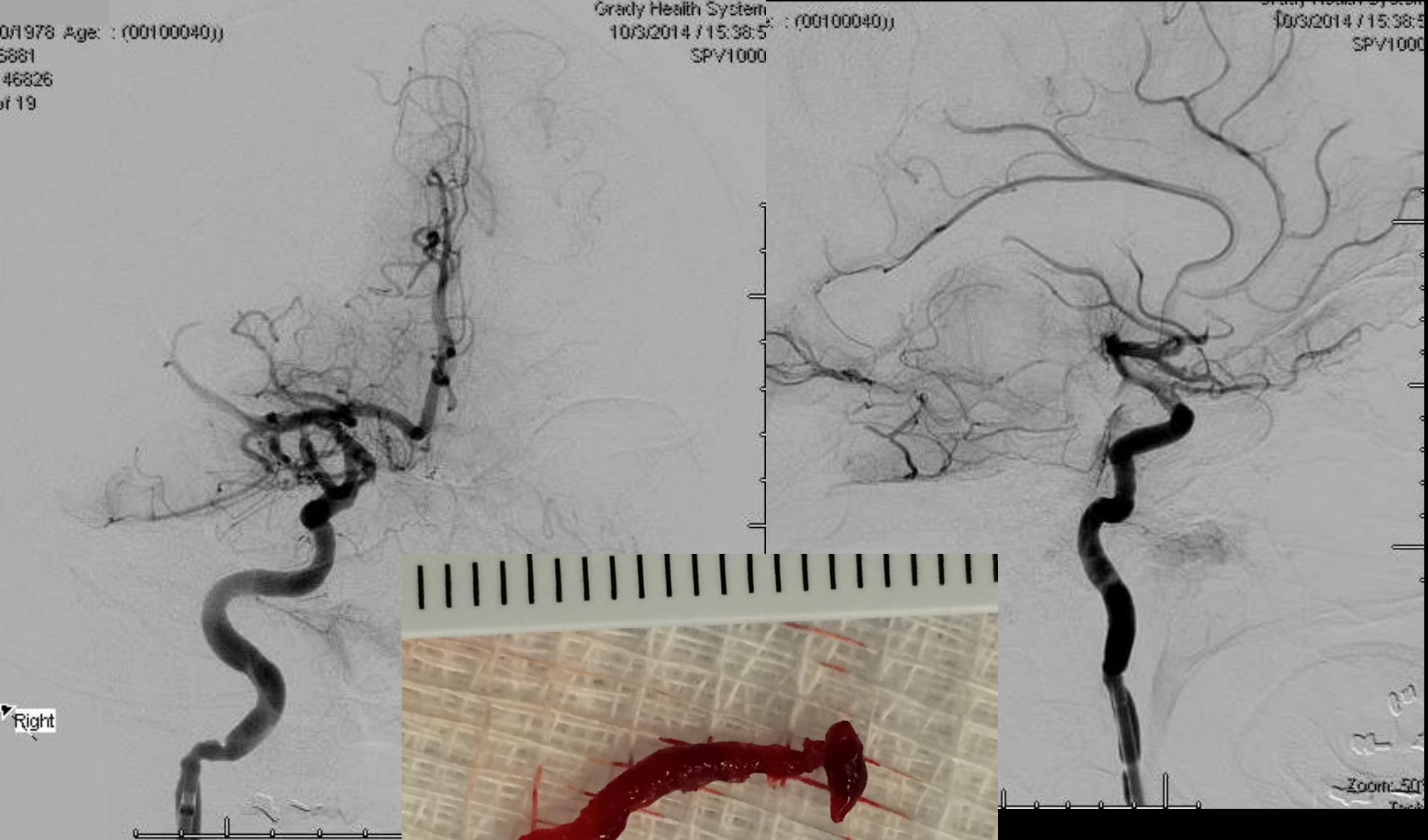
CBF (<30%) volume: 165.1 ml

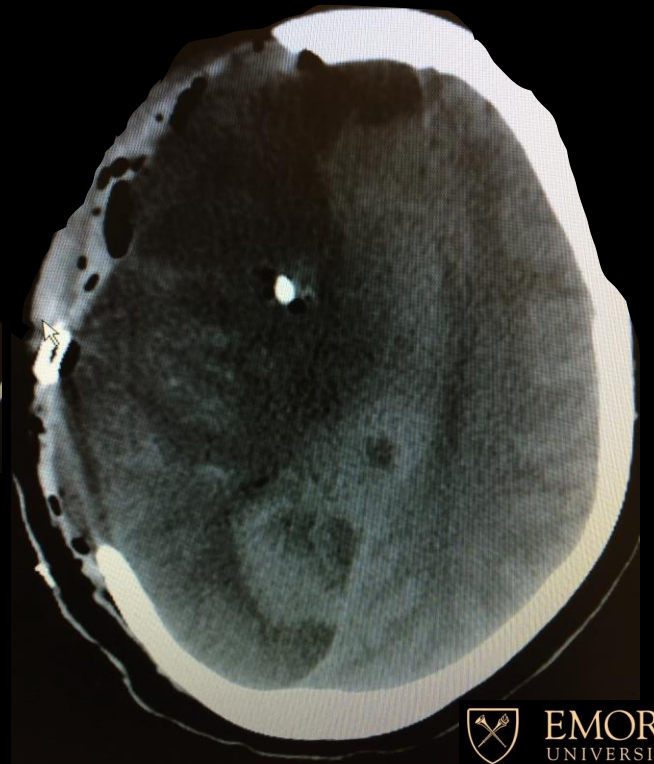
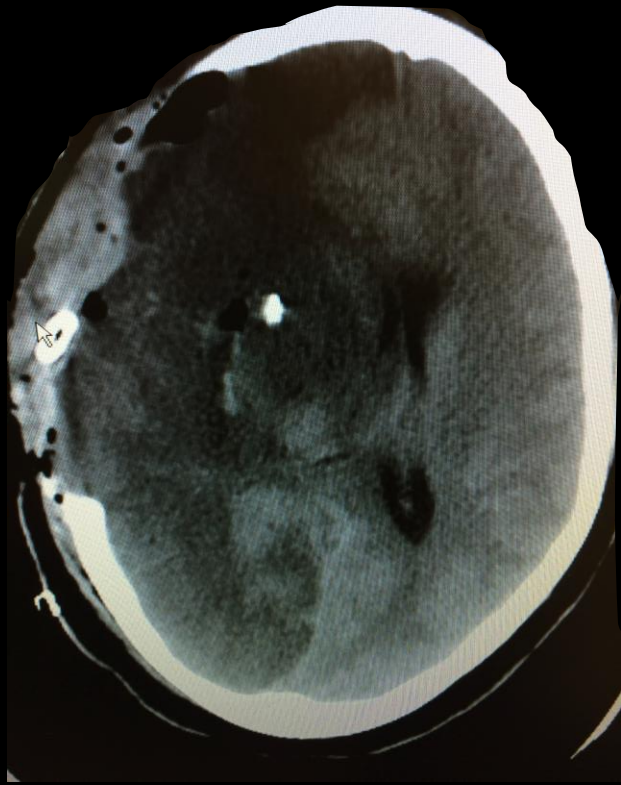
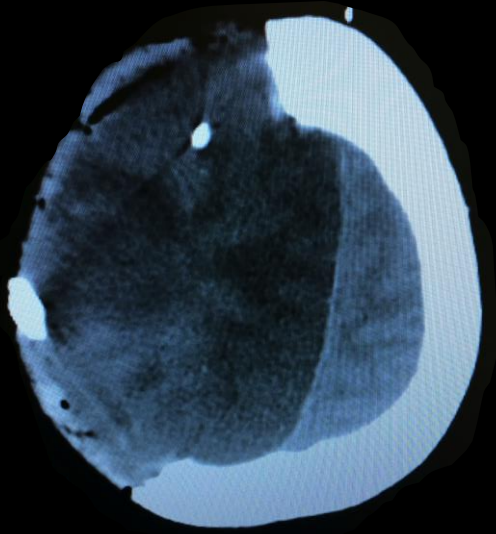
Perfusion (Tmax > 6.0s) volume: 187.0 ml

Mismatch volume: 21.9 ml



Right





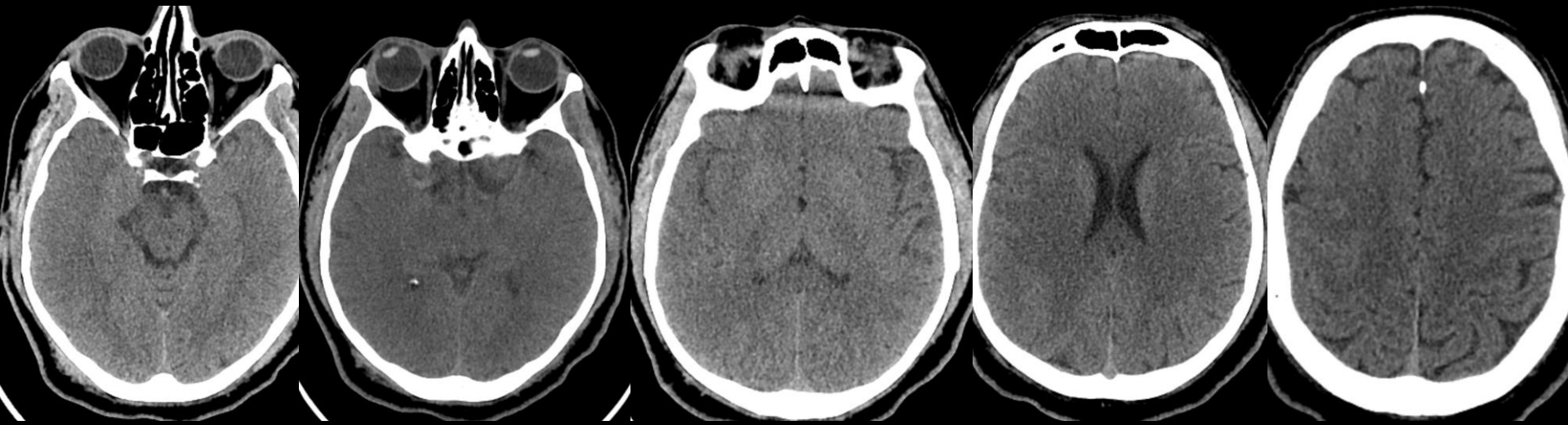
CASE #6

52yo M

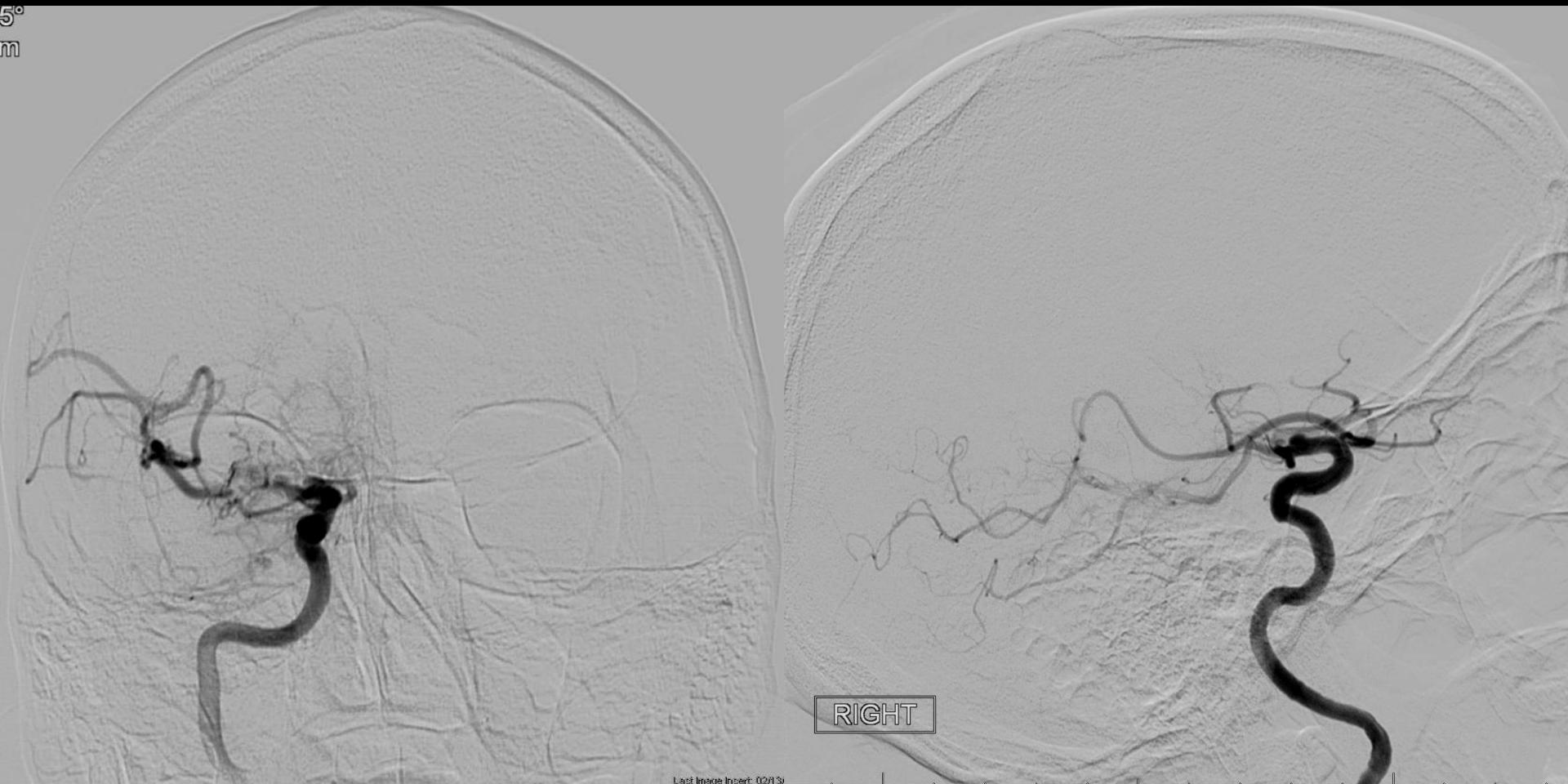HTN & ETOH.

Crashes car into another car in parking lot (coming from bar).

Abrasions only. Hemiplegic. NIHSS 10

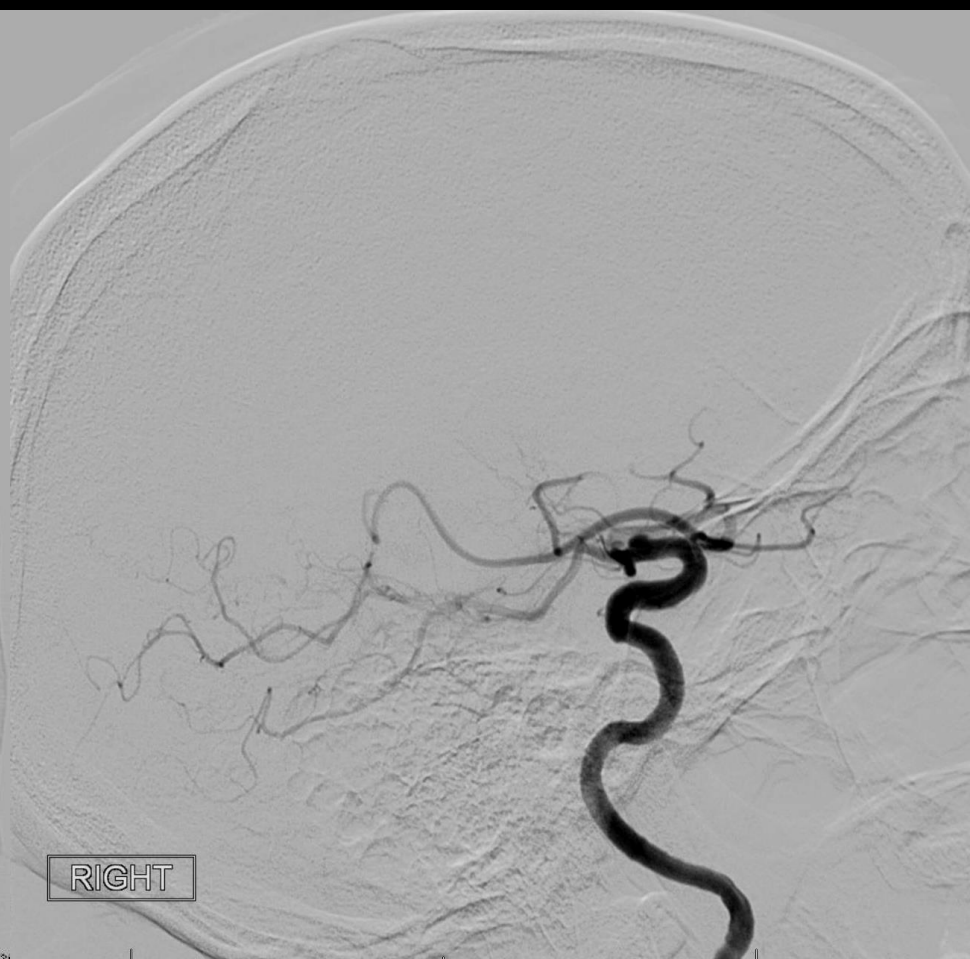
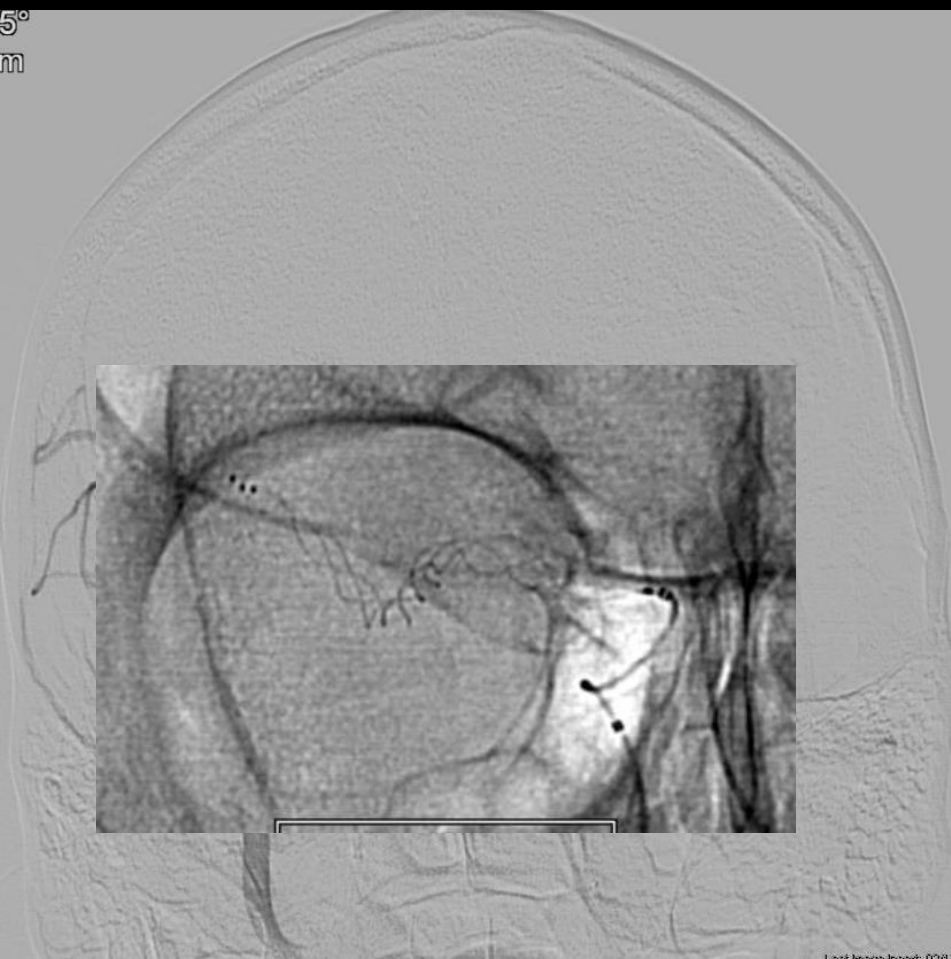
Baseline



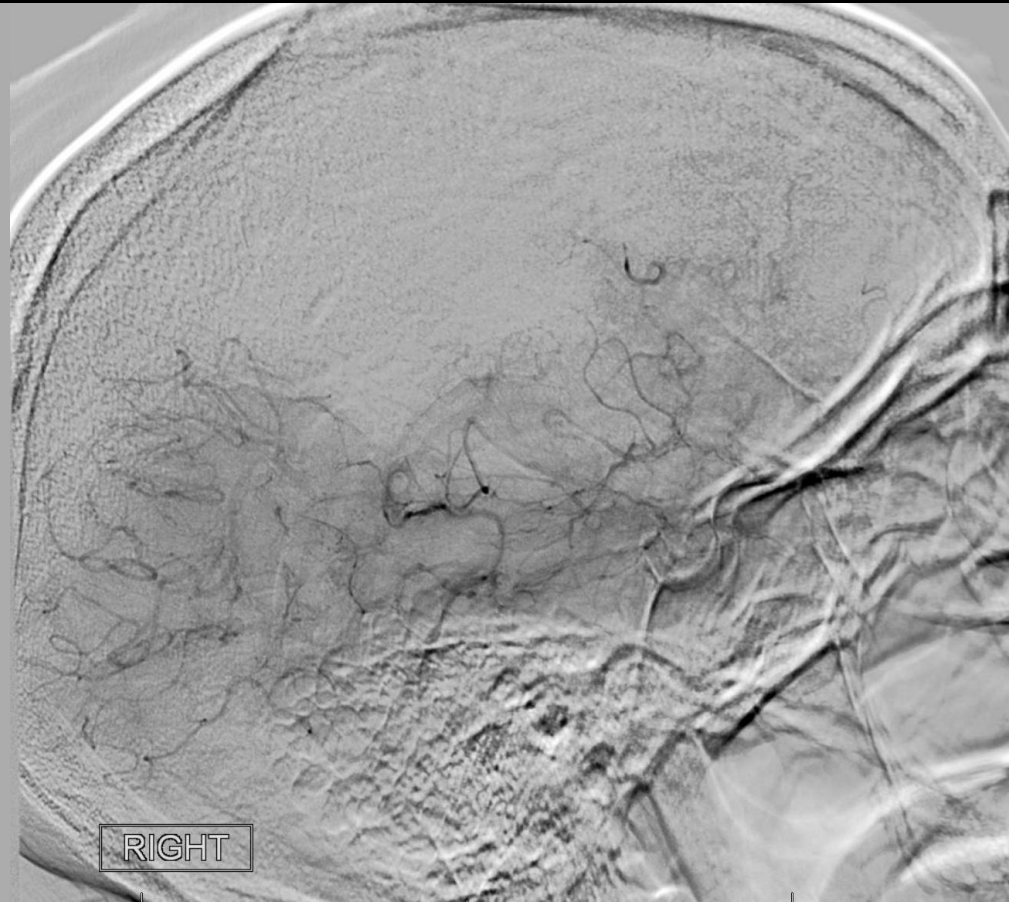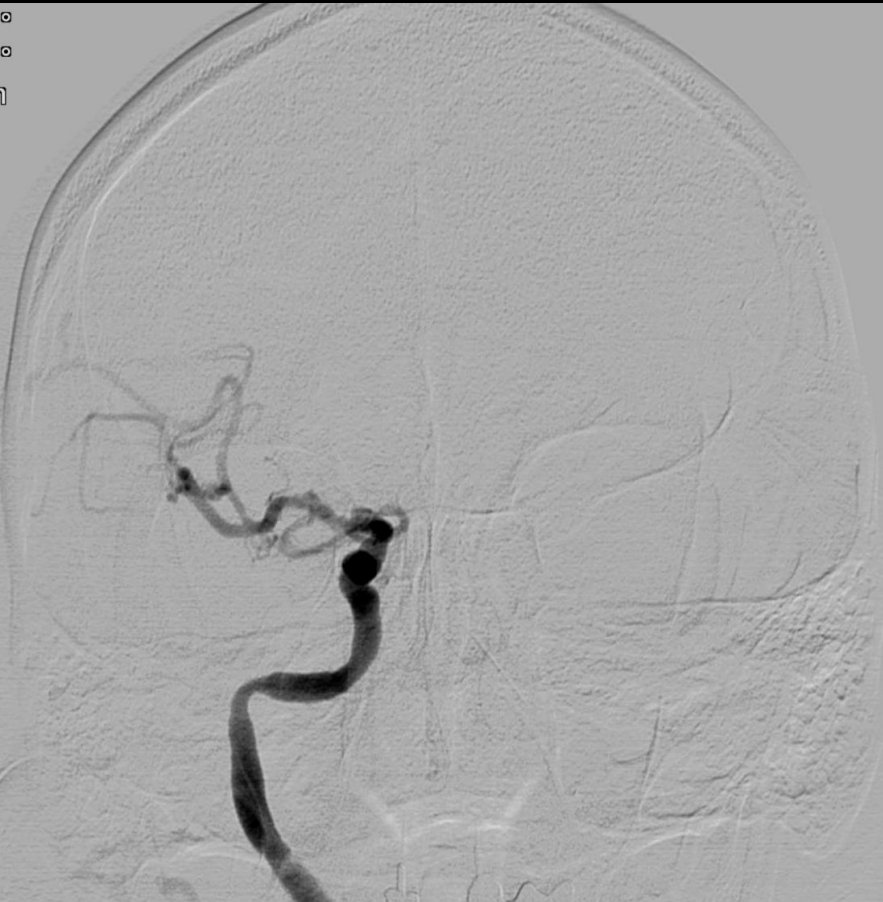
Trevo 4x30

5°
m

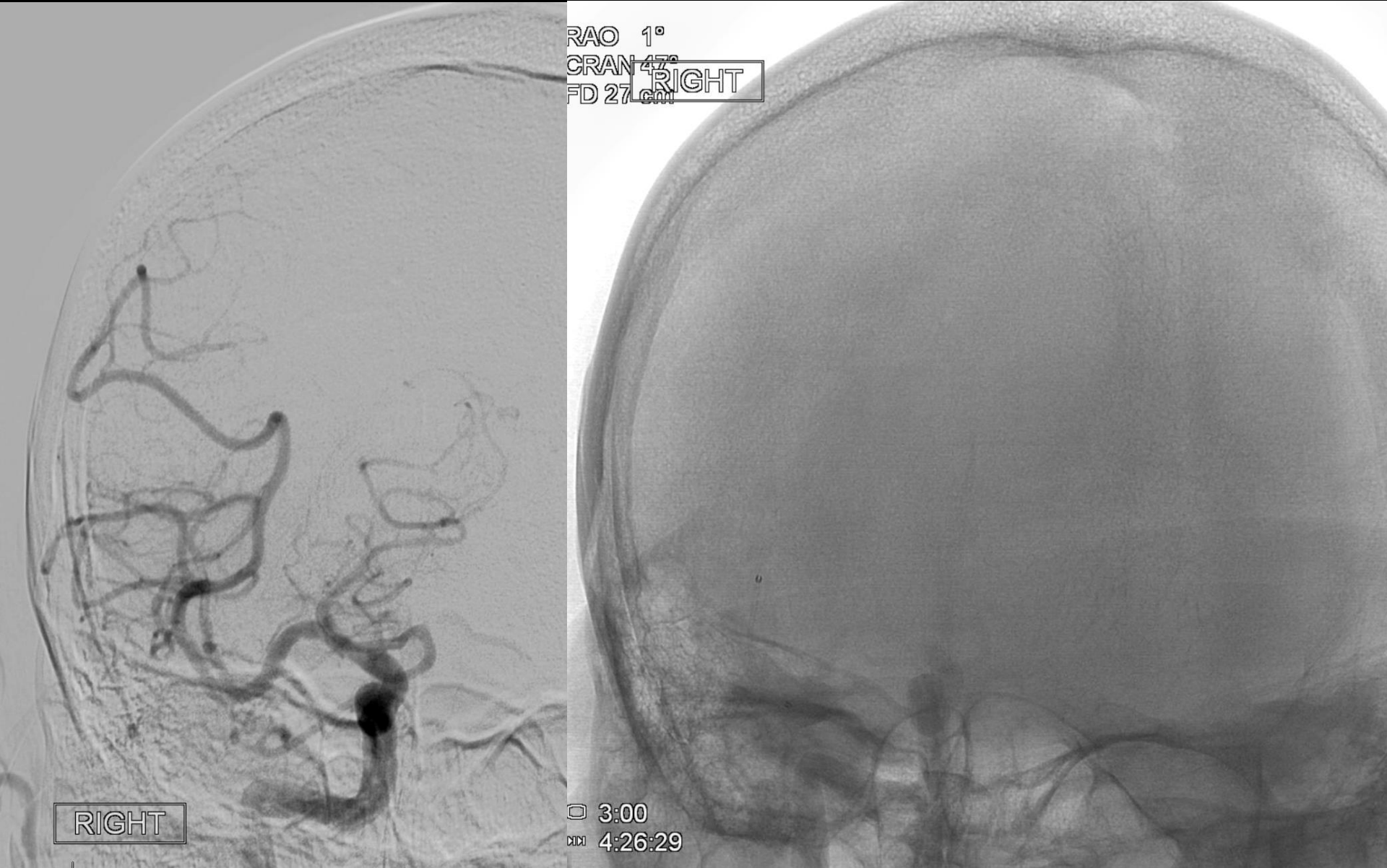


Last Image Insert: 0213

mTICI2b

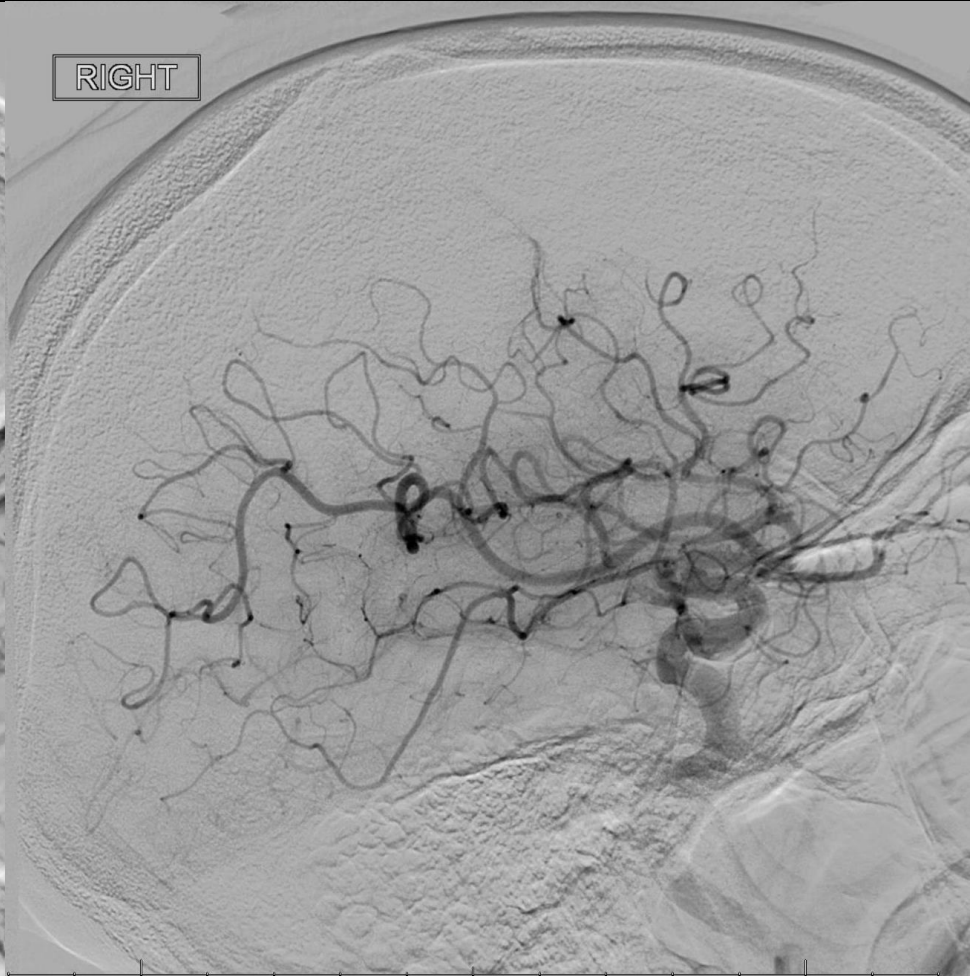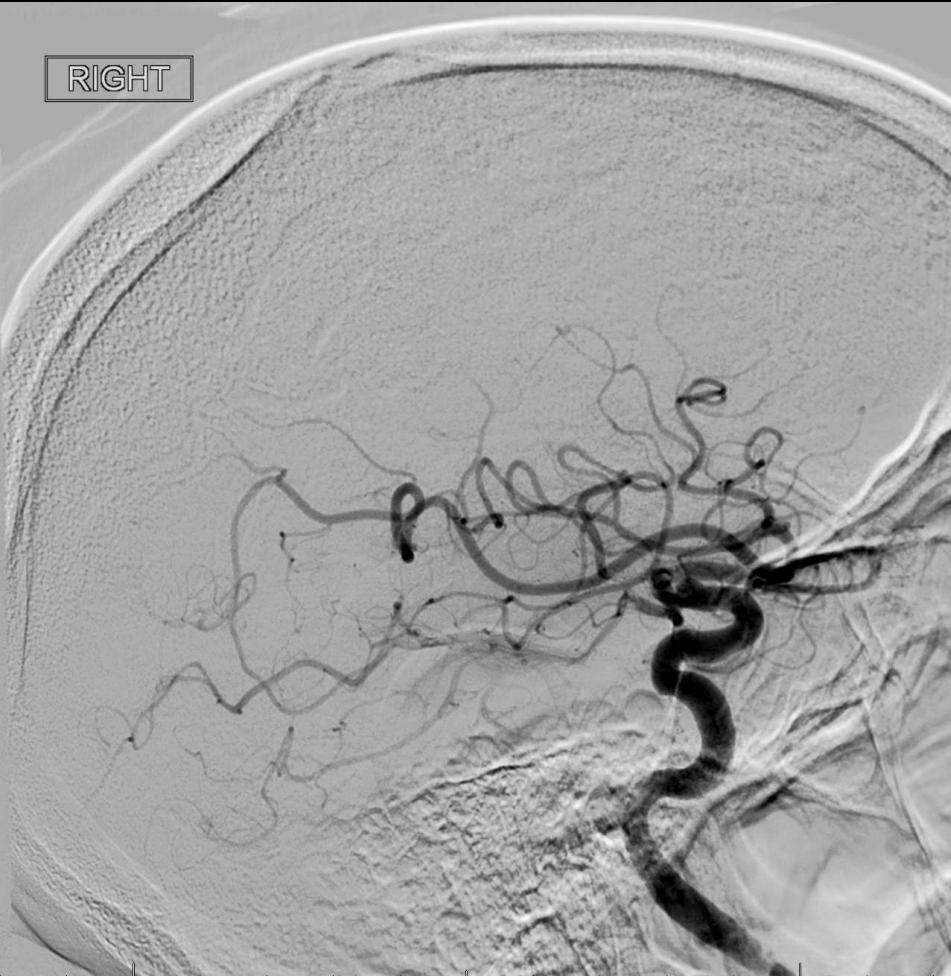


Intraluminal thrombus (sup division) IA tPA 8mg

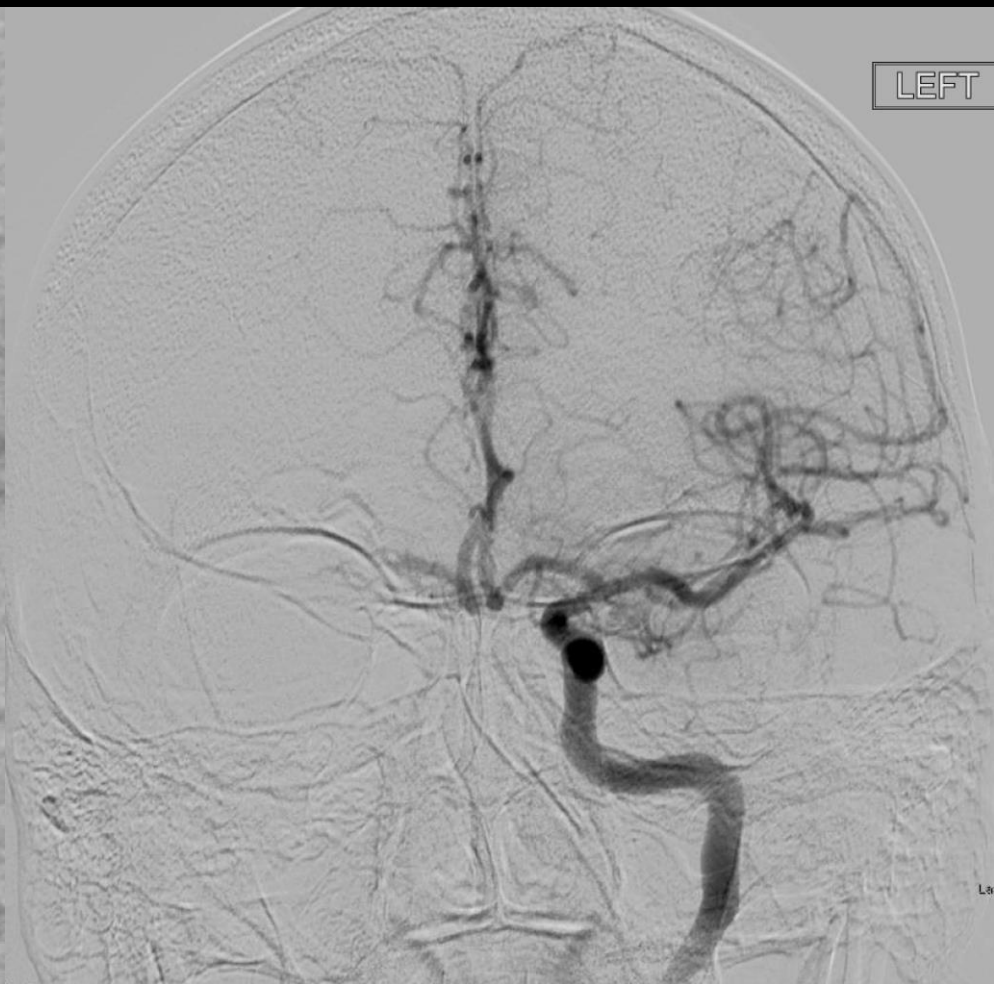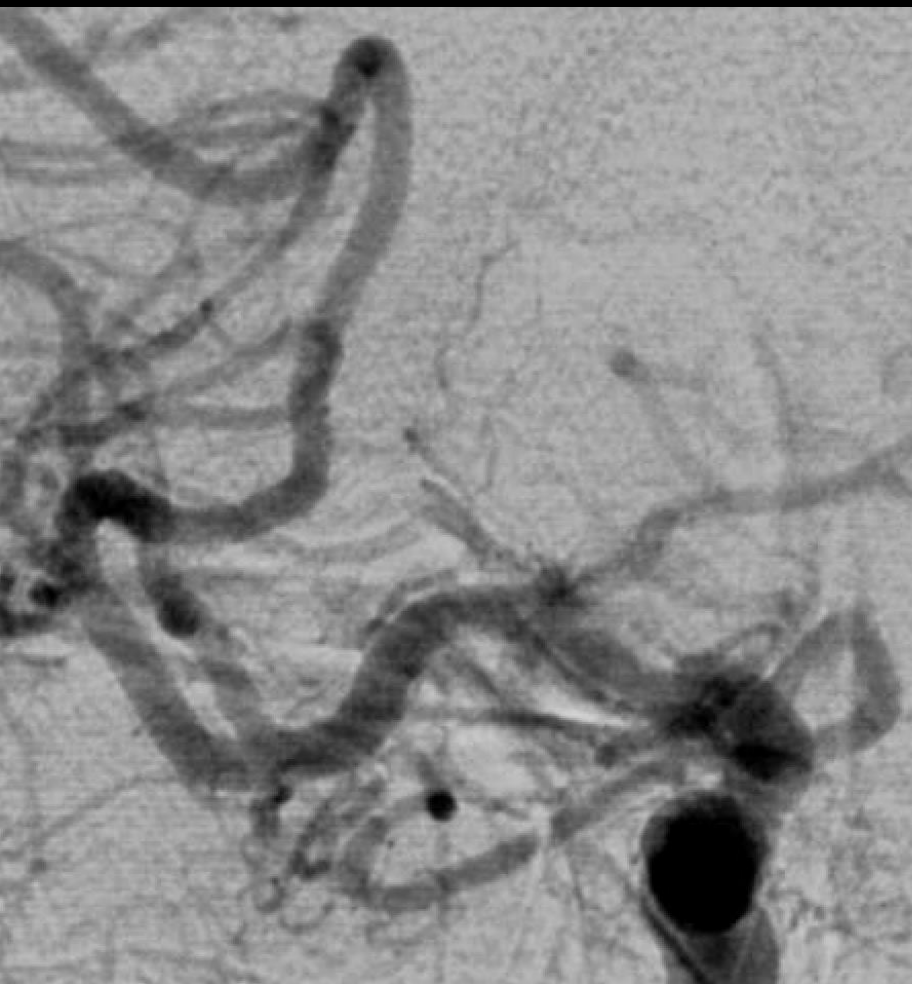


TICI ?3

ASA 300mg PR

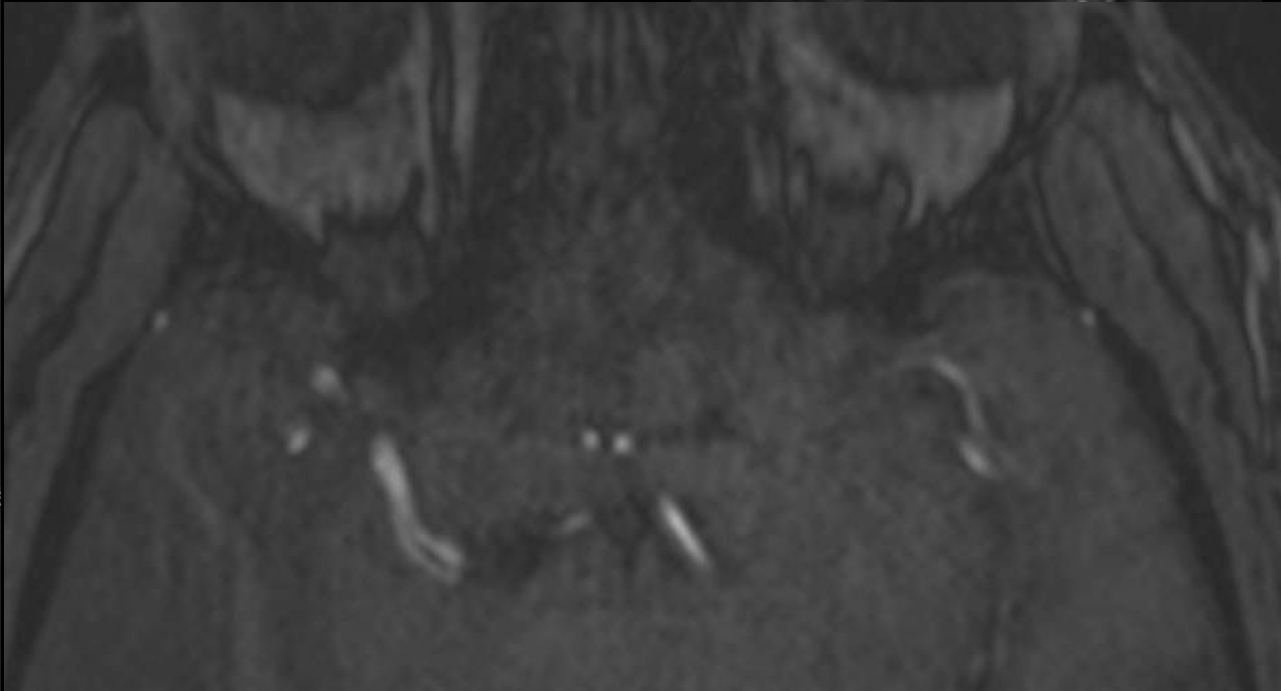
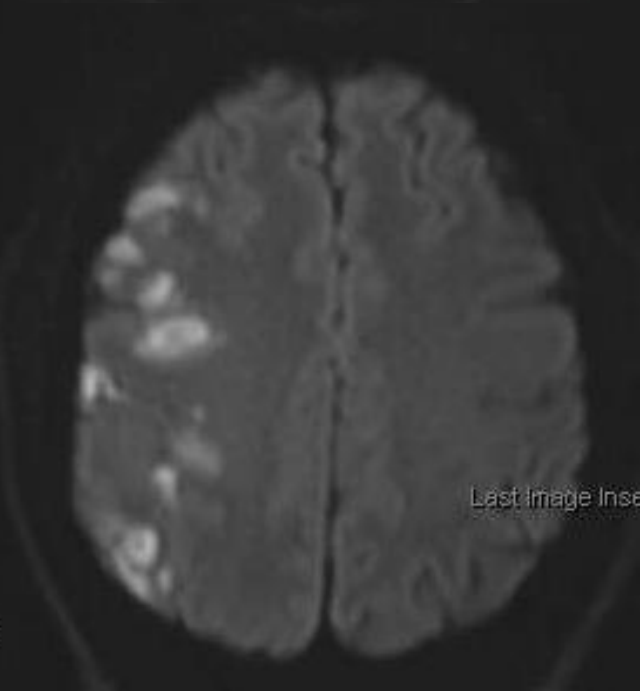
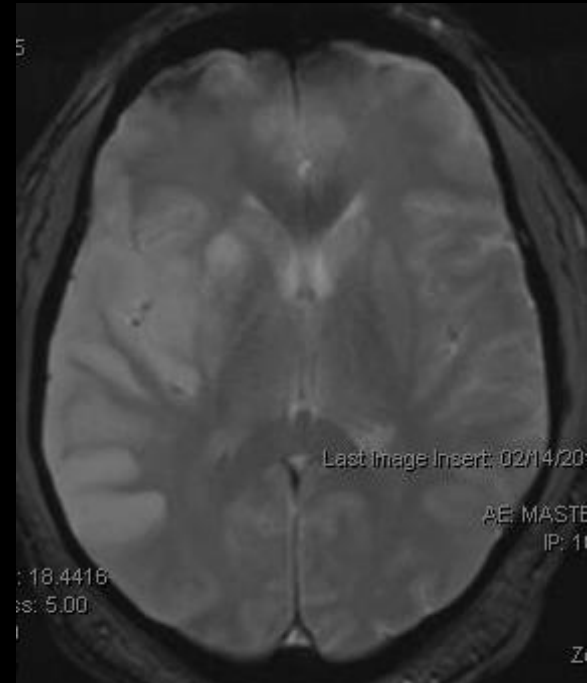
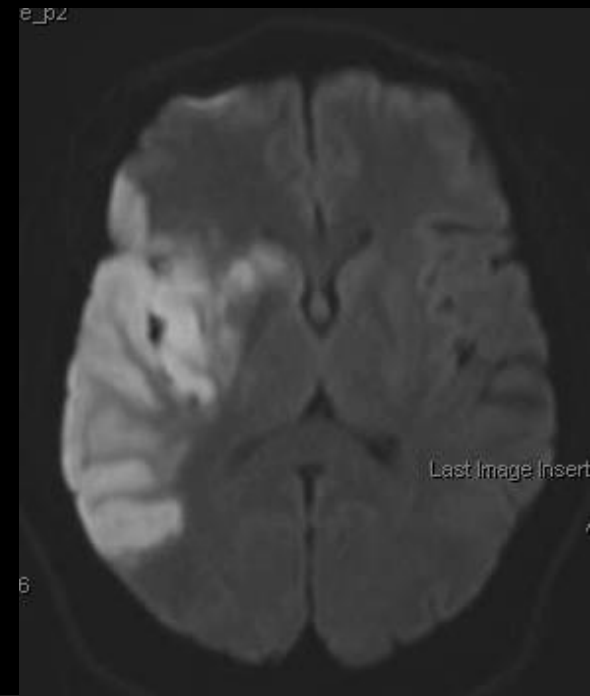


mTICI 2b

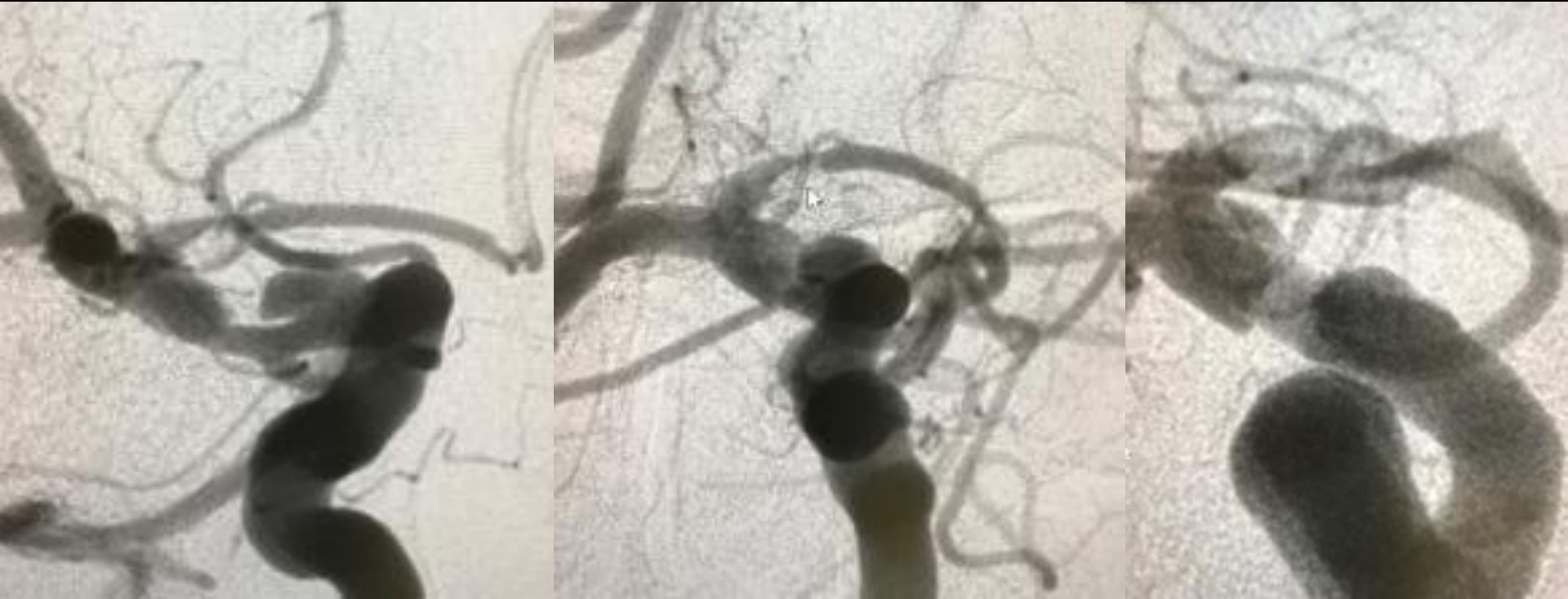


MRI / MRA 24h

NIHSS 4



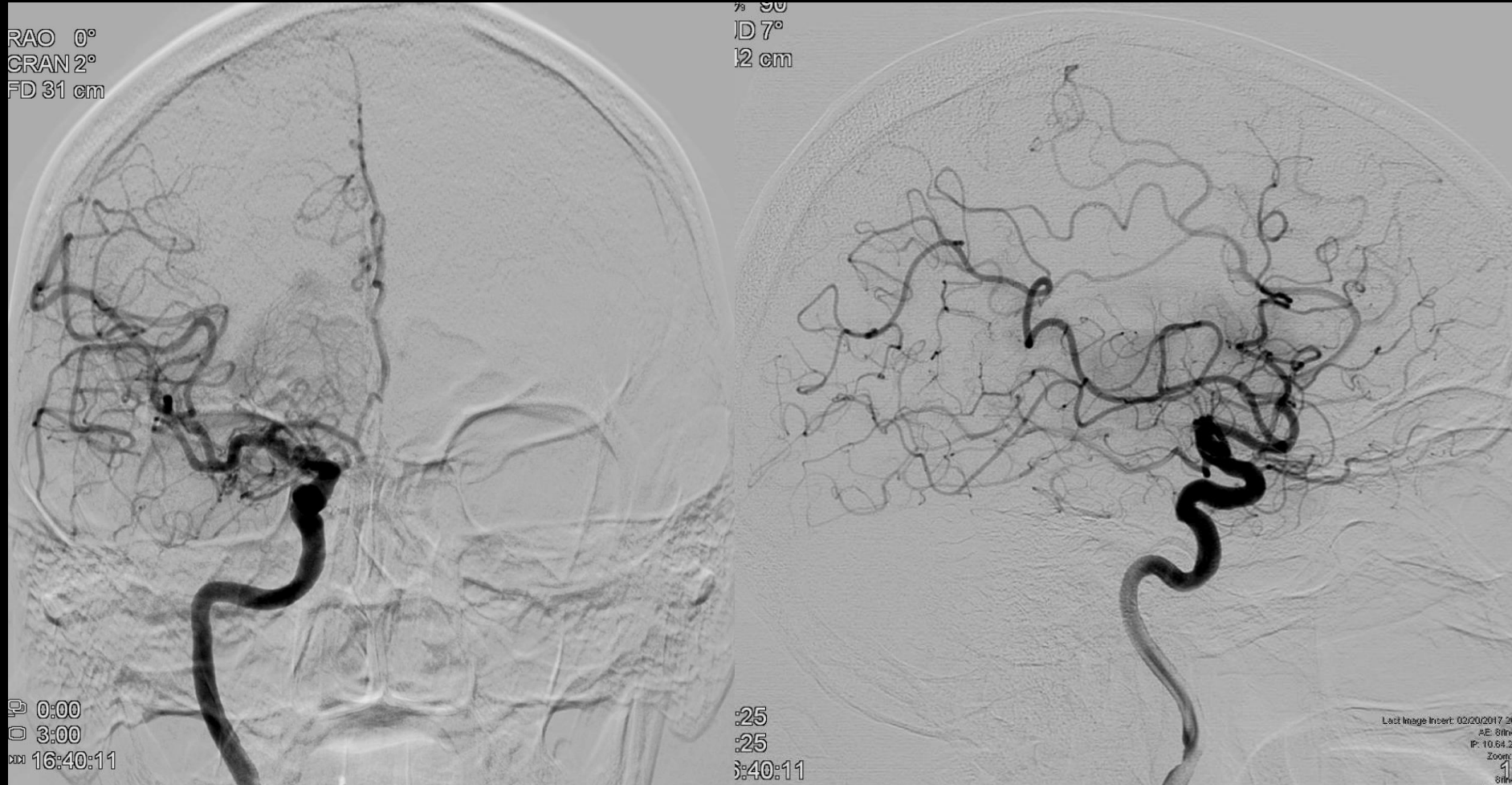Elective Repeat Angio @48h



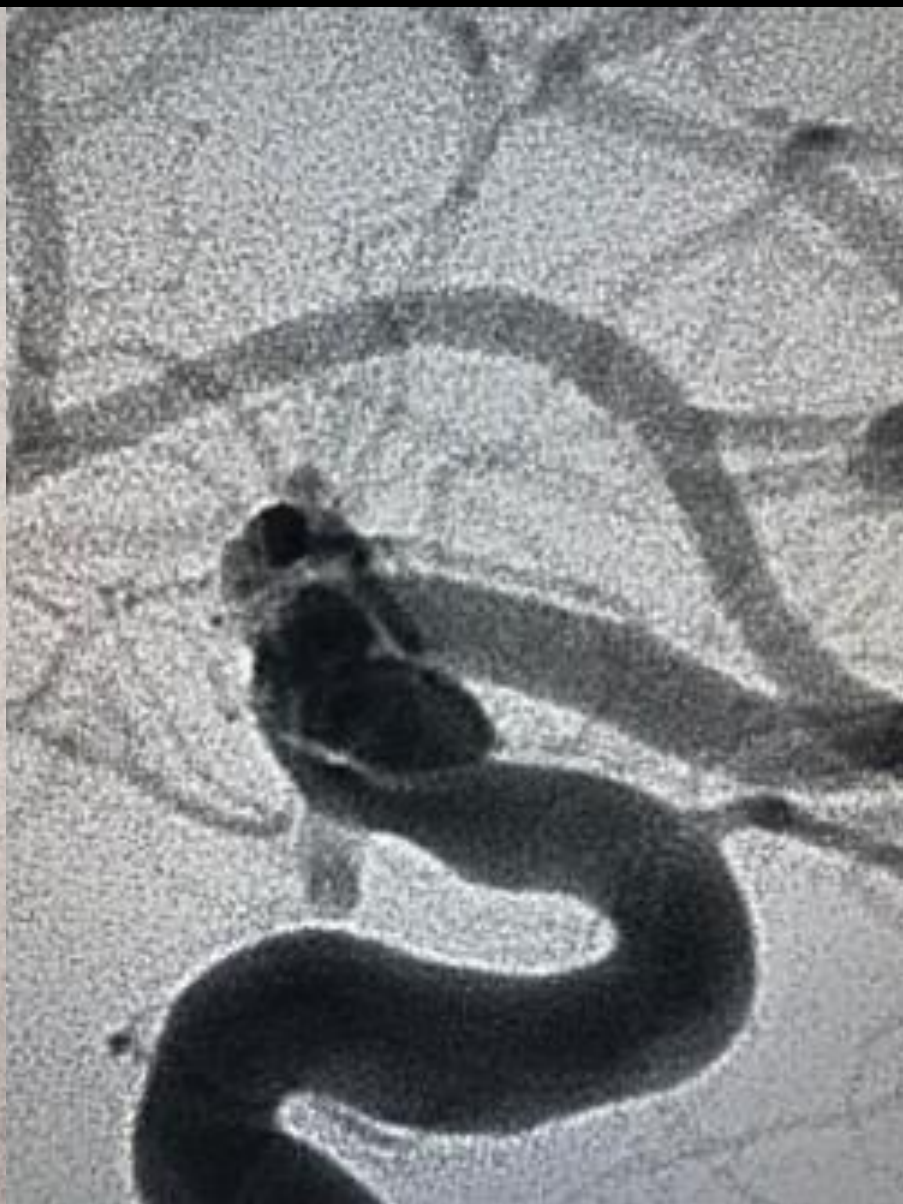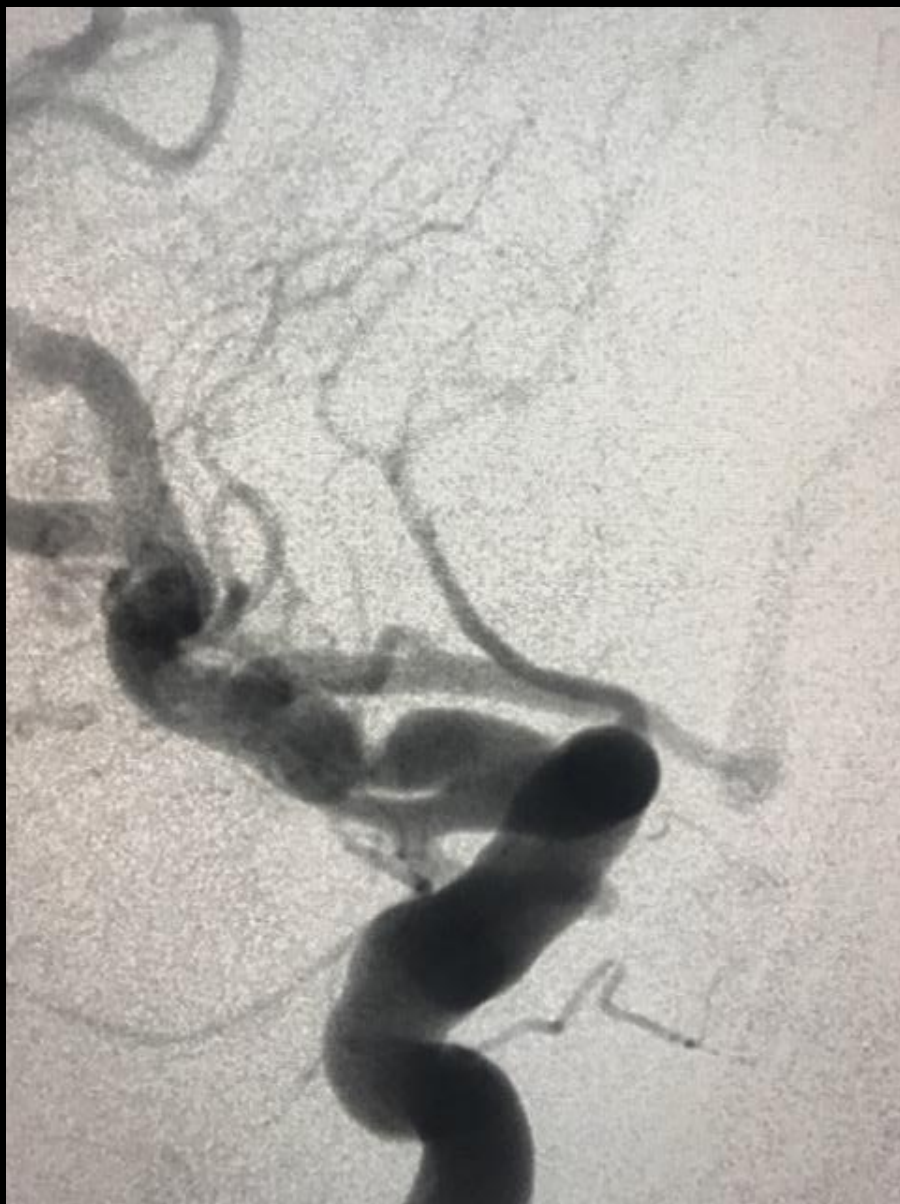Plan to repeat angio @ D10

D9

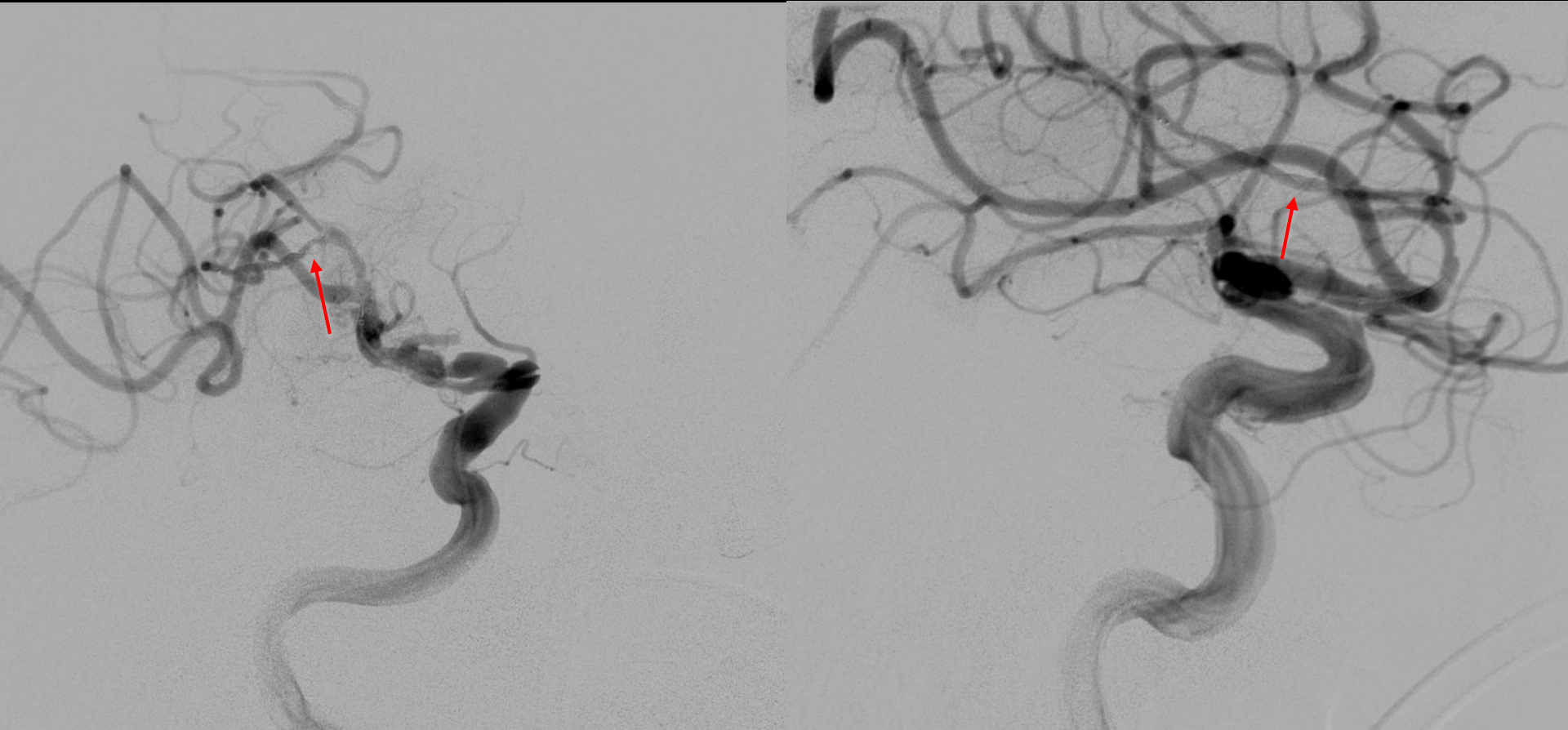NIHSS 16



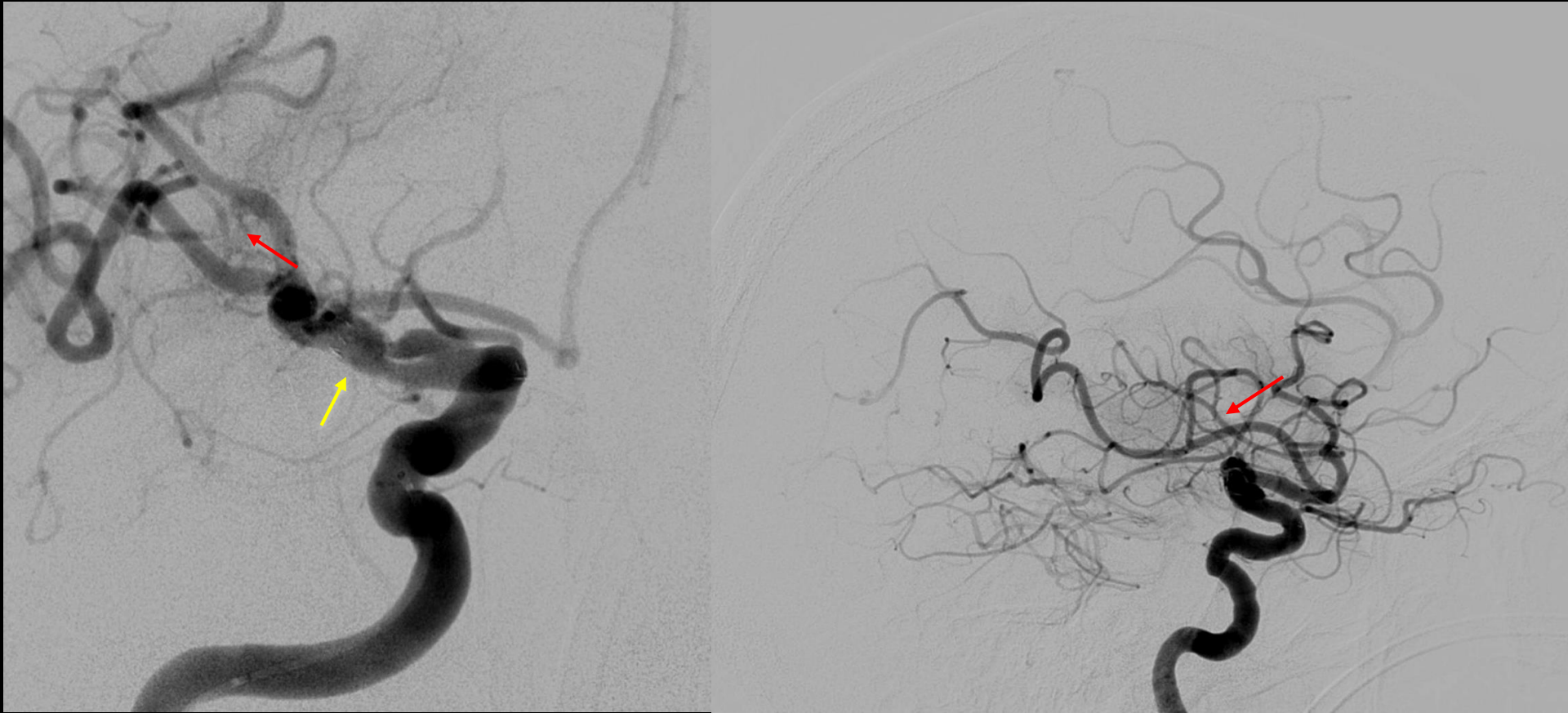
Baseline



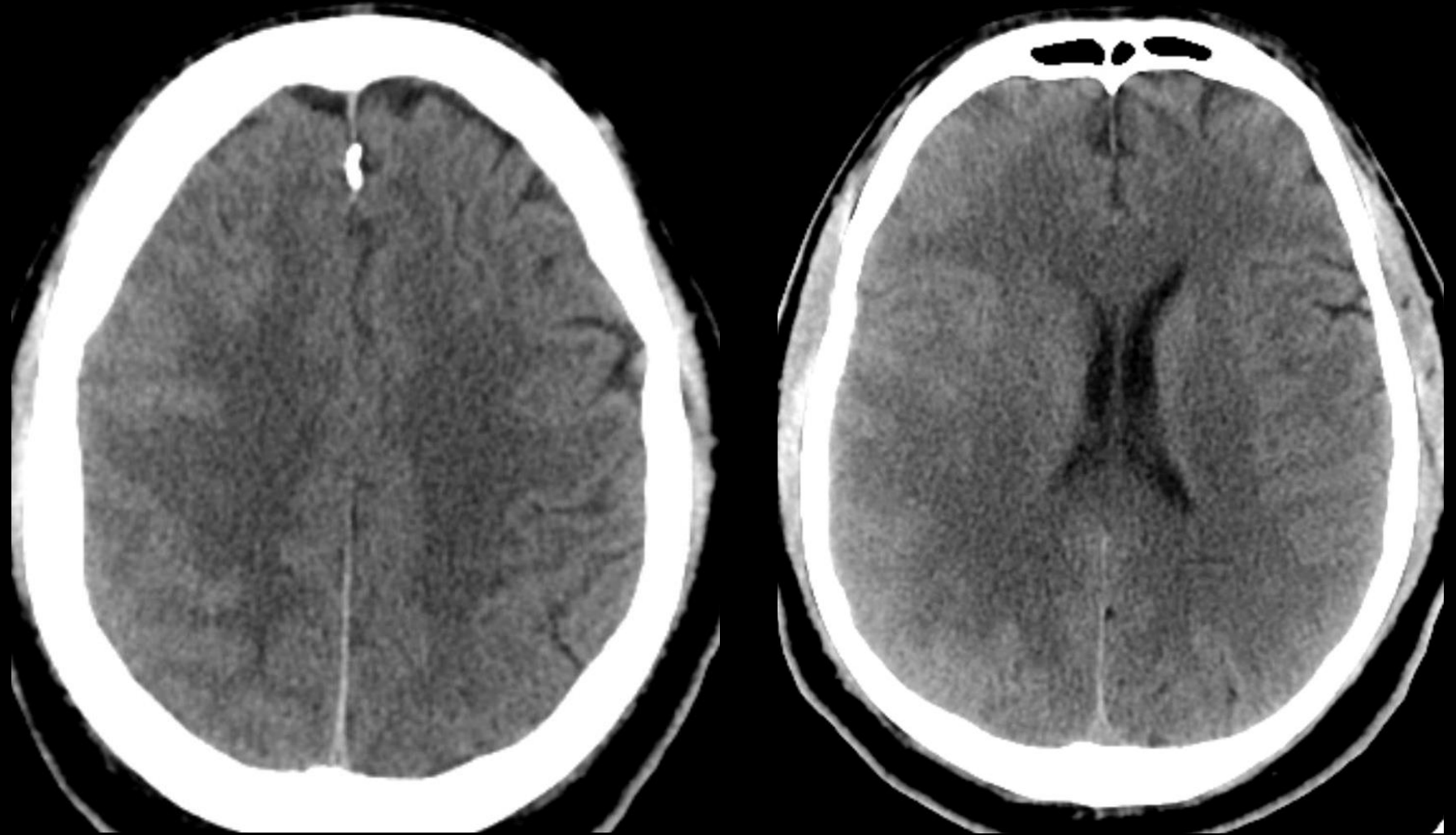
Trevo 3x20



AOL 2 / mTICI2a Enterprise SES

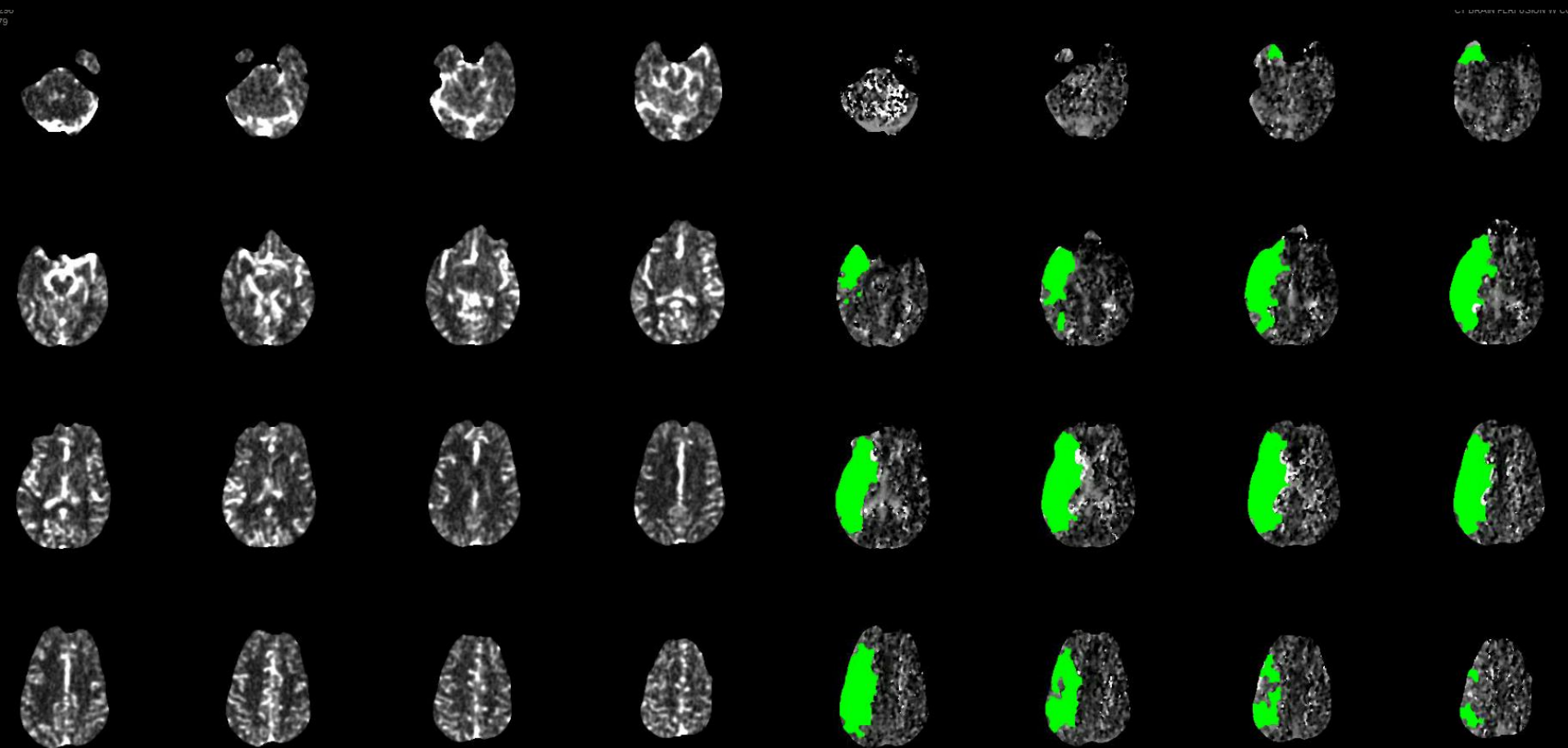


NIHSS 5 at DC



CASE #7

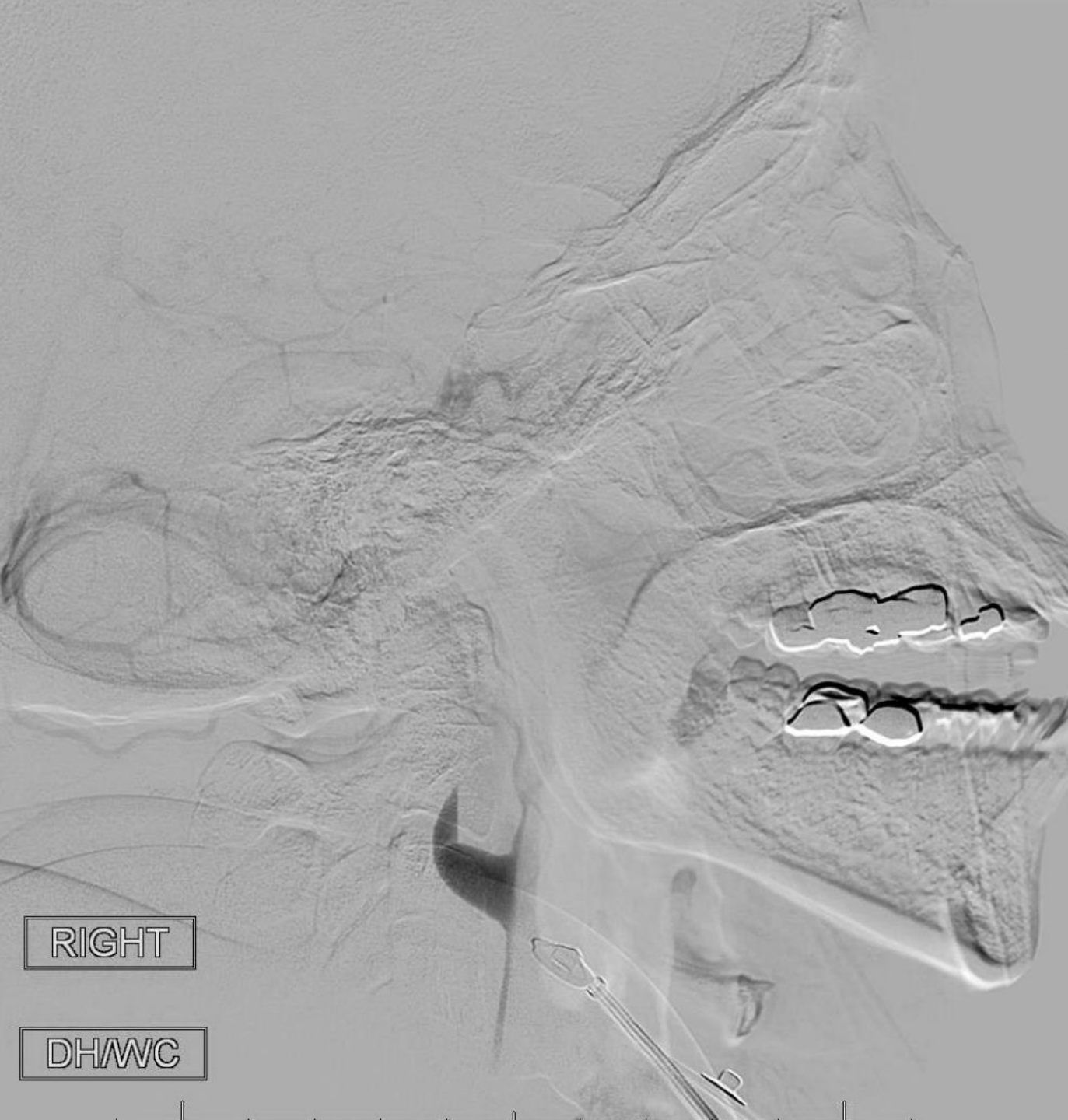55yo with cardiomyopathy. NIHSS4. 3h after onset.
IV fluids started. Worsened strength from drift to falling to
bed and worsening hemisensory loss.



CBF<30% volume: 0 ml

Tmax>6.0s volume: 167 ml

Mismatch volume: 167 ml
Mismatch ratio: infinite

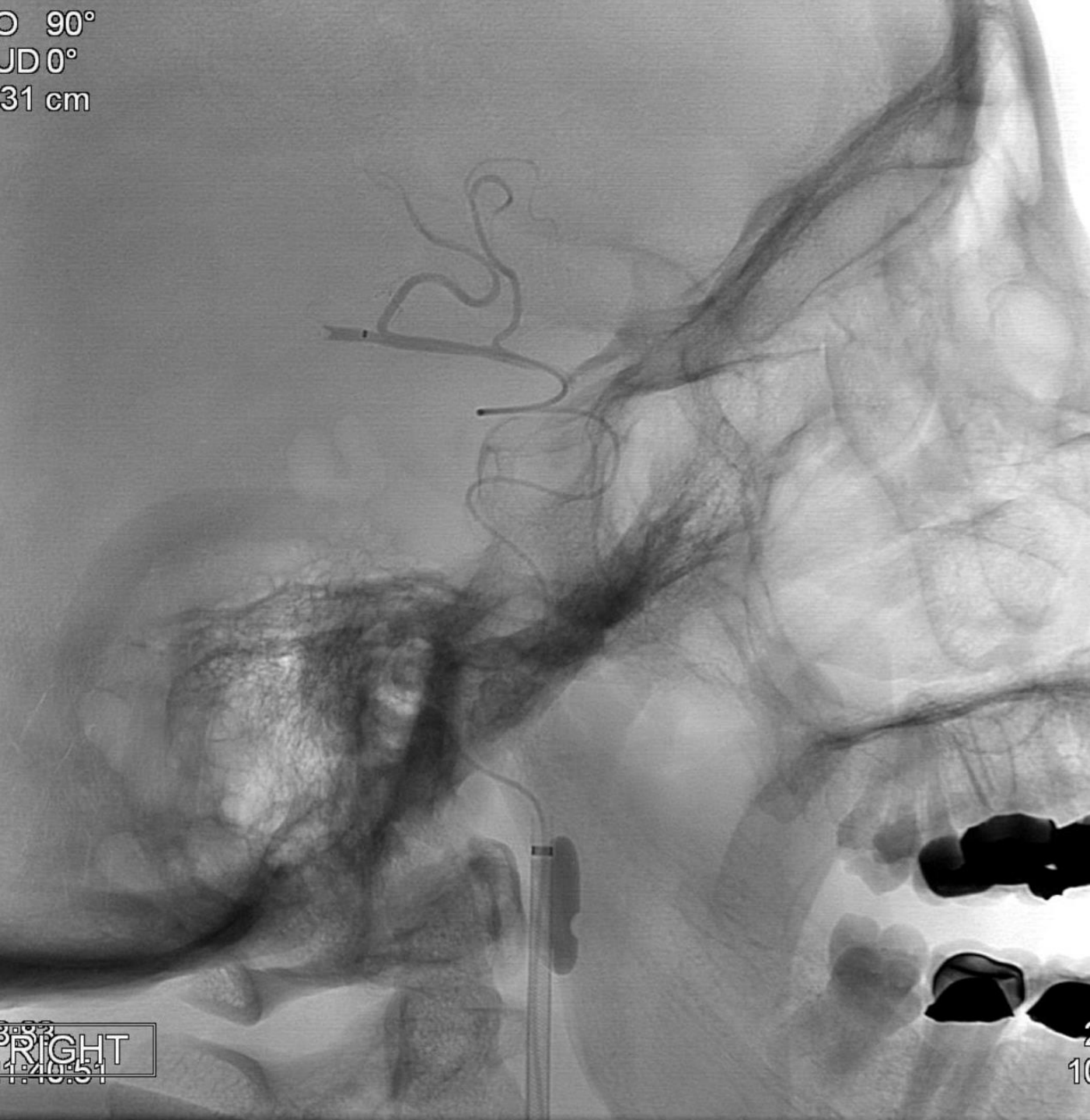

Baseline

RIGHT

DH/WC

90°
JD 0°
31 cm



Microcather
Run

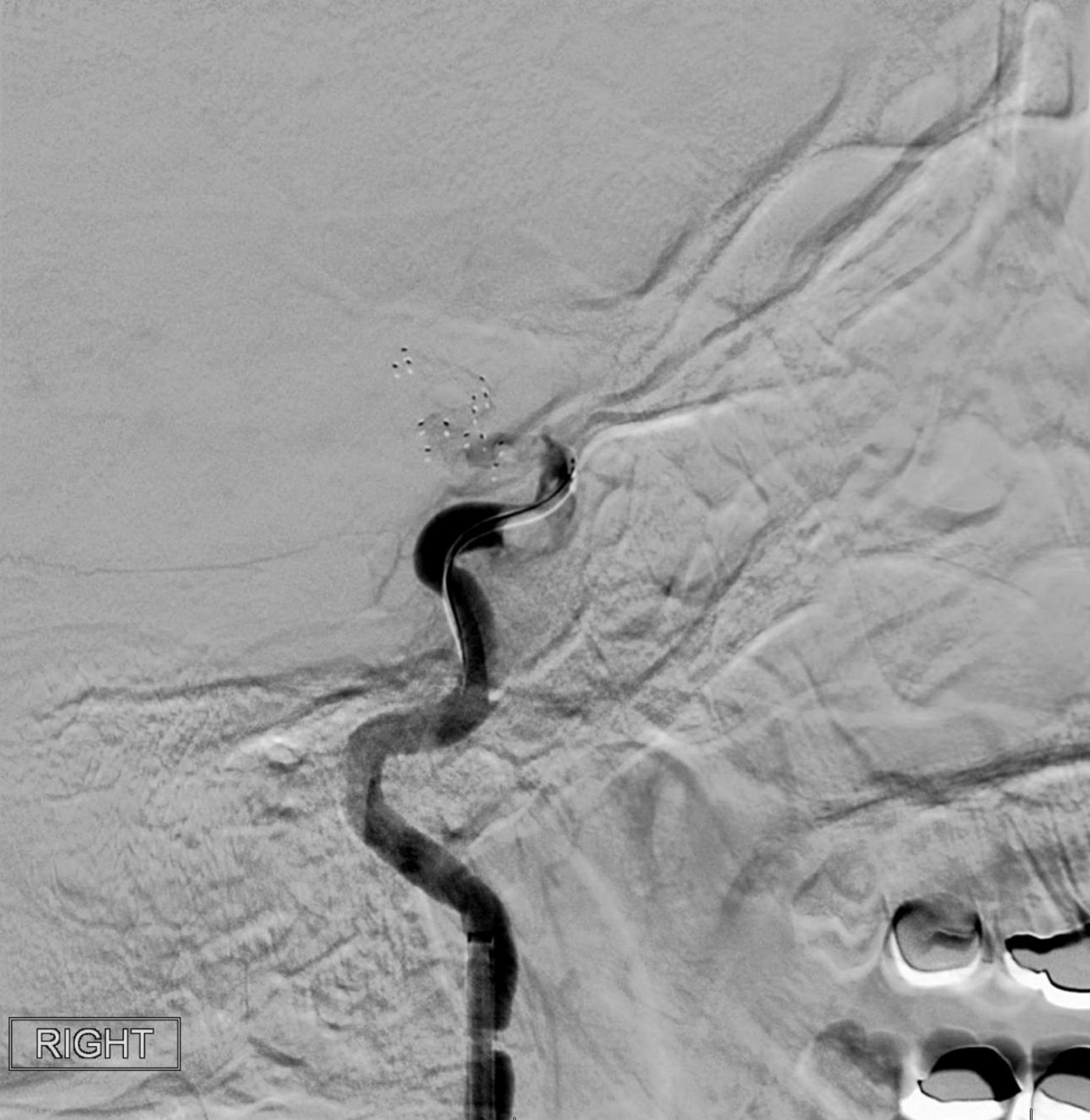RIGHT
1:40:51

10



RIGHT

Post first
Solitaire 4x40
Pass
TICIO



Second
Solitaire 4x40
Pass

RIGHT



TICIO

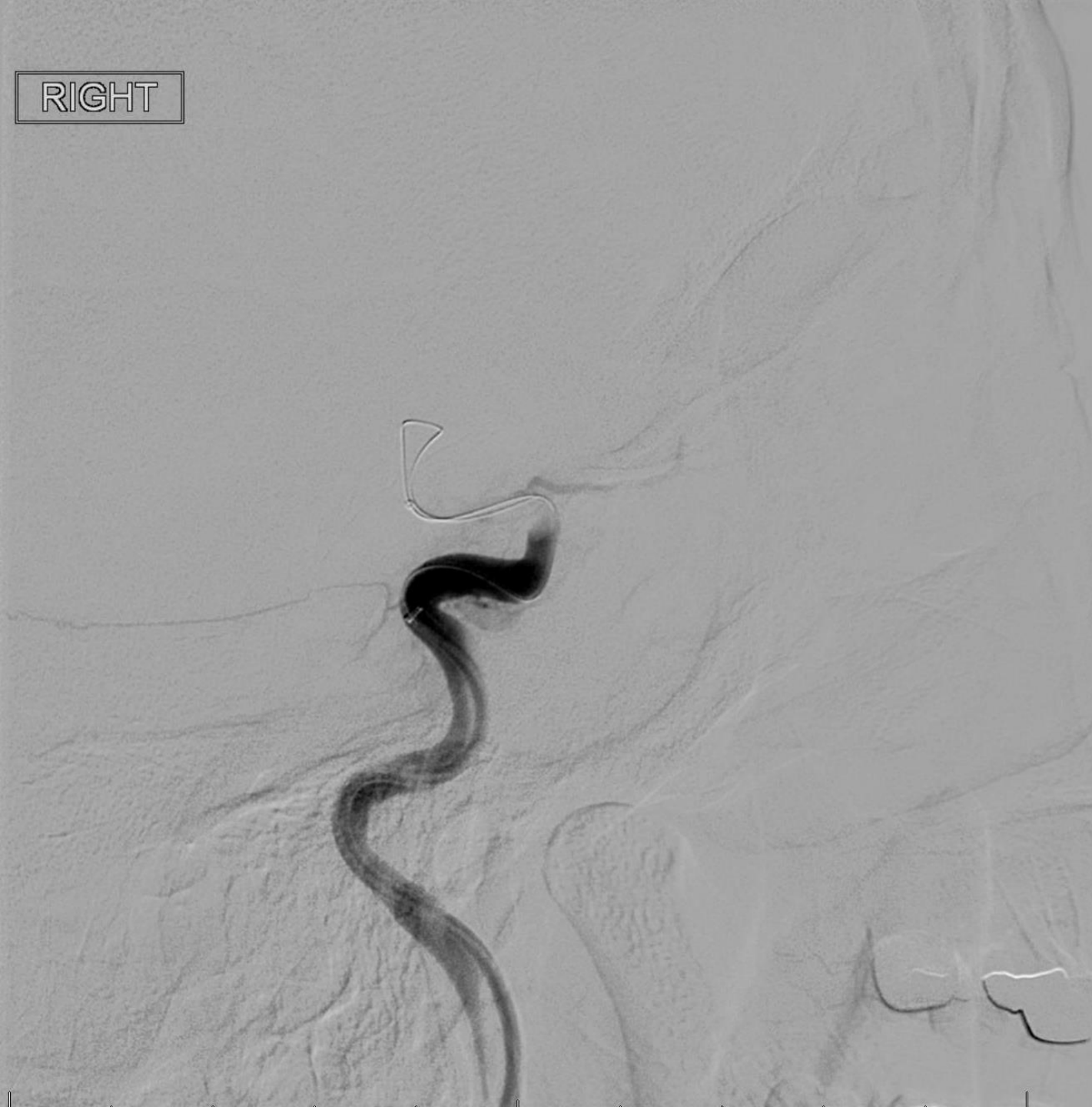RIGHT

Last Image Inse

RIGHT

3rd Pass
Penumbra 68
+ Solitaire
4x40

4th
Penumbra
68 + Trevo
6x25



2 Microcatheters

One retriever on each

RAO 15°
CRAN 14°
FD 22 cm

AO 90°
AUD 0°
D 27 cm

RIGHT
4.36
22:48:33

RIGHT
5.00
22:48:33

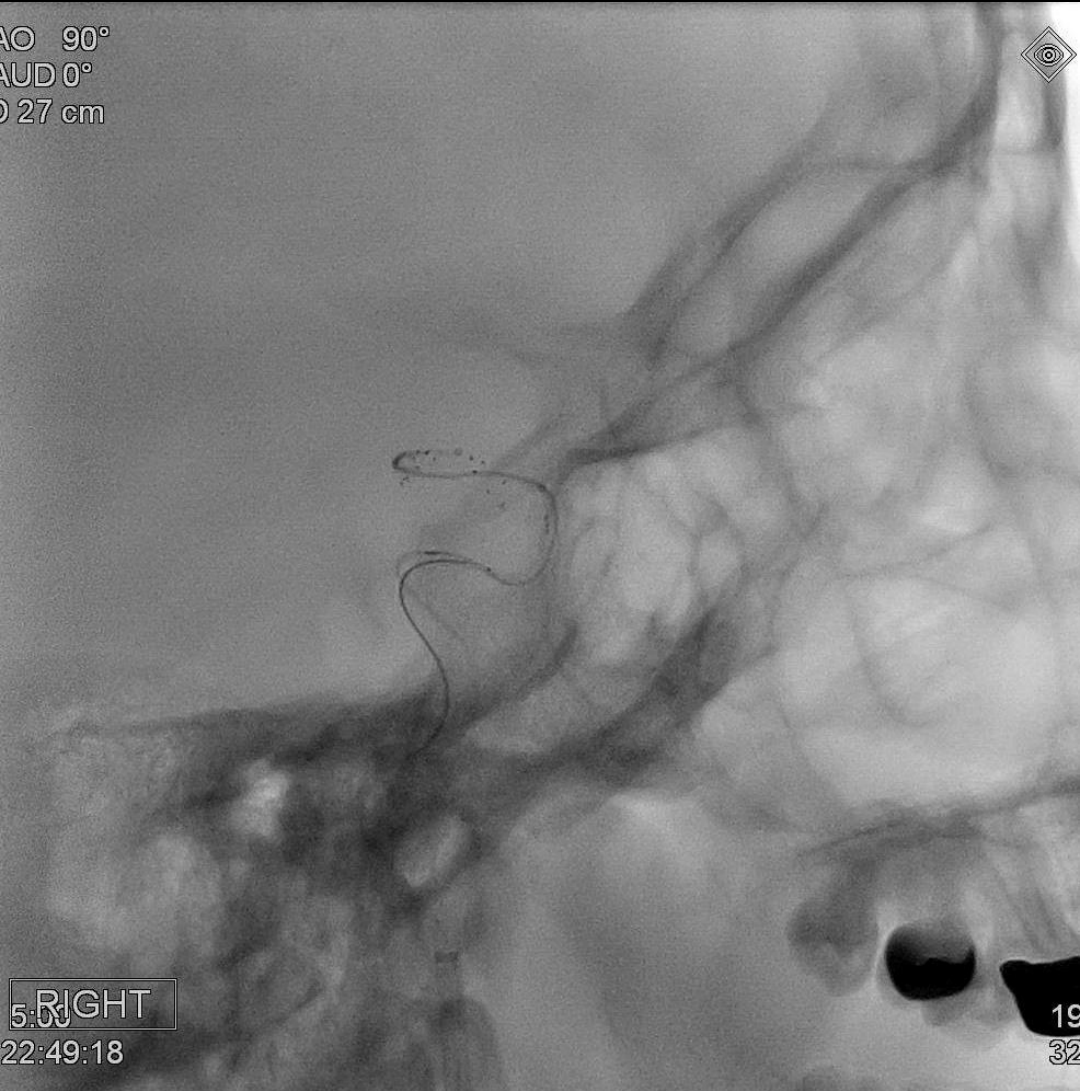
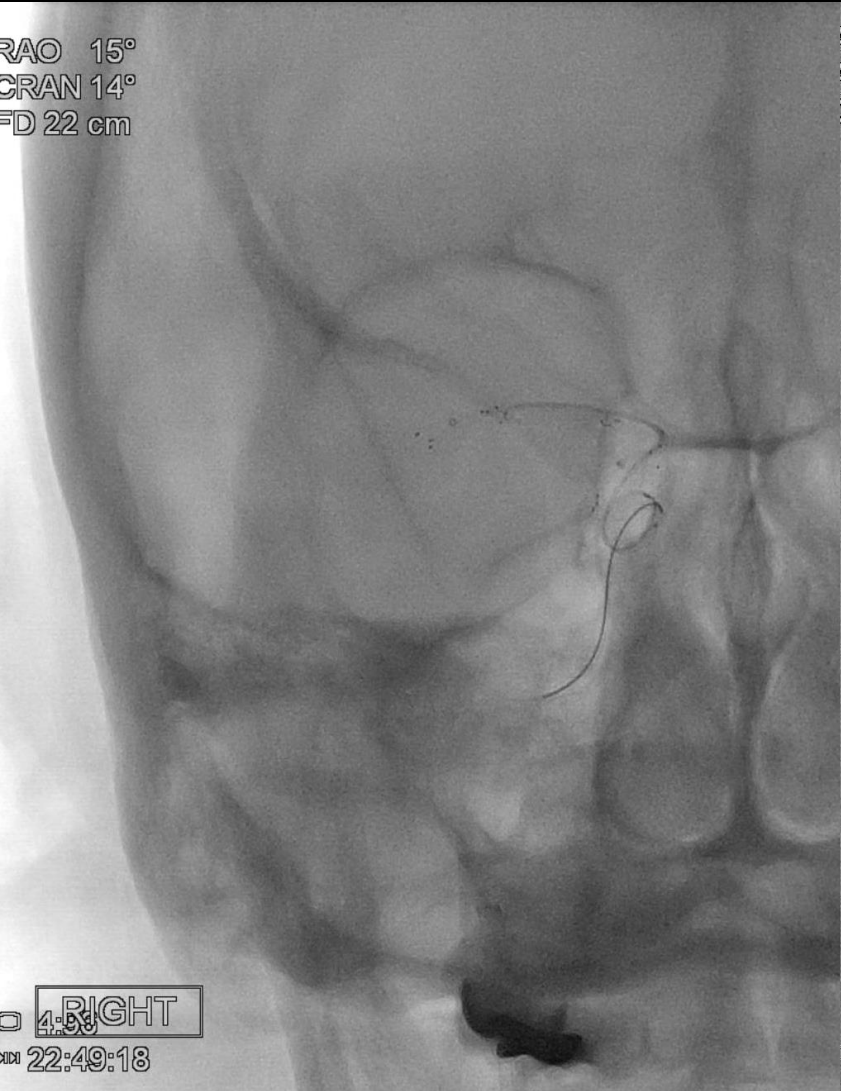


18
32

Solitaire 4x40 deployed first

RAO 15°
CRAN 14°
FD 22 cm

AO 90°
AUD 0°
D 27 cm



RIGHT

RIGHT

22:49:18

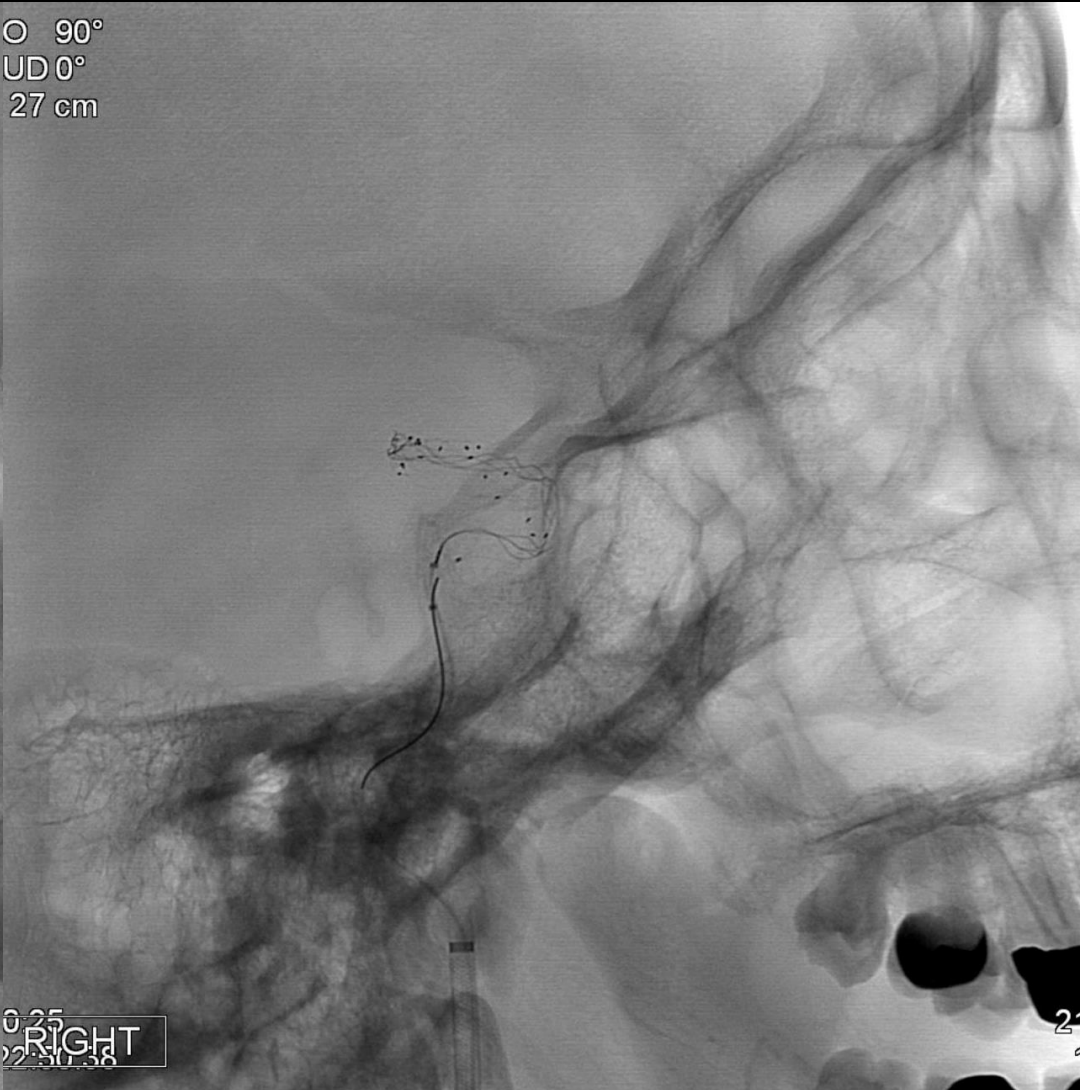
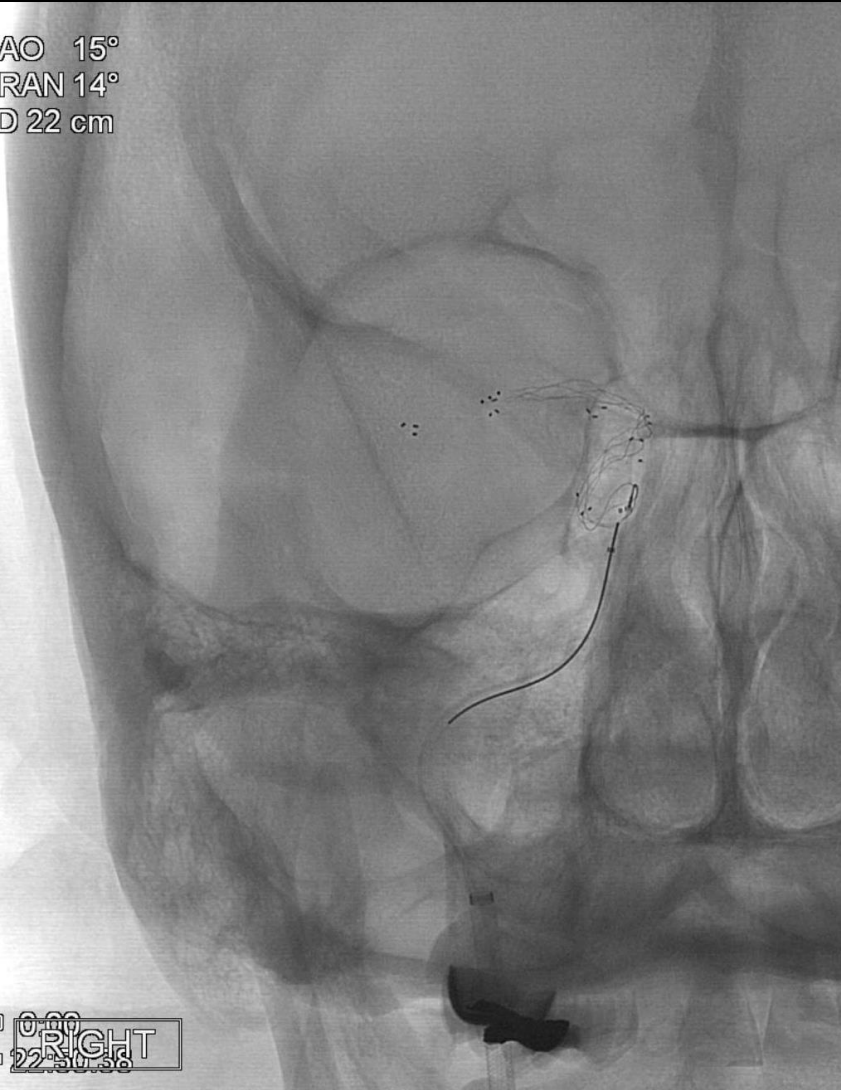
22:49:18

19
32

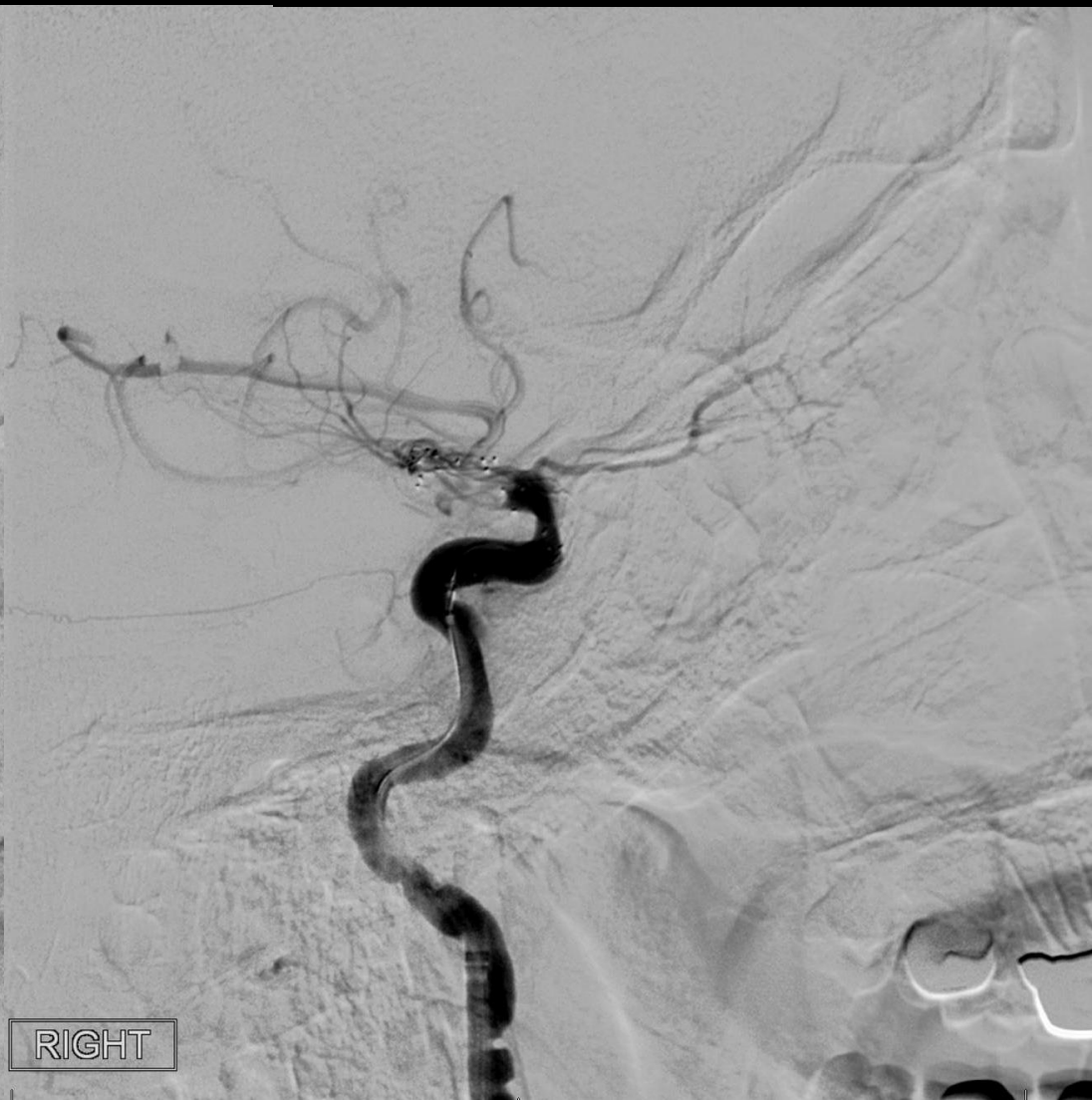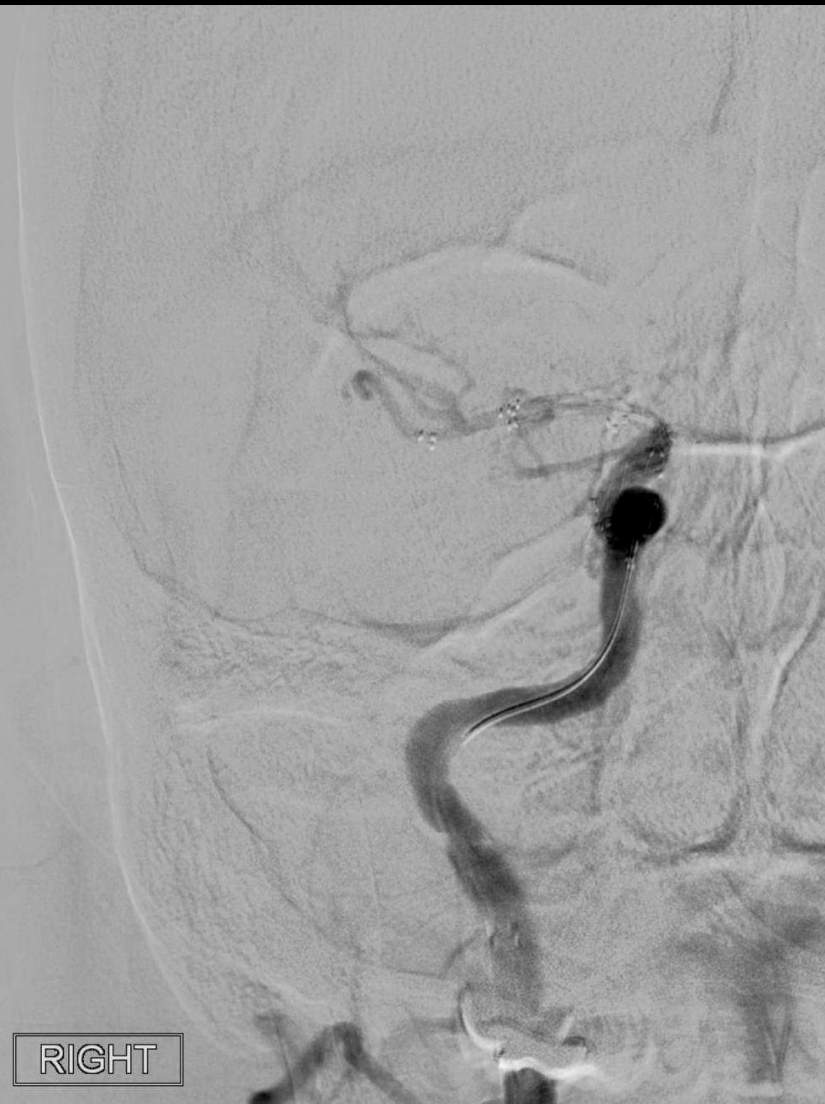Trevo 6x25 deployed

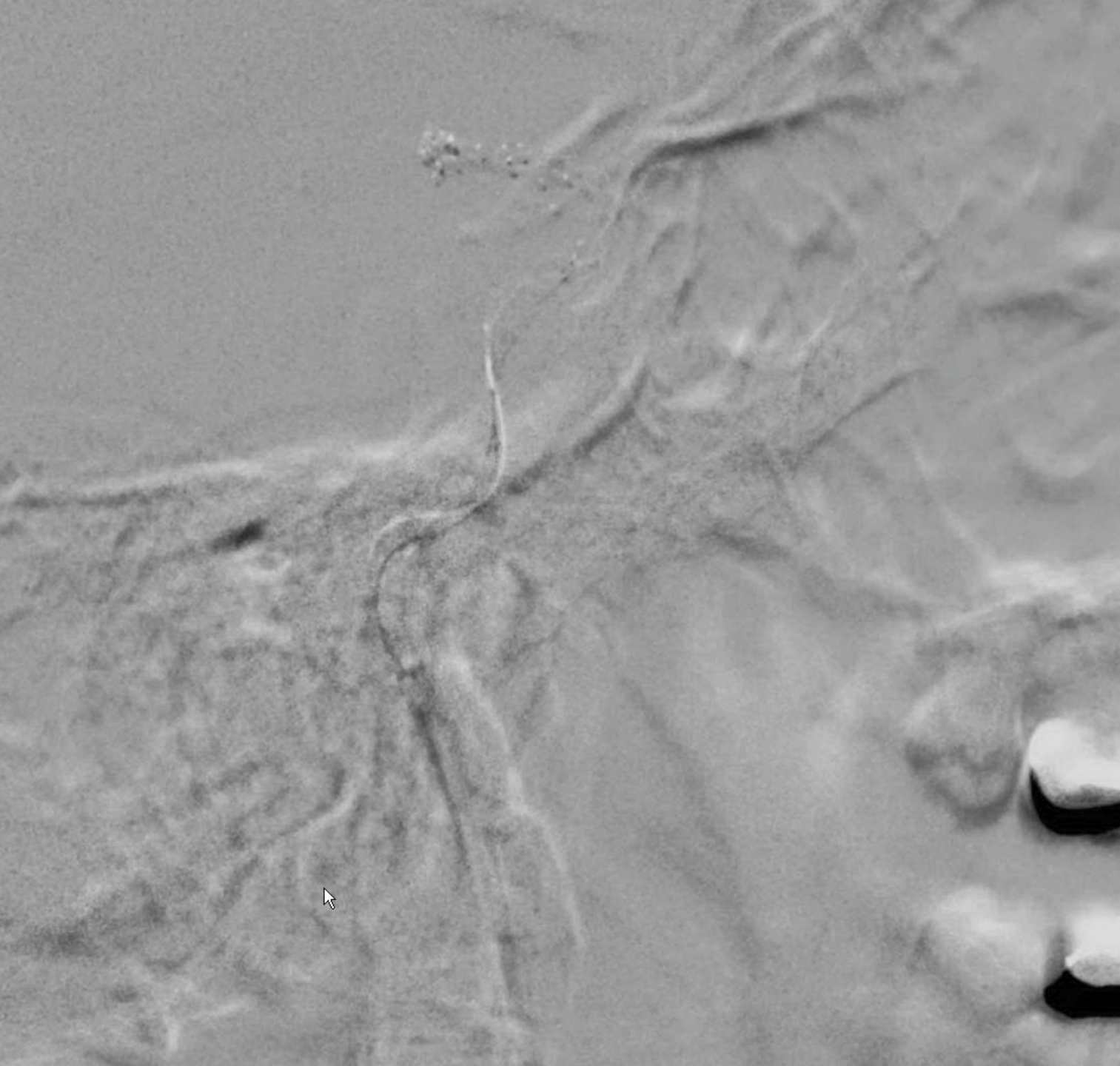
AO 15°
RAN 14°
D 22 cm

○ 90°
UD 0°
27 cm

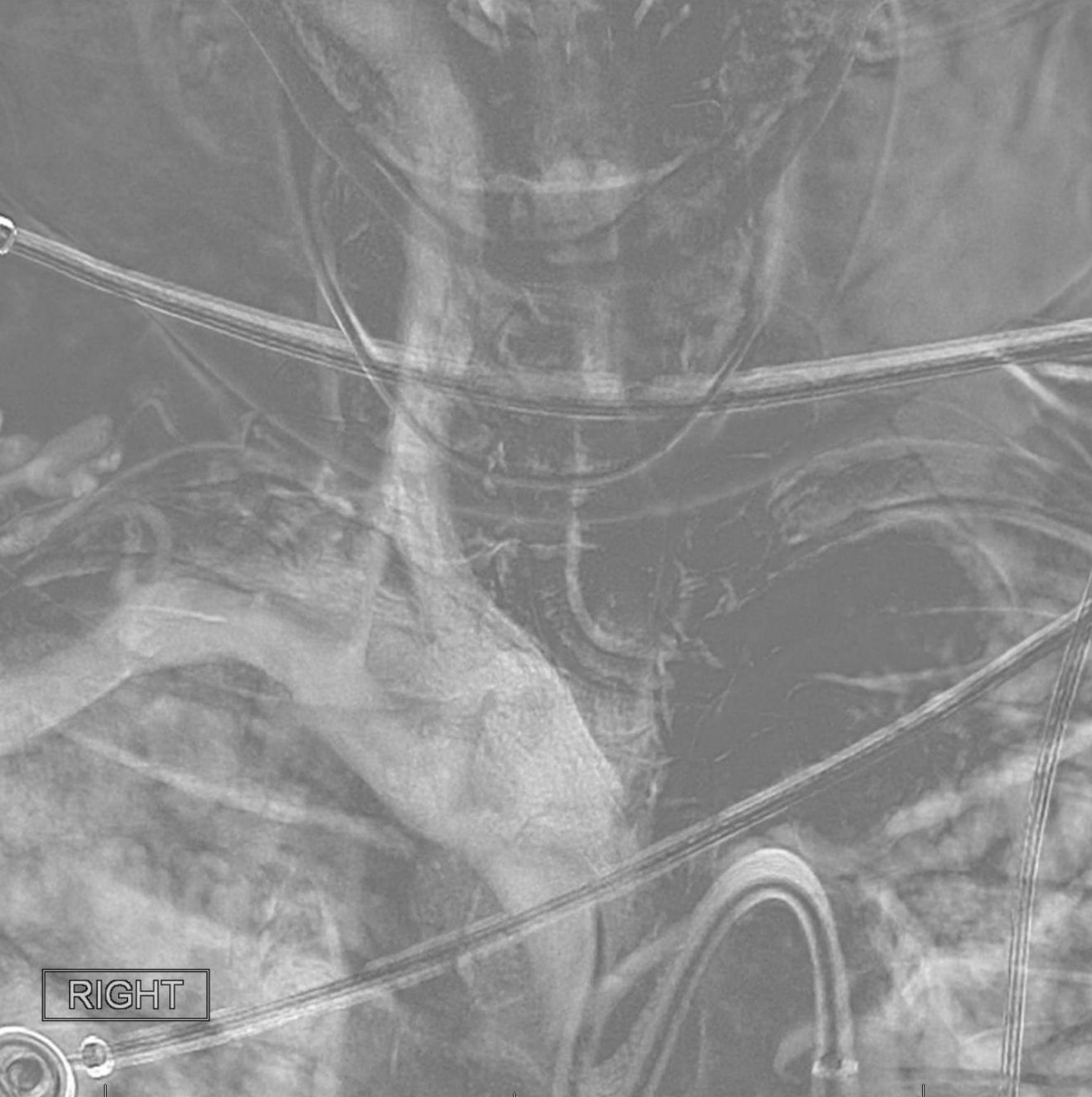

Perfusion Channel





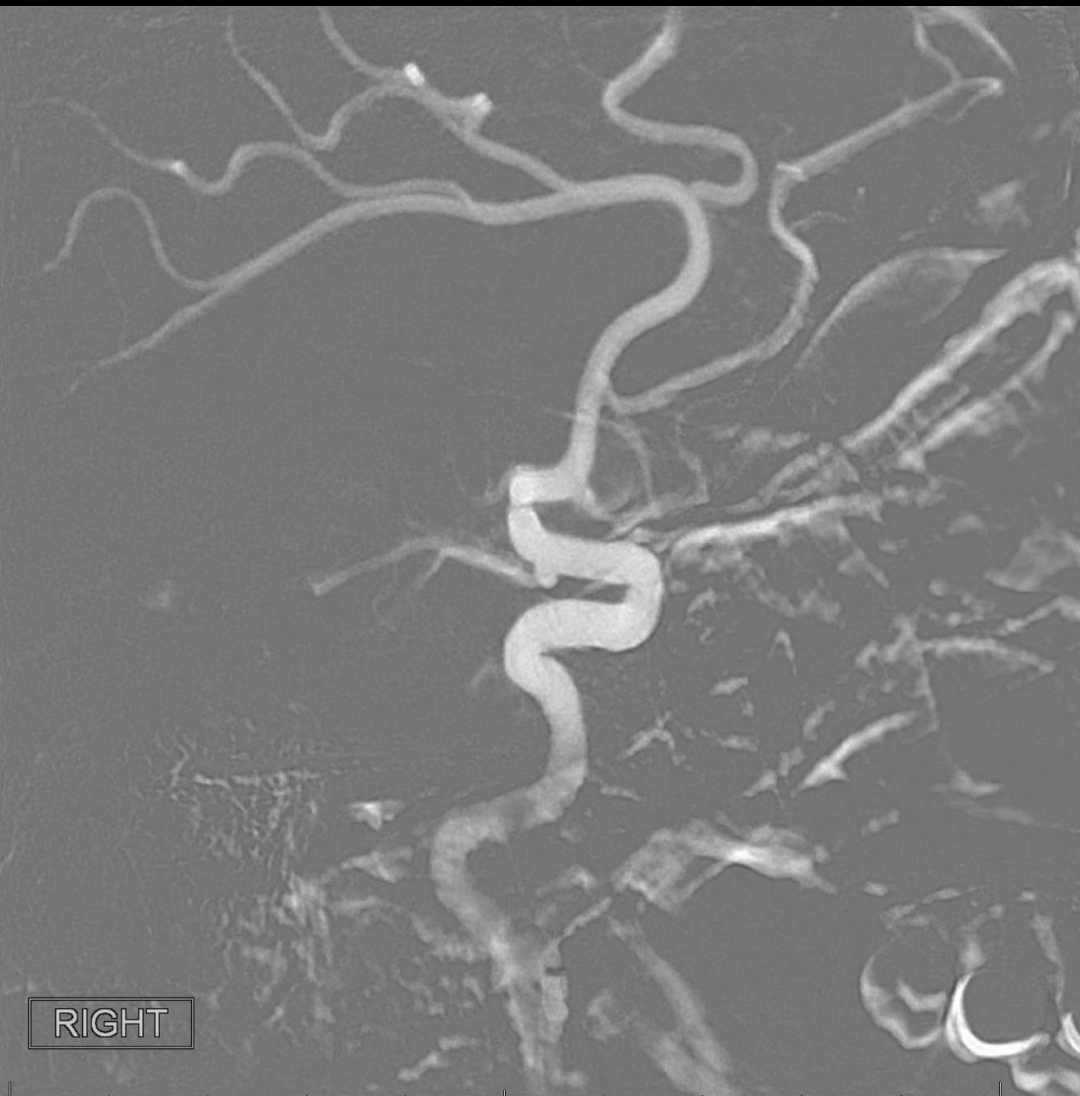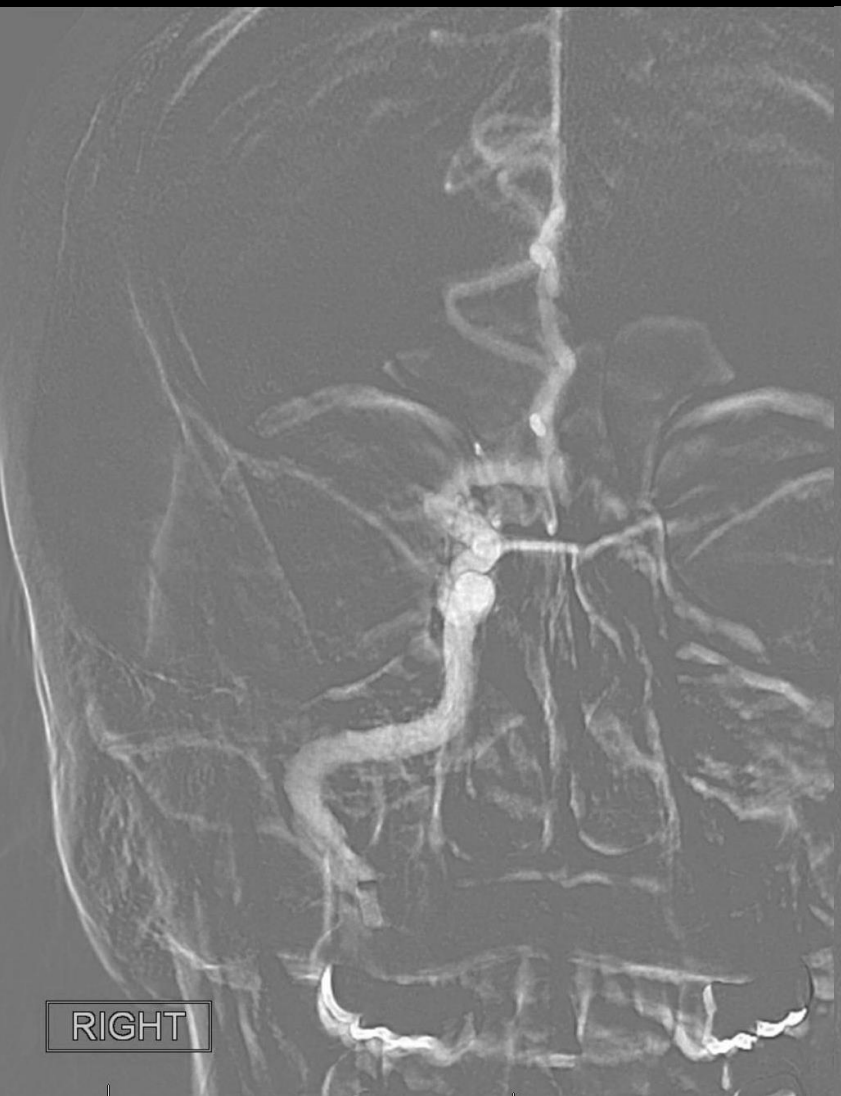Withdrawal



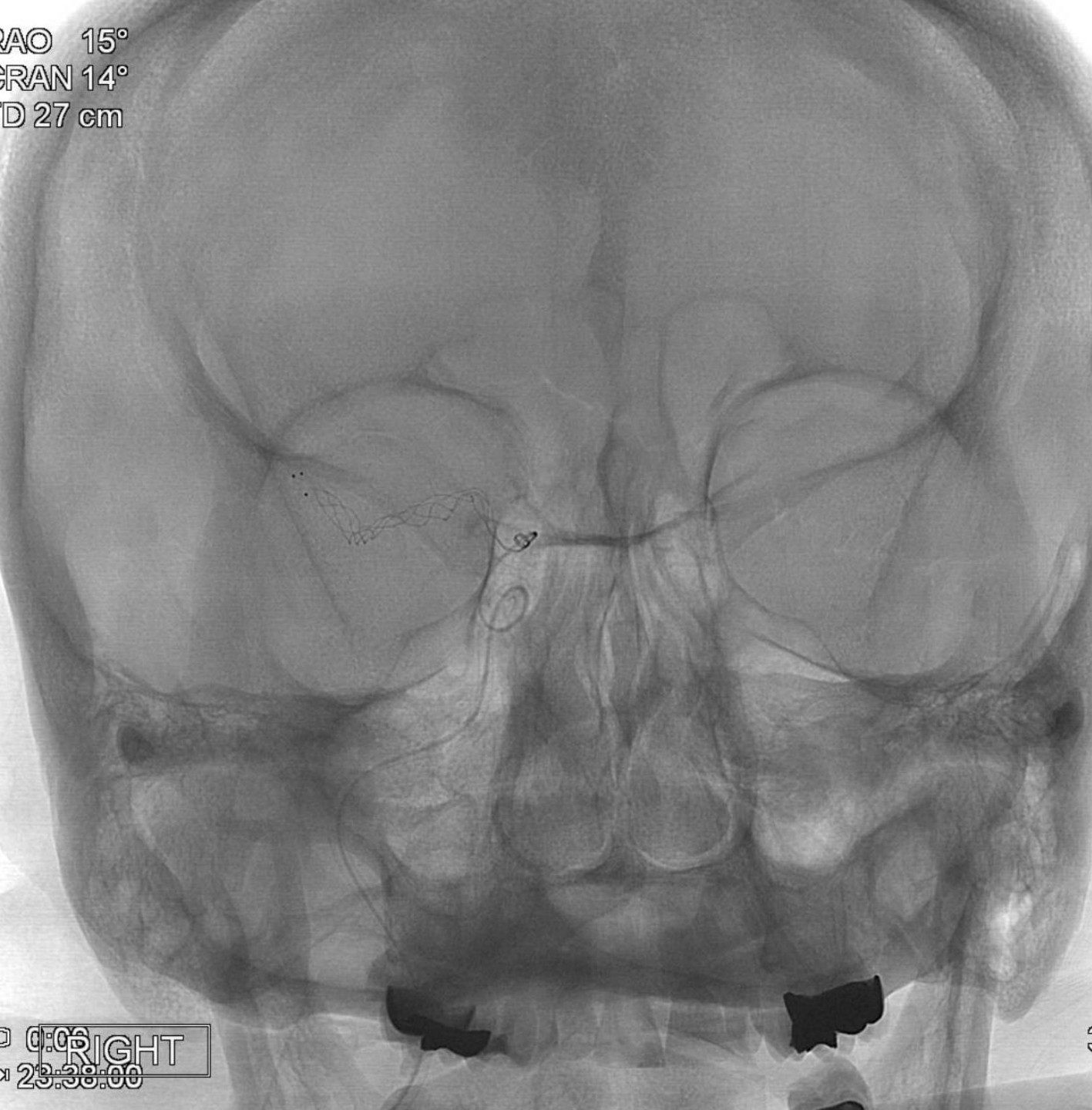
BCG clogged
Removed under
aspiration

RIGHT

Residual M1



AO 15°
RAN 14°
D 27 cm



Trevo 6x25 +
Penumbra 68

RIGHT
23:38:00

Trevo 6x25 + Penumbra 68

RAO 15°
CRAN 14°
FD 15 cm

90°
JD 0°
15 cm

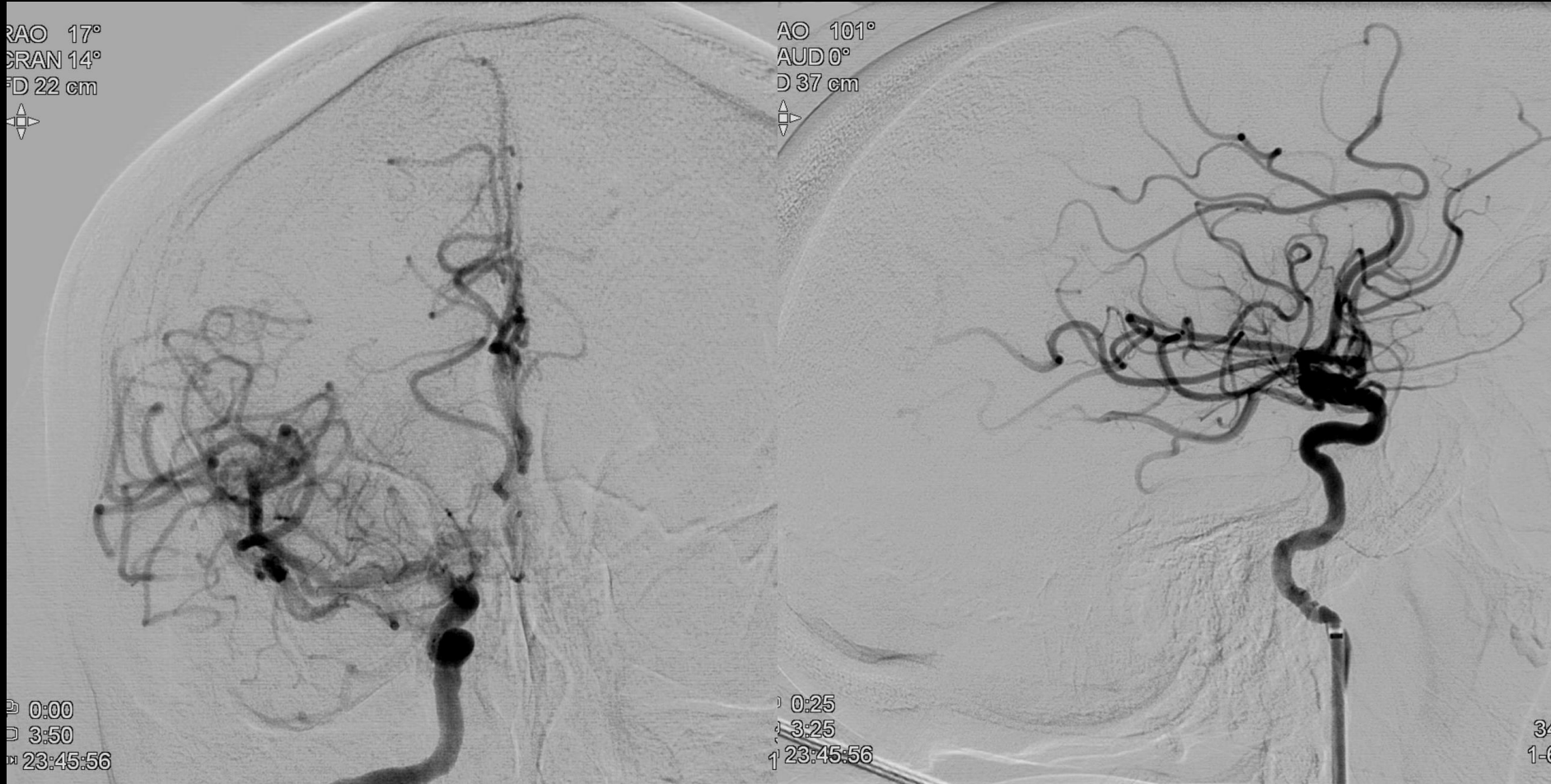


RIGHT
4:53
23:43:49

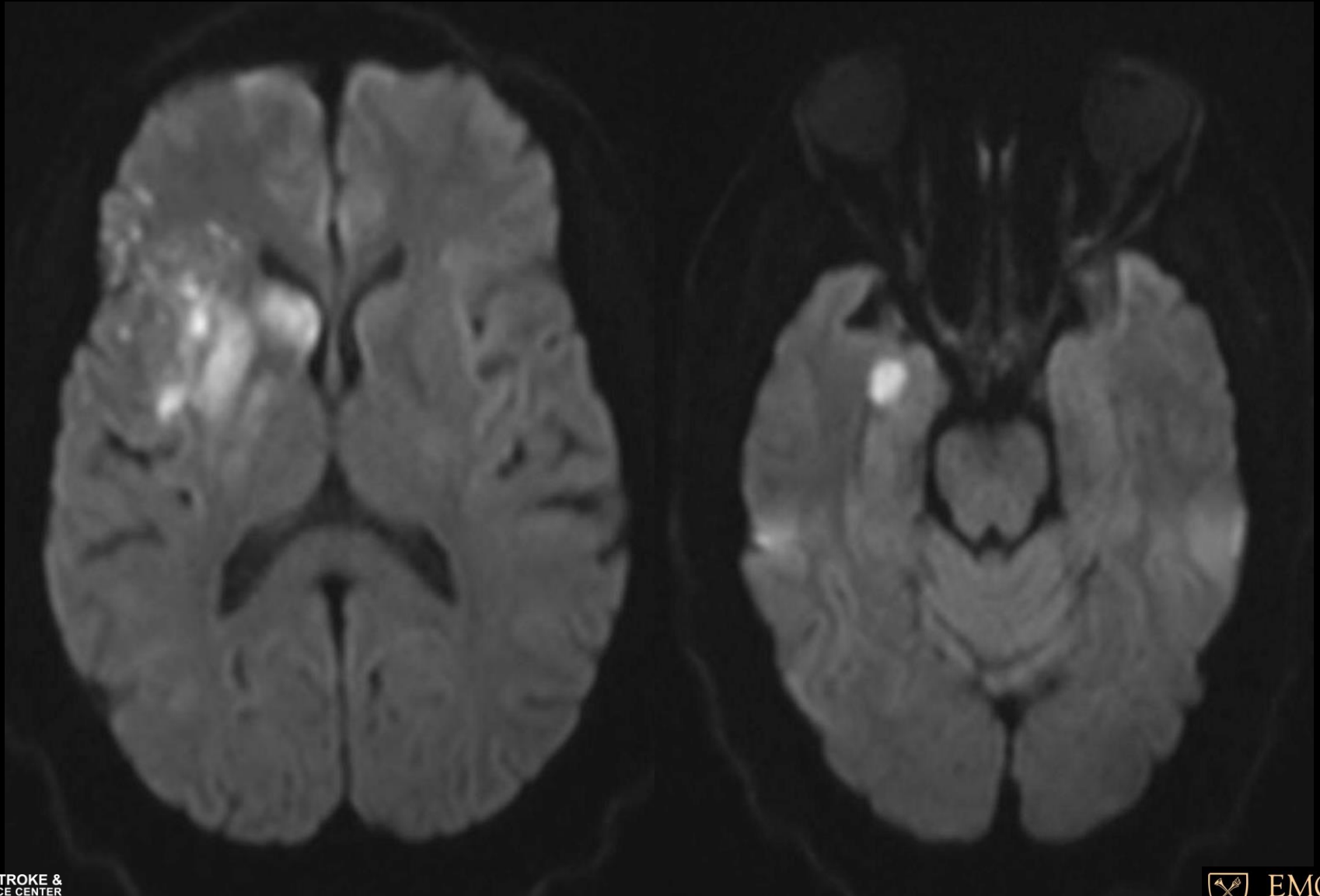
RIGHT
4:53
3:43:49

33
32

Final – TIC13

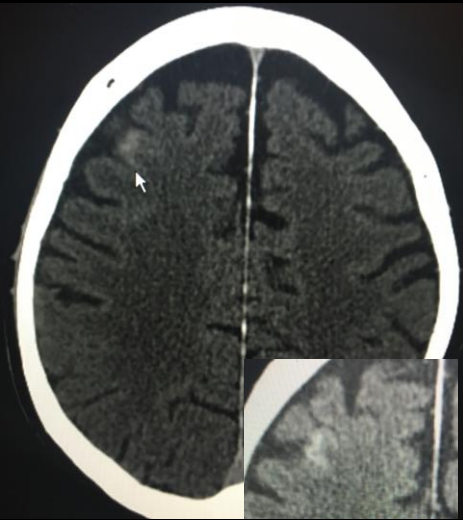


NIHSS 1 @ 24h

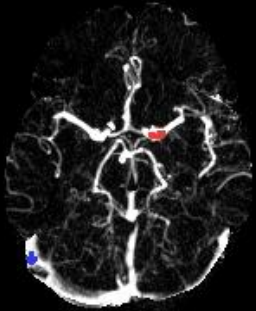
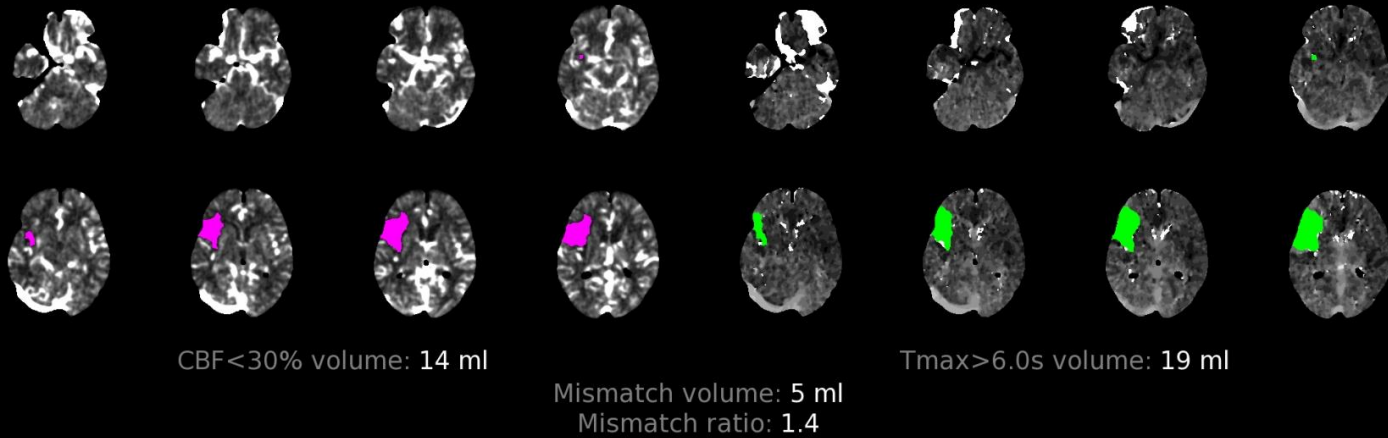


CASE #7

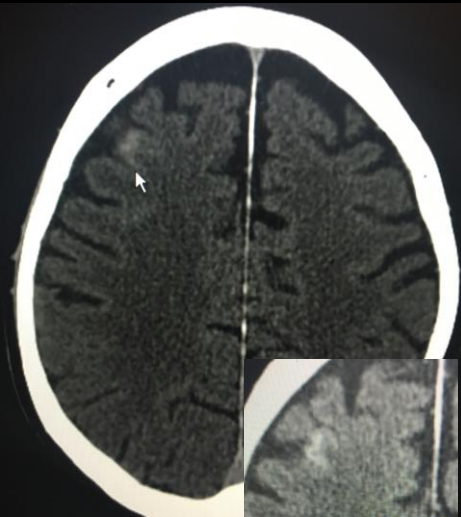62yo. Afib (?xarelto). NIHSS 16. No tpa. 2h out.



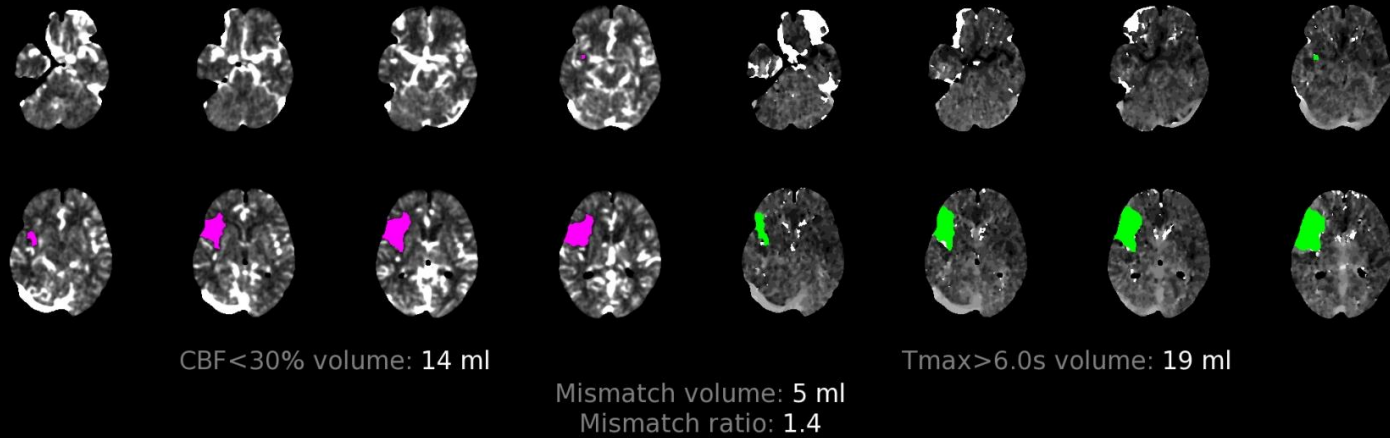
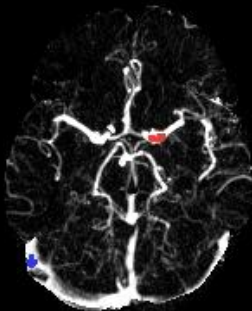
Bolus Time



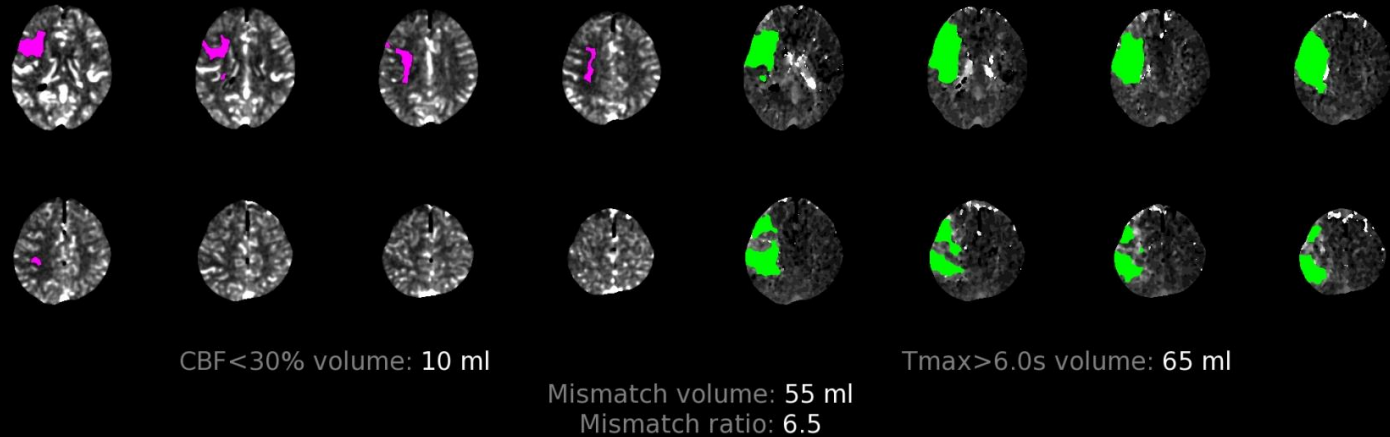
62yo. Afib (?xarelto). NIHSS 16. No tpa.



Bolus Time



Slab 1

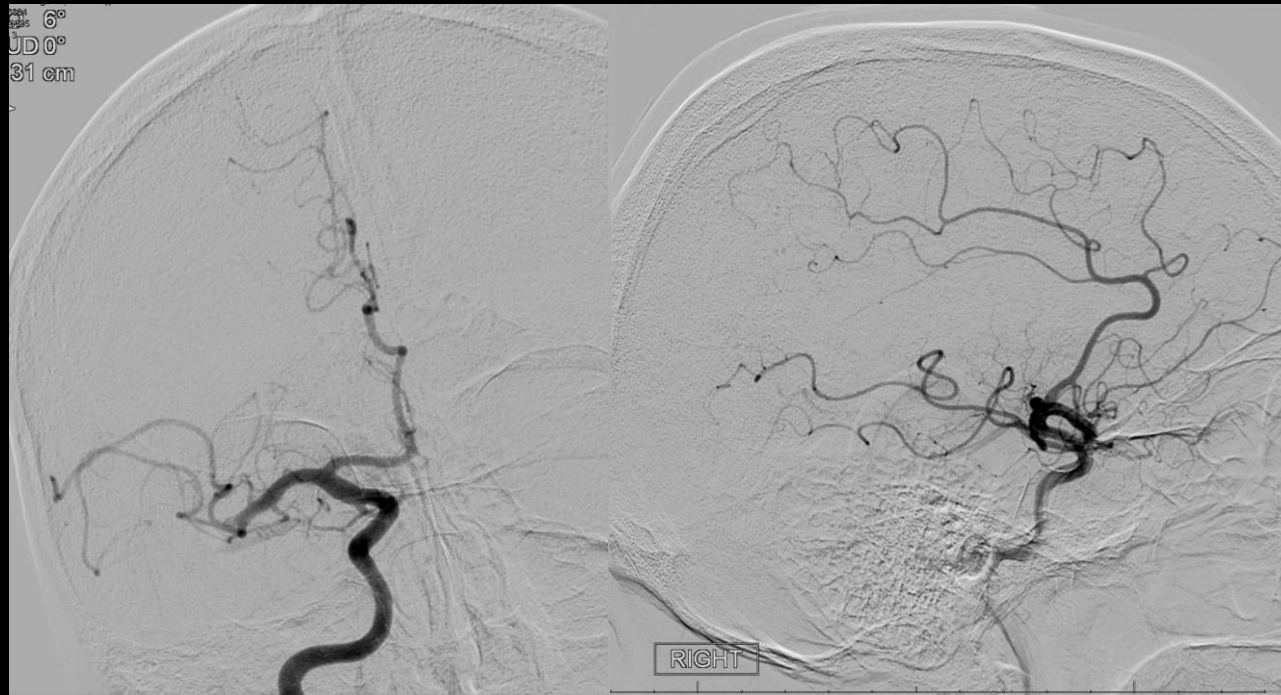

Slab 2

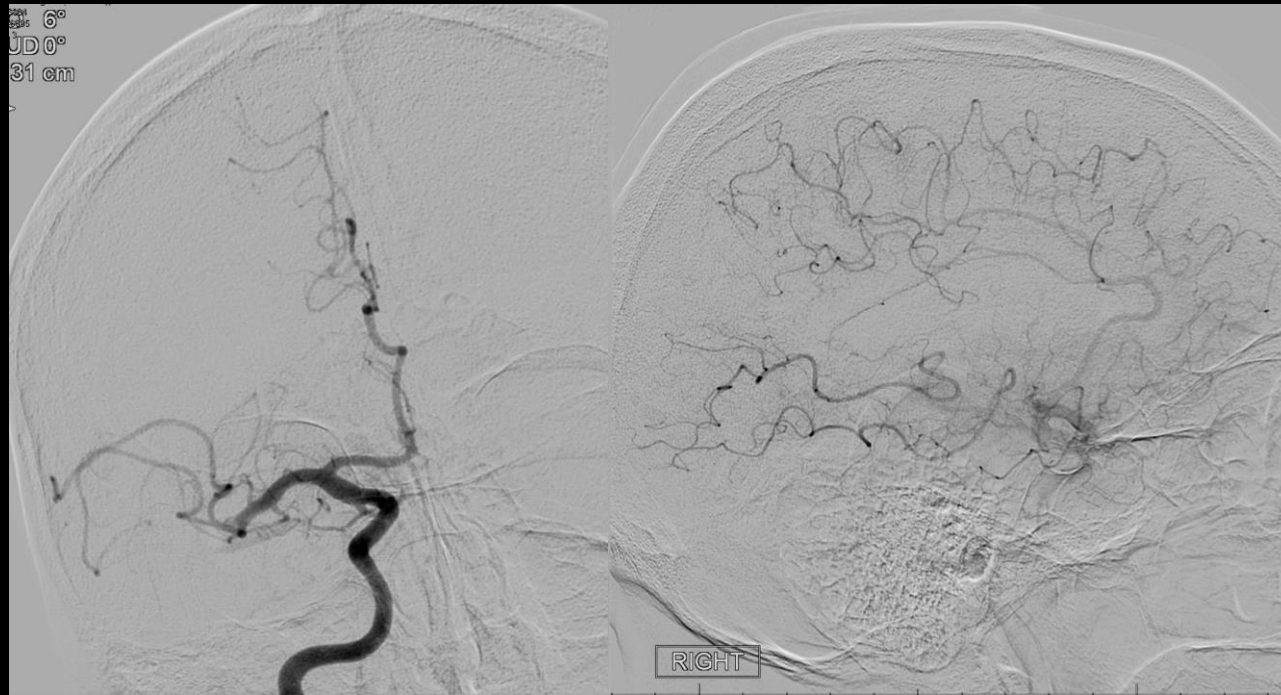Total CBF<30% volume: 24 ml
Total Tmax>6.0s volume: 84 ml
Total Mismatch difference: 60 ml
Total Mismatch ratio: 3.5

iSchemaView^{RAPID}
Not for primary diagnosis.

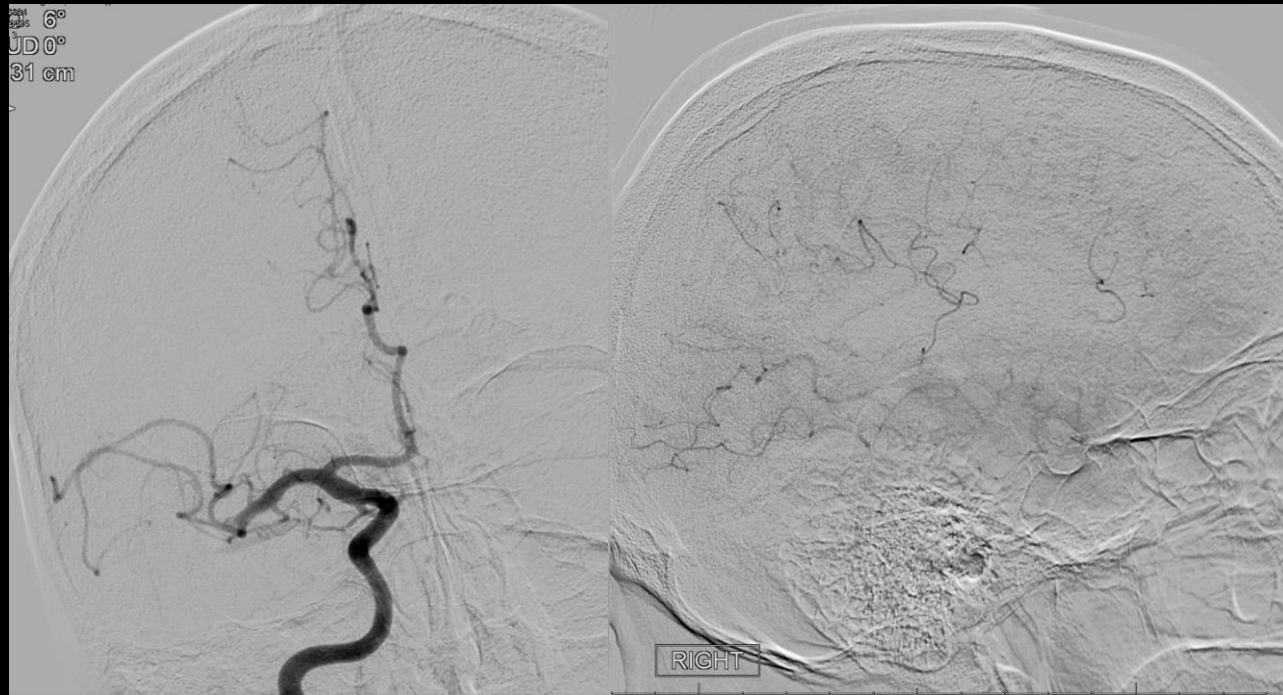
Baseline



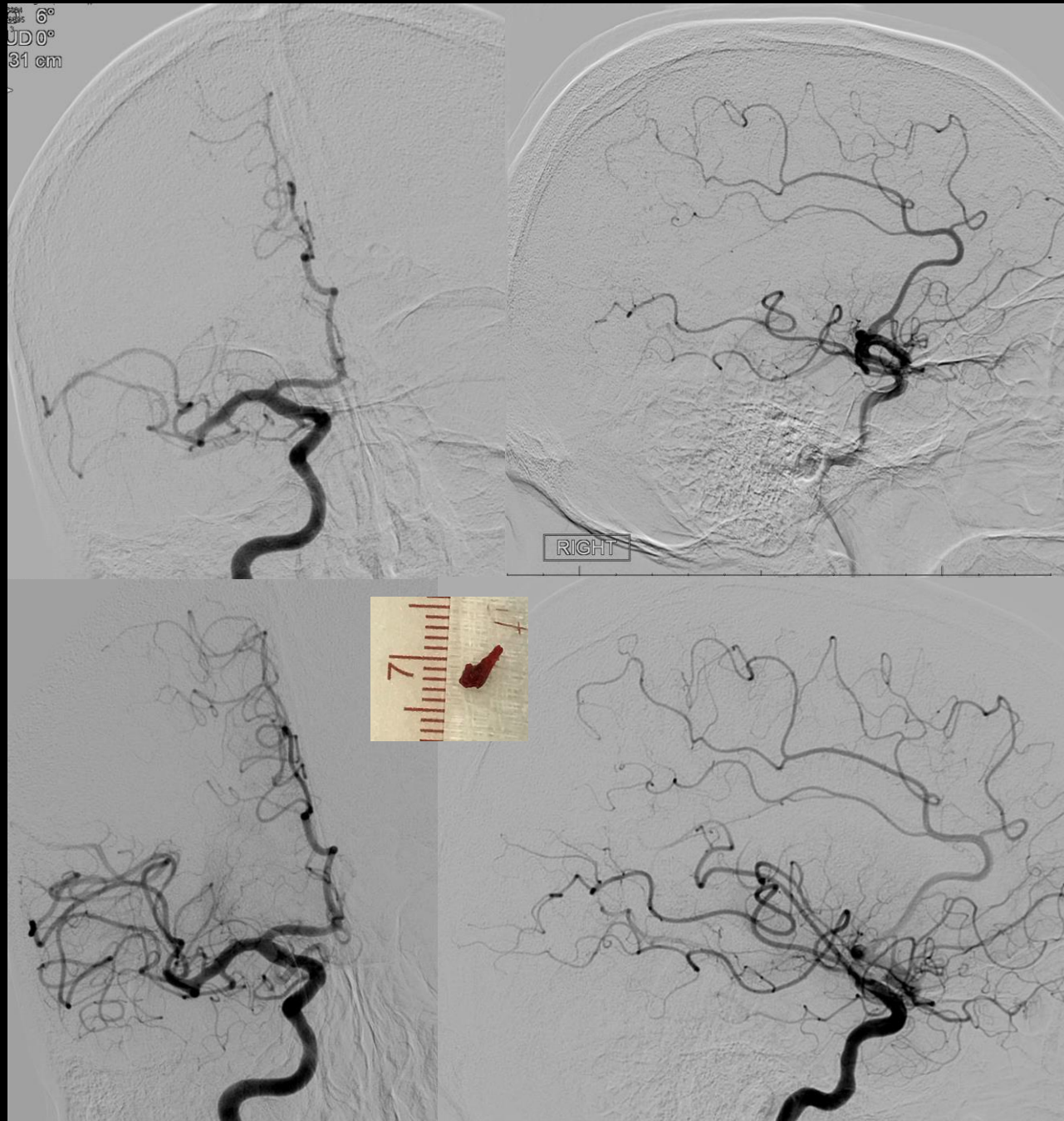
Baseline



Baseline

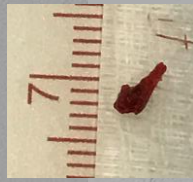


Pre and Post - 1st Pass Solitaire 4x40

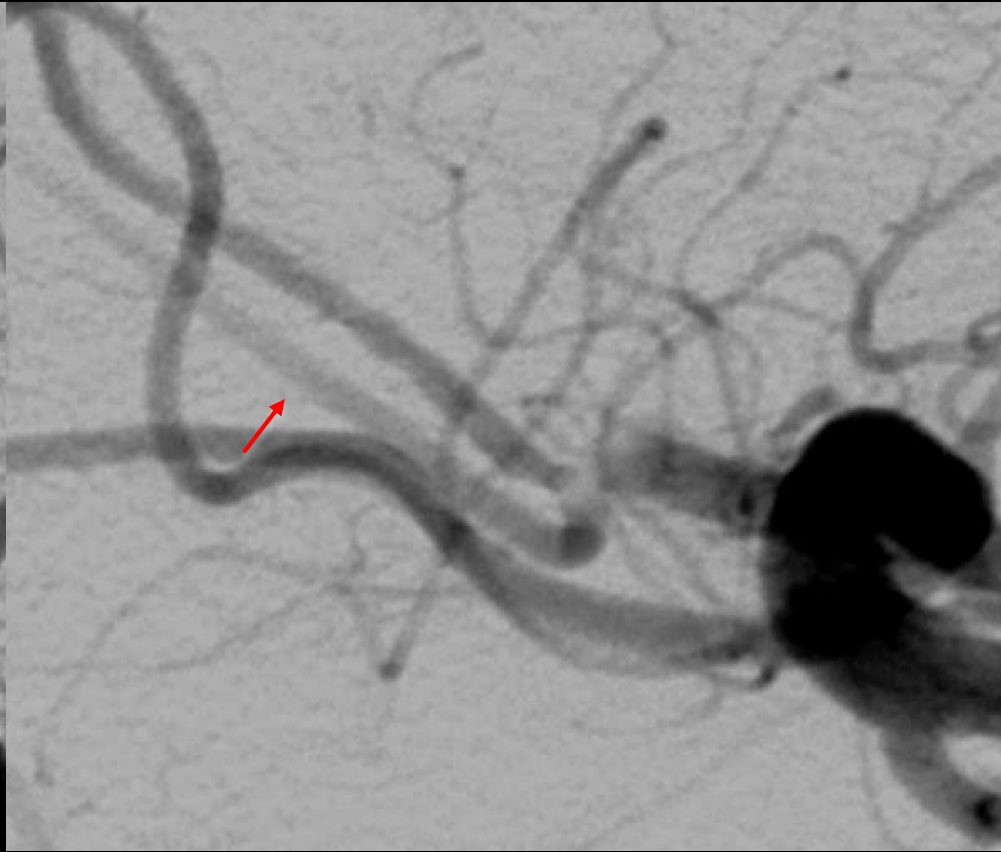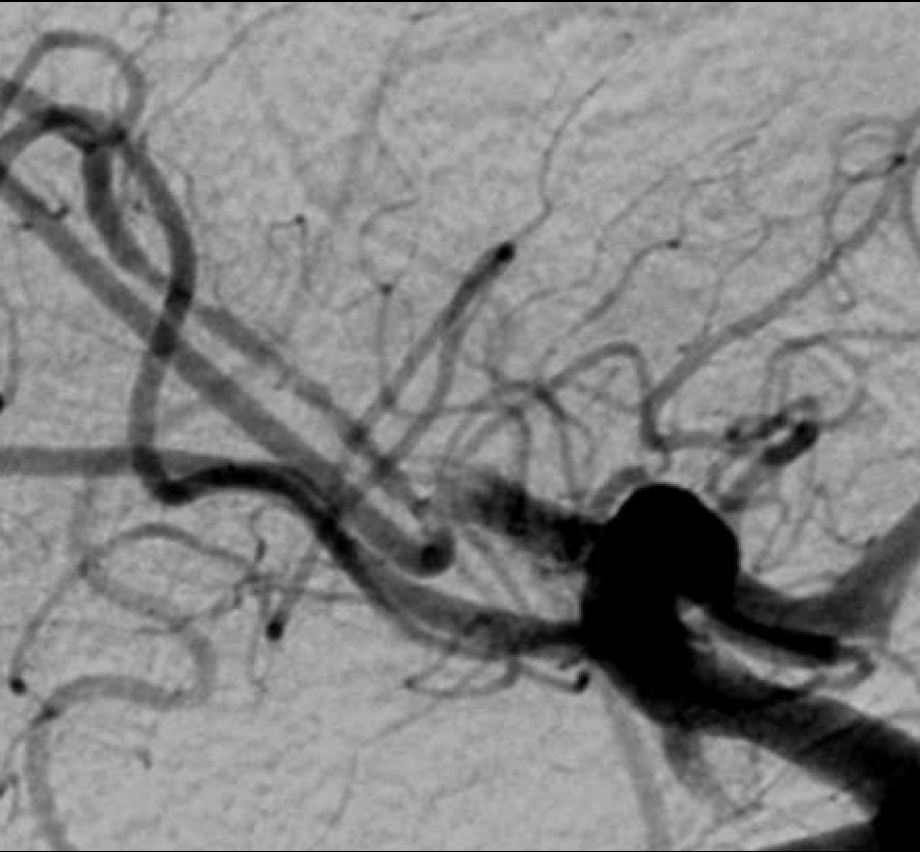


6°
JD 0°
31 cm

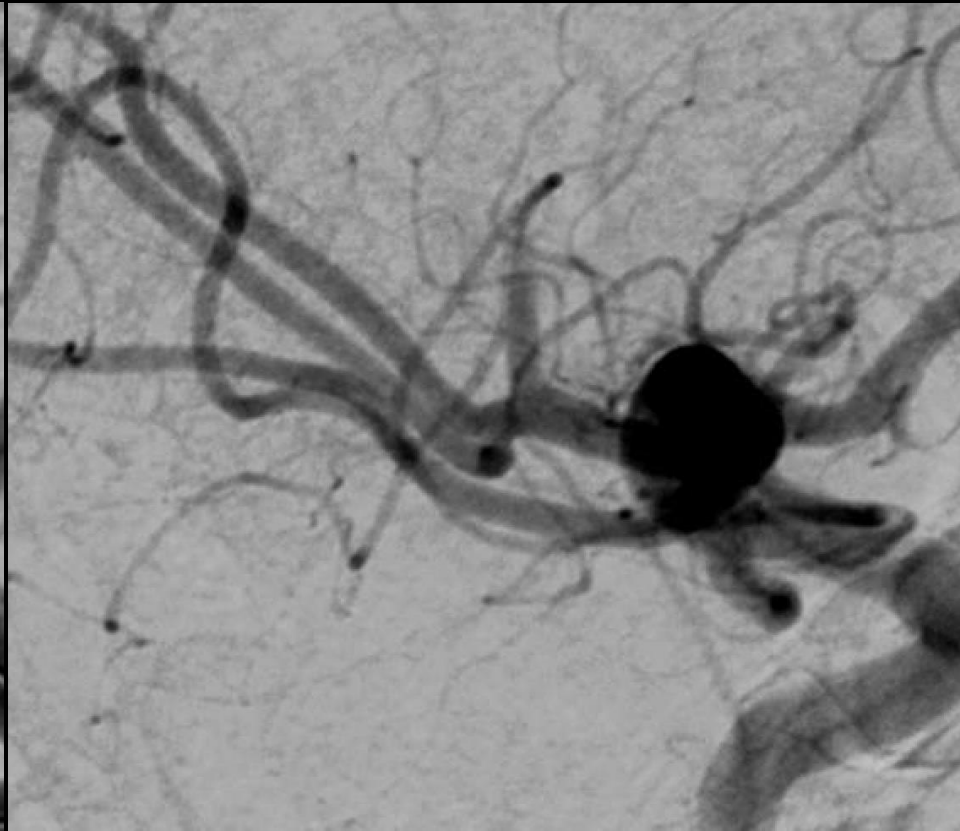
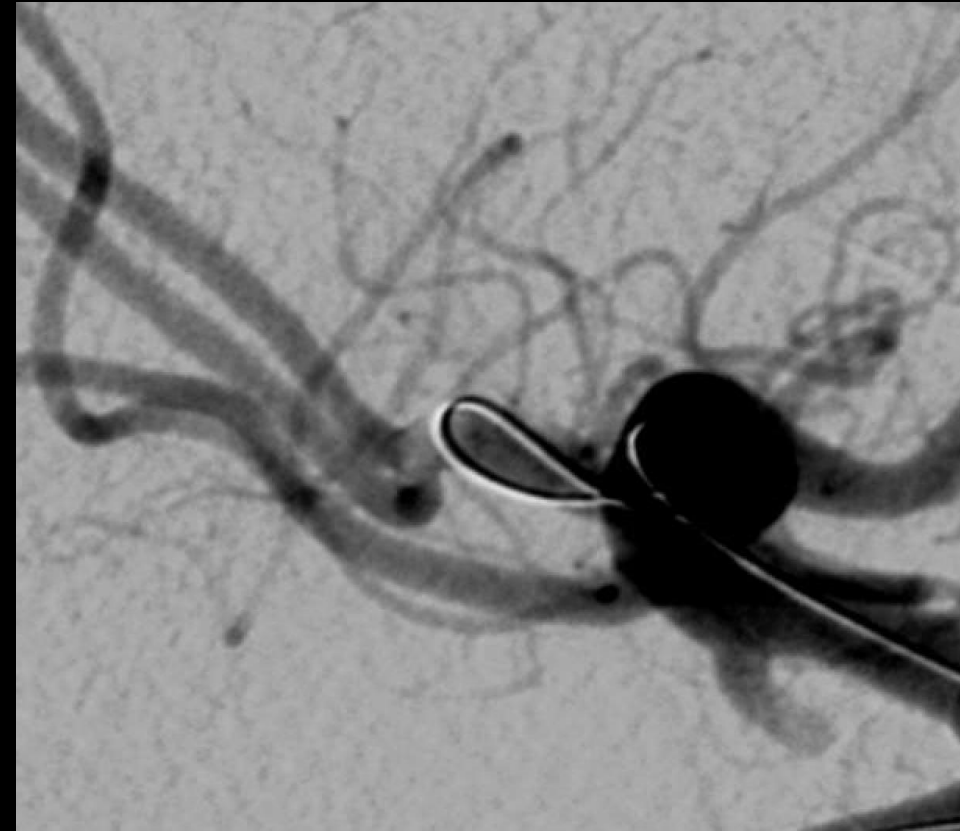RIGHT



3 Min Interval

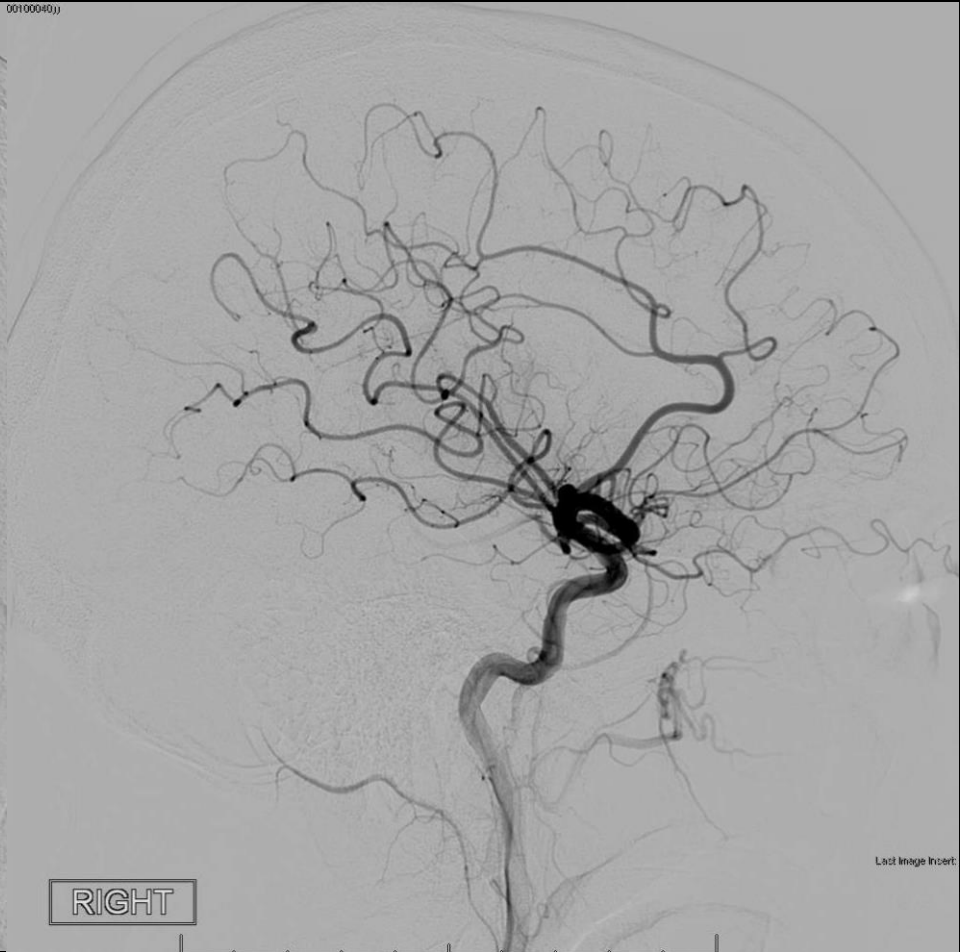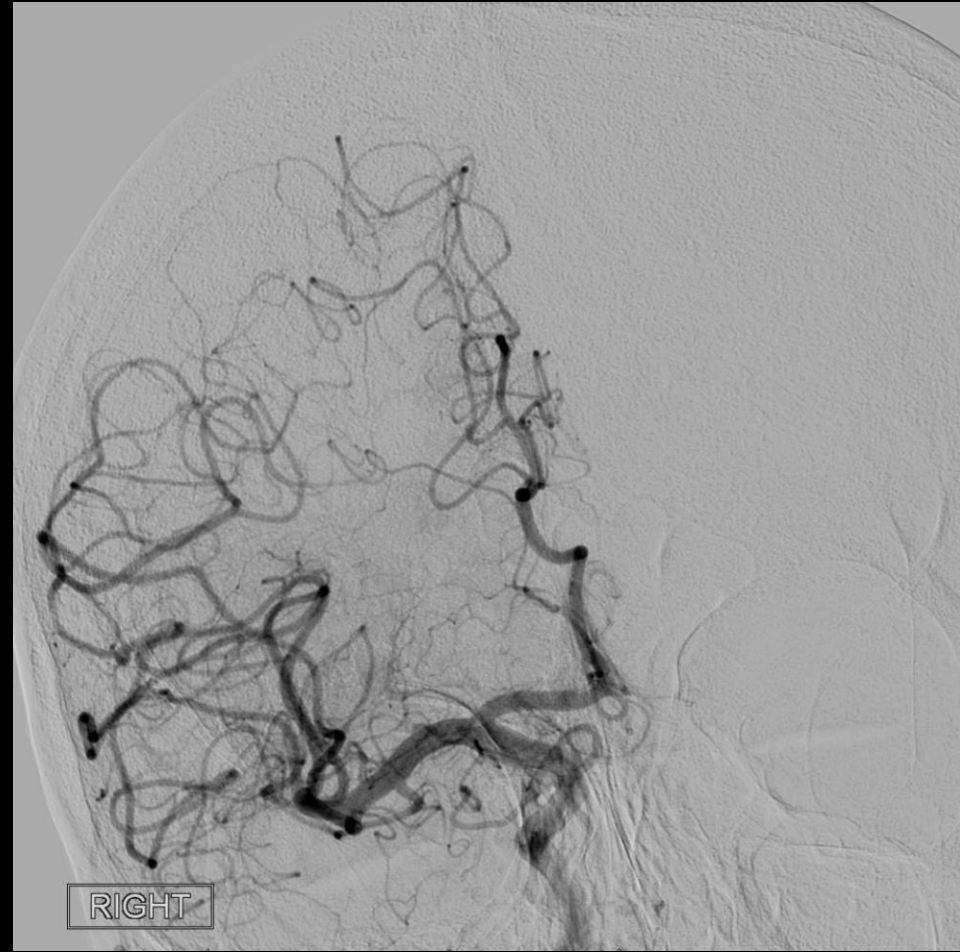


J'ed - microwire

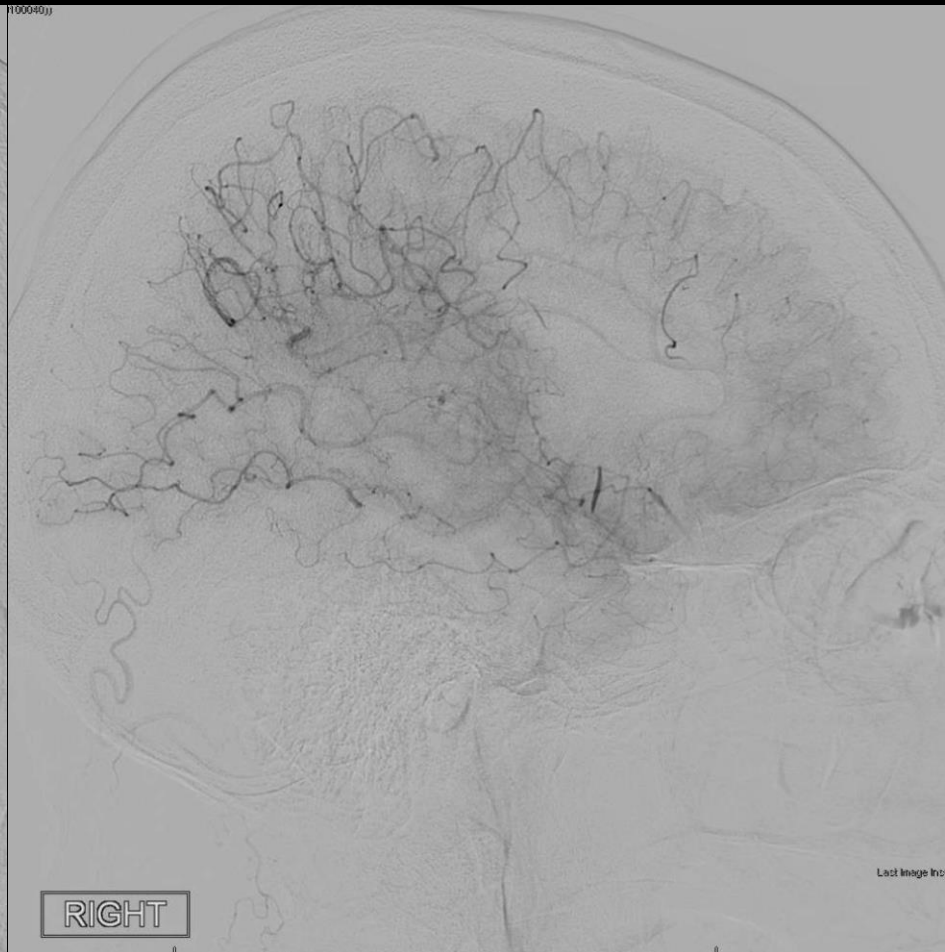
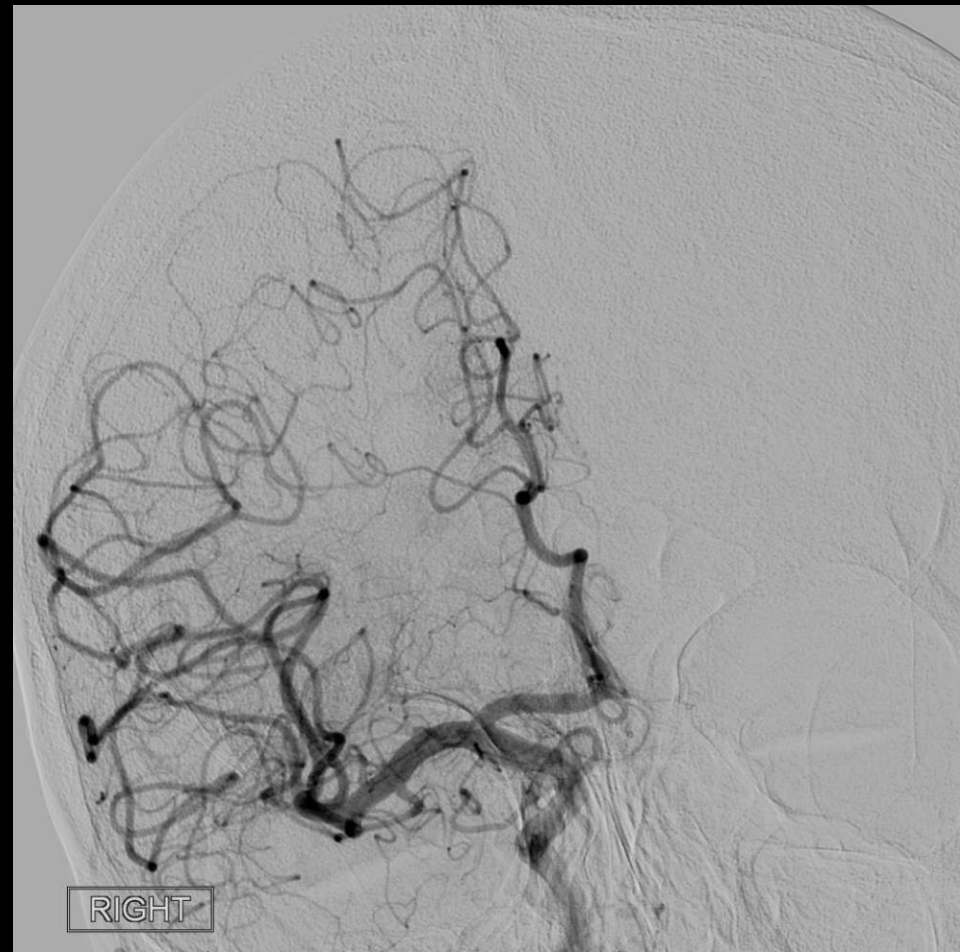

FINAL

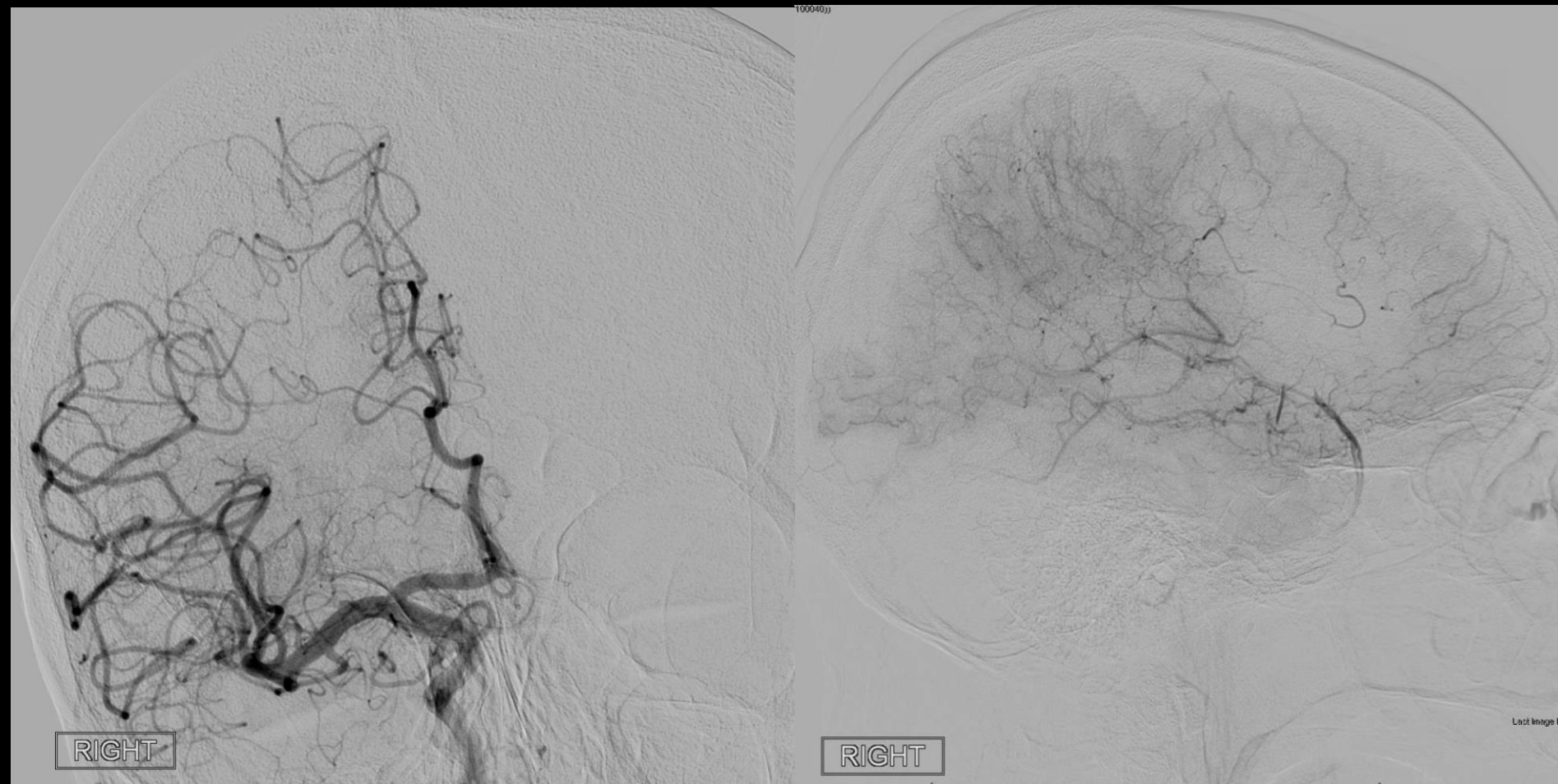00100040j



FINAL



FINAL



NIHSS 5 Immediately After the Procedure

