

Dural sinus compartments in DAVS

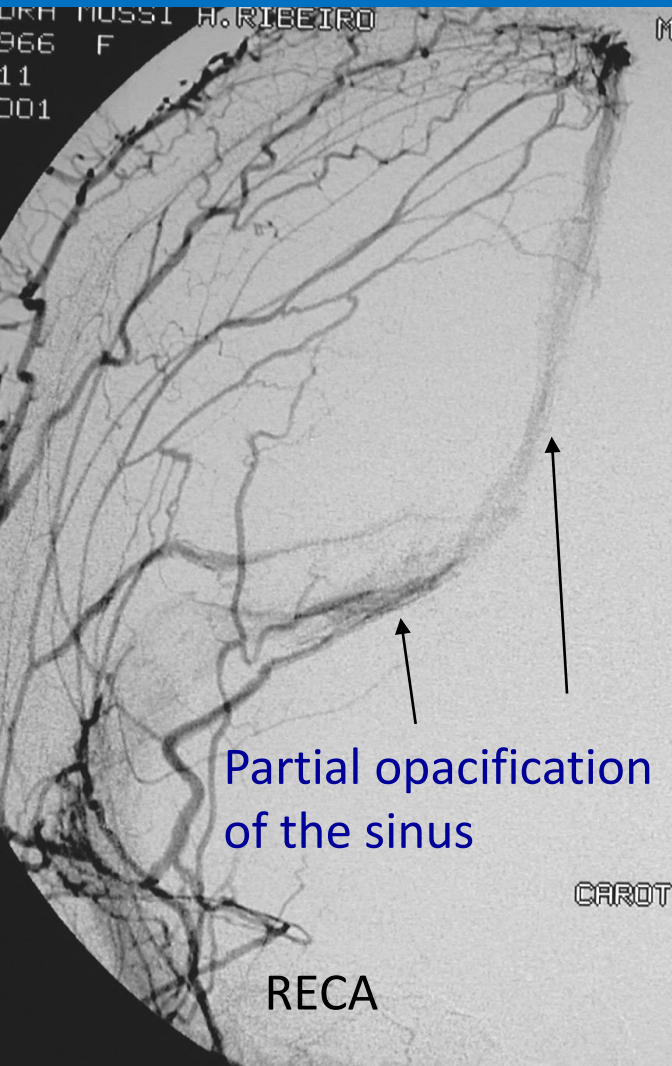
How identify the compartment?

- Partial opacification of the sinus
- Non opacified area into the sinus
- Superposition of arterial and venous phases
- Injection into the compartment (superposition with venous brain phase)

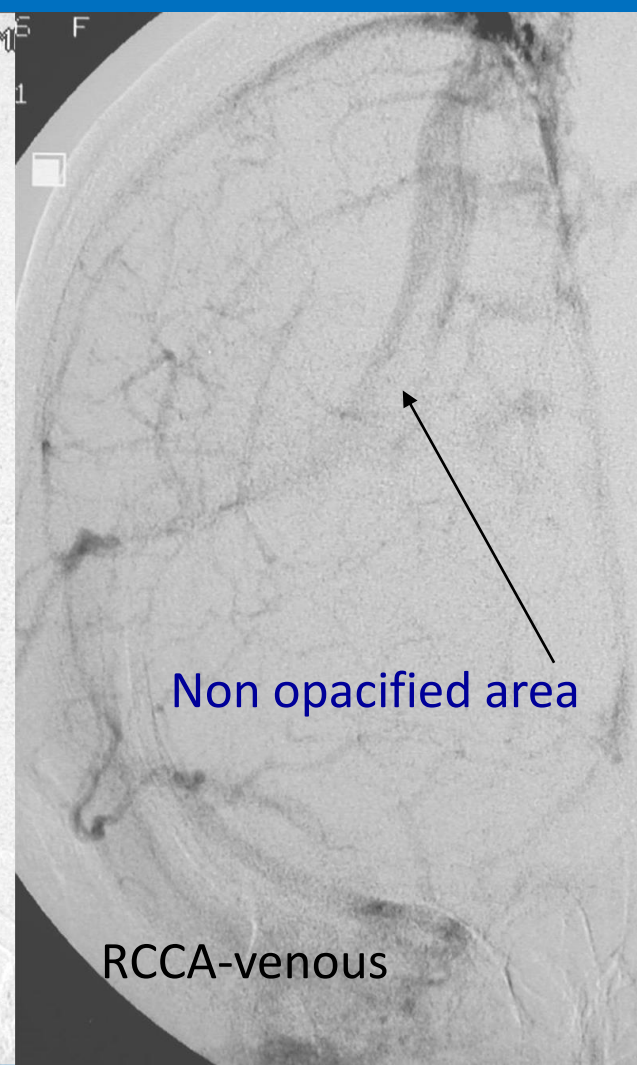
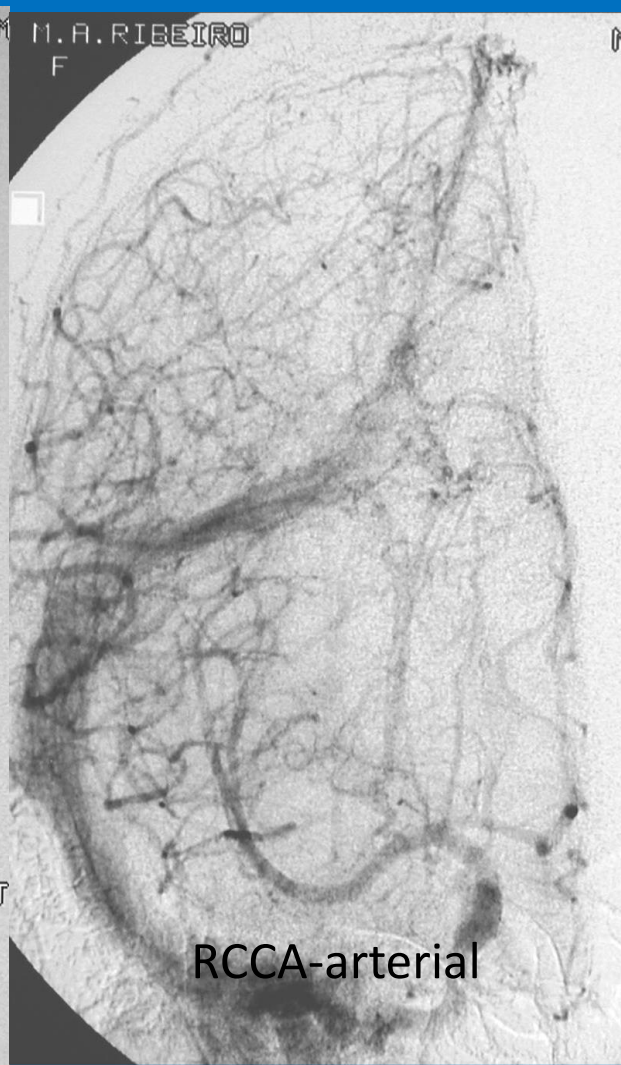
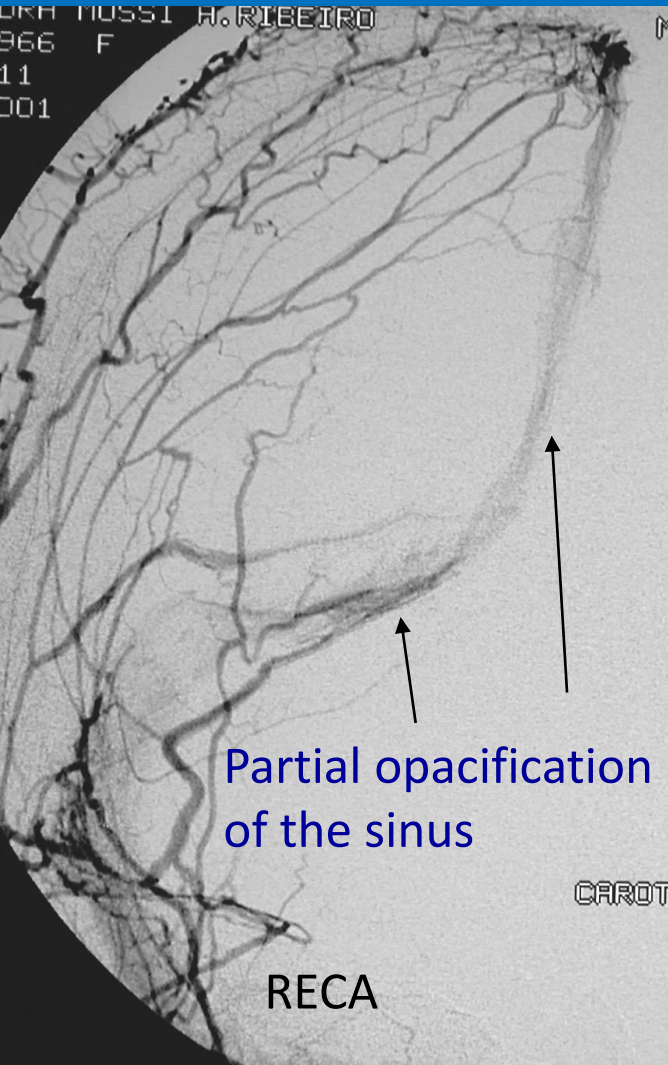
Ronie Leo Piske, MD, PhD

Hospital Beneficiencia Portuguesa de São Paulo, Brazil

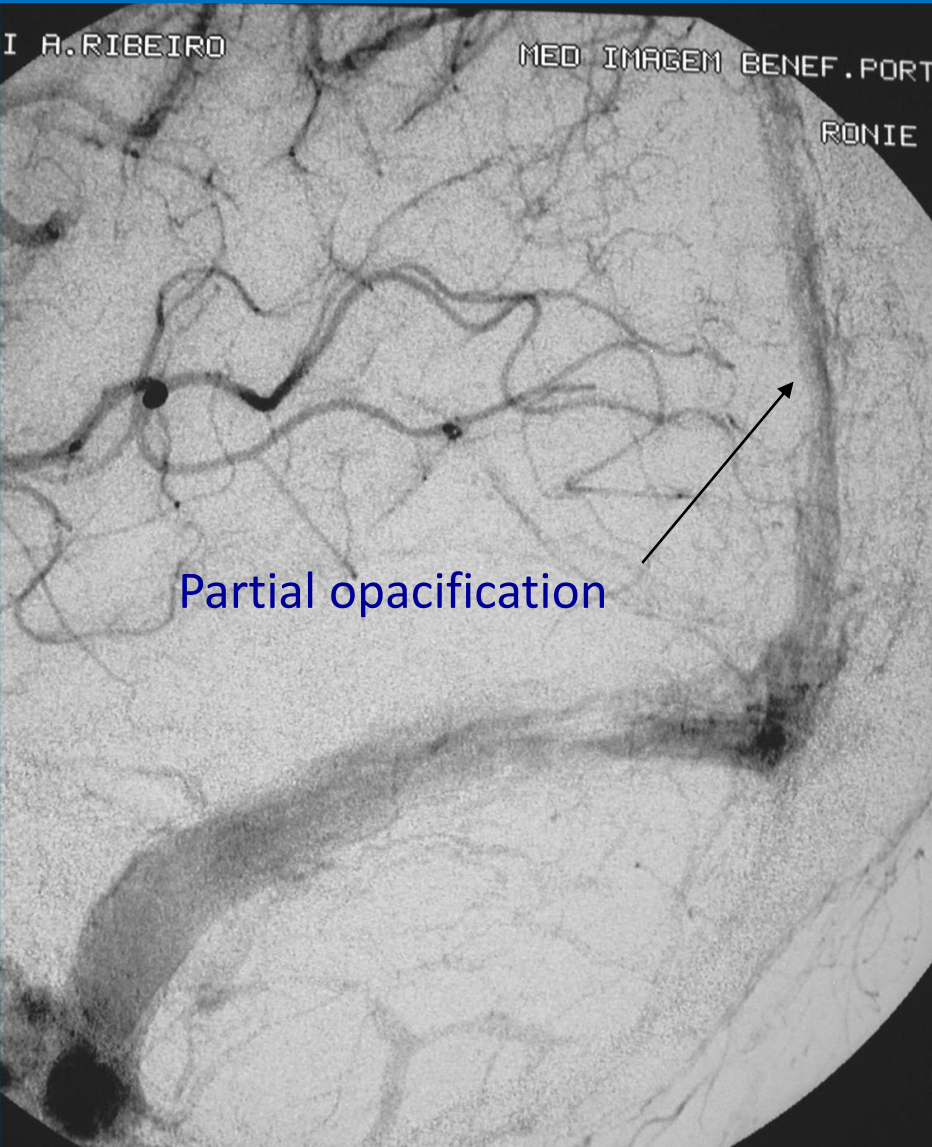
Septation into the SSS with DAVF



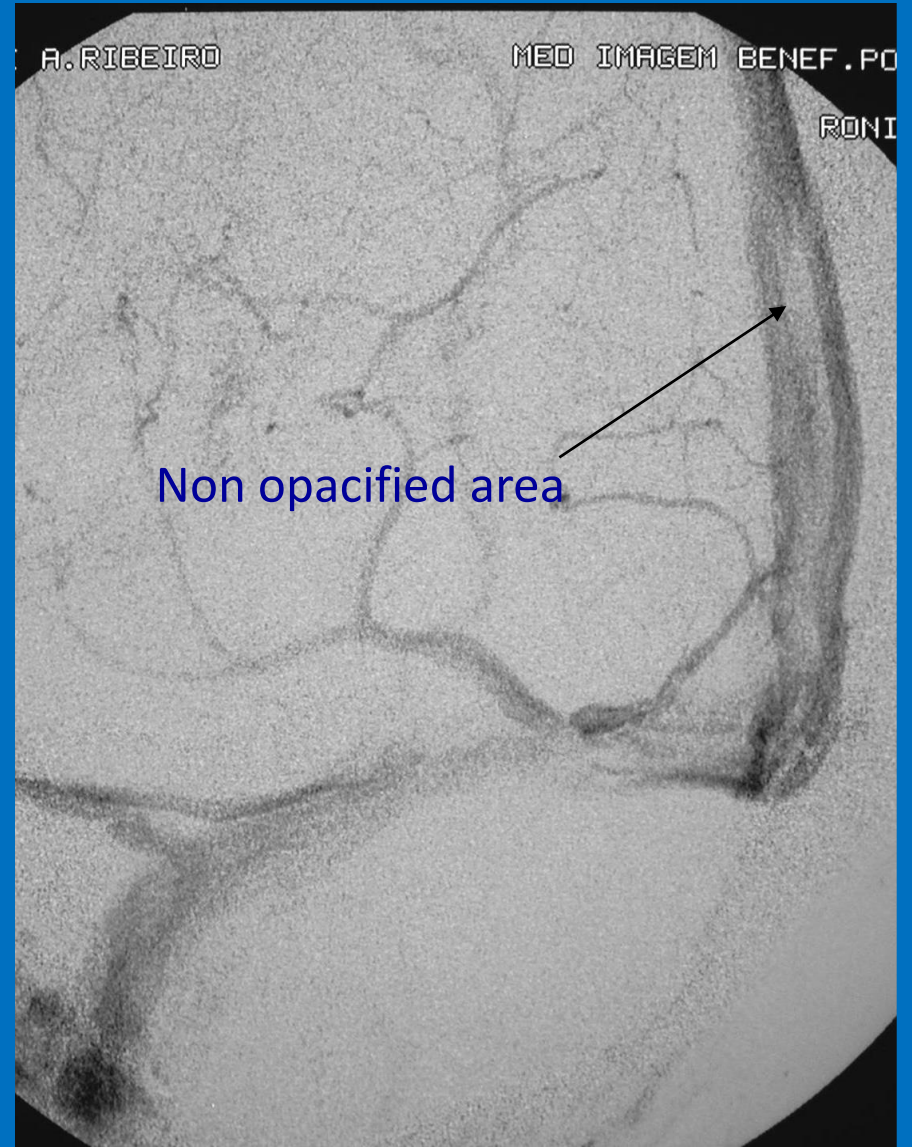
Septation into the SSS with DAVF



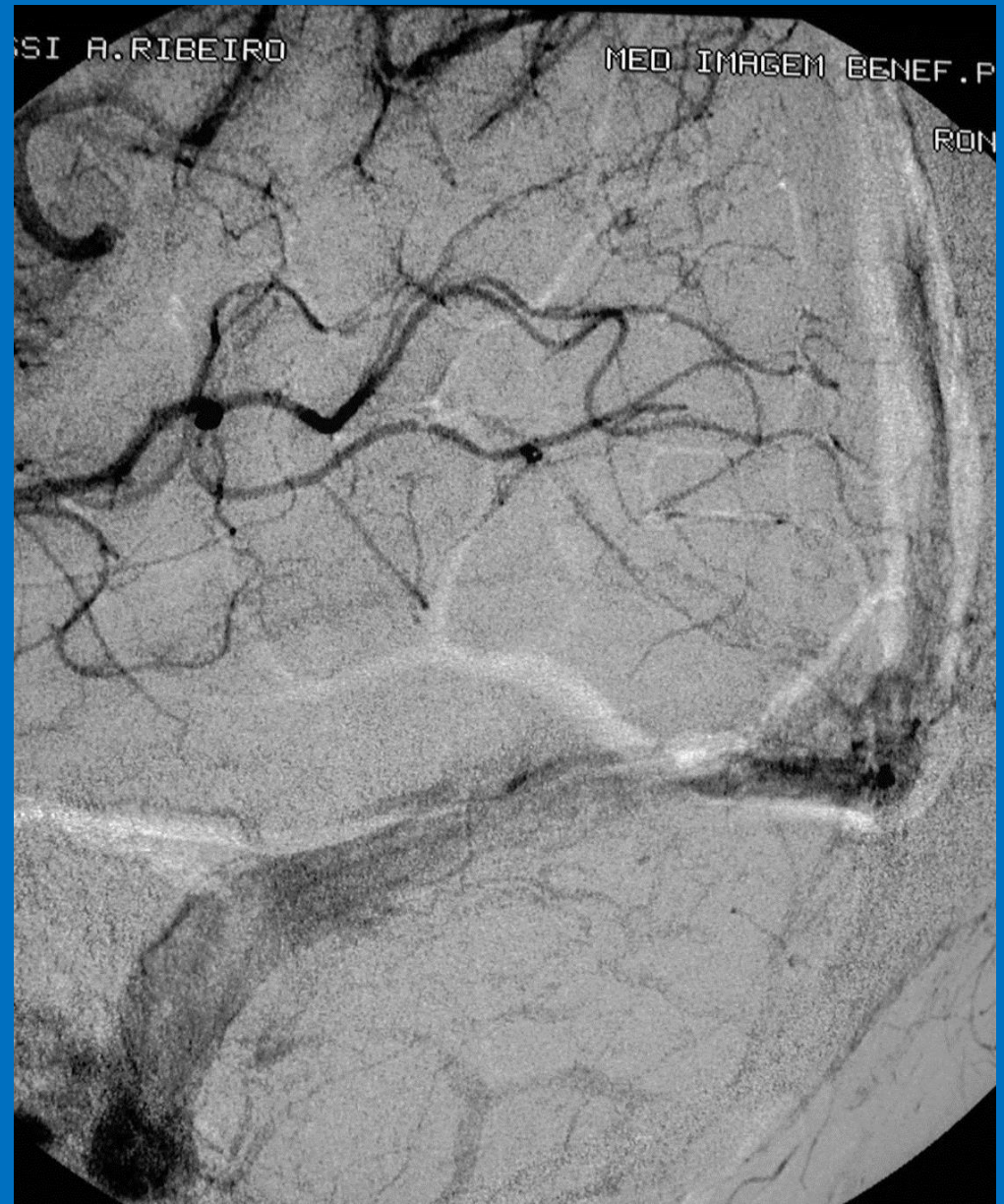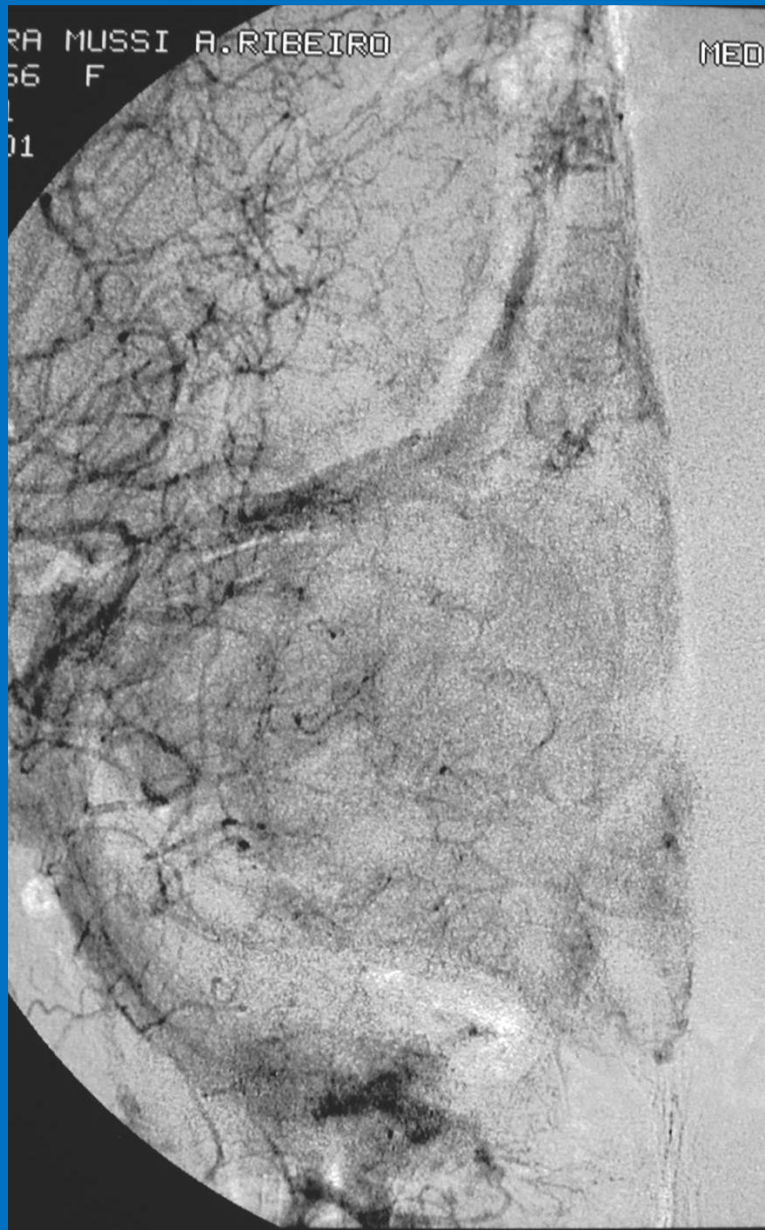
RPC – arterial phase



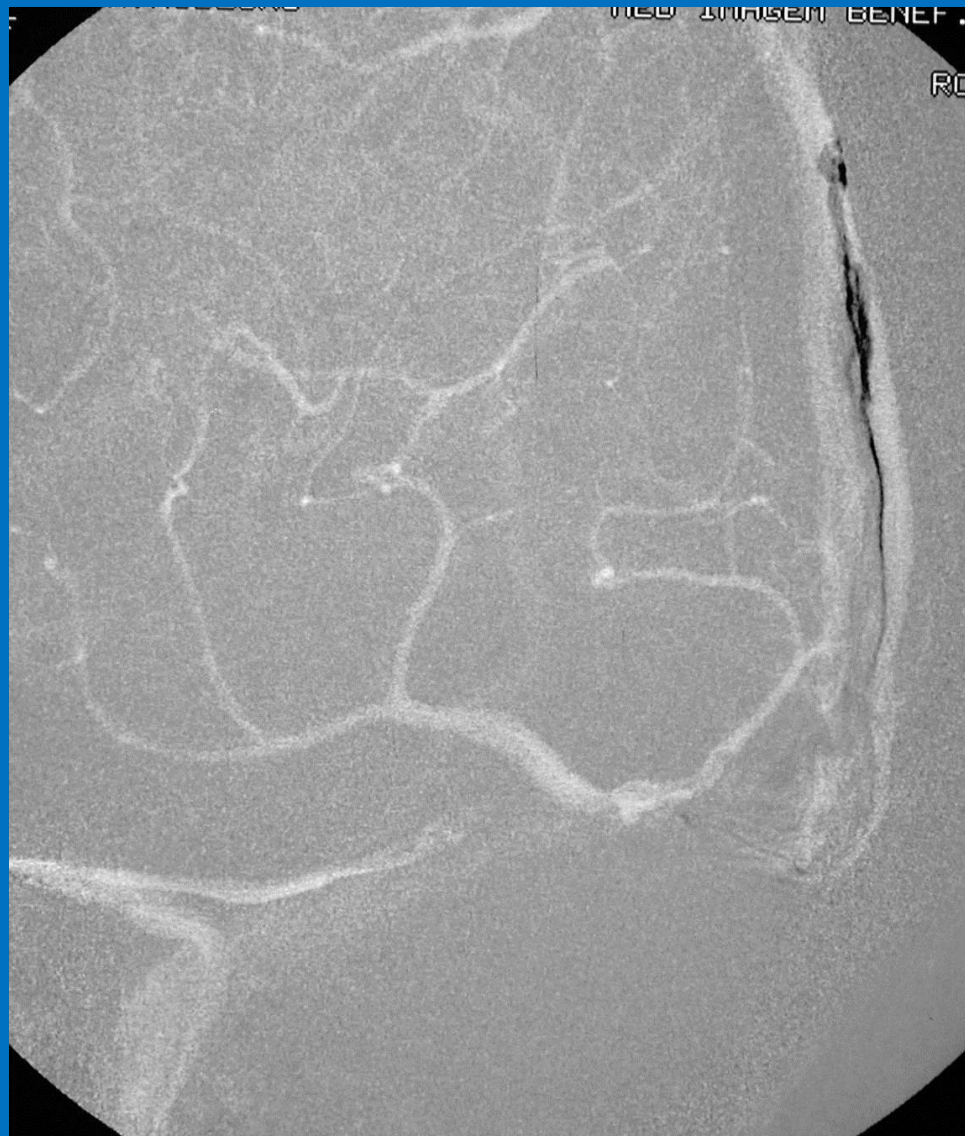
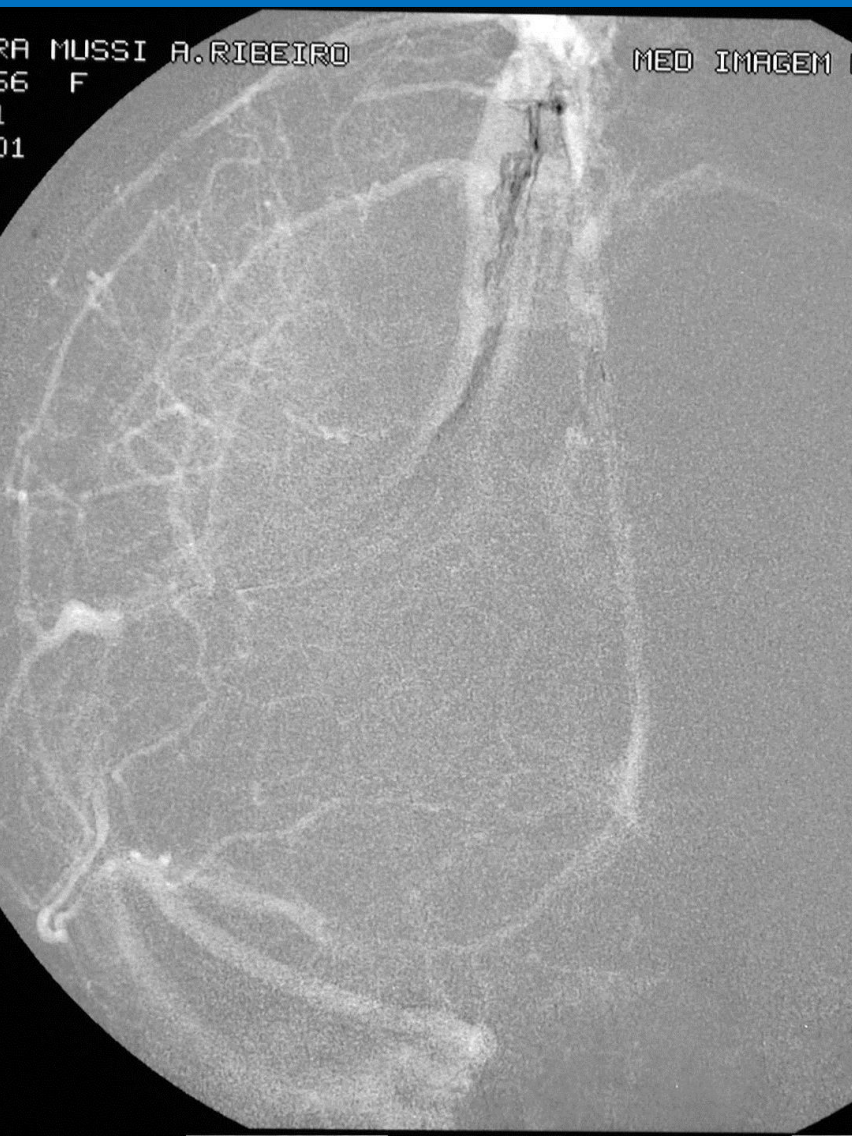
Venous phase



Superposition of arterial and venous phases



Injection into the septation during the RICA venous phase



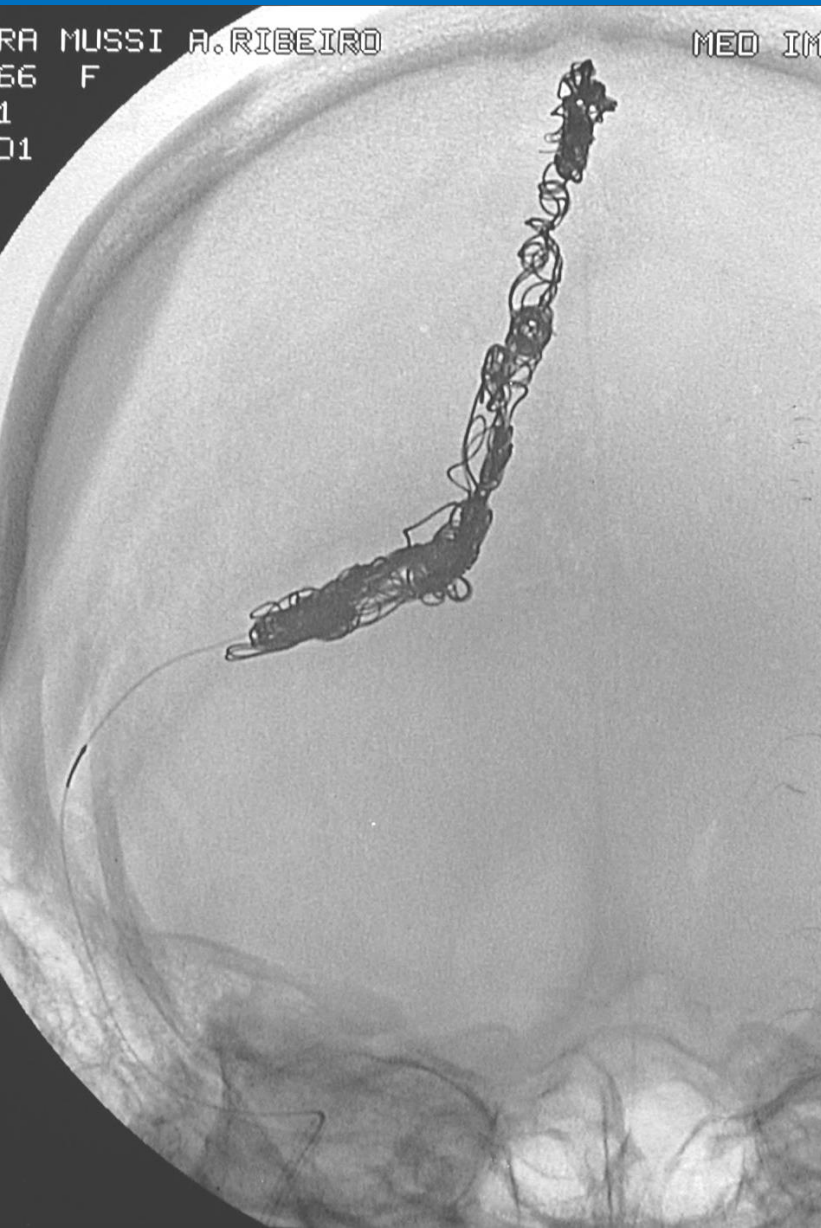RA MUSSI A. RIBEIRO

66 F

1

01

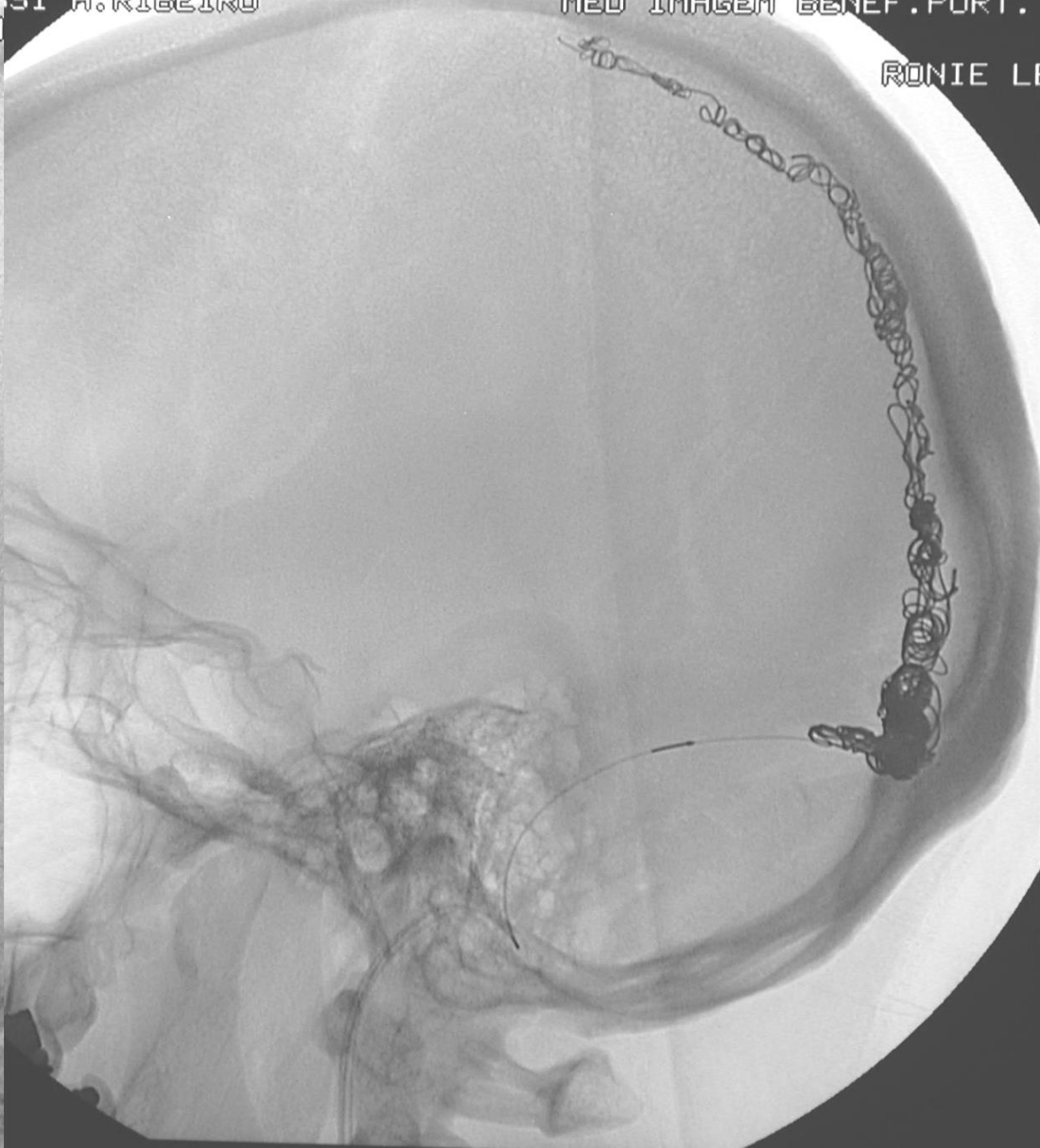MED IM



SI A. RIBEIRO

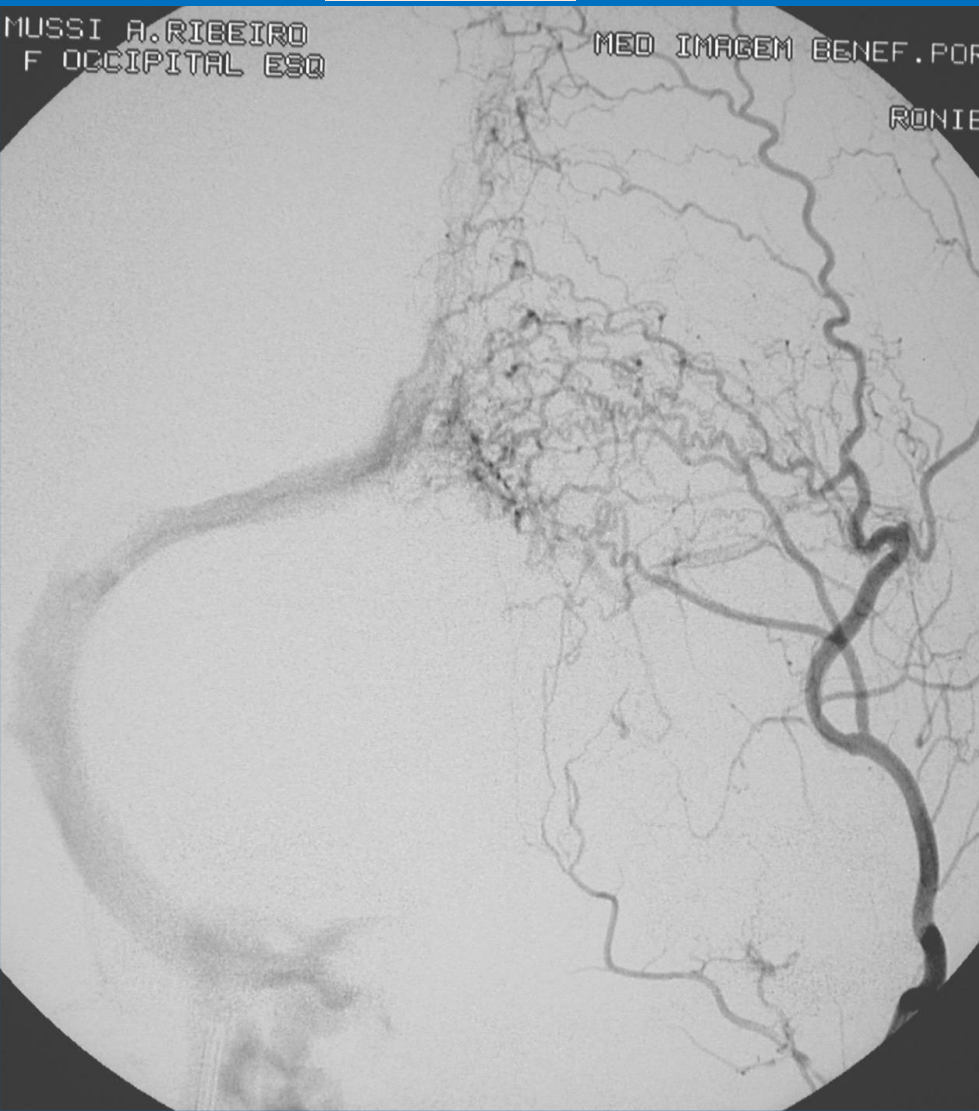
MED IMAGEM BENEF. PORT.

RONIE L

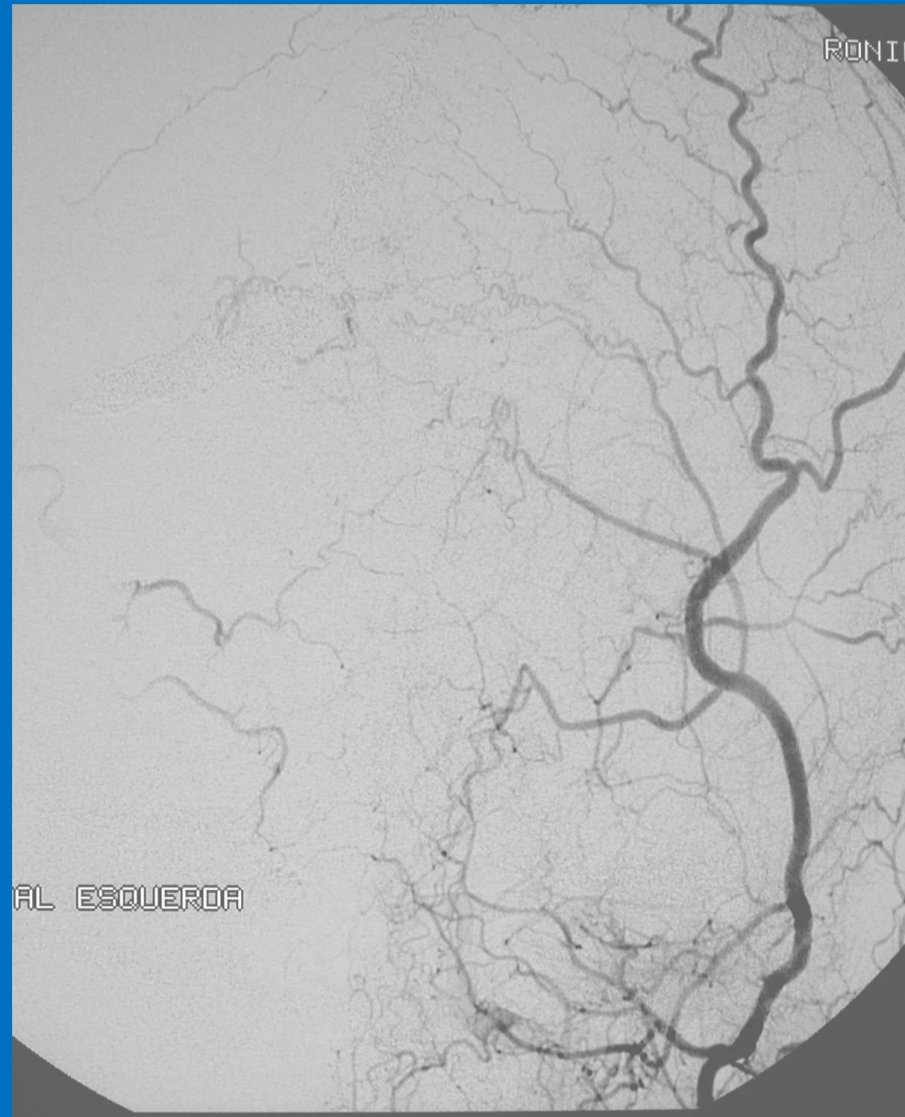


Left Occipital Artery angiogram

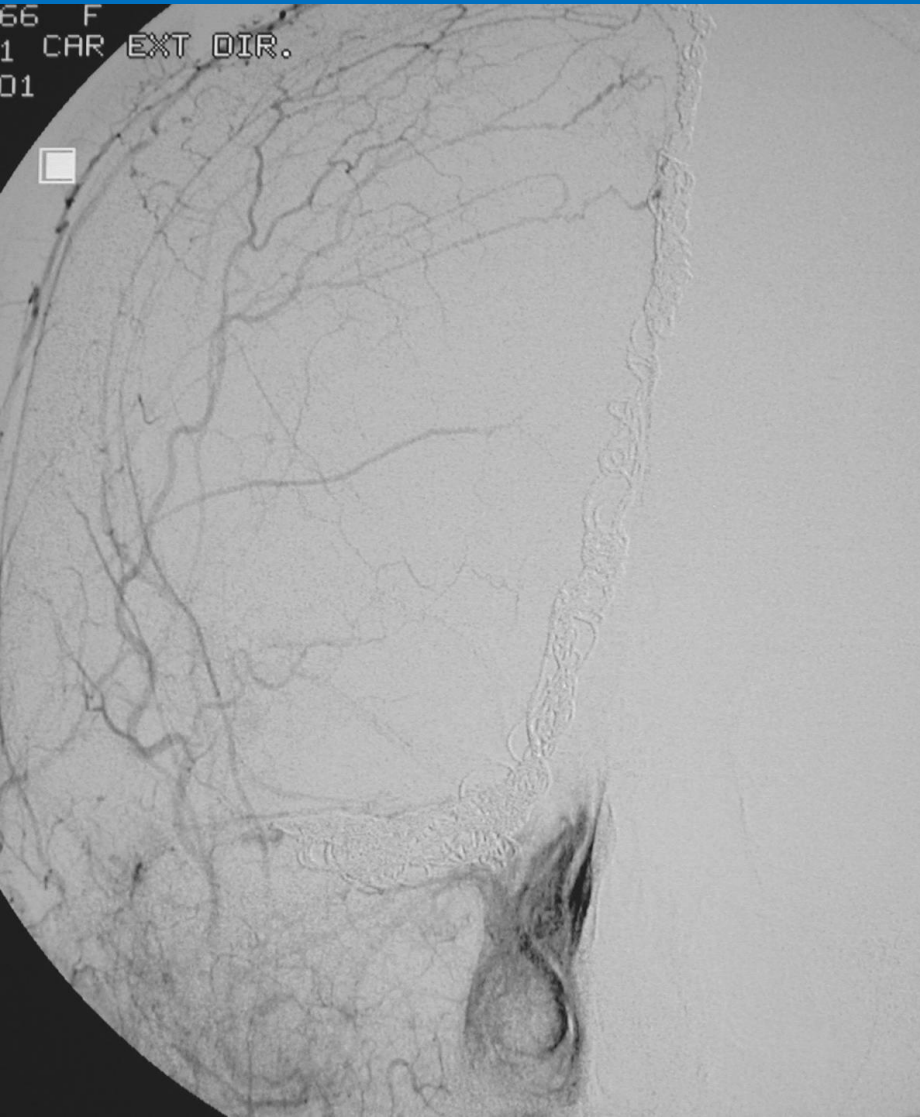
before



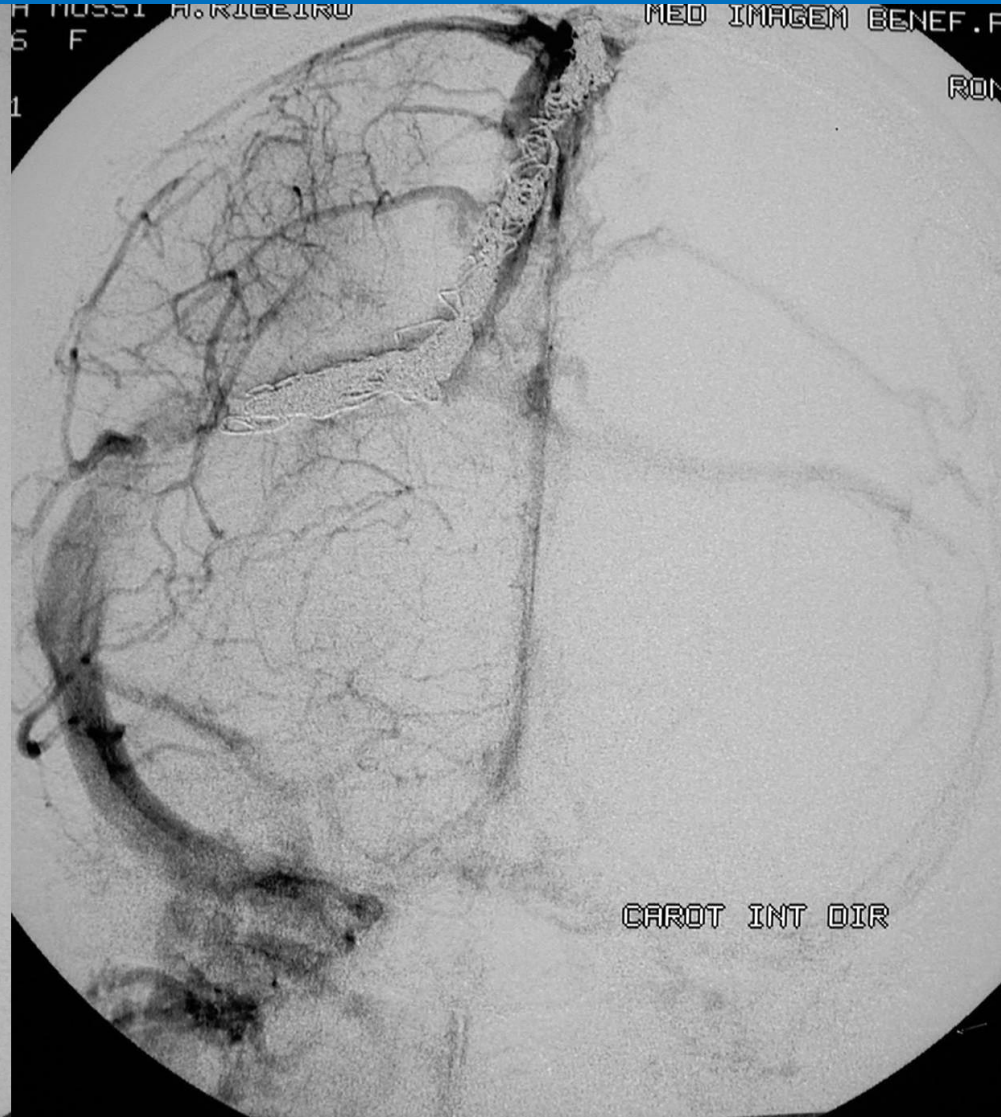after



RECA after embolization
A-P view



RICA after embolization
A-P view



After superselective occlusion of
the septation

