


EVT of giant, partially thrombosed aneurysm following failed surgery

Gyula Gál

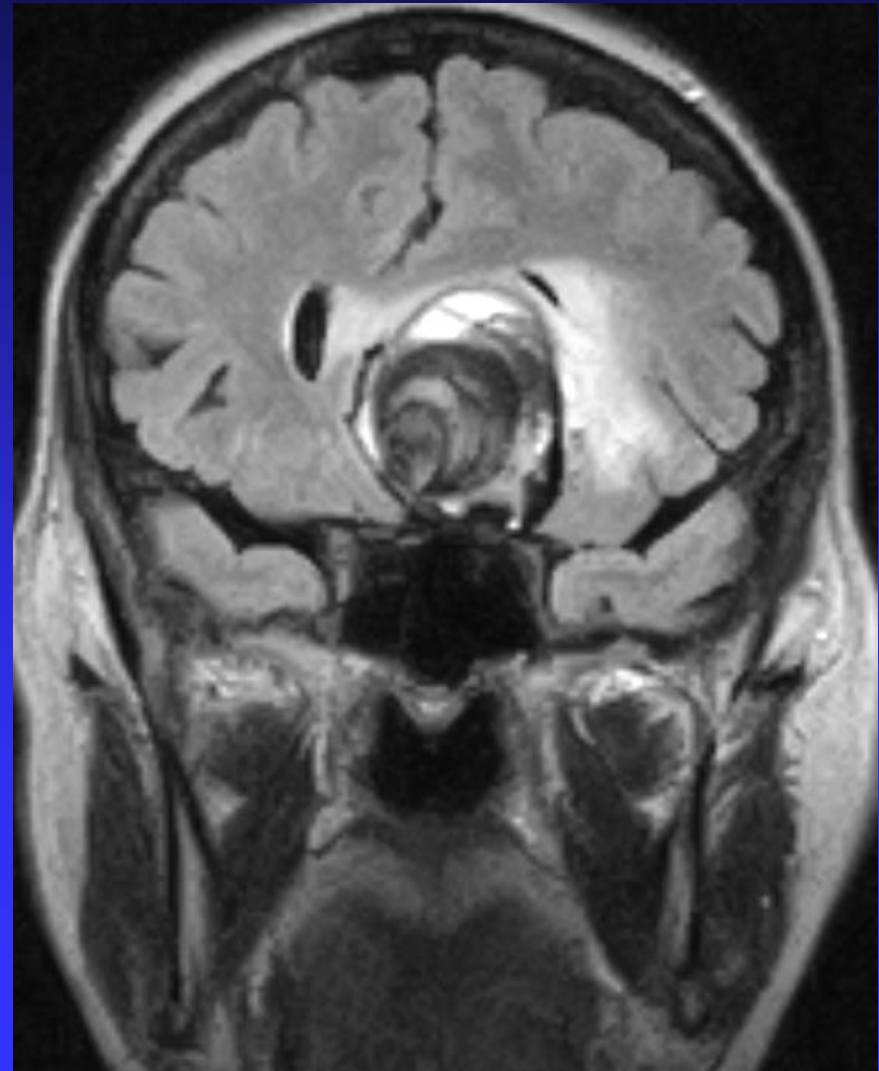
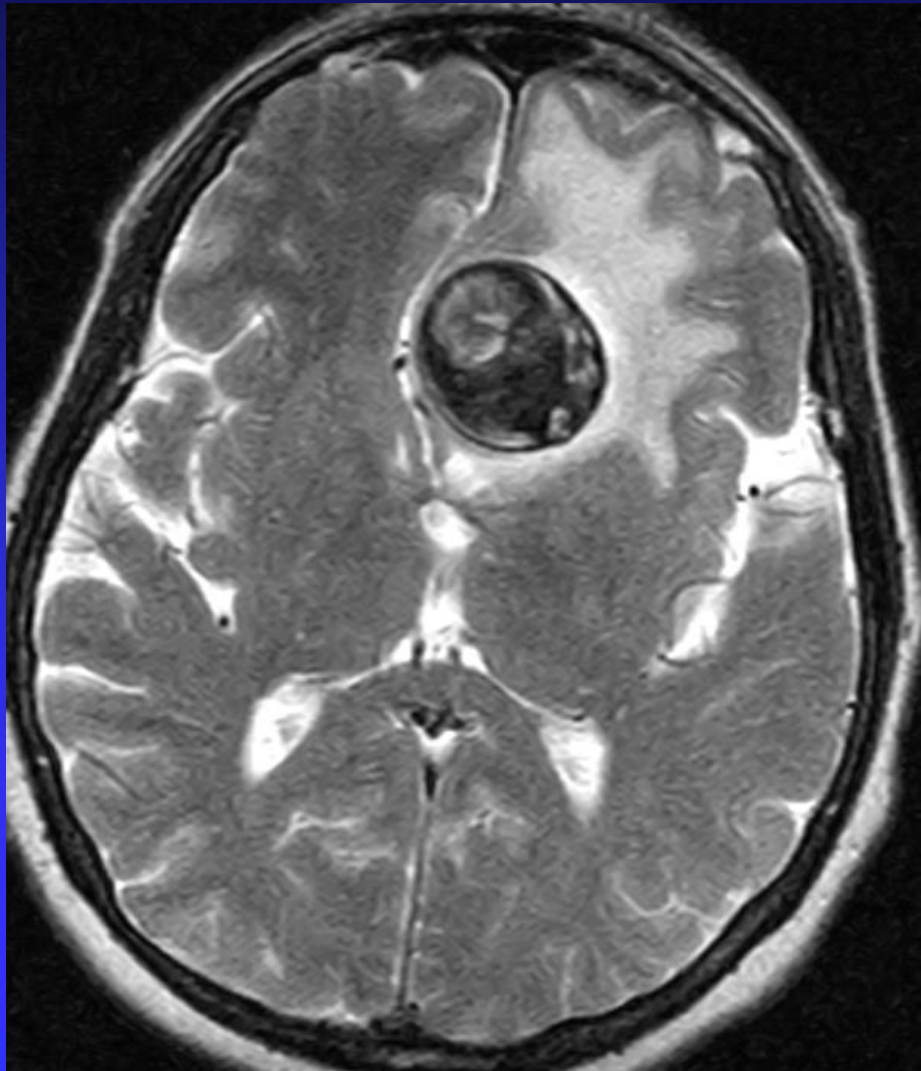
Department of Radiology

University Hospital

Odense, Denmark



62 yrs fem, severe headache



Unders.dato: 2013/11/25

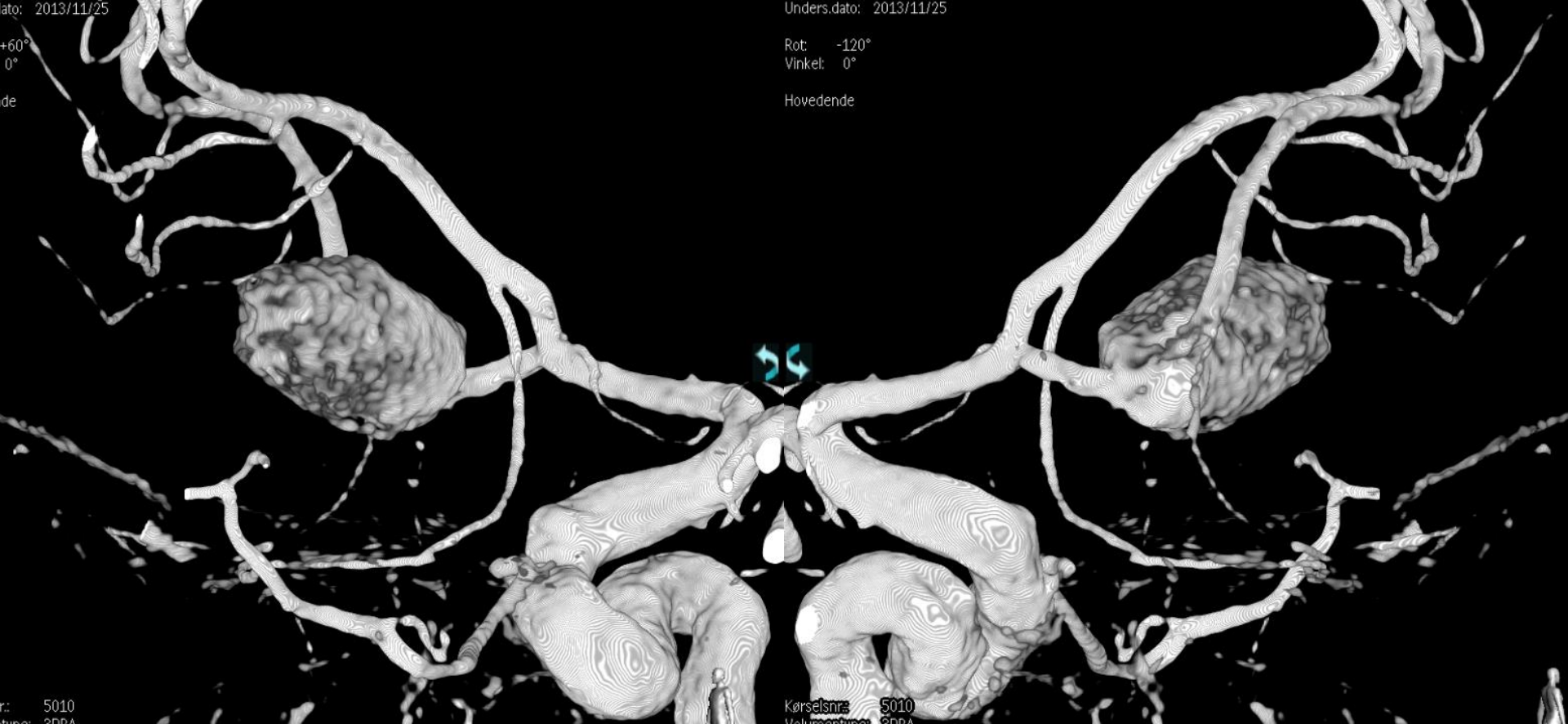Unders.dato: 2013/11/25

+60°
0°

Rot: -120°
Vinkel: 0°


de

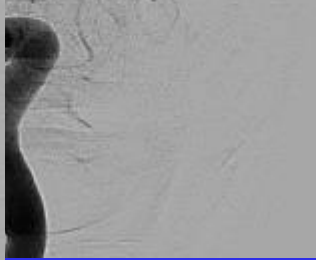
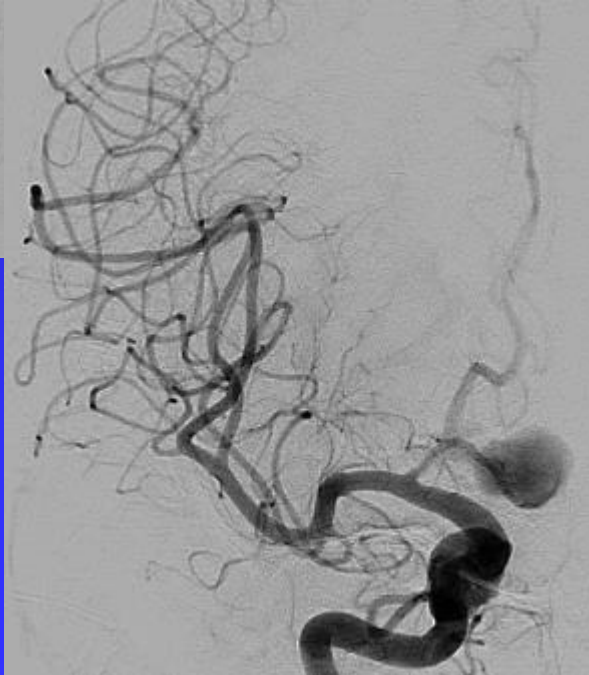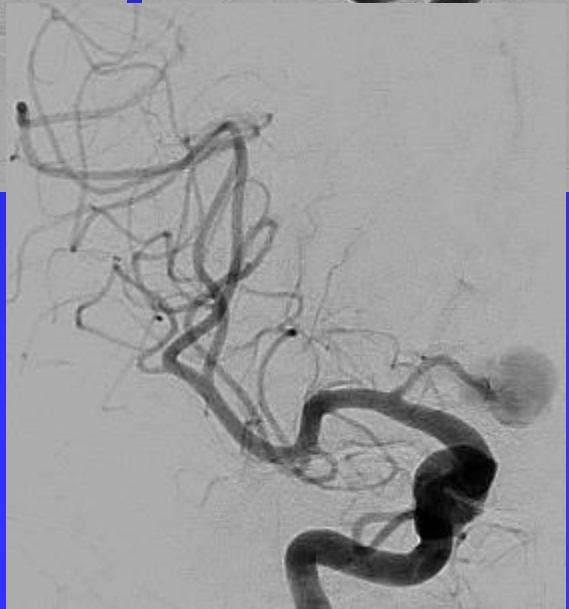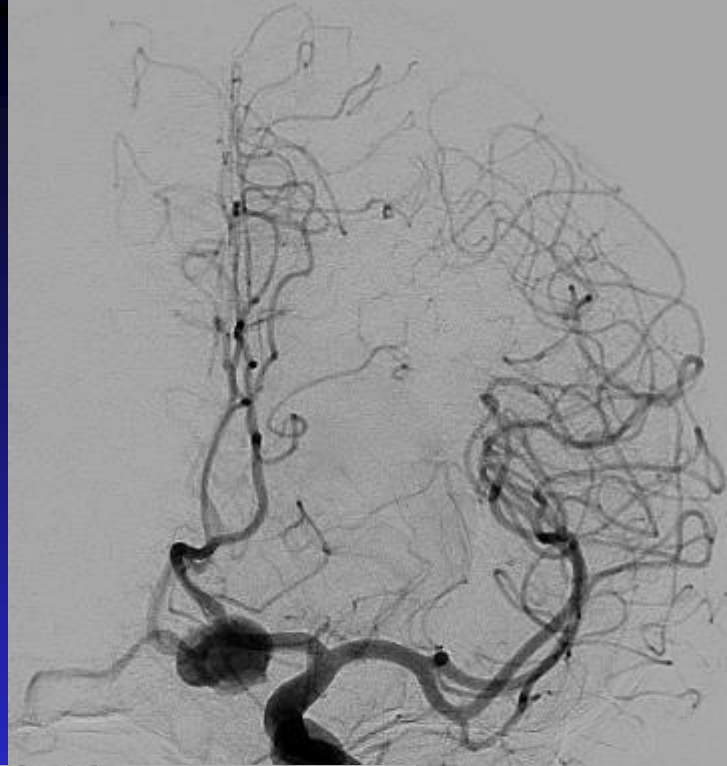
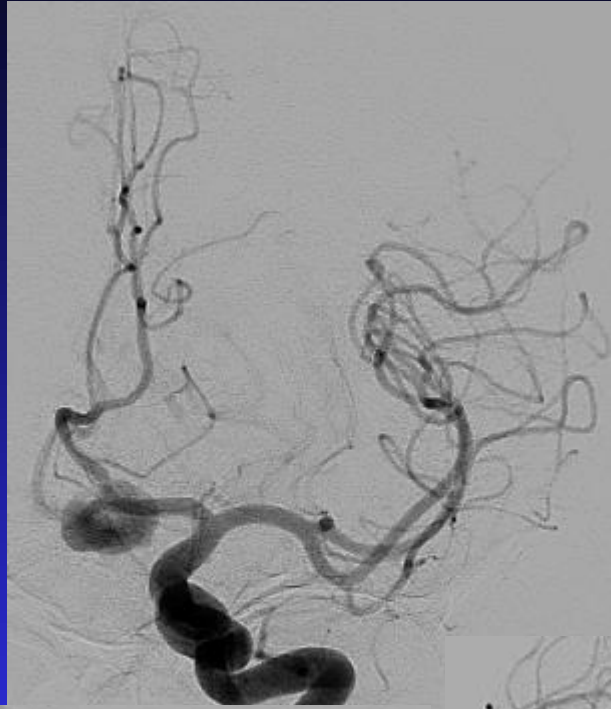
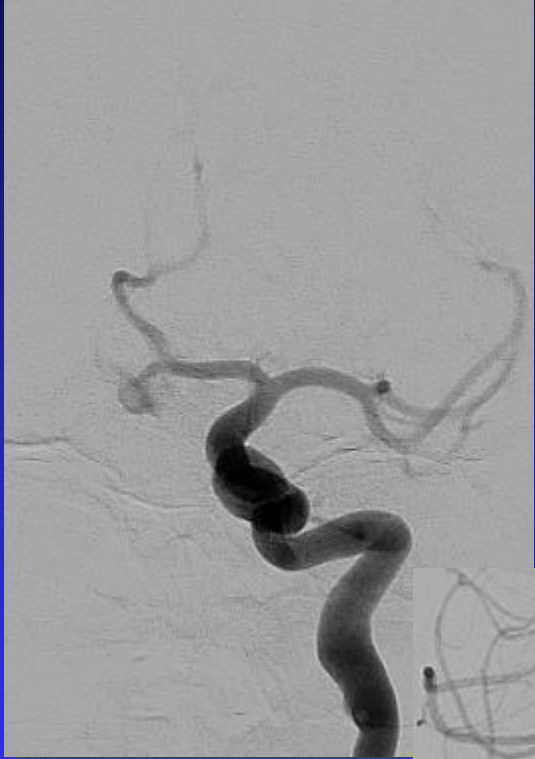Hovedende



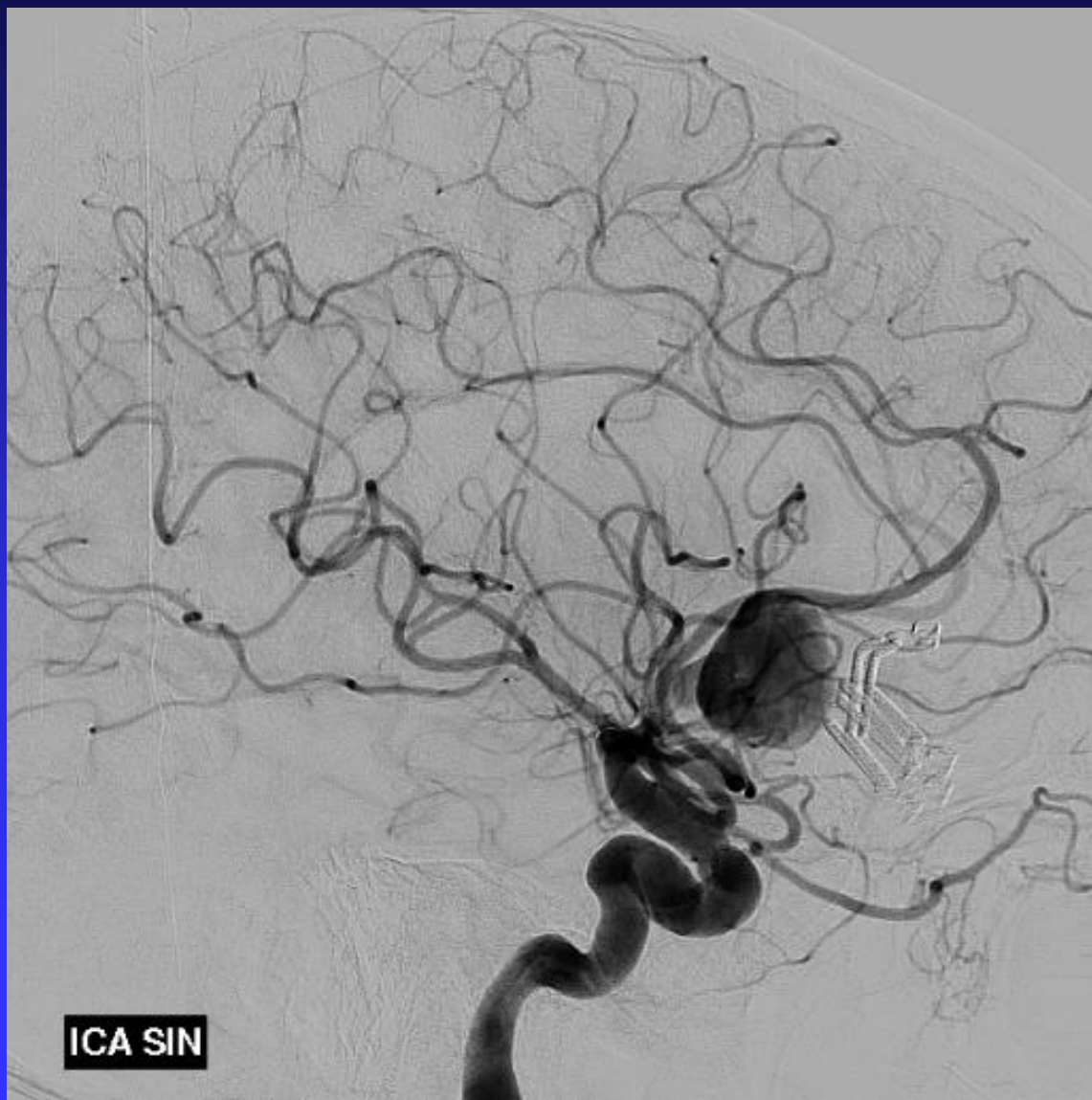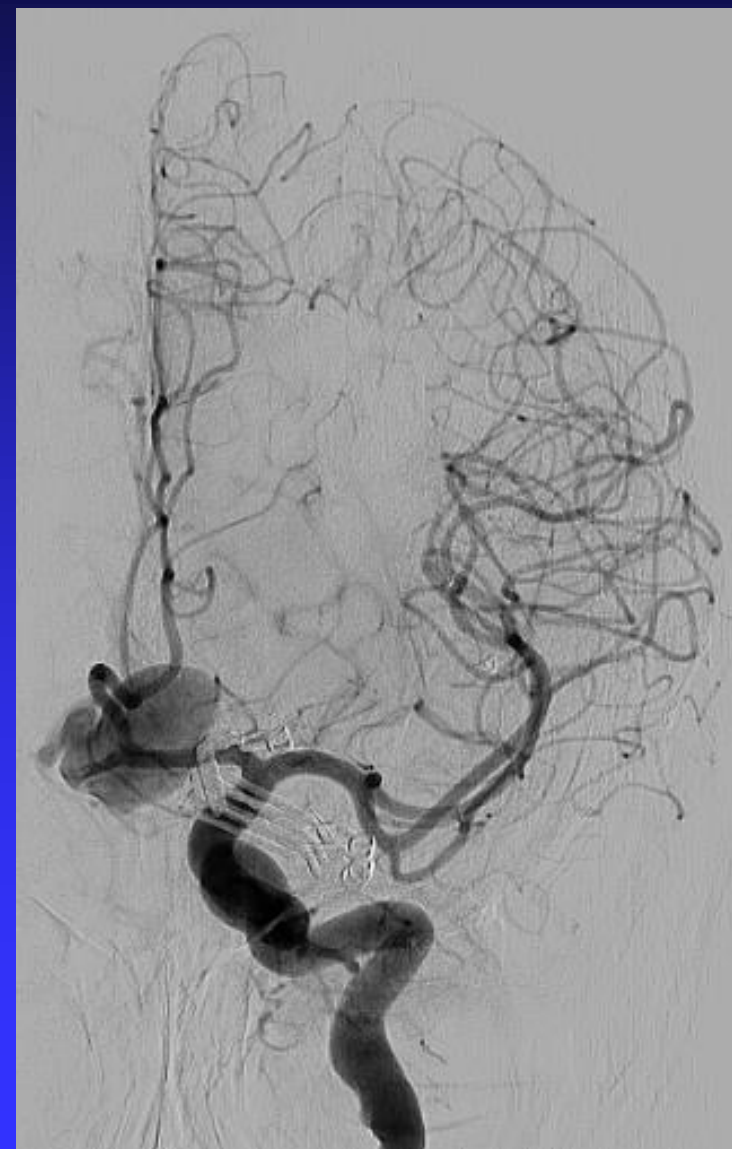
r: 5010
t: 200A

Kørselsnr: 5010
Volumensnr: 200A





Surg 26 Nov '13, f u 22 May '14



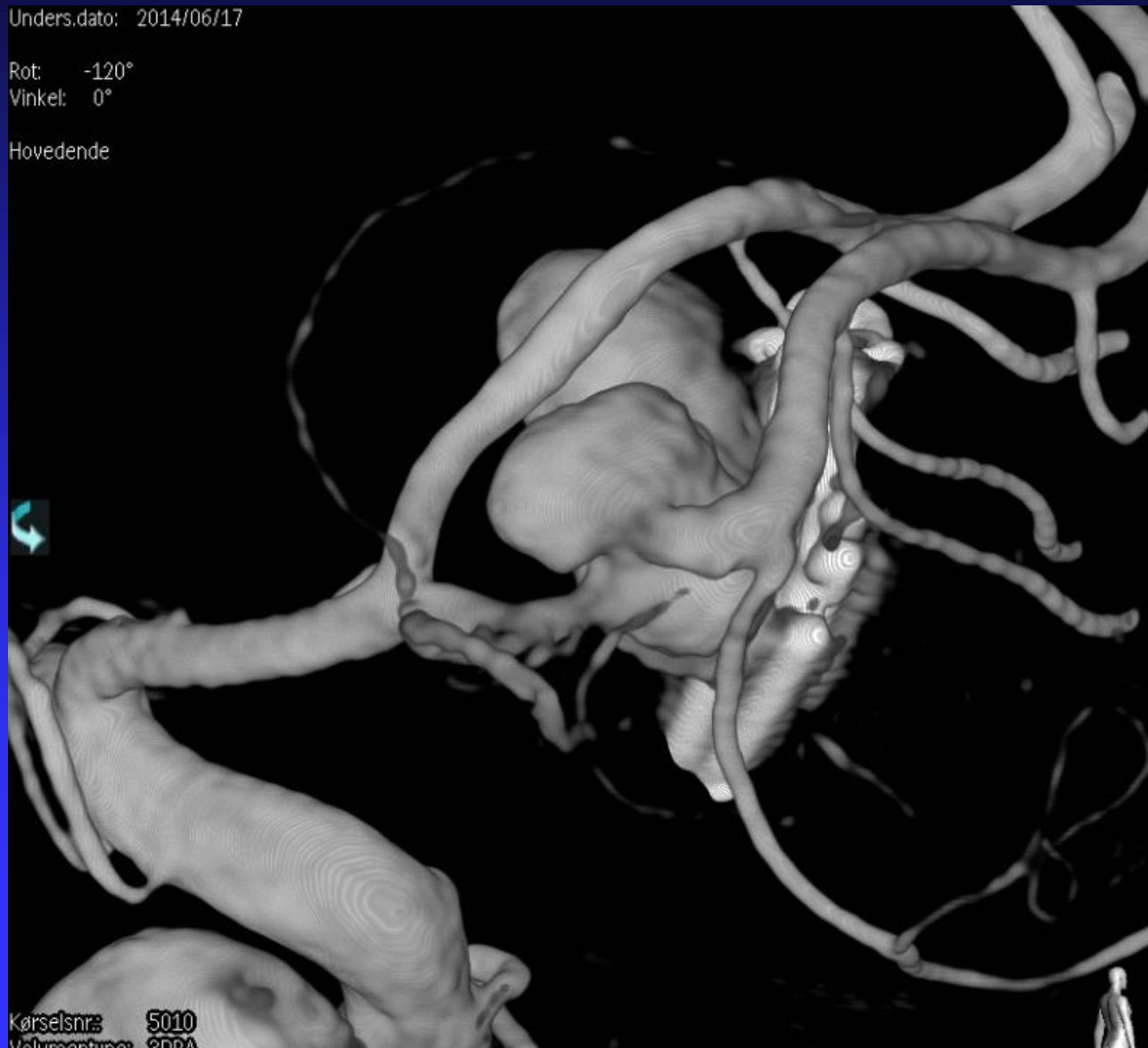EVT 17 June 2014

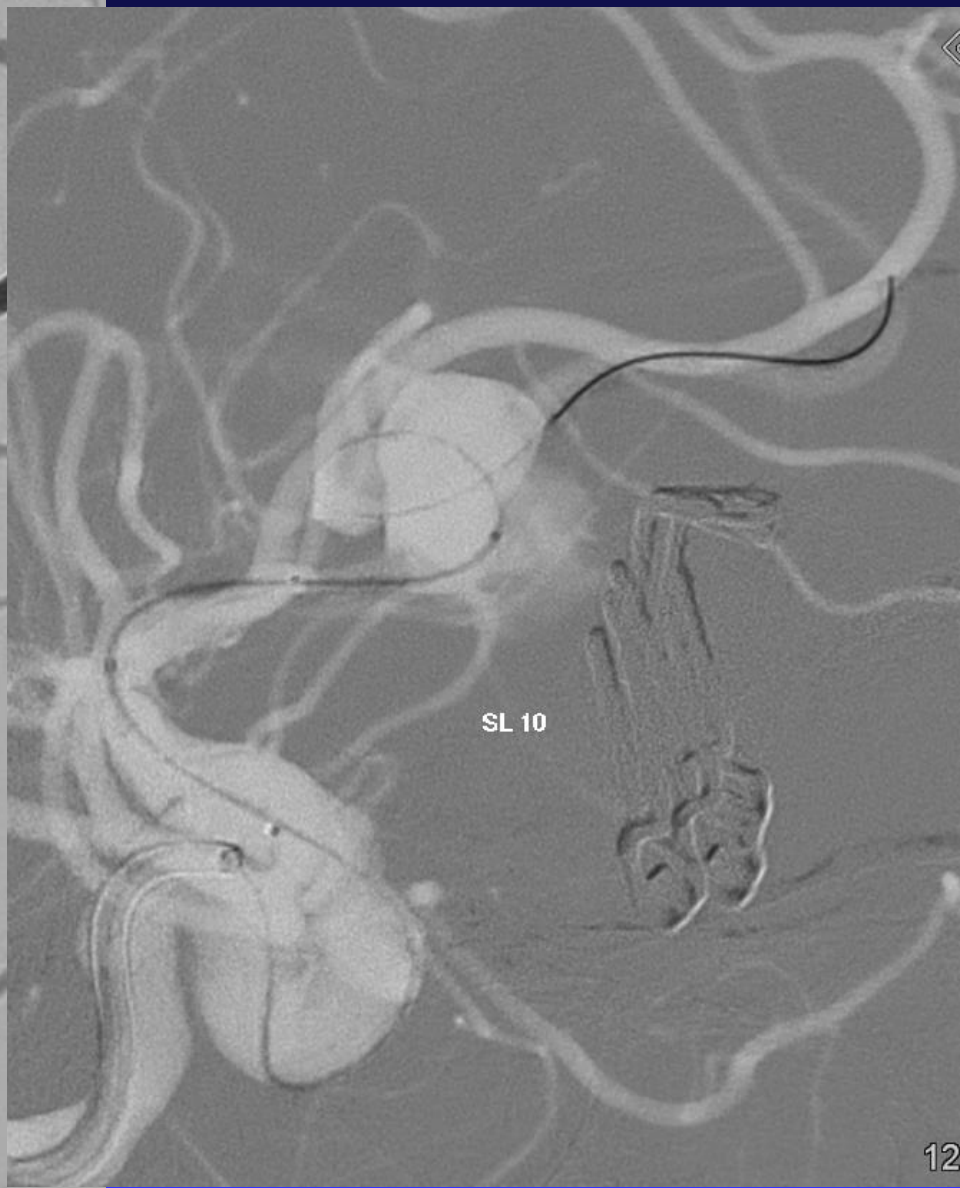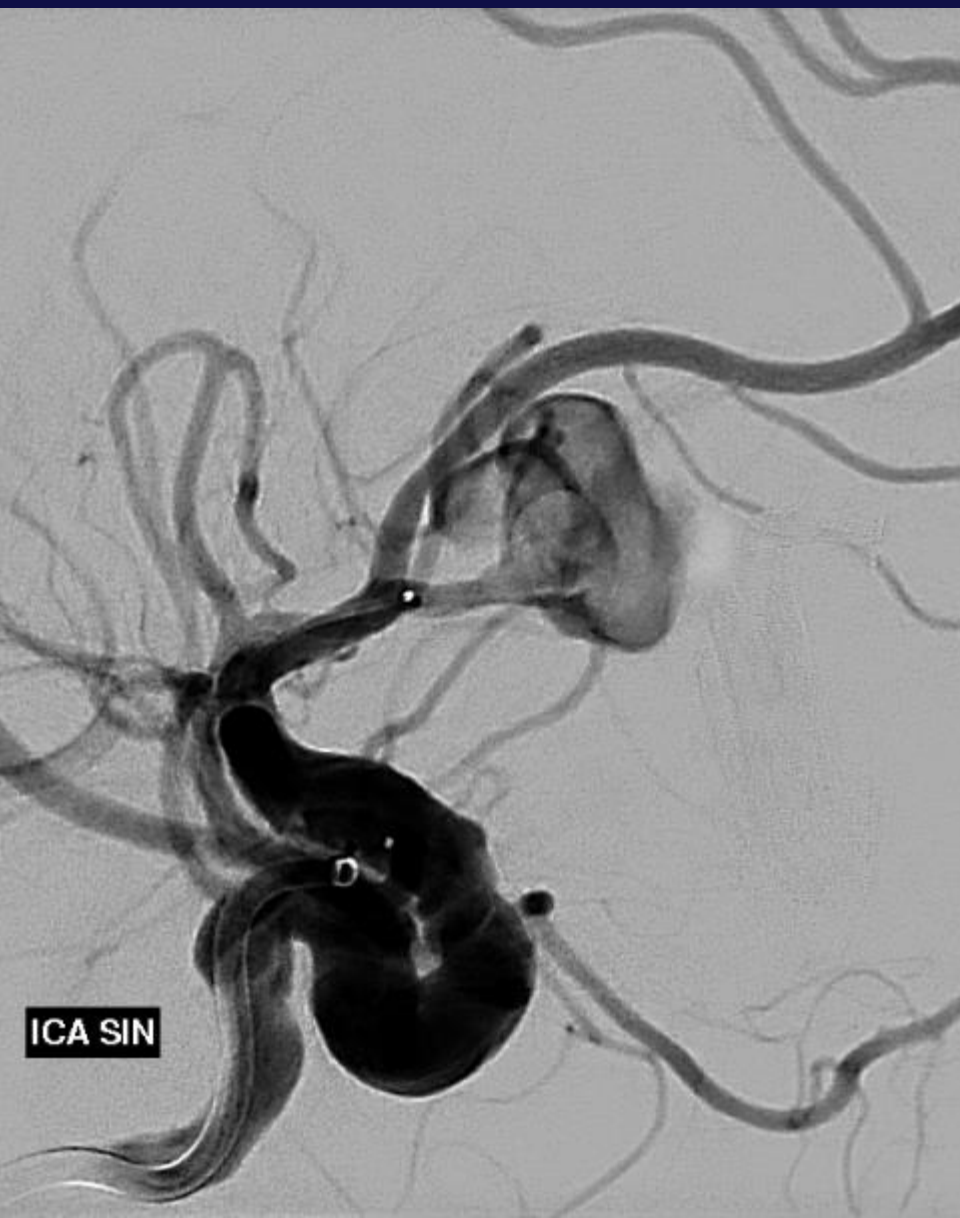Unders.dato: 2014/06/17

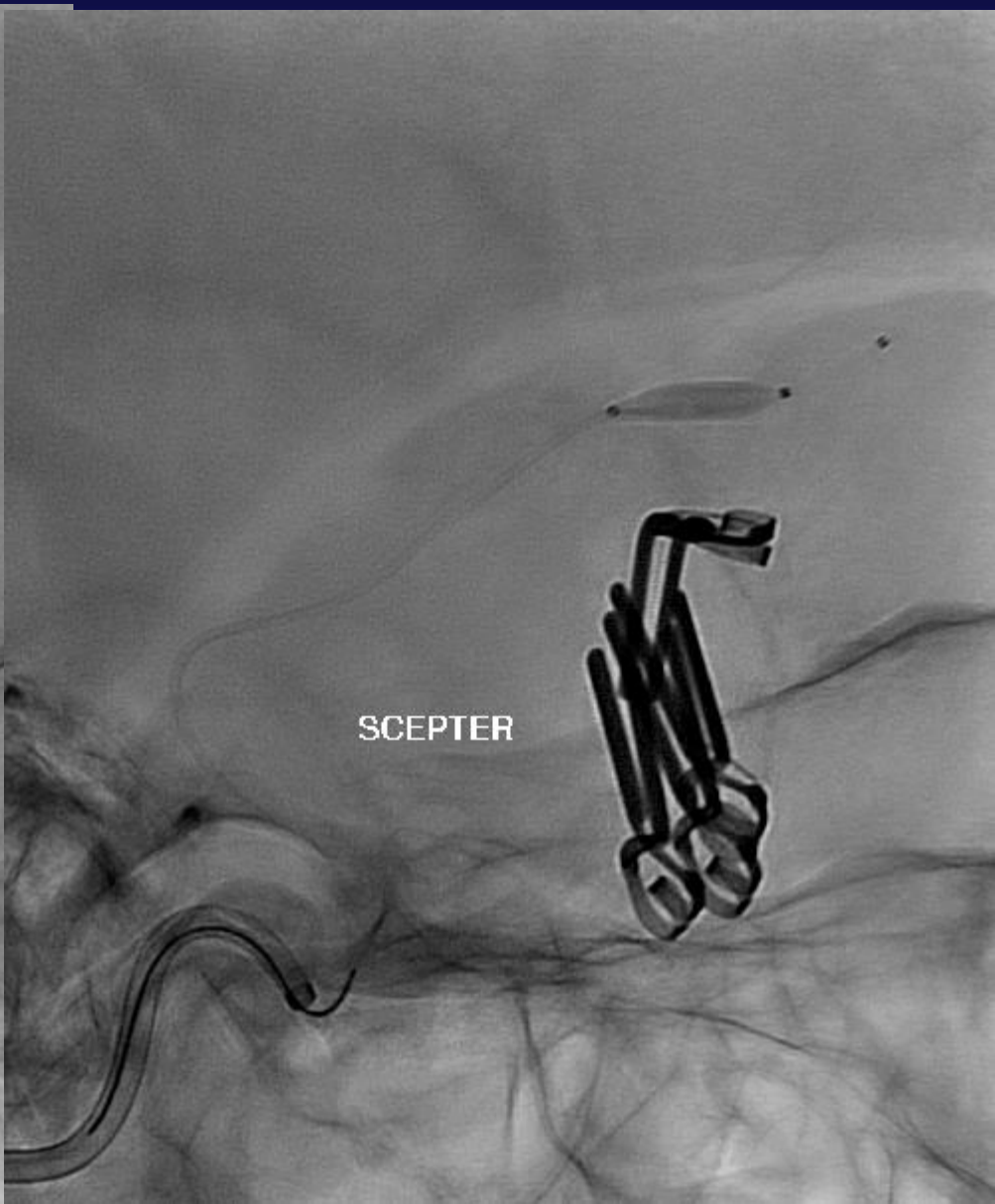
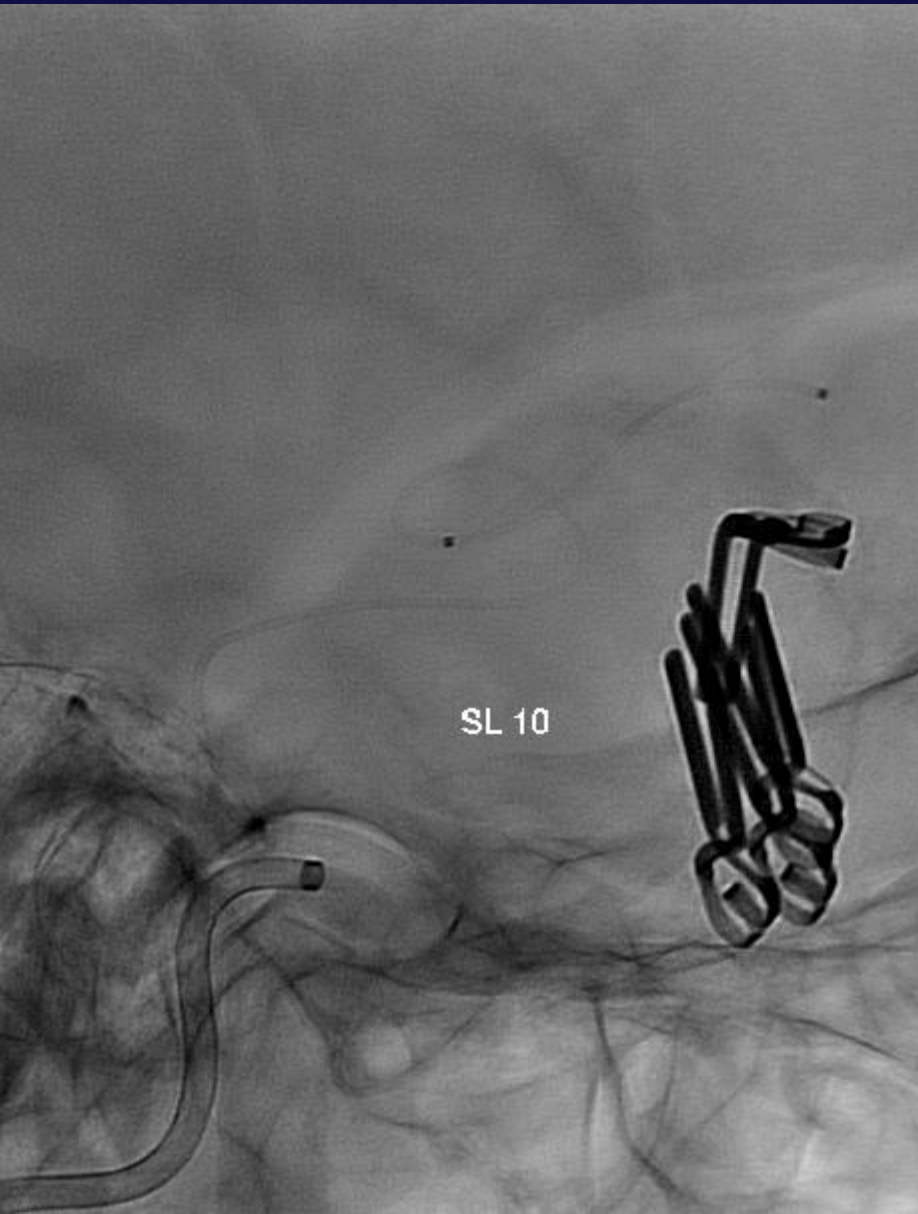Rot: -120°

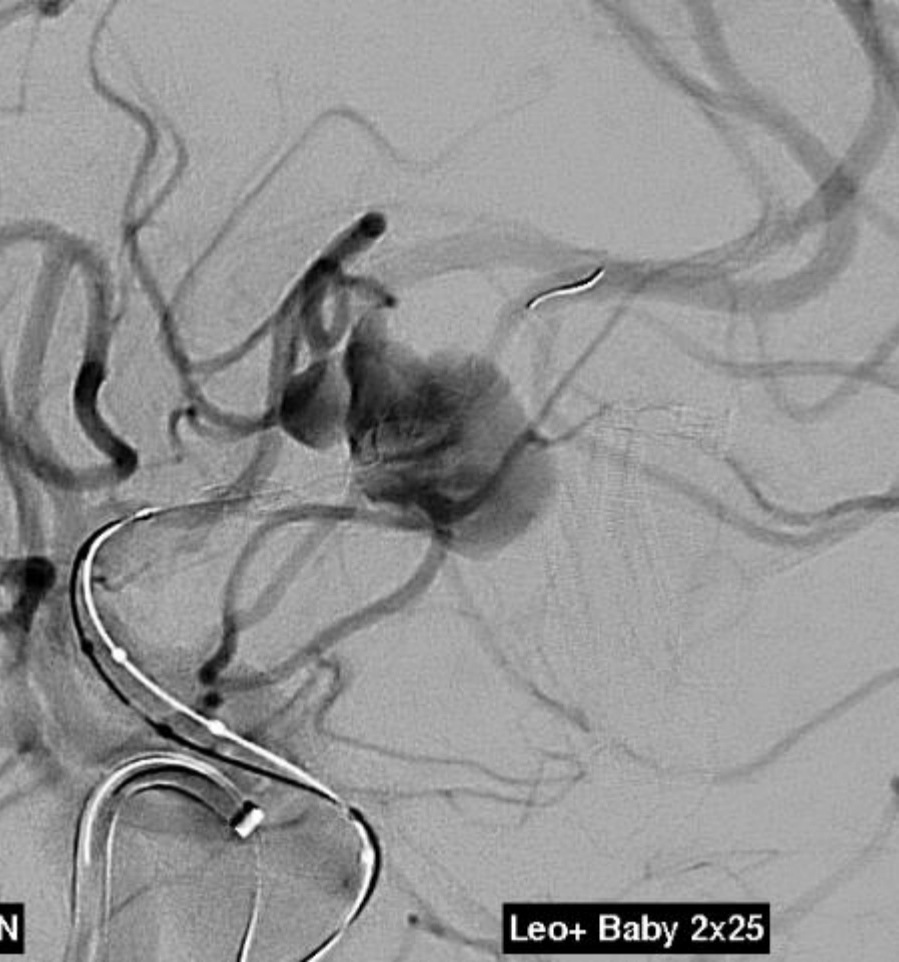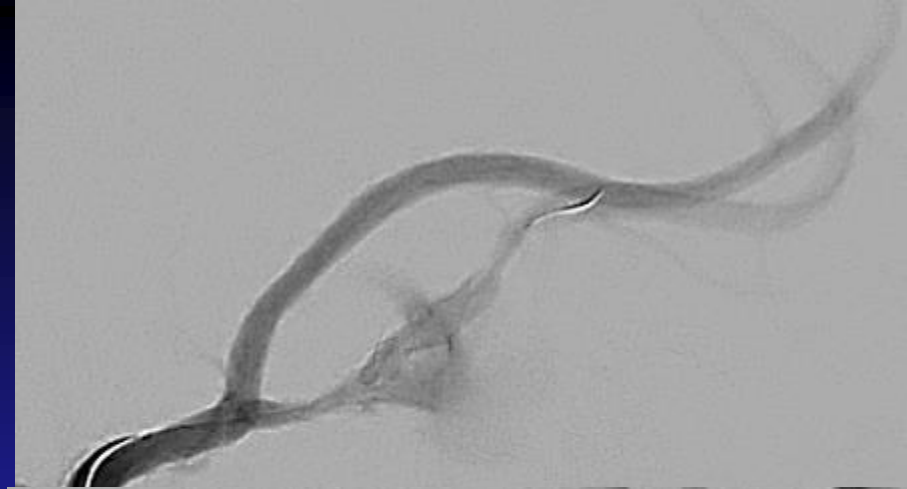
Vinkel: 0°

Hovedende

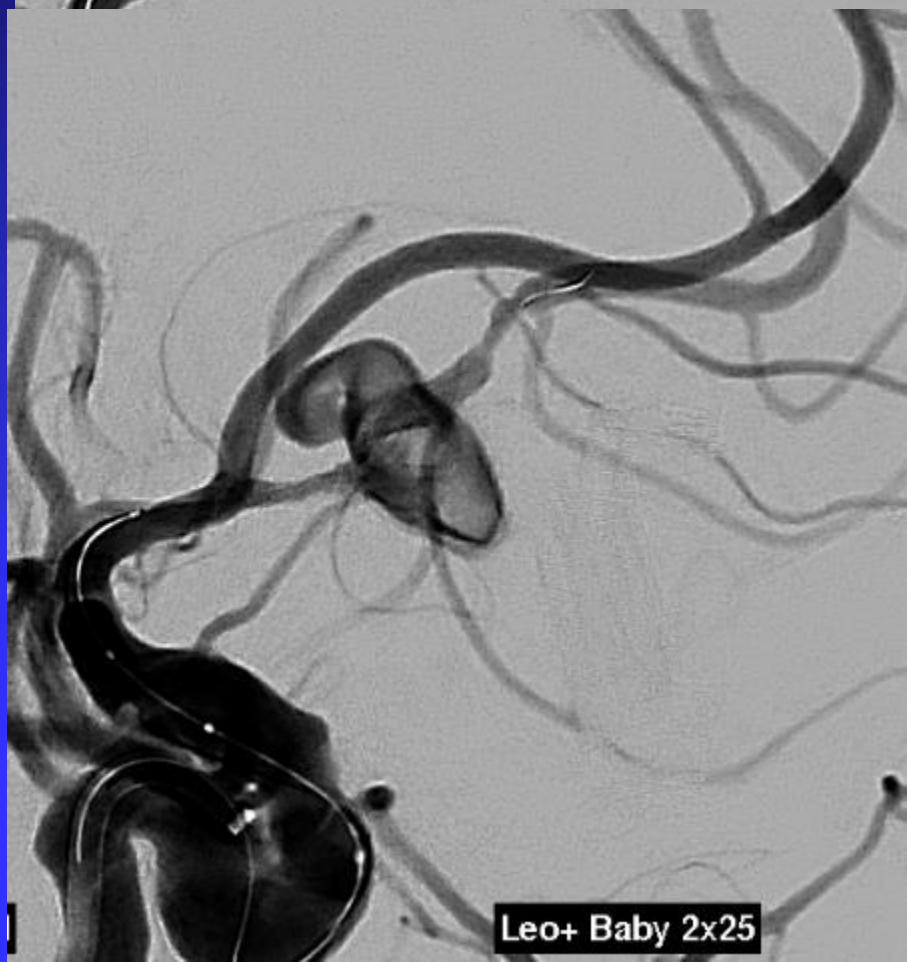




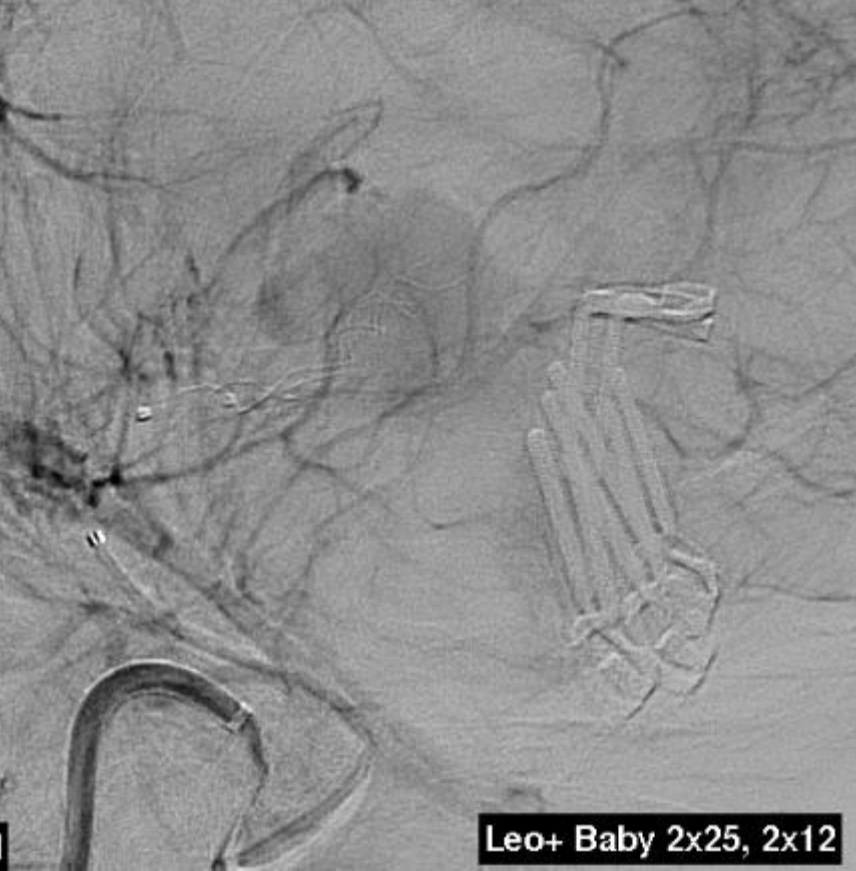



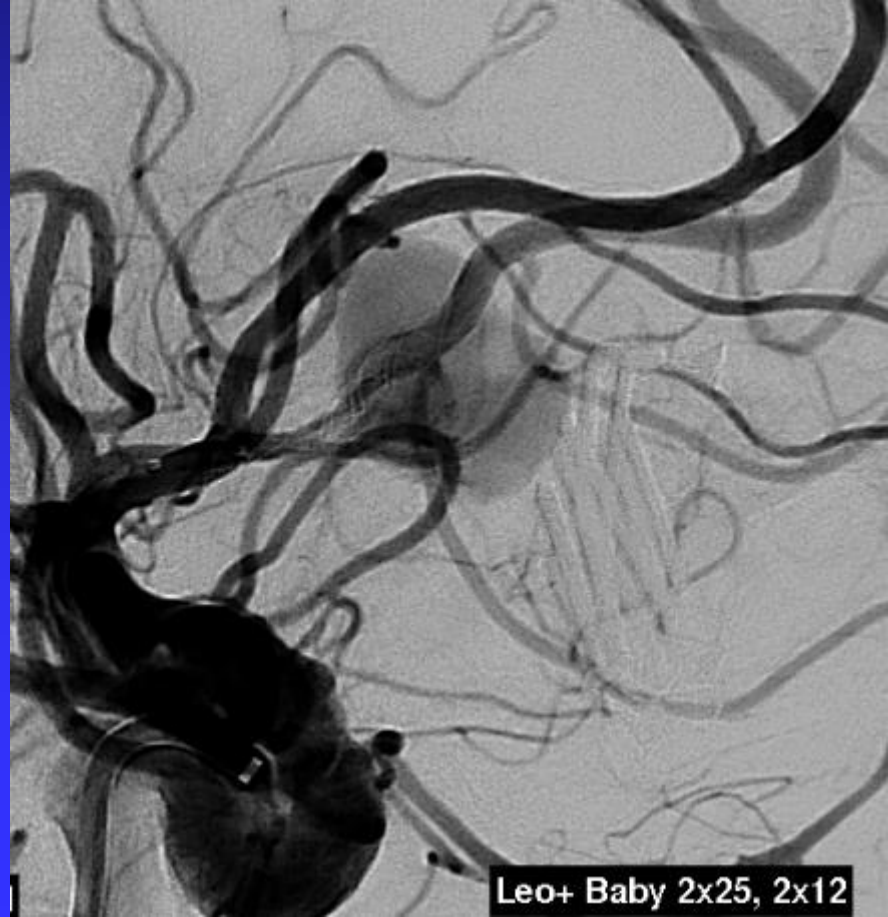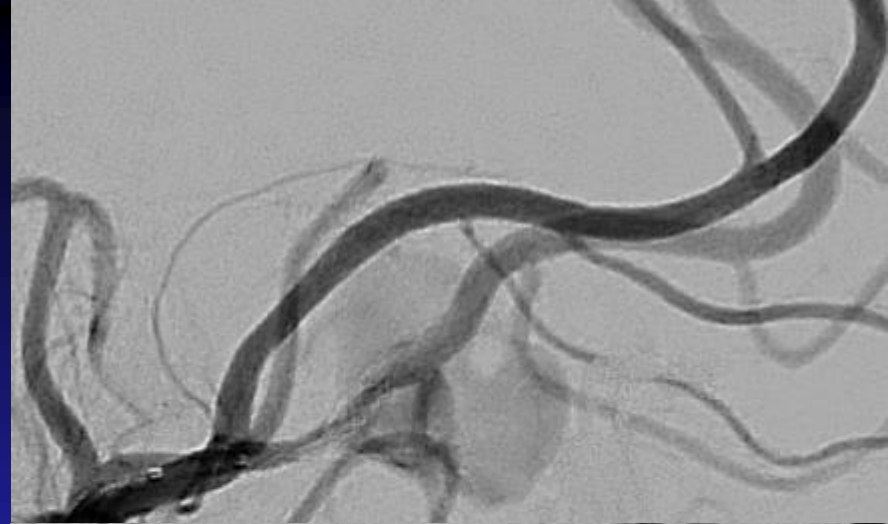Leo+ Baby 2x25



Leo+ Baby 2x25

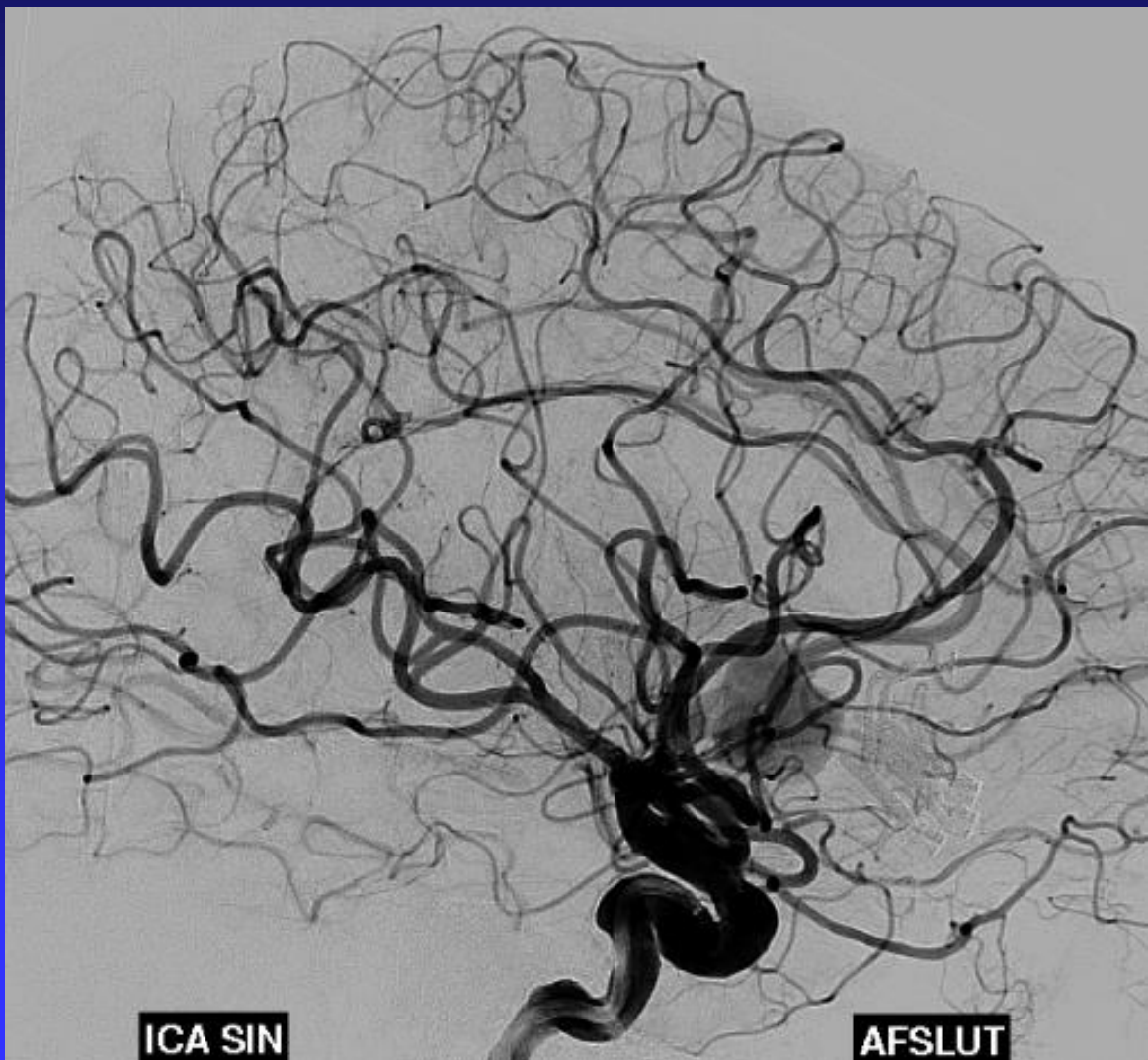
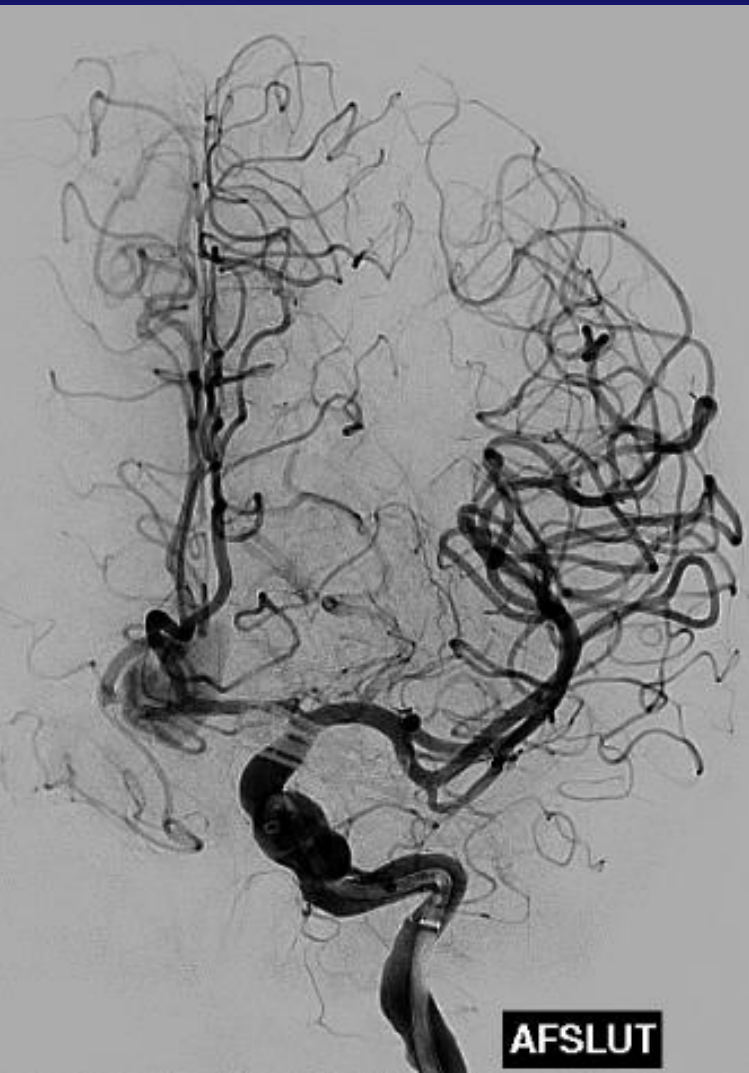

Leo+ Baby 2x25, 2x12

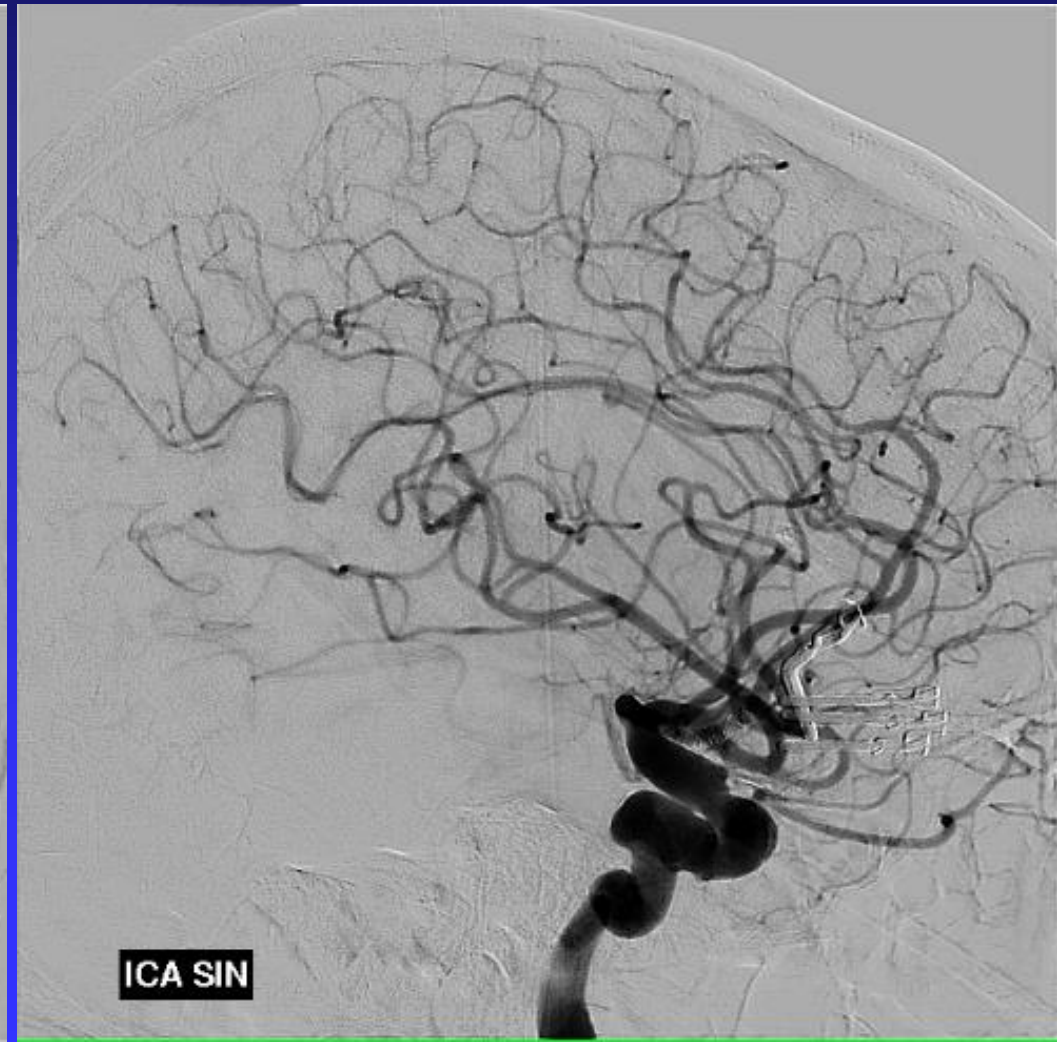
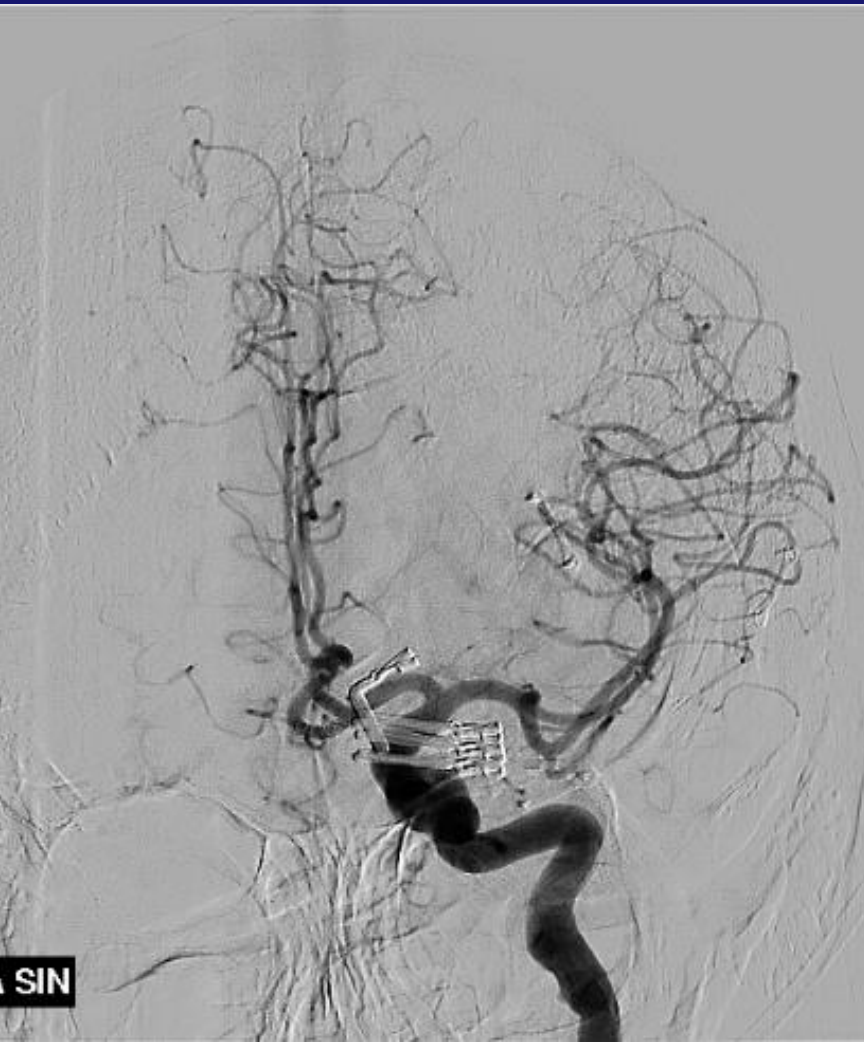


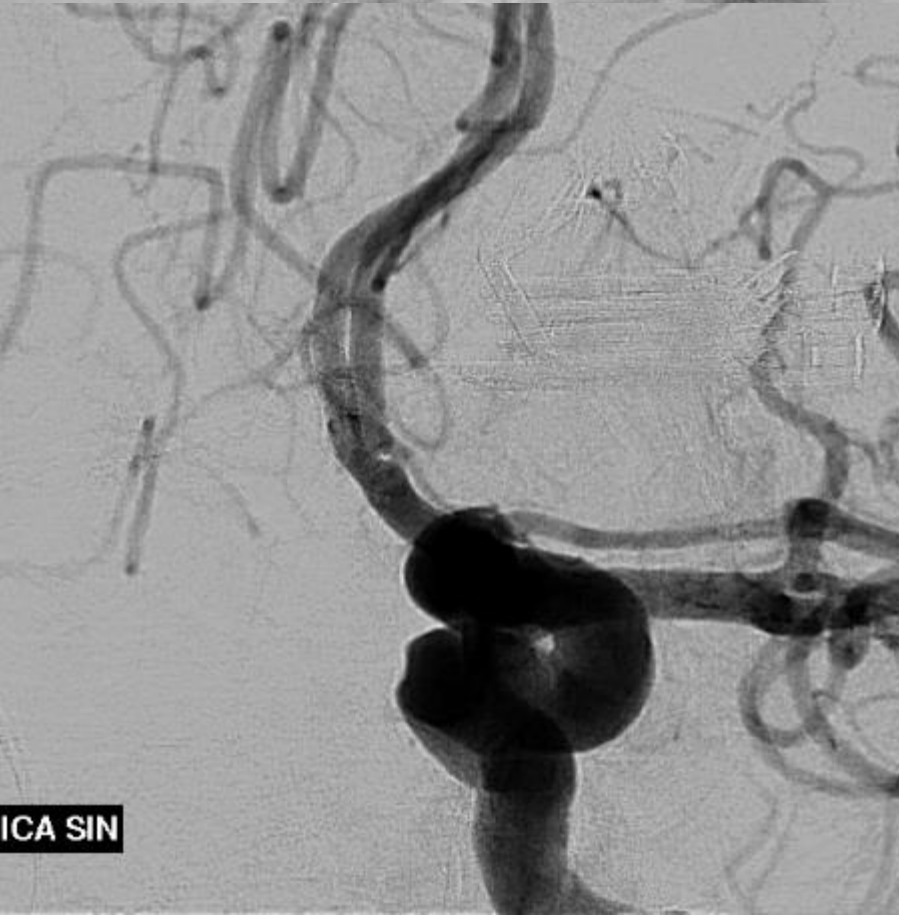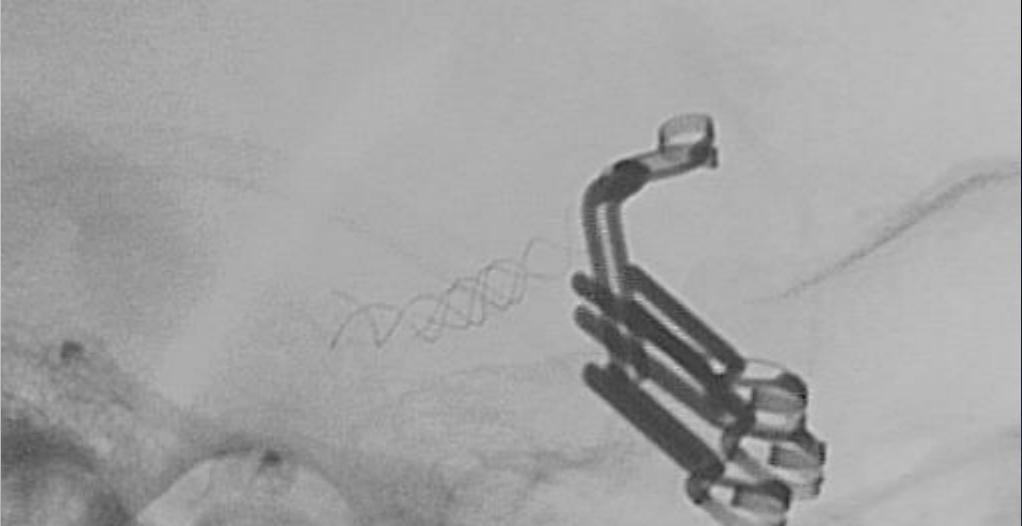
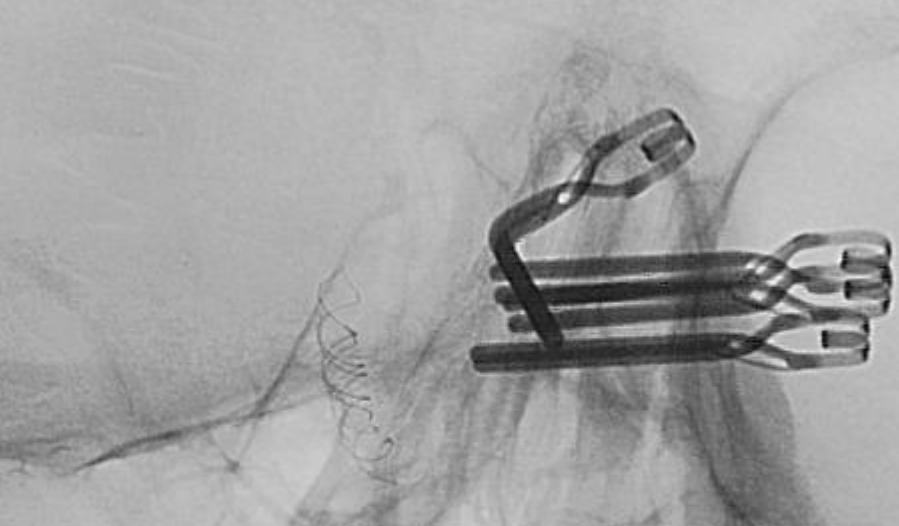
Leo+ Baby 2x25, 2x12

Final angiogram

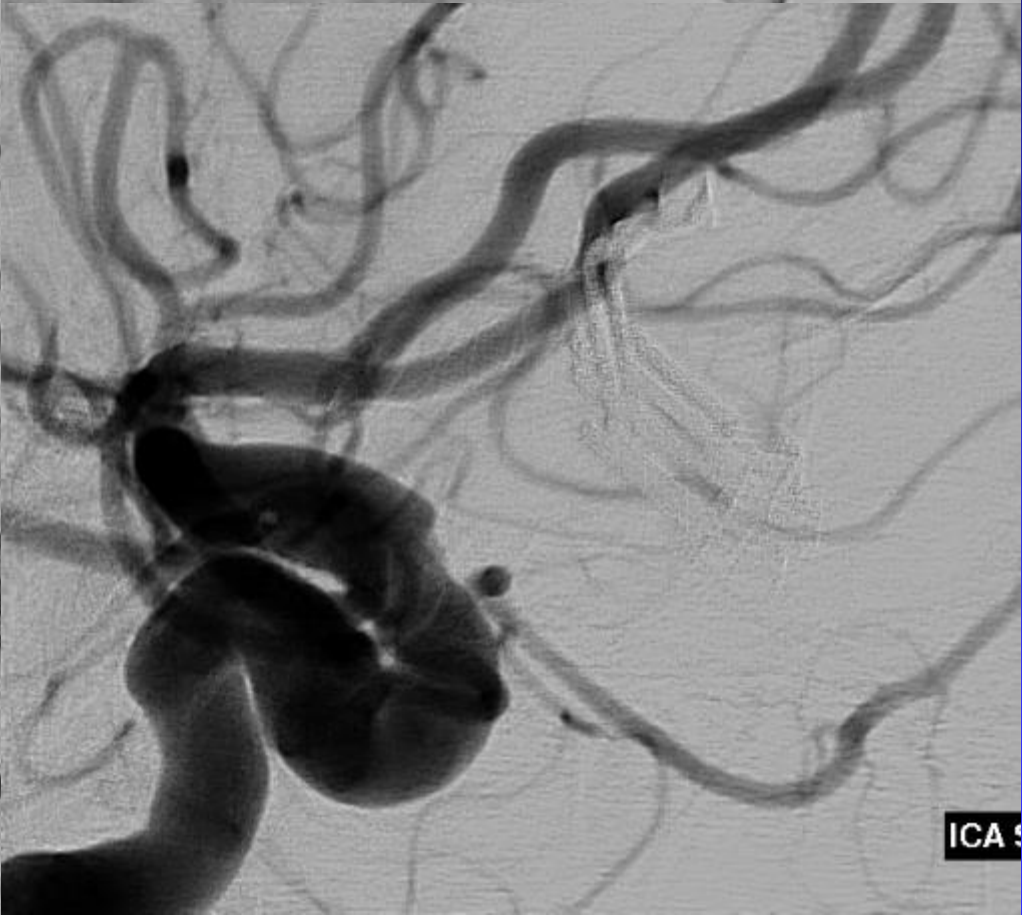

F u @ 18 m





ICA SIN



ICA S