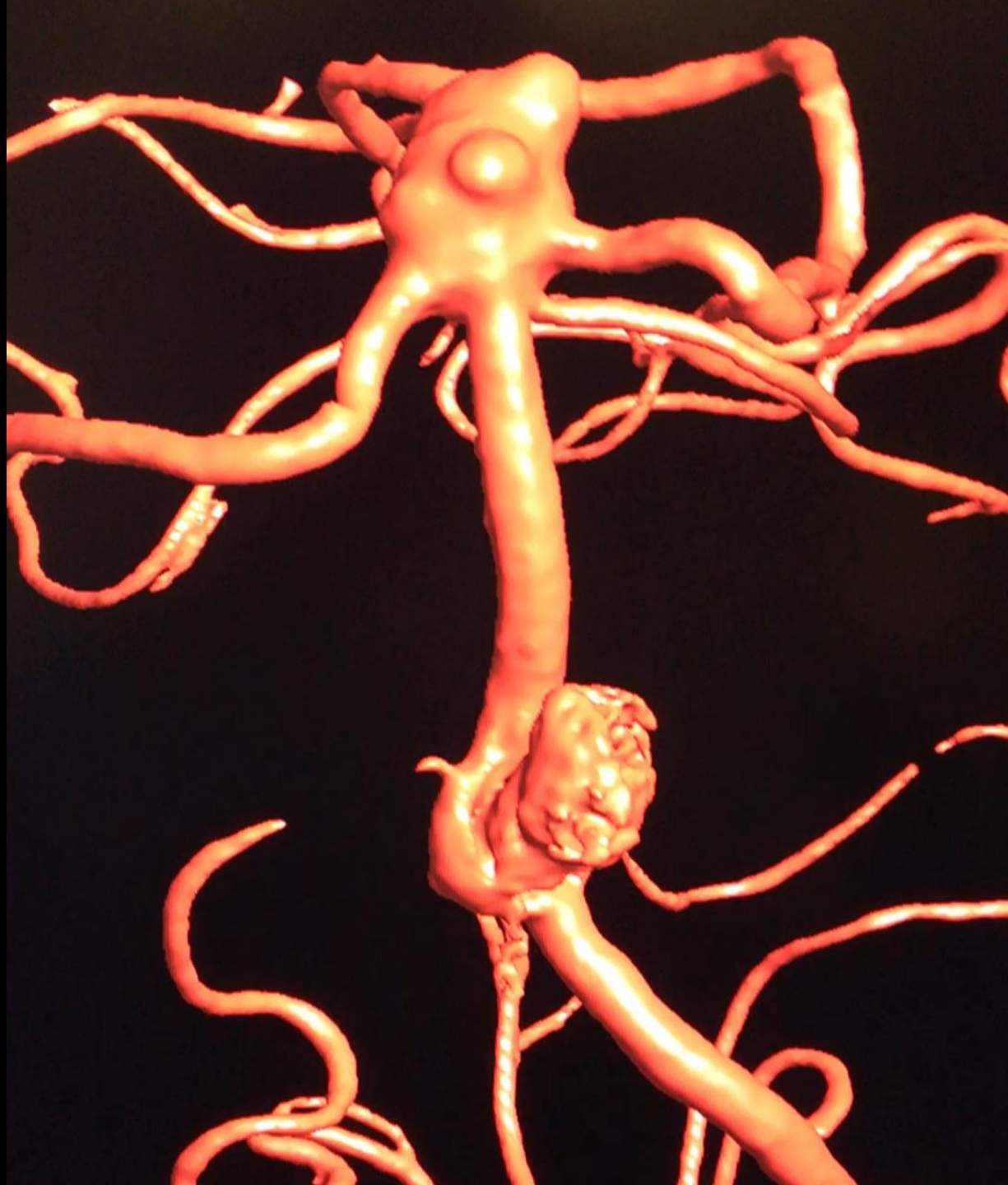

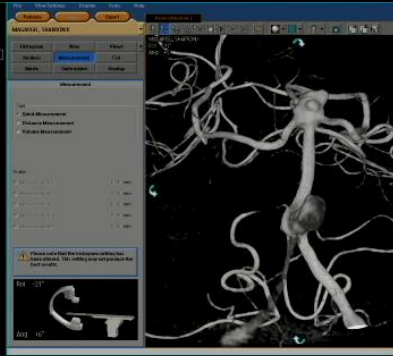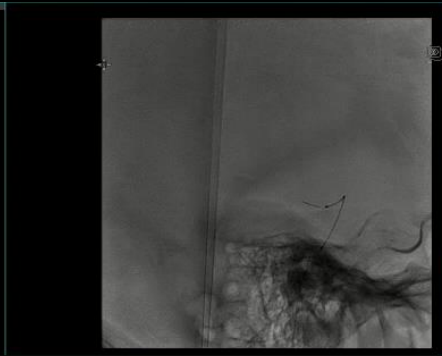
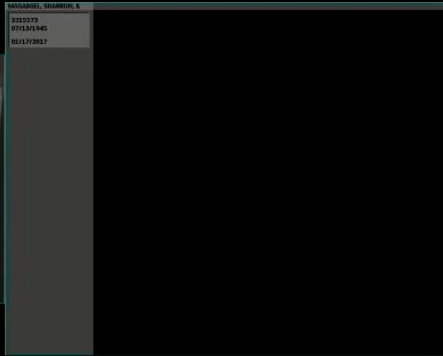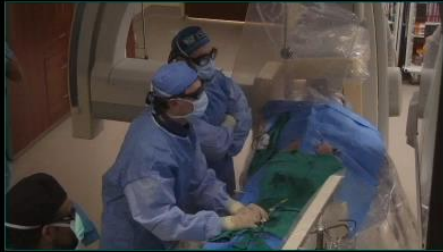Case Presentation

- 66 year old woman
- Headaches and “dizziness”
- Found to have a basilar artery aneurysm on MRI/MRA

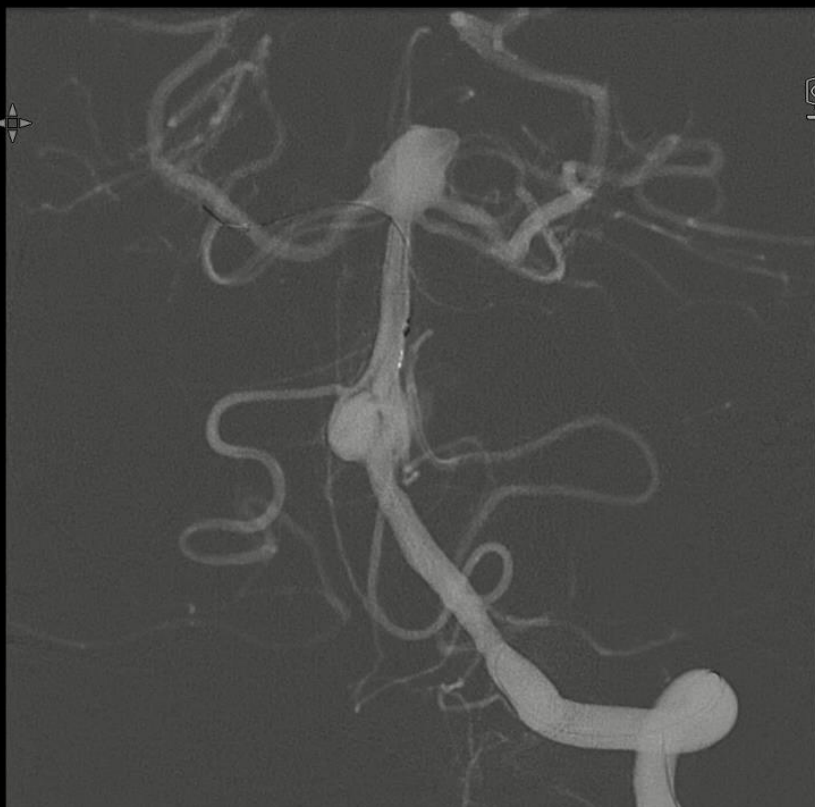

Plan & Devices

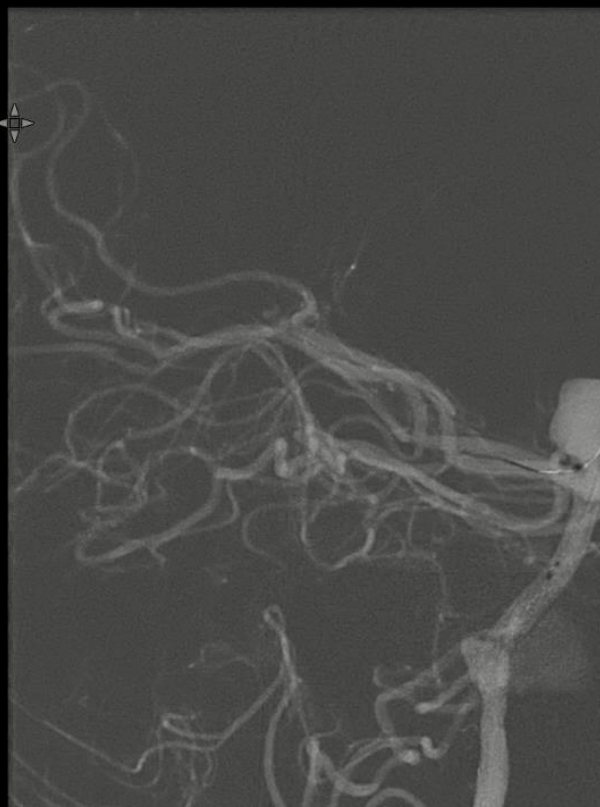- Y stenting and coil basilar apex
- Stenting one arm of the fenestration and coil
- 6F Shuttle
- Navien 0.58
- LVIS 3.5 x28
- LVIS 3.5 x18

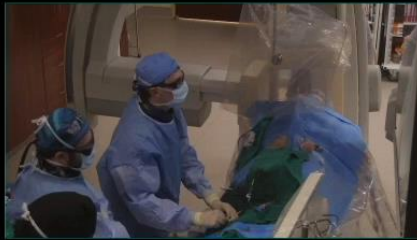

78	12.4
kV	mA
RAO	7°
CRAN	5°
Height	+3
cm	
SID	110
cm	
FD	15
cm	
2	
Fluo	N 12.5fr
Time	10.9
min	
K	40.7
	mGy/min
DAP	50.3
	mGy ^{cm} ²/s
K	145
	mGy

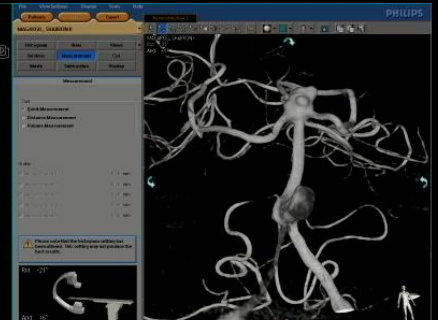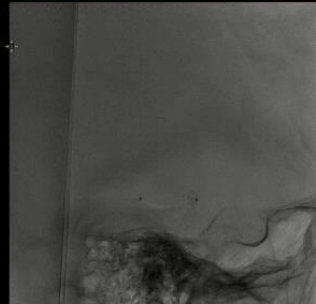


71	8.3
kV	mA
RAO	89°
	0°
SID	109
cm	
FD	19
cm	
2	
Time	0.8
min	
K	24.9
	mGy/min
K	34
	mGy





MICHAEL, SHARON A
 021073
 07131440
 06/17/2017

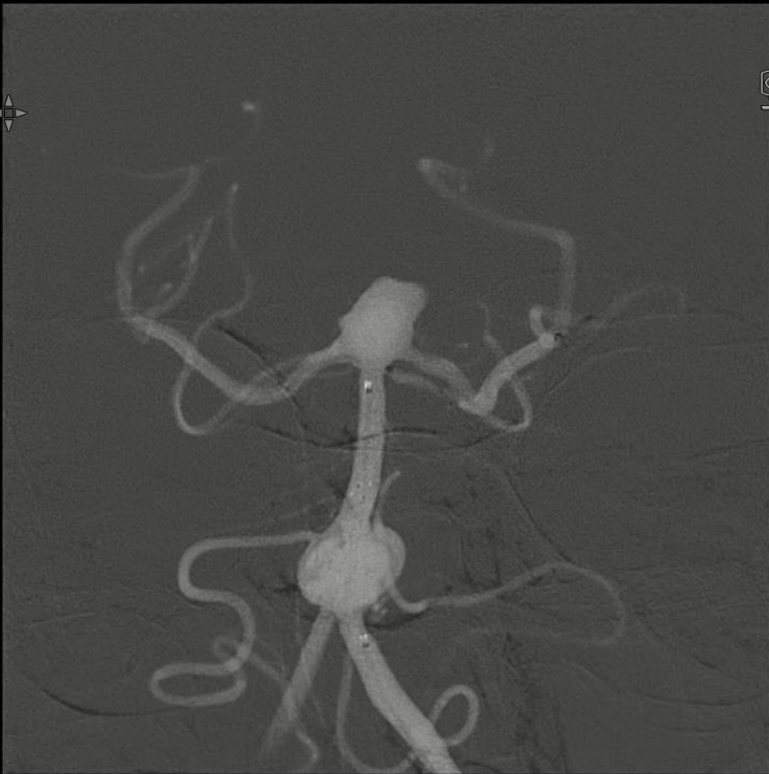

4 9.6
 mA

7°
 8°
 +1
 113
 15

2
 M 12.5fr
 36.1
 24.5
 mGy/min
 26.2
 mGycm²/s
 896
 mGy

3:02PM

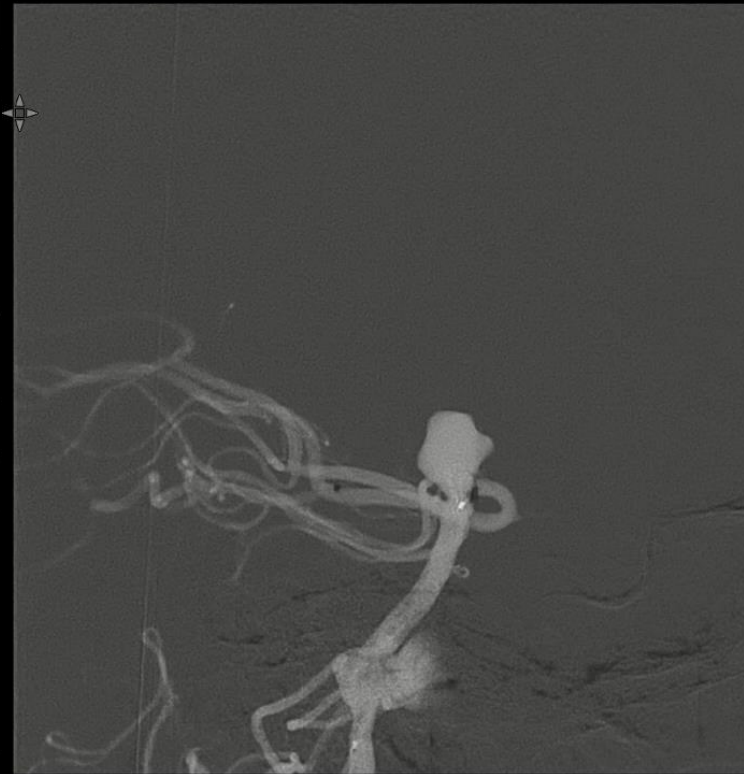

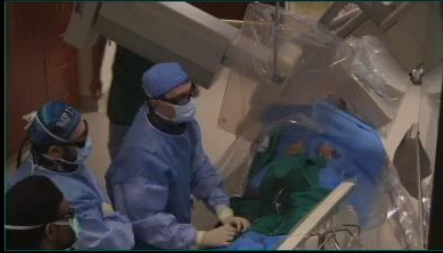76 8.7
 kV mA

RAO 89°
 0°
 SID 109
 cm
 FD 19
 cm

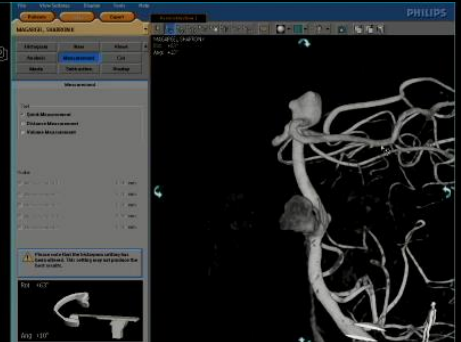
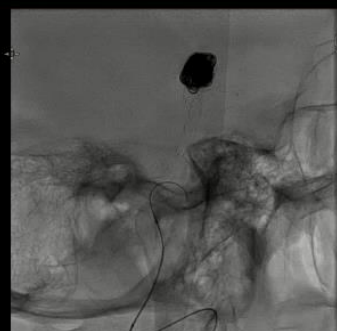
2
 fps

Time 25.2
 min
 K 11.5
 mGy/min
 K 432
 mGy

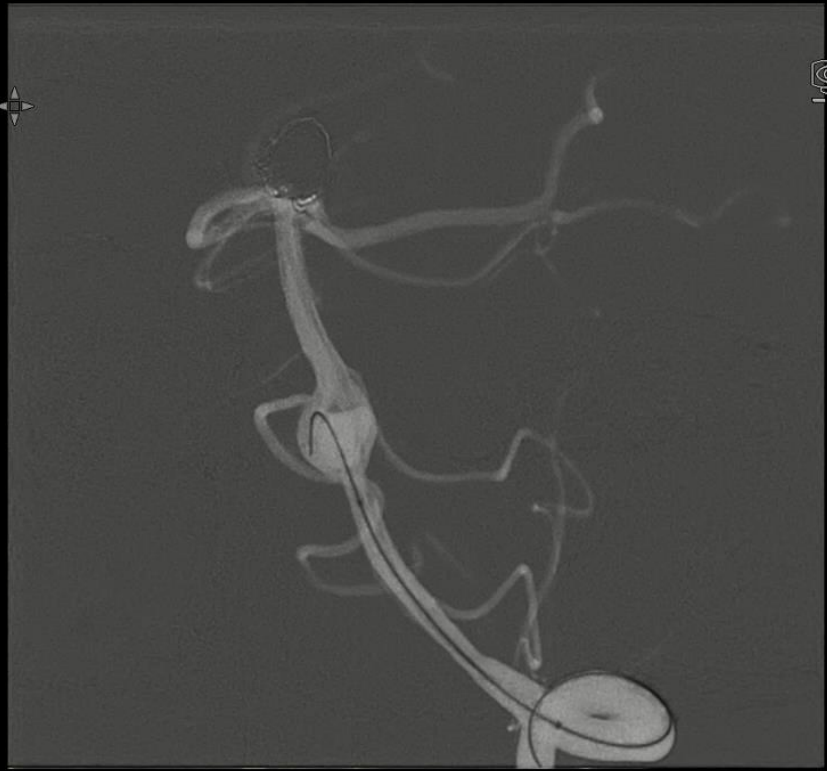




MARGARET STRANDBOM K
2205073
071211495
0412770017



0.7
mA
45
2
+1
106
15
2
12.5fr
51.4
16.2
mGy/min
22.6
mGycm²/s
1423
mGy



85 9.4
kW mA
RAO 68
0
SID 109
cm
FD 15
cm
2
fps
Time 39.8
min
K 19.1
mGy/min
K 748
mGy

