

# MAV DURAL

## DEFINICION OF DURAL AVF

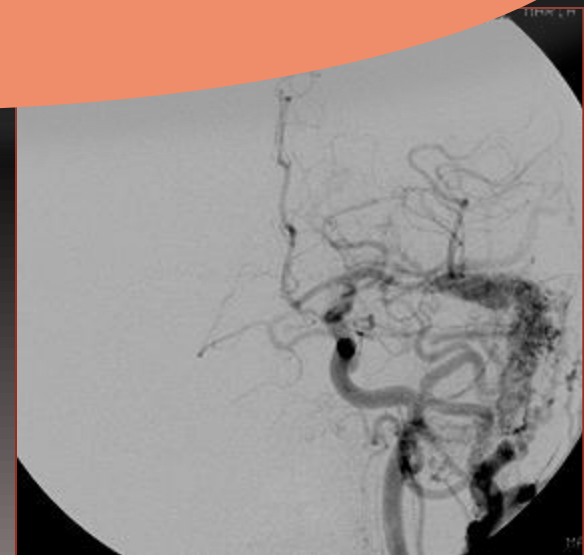
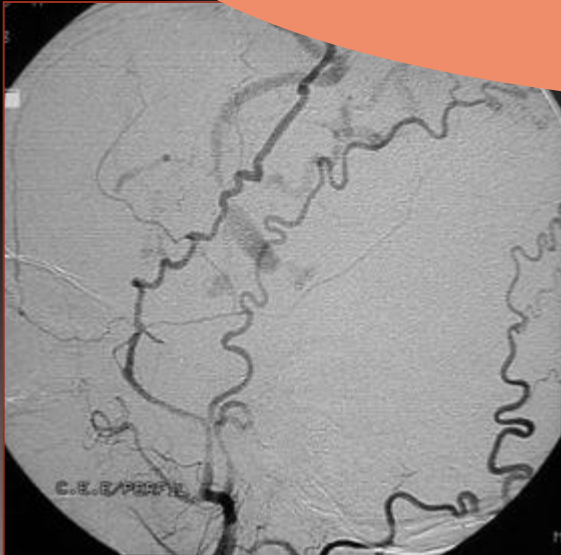
Shunt located in dura mater on the surface of brain

Shunt located in dura mater involving the dural sinus

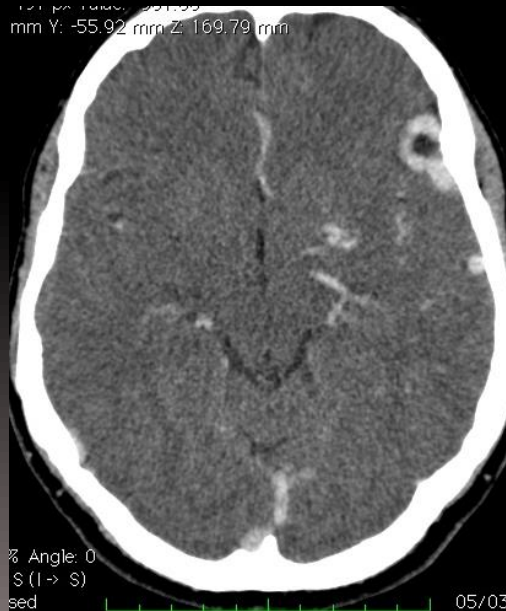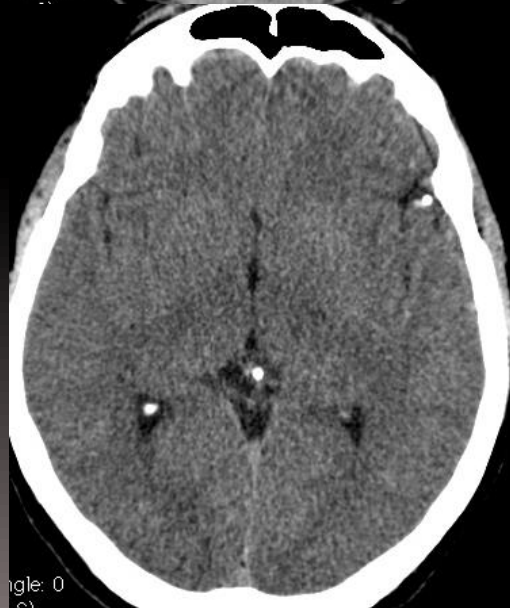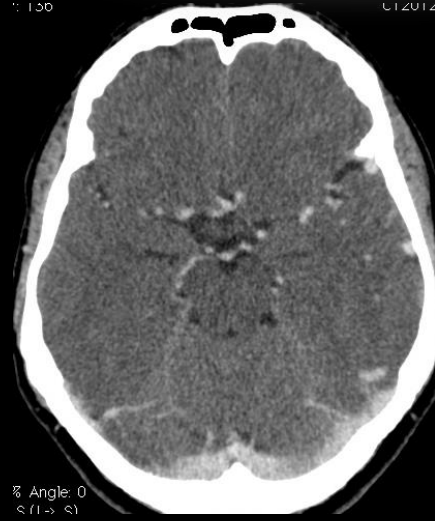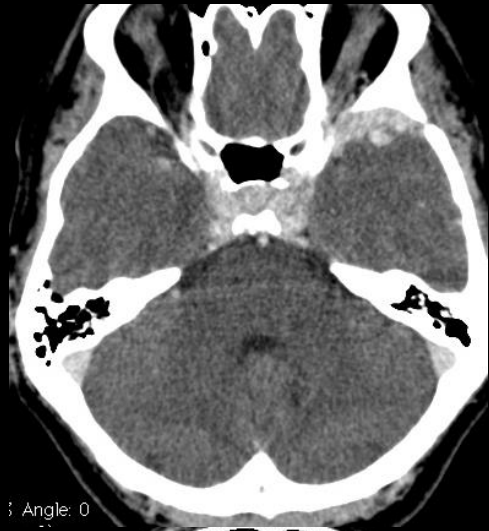
meningeal  
cortical vein

Elimination of venous hypertension  
Always associated with reflux to cortical vein

ral

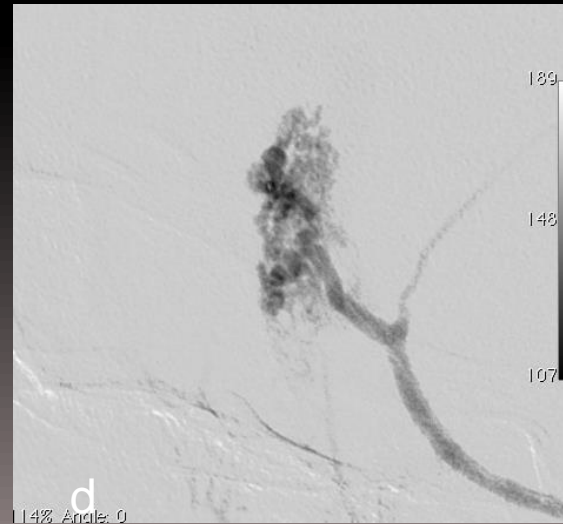
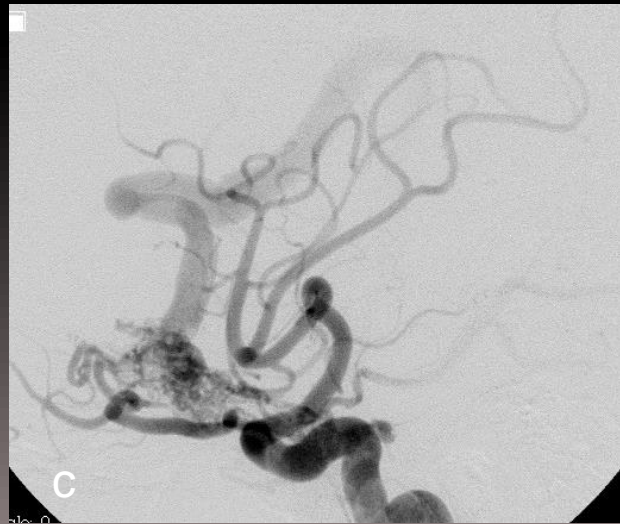
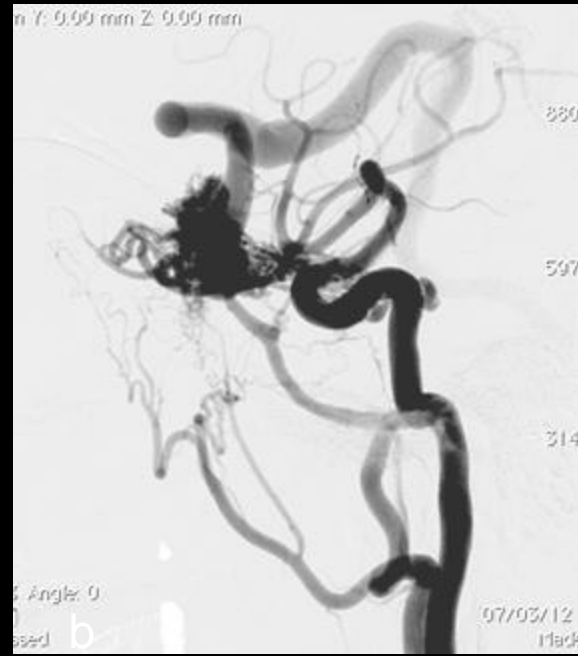
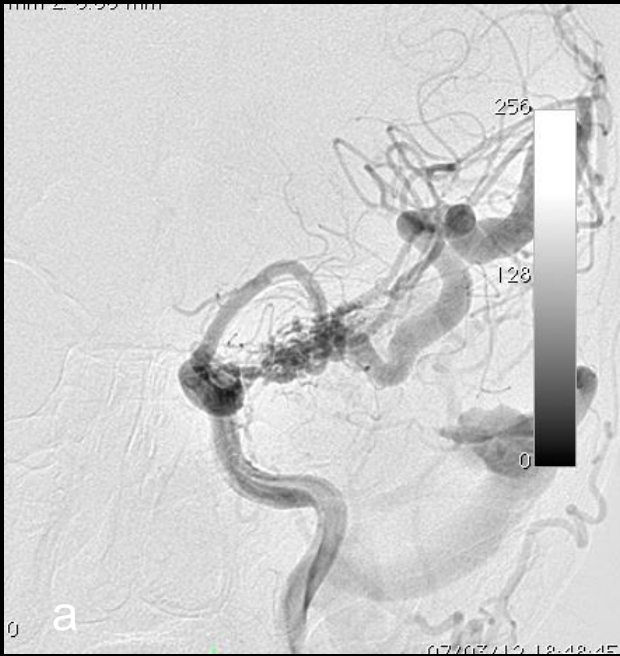# MAV DURAL

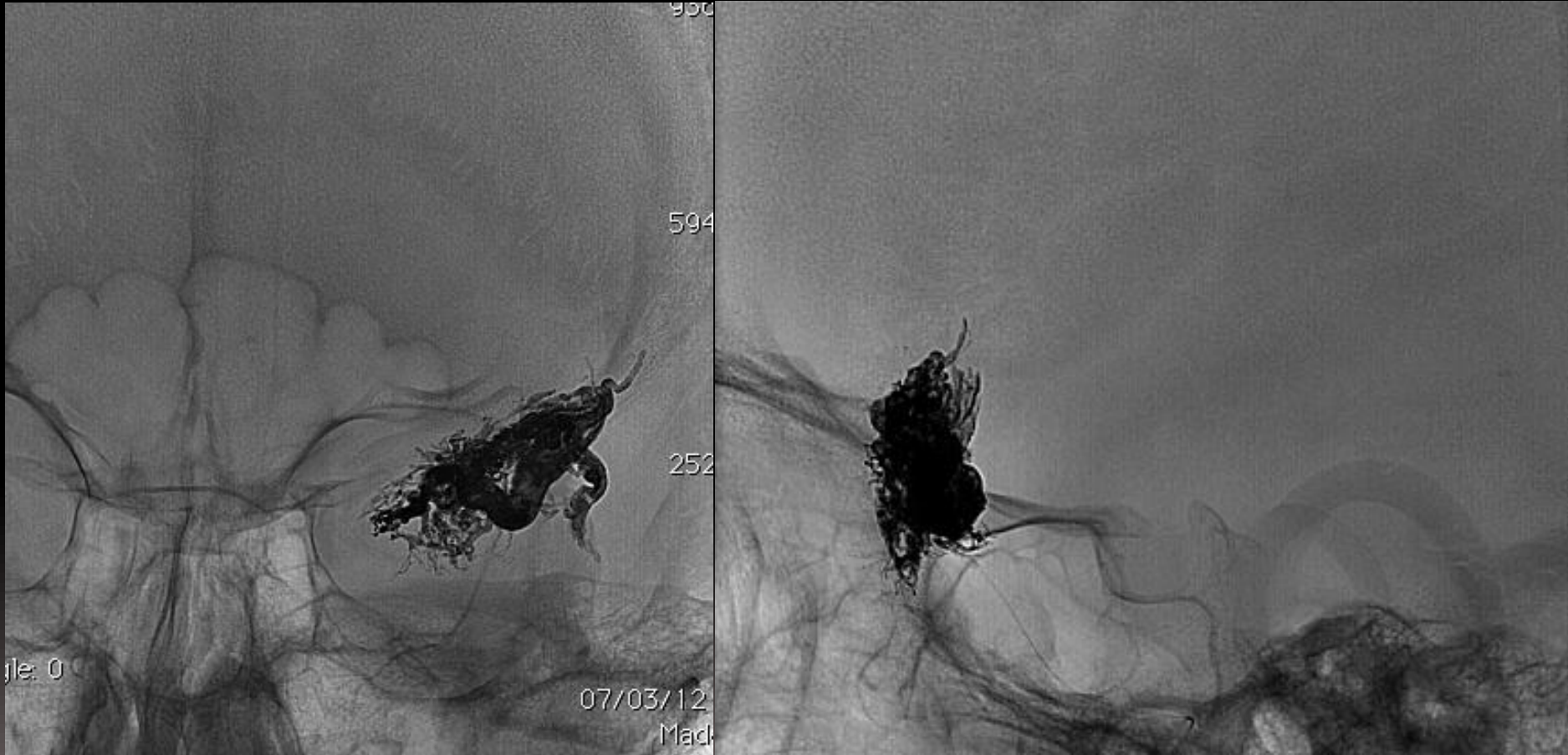


45 Y  
seizure

# DURAL AVM

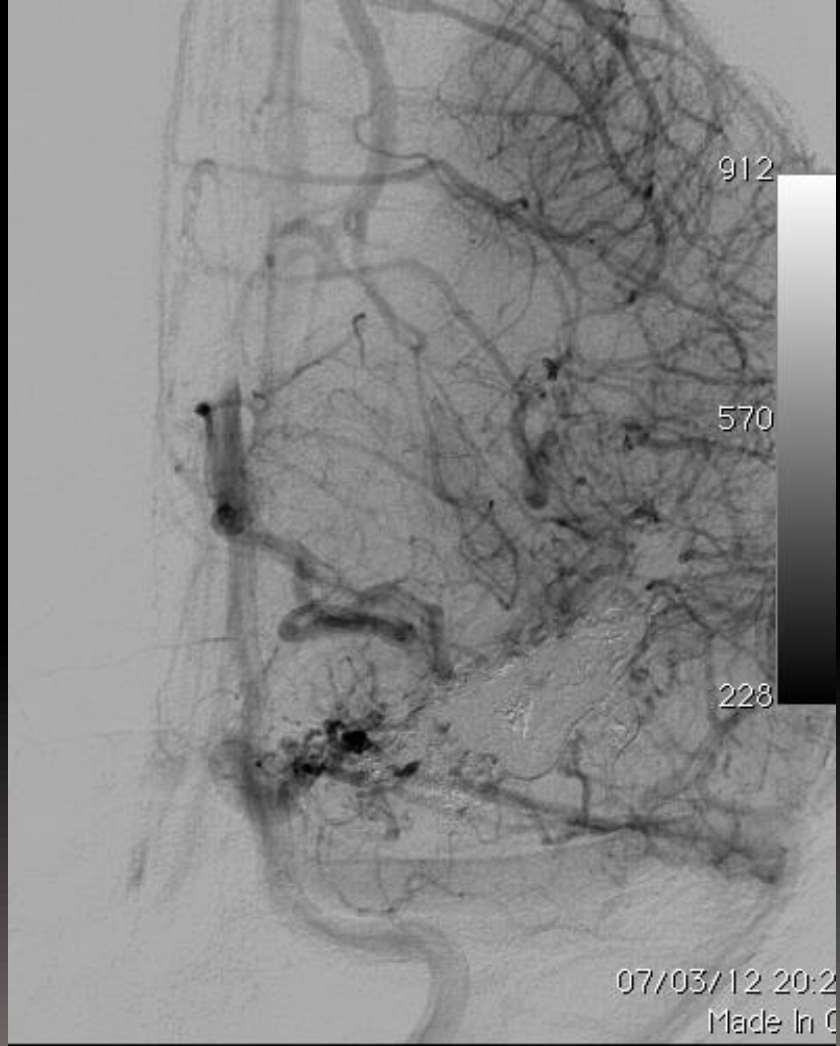
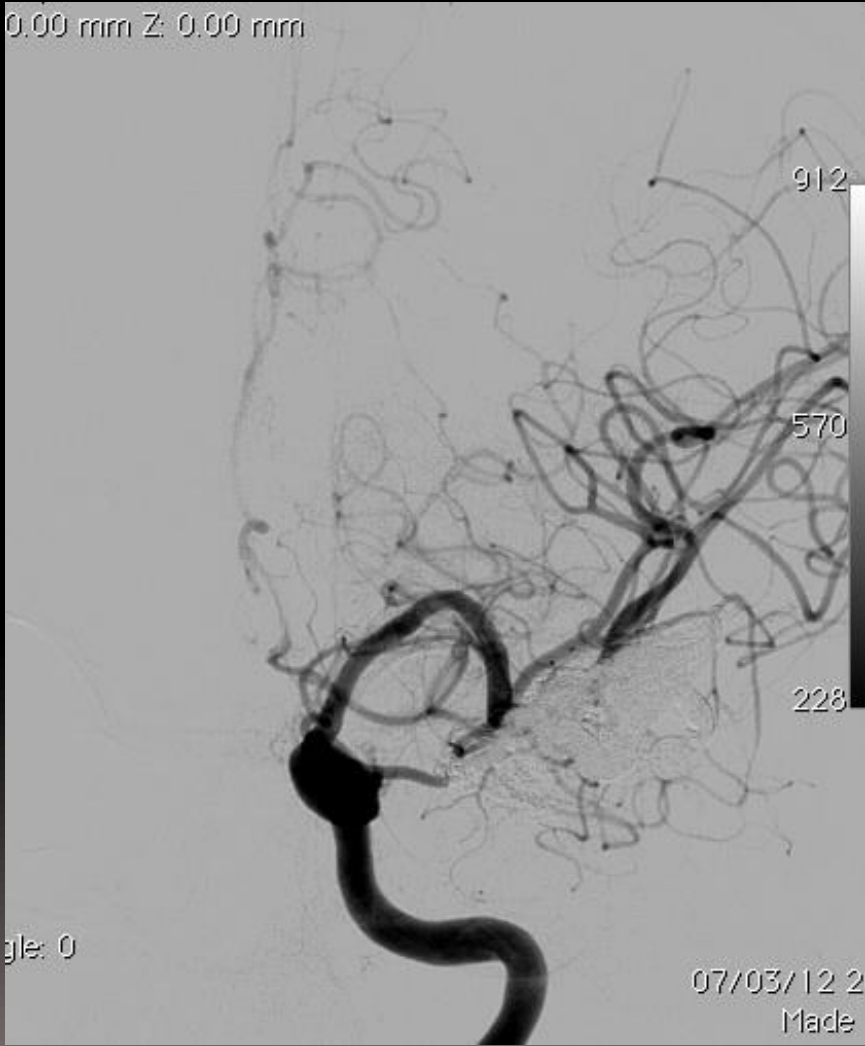

# DURAL AVM

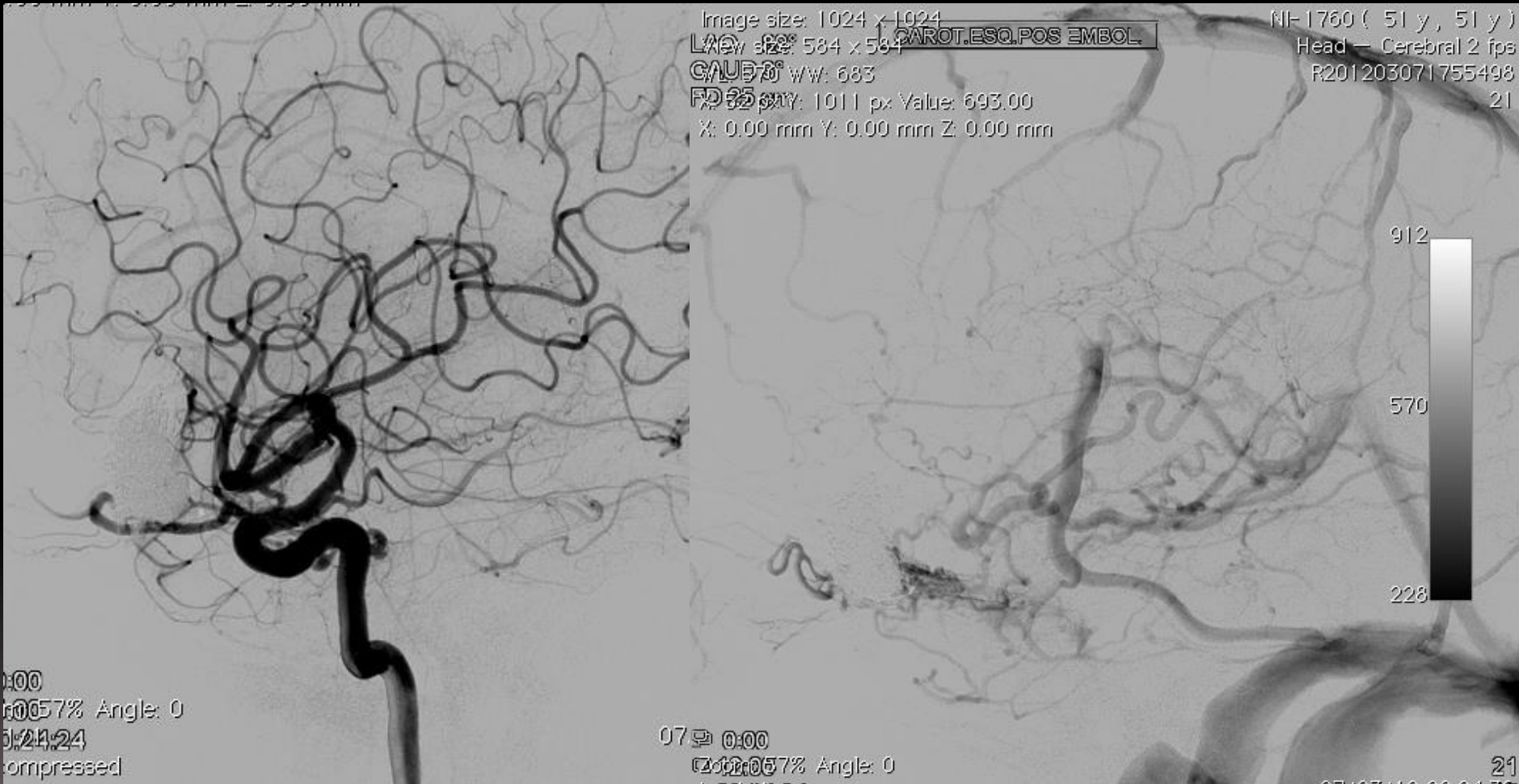




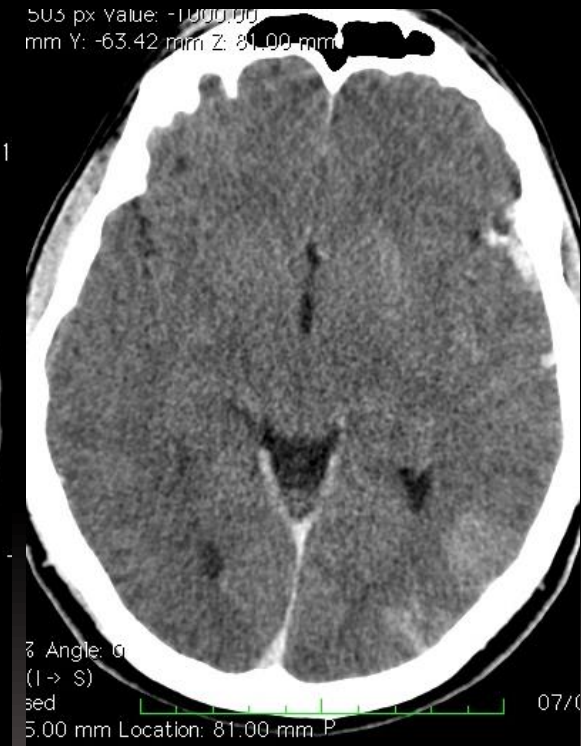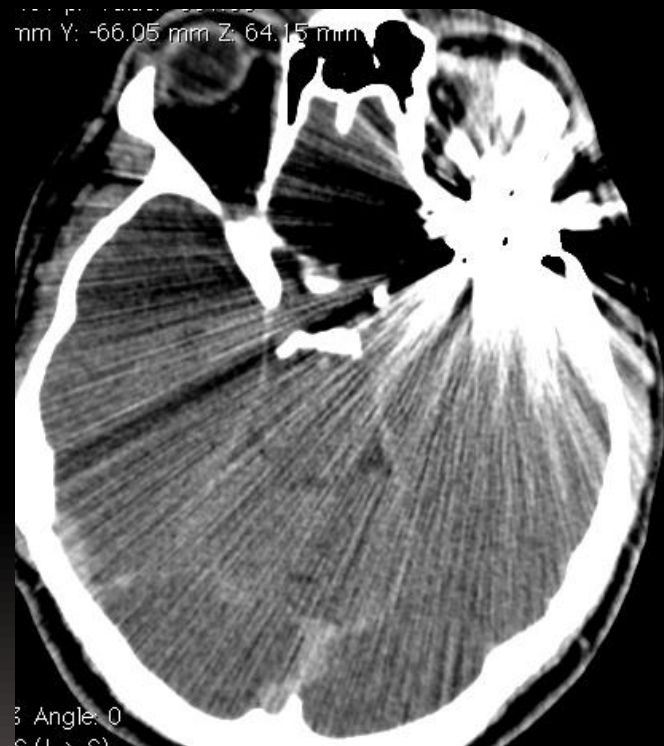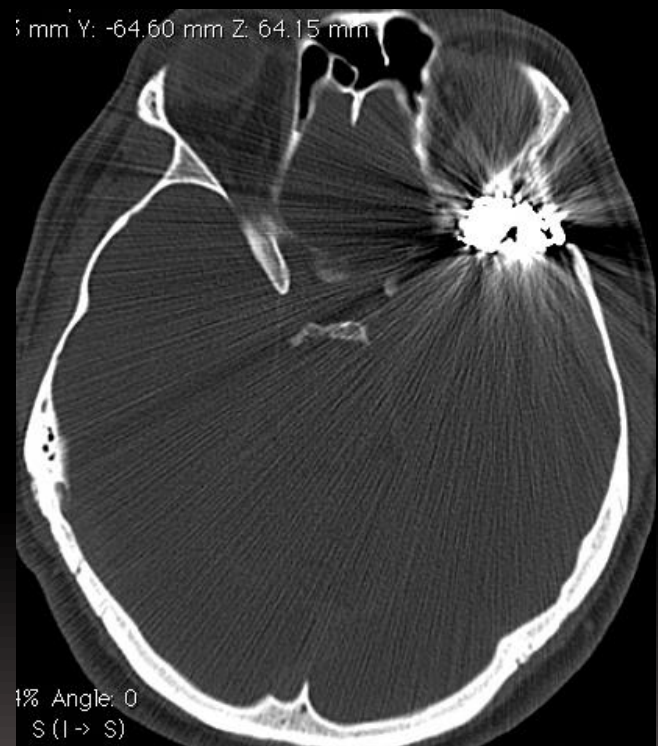# DURAL AVM



# DURAL AVM



# DURAL AVM



## DURAL AVM

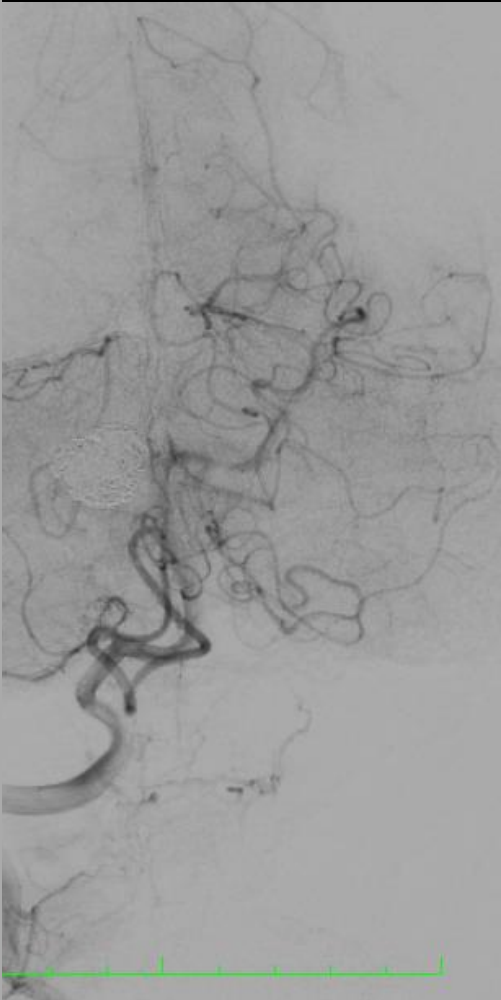
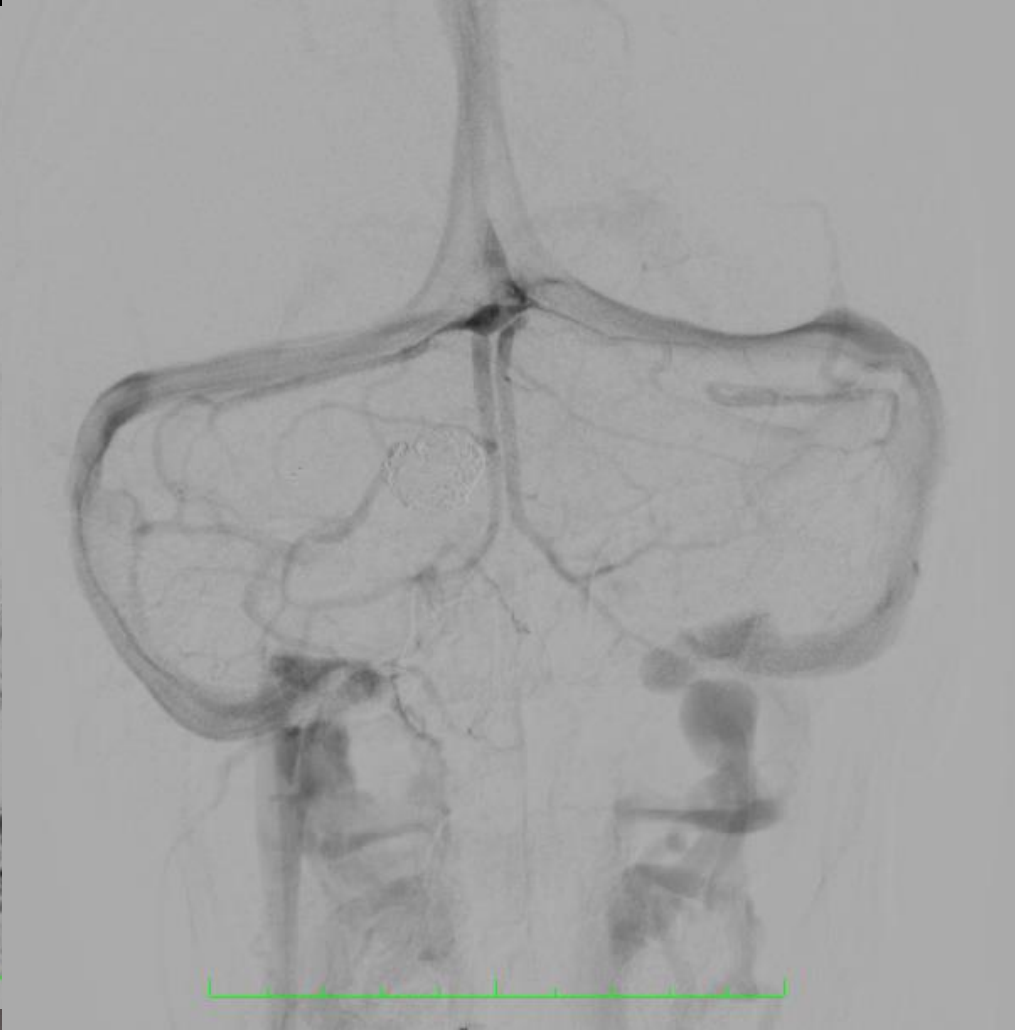
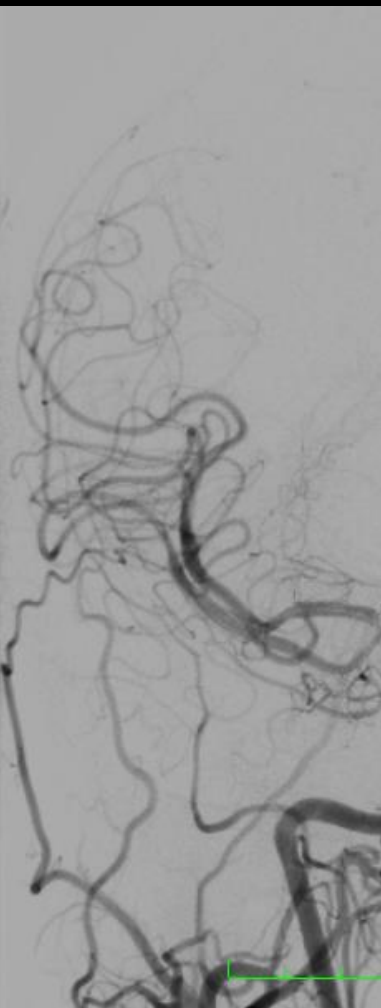Paciente CRB, sexo feminino, 29 anos.

Perda progressiva da acuidade auditiva OE

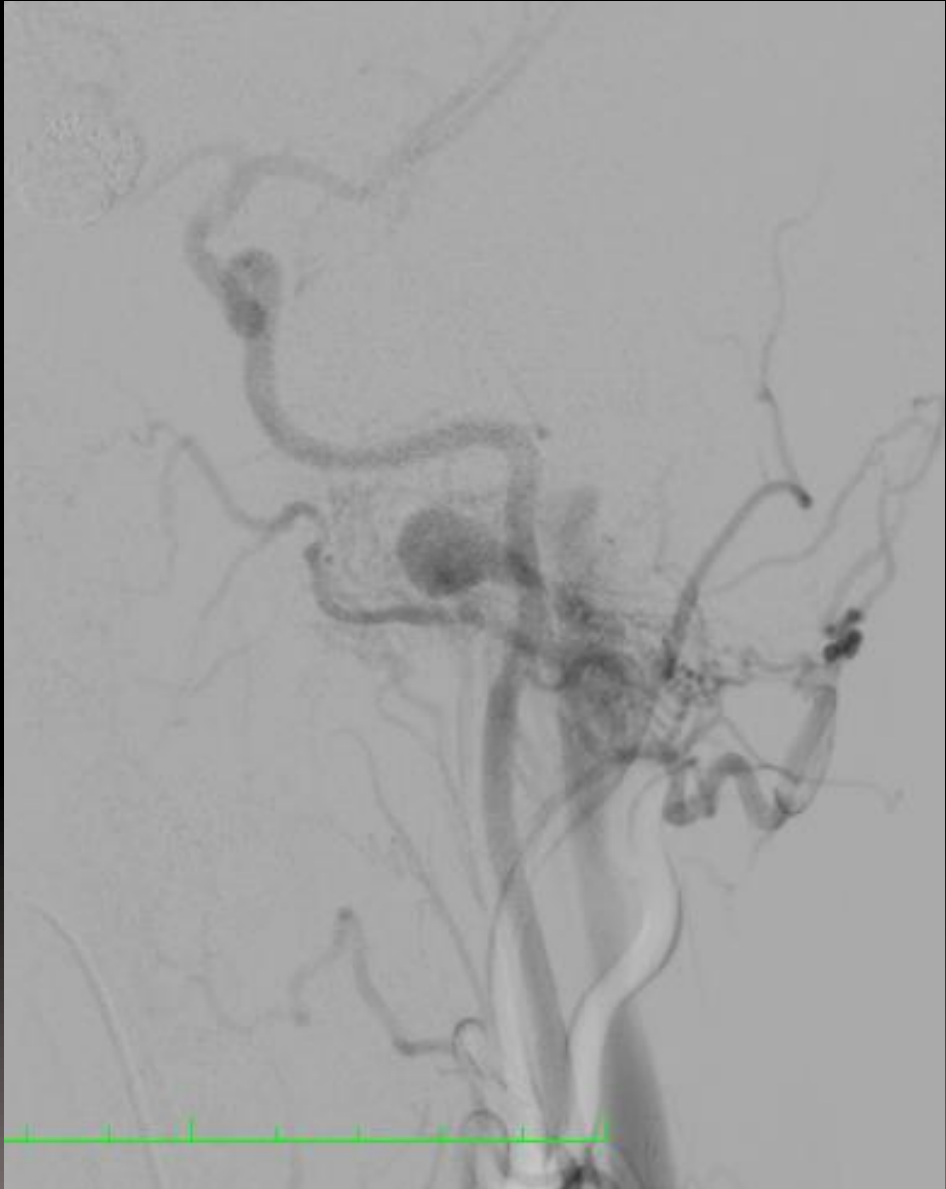
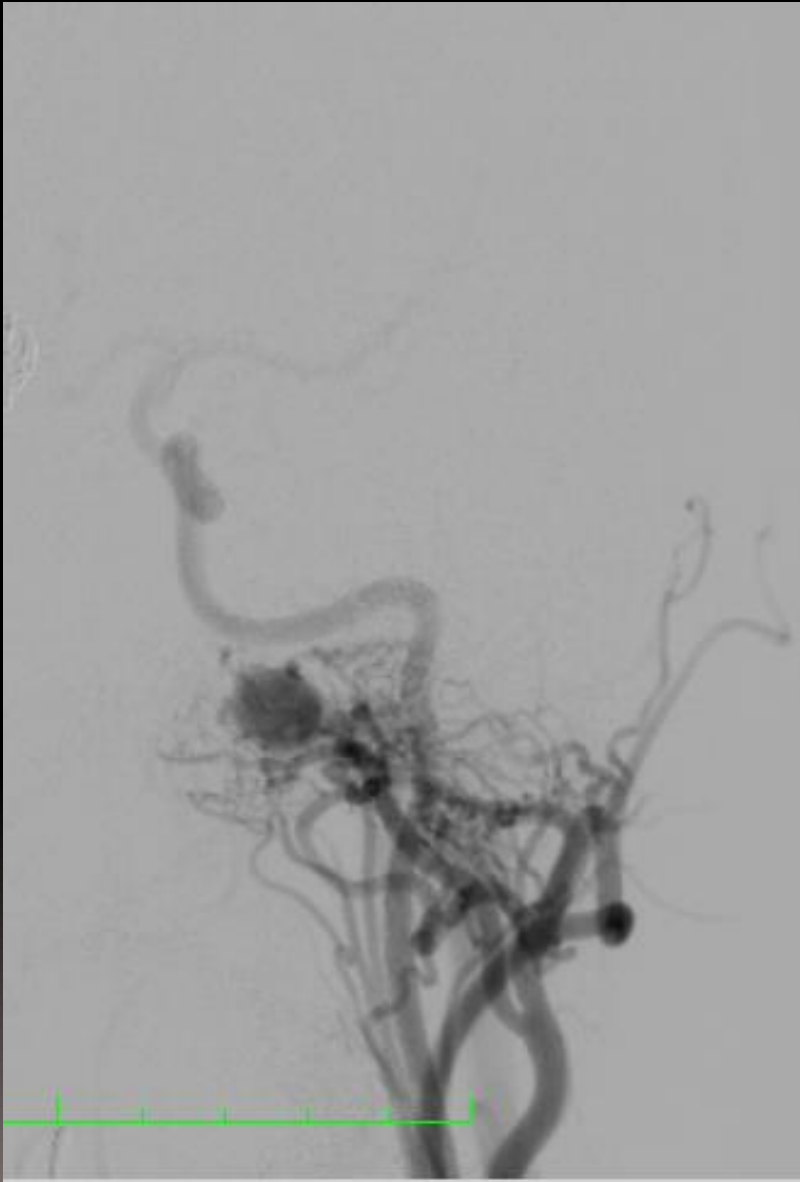
Hipoacusia E.



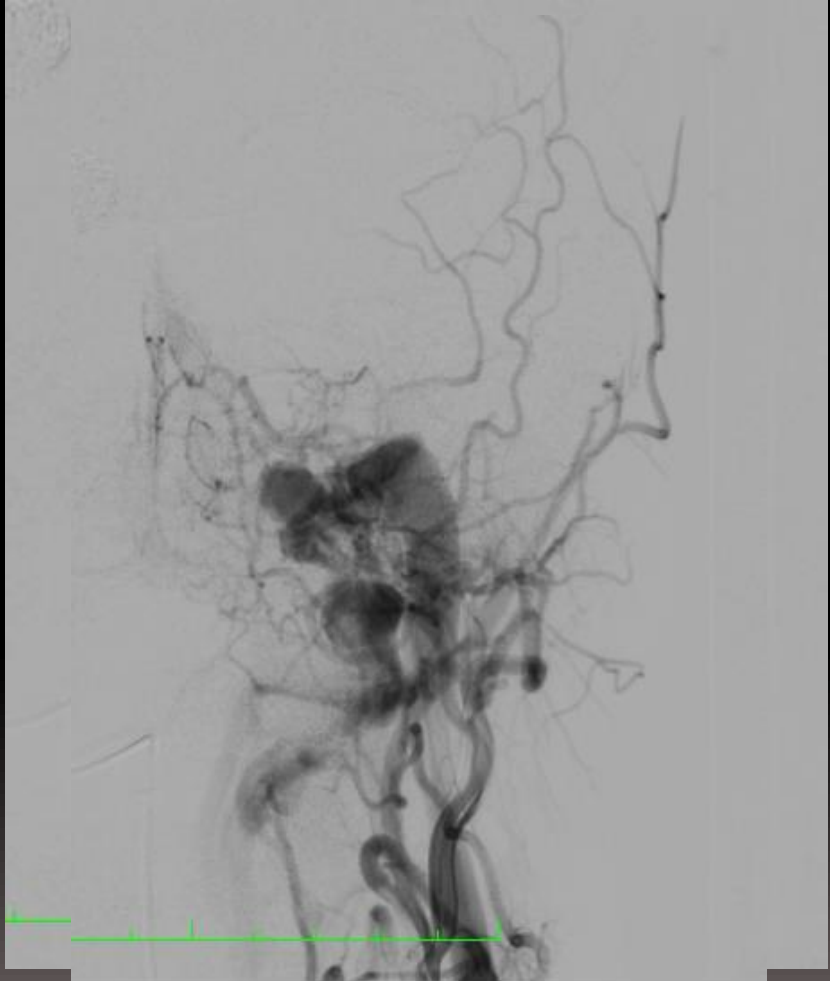
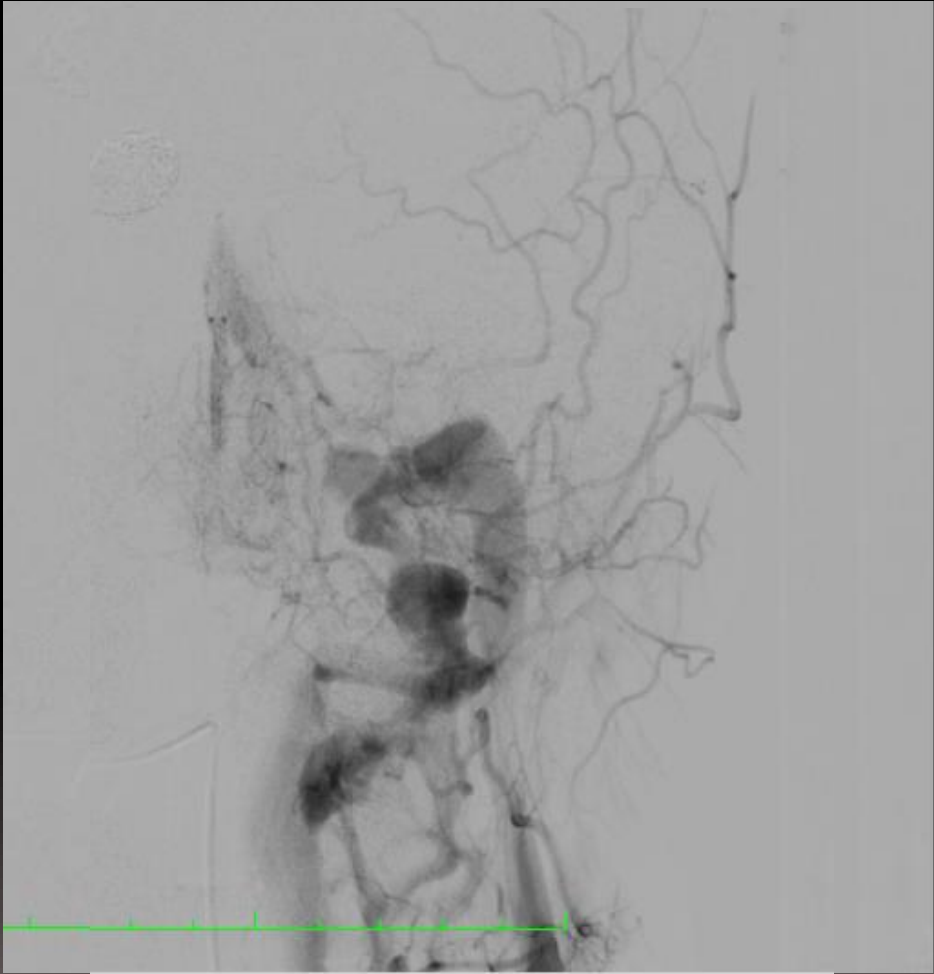
# DURAL AVM



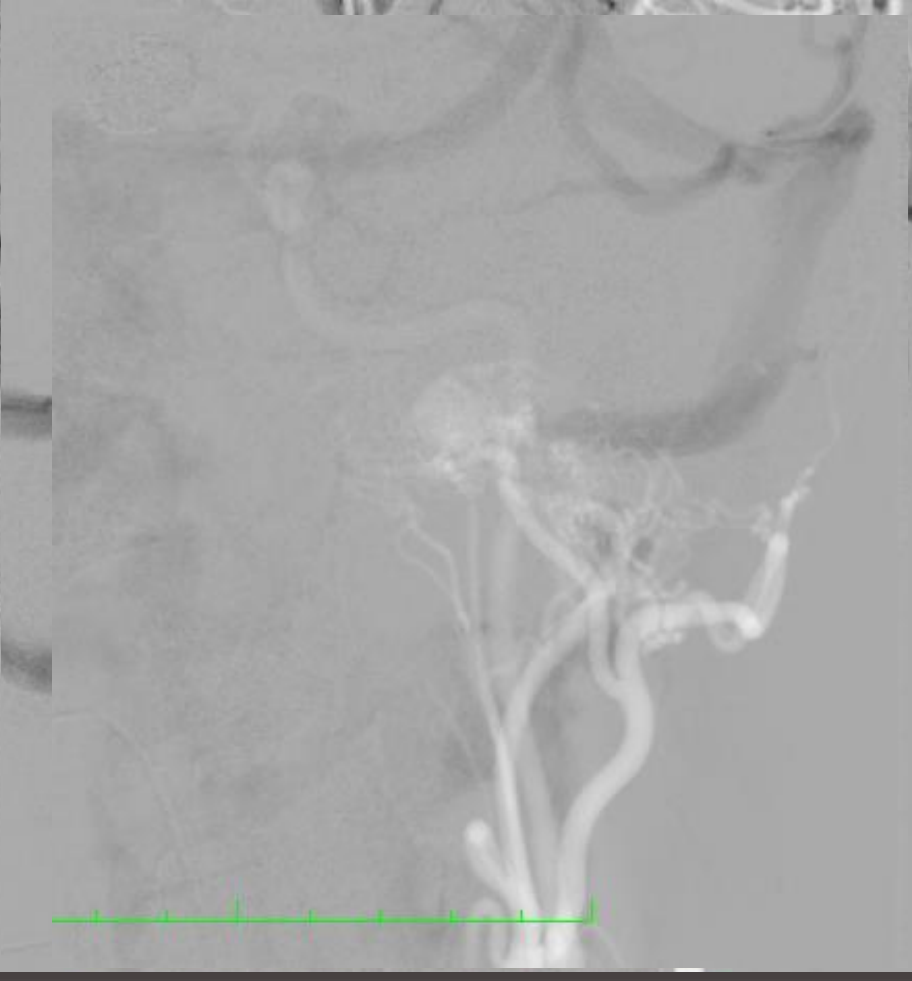
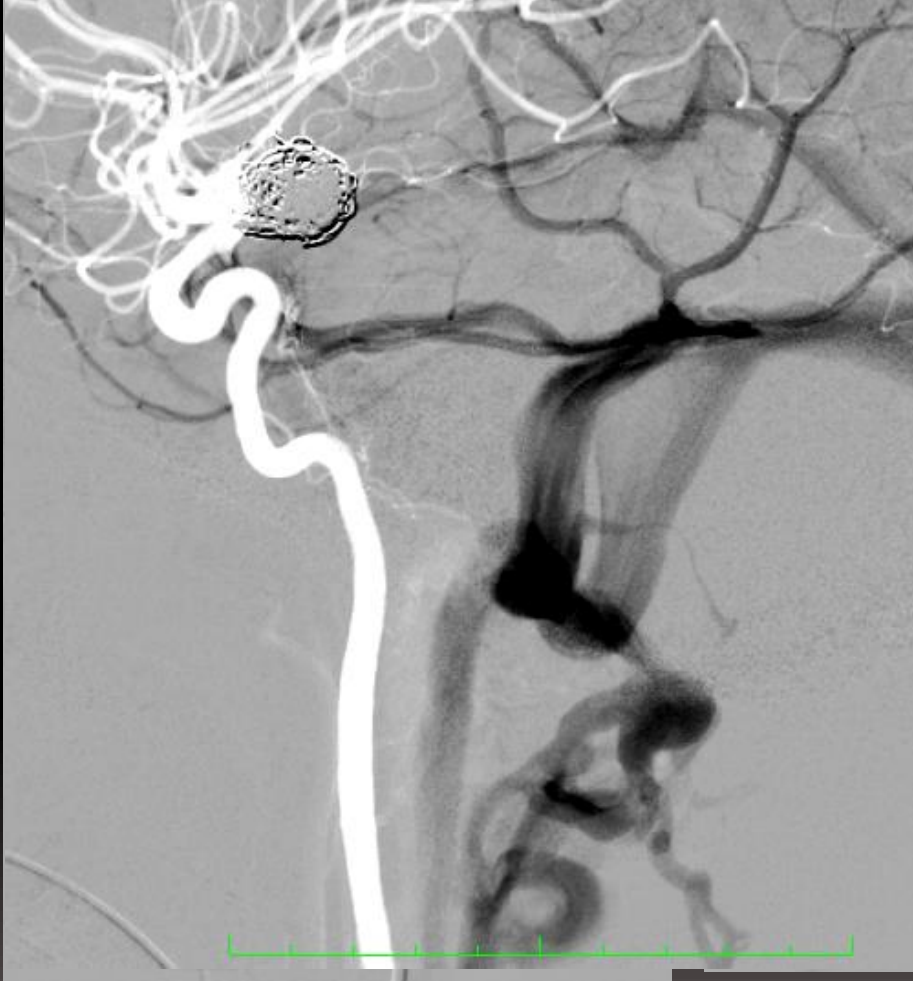**DURAL AVM**



# DURAL AVM

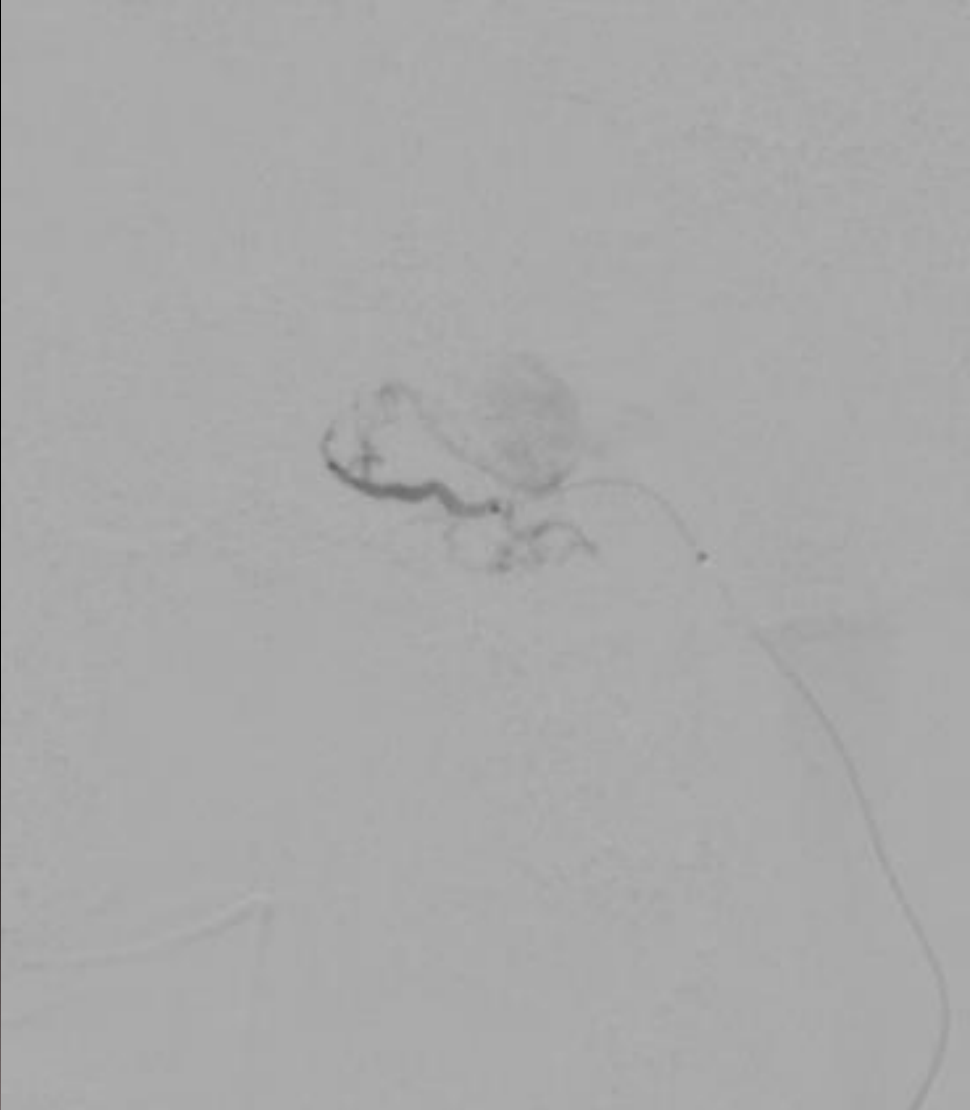
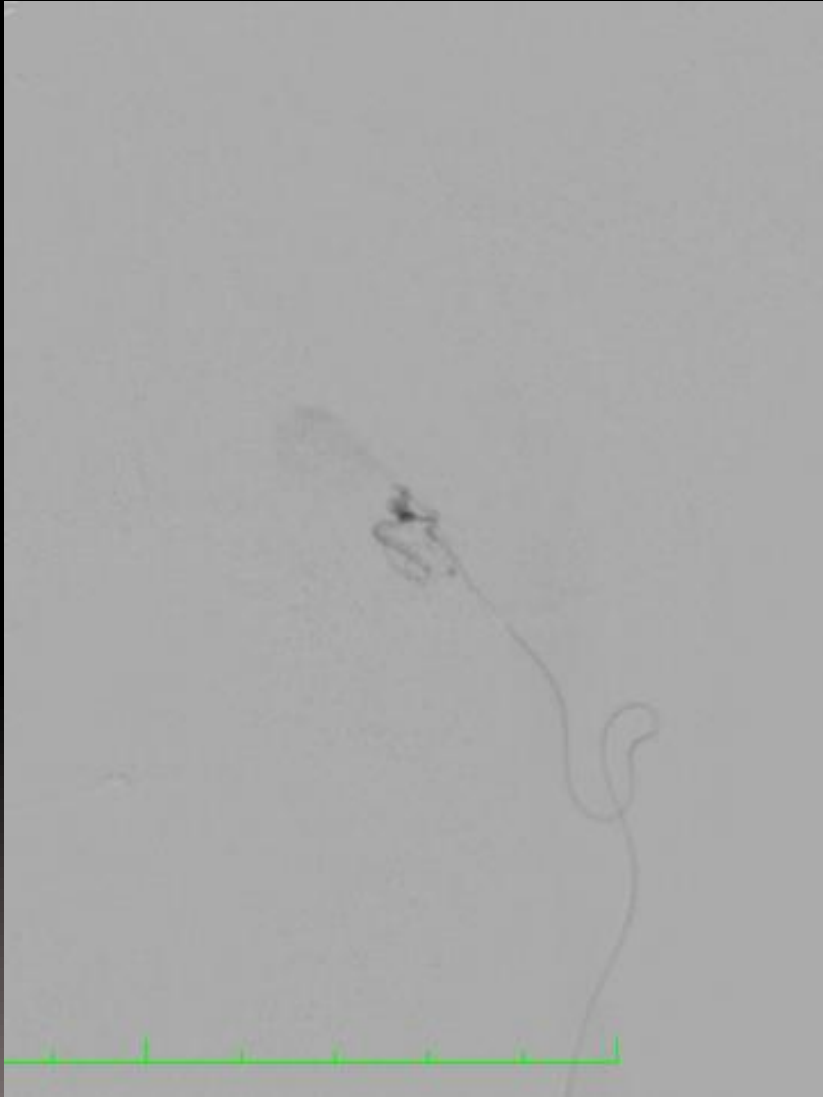


# DURAL AVM

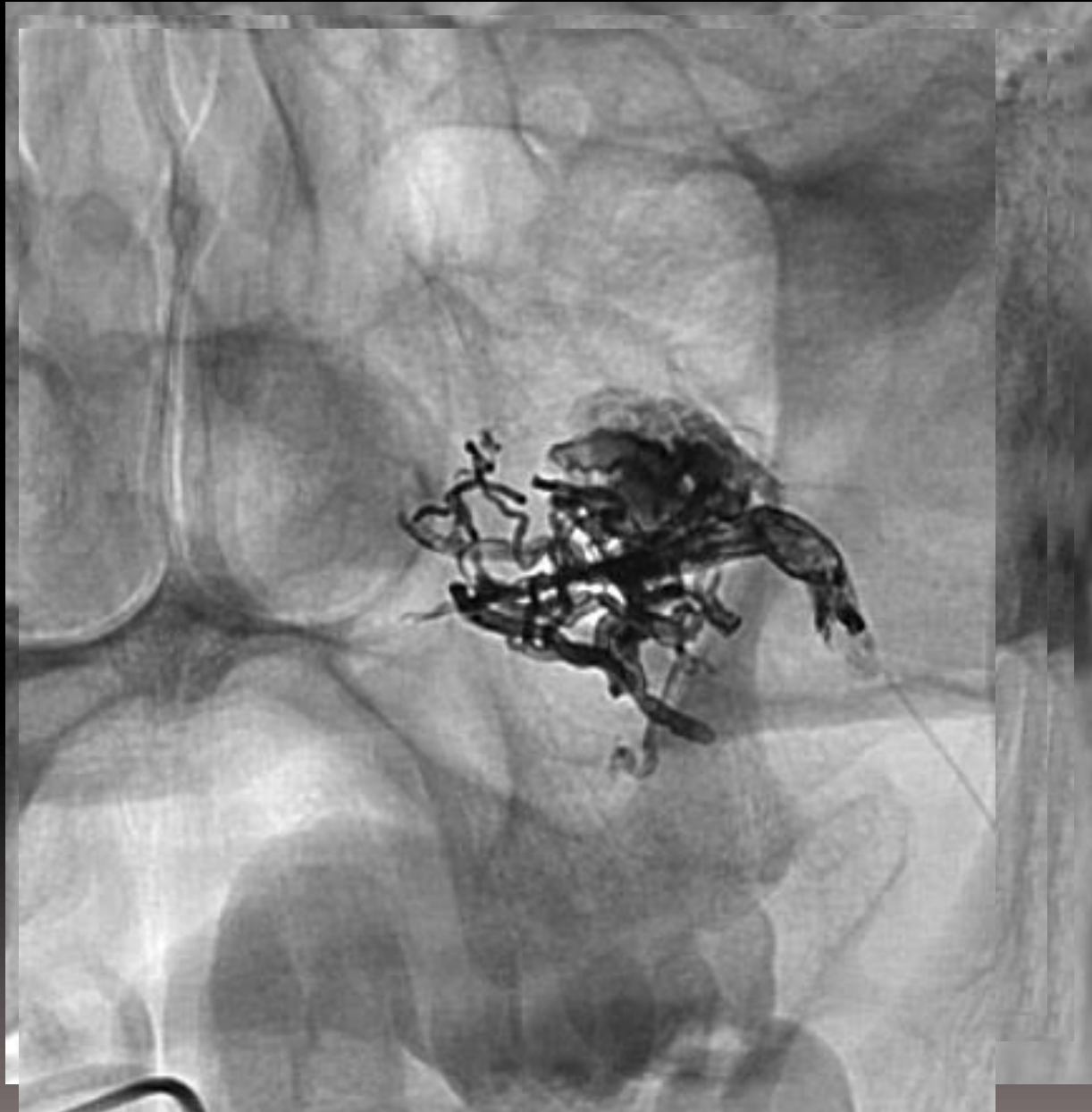



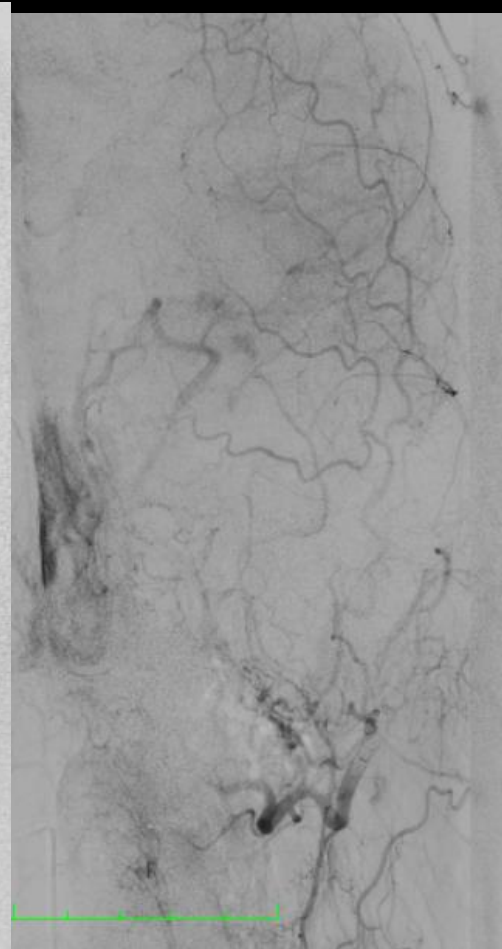
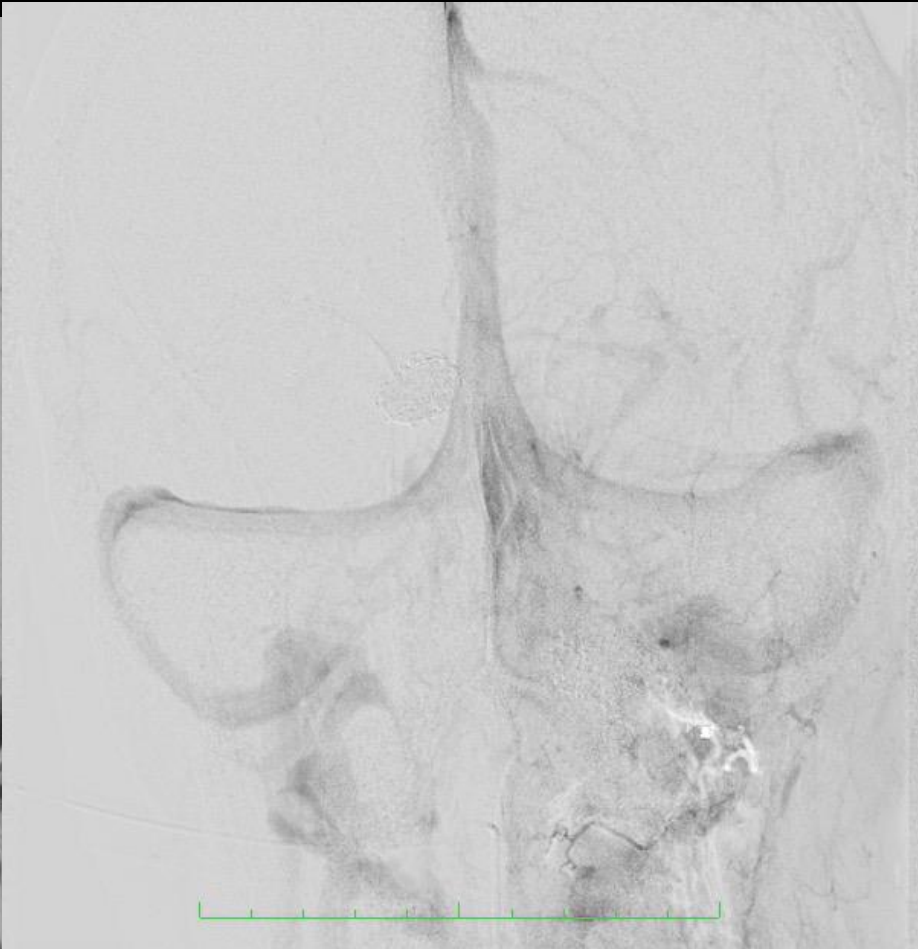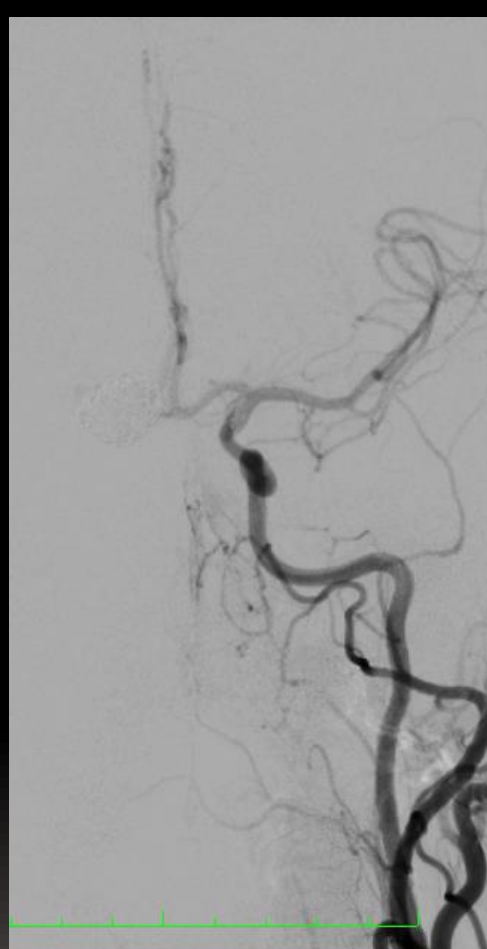
# DURAL AVM



# DURAL AVM



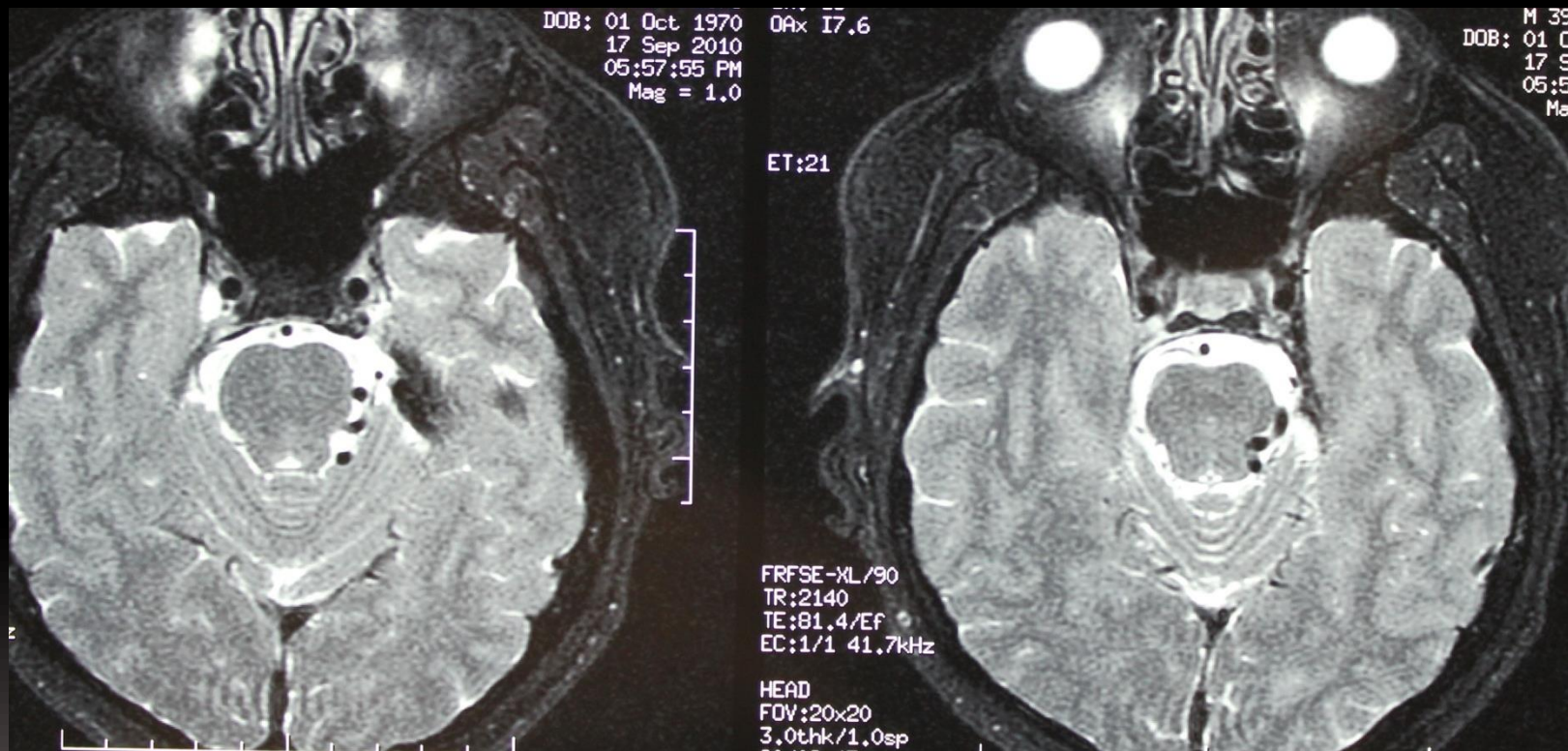
# DURAL AVM



# DURAL AVM

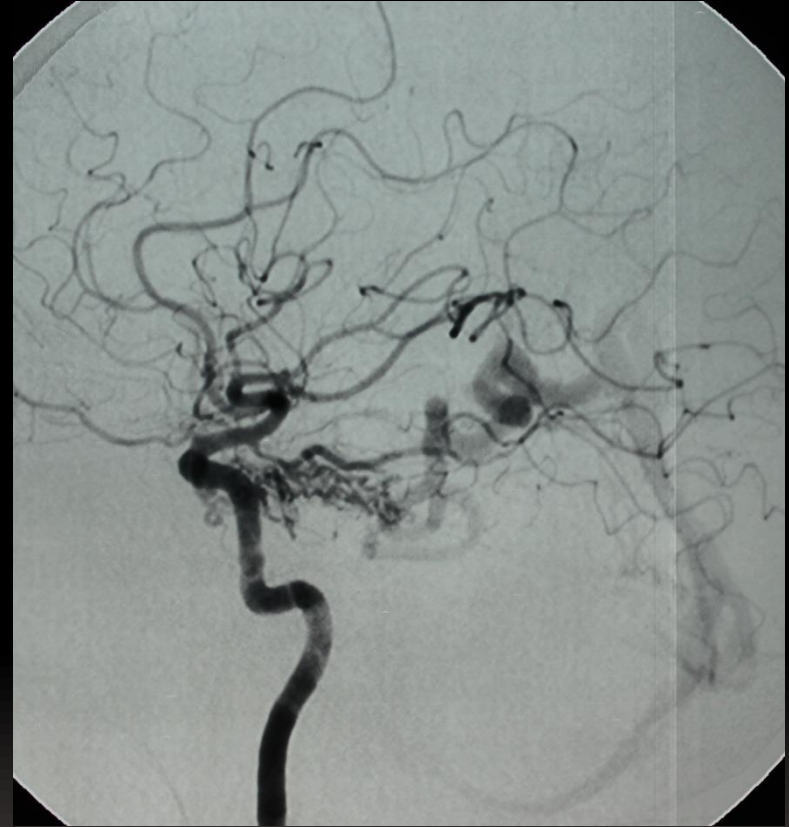
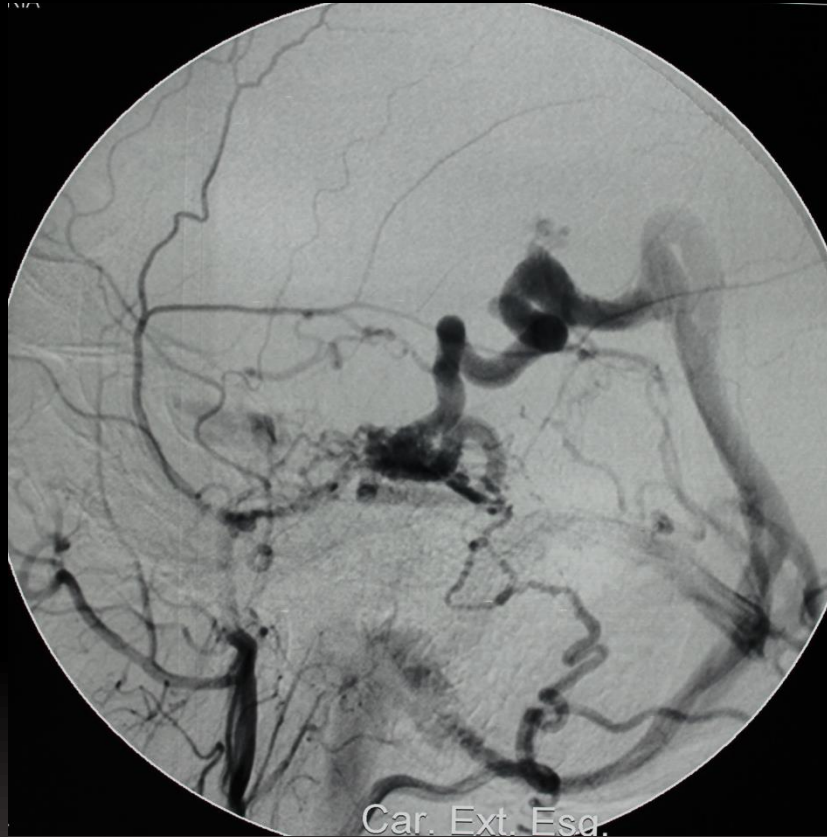**41 anos**  
**Left Trigeminal Neuralgia**

Cortesy by Jorge Campos

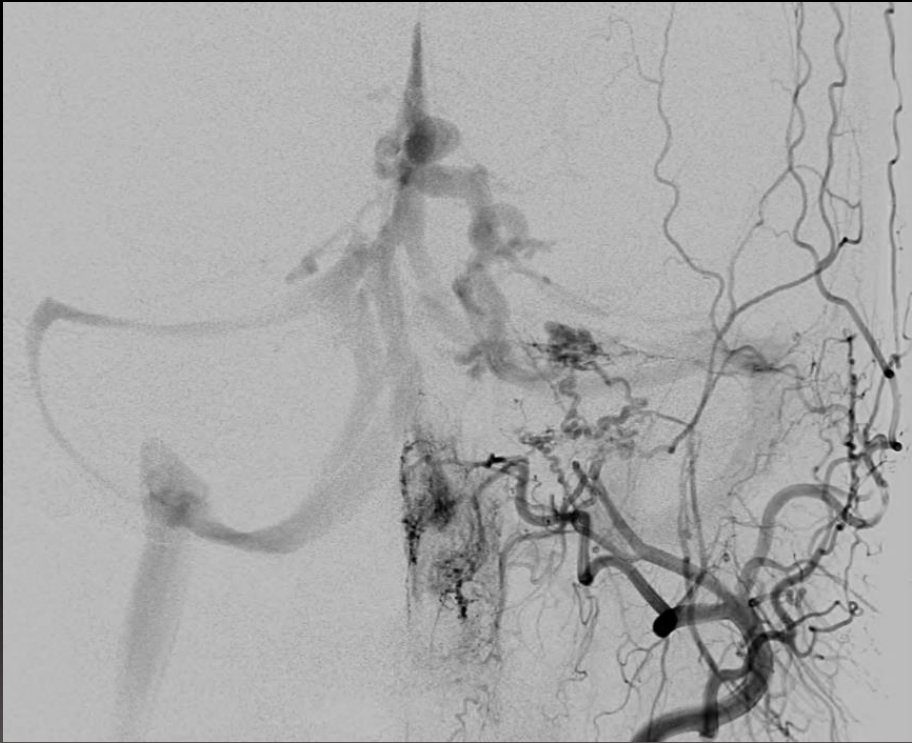
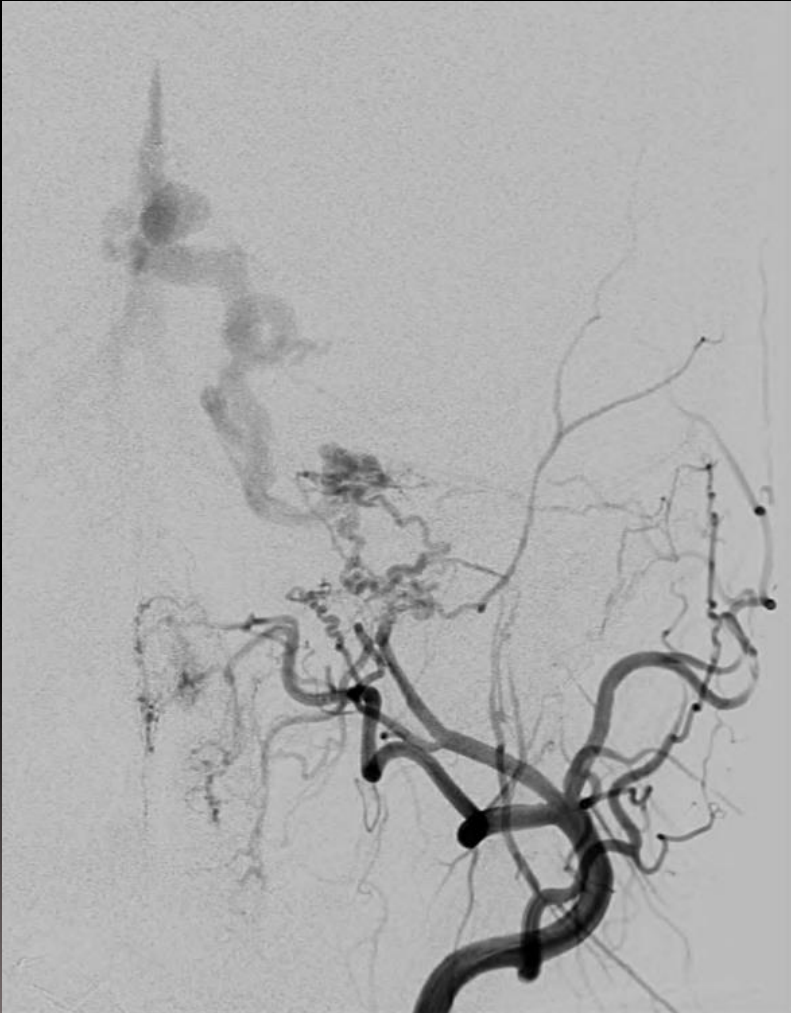




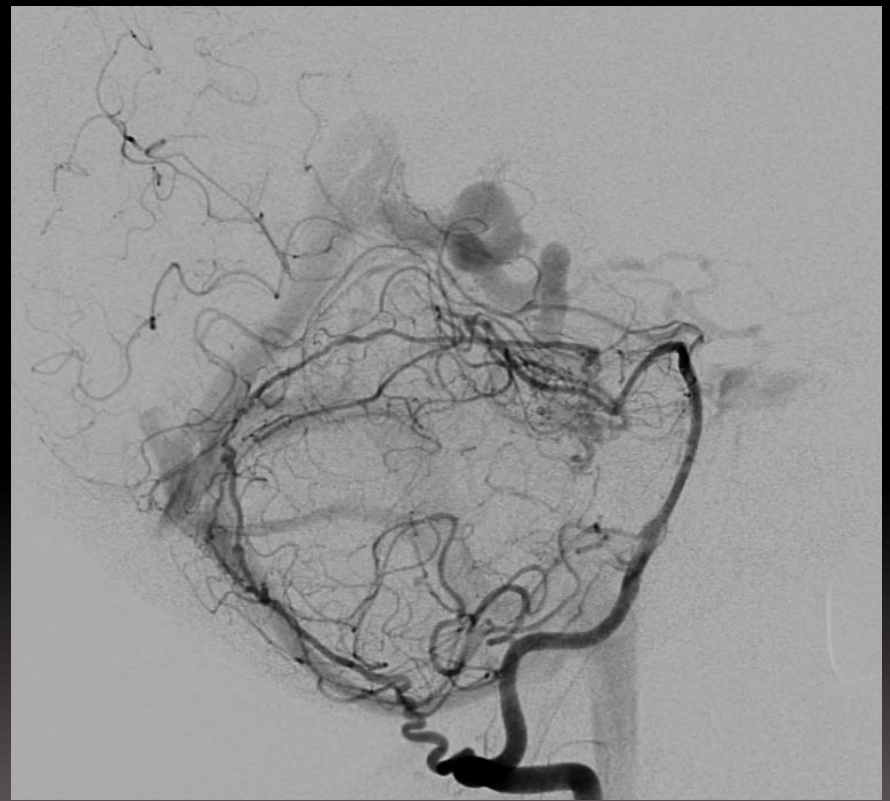
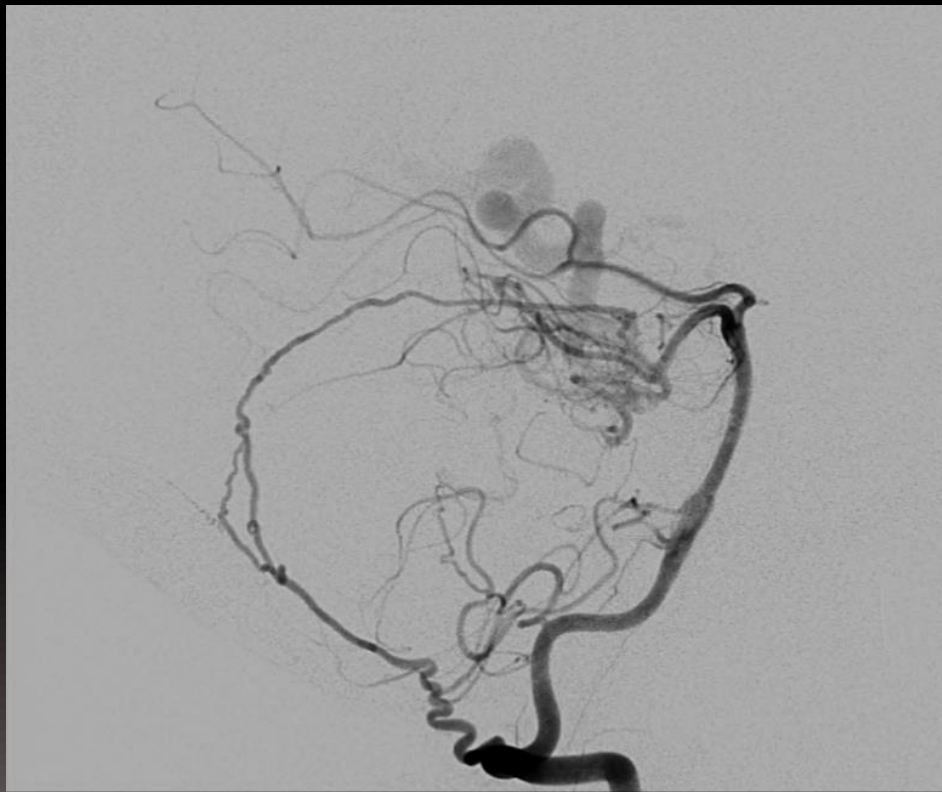
# DURAL AVM



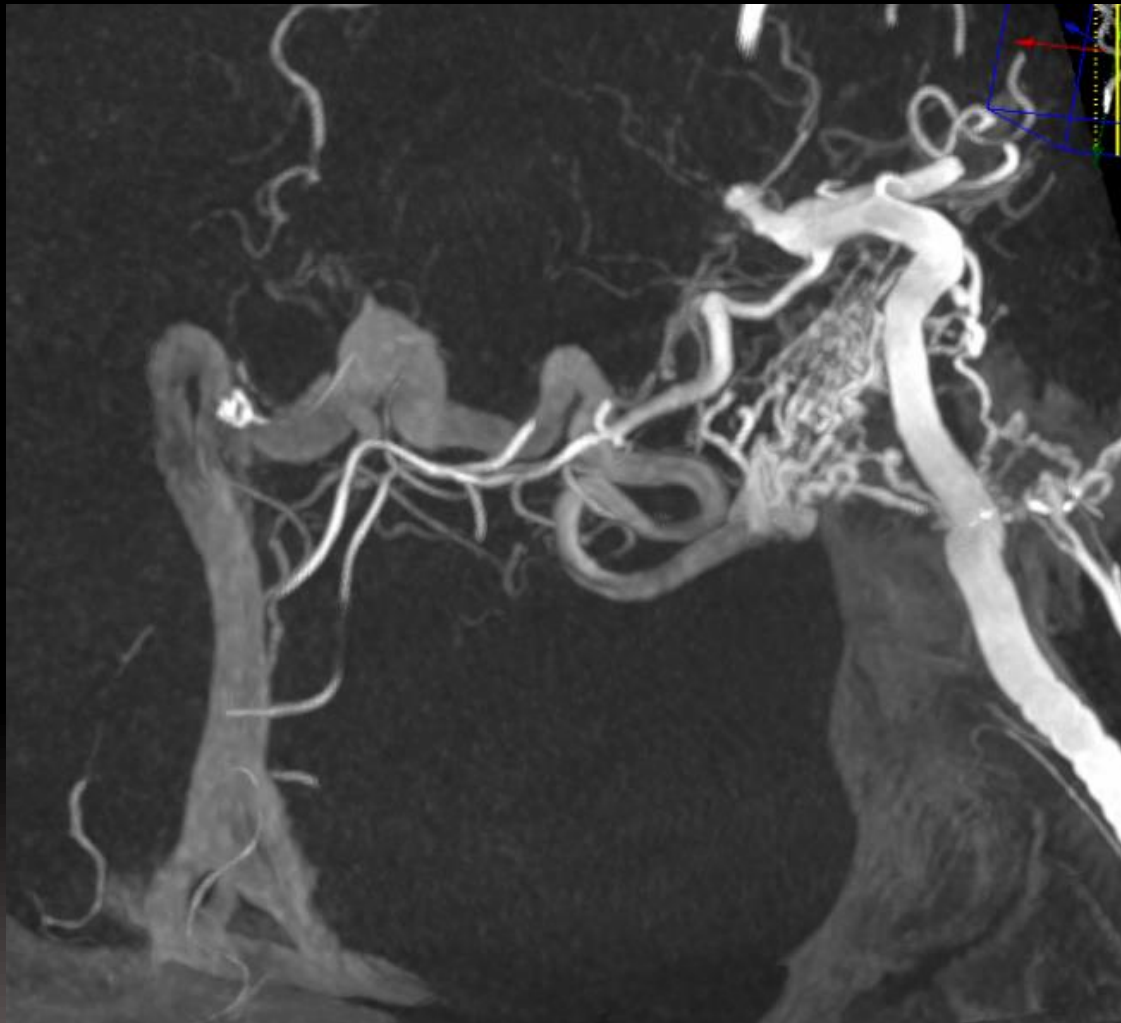
# DURAL AVM



# DURAL AVM



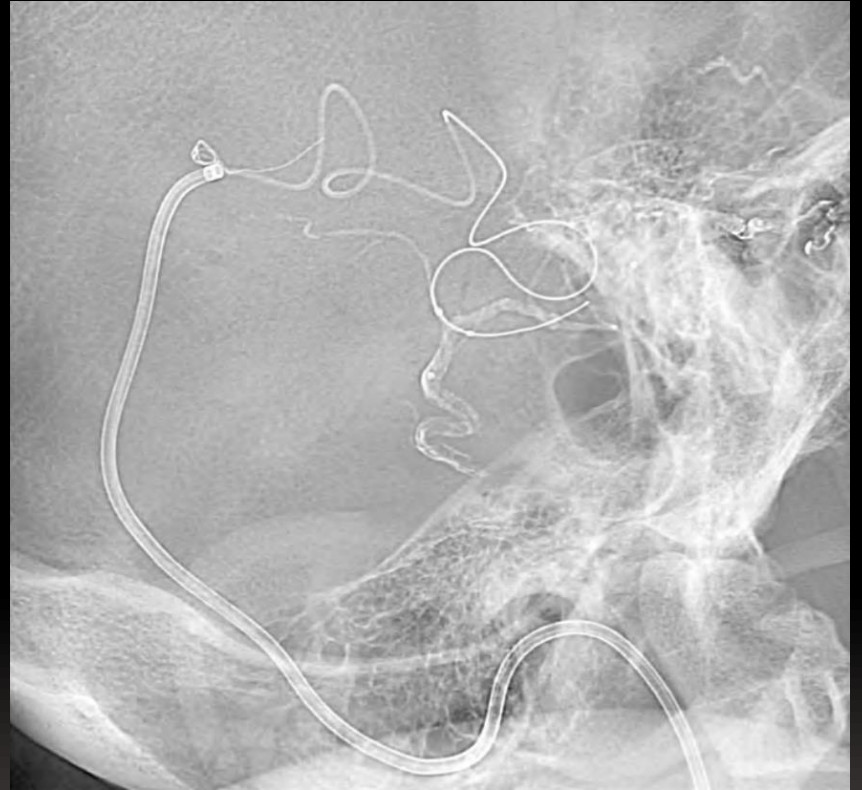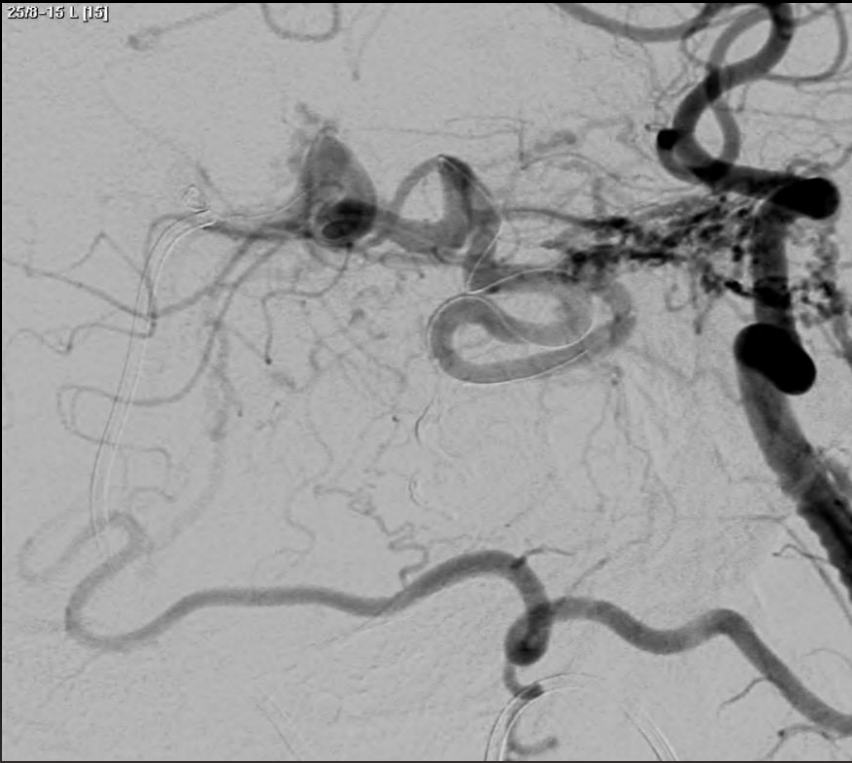# DURAL AVM



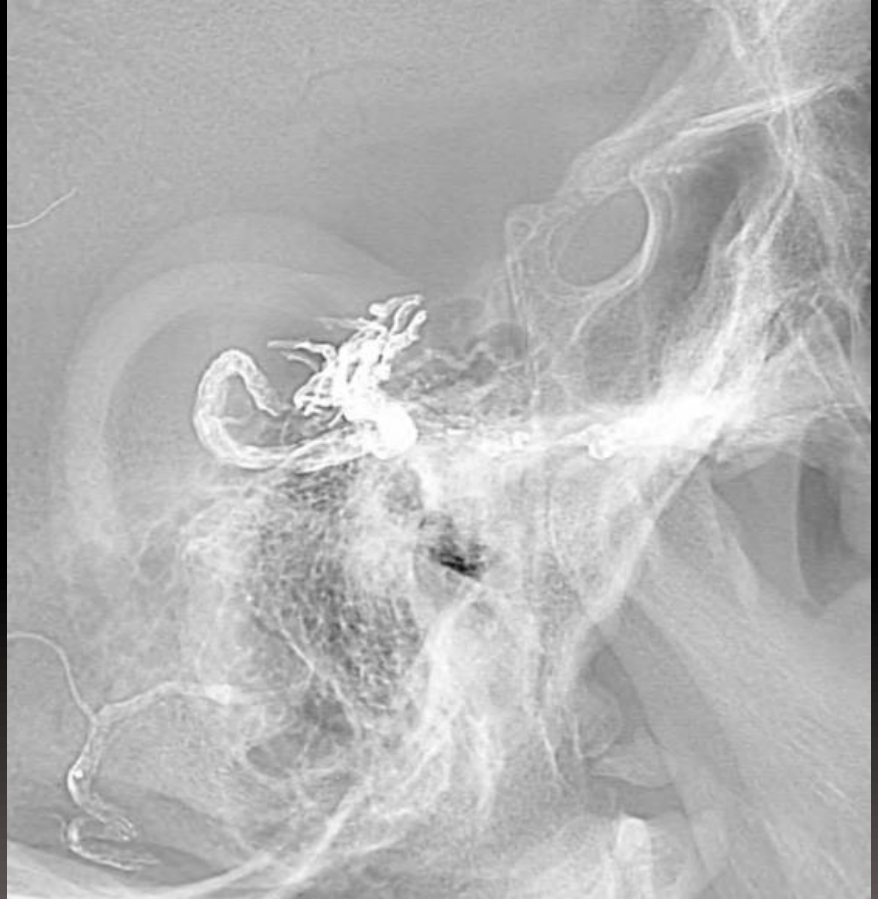
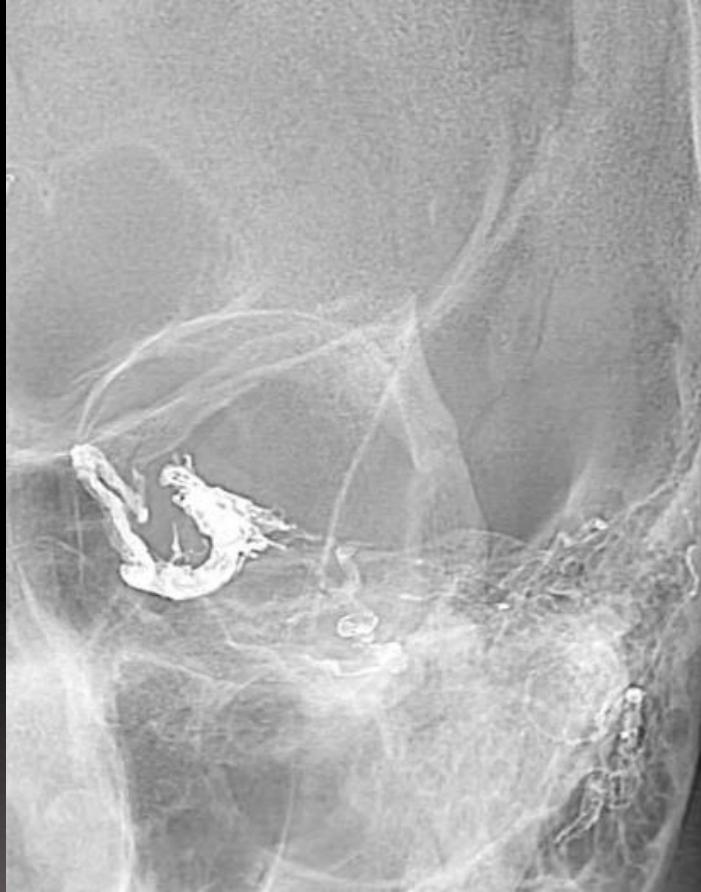
# DURAL AVM

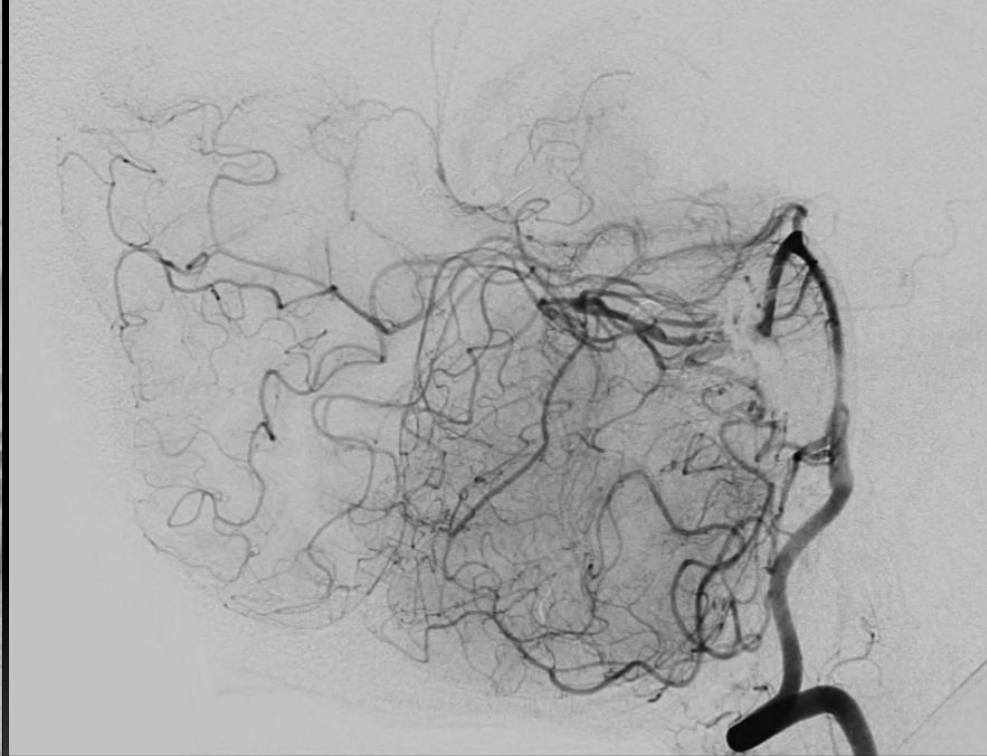
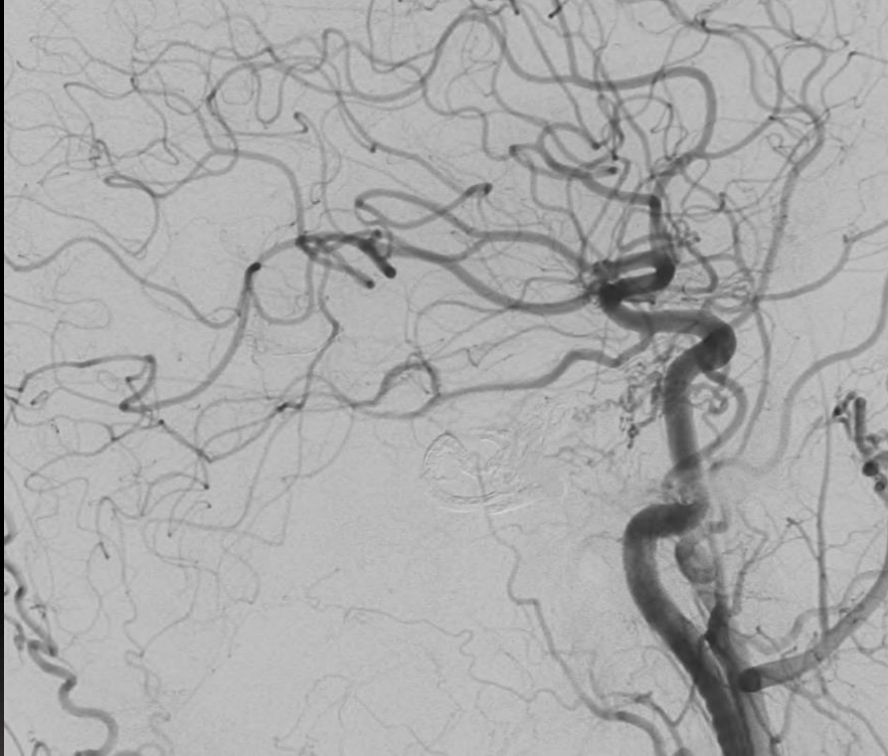
2578-15 L (15)



# DURAL AVM

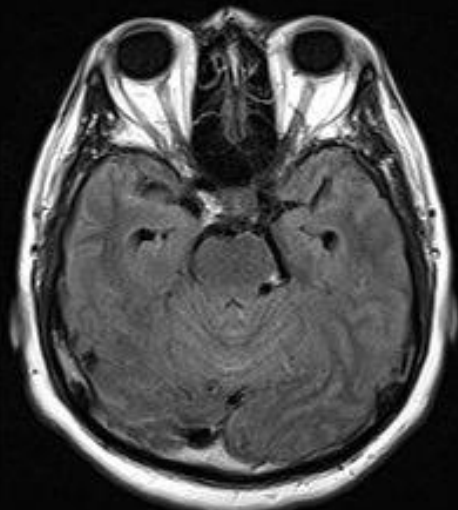


# DURAL AVM

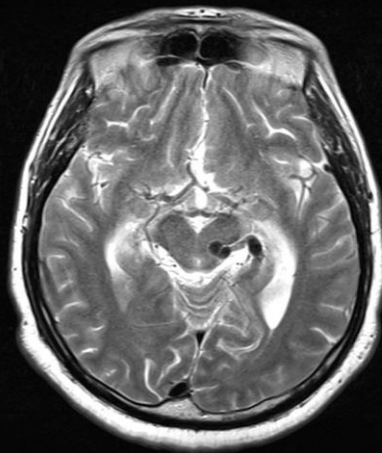




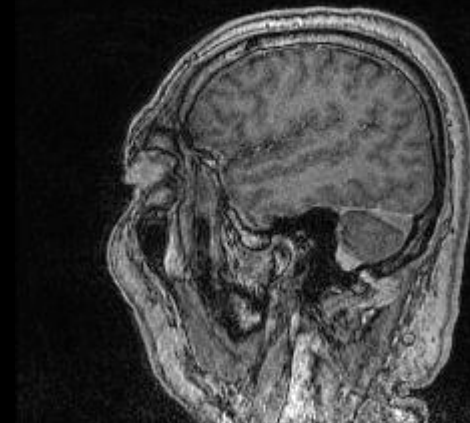
# DURAL AVM



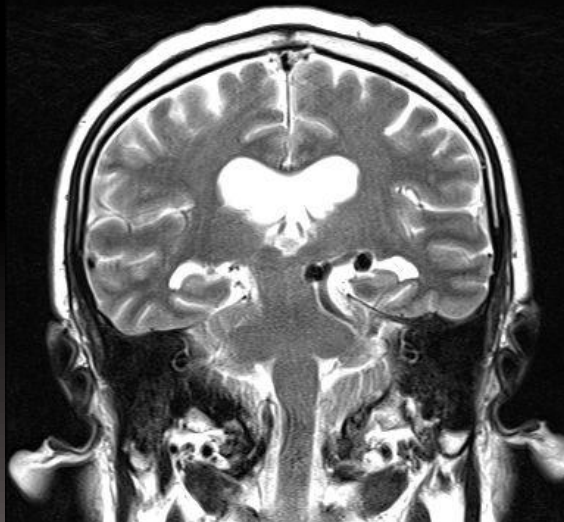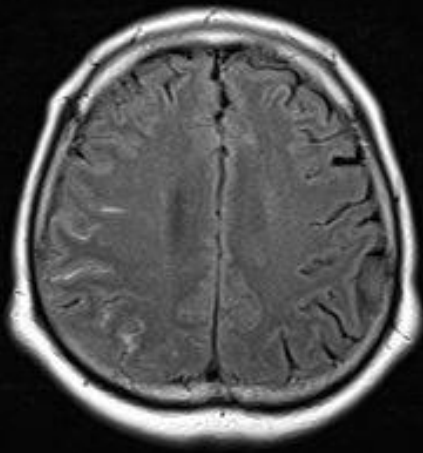
Flair



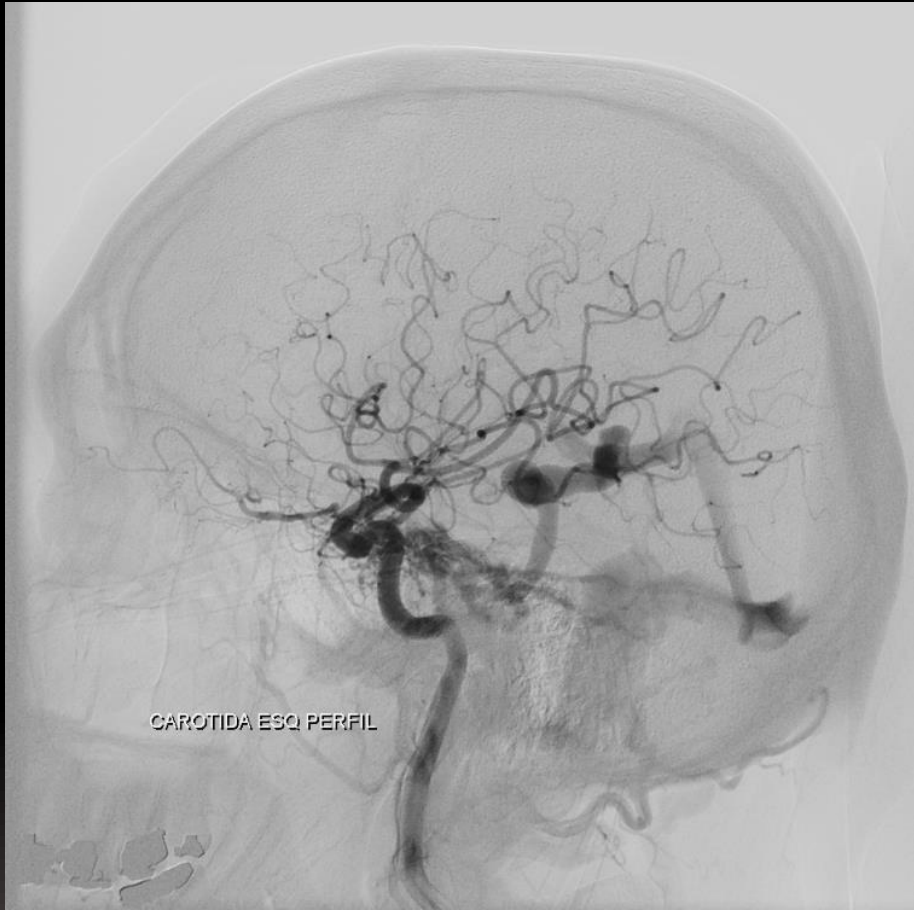
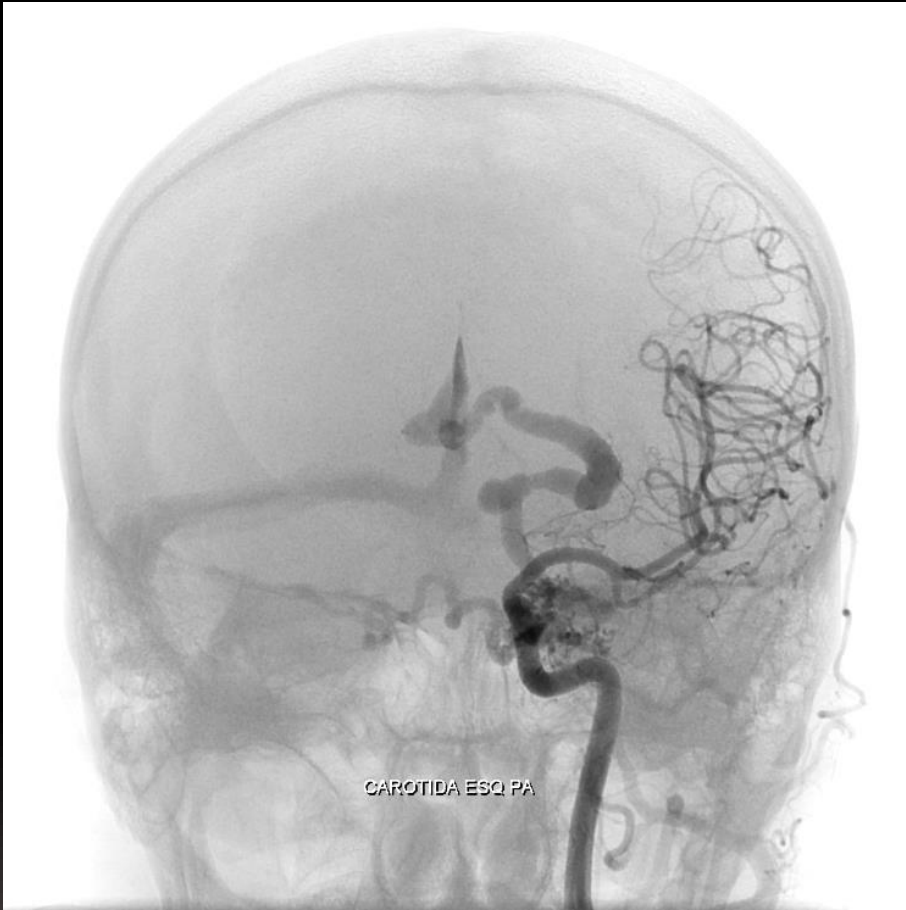
T2



T1 pós-contraste

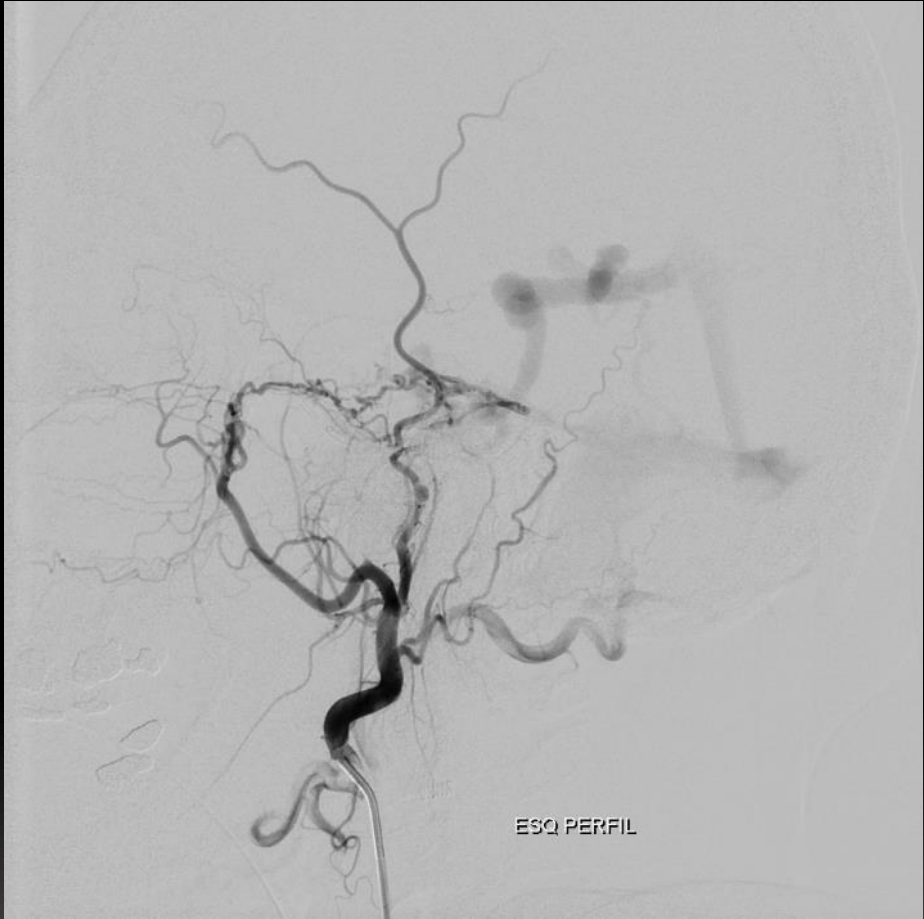
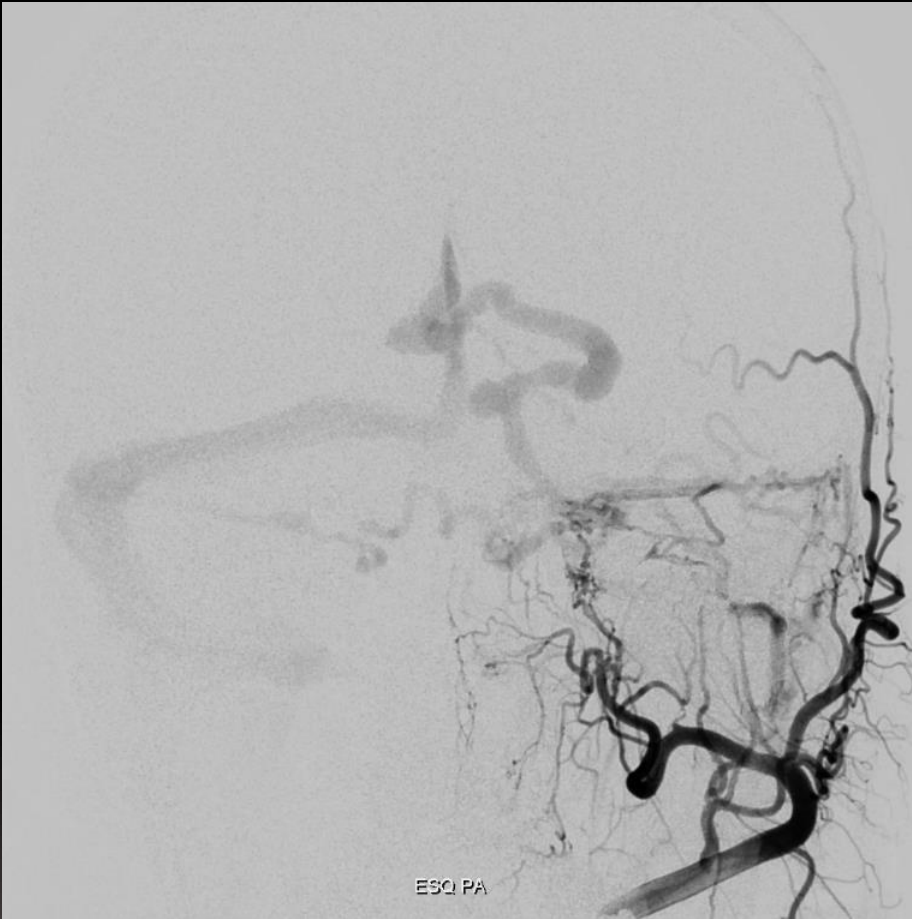

# DURAL AVM

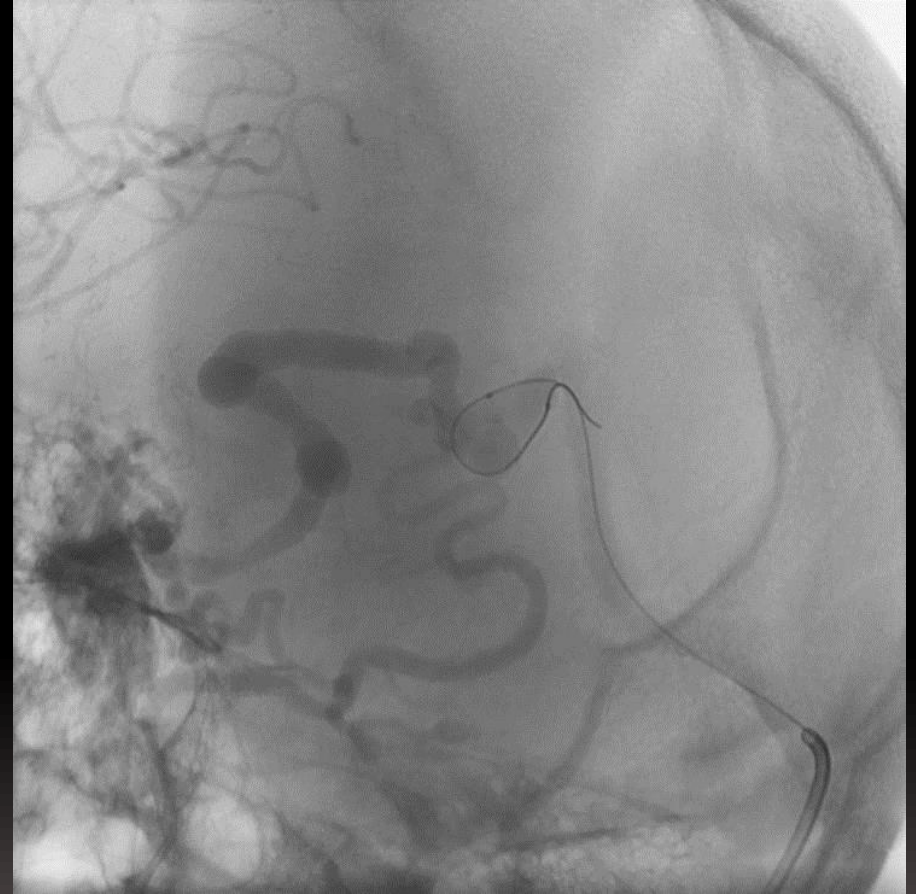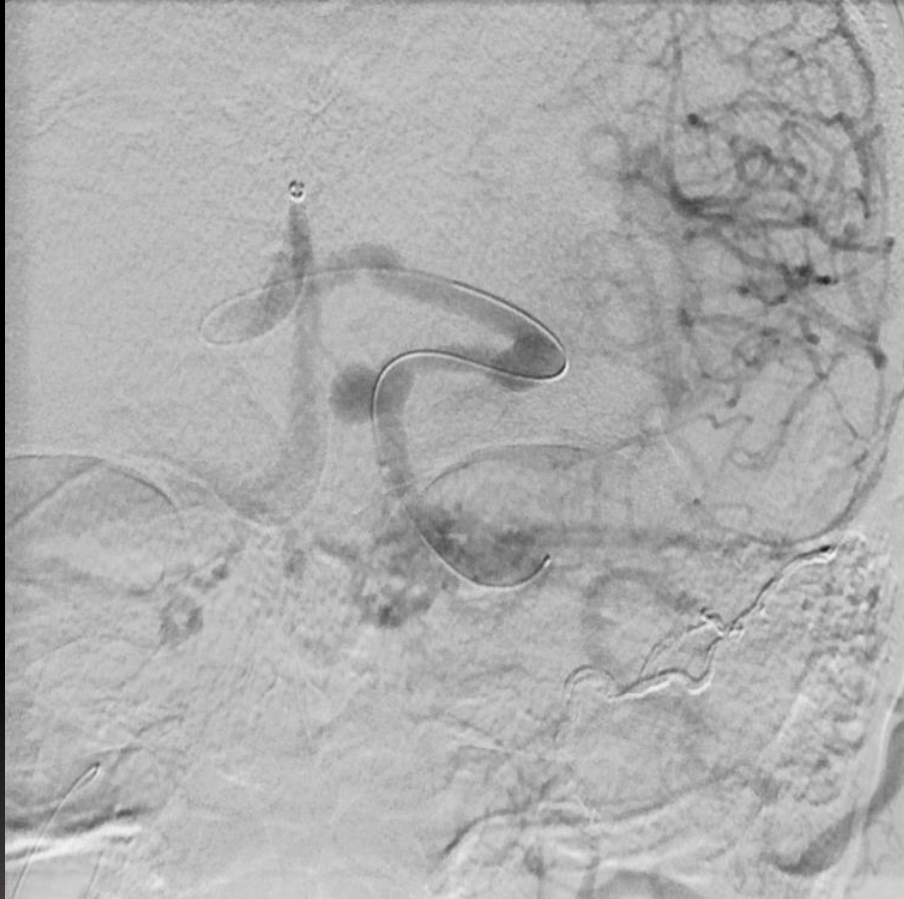




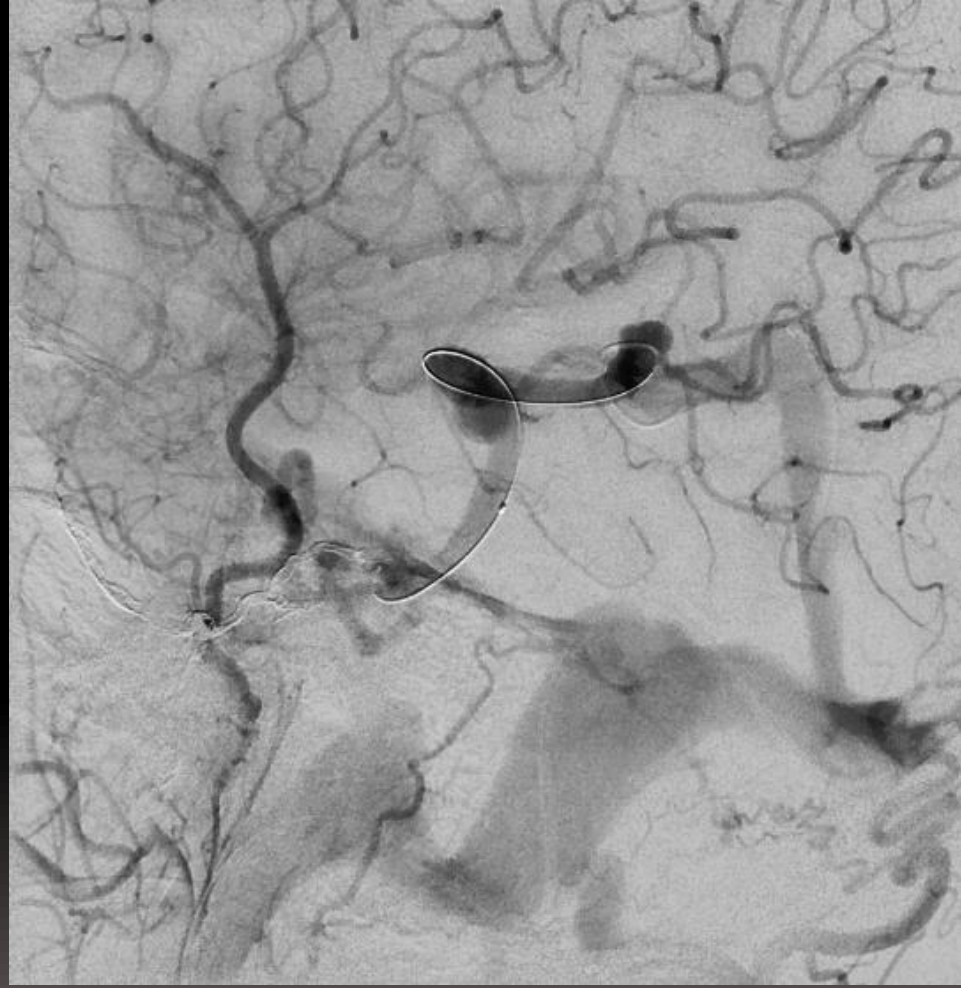
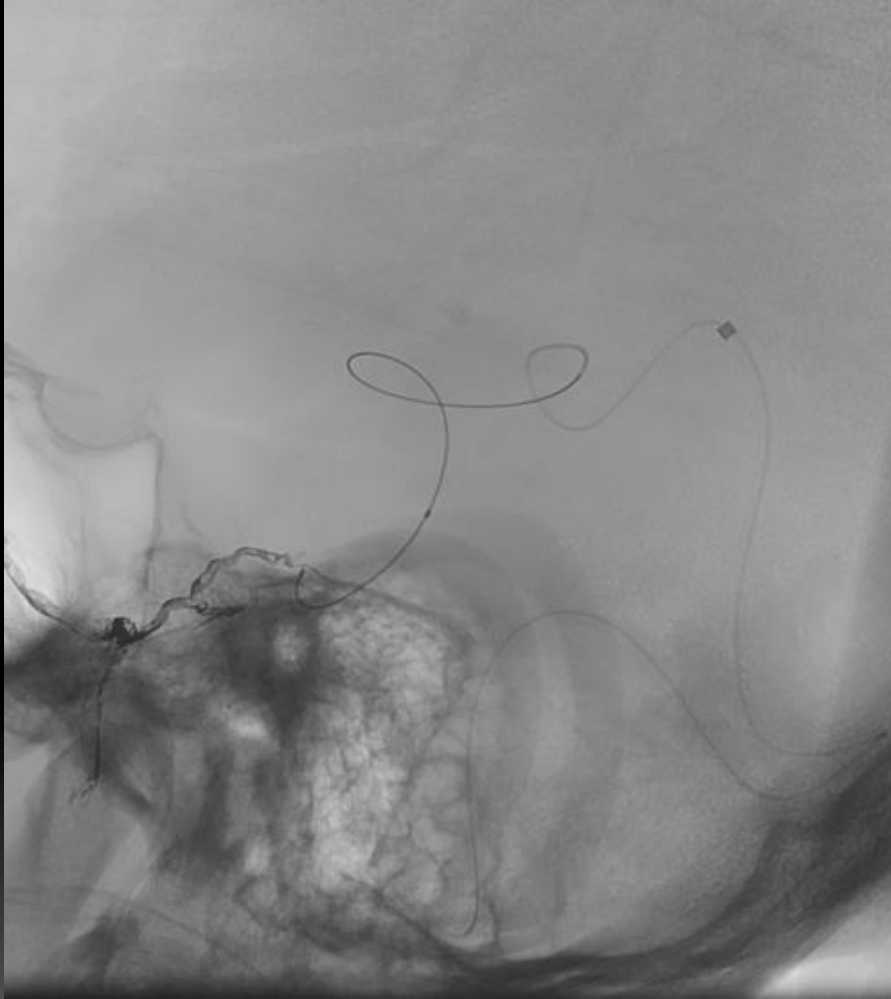# DURAL AVM



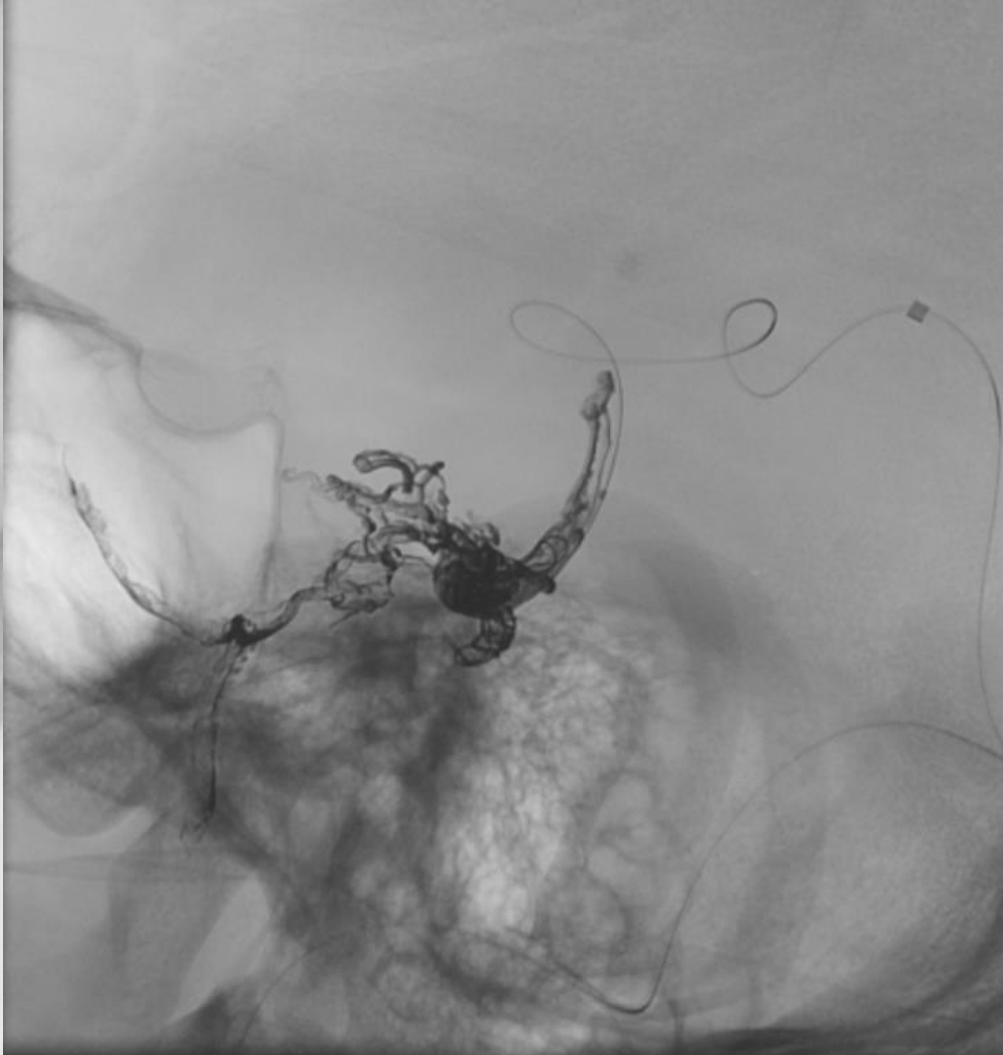
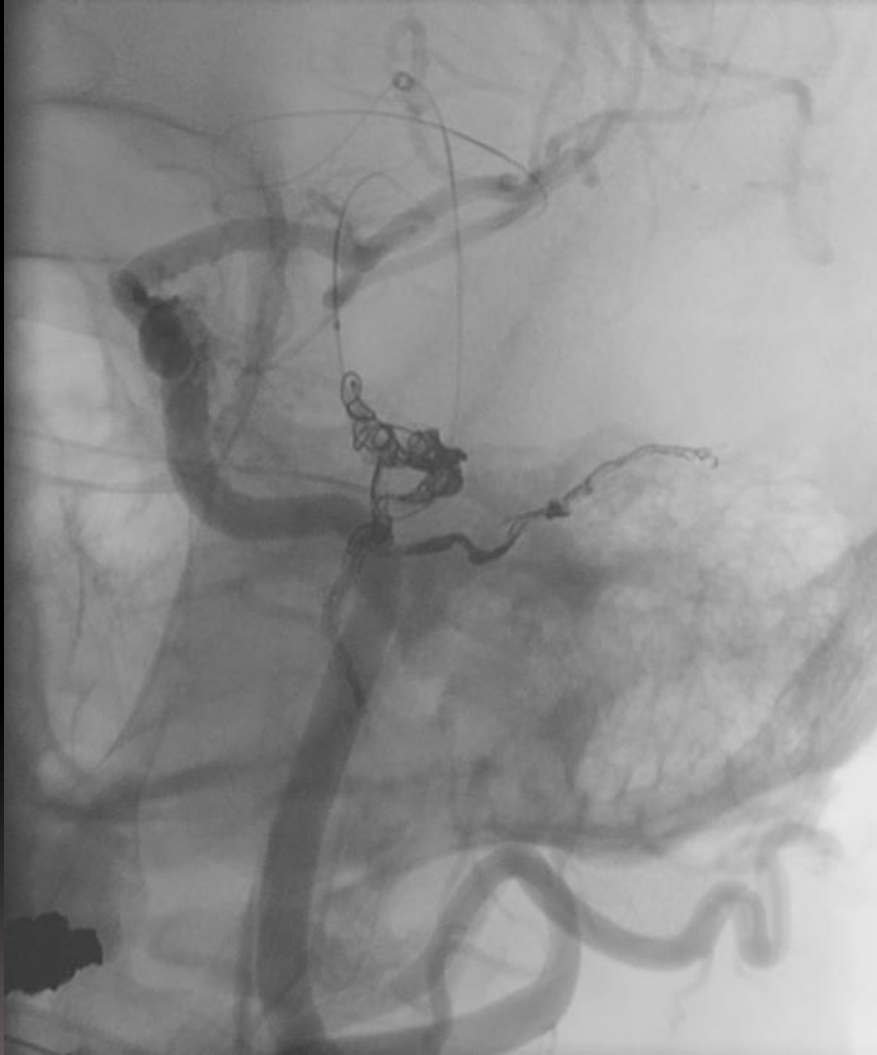# DURAL AVM



# DURAL AVM

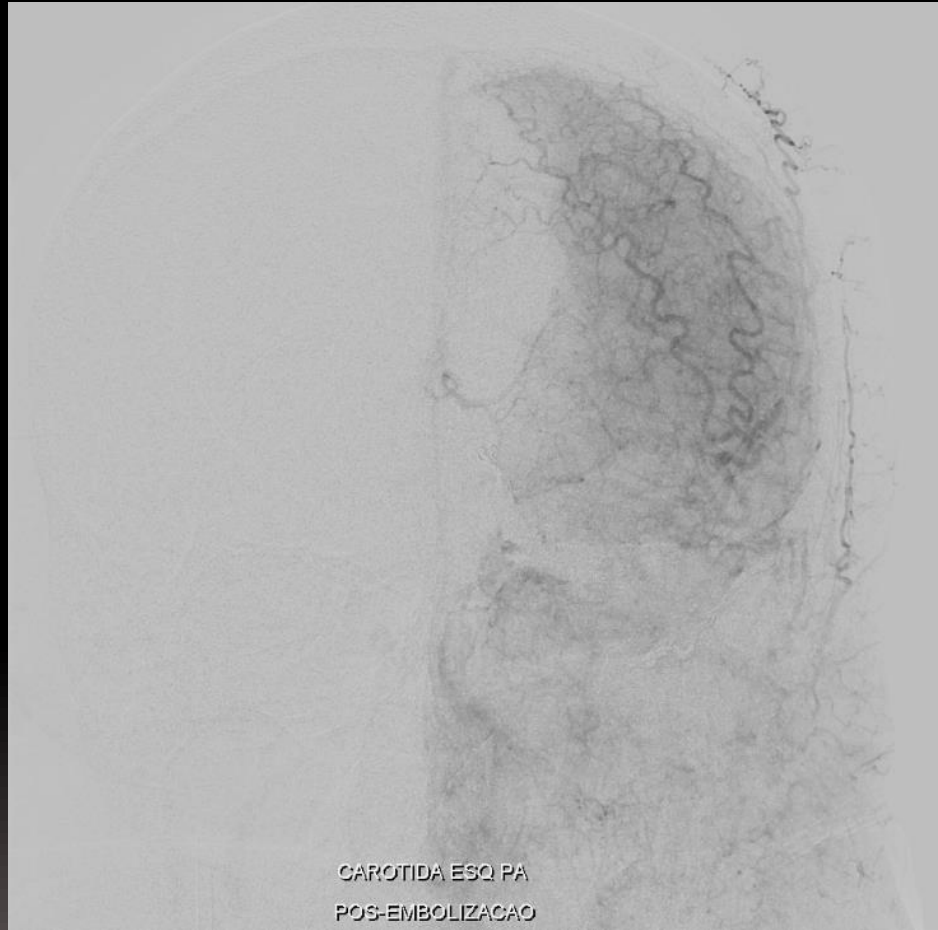
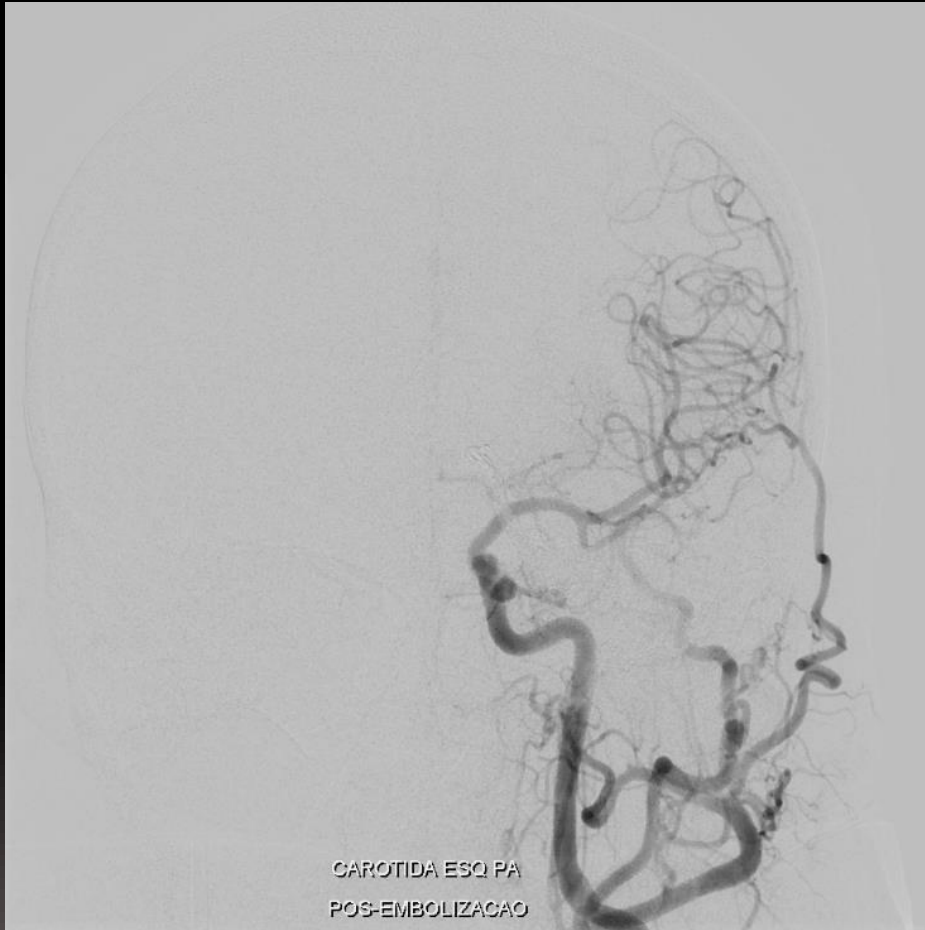


# DURAL AVM



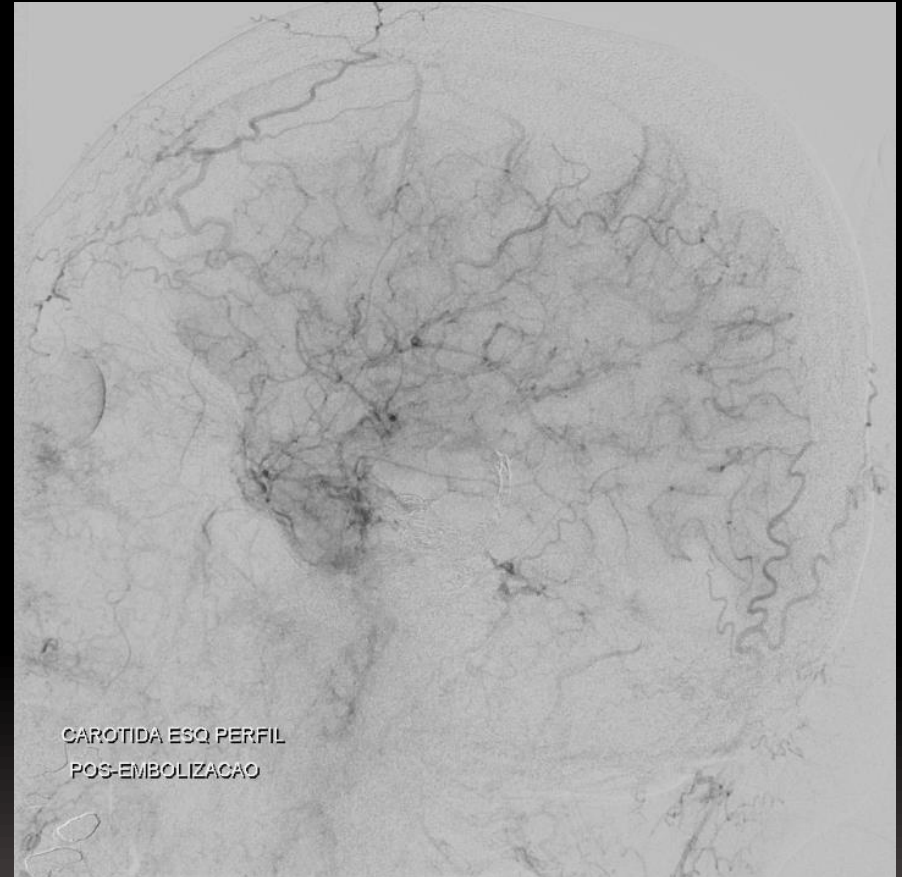
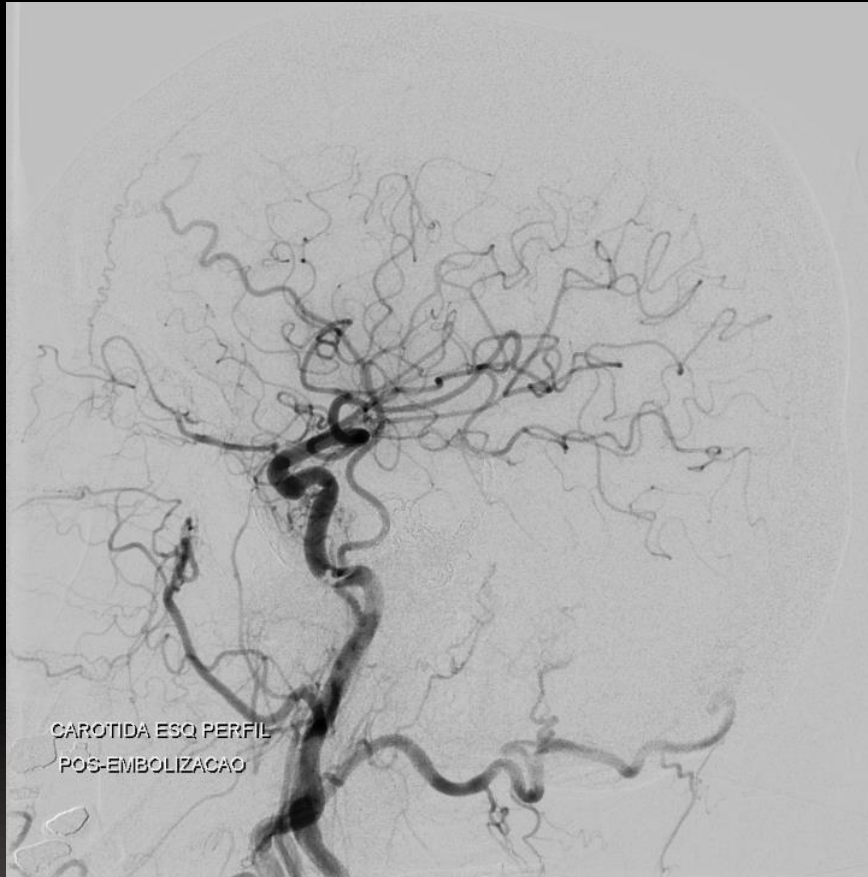

# DURAL AVM





# DURAL AVM



# DURAL AVM

CAROTIDA ESQ PA

CAROTIDA ESQ PA

CAROTIDA ESQ PA

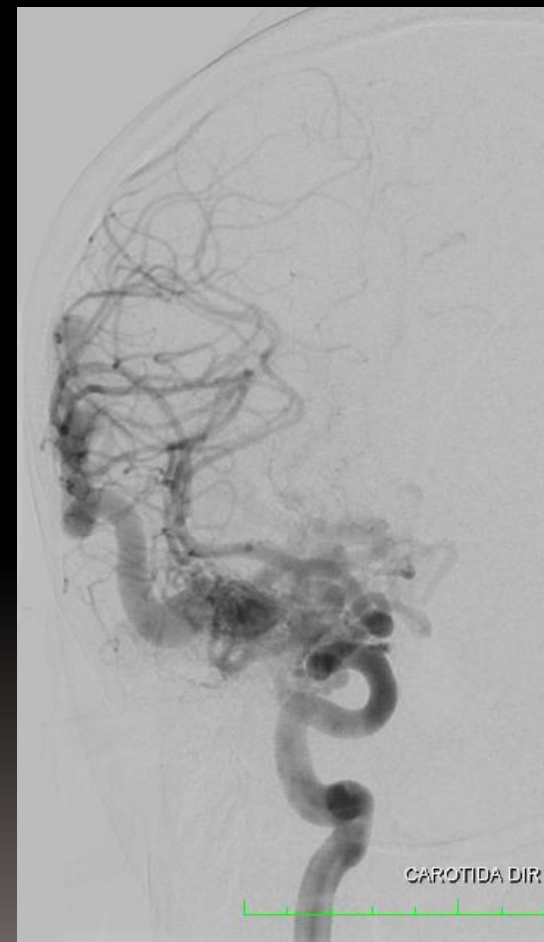
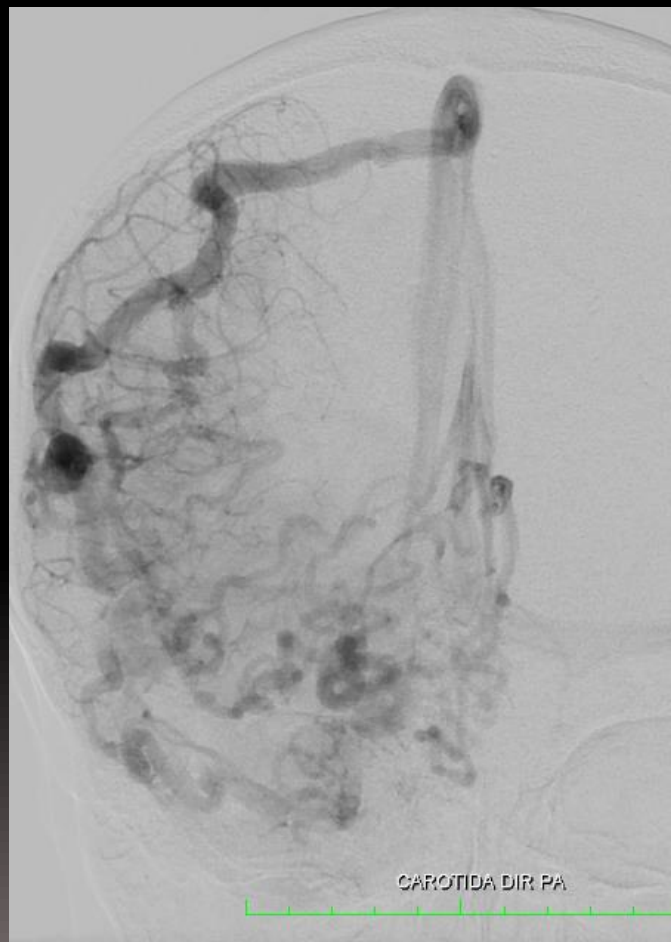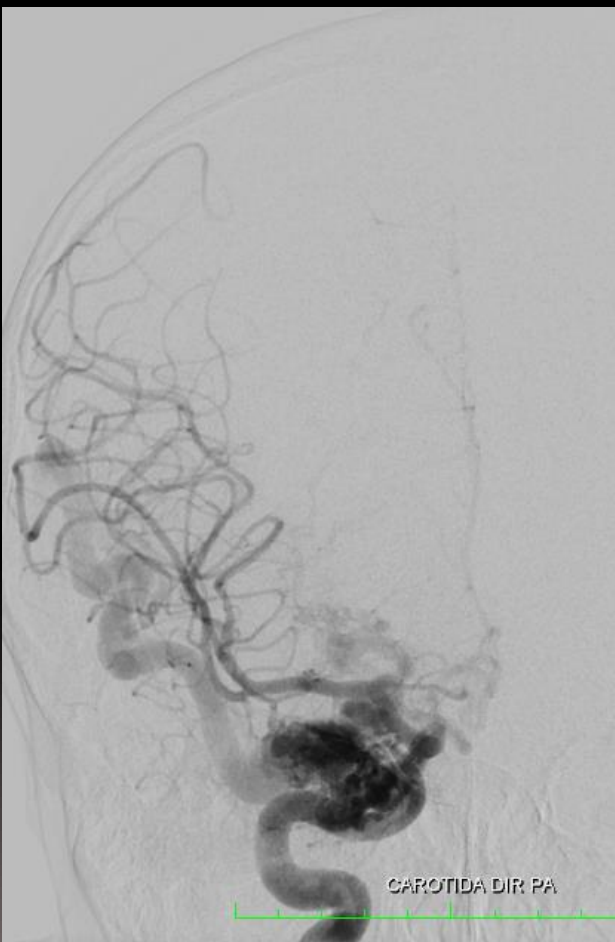
CAROTIDA ESQ PERFIL

CAROTIDA ESQ PERFIL

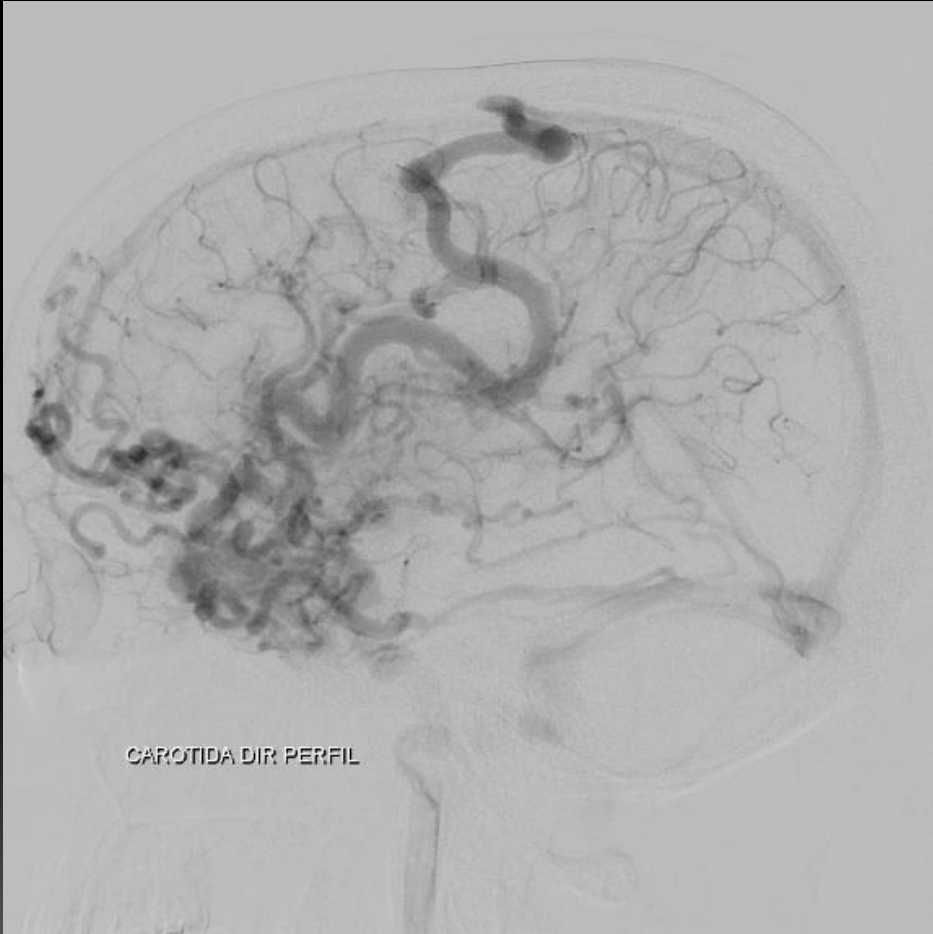
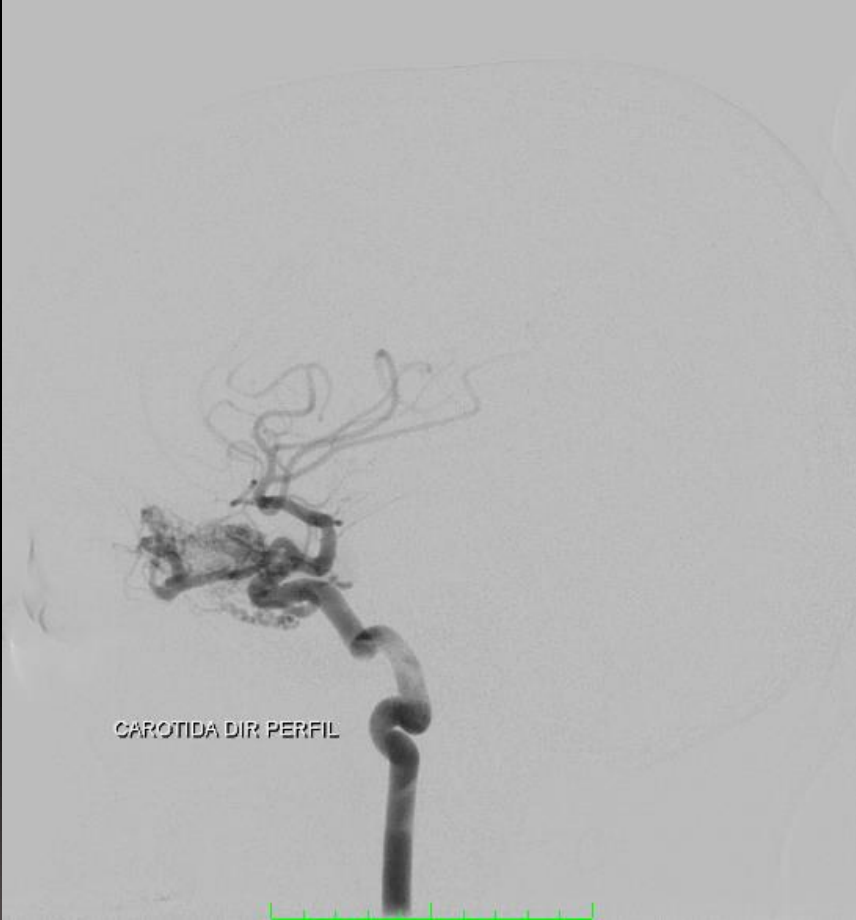CAROTIDA ESQ PERFIL

Angio controle 8 meses

# DURAL AVM

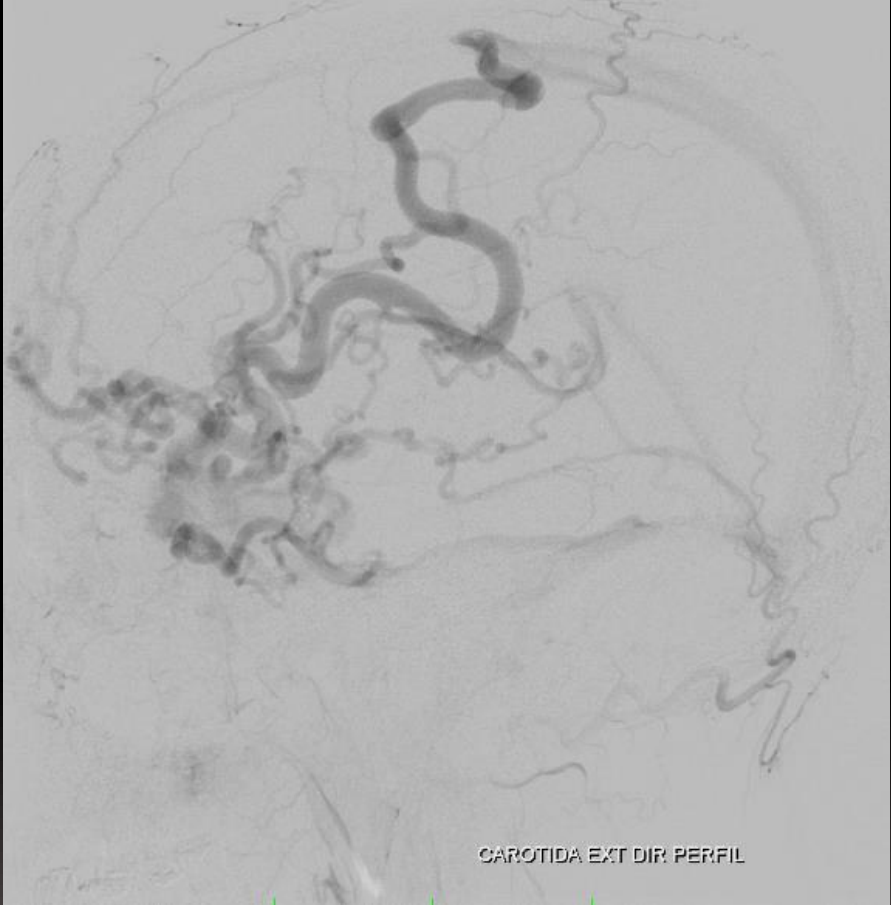
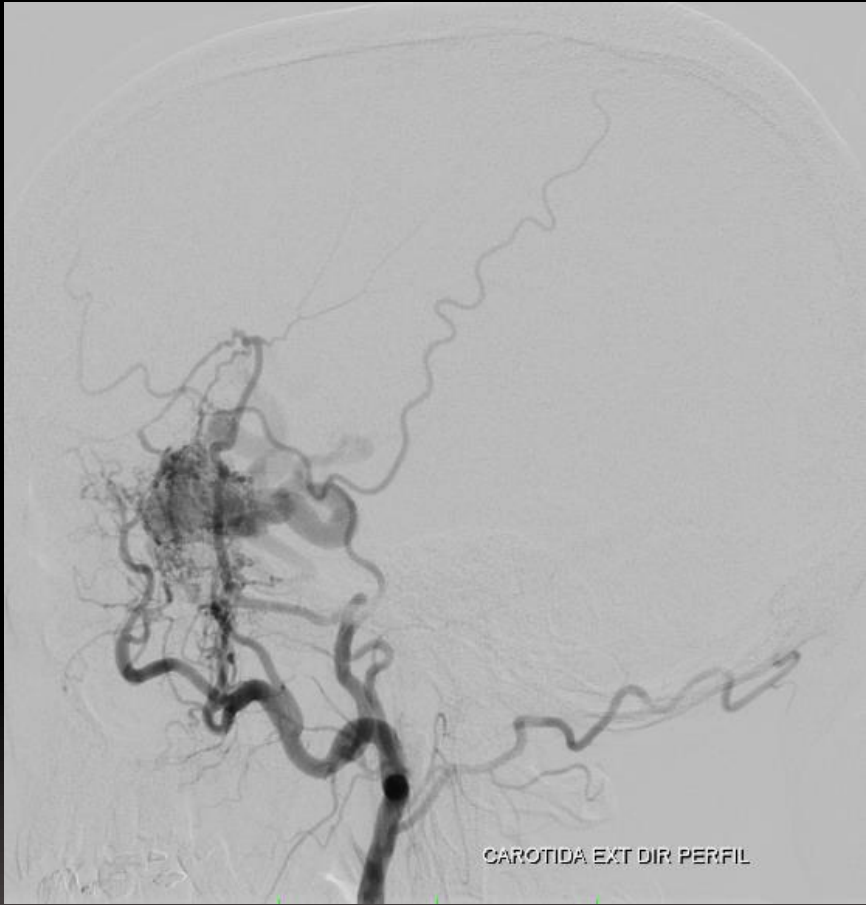

# DURAL AVM



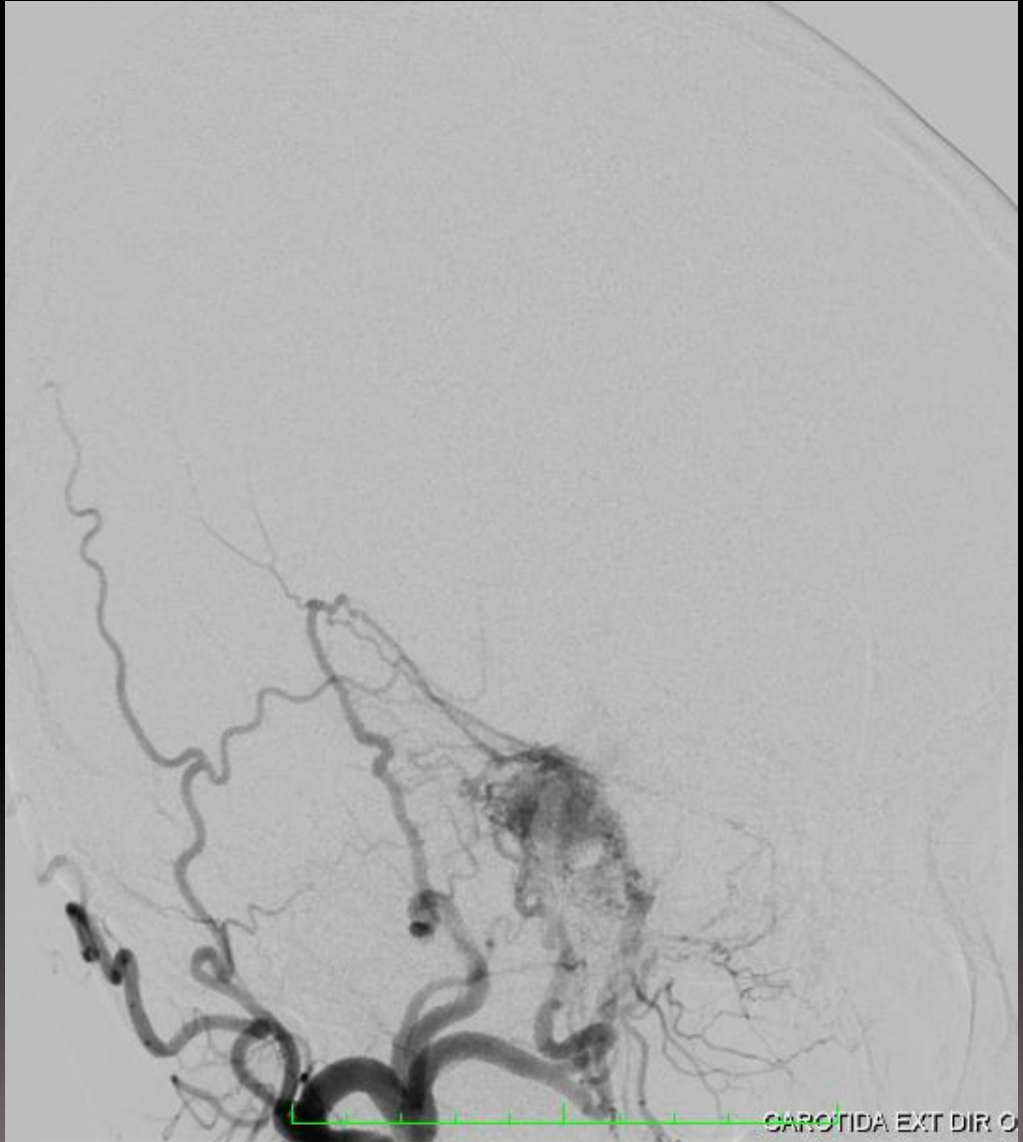
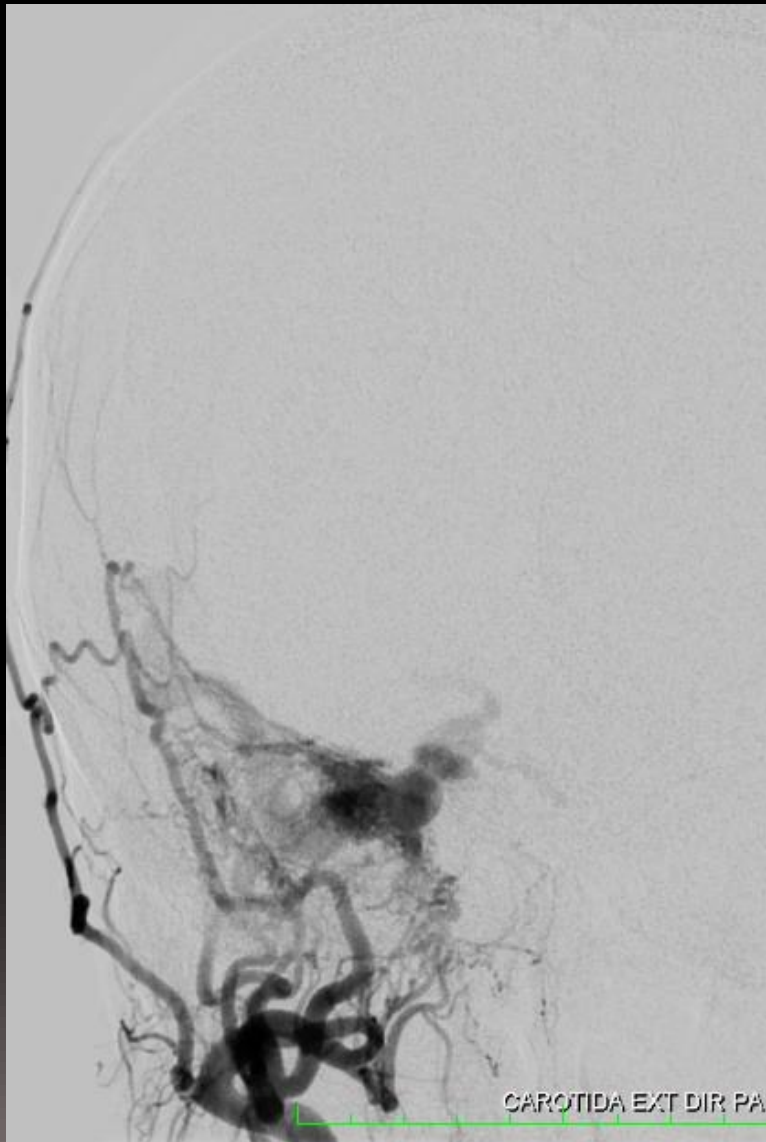


# DURAL AVM

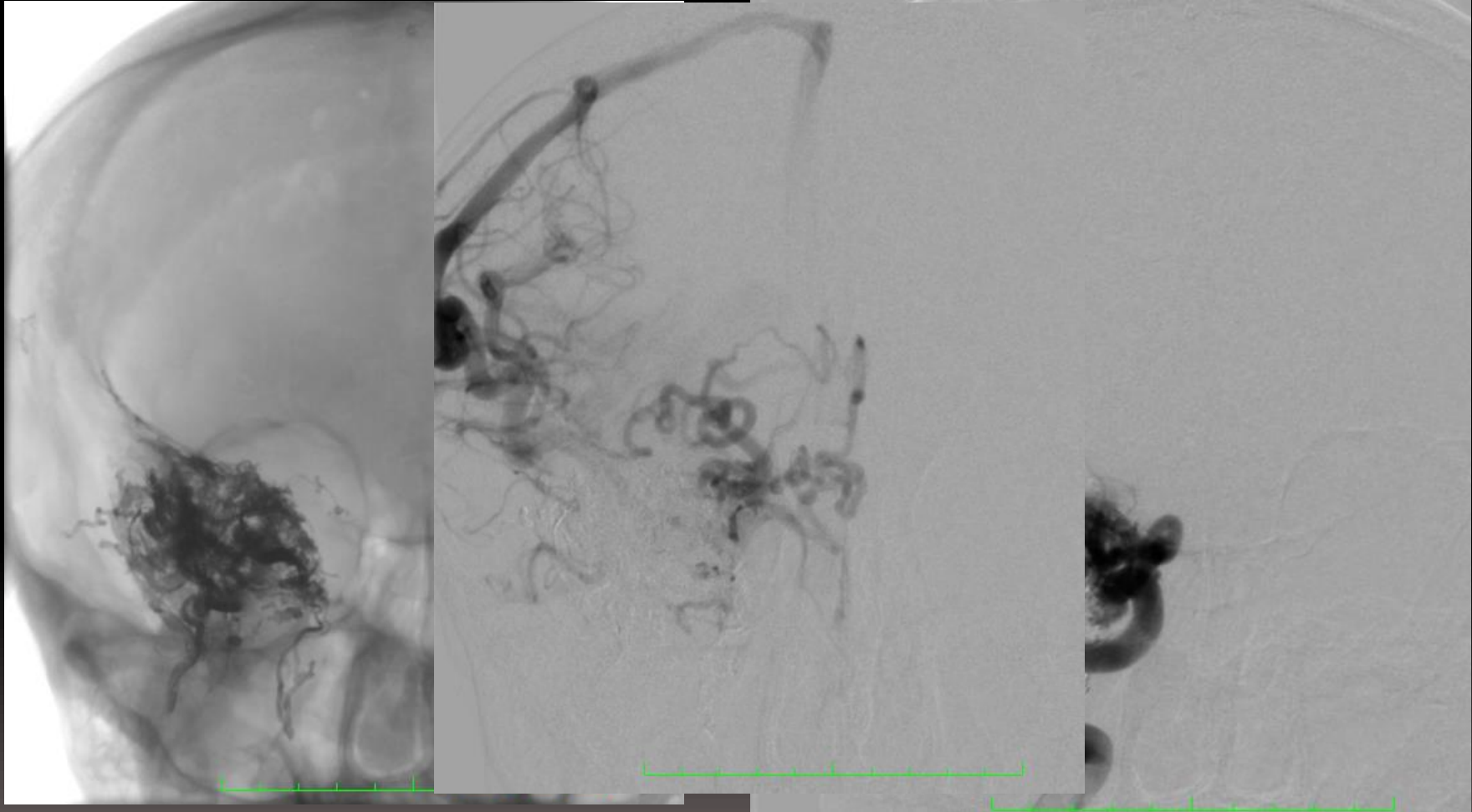




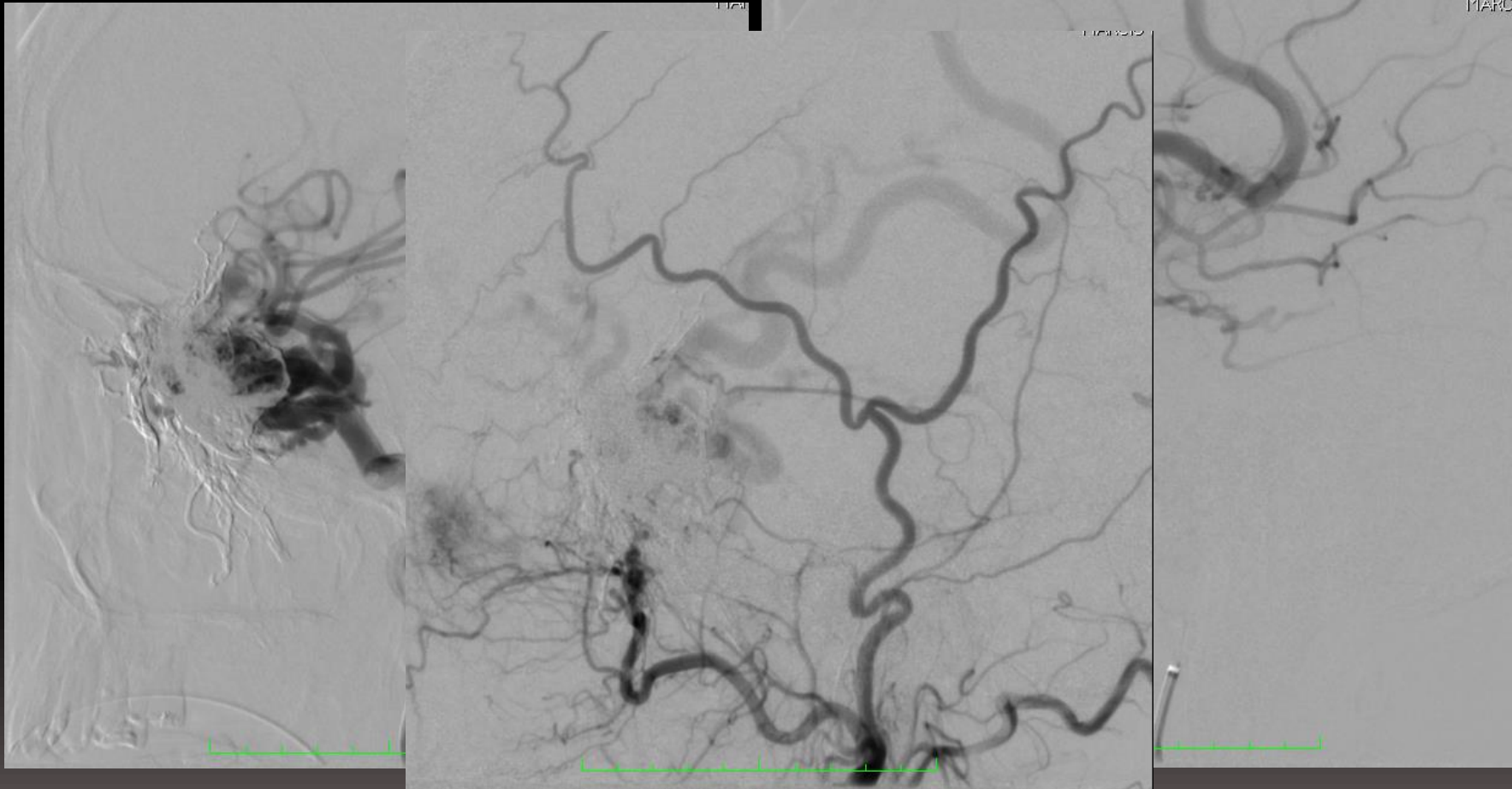# DURAL AVM



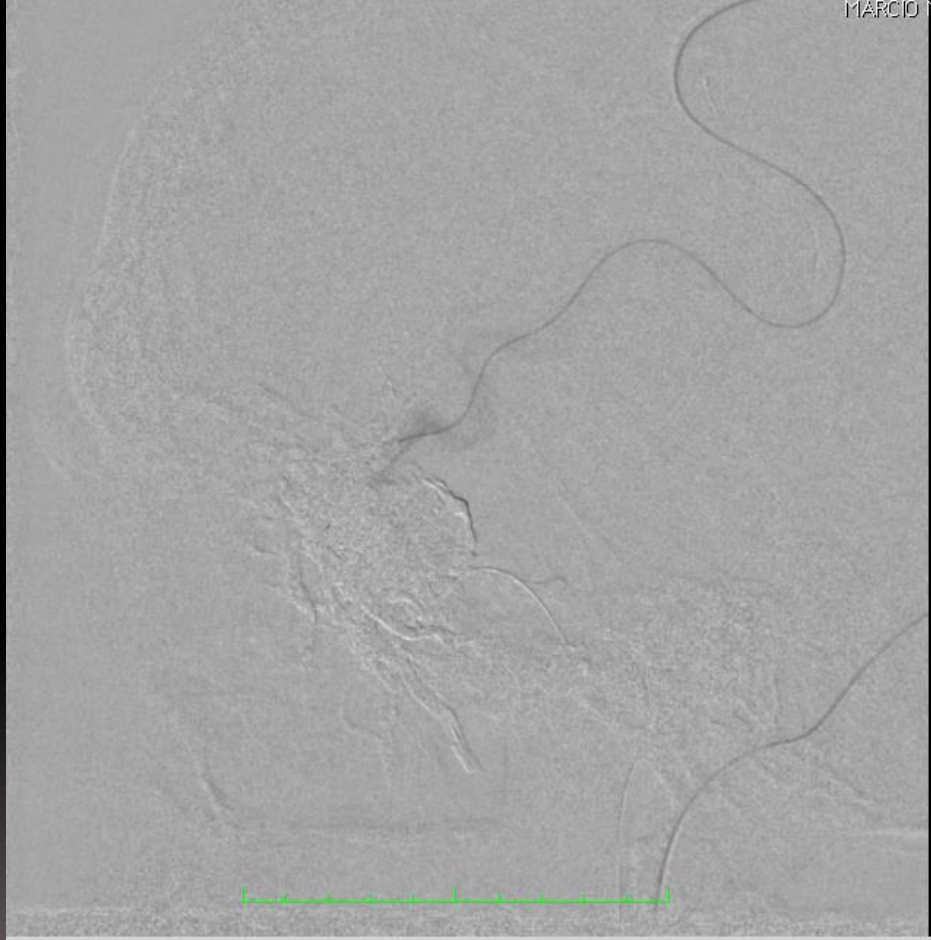
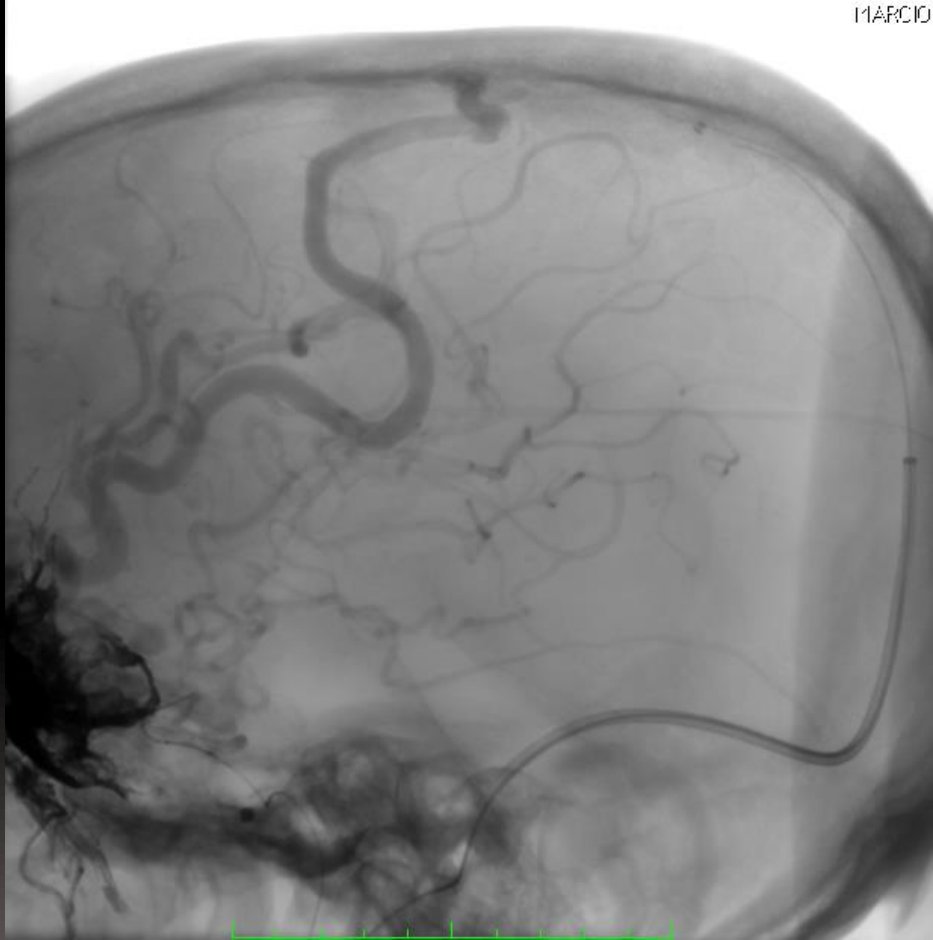
# DURAL AVM



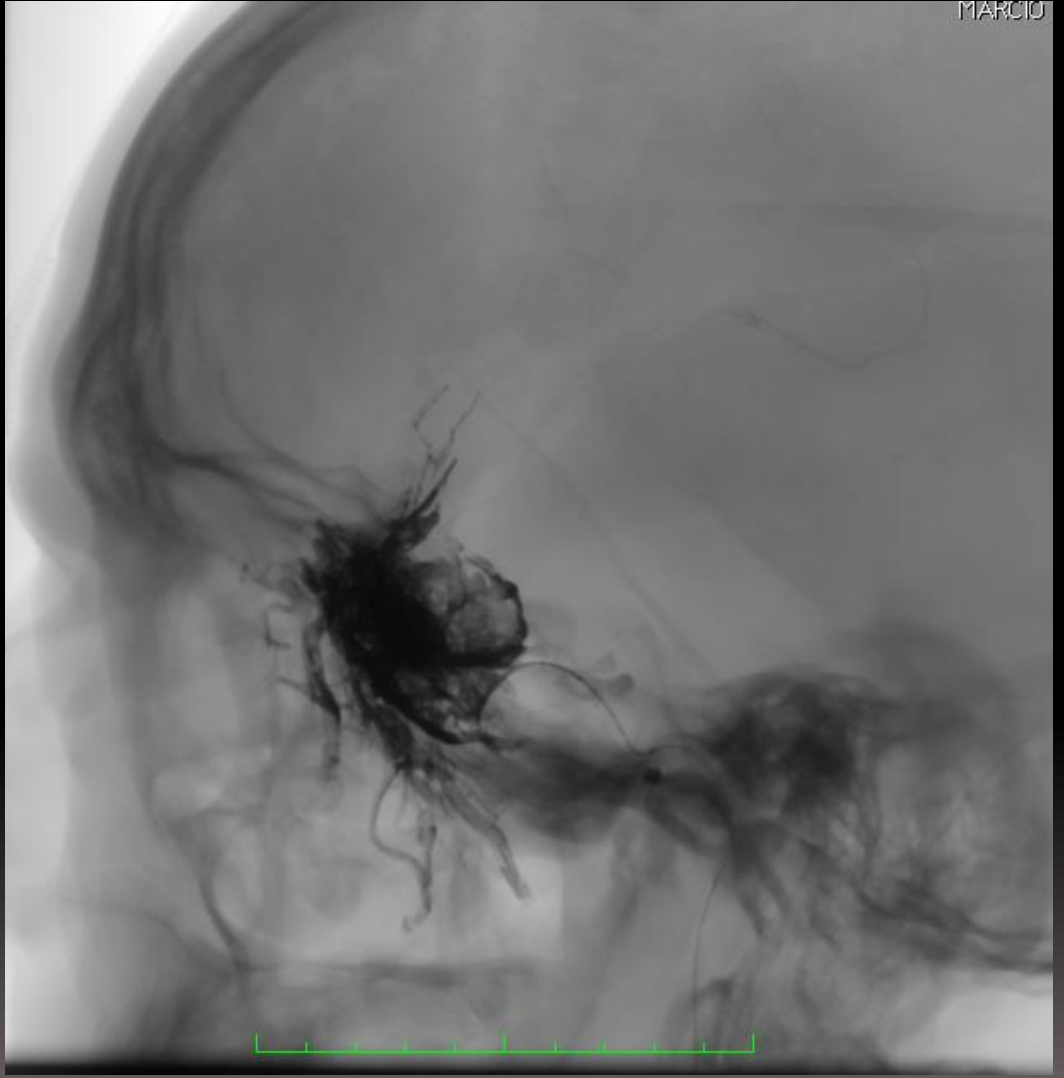
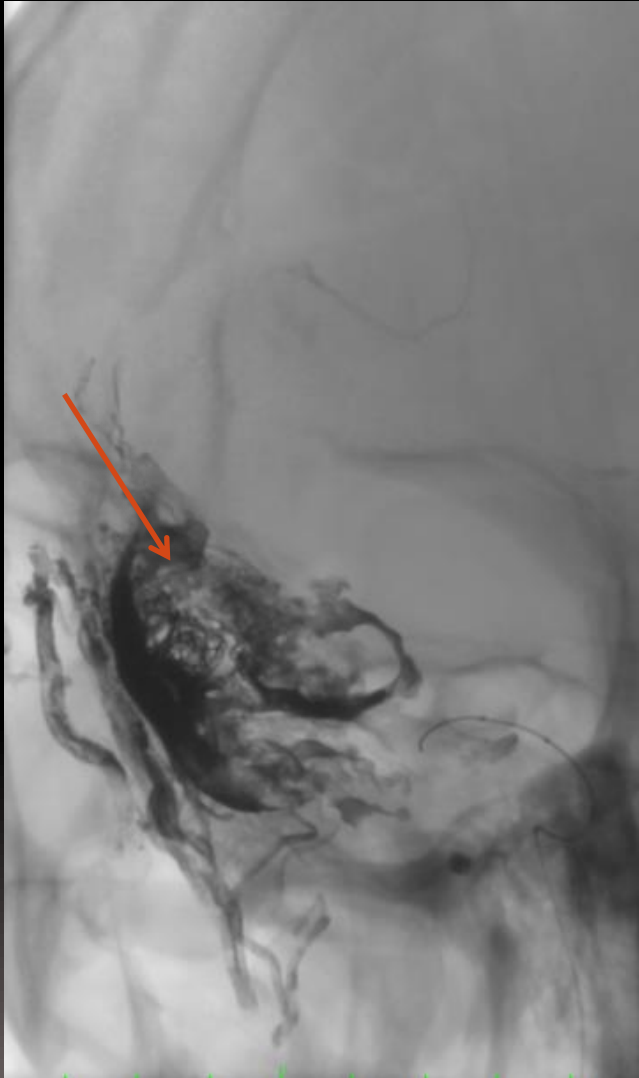
# DURAL AVM



# DURAL AVM

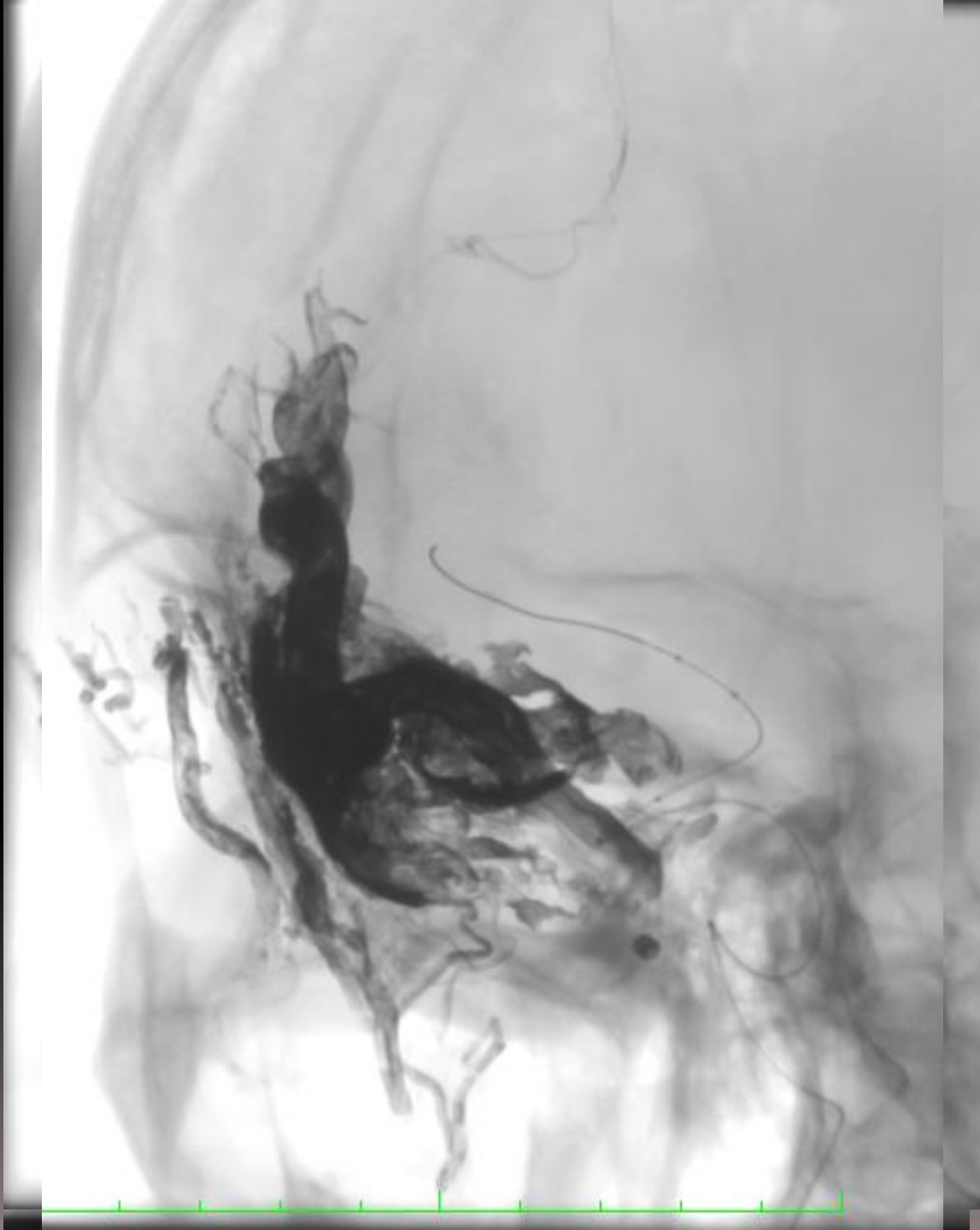


# DURAL AVM

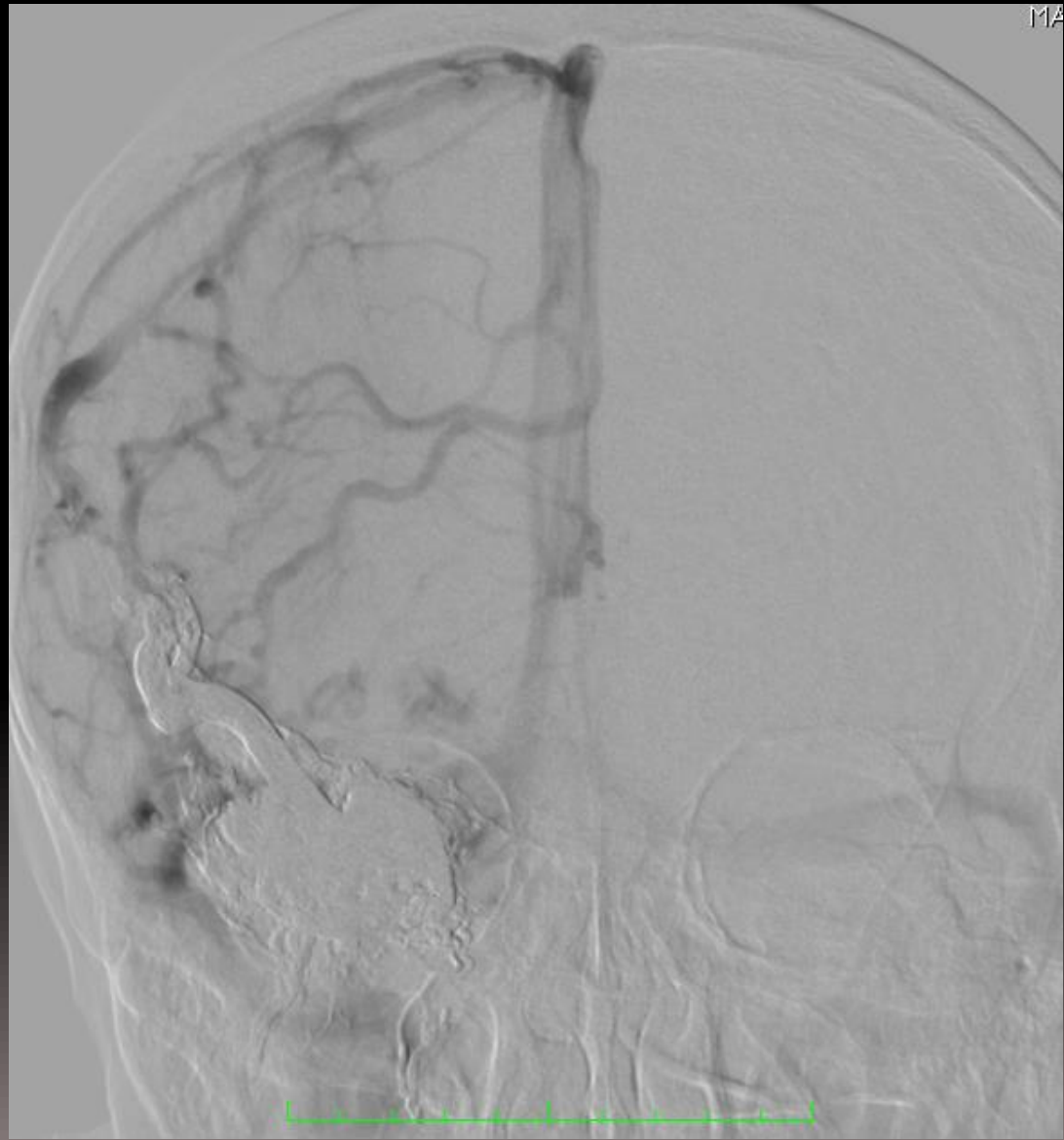
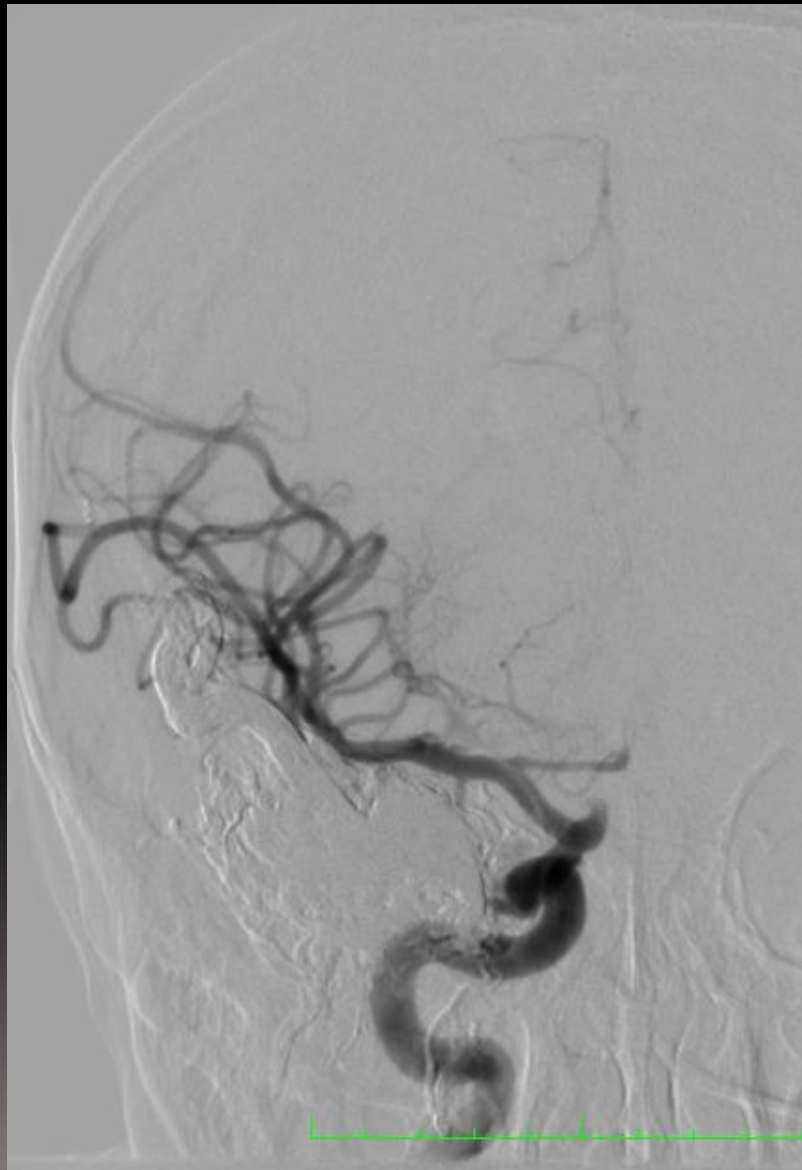
MARCIU

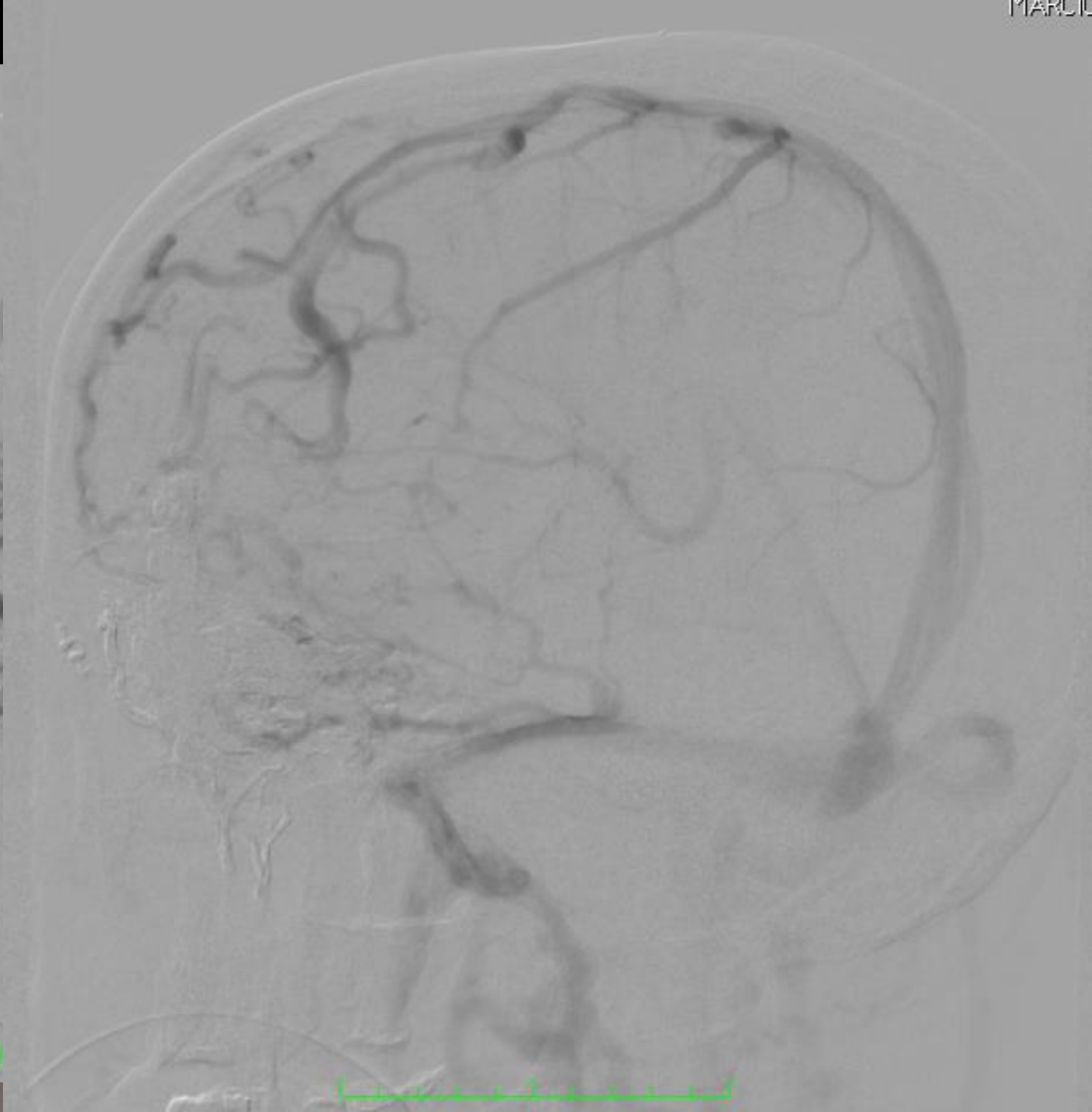




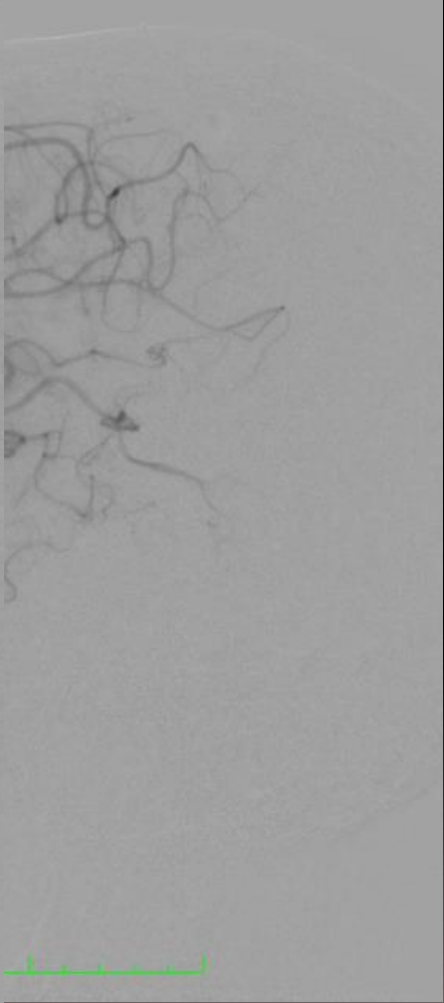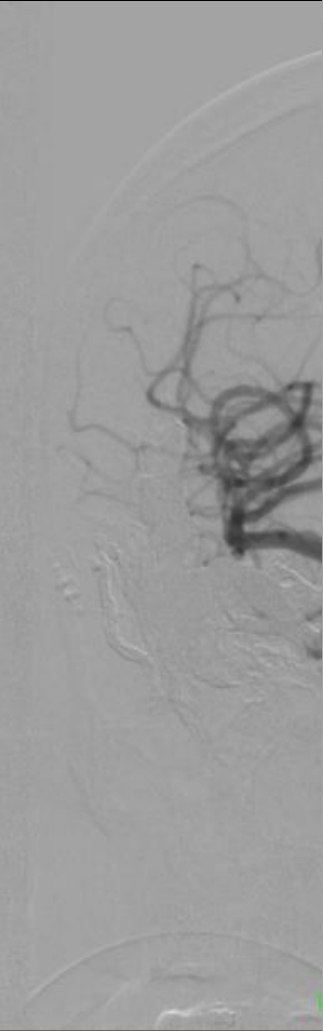
# DURAL AVM



# DURAL AVM



MAR 02



# DURAL AVM

Image size: 960 x 960

View size: 646 x 646

WL: 128 WW: 256

MARCIO MONTEIRO PINTO NRI-5631 ( 44 y, 44 y )

MAY CARE — MAY CARE

1

48

256

128

0

Heparina EV 5 dias

Zoom: 67% Angle: 0

Im: 1/51

Uncompressed

Position: HFS

28/06/16 22:30:59

Made In Osirix

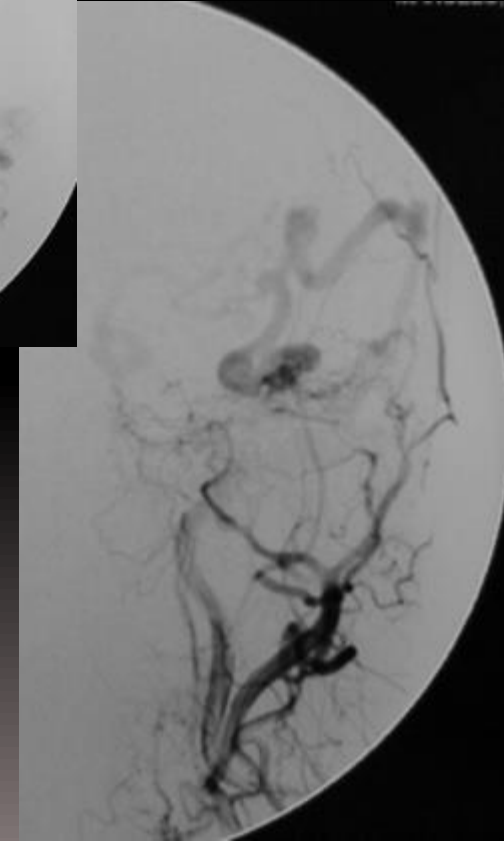
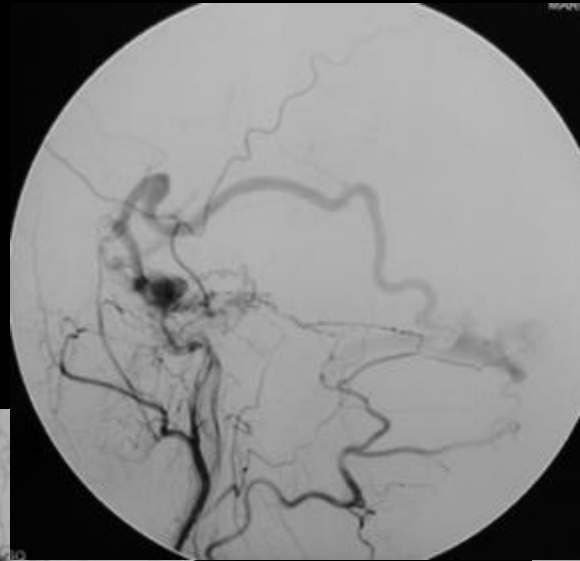
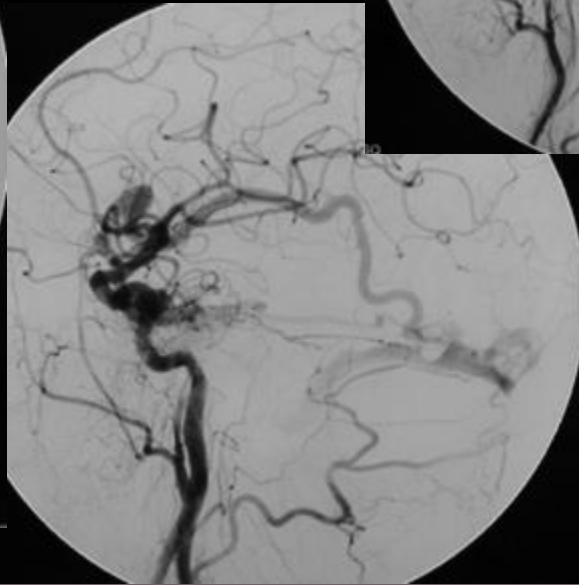
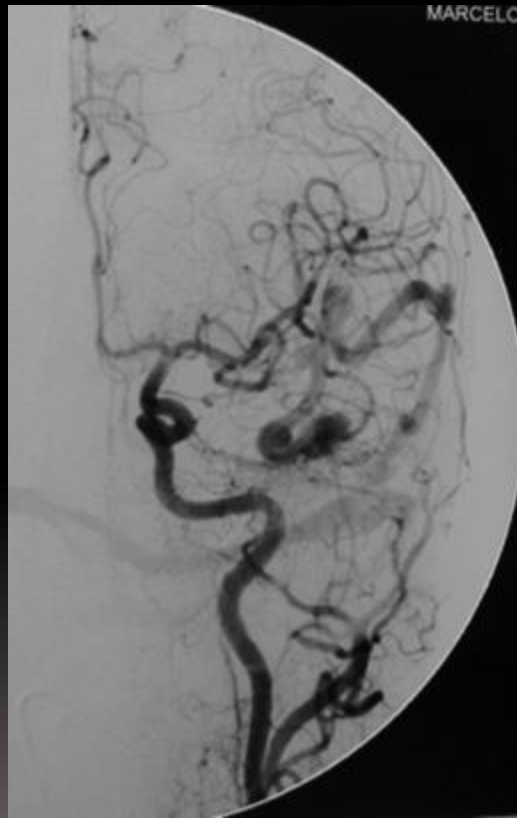


# COMPLICATIONS

# DURAL AVM

**M.G.M, ♀, 69 y**  
**Vertebro-basilar Stroke**

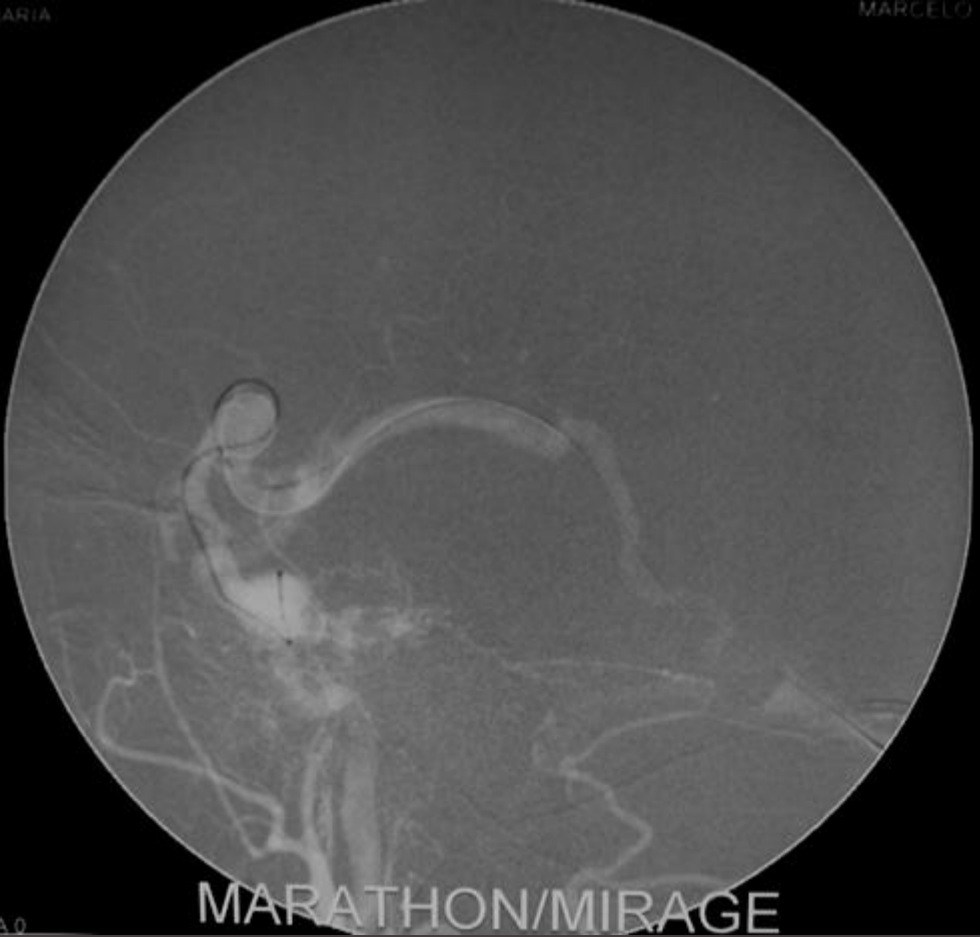Cortesy by Jorge Campos



# DURAL AVM

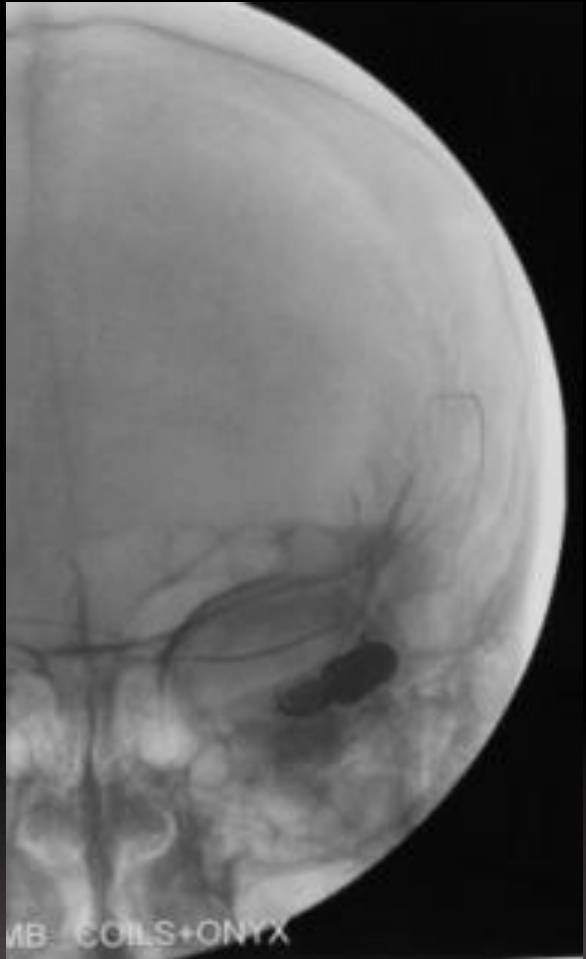TARIA

MARCELO 1



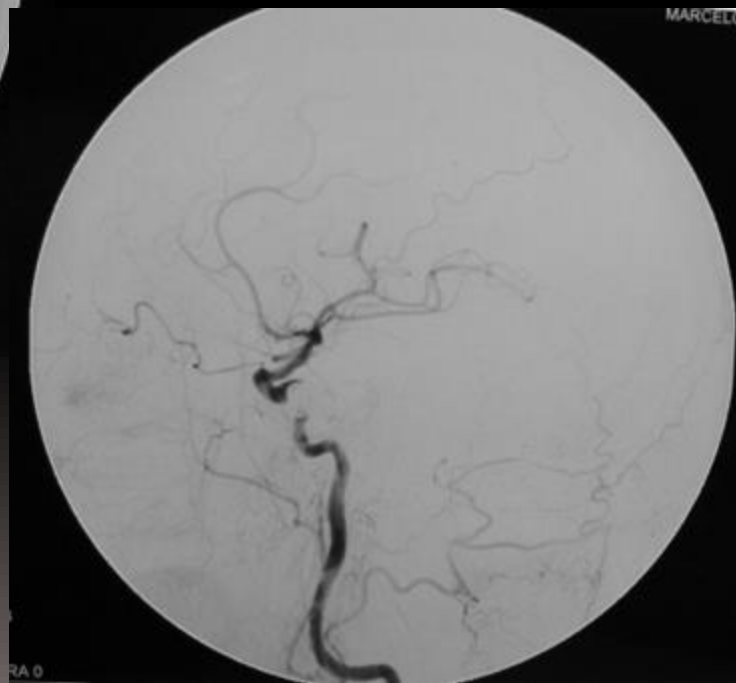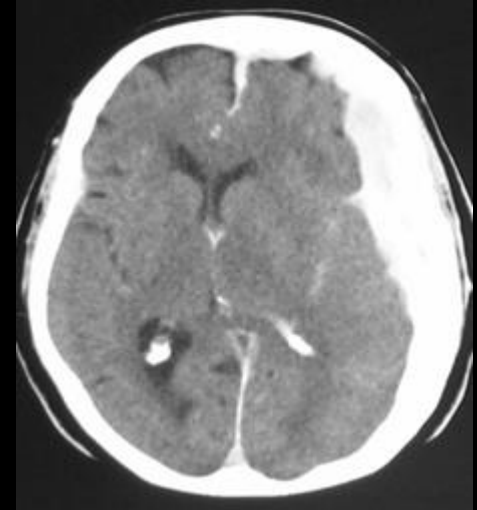
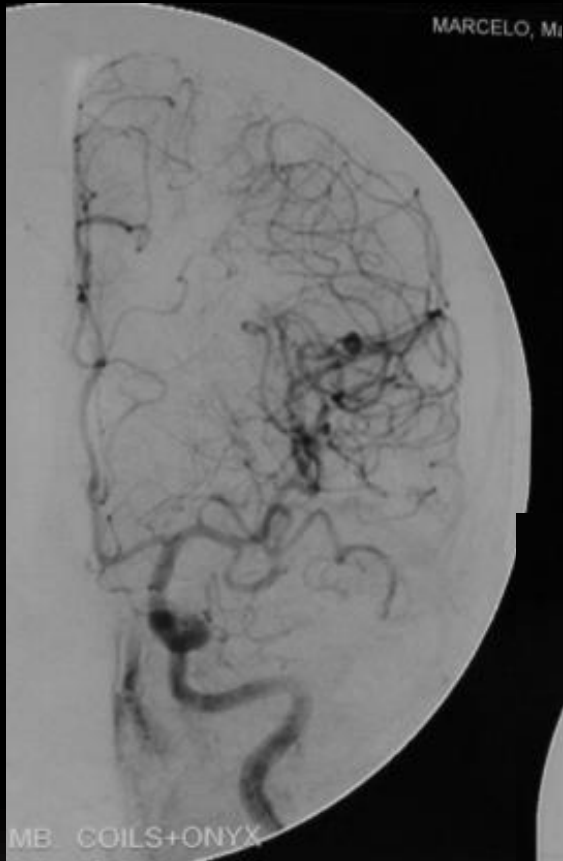
MARATHON/MIRAGE

A 0



MB COILS+ONYX

# DURAL AVM



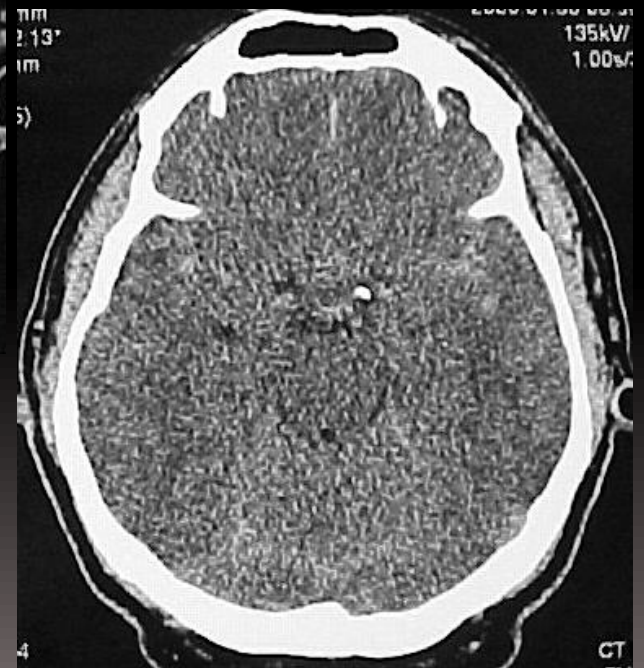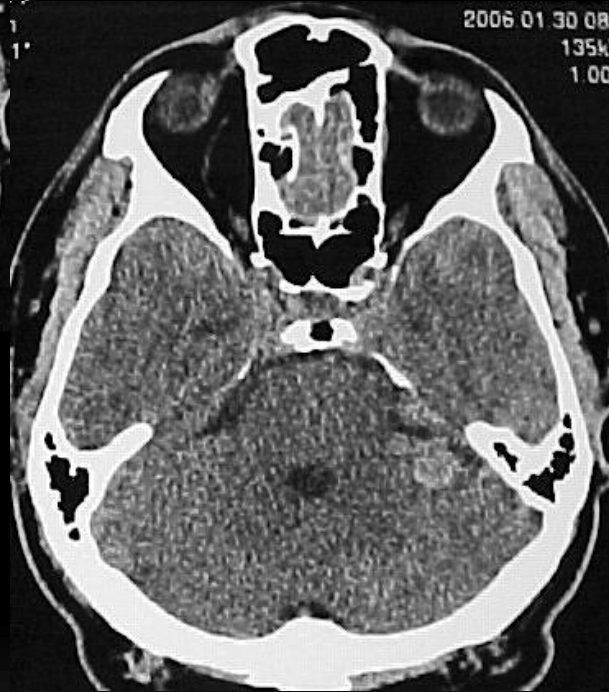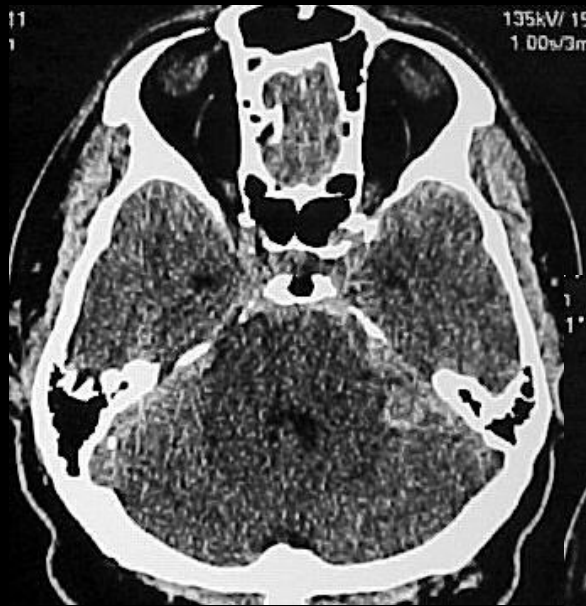Subdural hematome



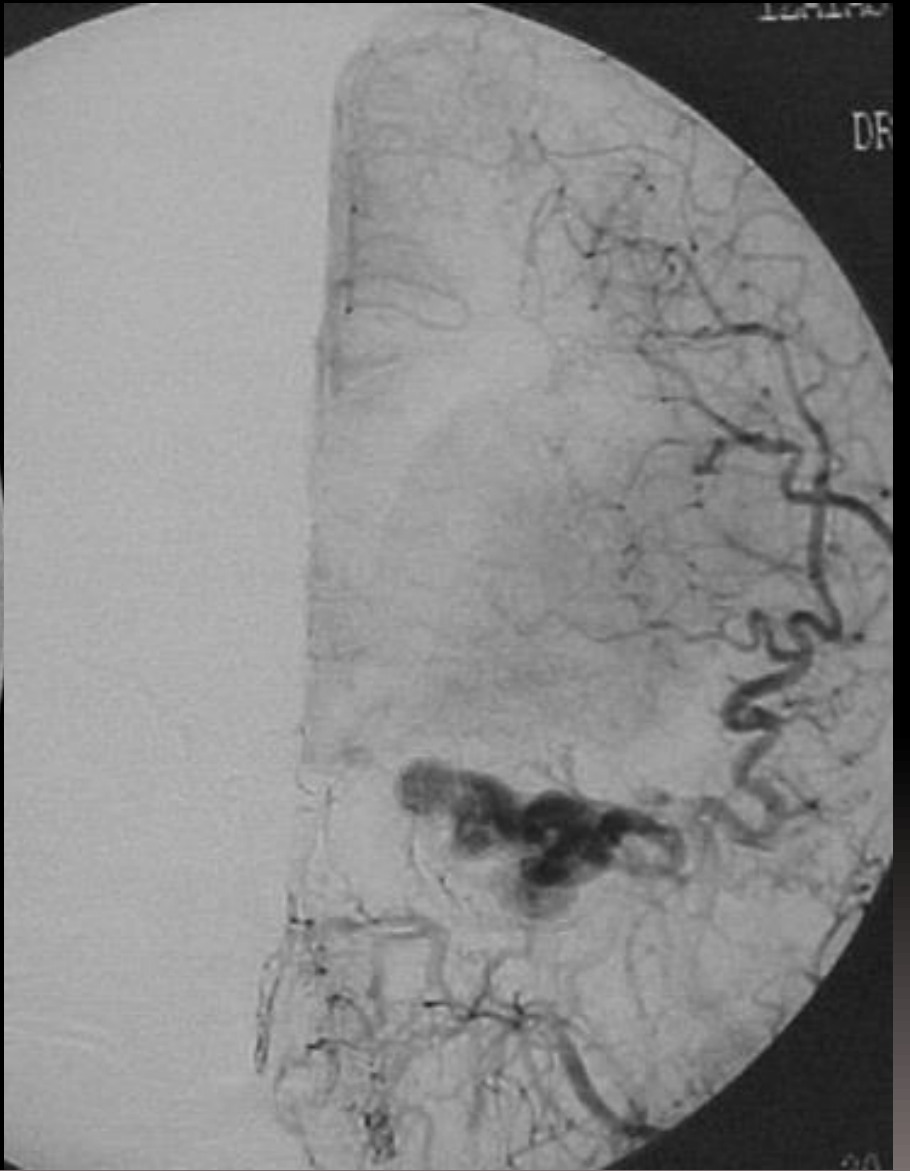
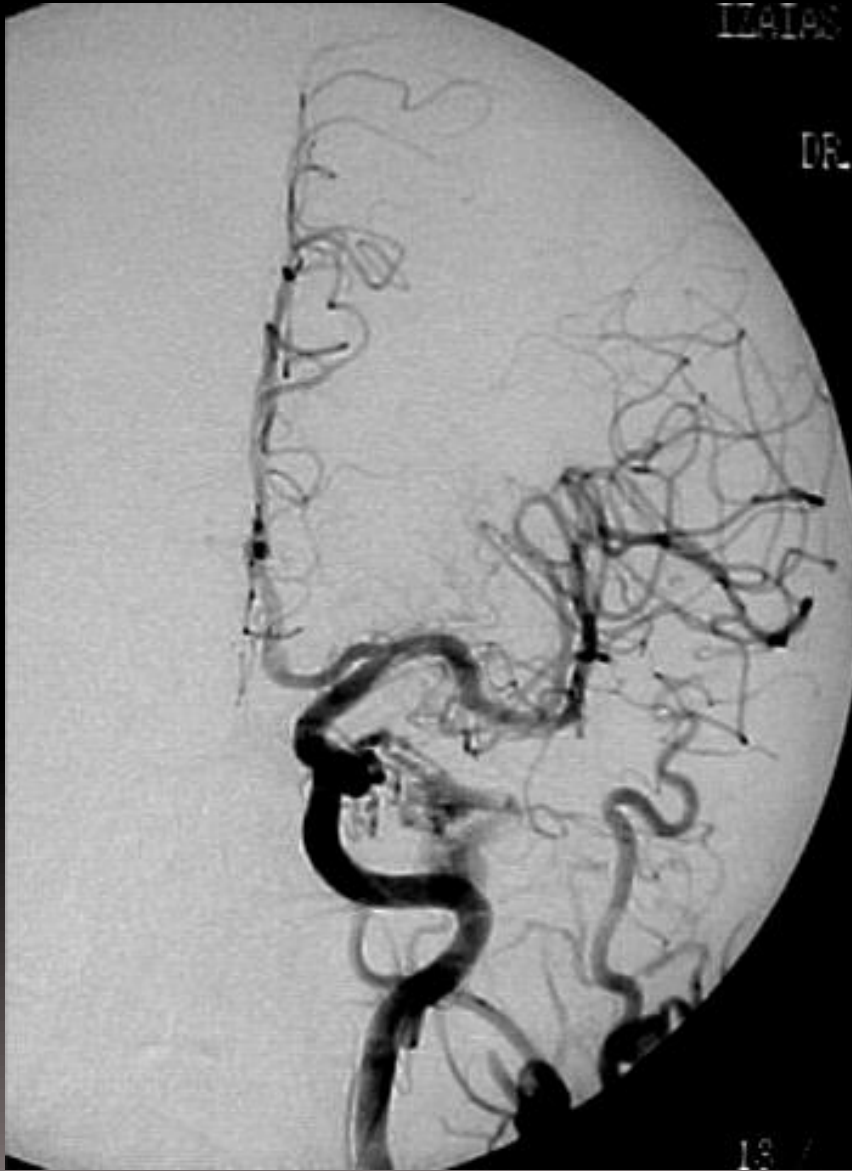# DURAL AVM

57 Y

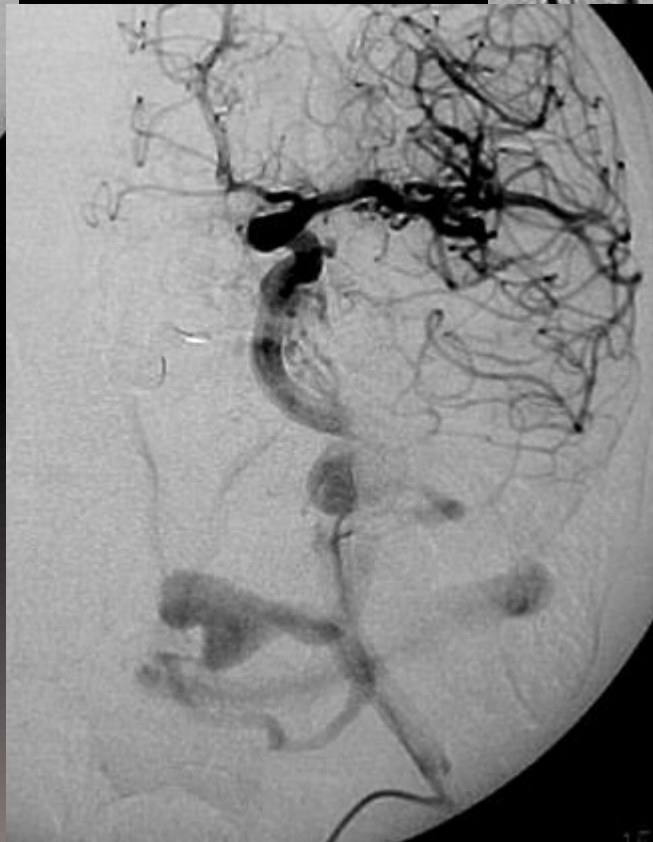
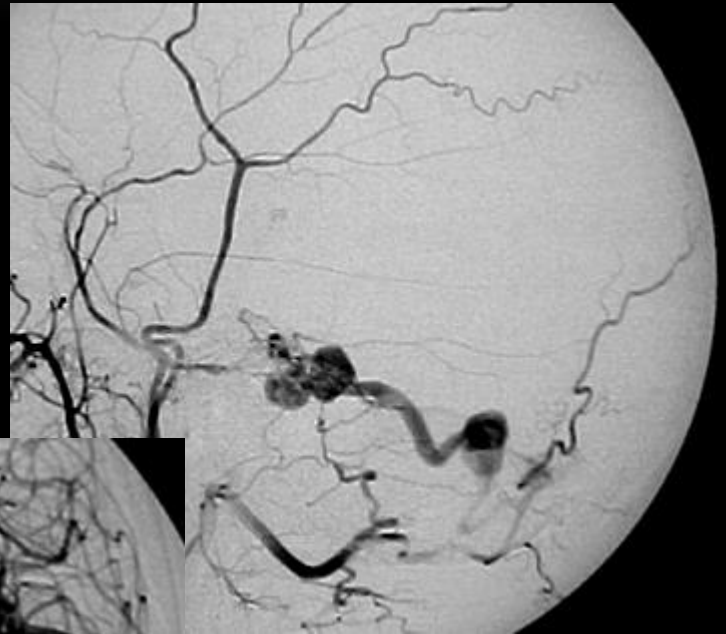
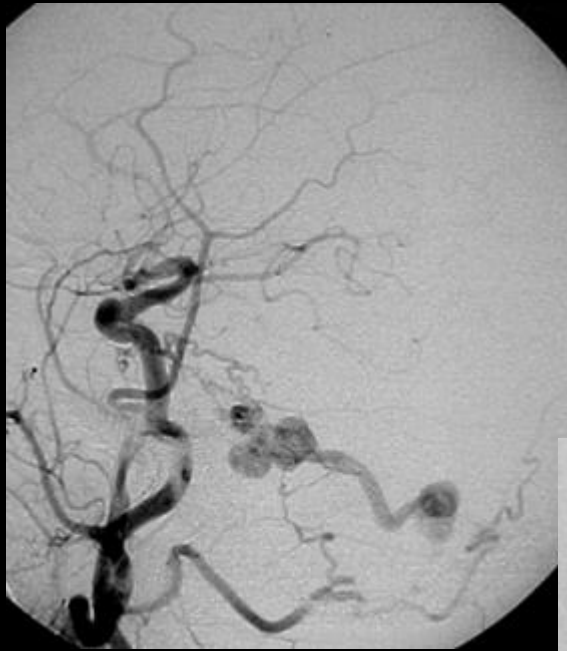
headache and cerebellar syndrome



# DURAL AVM

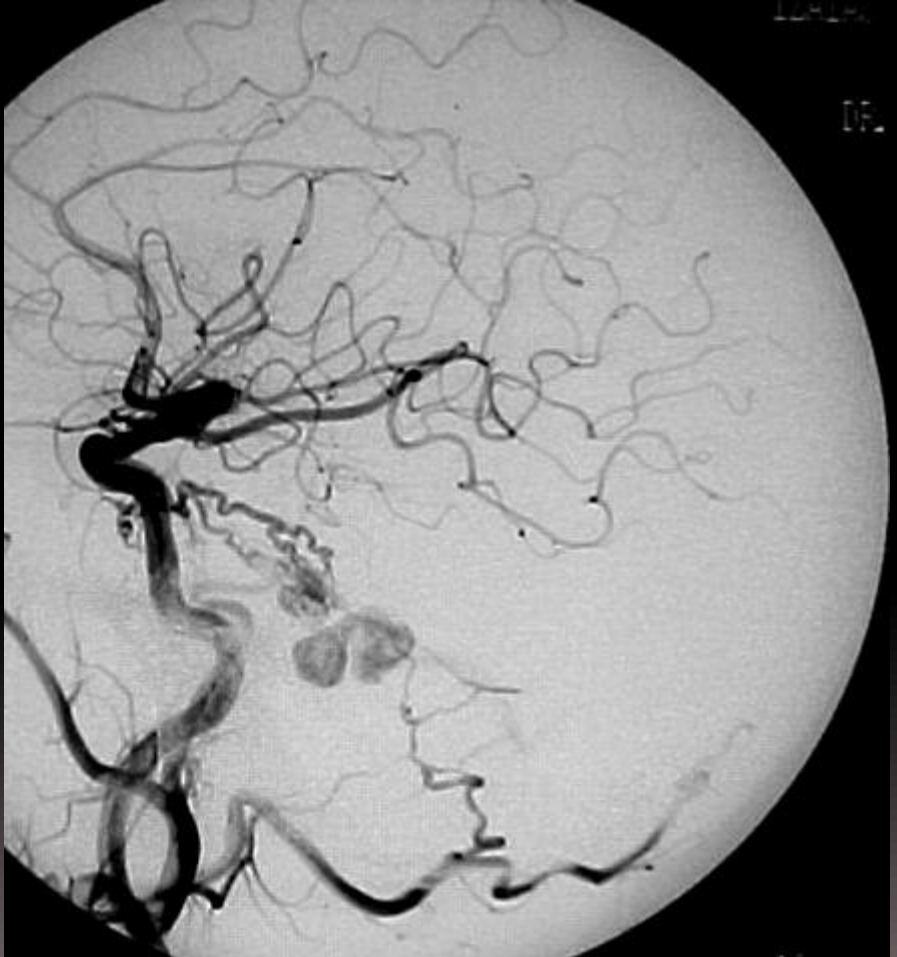
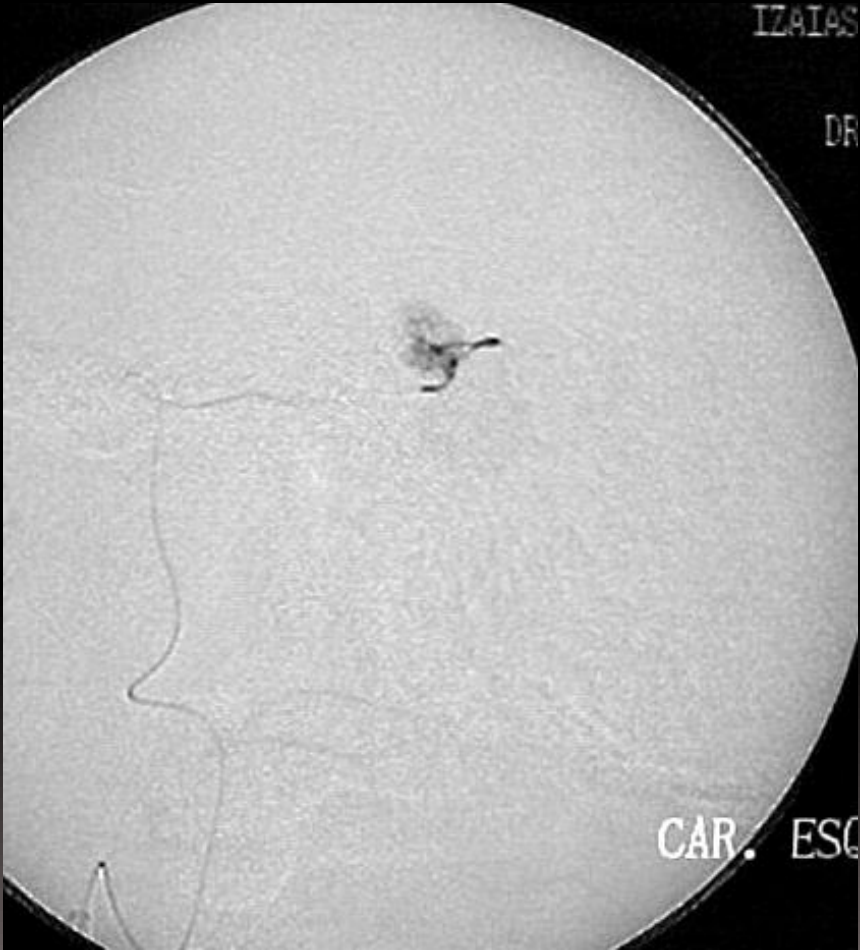
# DURAL AVM



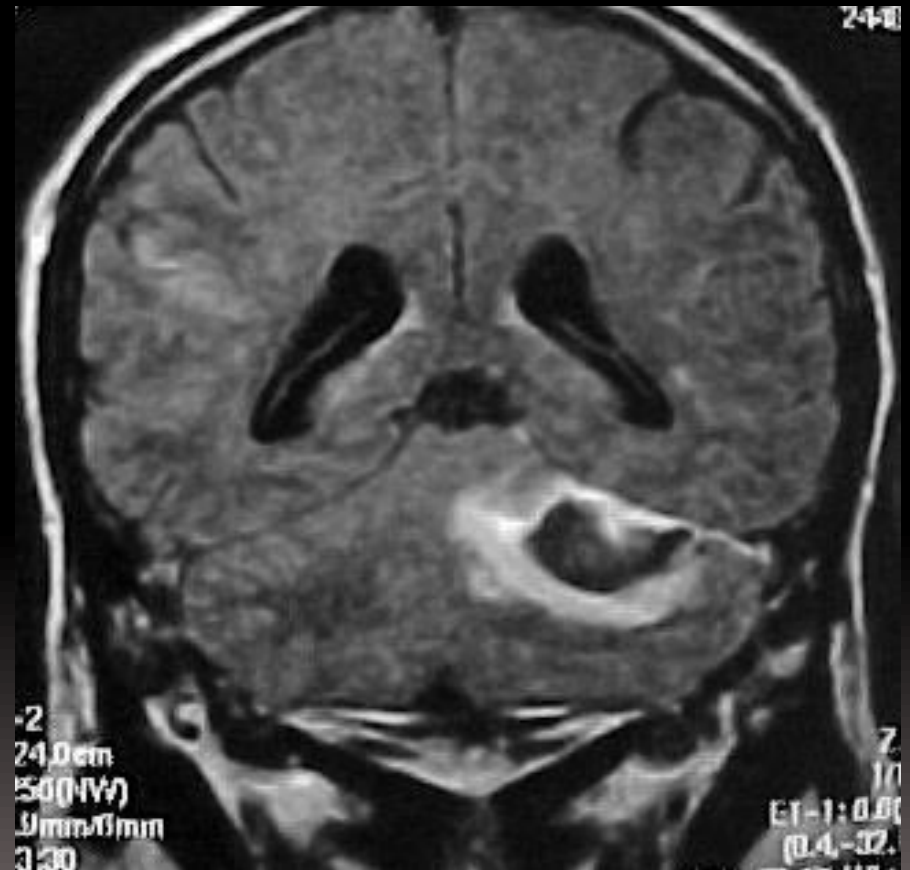
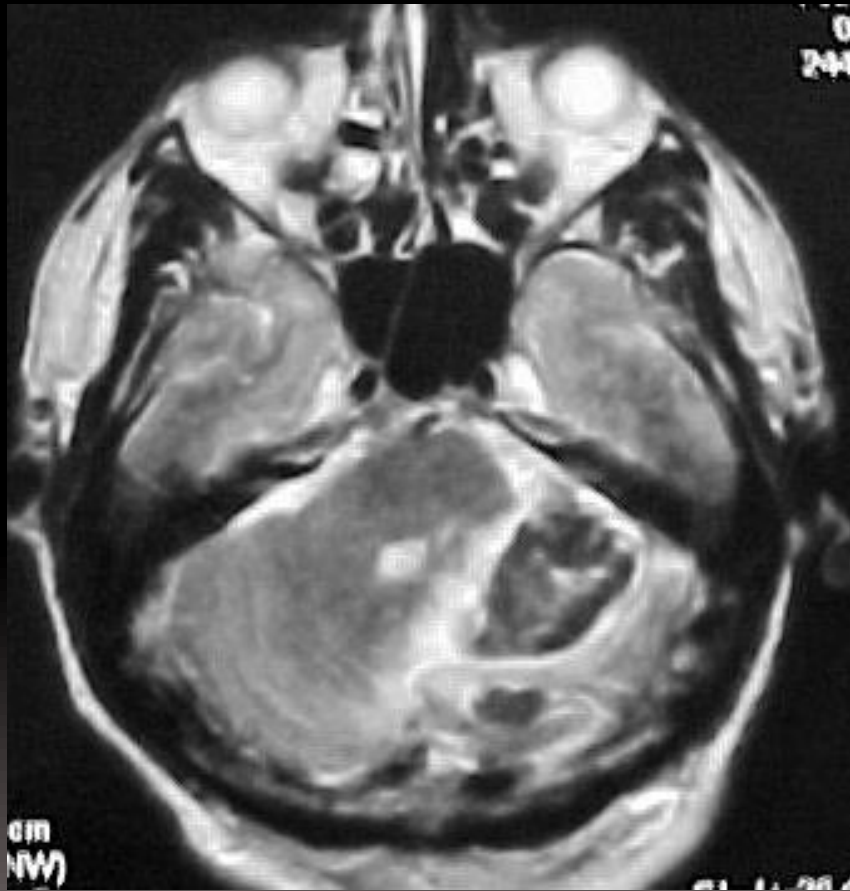


# DURAL AVM



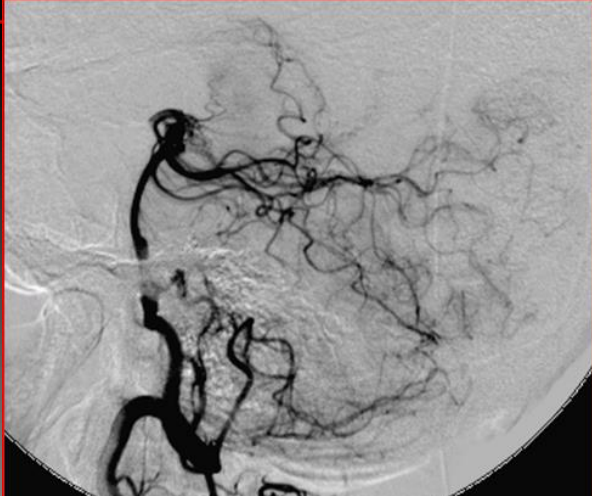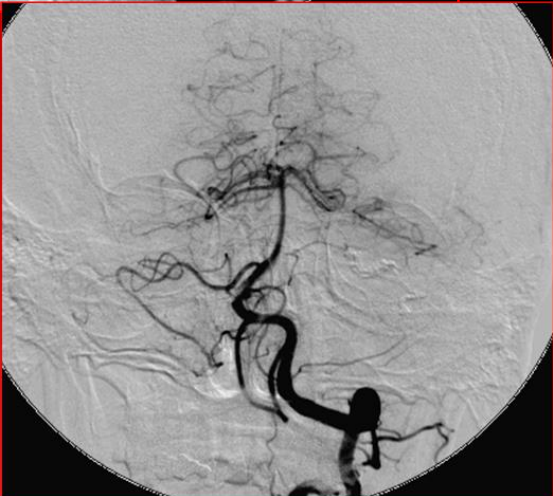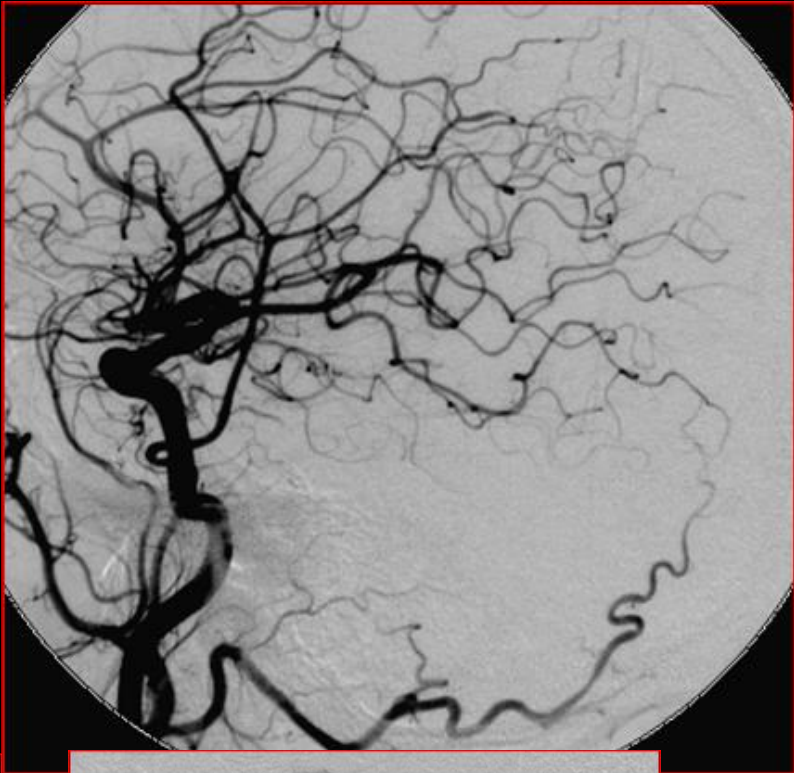
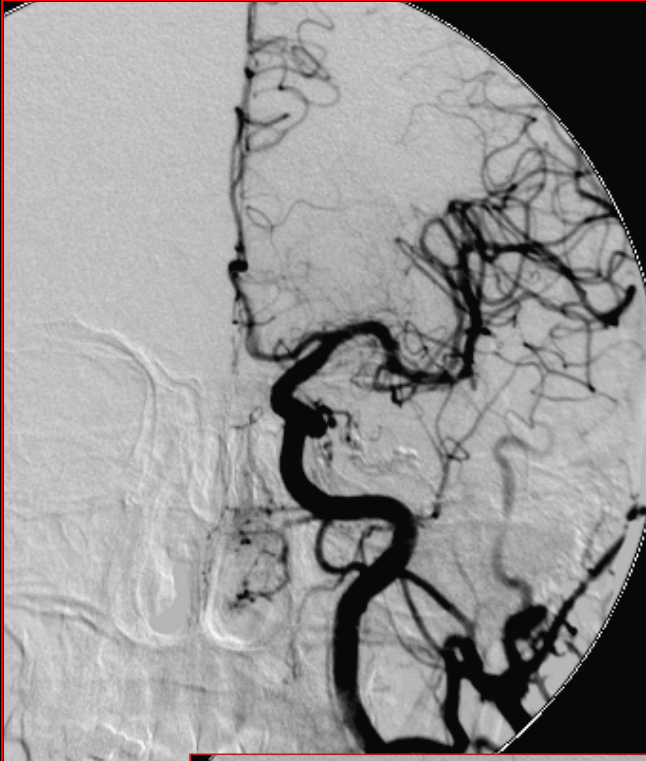


# DURAL AVM



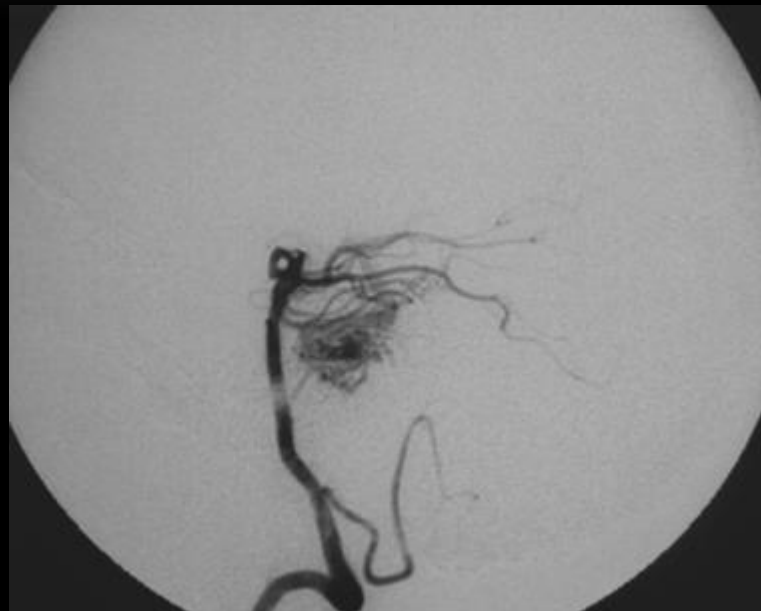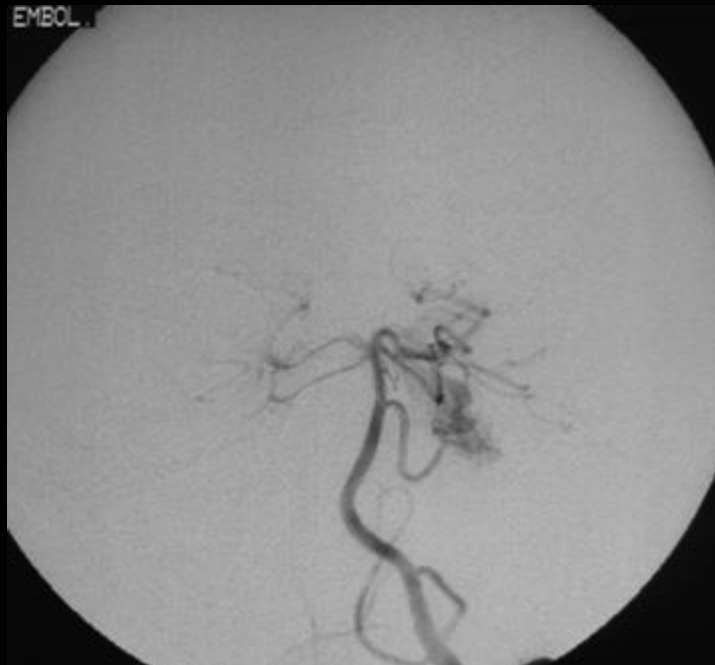Cerebellar hematoma

# DURAL AVM

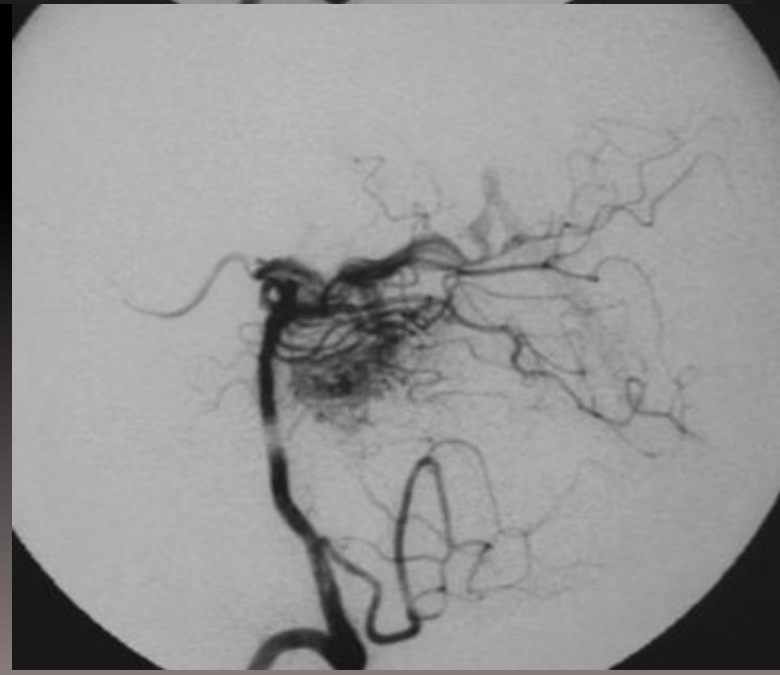
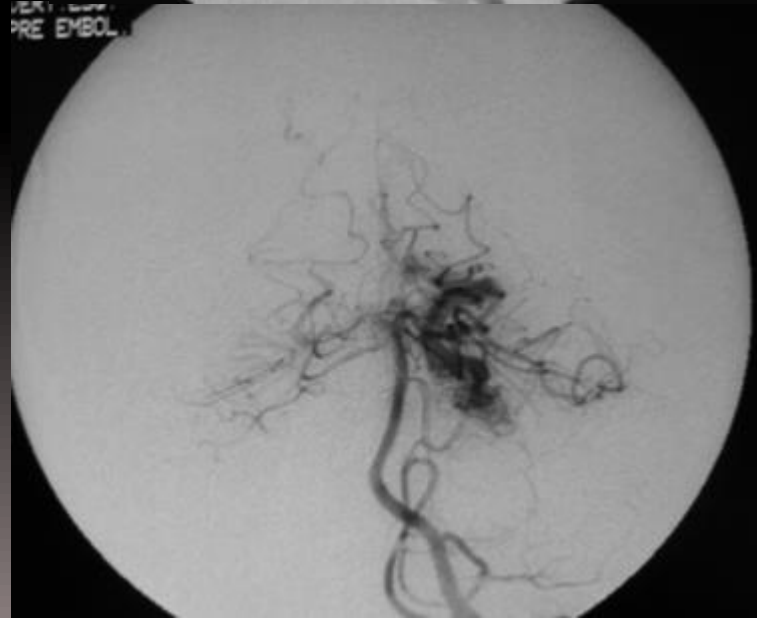

# DURAL AVM

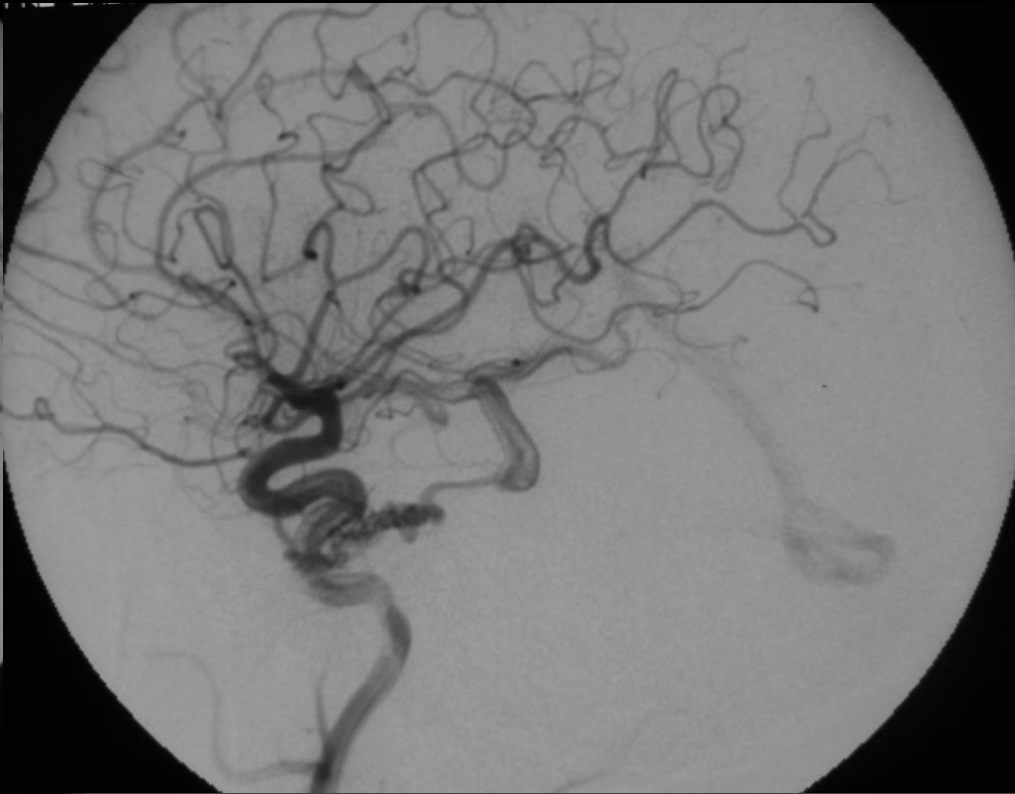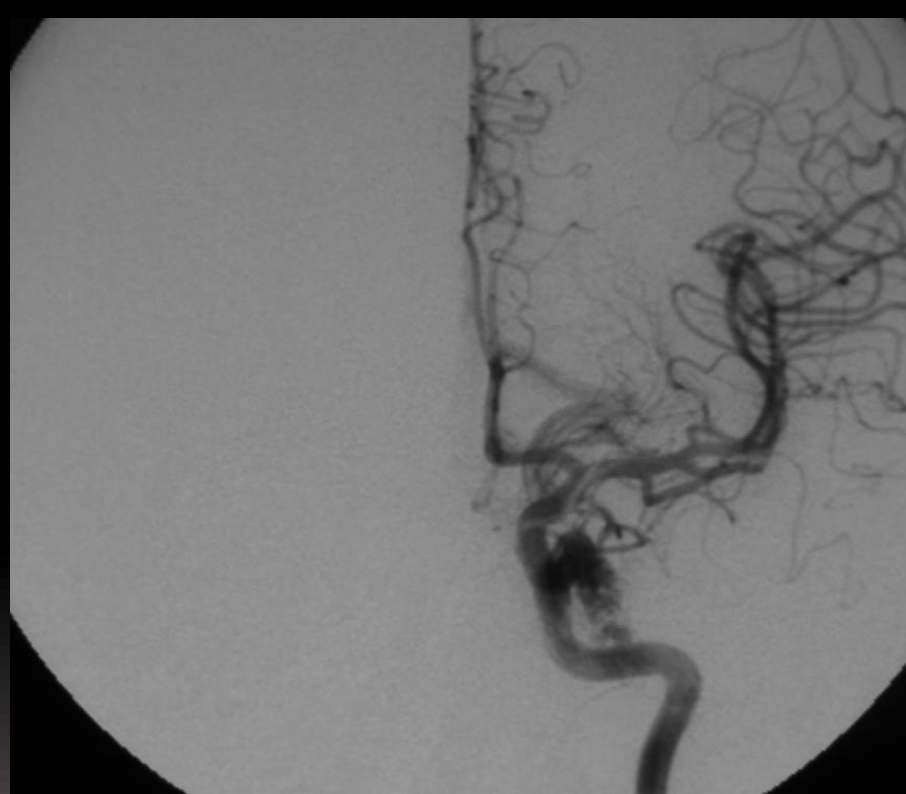EMBOL.



PRE EMBOL.



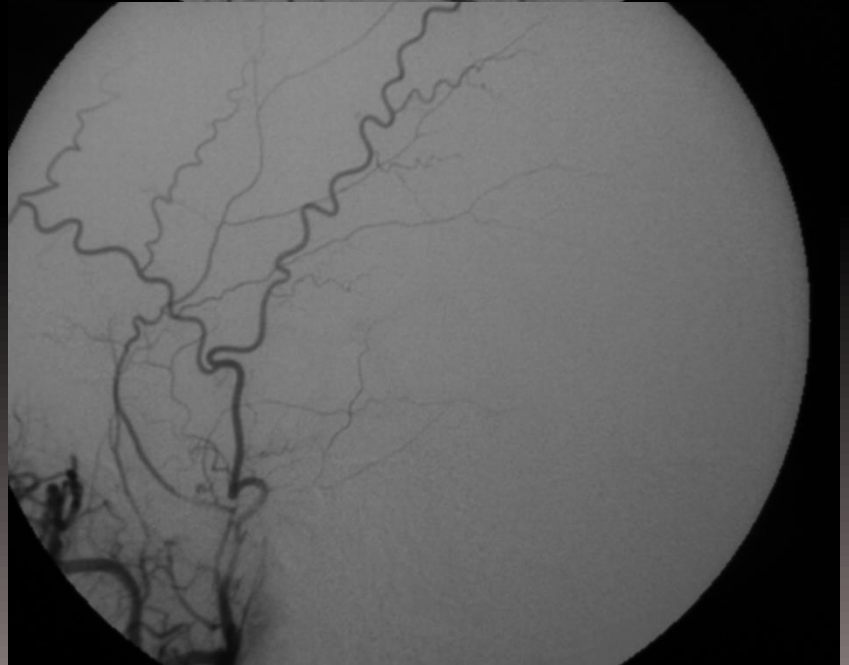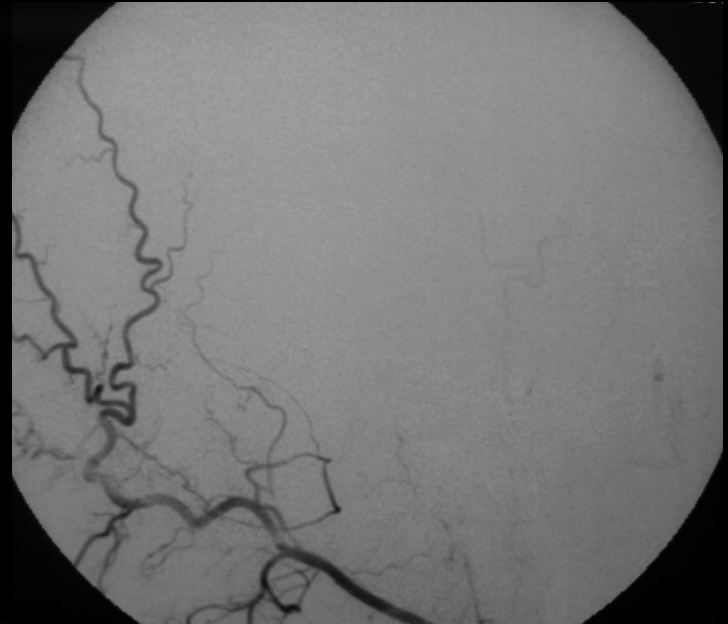
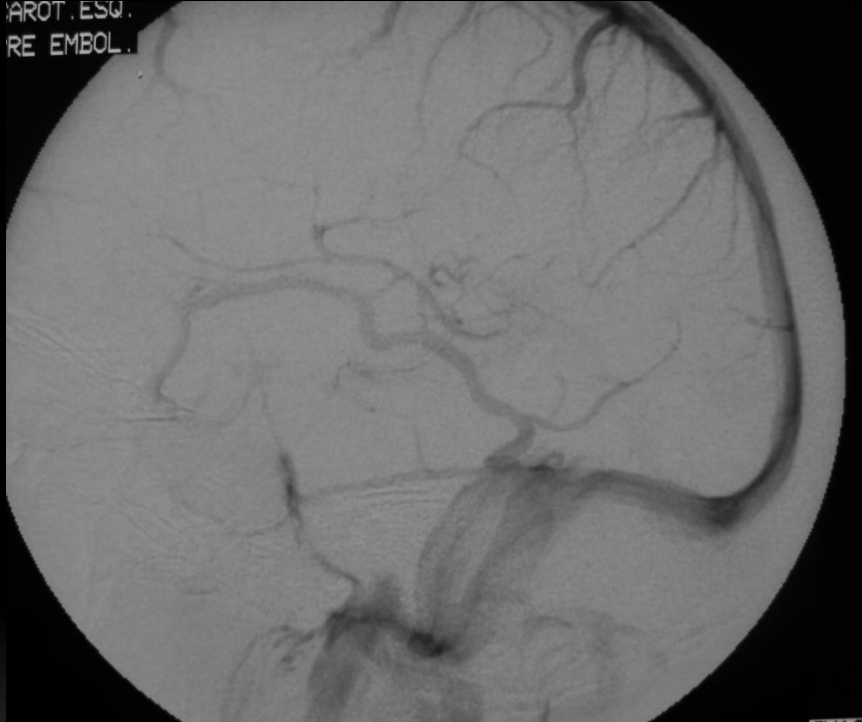# DURAL AVM



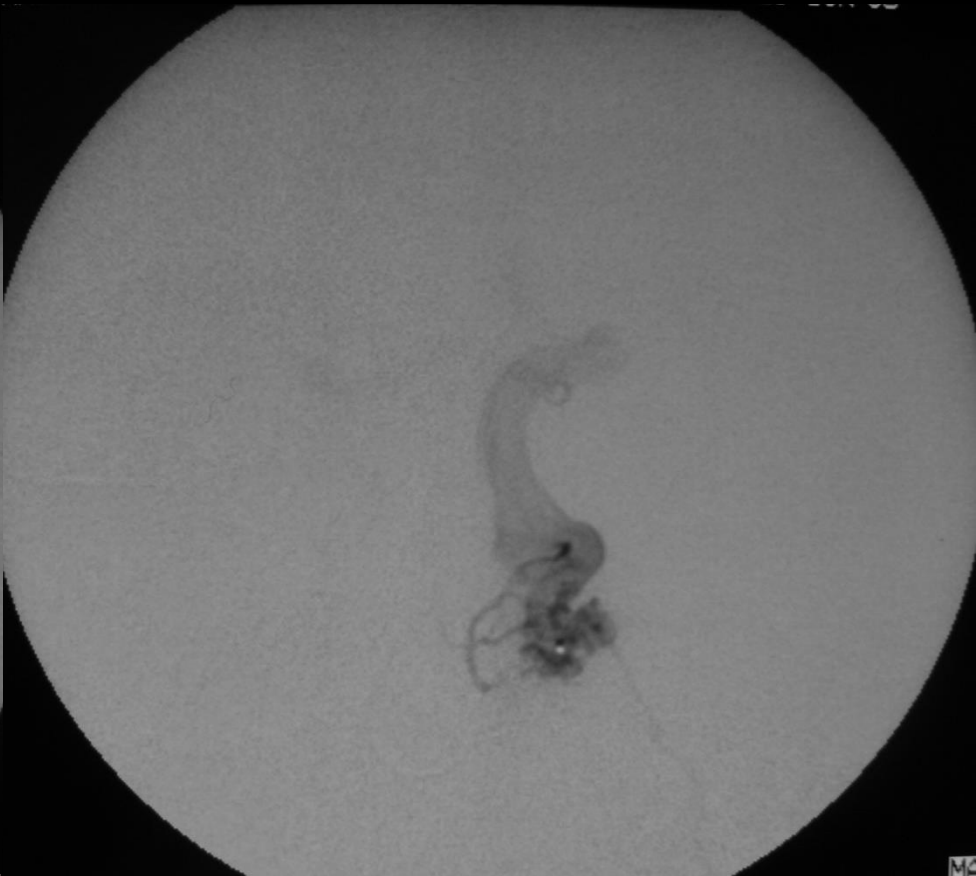
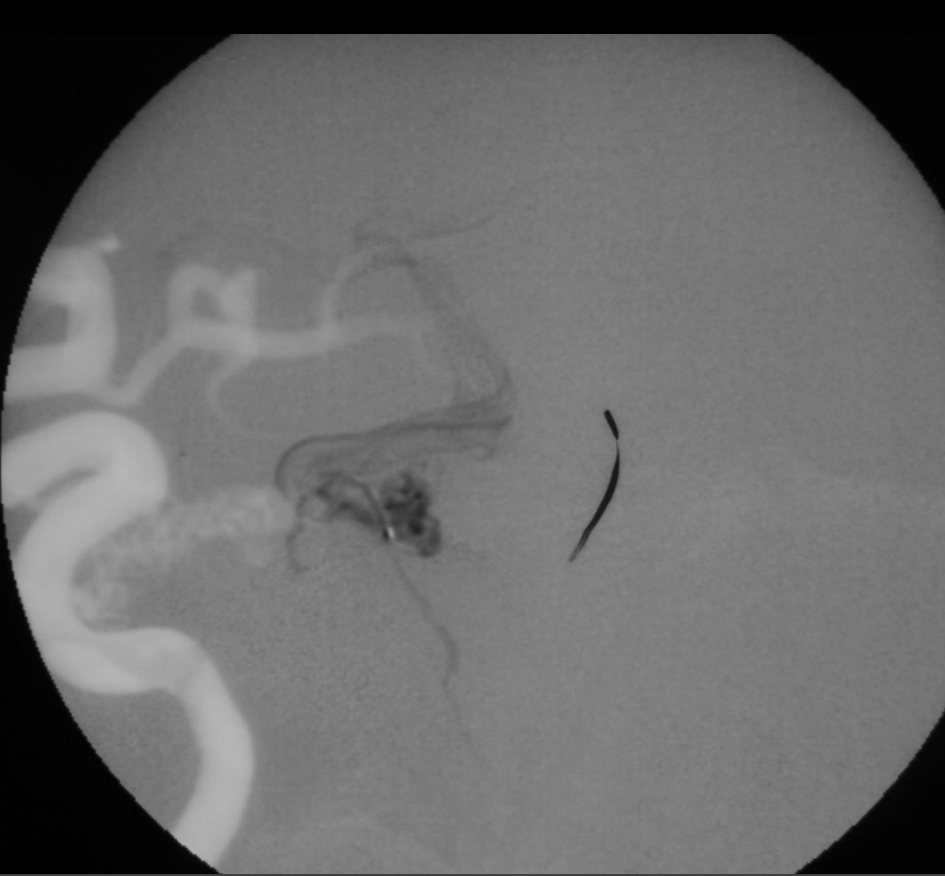
# DURAL AVM

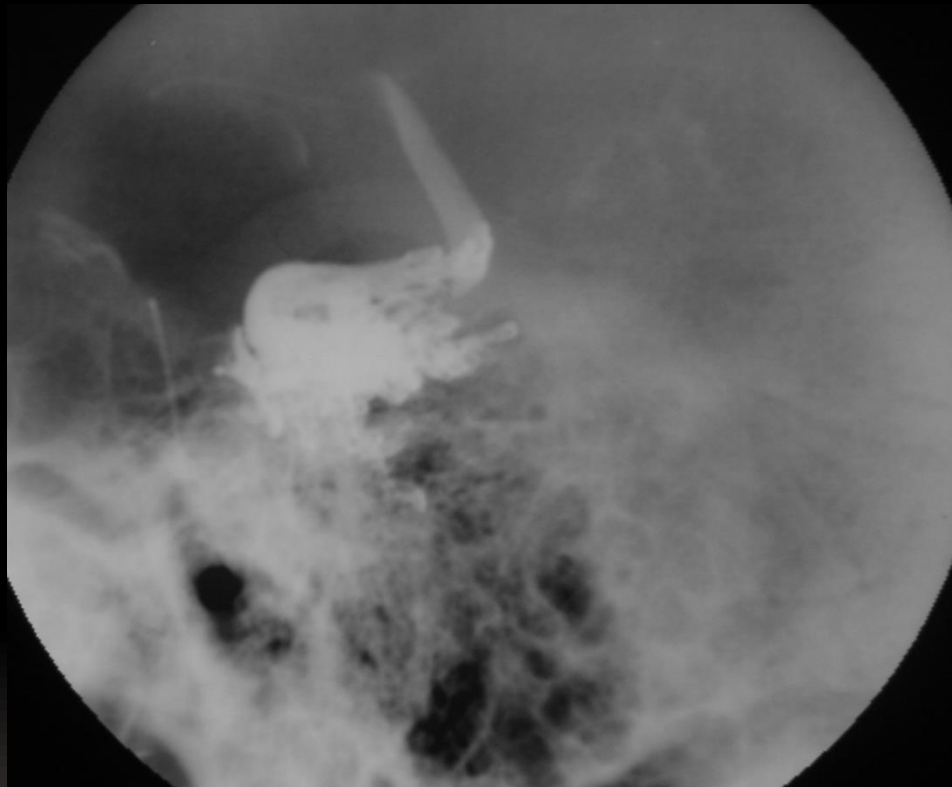
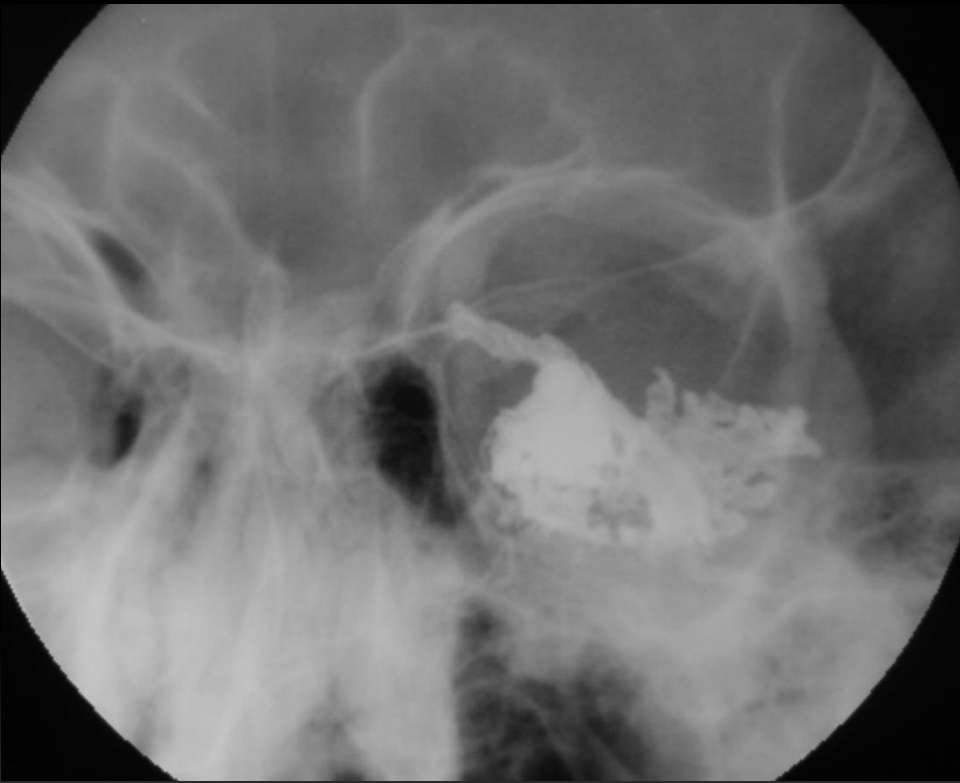
AROT. ESQ.  
RE EMBOL.



DURAL AVM

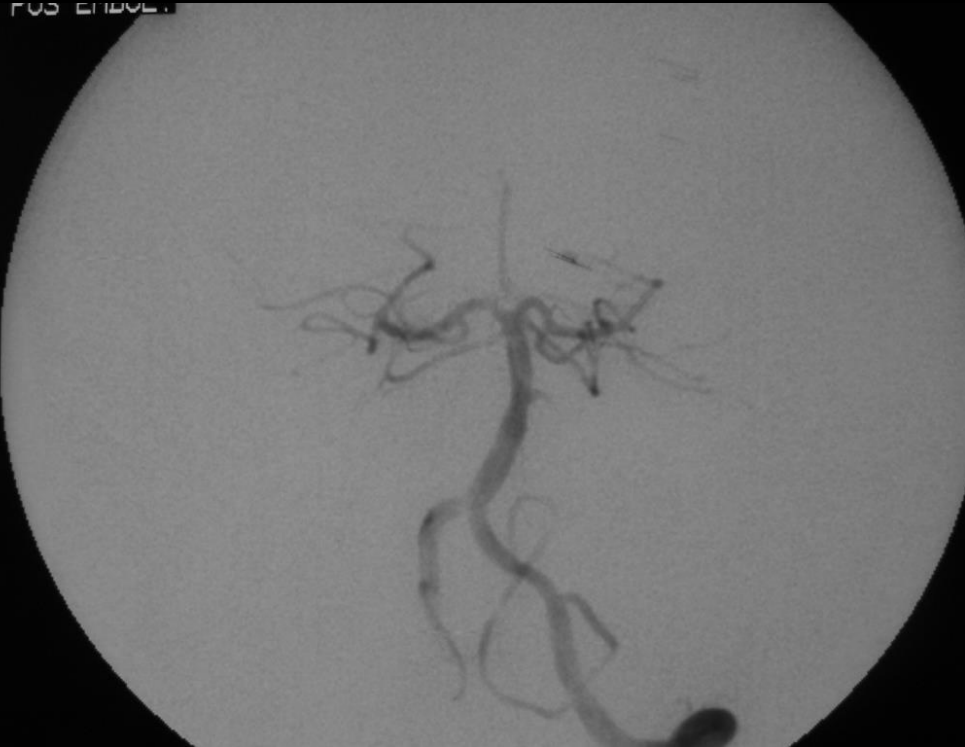

**DURAL AVM**

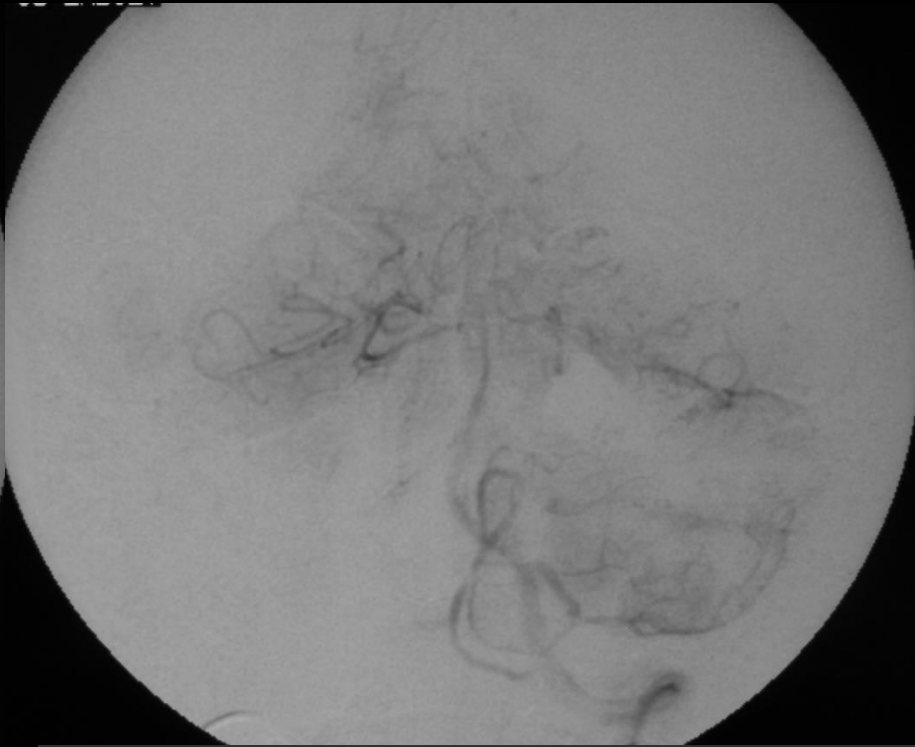

# DURAL AVM

P03 010001

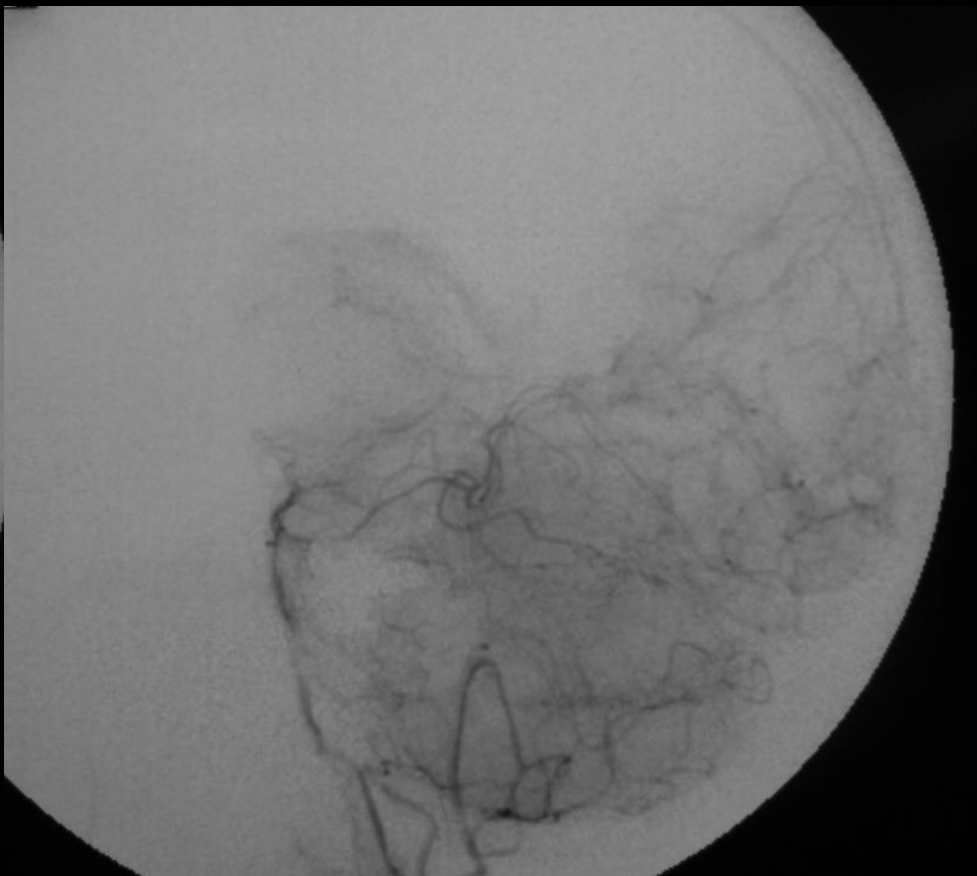
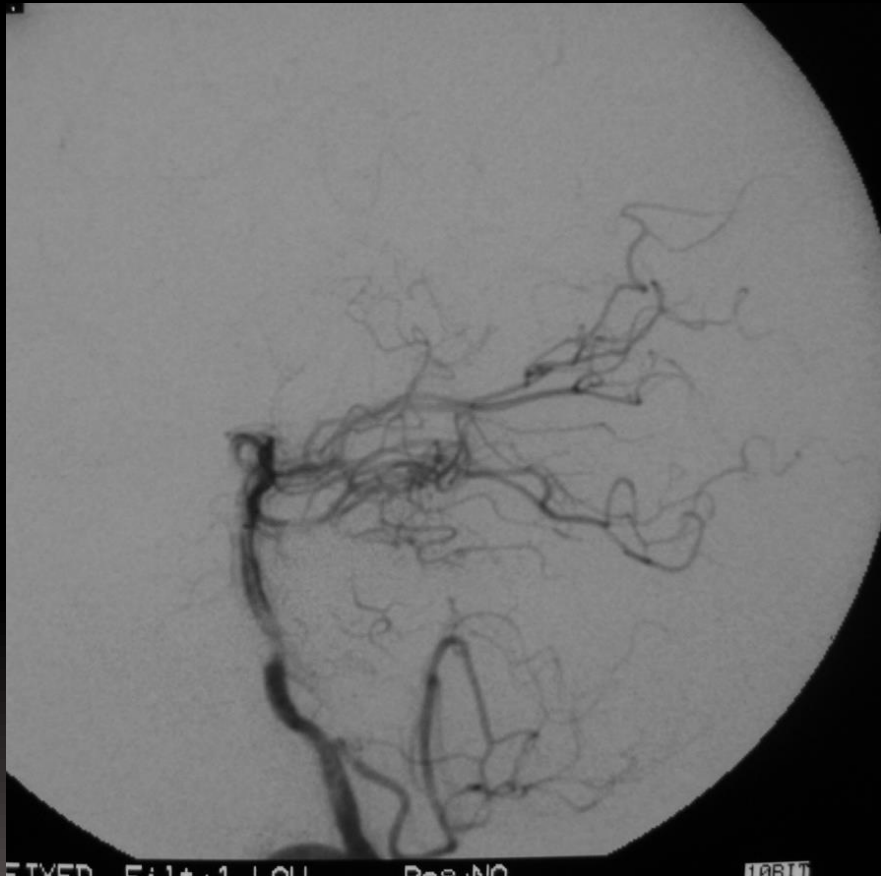

P03 010002





# DURAL AVM



Trigeminal neuralgia during 03 months

# GRACIAS

