



*medicina minimamente invasiva, liderando el camino*

*minimally invasive medicine, leading the way*

**XXV SEMANA DEL INTERVENCIONISMO MINIMAMENTE INVASIVO**  
**BUENOS AIRES ARGENTINA · 4/6 JULIO 2016 HOTEL HILTON**

# Percutaneous sclerotherapy of head and neck low-flow vascular malformations

**Jorge Guedes Campos**

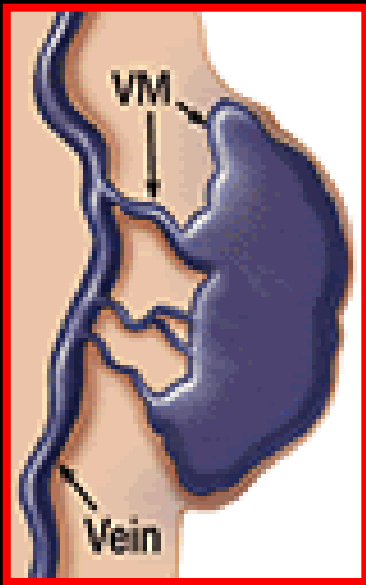
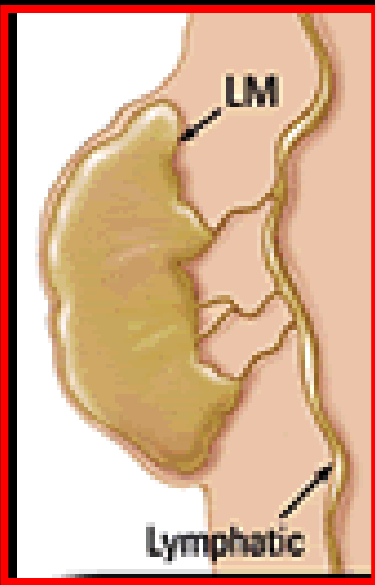
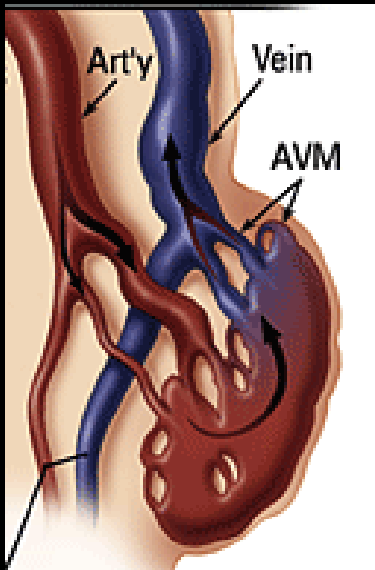
**Serviço de Imagiologia Neurológica**

**CHLN, EPE – Hospital Universitário de Santa Maria**

# Percutaneous sclerotherapy of head and neck low-flow vascular malformations

## Introduction / Objective

Vascular tumors	Vascular malformations
Infantile hemangioma	Slow-flow
Congenital hemangioma	Capillary malformations
Tufted angioma	Venous malformations
Kaposiform hemangioendothelioma	Lymphatic malformations
	Fast-flow
	Arteriovenous malformations



# **Percutaneous sclerotherapy of head and neck low-flow vascular malformations**

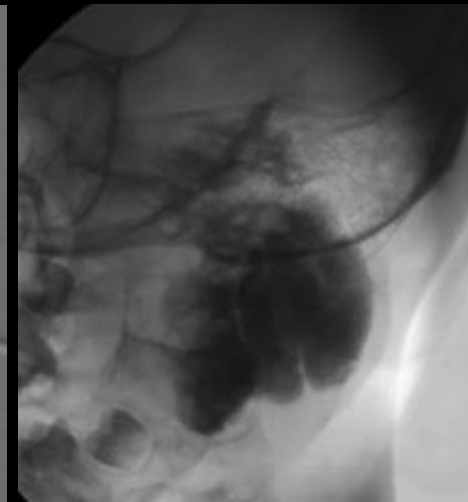
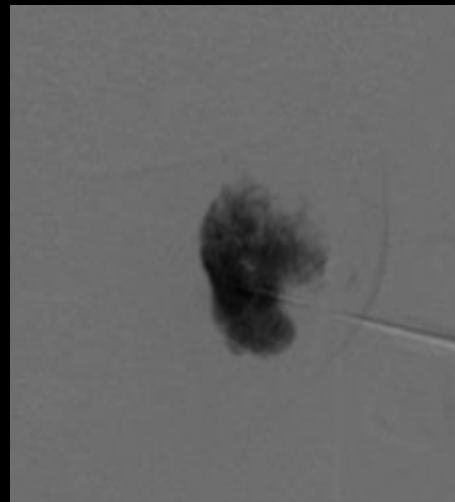
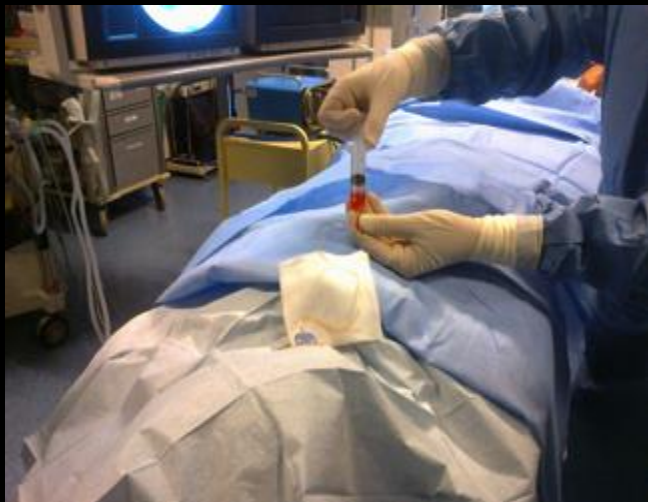## **Material / Methods**

- **Retrospective Review**
- **Aug 2011 – Jun 2016**
- **12 patients**
  
- **5 males**
- **7 females**
  
- **0 - 5 yo – 4 patients**
- **10-20 yo – 2 patients**
- **> 20 yo – 6 patients**
  
- **8 venous**
- **2 lymphatic**
- **2 capillary**
  
- **swelling (12)**
- **cosmetic deformity (12)**
- **hemorrhage (3)**
- **functional problems (2)**

# Percutaneous sclerotherapy of head and neck low-flow vascular malformations

## Material / Methods

- Physical Examination
- Doppler
- CT Scan / MRI
- Angiographic suite
- General anesthesia
- AB + steroids
- Aspirate first
- Bleomycin – 1
- Alcohol – 3
- Sclerogel ® - 3
- Alcohol + Bleomycin – 2
- Alcohol + Sclerogel ® - 3
- If venous drainage compress the vein while injecting the sclerosing agent



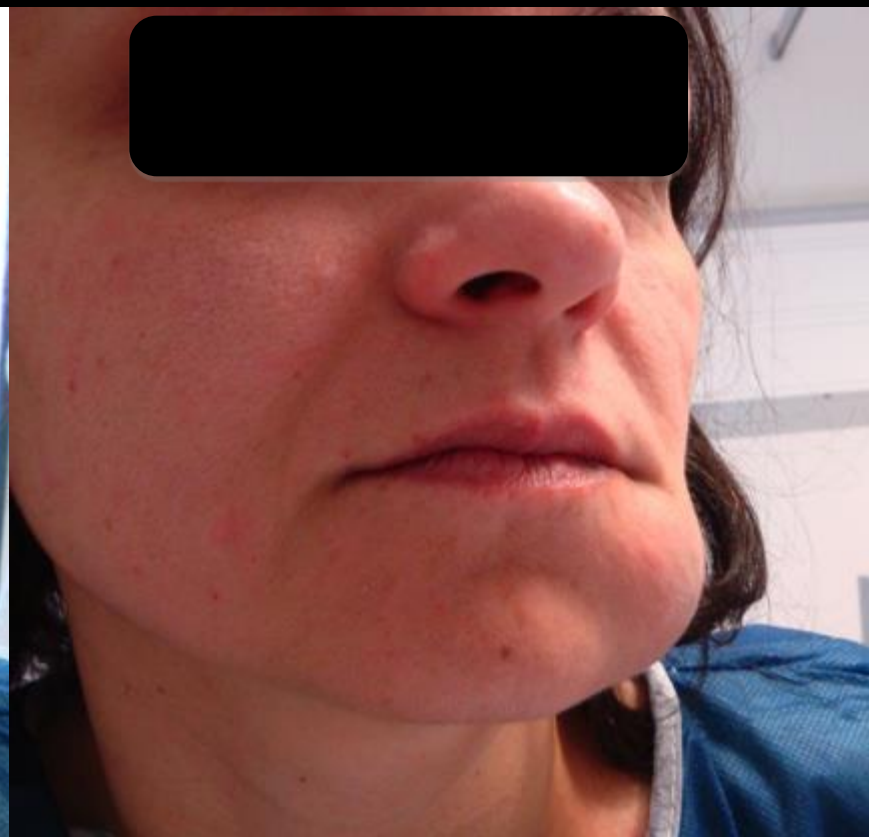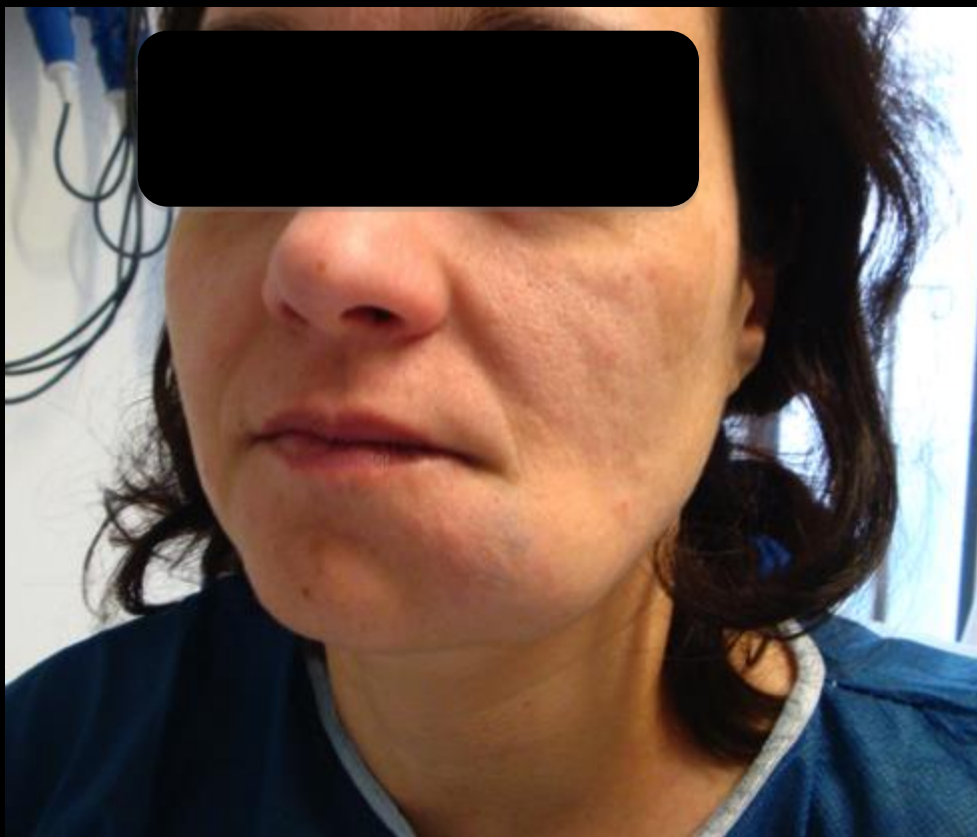# **Clinical Cases**

# Percutaneous sclerotherapy of head and neck low-flow vascular malformations

40 yo, ♀

Venous malformation

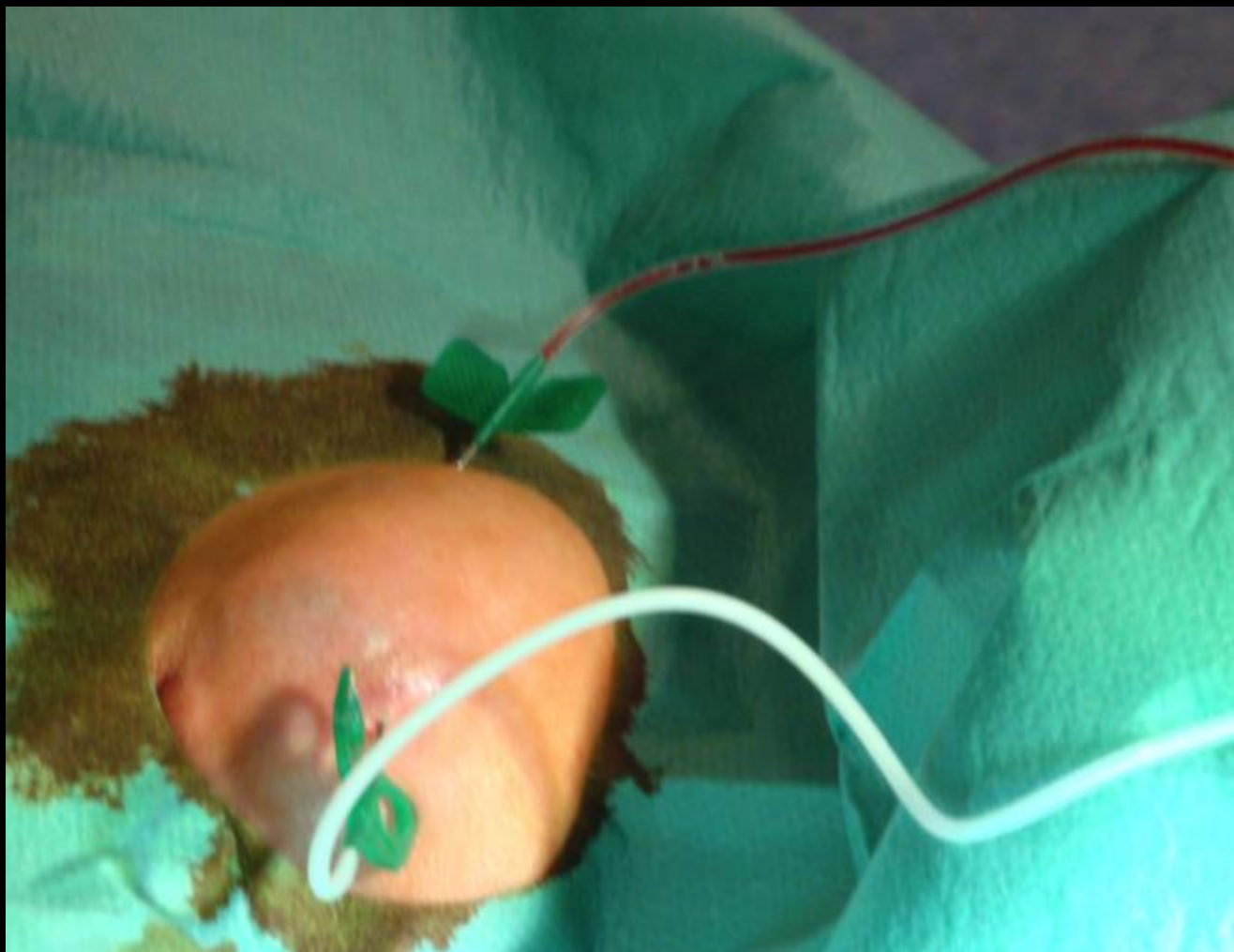Inferior lip/chin - previous surgery



# Percutaneous sclerotherapy of head and neck low-flow vascular malformations

**2 session - 5 punctures**

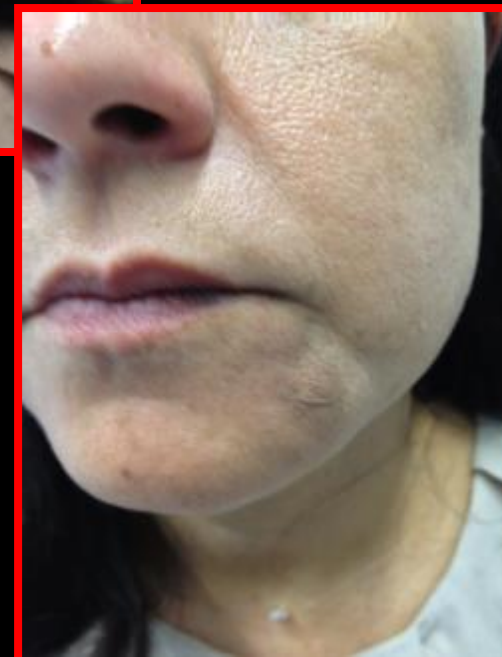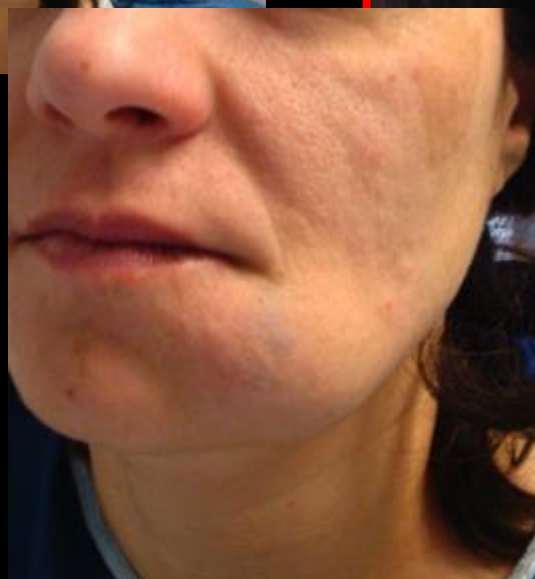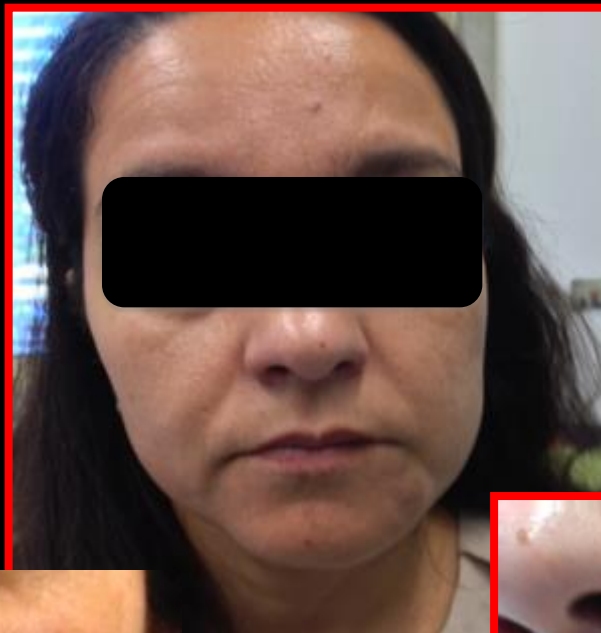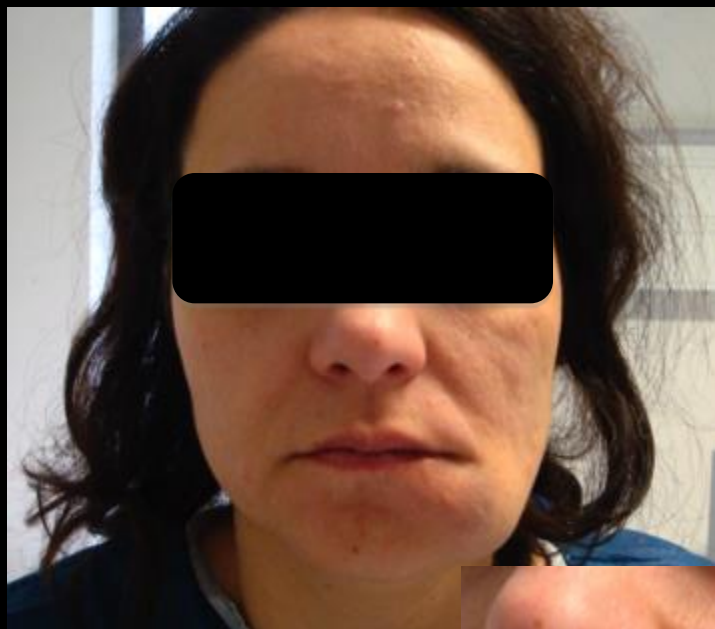**18 cc alcohol (99%)**



# Percutaneous sclerotherapy of head and neck low-flow vascular malformations

Jan / 2013

Sept / 2013



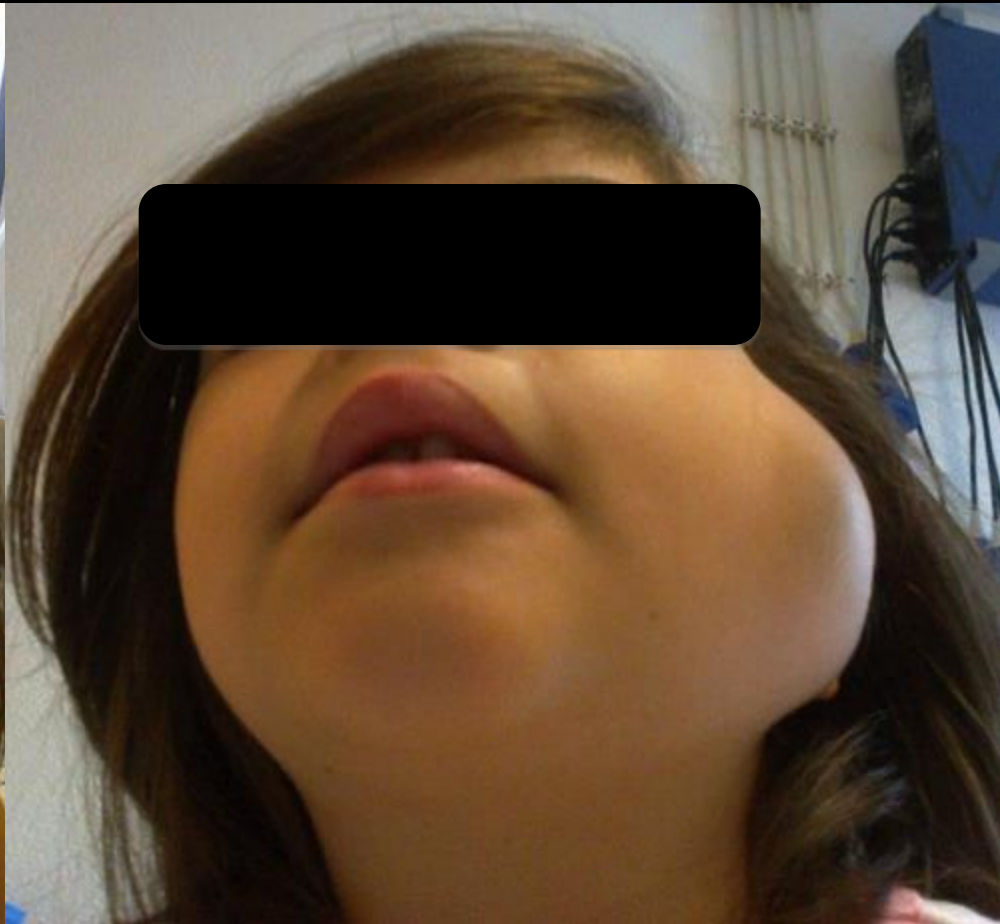
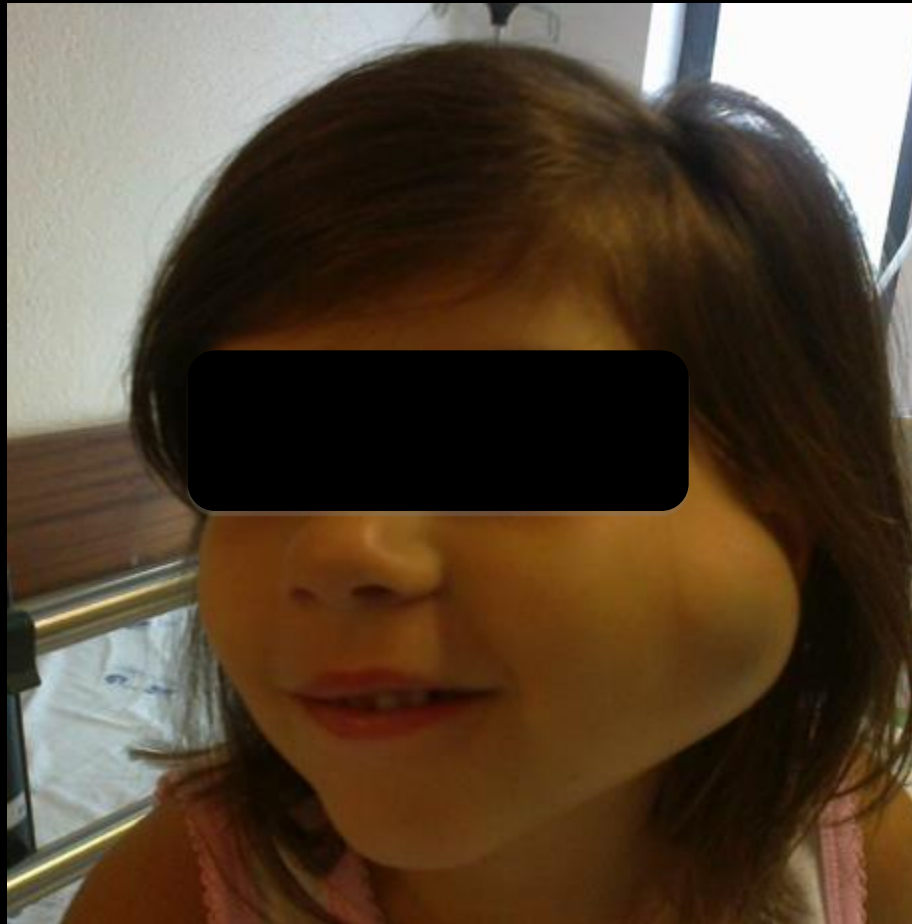
# Percutaneous sclerotherapy of head and neck low-flow vascular malformations

5 yo, ♀

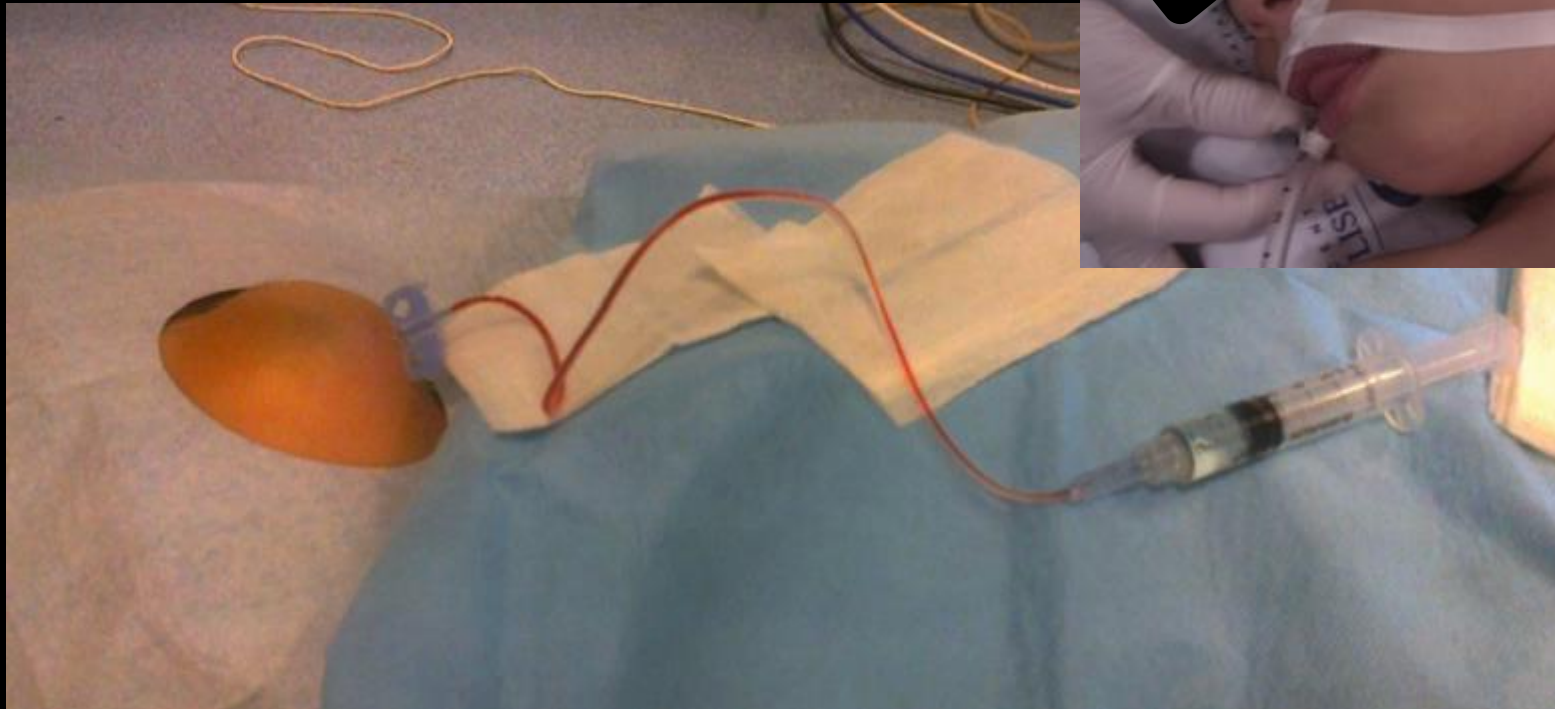
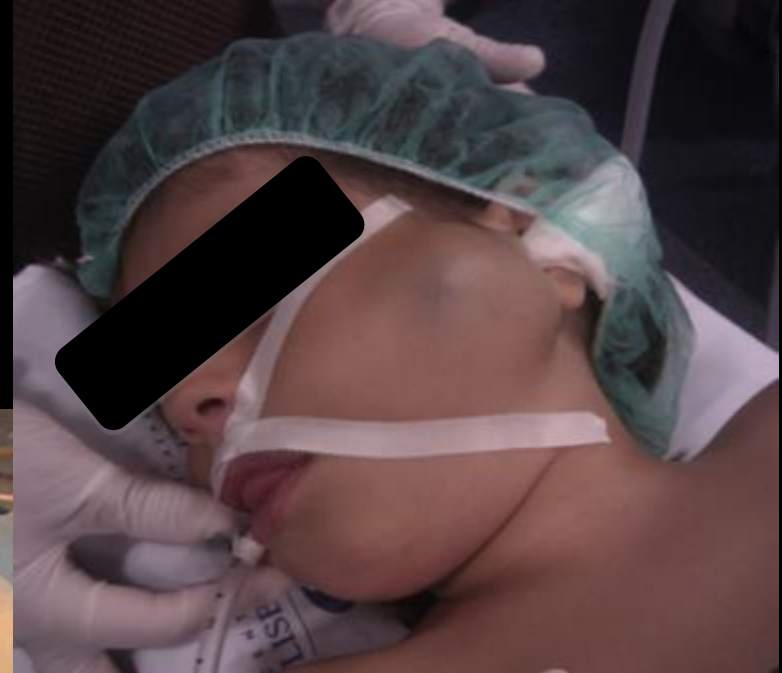Venous malformation

Left cheek



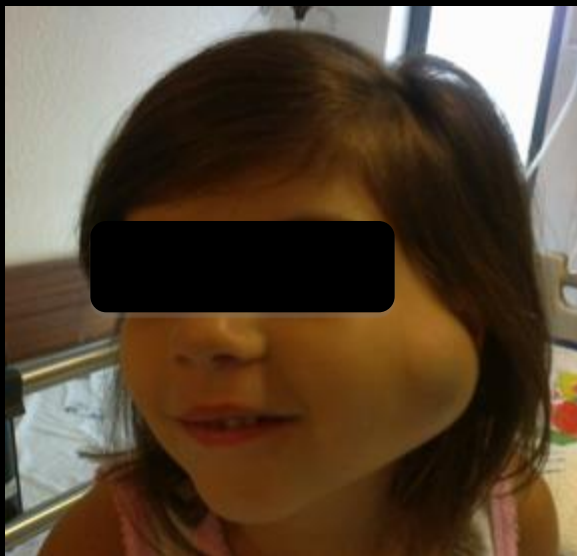## Percutaneous sclerotherapy of head and neck low-flow vascular malformations

**2 sessions - 10 mo in between**  
**4 punctures + 5 punctures**  
**8,5 cc + 10cc alcohol (99%)**



# Percutaneous sclerotherapy of head and neck low-flow vascular malformations

**Aug / 2011**



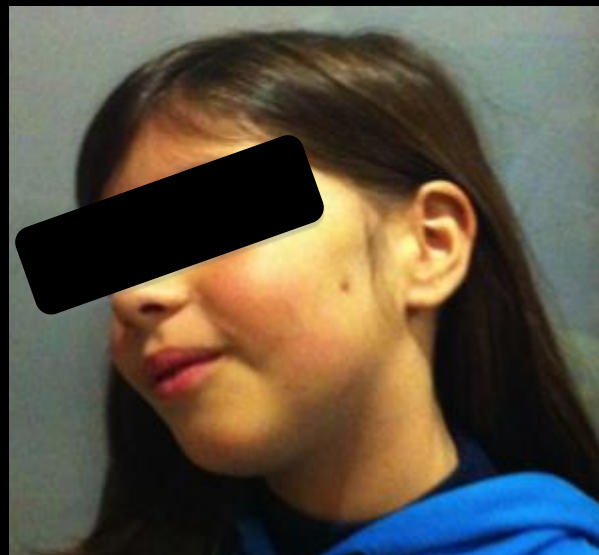**Apr / 2012**



**Dec / 2012**



**Feb / 2013**



**Percutaneous sclerotherapy of head and neck low-flow vascular malformations**

**40 yo, ♀**

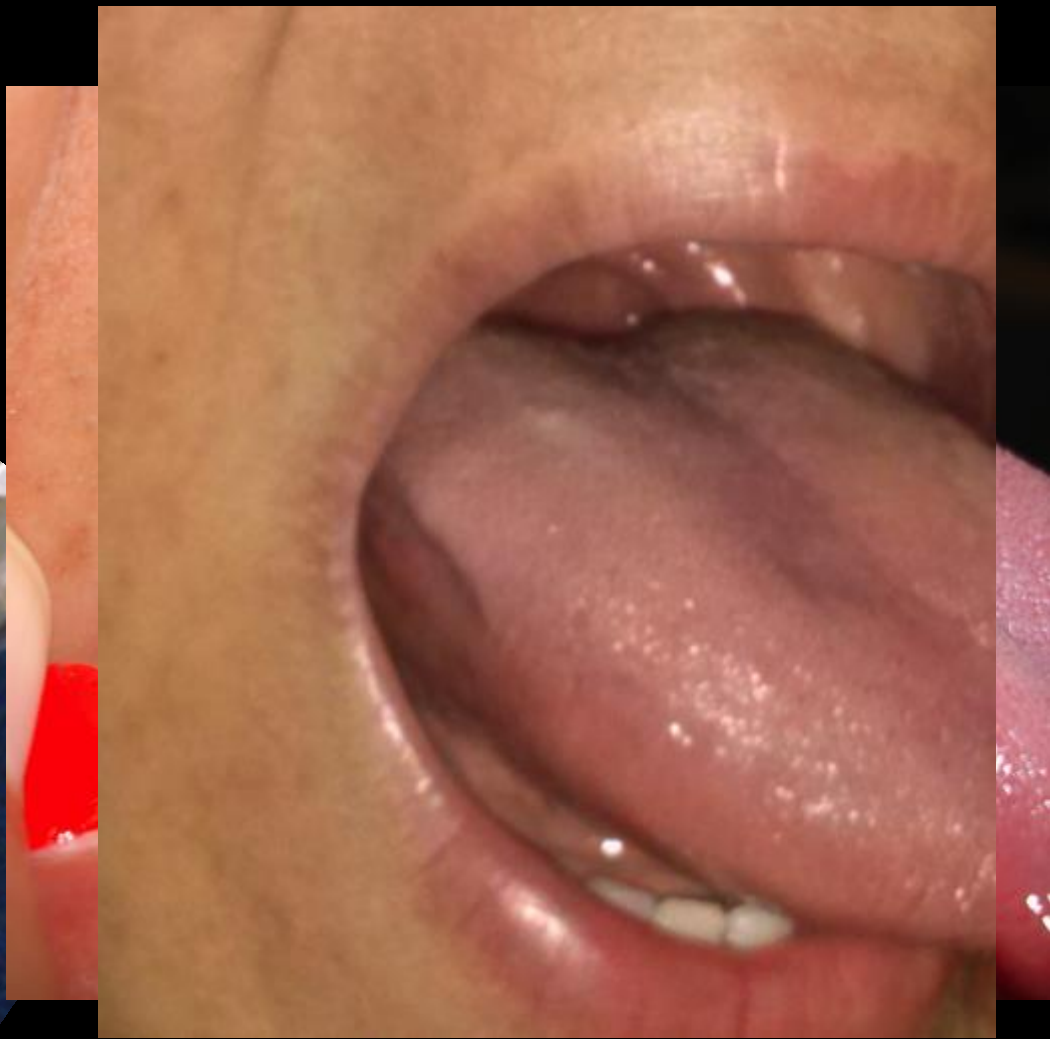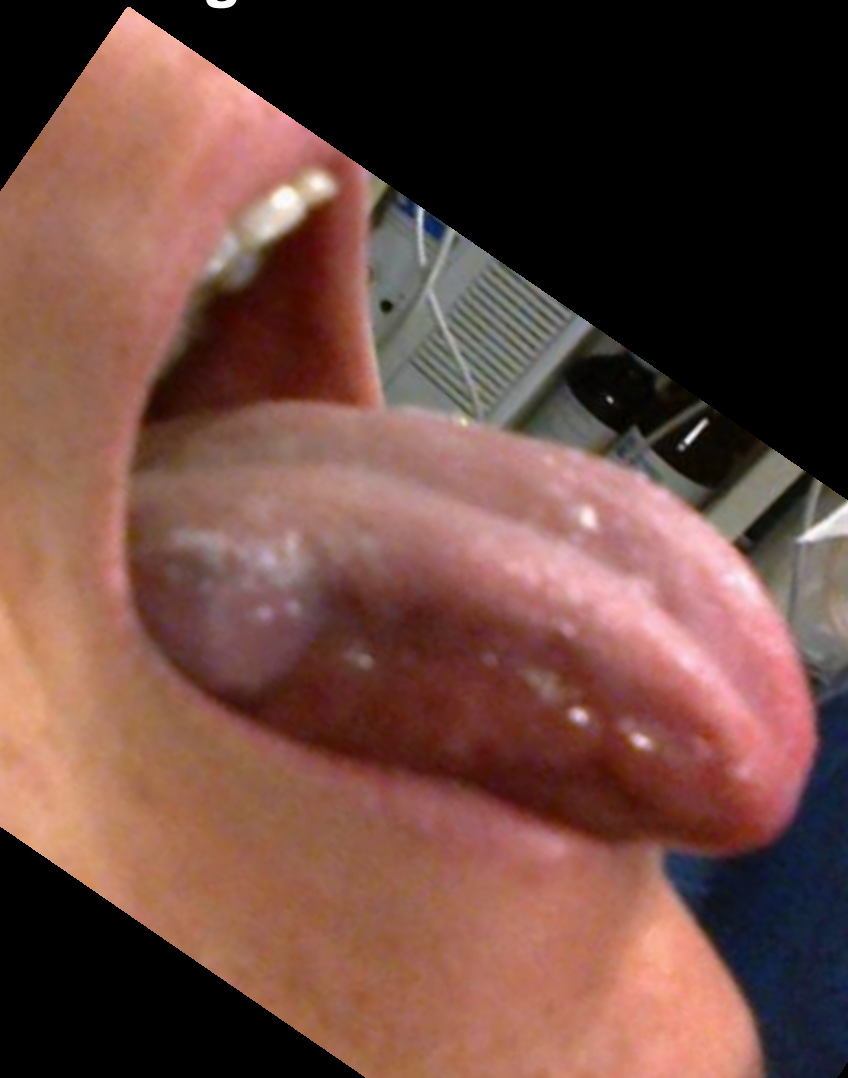
**Venous malformation**

**Tongue**

**2 sessions - 7 mo in between**

**12000U bleomycin**

**2cc alcohol (99%)**

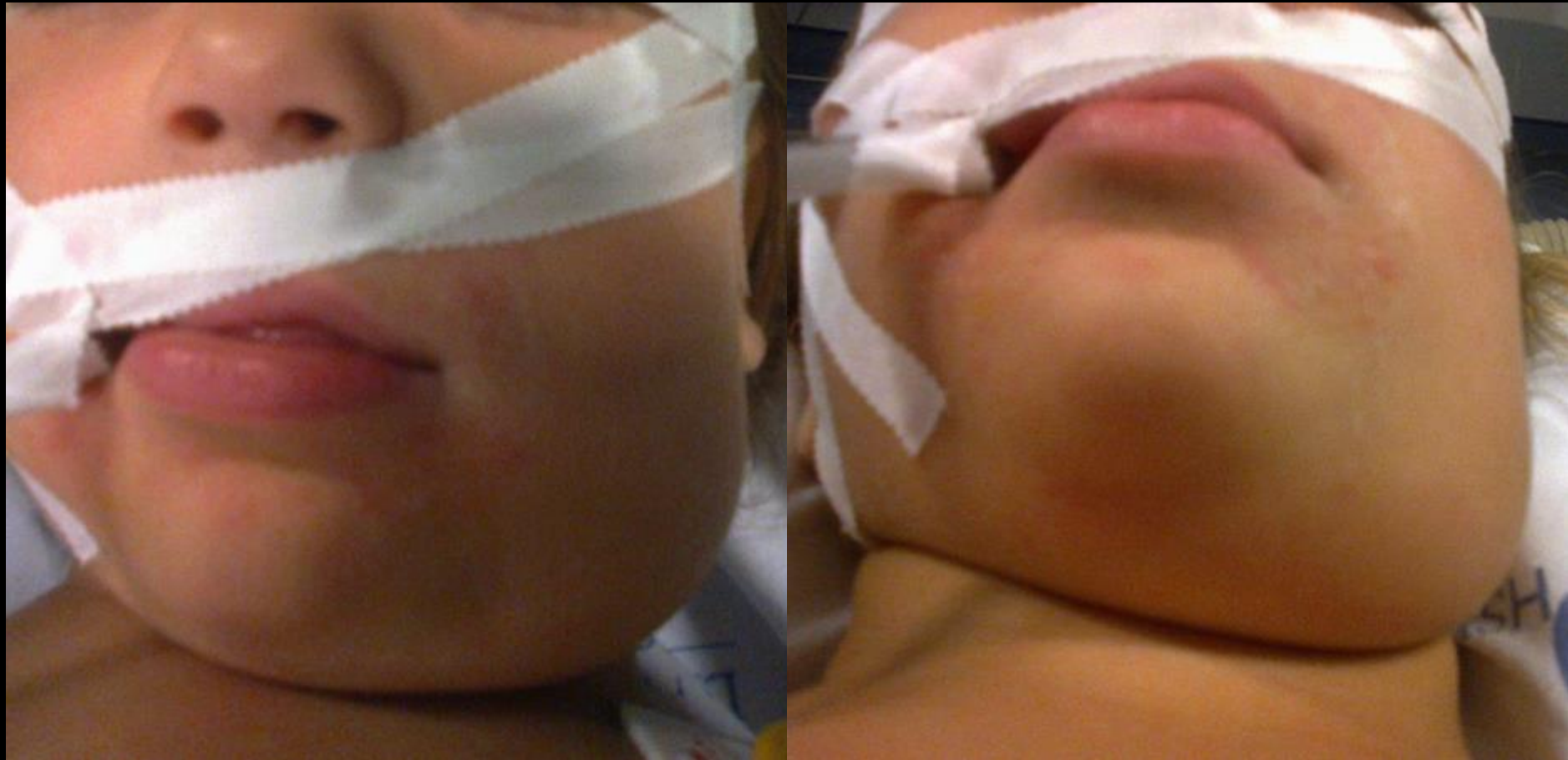

**Percutaneous sclerotherapy of head and neck low-flow vascular malformations**

**2 yo, ♀**

**Lymphatic malformation**

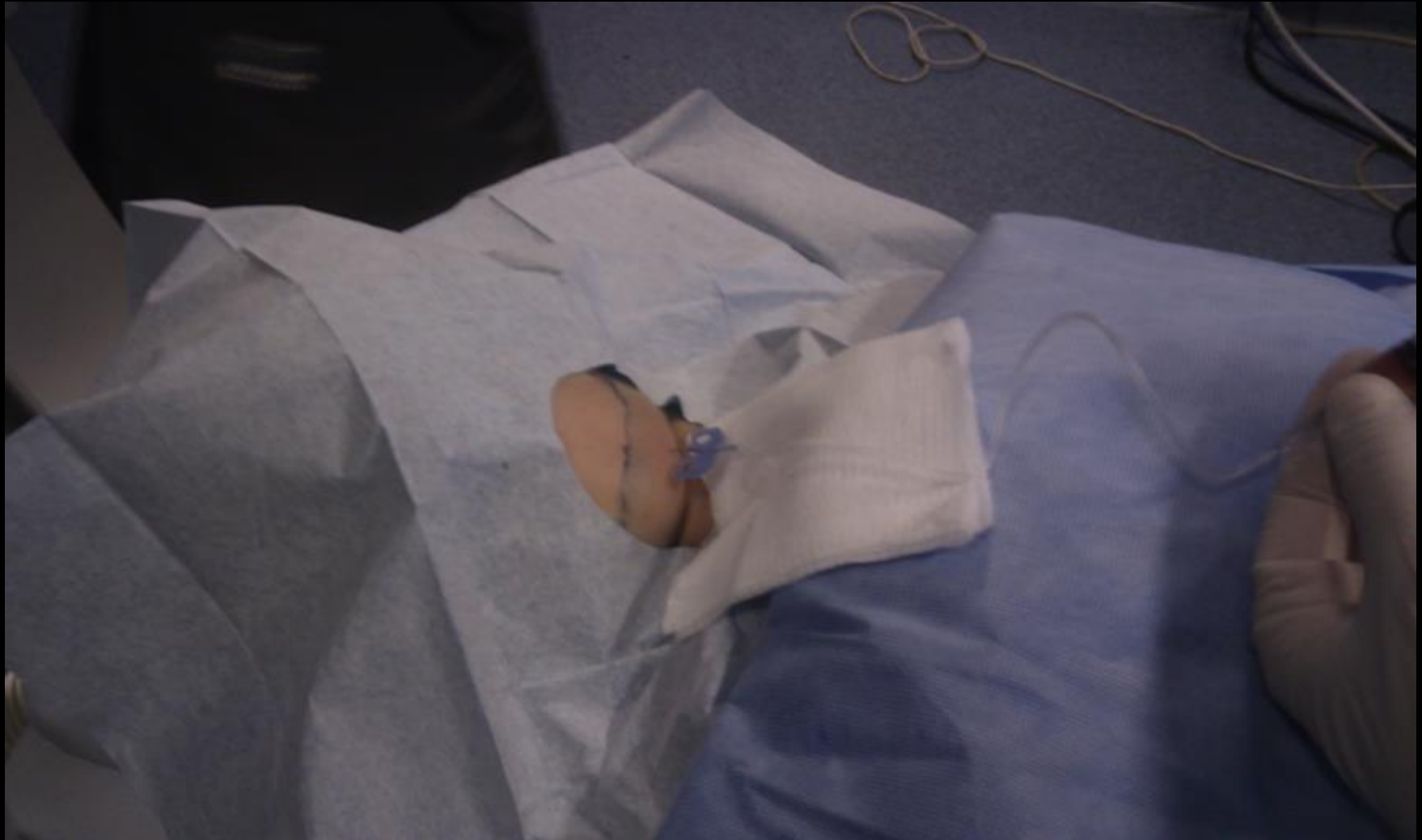**Submandibular**



# Percutaneous sclerotherapy of head and neck low-flow vascular malformations

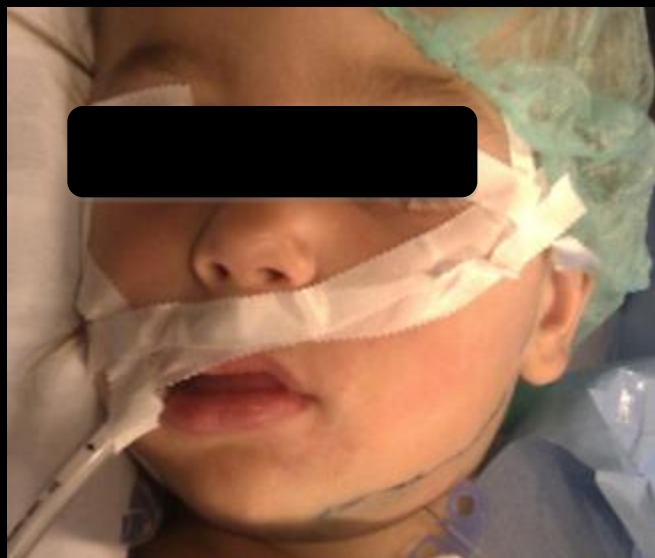**1 session**

**12000U bleomycin**

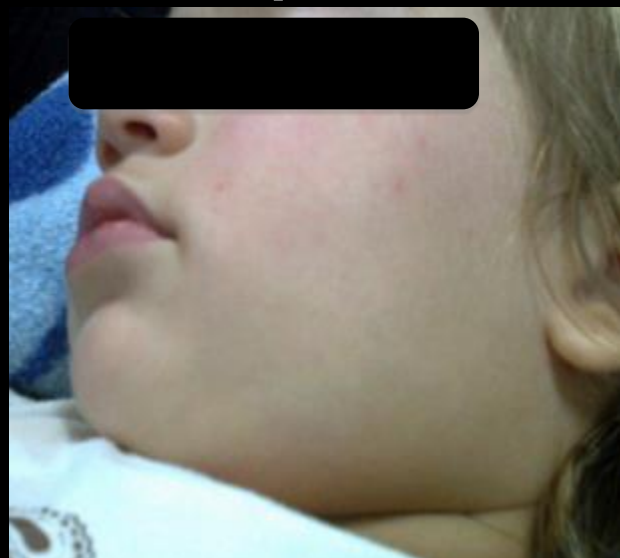

# Percutaneous sclerotherapy of head and neck low-flow vascular malformations

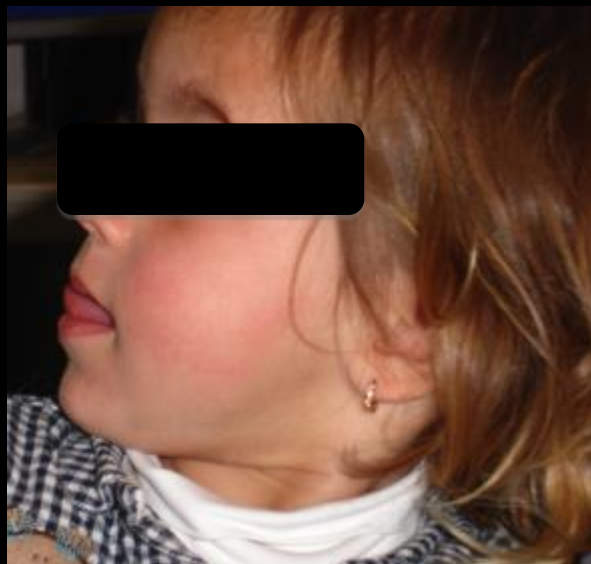**Aug / 2011**



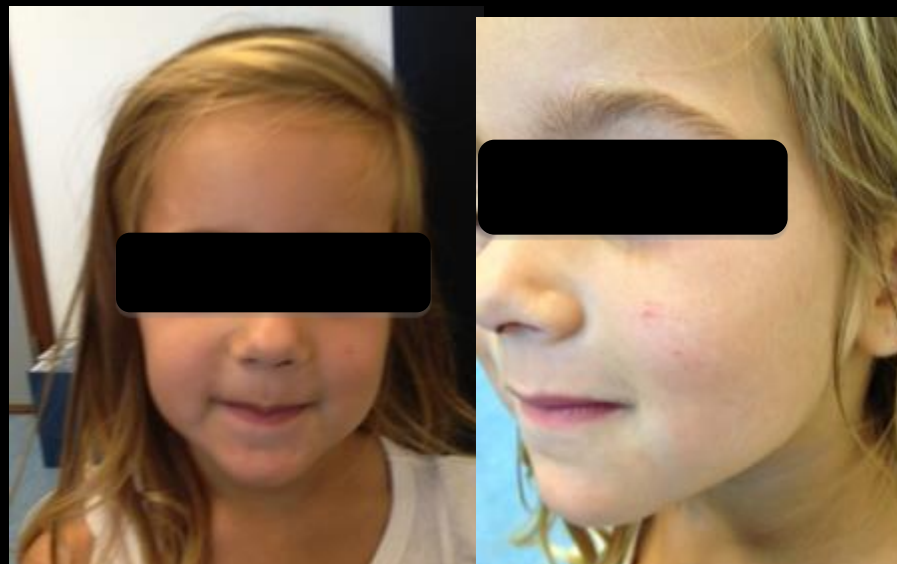**Apr / 2012**



**Dec / 2012**



**Feb / 2013**



## Percutaneous sclerotherapy of head and neck low-flow vascular malformations

27 yo, ♀

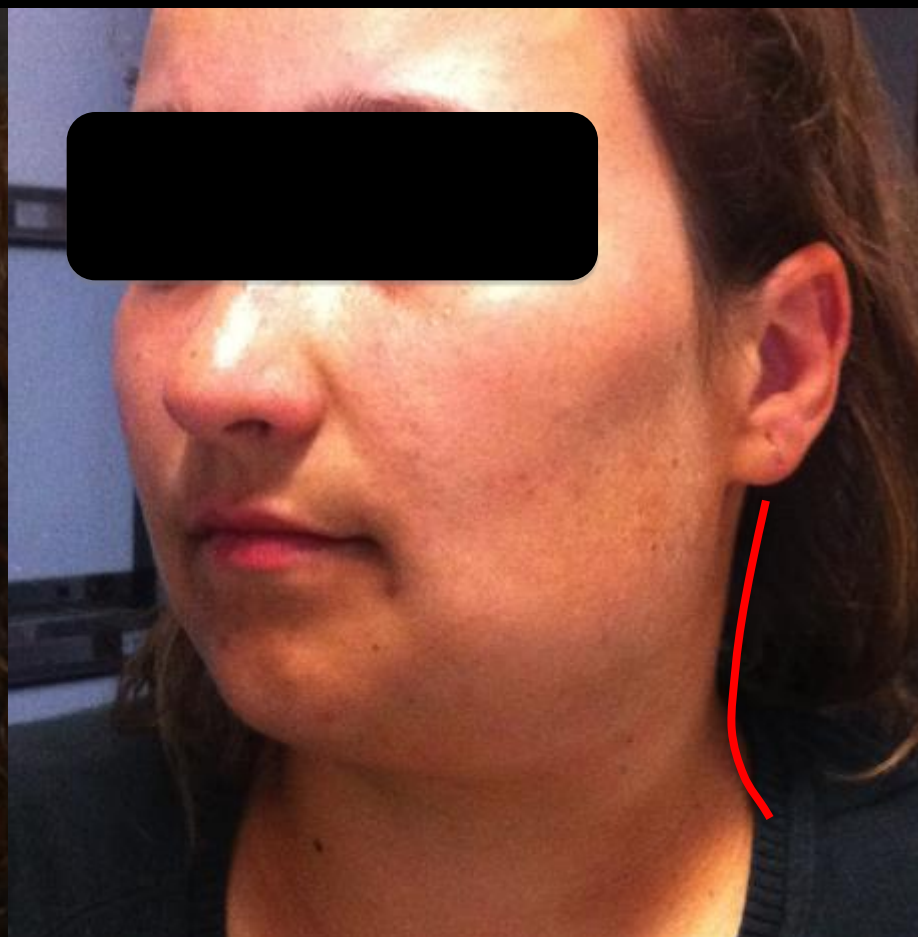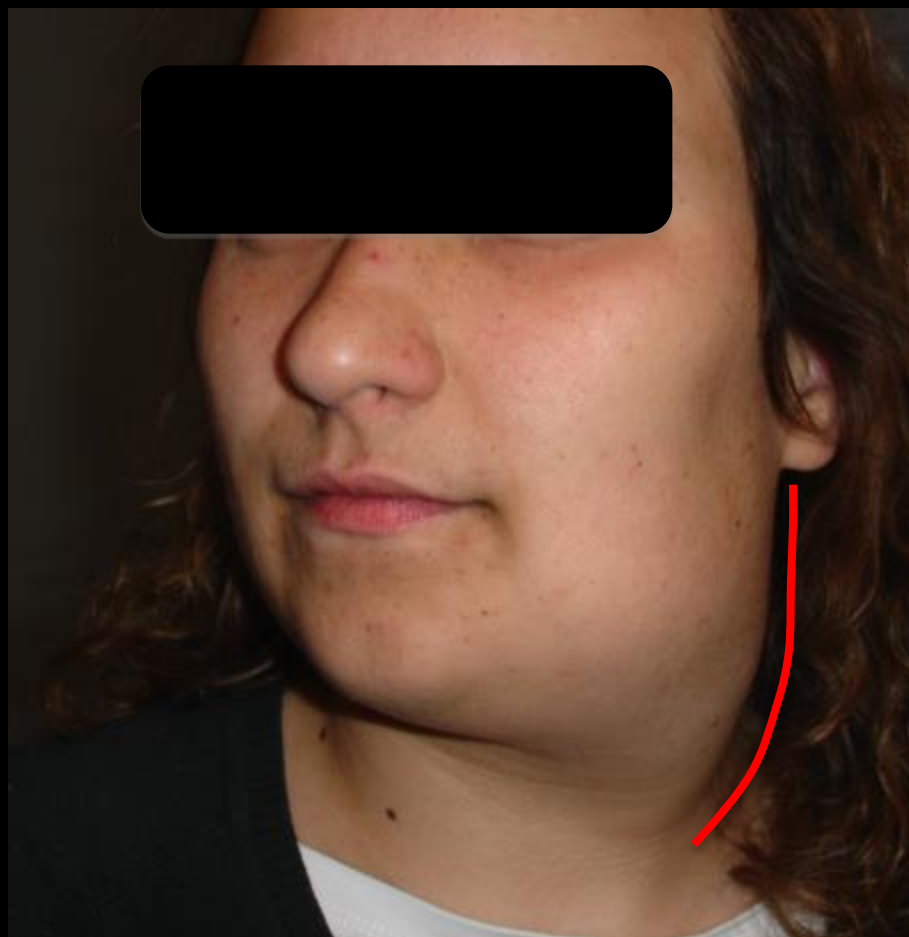Venous malformation

Face/neck

4 sessions

24000U bleomycin

15ml alcohol (99%)

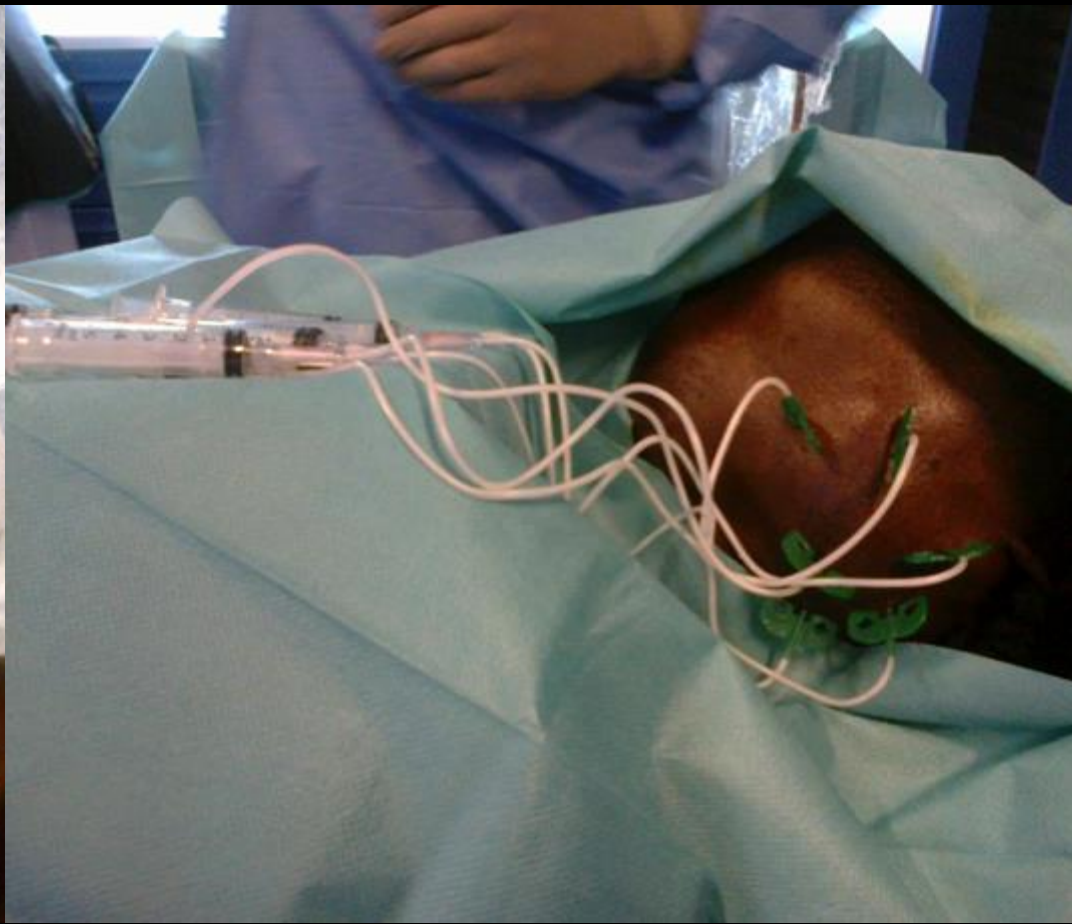
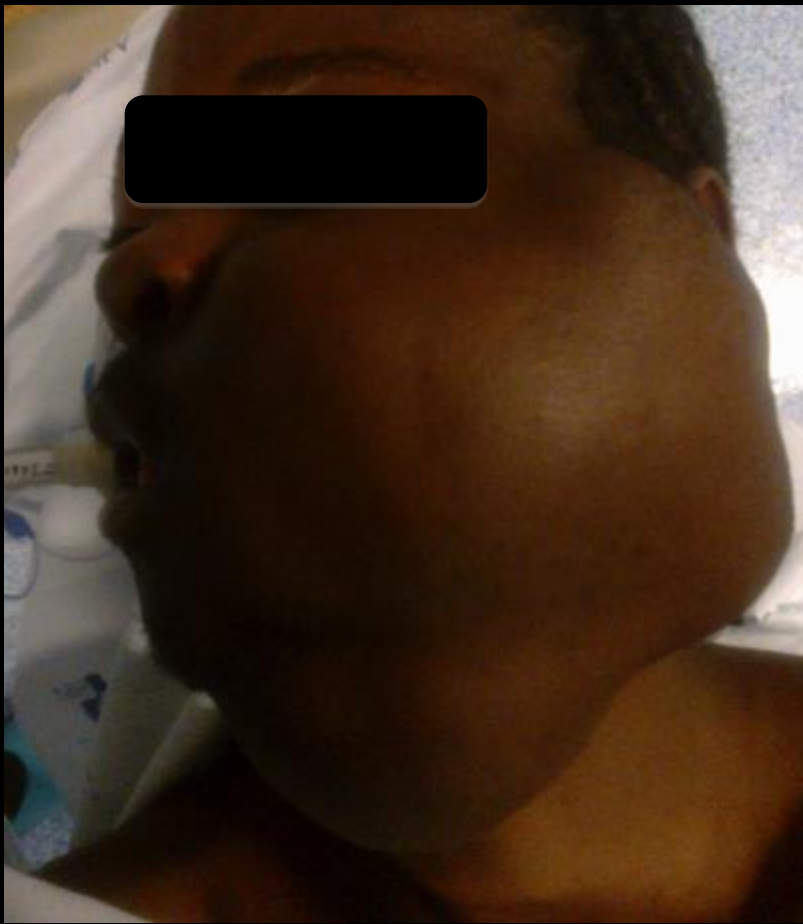


# Percutaneous sclerotherapy of head and neck low-flow vascular malformations

26 yo,  
Venous malformation  
Face/neck

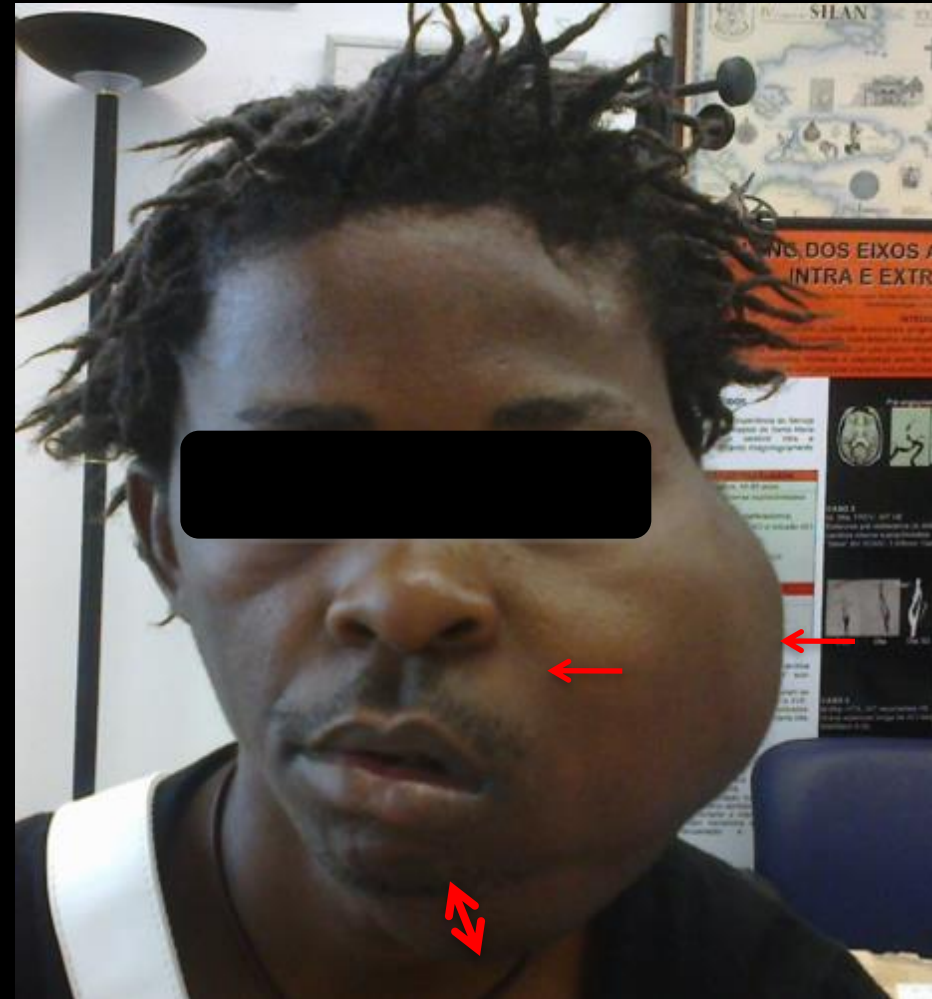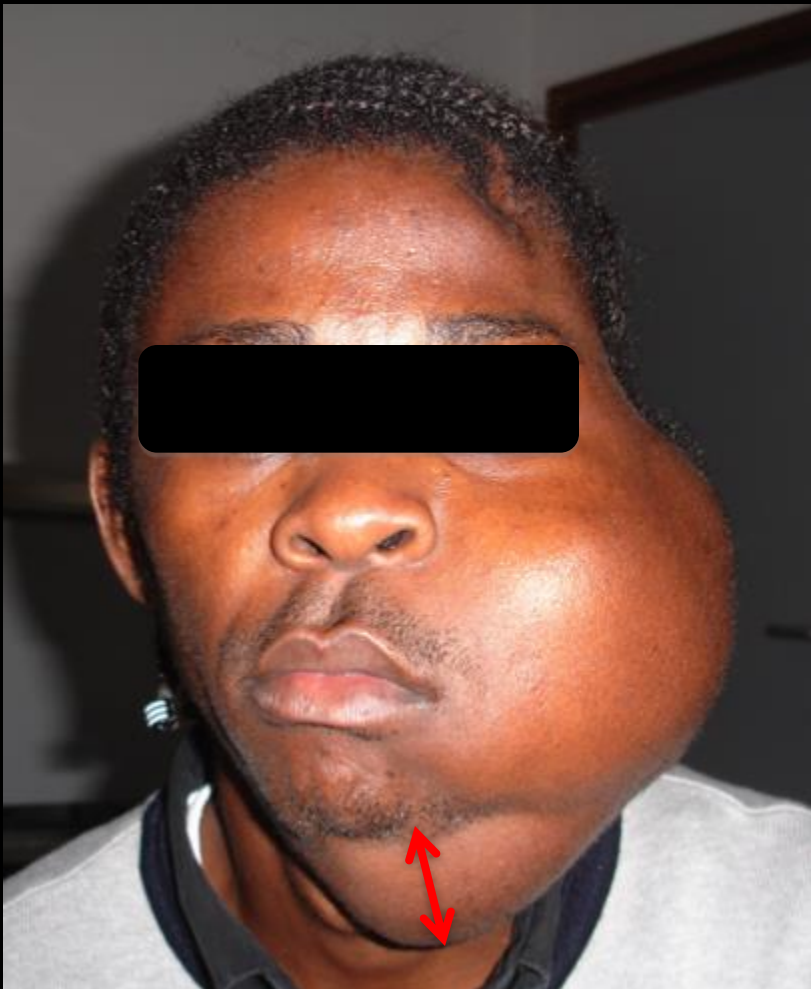
14 sessions  
Sclerogel® and alcohol (99%)



# Percutaneous sclerotherapy of head and neck low-flow vascular malformations

26 yo,  
Venous malformation  
Face/neck

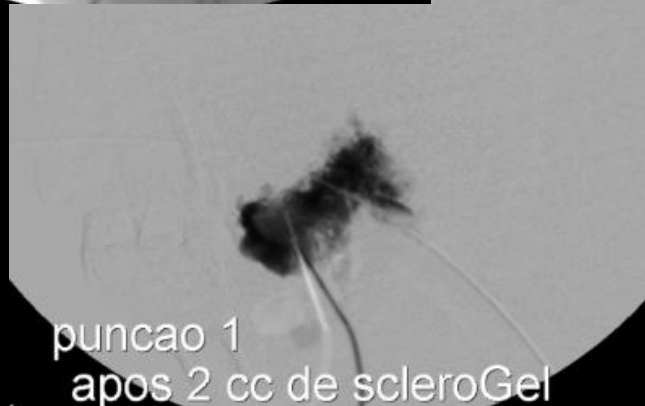
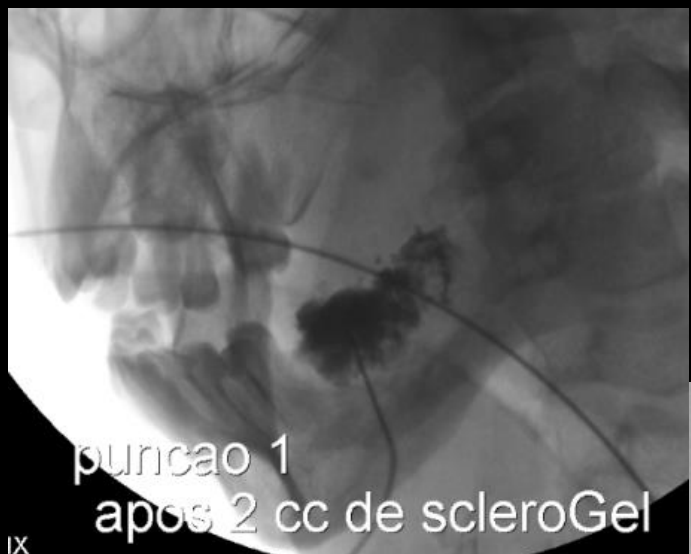5 sessions  
30ml alcohol (99%)



# Percutaneous sclerotherapy of head and neck low-flow vascular malformations

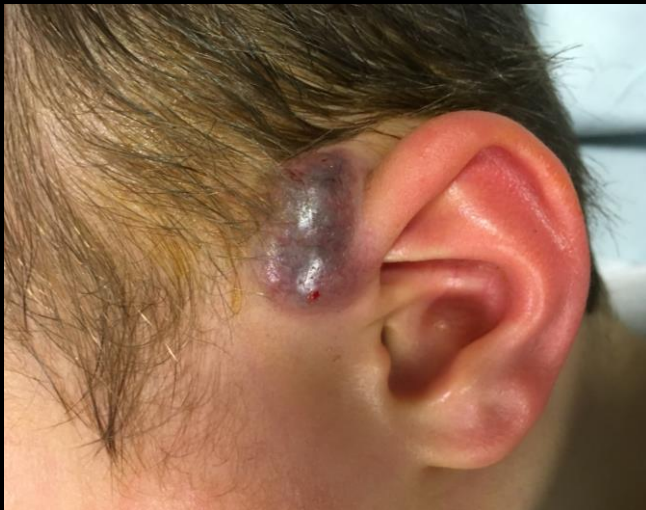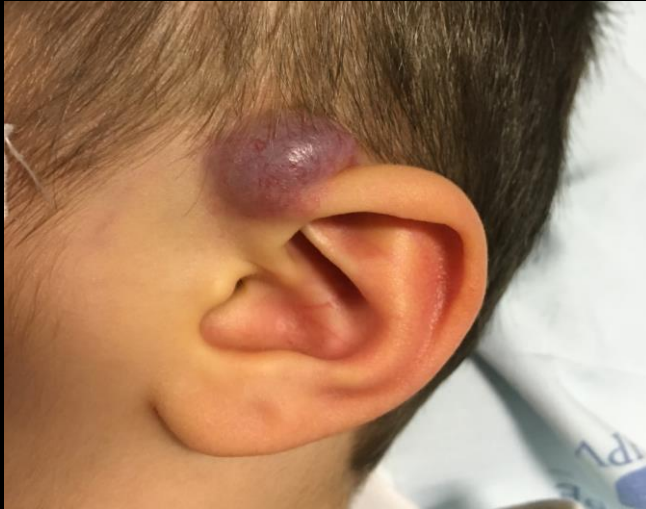26 yo,  
Venous malformation  
Face/neck

5 sessions  
30ml alcohol (99%)

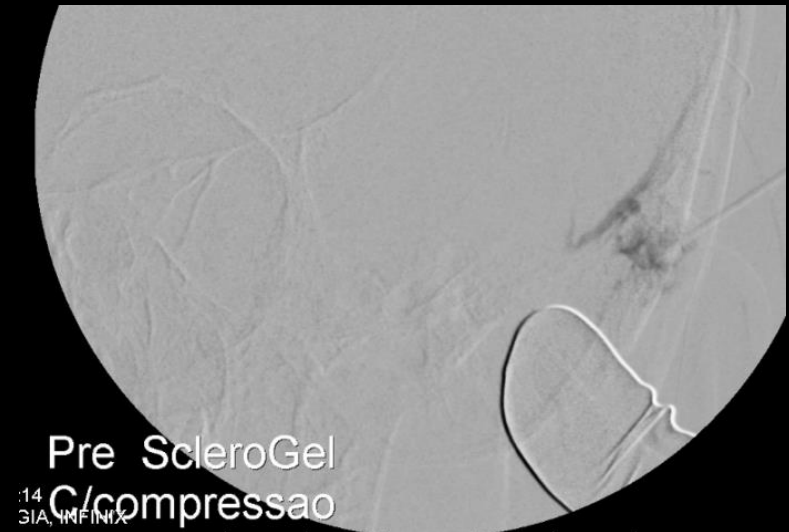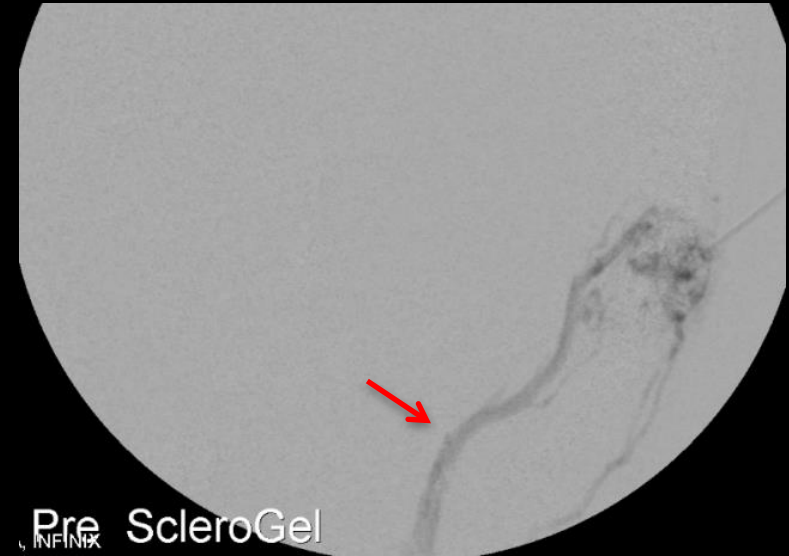


# Percutaneous sclerotherapy of head and neck low-flow vascular malformations

2 yo,  
Capillary malformation  
Pre-auricular



2 sessions  
Alcohol (99%) and Sclerogel®



## **Results**

- **All the patients benefited from treatment**
- **Excellent result - 6 patients (50%)**
- **Good result - 2 patient (1 still under treatment)**
- **Fair result - 4 patient (all still under treatment)**
  
- **Transient facial palsy (2)**
- **Small cheek scar (1)**
- **No systemic complications**
- **No surgery after treatment**

## **Conclusions**

**With thorough planning and careful patient selection, sclerotherapy is a simple, safe and cost effective treatment for the Low Flow Vascular Malformations**

