



medicina mínimamente invasiva, liderando el camino

minimally invasive medicine, leading the way

XXV SEMANA DEL INTERVENCIONISMO MÍNIMAMENTE INVASIVO
BUENOS AIRES ARGENTINA · 4/6 JULIO 2016 HOTEL HILTON

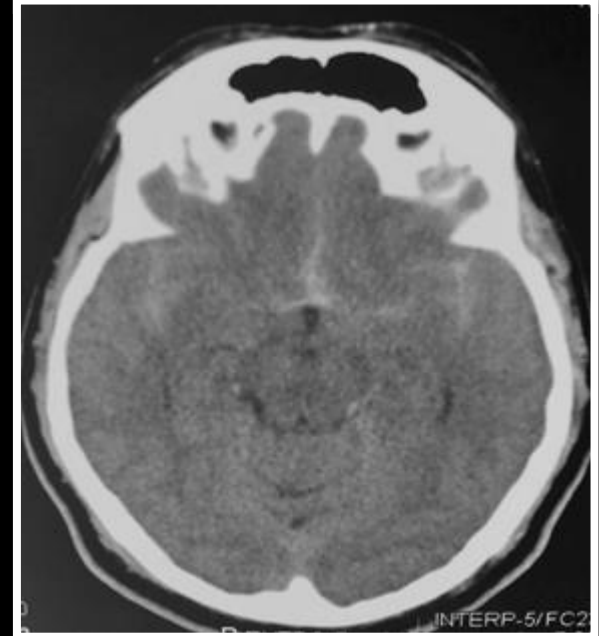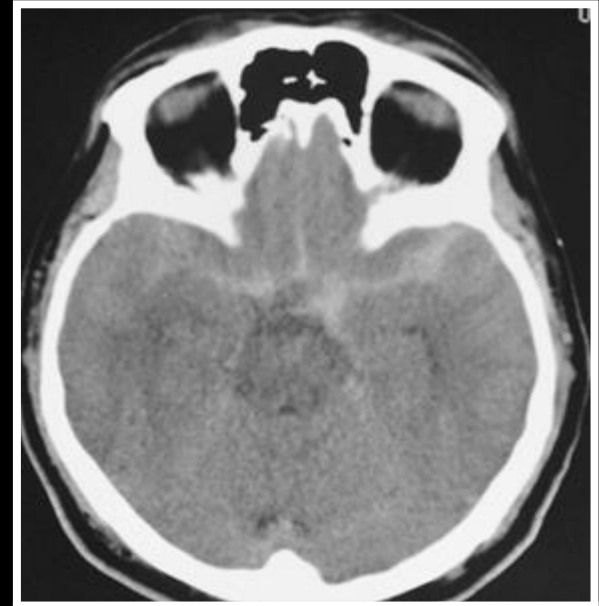
STROKE HEMORRAGICO

Discusión de casos...

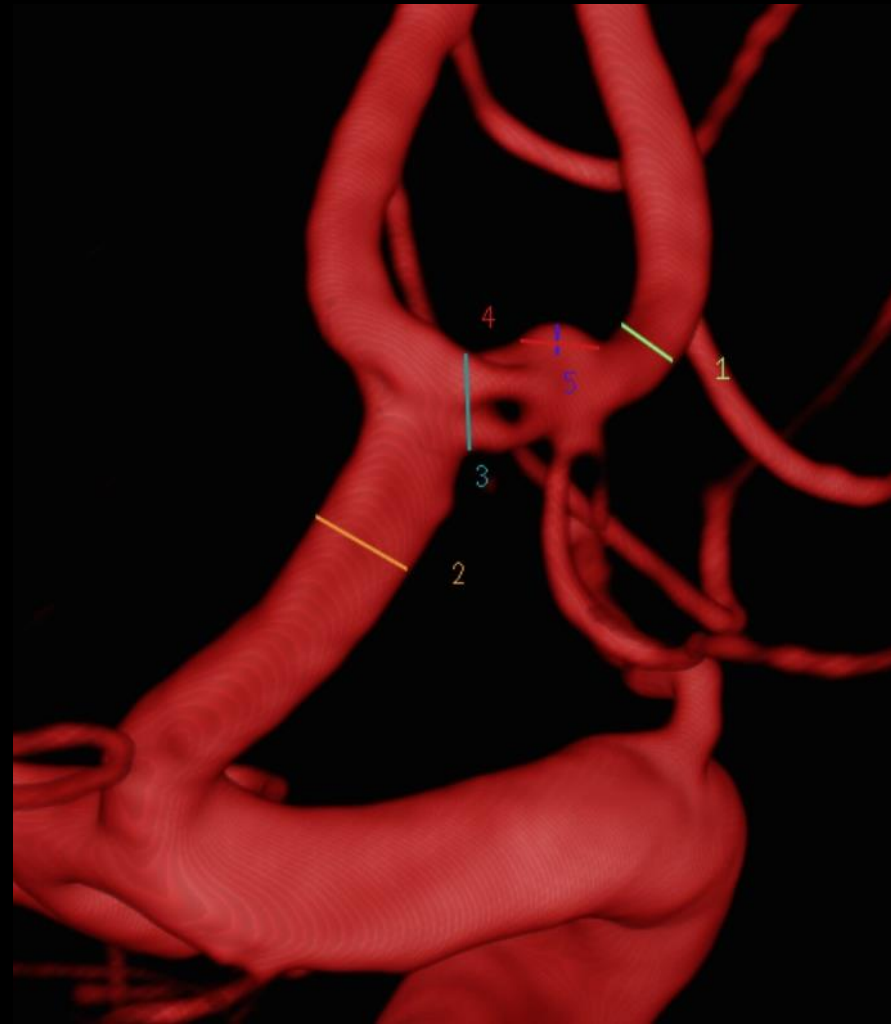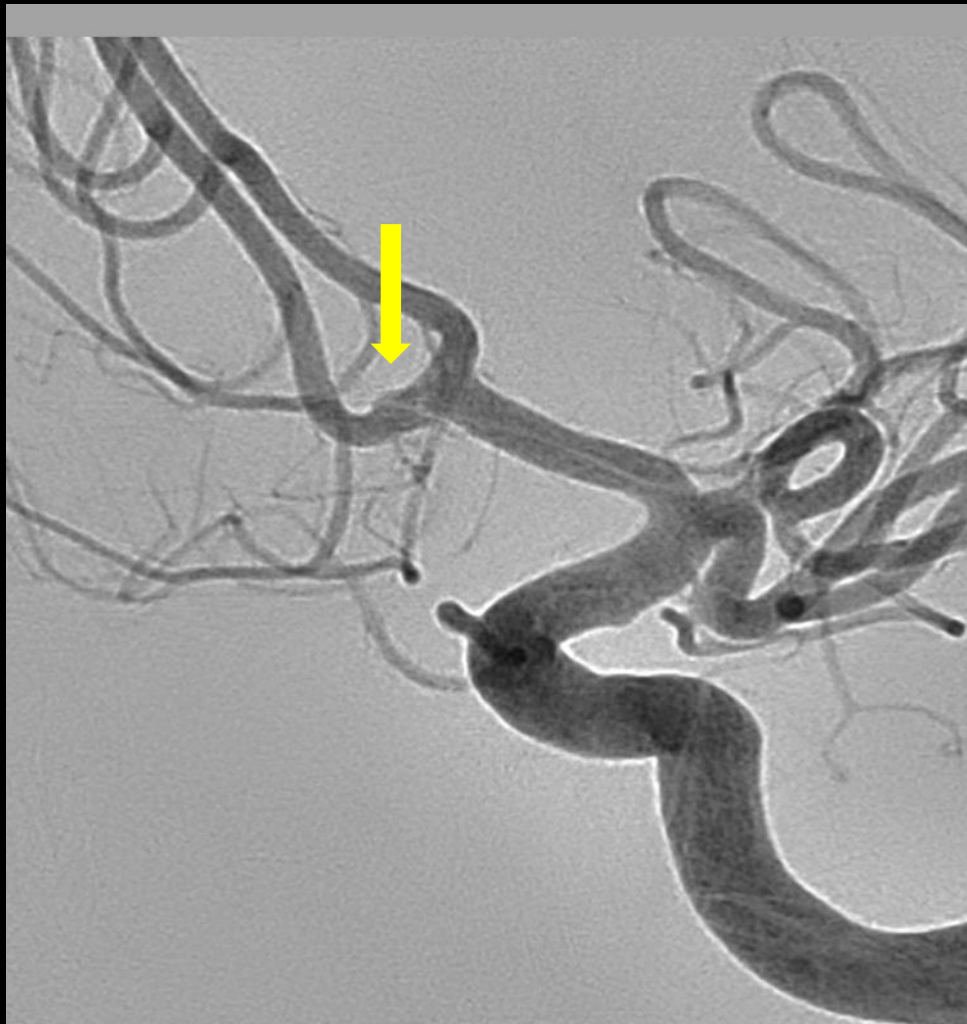MH, Masculino, 54 y.o.
Tabaquista.
HSA Fisher III Hunt Hess II (mayo-9-2016)

ASD: Aneurisma BL AcommA pequeño
Fenestración del complejo AcommA

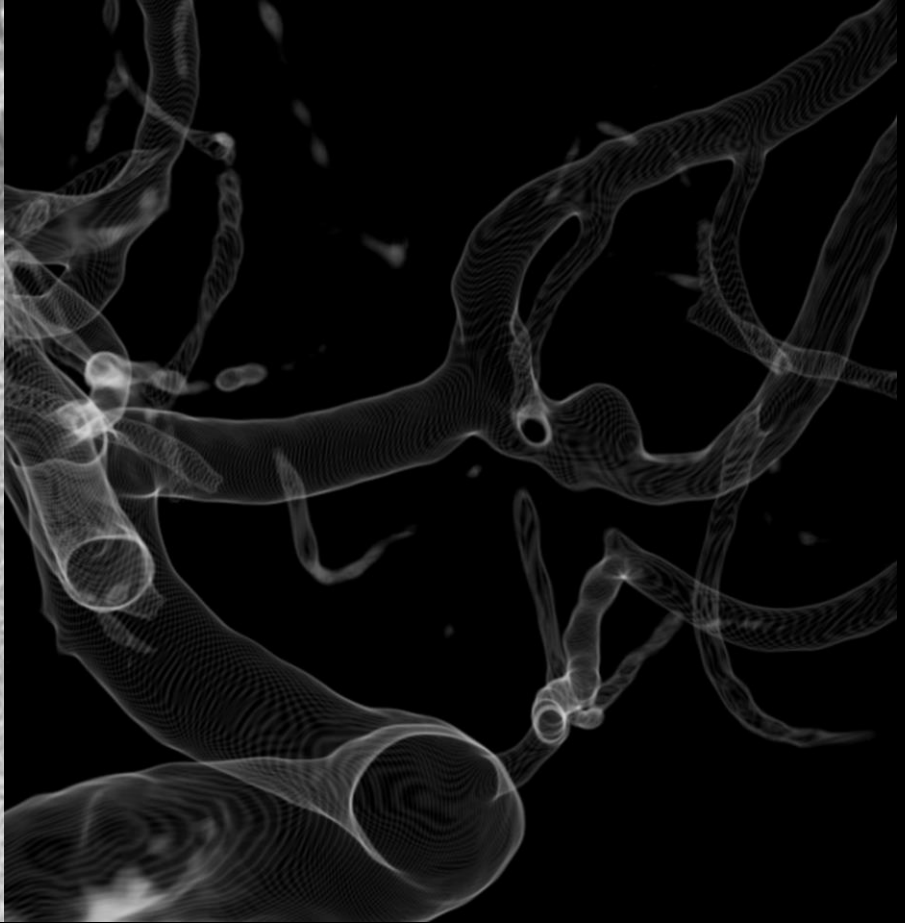
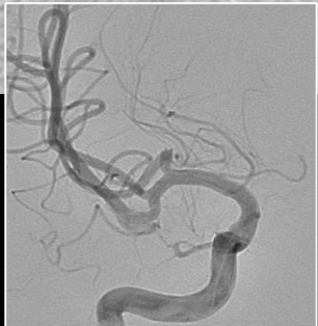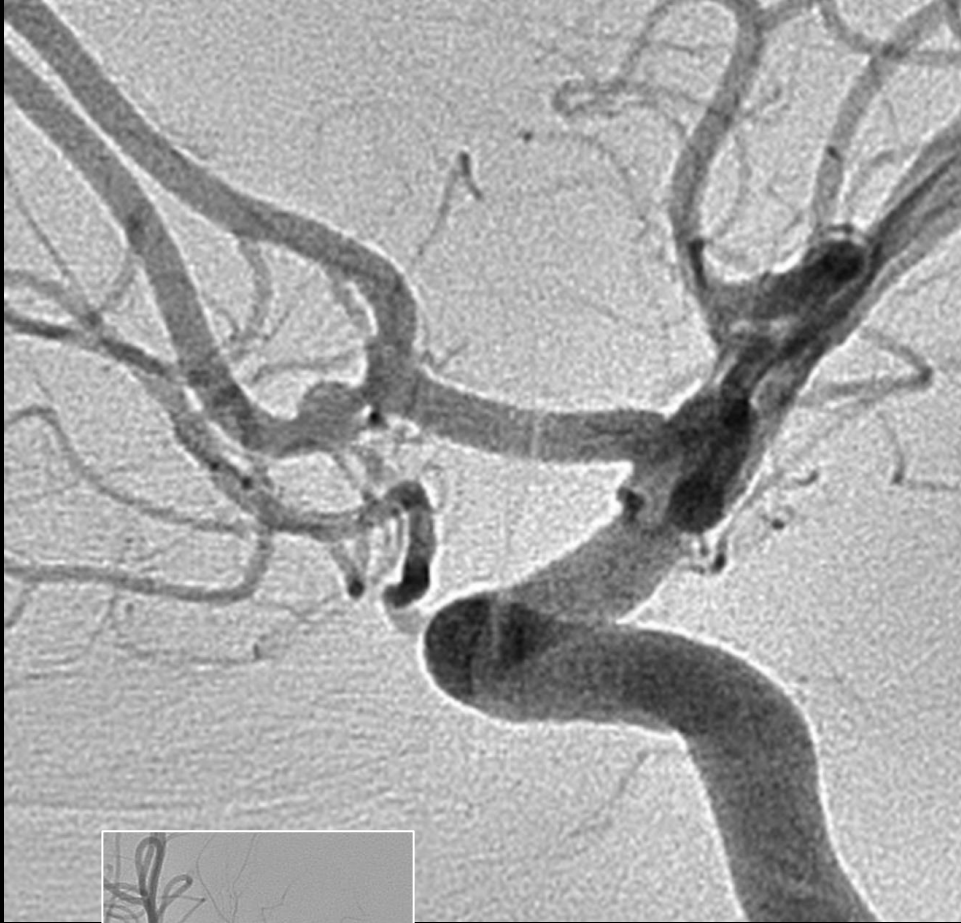Estrategia: ???



PRE TRATAMIENTO



15 DIAS DE EVOLUCION





A.Clipado quirúrgico

B.Balón & coils

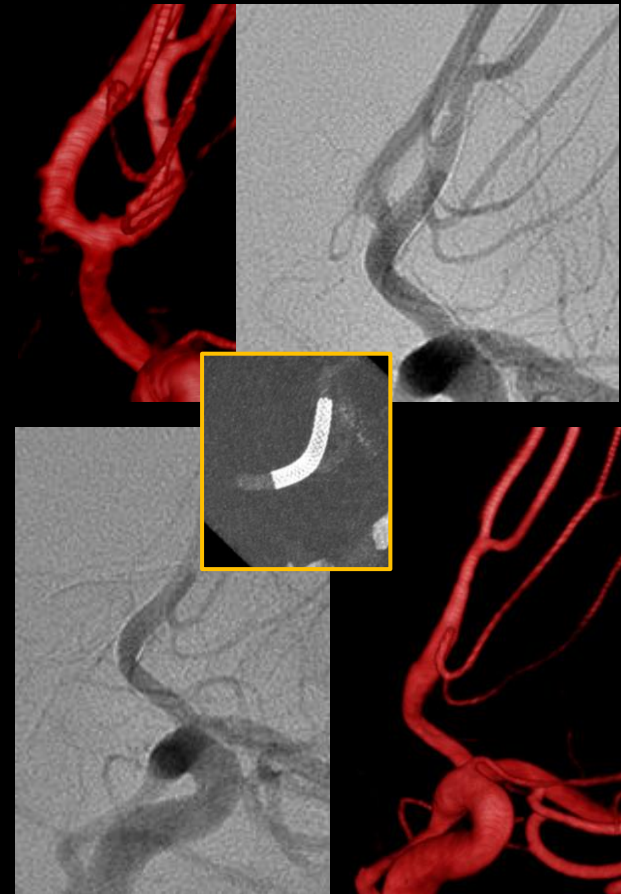C.Stent & coils

D.Diversor de flujo

E.Control

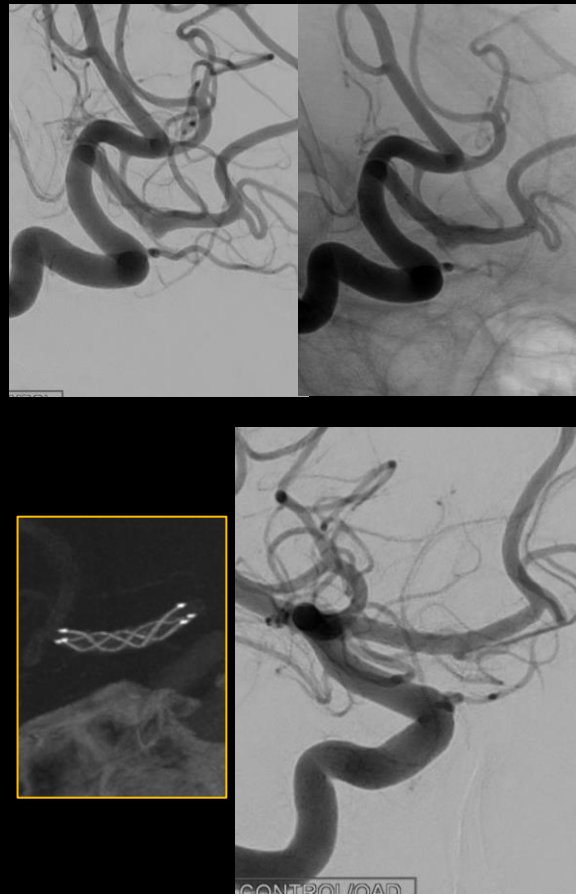
CASOS SIMILARES

Treatment - PED



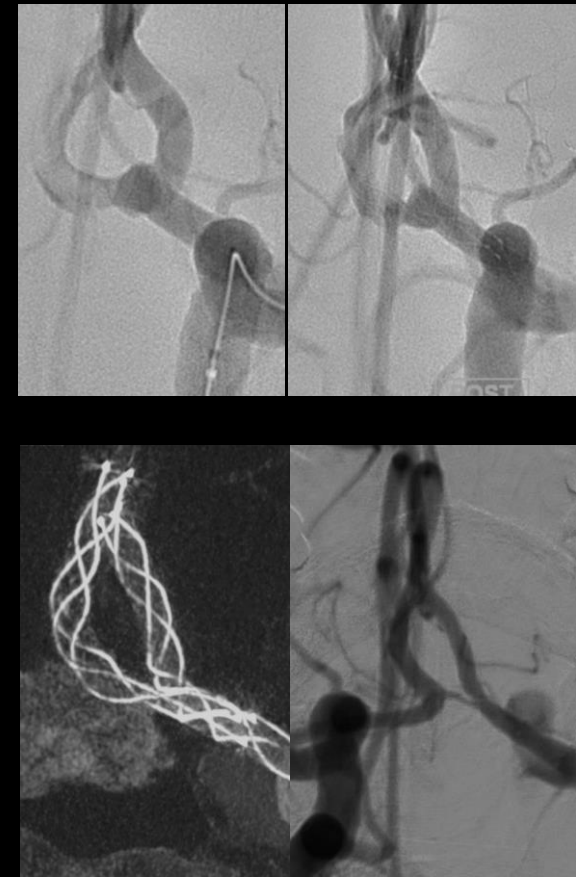
12 months FUP - PED

Treatment - Lvis JR



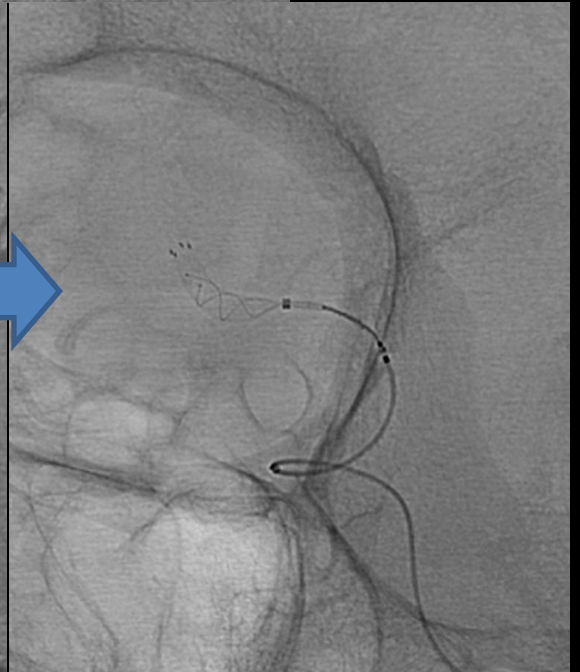
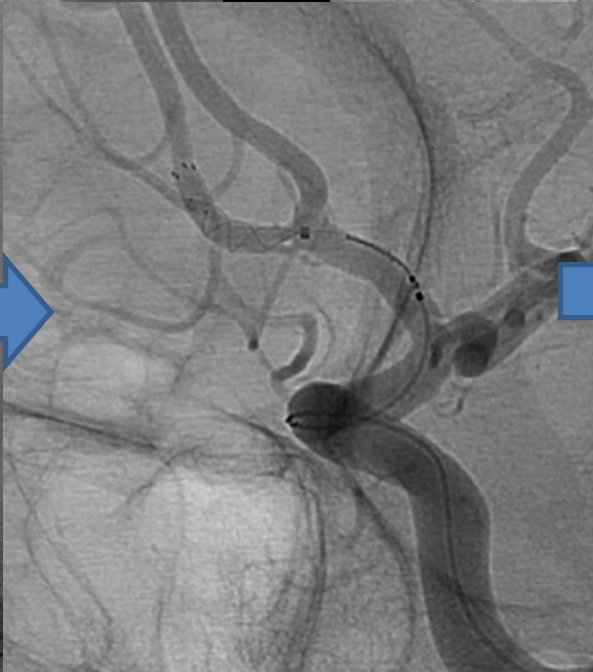
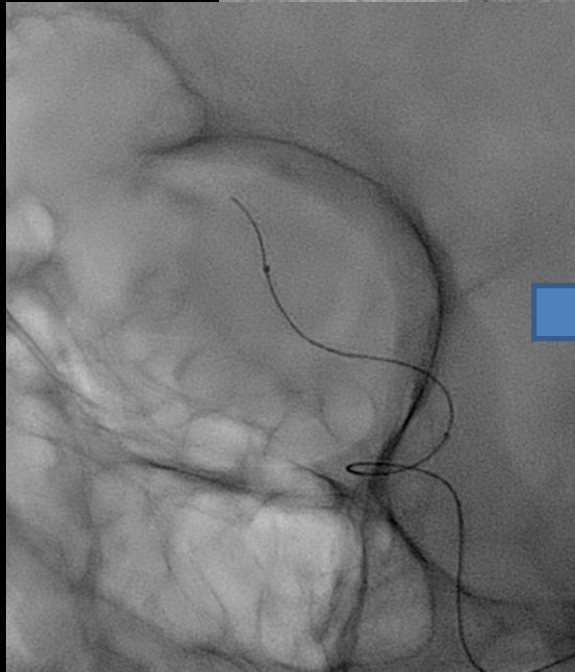
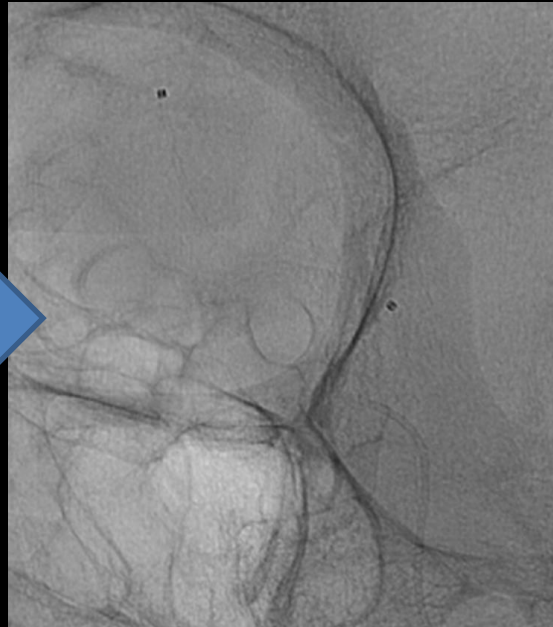

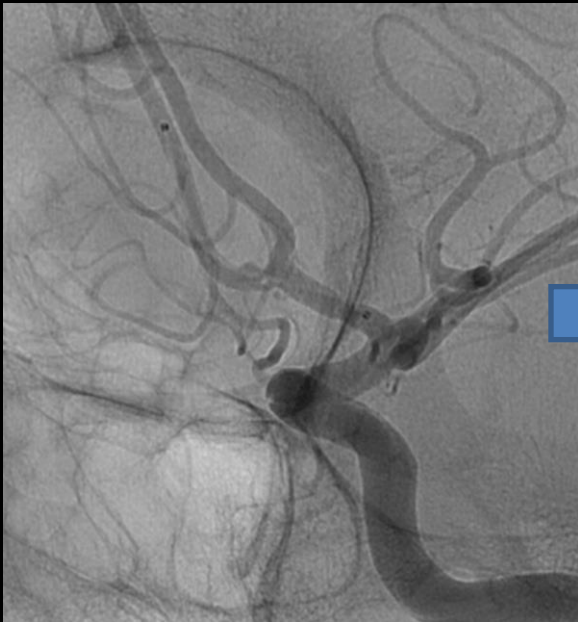
18 months FUP

Treatment - Y stent

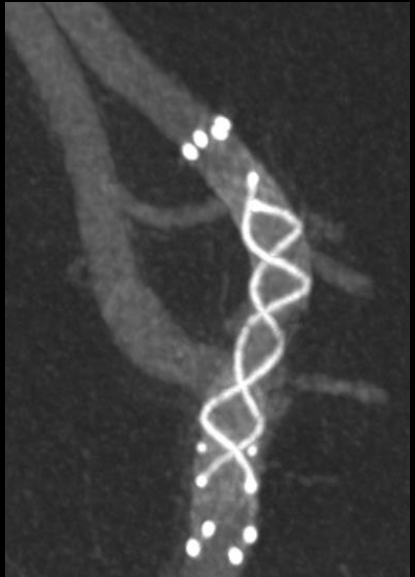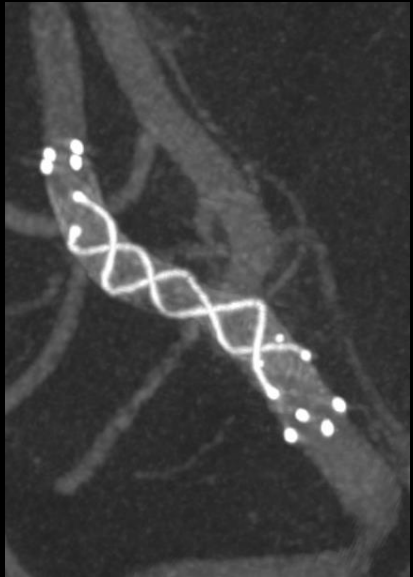

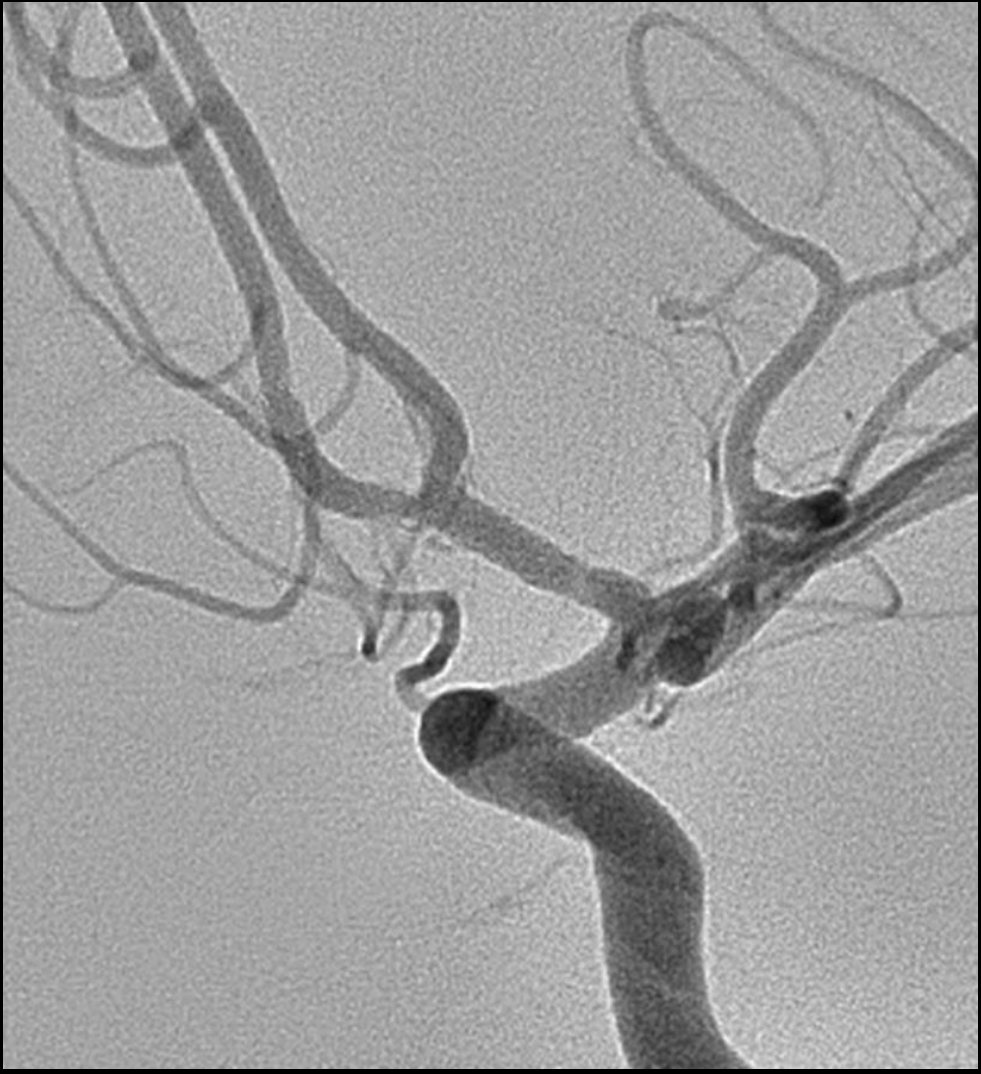
6 months FUP

Durante tratamiento...



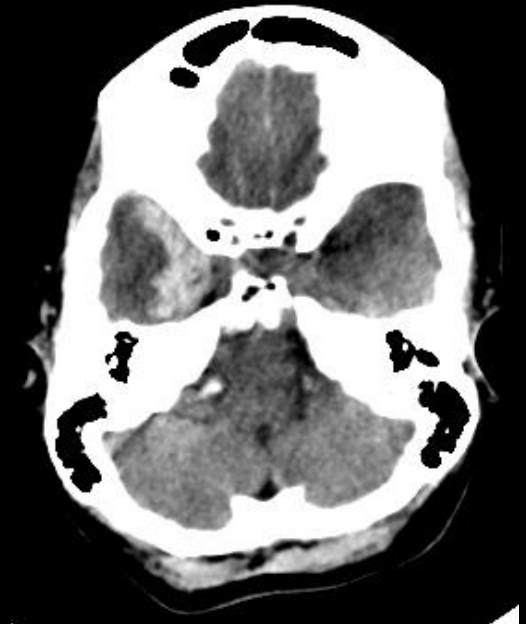
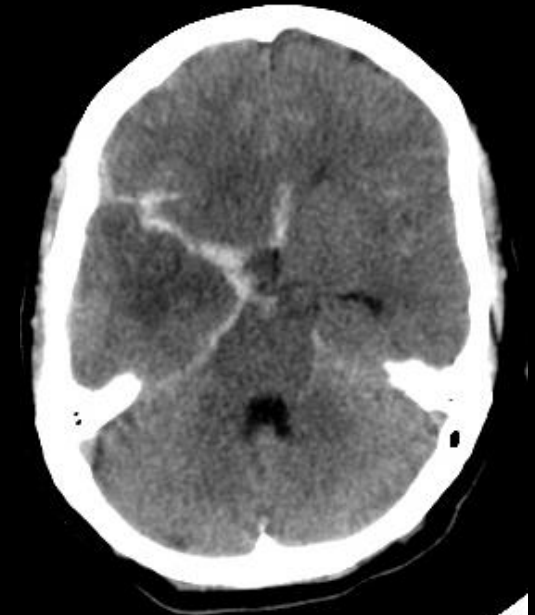POST TRATAMIENTO CON FD



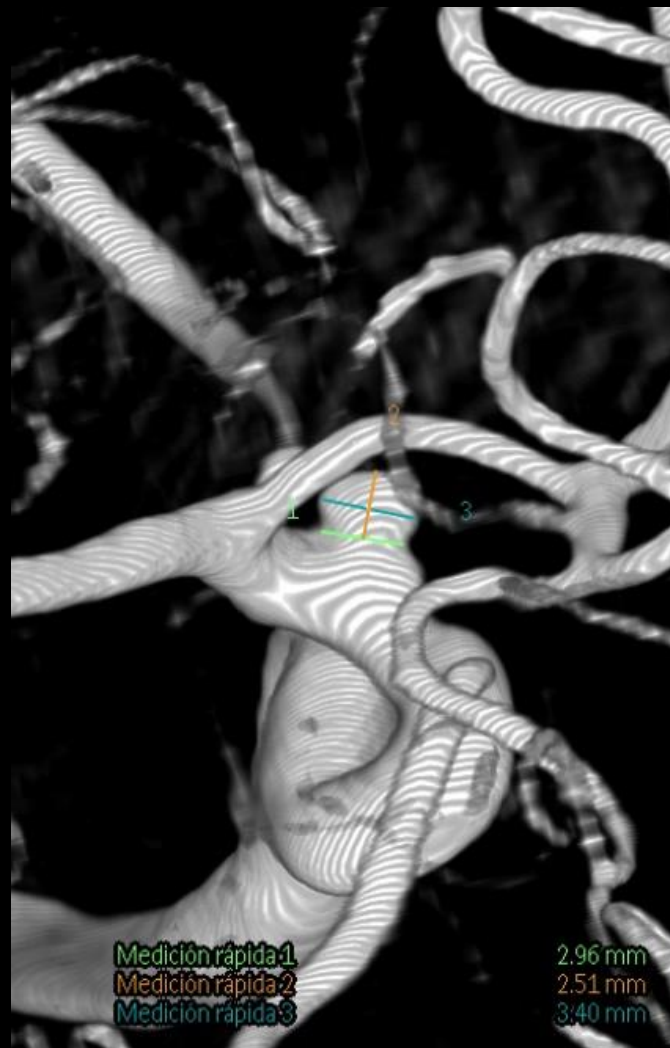
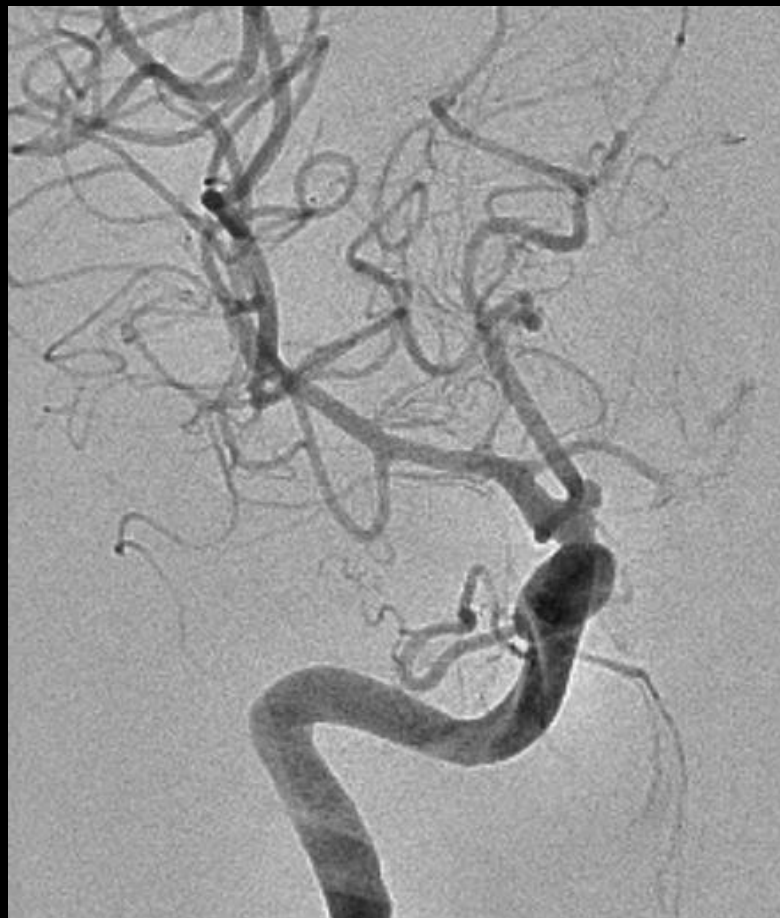Mujer, 55
HSA Fisher IV Hunt & Hess III 3

ASD: Aneurisma disecante supraclinoideo derecho

ESTRATEGIA: ???



PRE TRATAMIENTO





A. Balón & coils

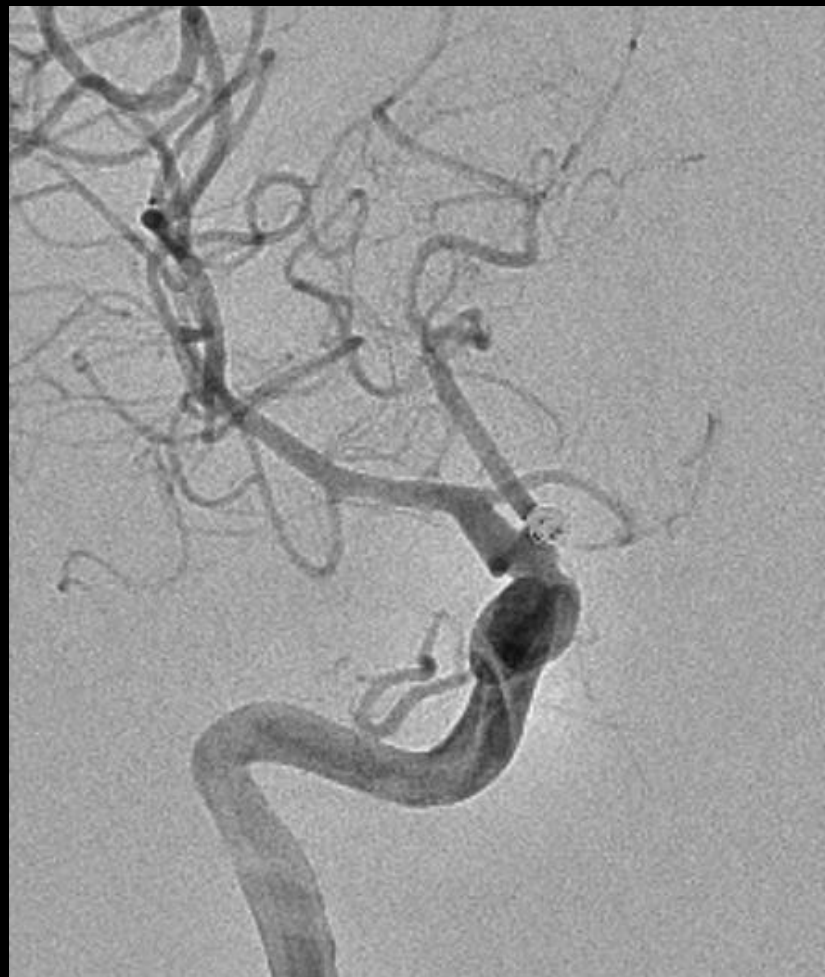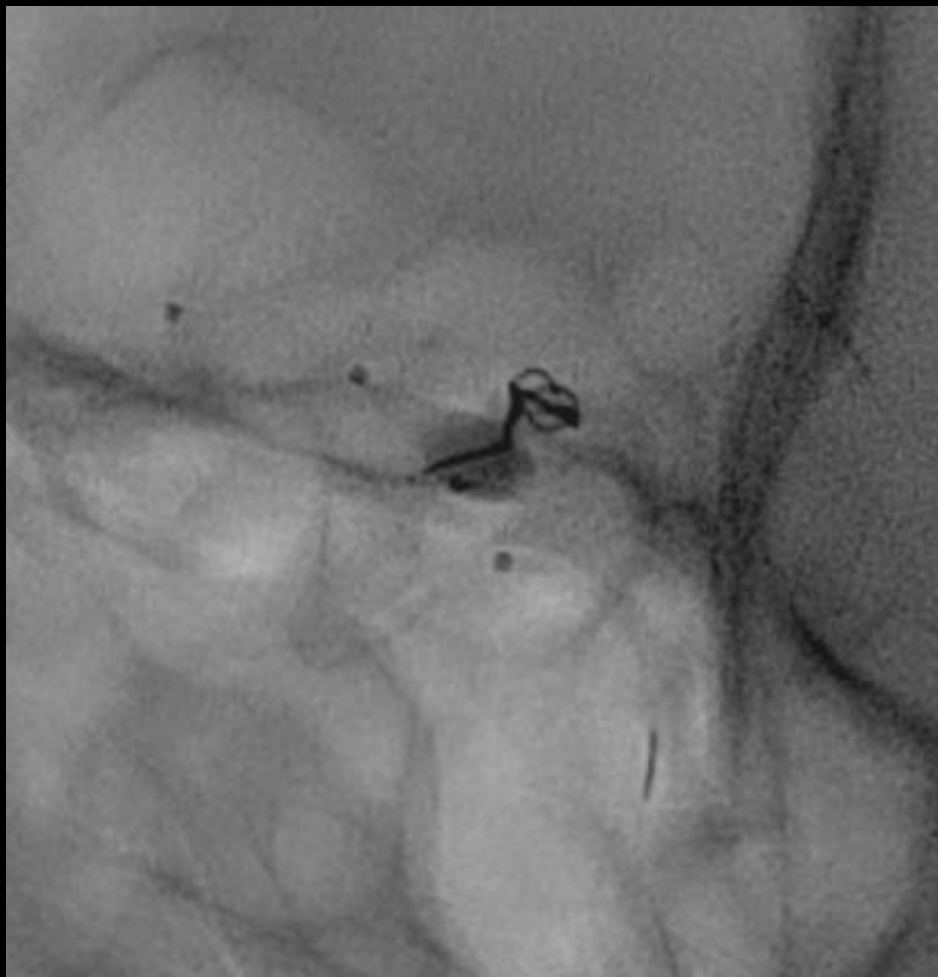
B. Stent & coils

C. Diversor de flujo

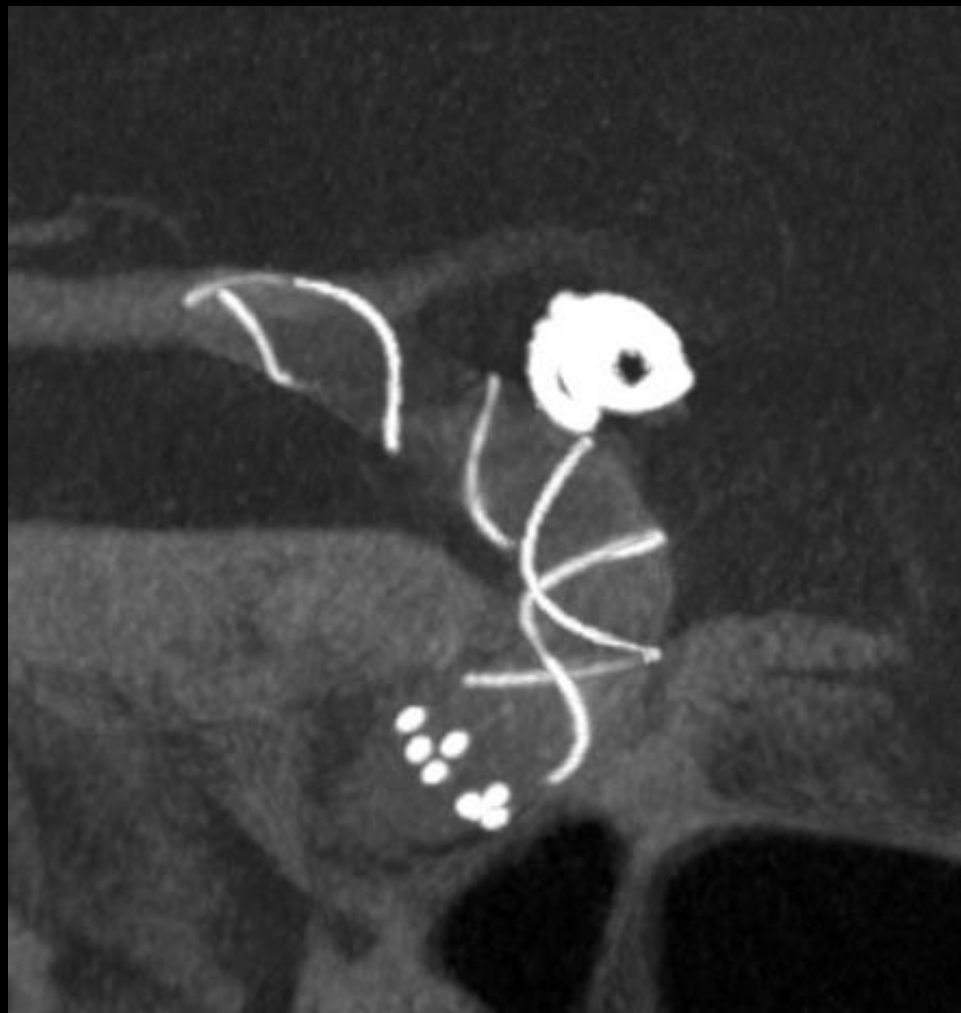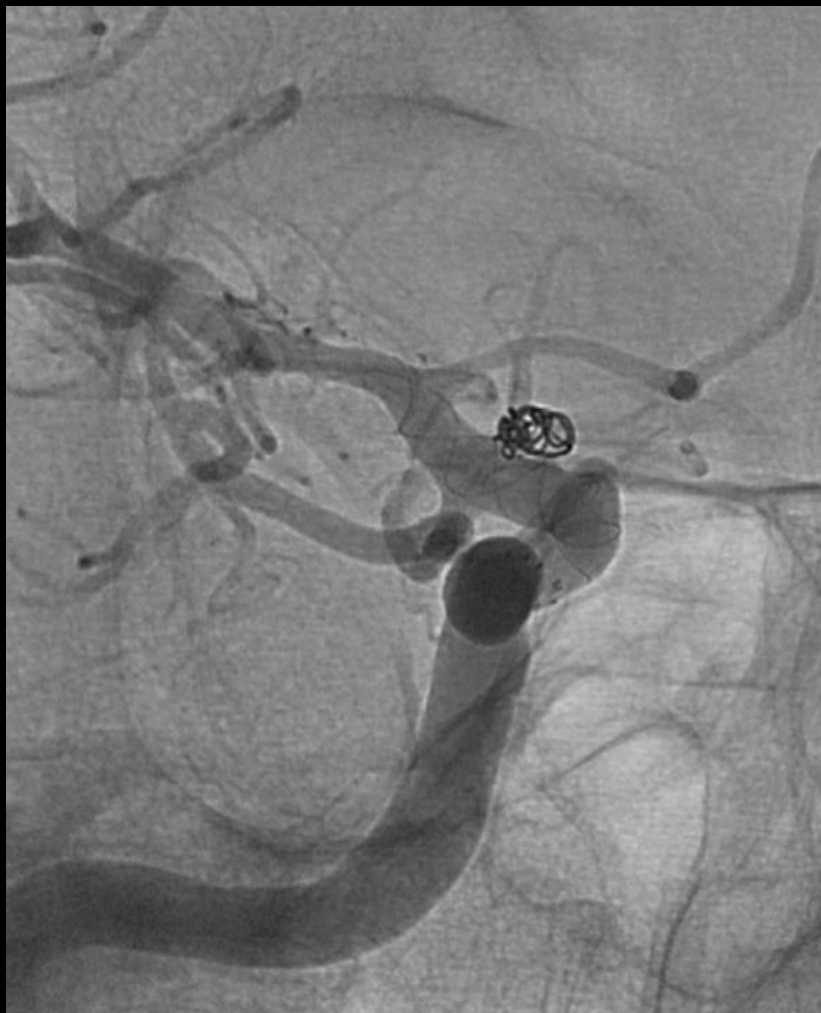**D. Diversor de flujo y
coils**

E. Clipado quirúrgico

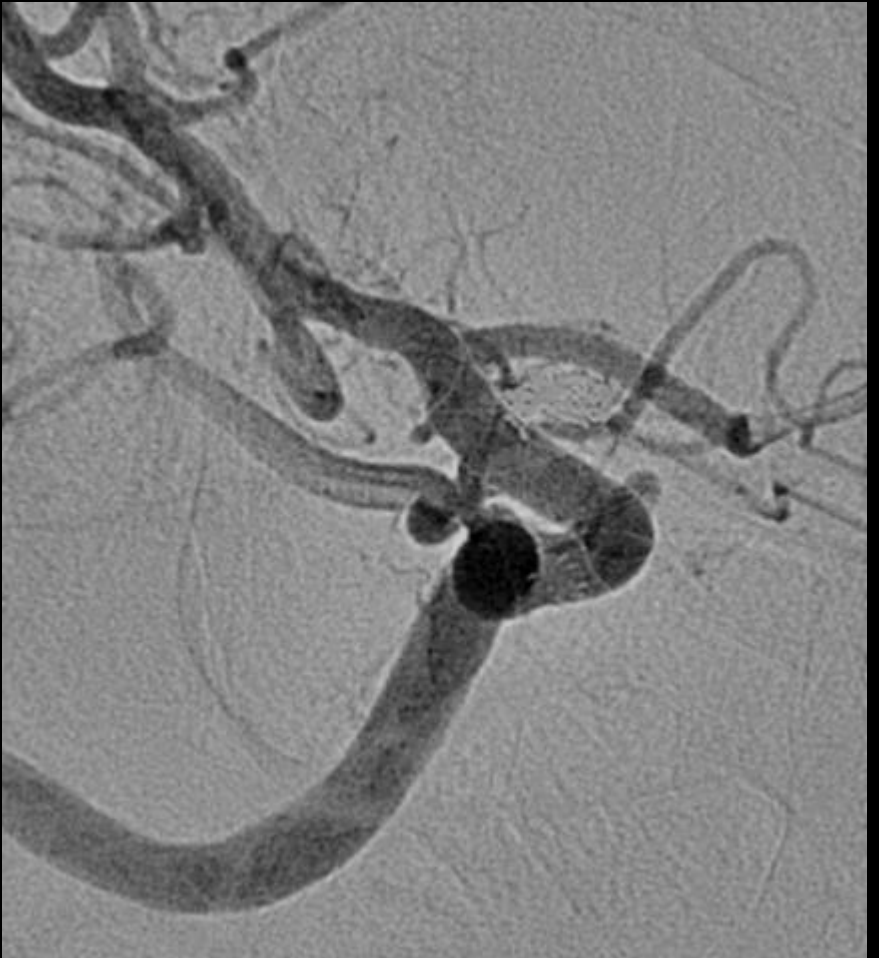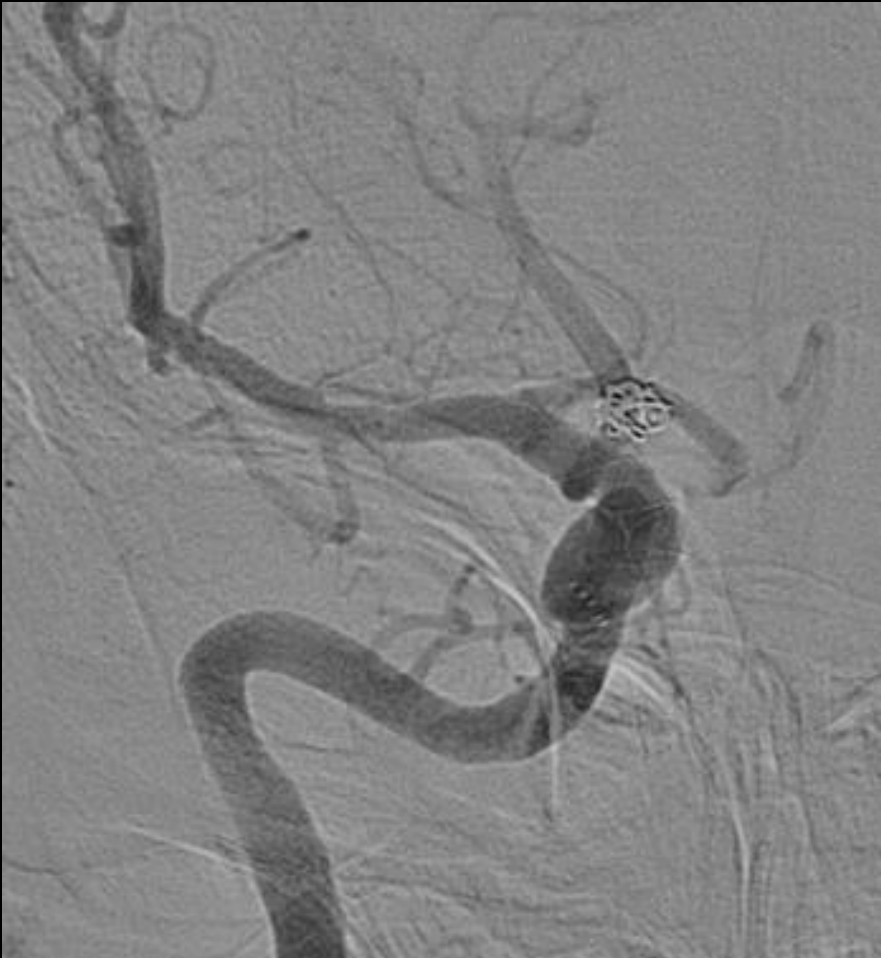DURANTE TRATAMIENTO EN EL PERIODO AGUDO



RETRATAMIENTO CON DIVERSOR DE FLUJO



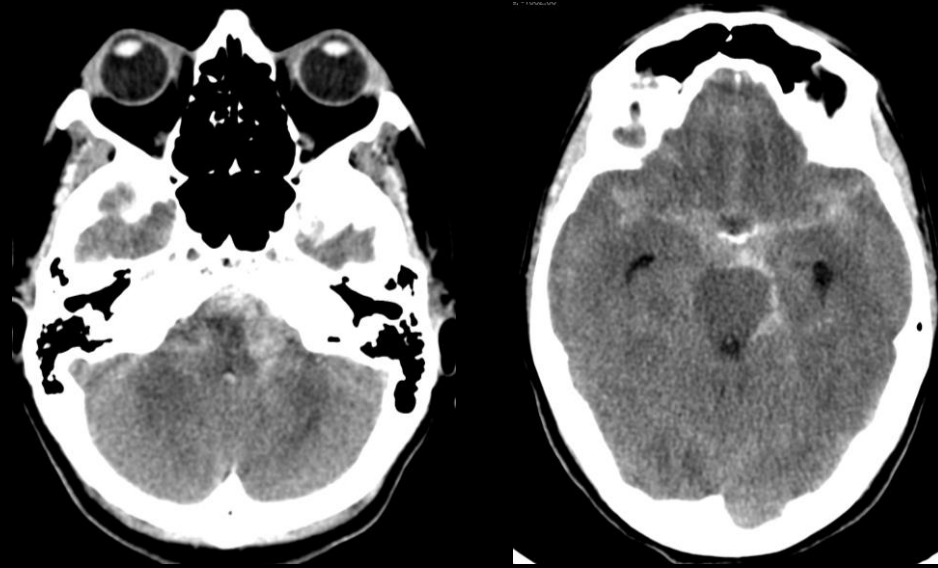
SEGUIMIENTO 1 MES / 1 AÑO



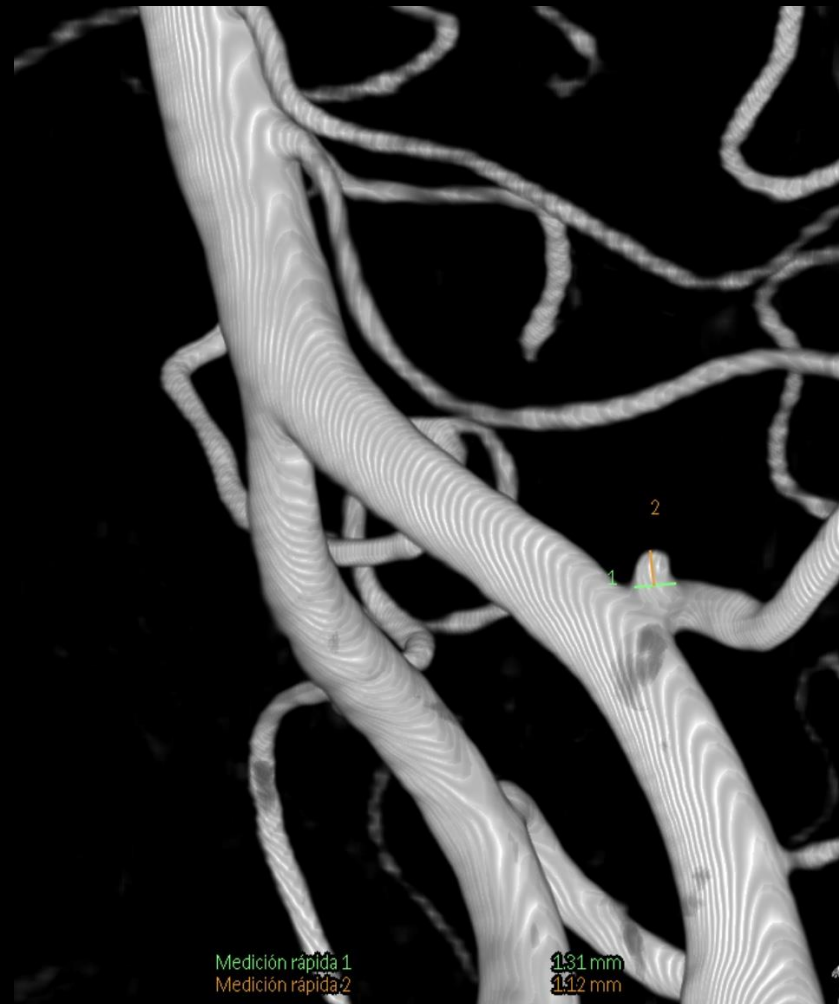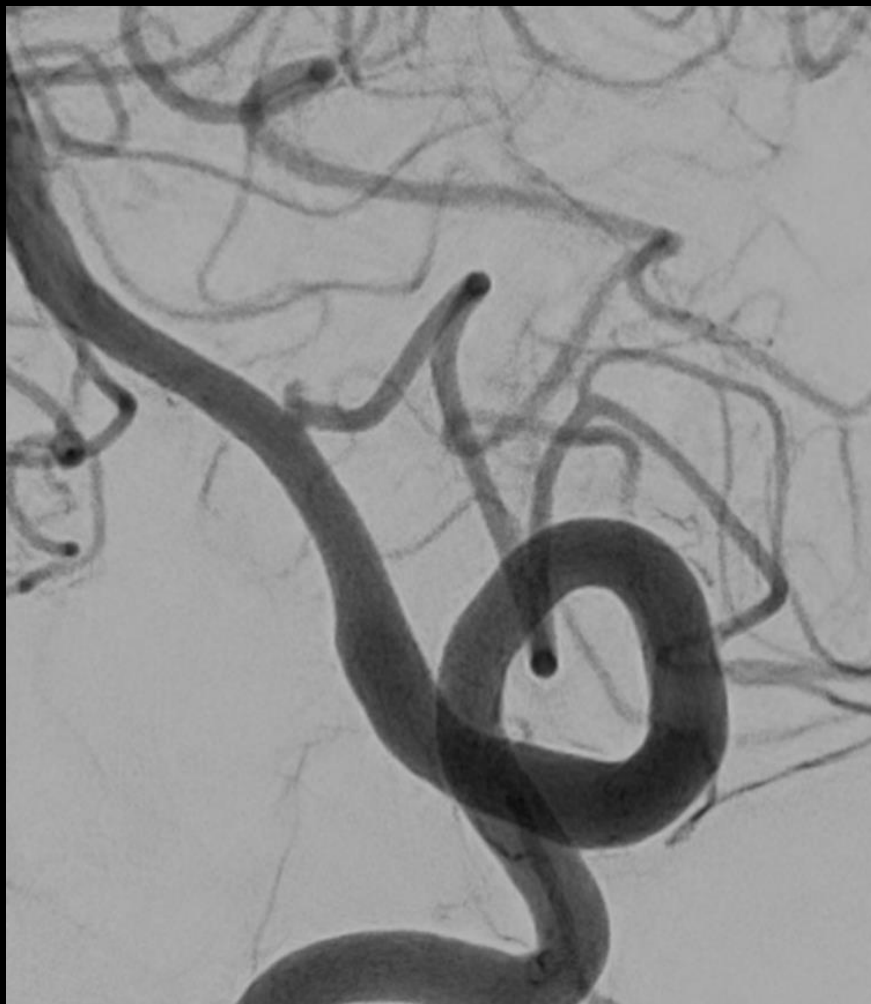
Mujer, 64
HSA Fisher IV Hunt & Hess IV

ASD: Aneurisma PICA izq

ESTRATEGIA: ???



PRE TRATAMIENTO





A.Coils

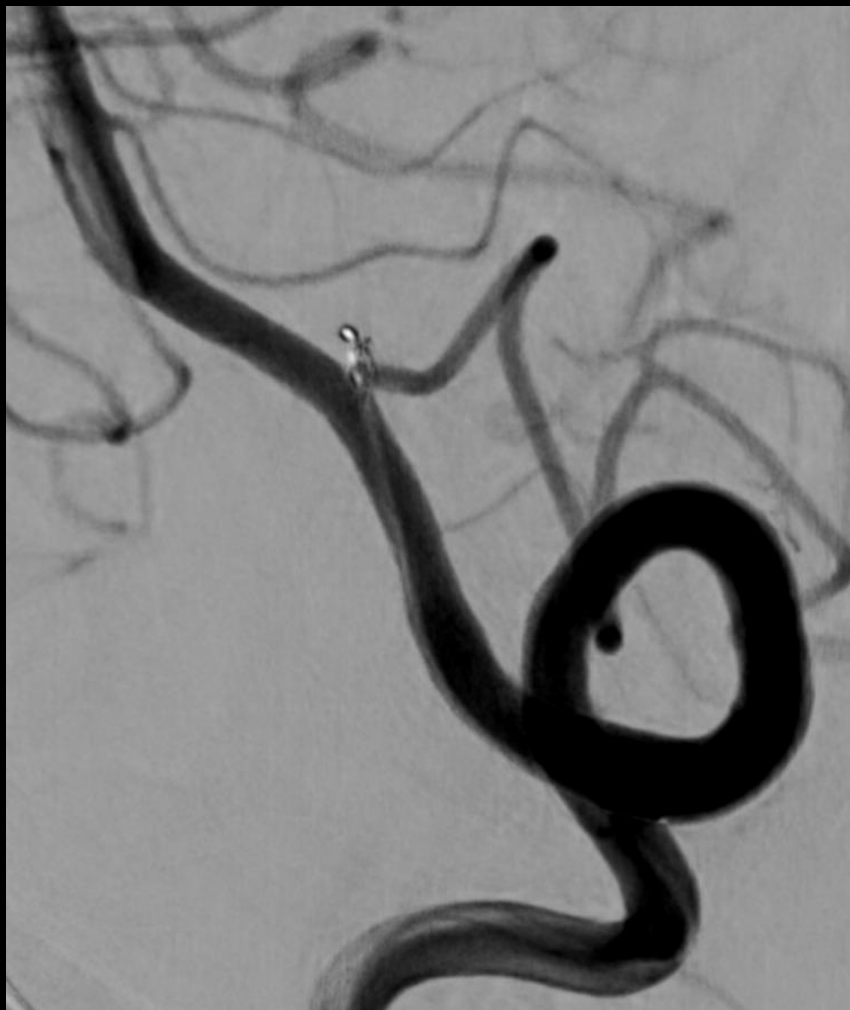B.Balón & coils

C.Diversor de flujo

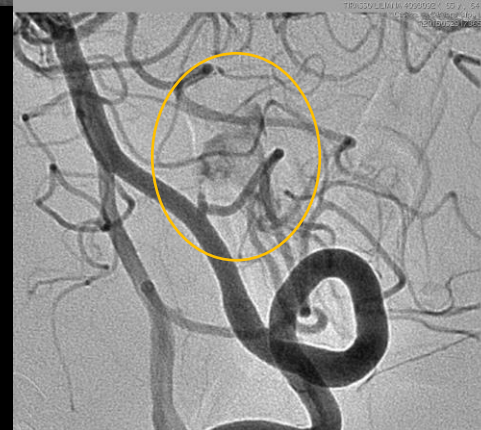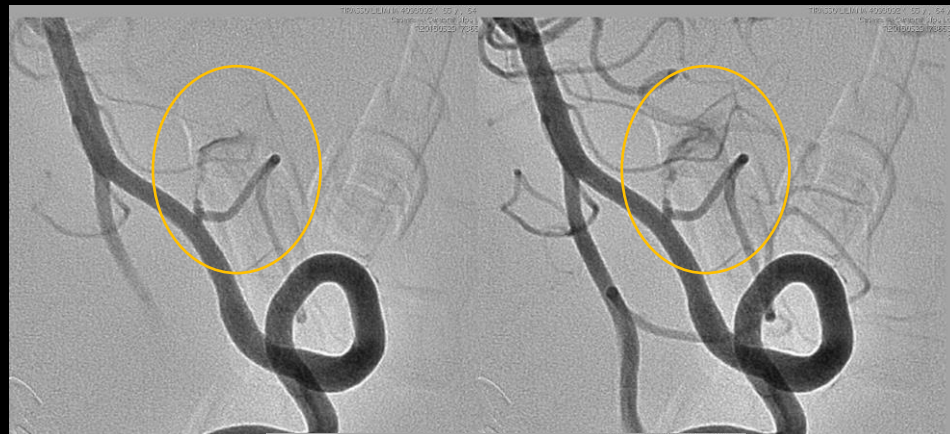D.Clipado quirúrgico

E.Oclusión del vaso

DURANTE TRATAMIENTO

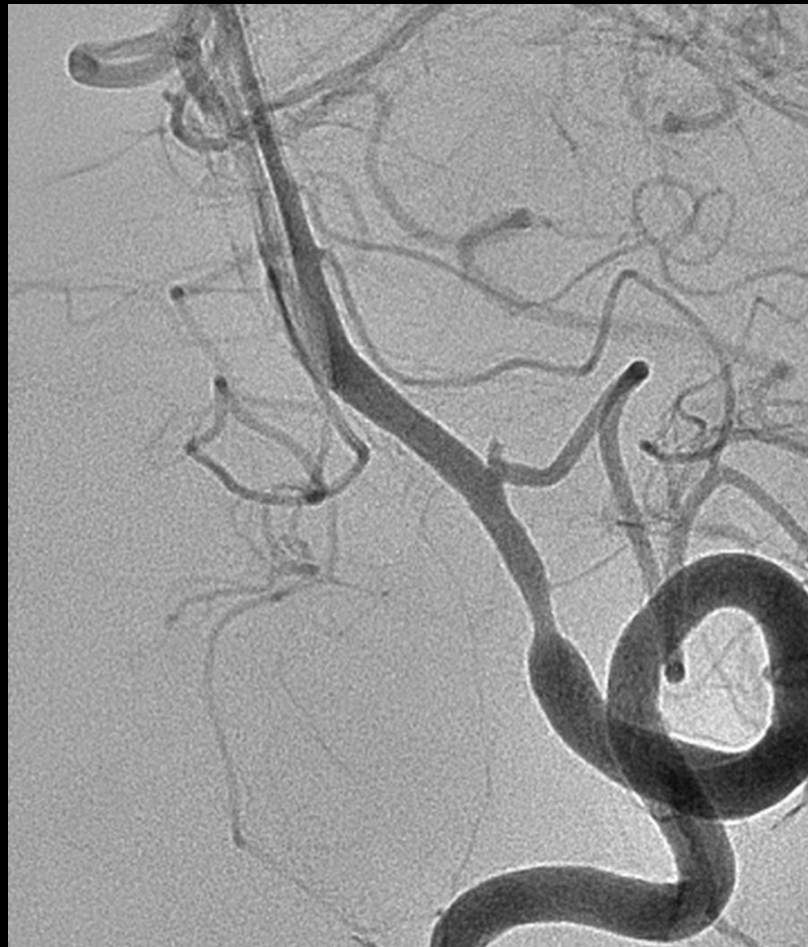
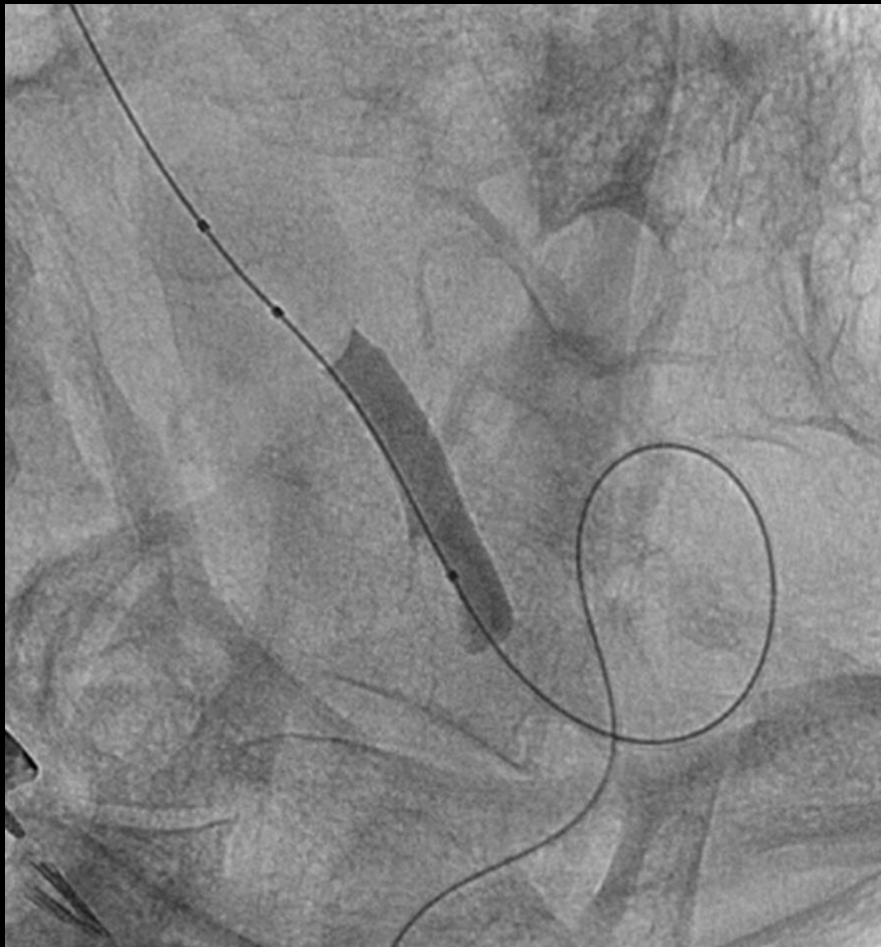

DURANTE TRATAMIENTO



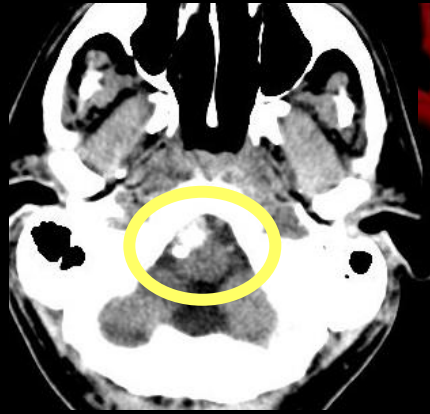


DURANTE TRATAMIENTO

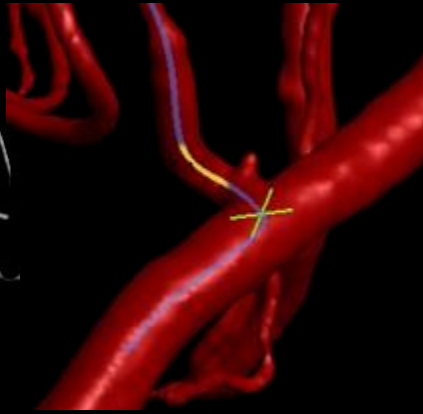


Blister-like – PED alone in a Bleeding Case

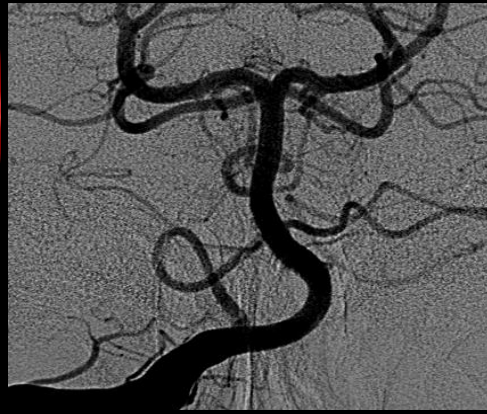
CT Pre Treatment



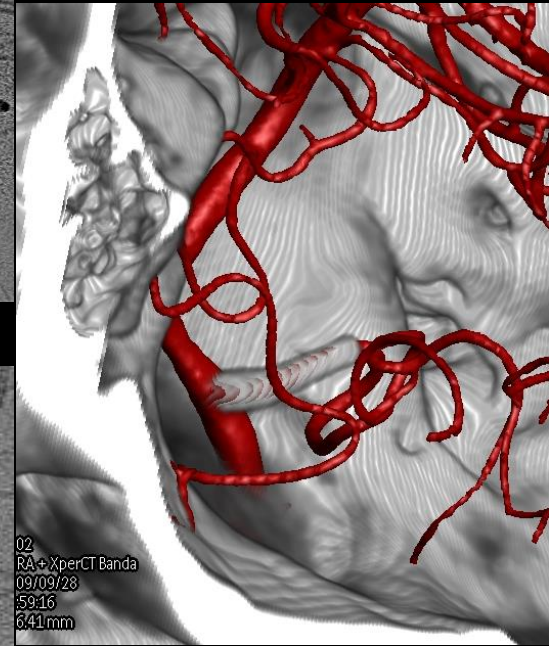
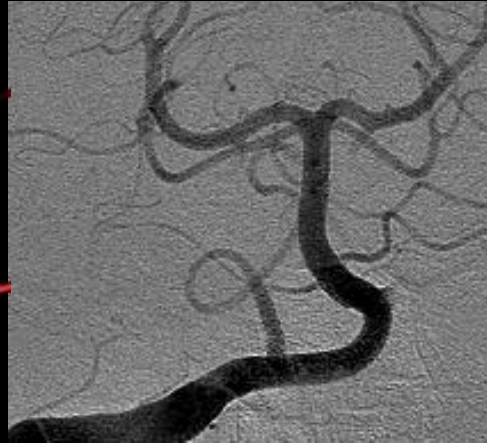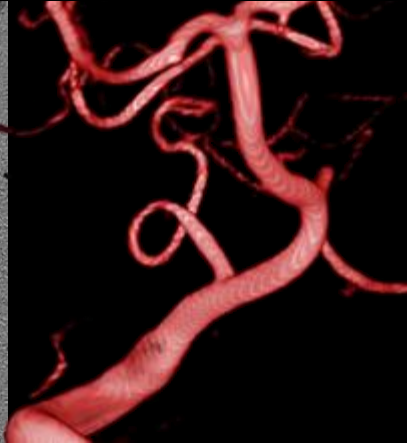
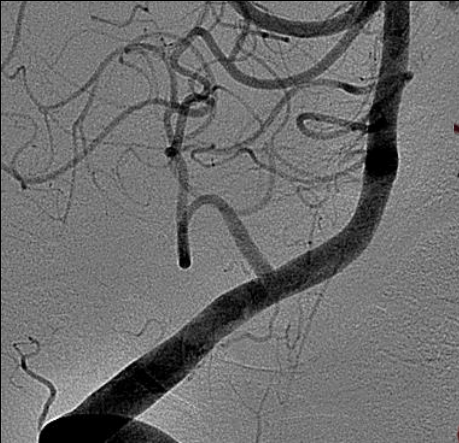3D DSA Pre Treatment



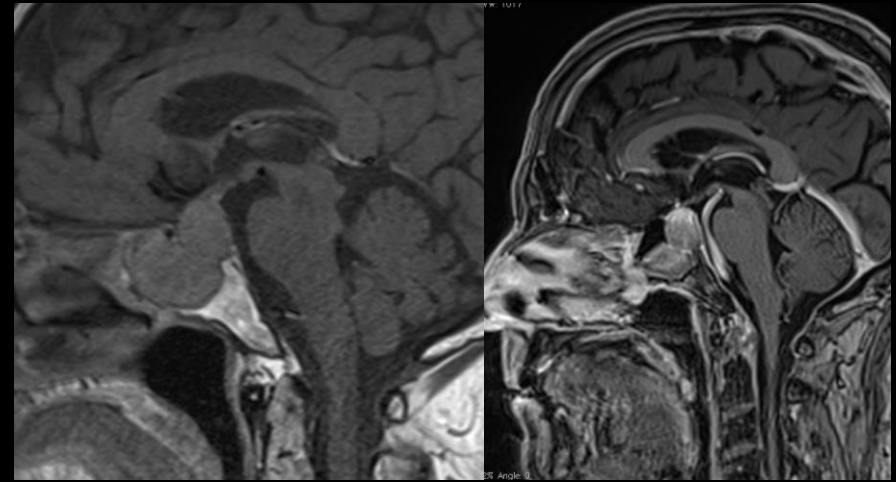
2D DSA Pre Treatment



DSA 21 months FUP

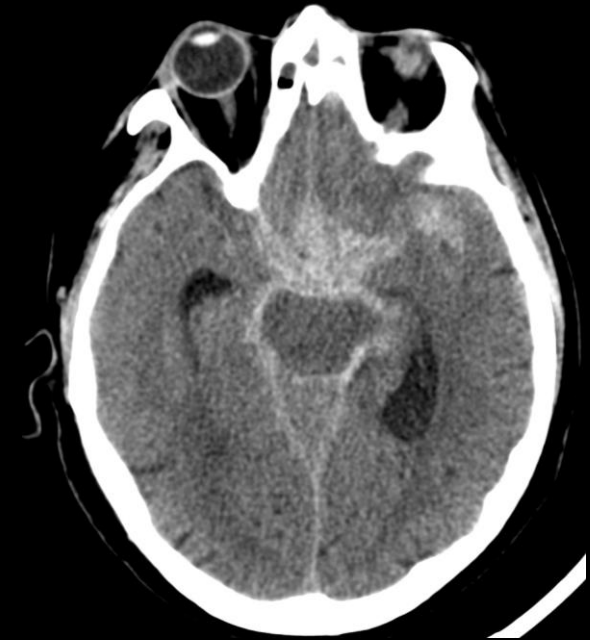


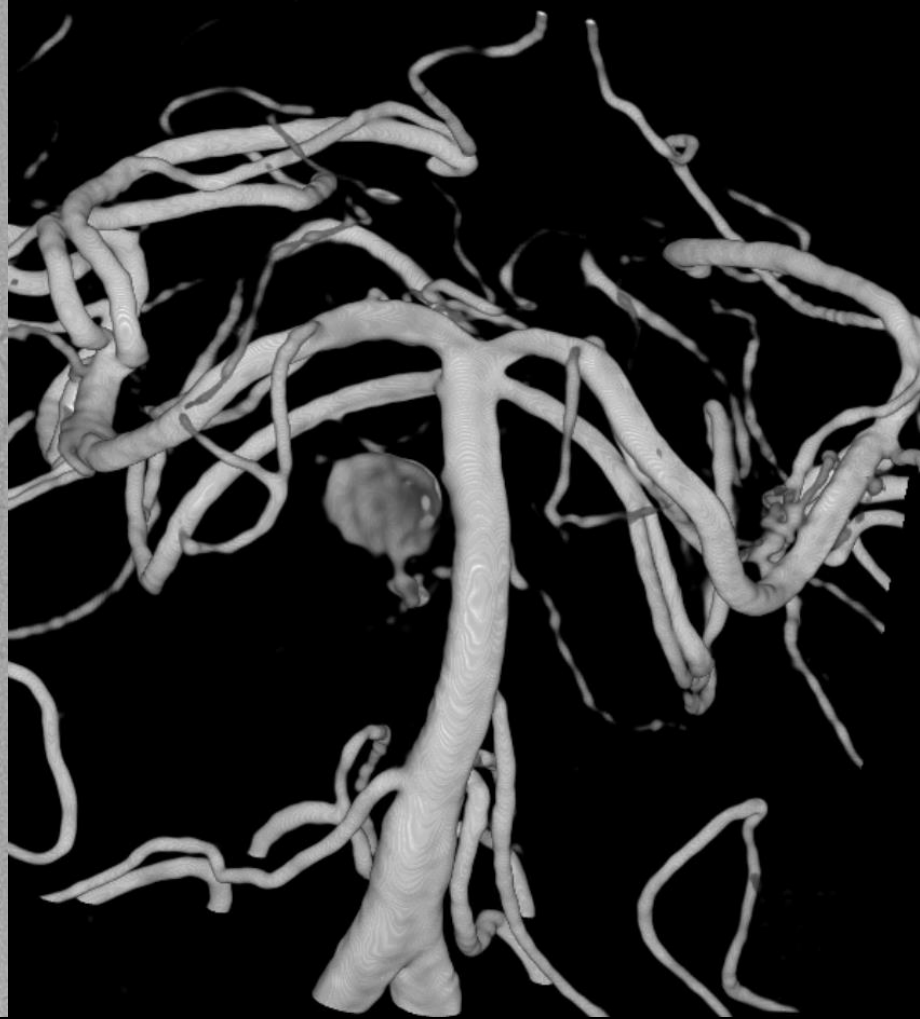
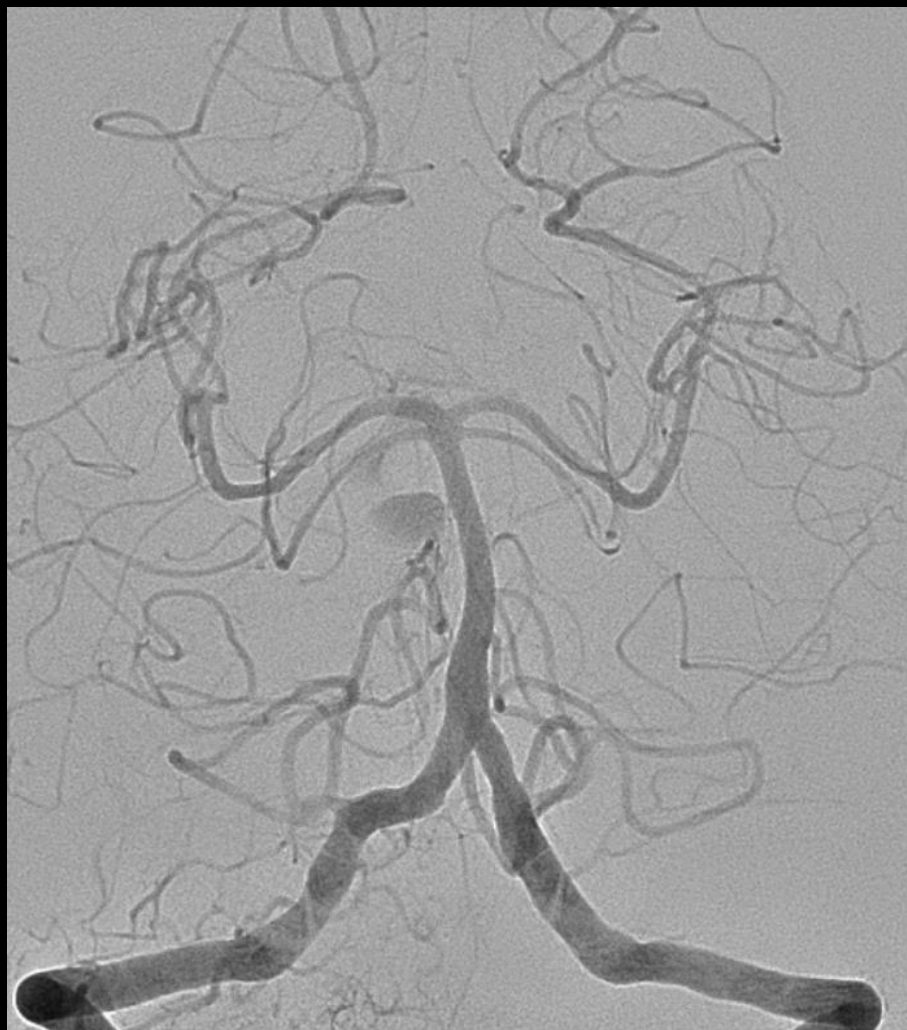Varón, 66
Tumor hipofisario operado por vía trans
esfenoidal



ASD: Disección traumática del tronco
basilar

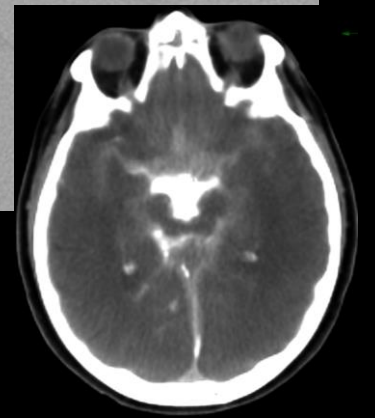
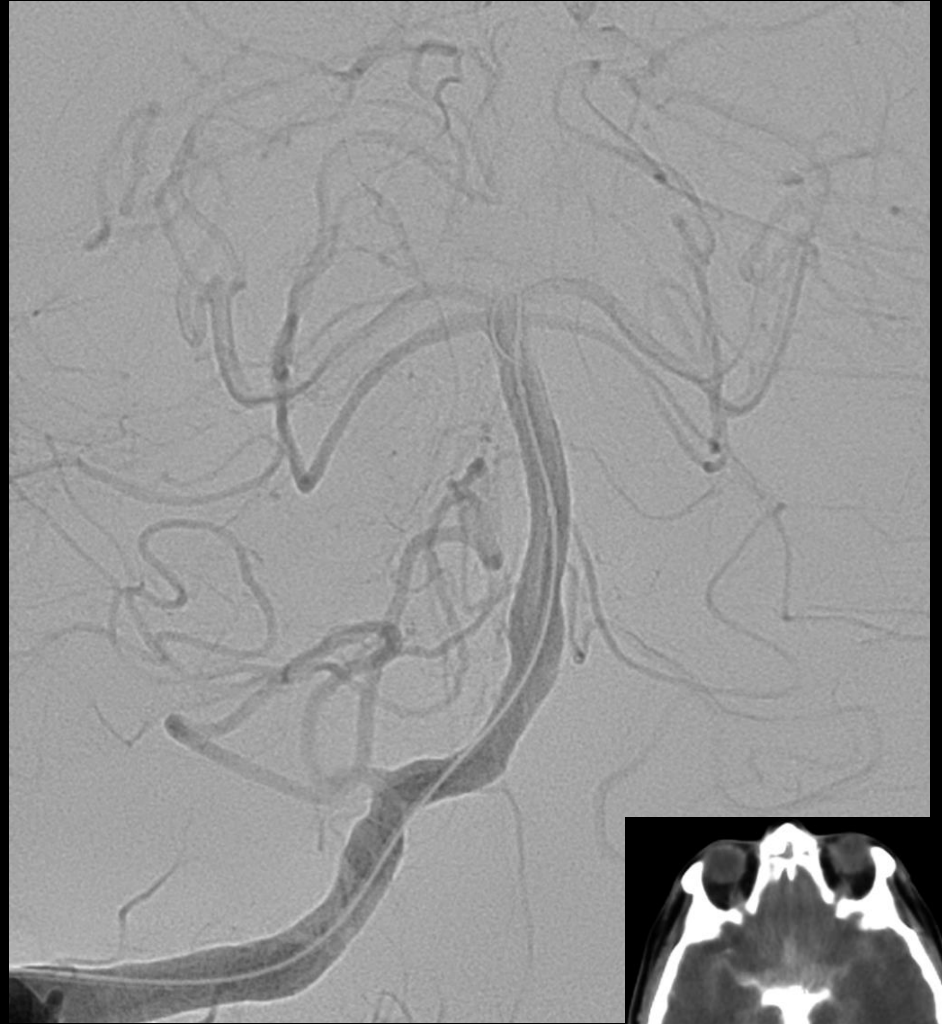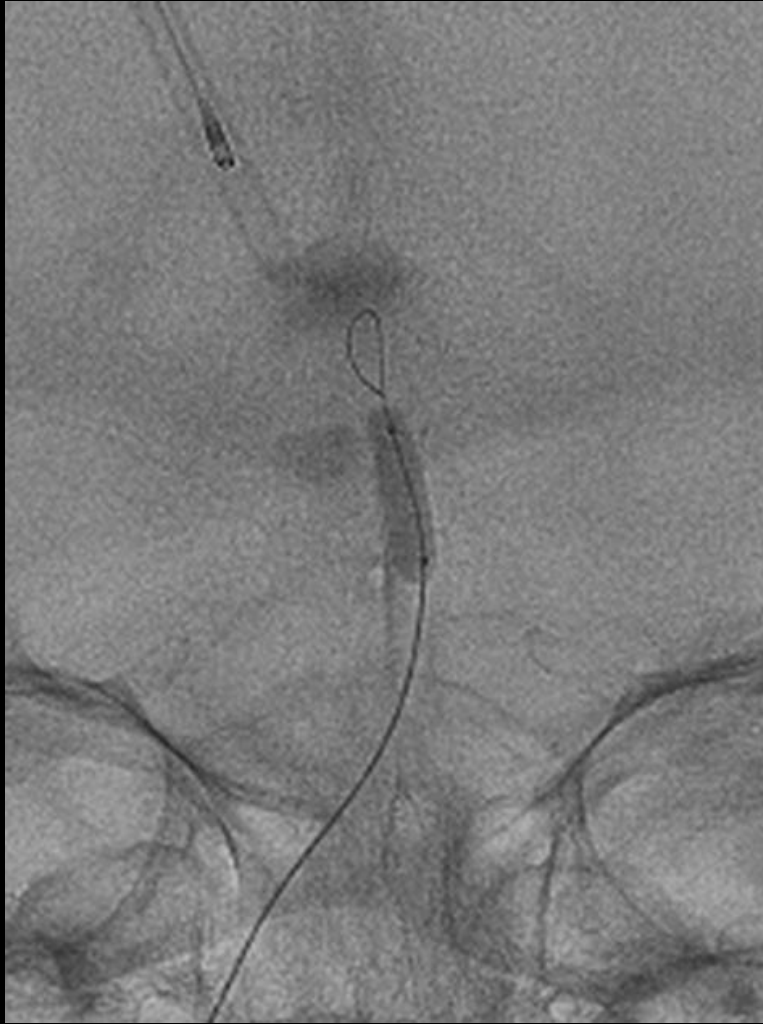
ESTRATEGIA: ???







- A.Oclusión del vaso**
- B.Balón & coils**
- C.Diversor de flujo**
- D.Oclusión temporaria
con balón**



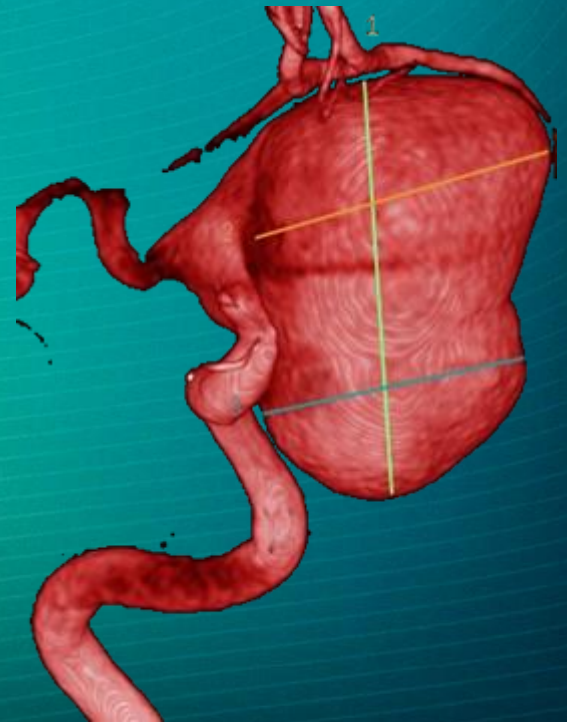


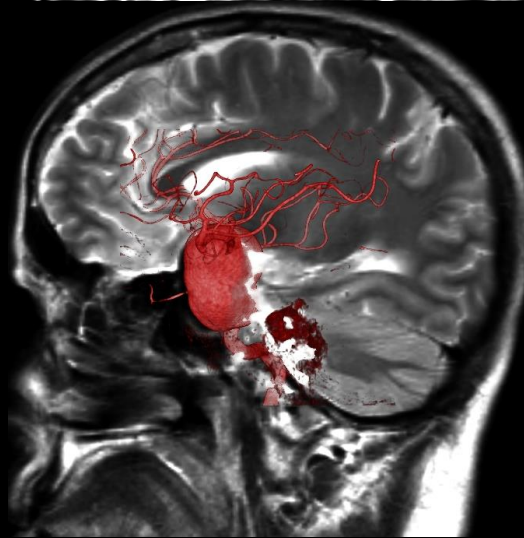
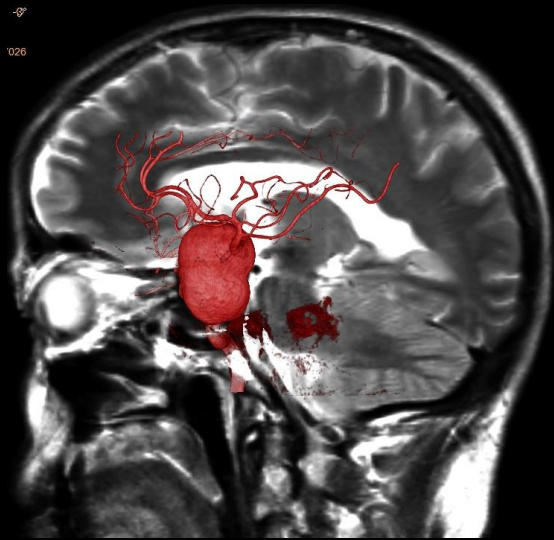
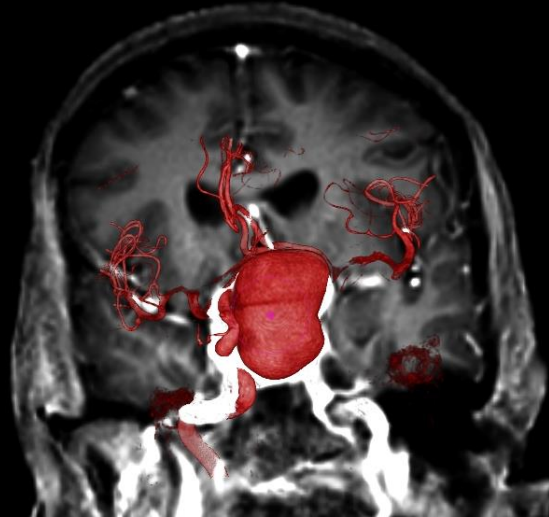
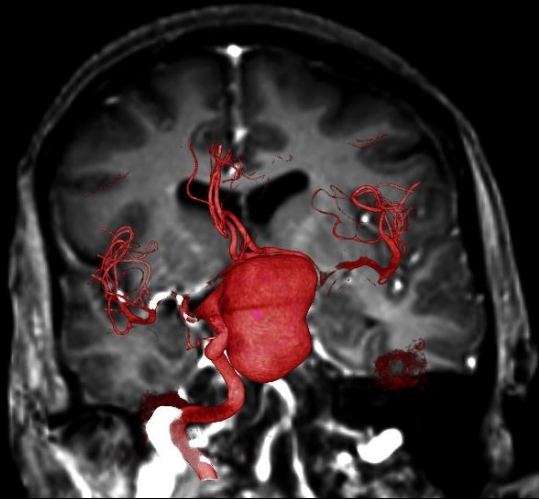
GM, Mujer, 61
Déficit visual bilateral, ceguera en OD

Aneurisma hipofisario superior derecho gigante
Estenosis carotídea contralateral severa
- Oclusión de ACI supraclinoidea izq.

ASD: aneurisma hipofisario sup der gigante

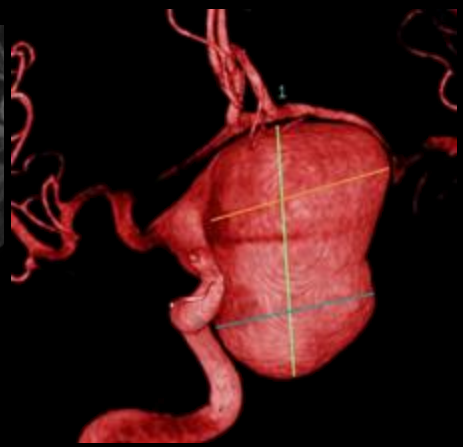
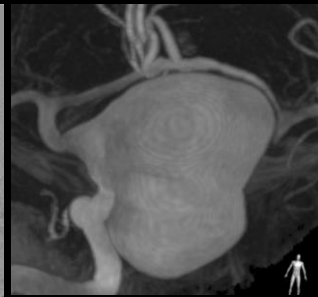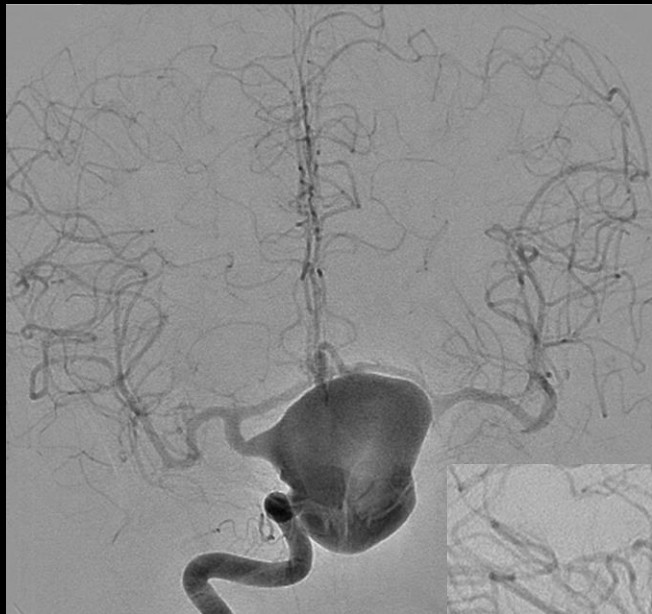ESTRATEGIA: Diversor de Flujo



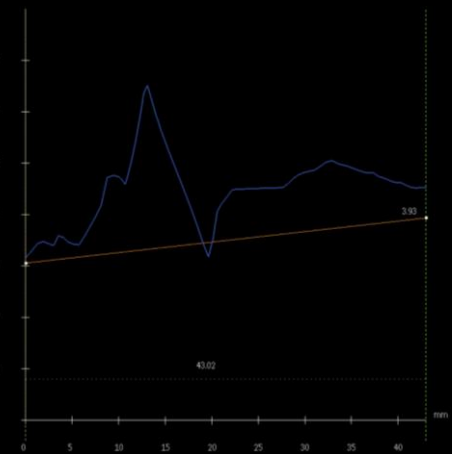
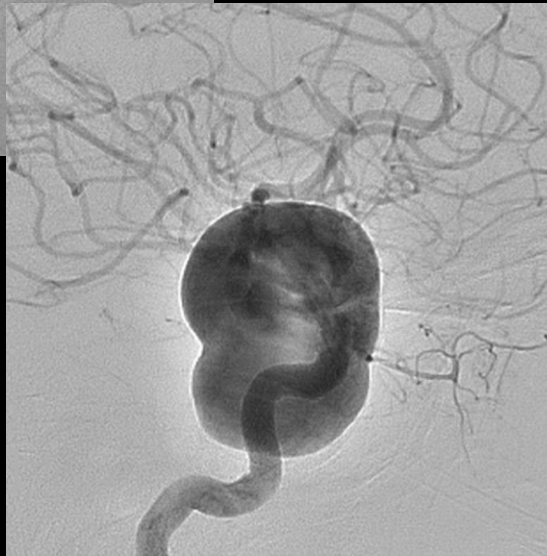
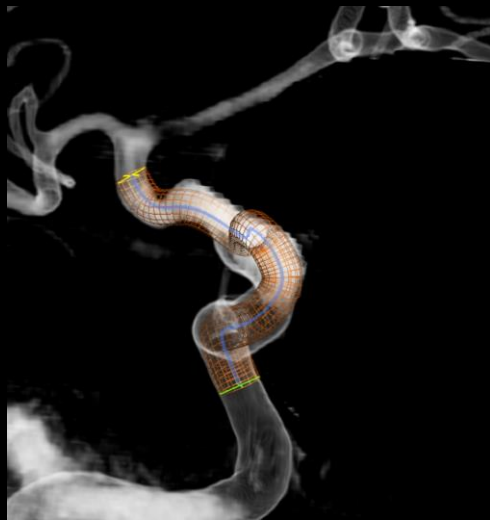


-9°
026

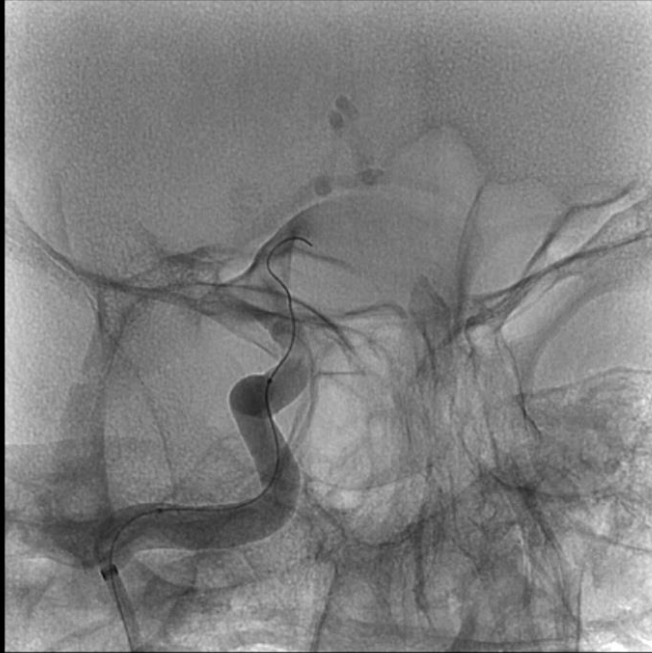PRE TRATAMIENTO



Medición rápida 1 34.57 mm
Medición rápida 2 26.57 mm
Medición rápida 3 23.24 mm



DURANTE TRATAMIENTO

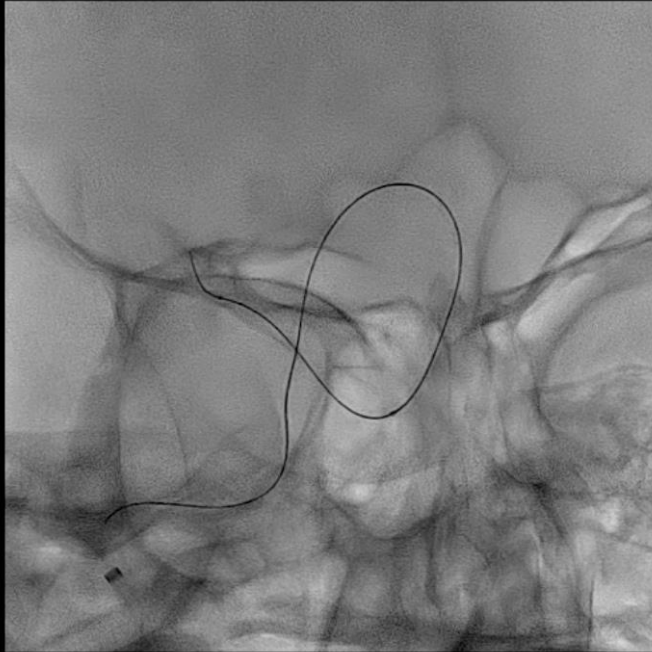

1^{er} intento a M1 → **FALLIDO**



- A. 2 microguías diferentes
- B. Loop de 360 dentro del aneurisma
- C. Mayor soporte con el catéter guía
- D. Balón en el aneurisma para mayor soporte con la guía
- E. Cambio por MC mayor
- F. Doble guía

DURANTE TRATAMIENTO

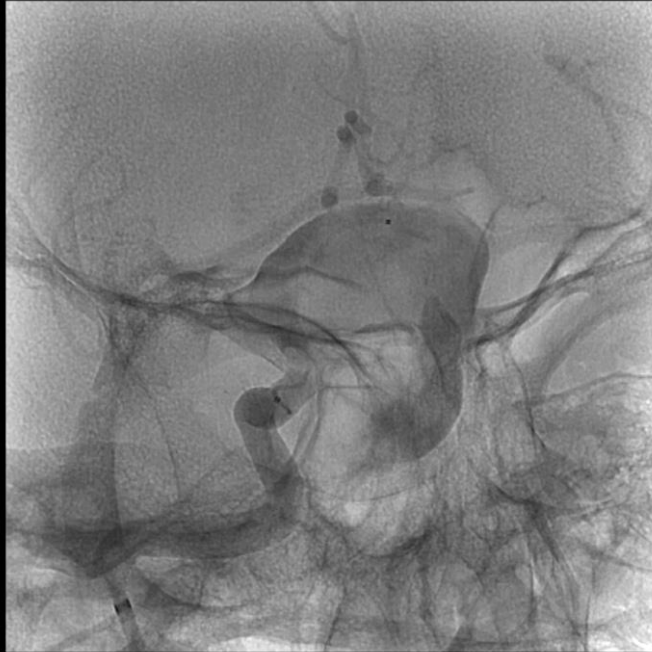


2^{do} intento, loop de 360° →
FALLIDO



- A. 2 microguías diferentes
- B. Loop de 360 dentro del aneurisma**
- C. Mayor soporte con el catéter guía
- D. Balón en el aneurisma para mayor soporte con la guía
- E. Cambio por MC mayor
- F. Doble guía

DURANTE TRATAMIENTO

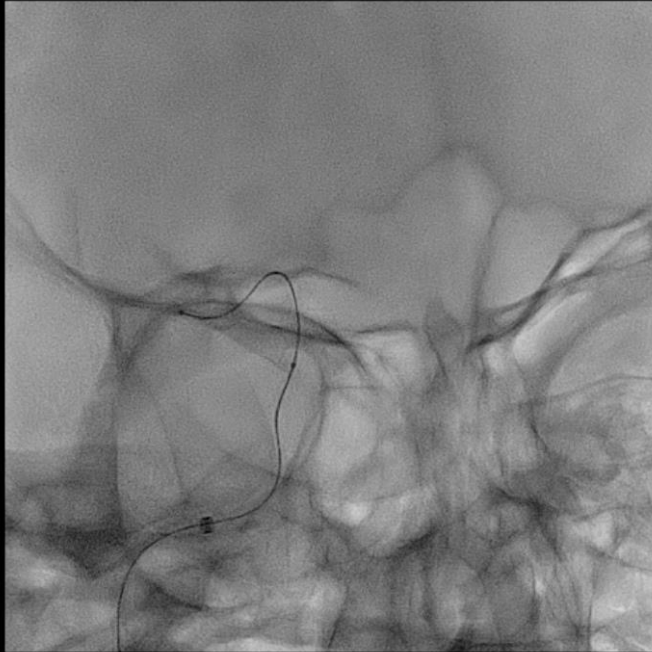


Guía y catéter diferentes →
FALLIDO



- A. 2 microguías diferentes**
- B. Loop de 360 dentro del aneurisma**
- C. Mayor soporte con el catéter guía**
- D. Balón en el aneurisma para mayor soporte con la guía**
- E. Cambio por MC mayor**
- F. Doble guía**

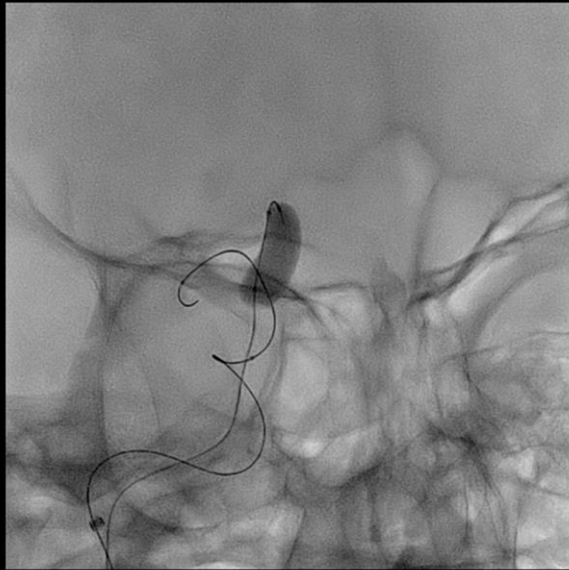DURANTE TRATAMIENTO



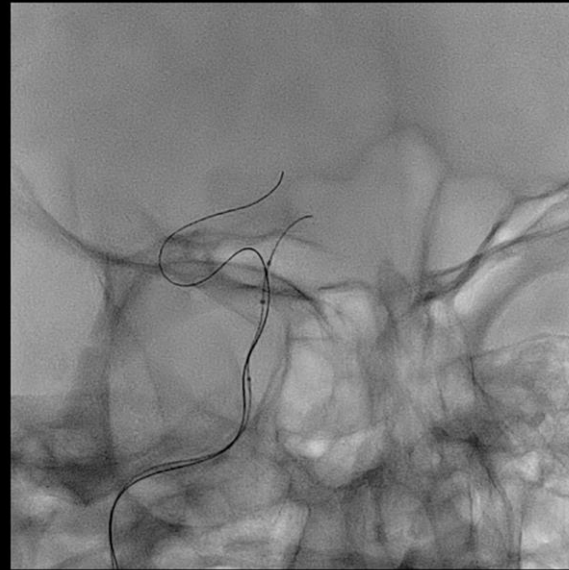
Mayor soporte con el Navien →
FALLIDO



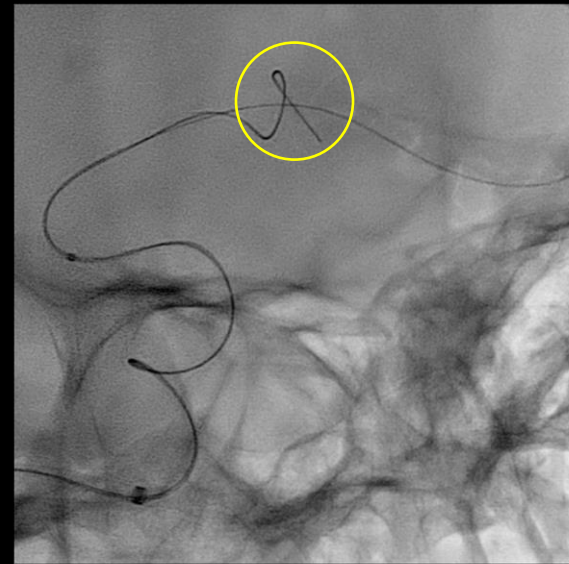
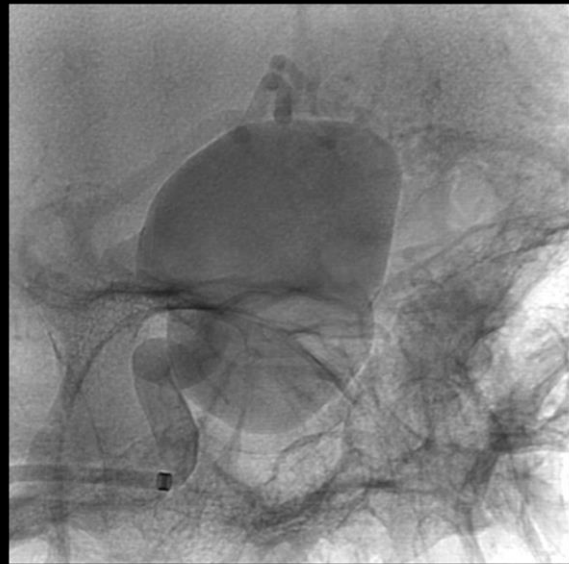- A. 2 microguías diferentes
- B. Loop de 360 dentro del aneurisma
- C. Mayor soporte con el catéter guía
- D. Balón en el aneurisma para mayor soporte con la guía
- E. Cambio por MC mayor
- F. Doble guía



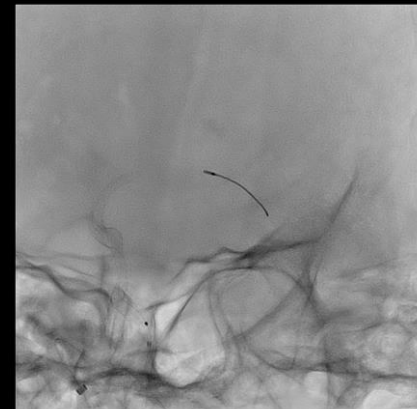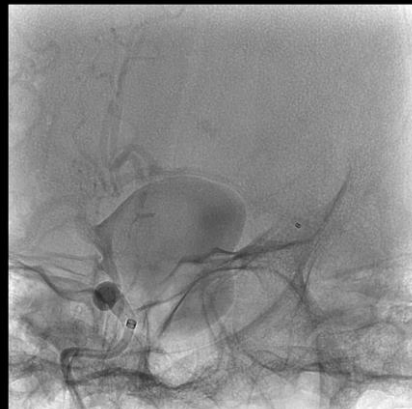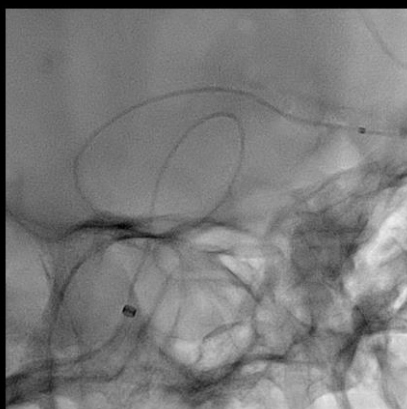
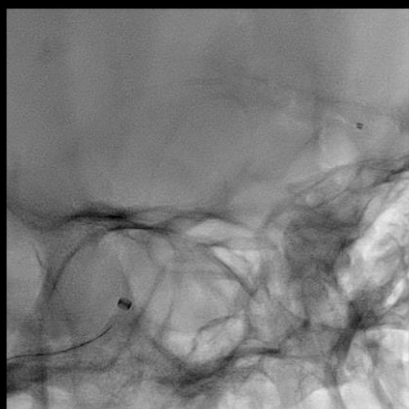
Balón Scepter 4x10mm + M.C. aM1



Yendo a A1

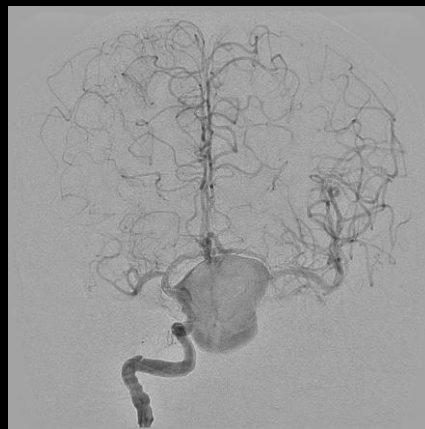
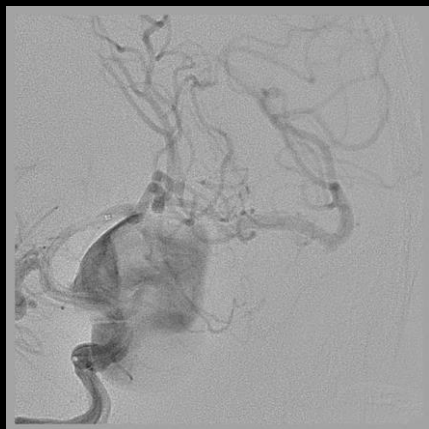
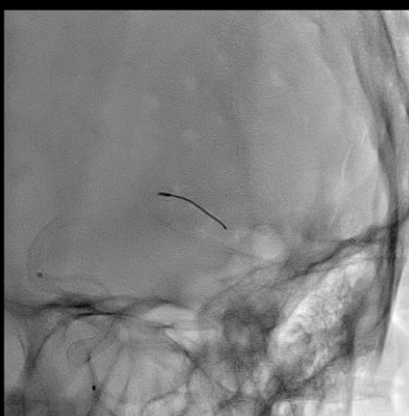**Utilizando Marksman y Transend
0.010 + 0.014**

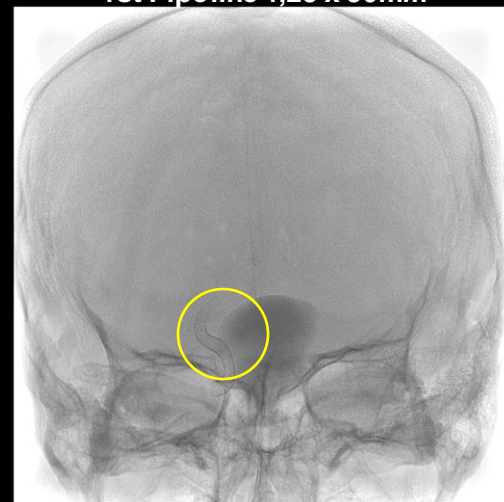


Marksman a través de AcomA para mayor soporte

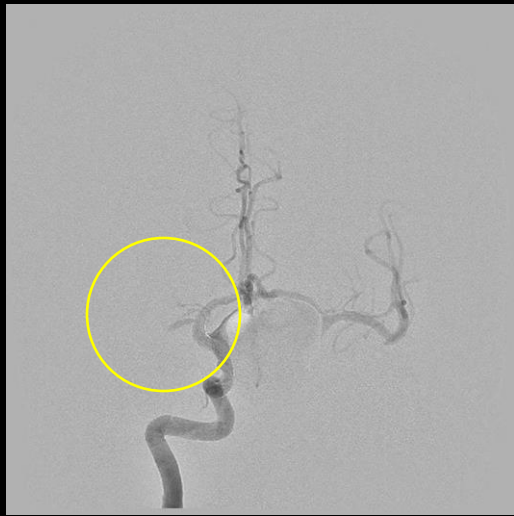1st Pipeline 4,25 x 30mm



2nd Pipeline 4,25 x 20mm



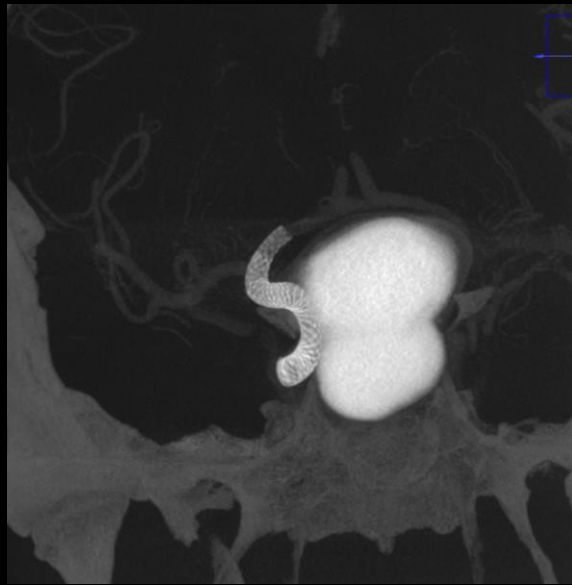
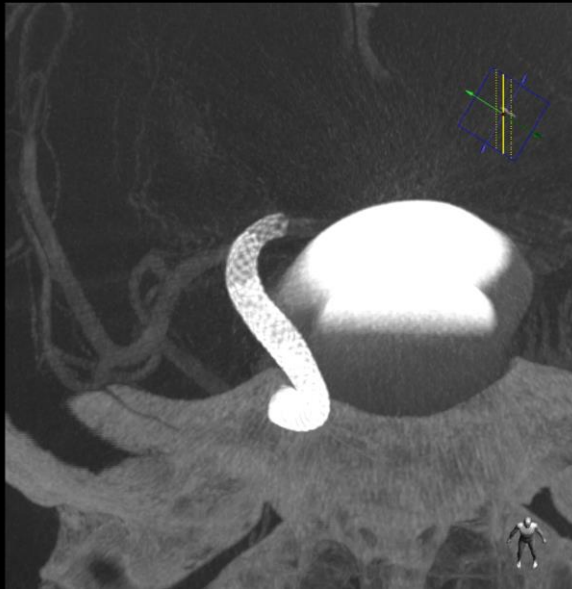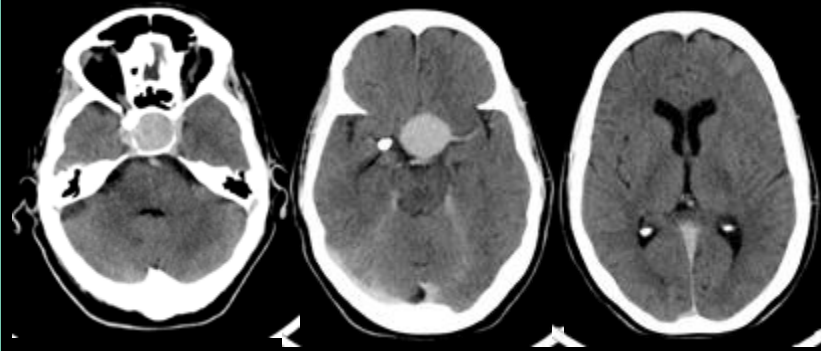
3rd Pipeline 4,25 x 14mm

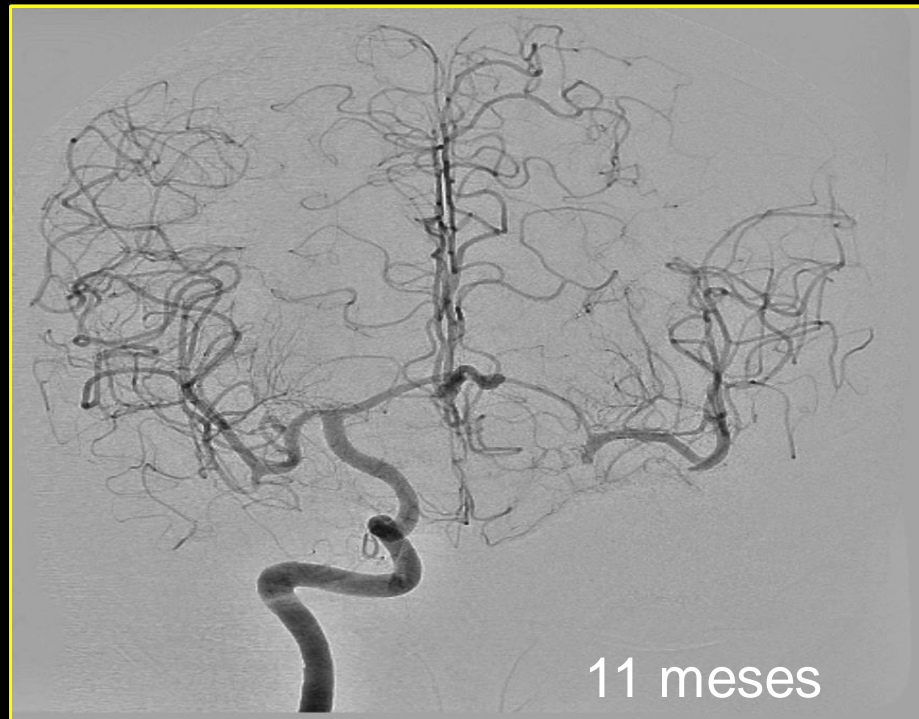
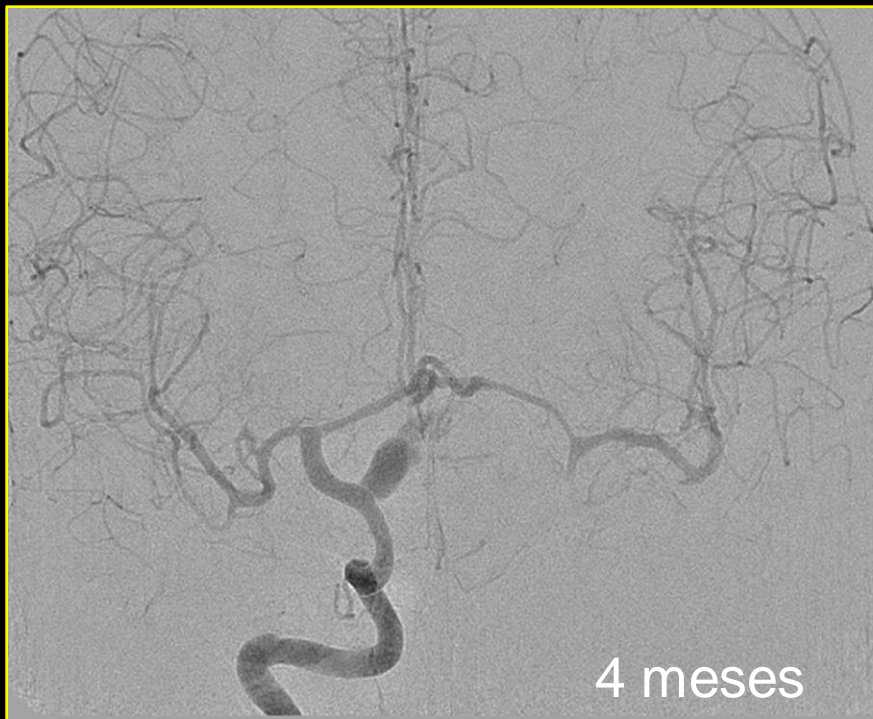
?????



Esperar y retirar los sistemas...



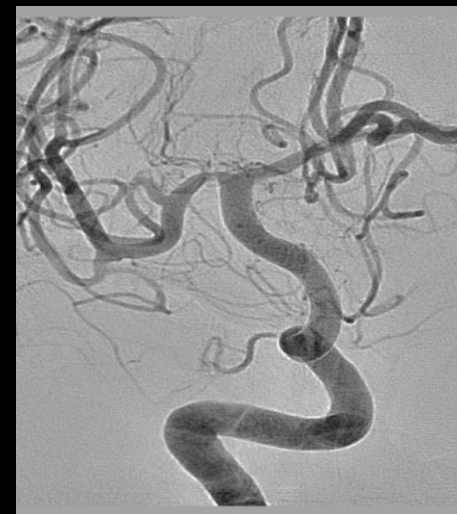
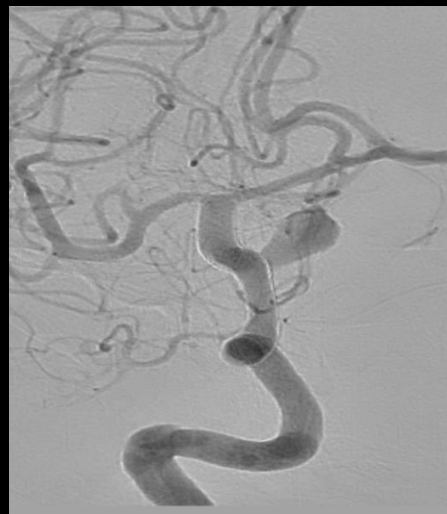
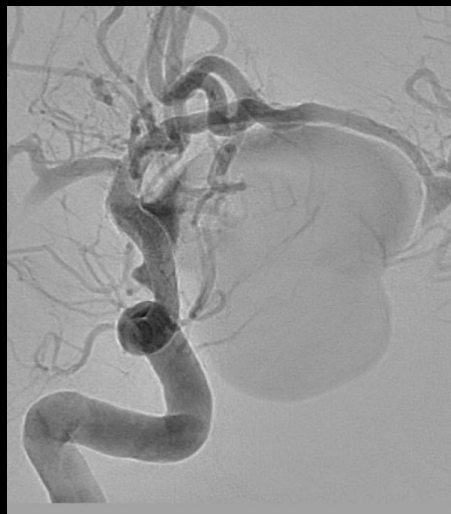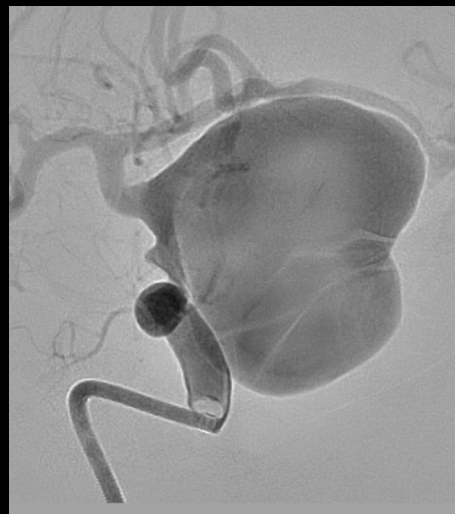PRE TTO.

POST TTO.

4 MESES

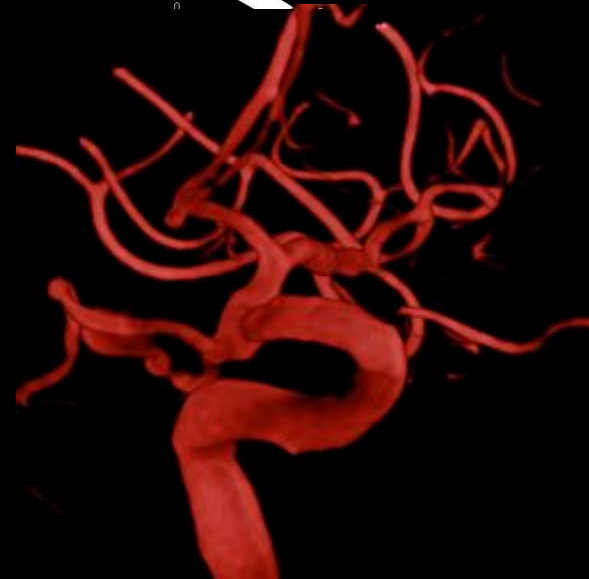
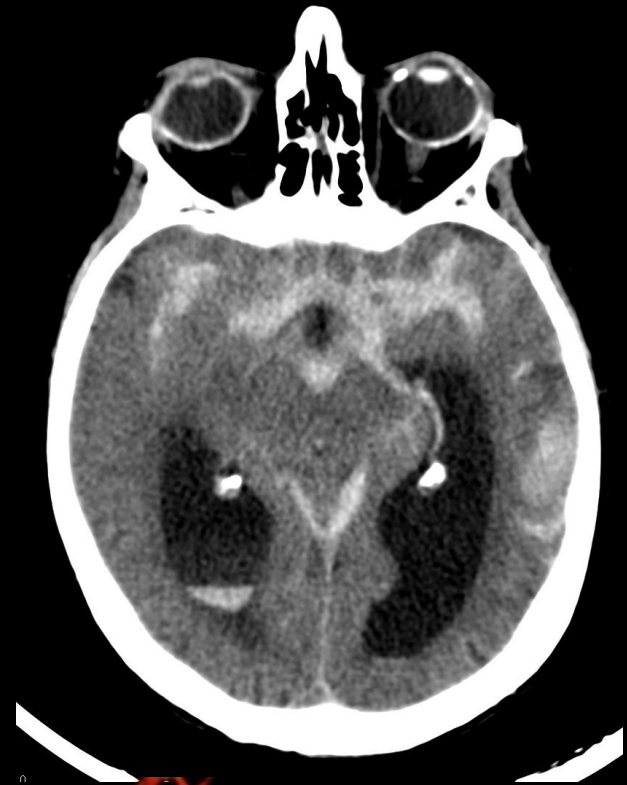11 MESES

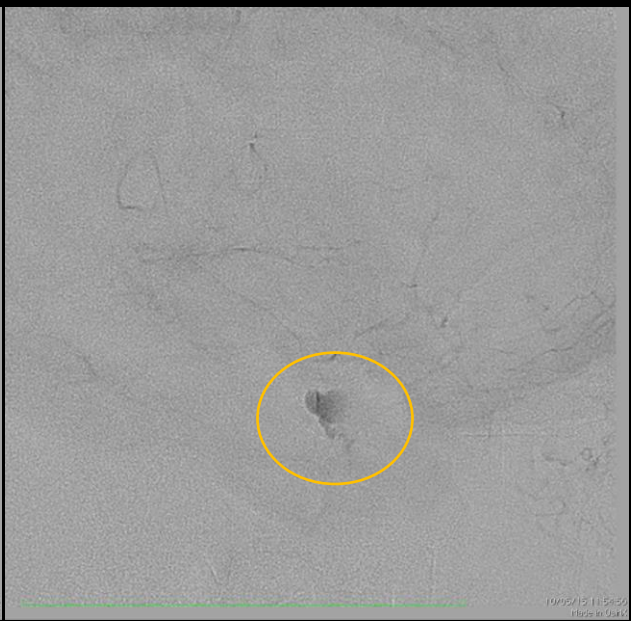
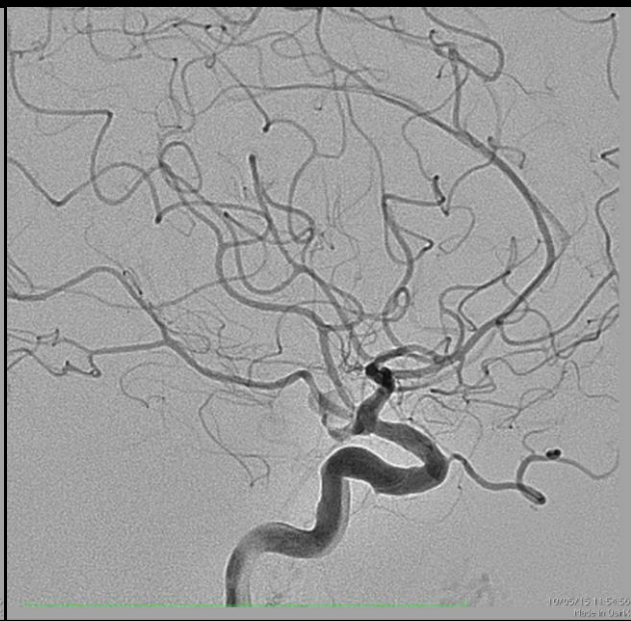
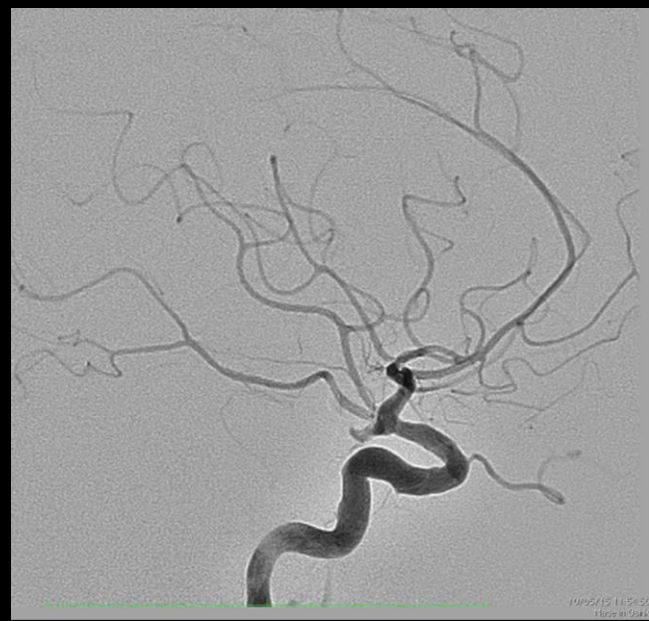Mujer, 97
HSA Fisher IV Hunt & Hess III
III par completo.

ASD: Aneurisma comunicante posterior izquierdo grande, con pseudoaneurisma

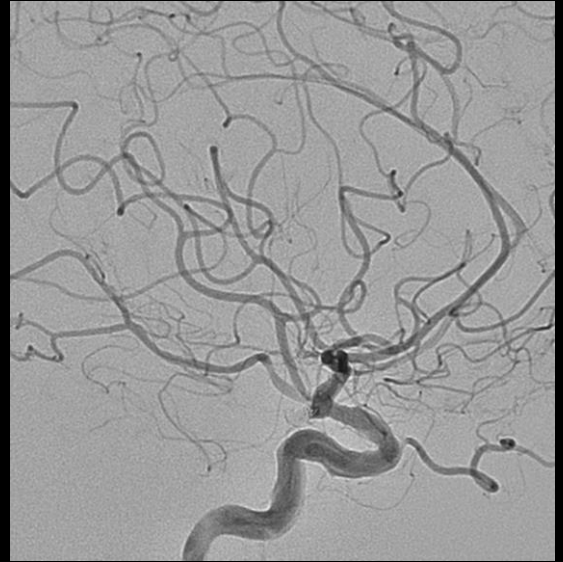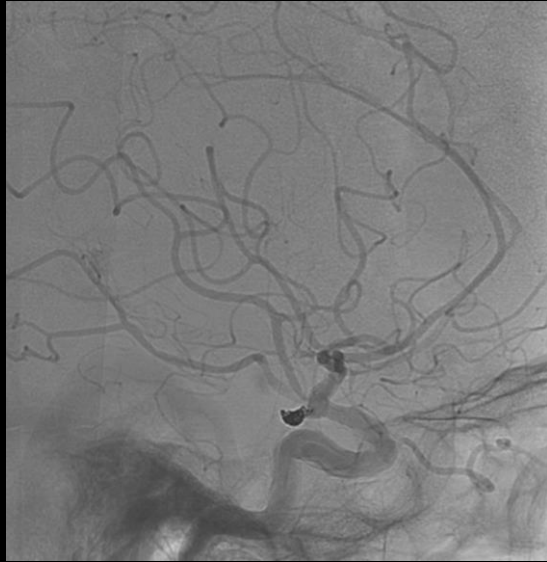
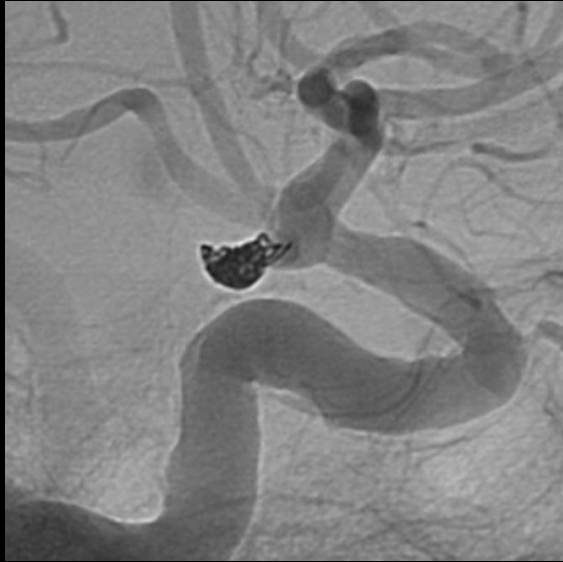ESTRATEGIA: ???







- A.Coils en el aneurisma**
- B.Coils en el aneurisma y en el pseudo**
- C.Diversor de flujo y coils**
- D.Diversor de flujo**
- E.Clipado quirúrgico**



Mujer, 33

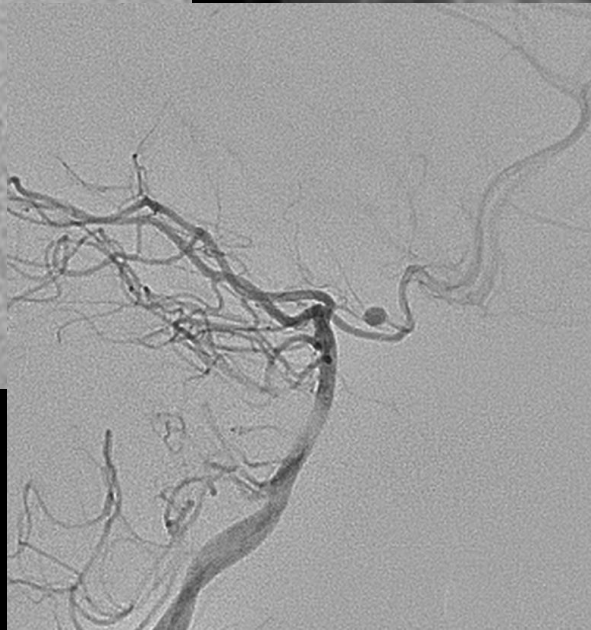
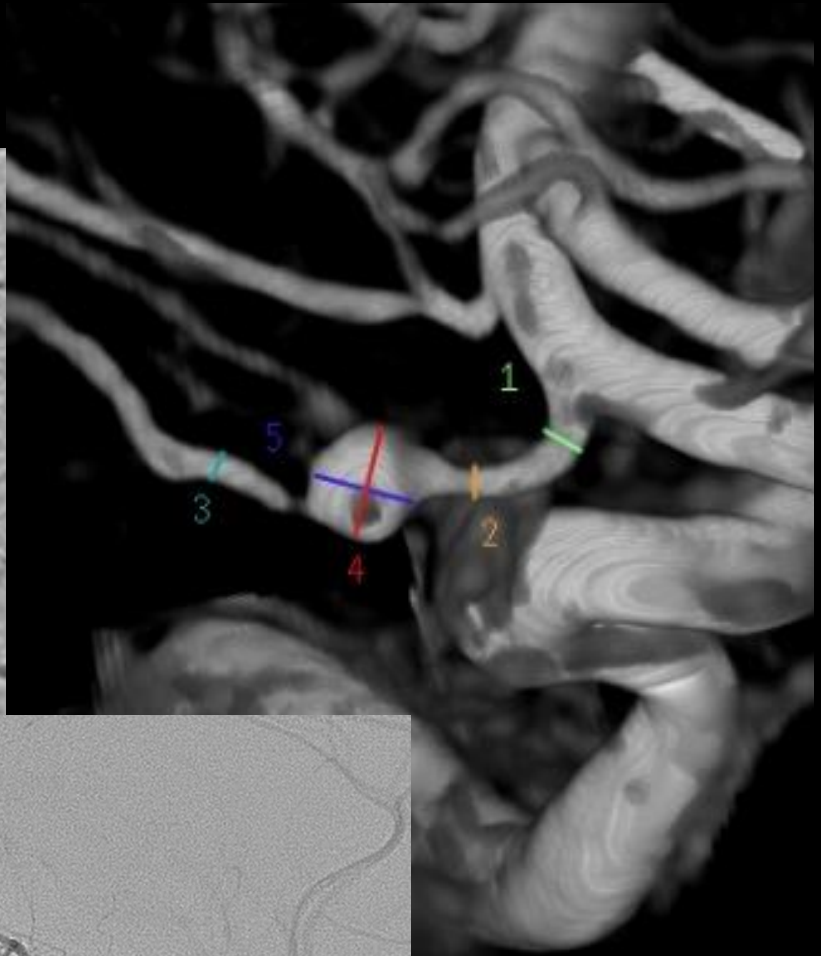
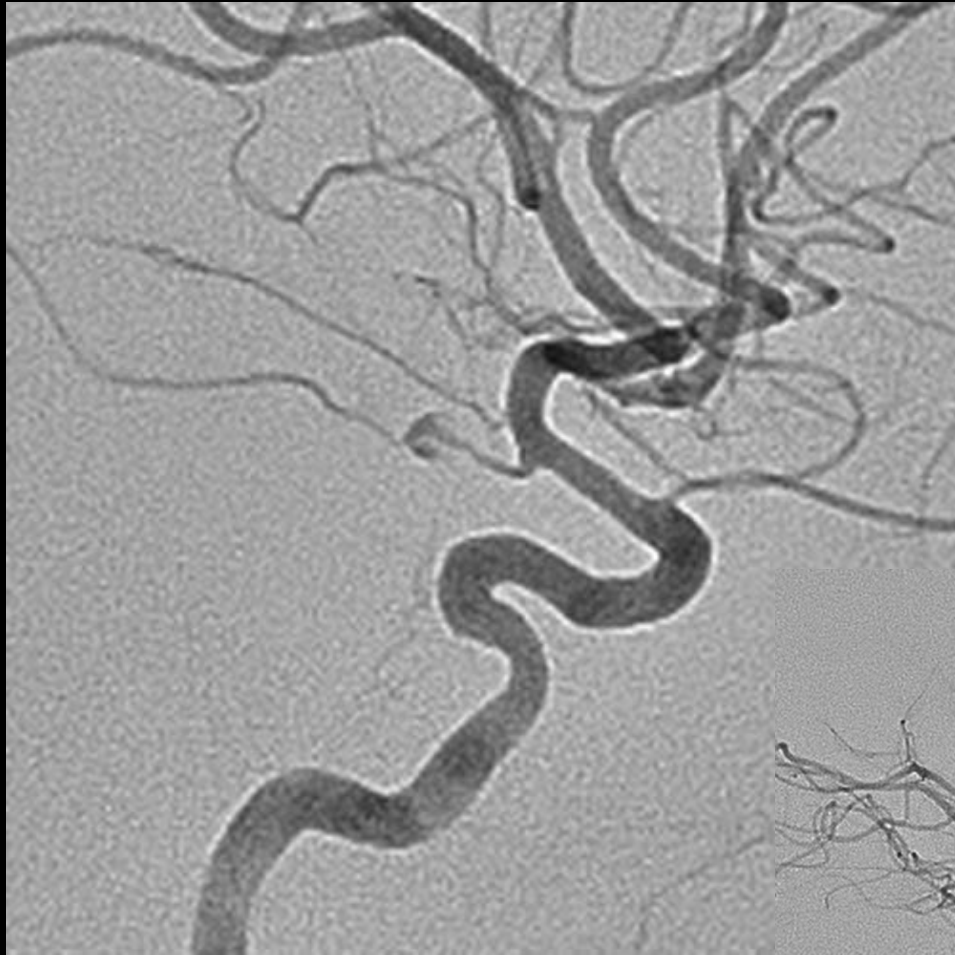HSA Fisher III Hunt & Hess II 30 días.

Tratamiento fallido en otra institución.

ASD: Aneurisma comunicante posterior izquierdo
disecante de la arteria comunicante posterior

ESTRATEGIA: ???

PRE TRATAMIENTO





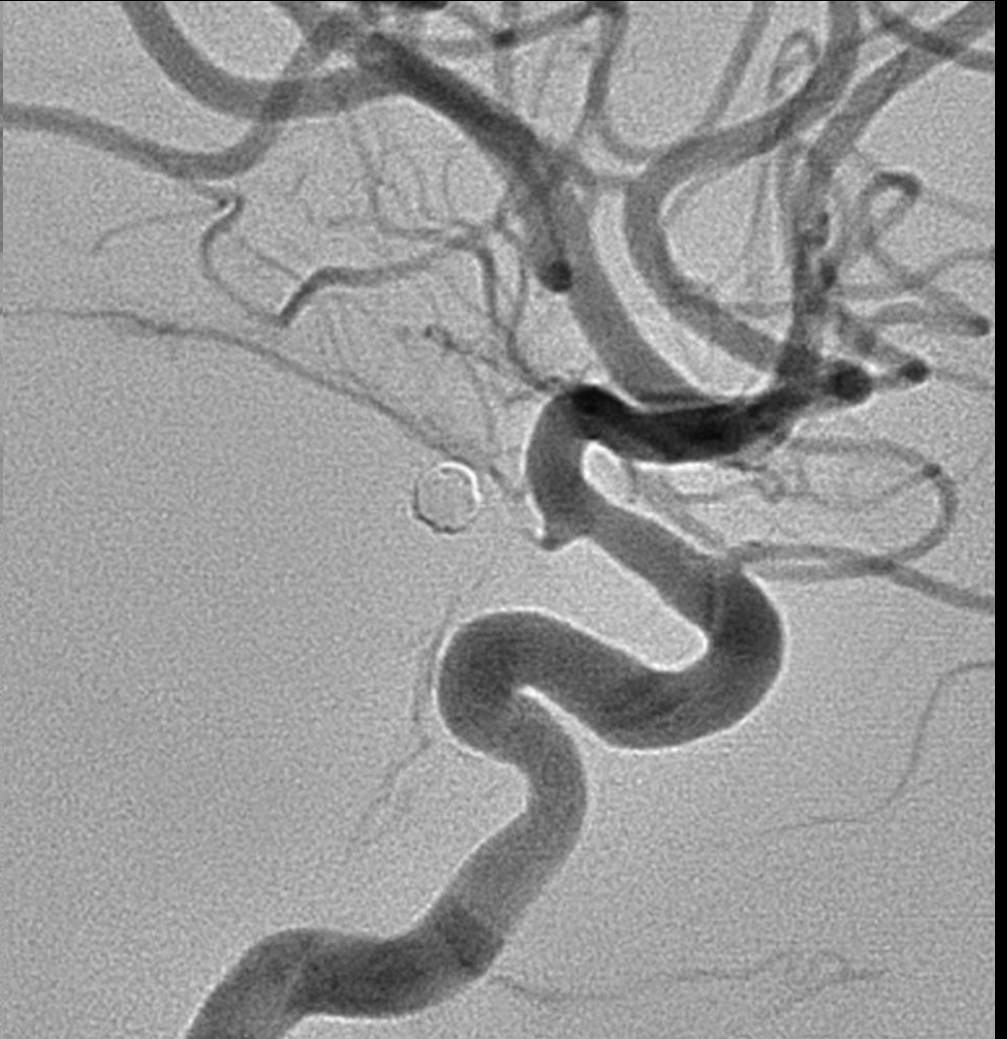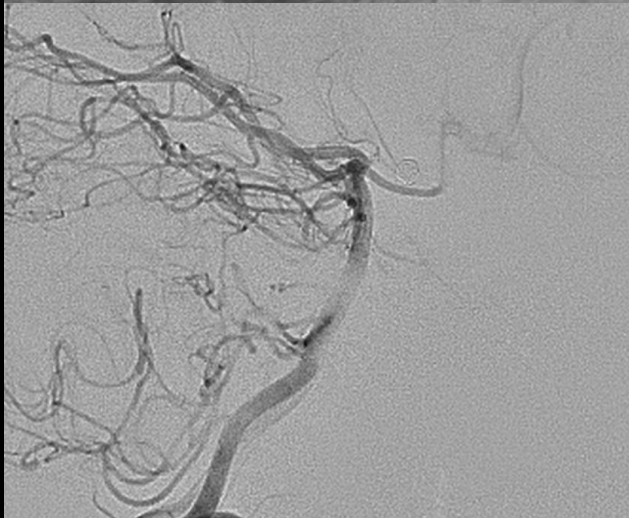
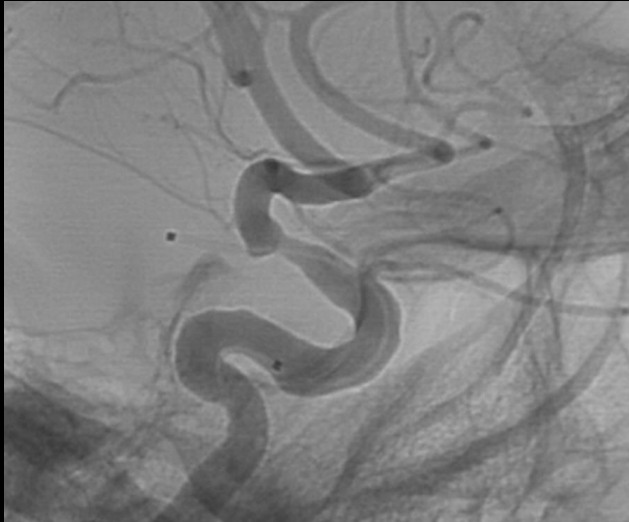
A.Control

B.Oclusión del vaso

**C.Diversor de flujo en
arteria carótida interna**

D.Clipado quirúrgico

TRATAMIENTO



11 MESES DE SEGUIMIENTO

