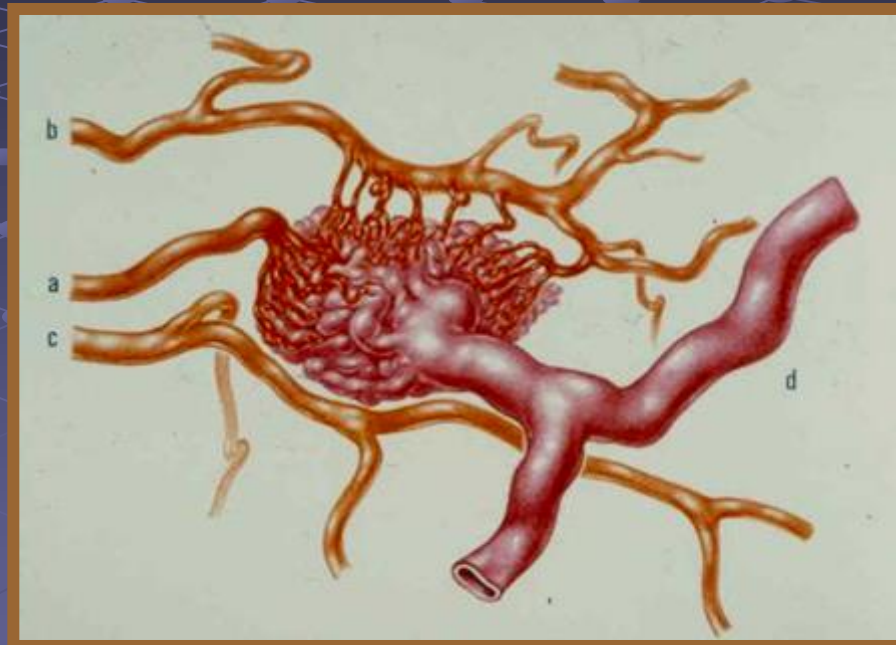

Brain Arteriovenous Malformations

Endovascular Therapy and Associated Therapeutic Protocols



Jorge Guedes Cabral de Campos

Neuroradiology Department
Hospital de Santa Maria – University of Lisbon

Brain Arteriovenous Malformations

Endovascular Therapy and Associated Therapeutic Protocols

CEREBRAL AVM – CLINICAL / EPIDEMIOLOGY

Brain AVM - 0,14% incidence in the population (cooperative study)
(1 / 7 of the incidence of cerebral aneurysms)

McCORMICK PROSPECTIVE PATHOLOGY STUDY:

Brain AVM 4,05 %

Venous angioma – 2,6 % Telangiectasia – 0,7 %
Cavernomas – 0,4% AVM – 0,6 %

HEMORRHAGE - most frequent clinical presentation

Wilkins 1985

Haemorrhagic risk 2% / year
Re-haemorrhagic risk 6% / year

Brain Arteriovenous Malformations

Endovascular Therapy and Associated Therapeutic Protocols

CEREBRAL AVM – CLINICAL / EPIDEMIOLOGY

SEIZURES - ++ frontal / parietal / temporal location

PROGRESSIVE NEUROLOGICAL DEFICE – related to arterial steal syndrome

HEADACHE - accidental

NATURAL EVOLUTION (Olivecrona)

25 % patients without treatment died with hemorrhage

33 % presented severe morbidity

25 % remain without symptoms during long years

IMPORTANCE OF NEW PROSPECTIVE STUDIES – MOHR

Brain Arteriovenous Malformations

Endovascular Therapy and Associated Therapeutic Protocols

CEREBRAL AVM – CLASSIFICATION

Yasargil / Berenstein – Lasjaunias / Valavanis

Location, size, arterial feeders, venous drainage, nidus pattern, presence of direct A / V fistulae

Importance of haemorrhagic risk factors

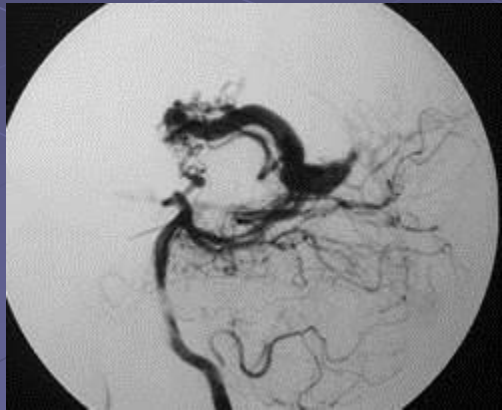
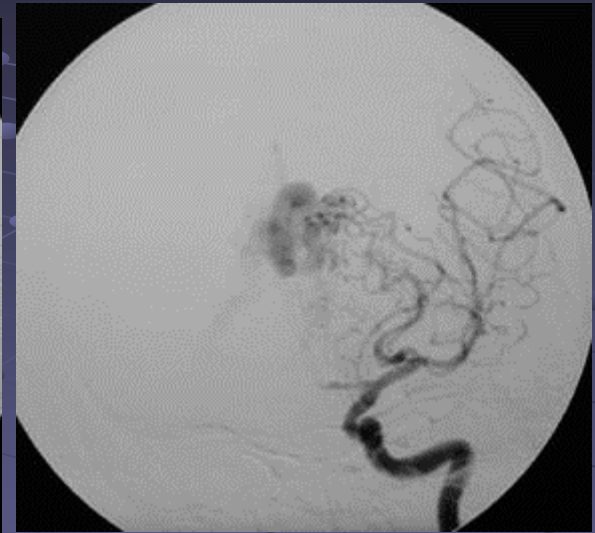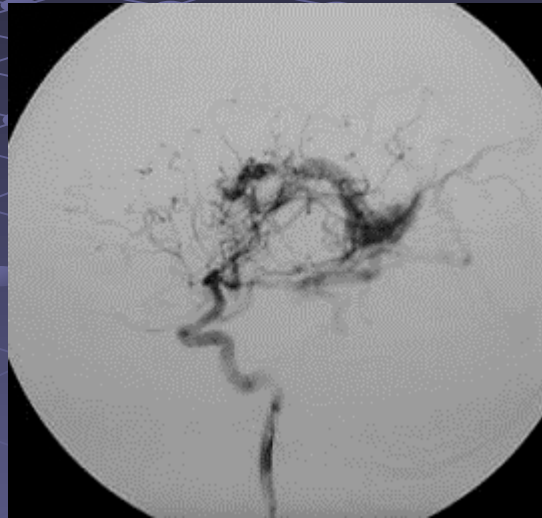
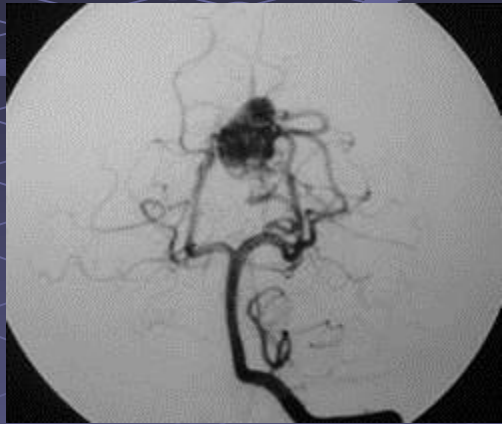Spetzler and Martin classification

Size / venous drainage / eloquence - **AVM SURGICAL RISK**

Brain Arteriovenous Malformations

Endovascular Therapy and Associated Therapeutic Protocols

Left deep AVM – intraventricular compartment
presented with HEADACHES



Frontal and lateral left carotid angiogram

Frontal and lateral left vertebral angiogram

Feeders with fistulae characteristics:

- LEFT ANTERIOR CHOROIDAL
- LEFT LENTICULOSTRIATE
- LEFT P1 PERFURATING ARTERY
- LEFT AND RIGHT POSTERIOR CHOROIDALS

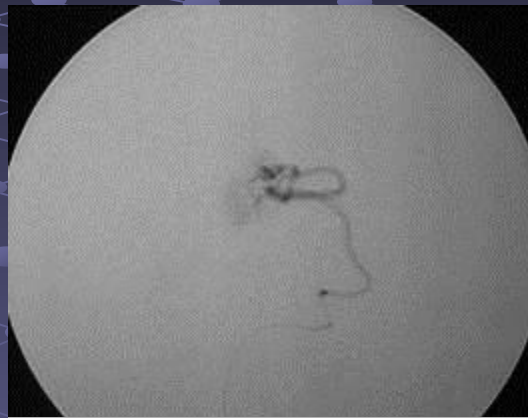Brain Arteriovenous Malformations

Endovascular Therapy and Associated Therapeutic Protocols

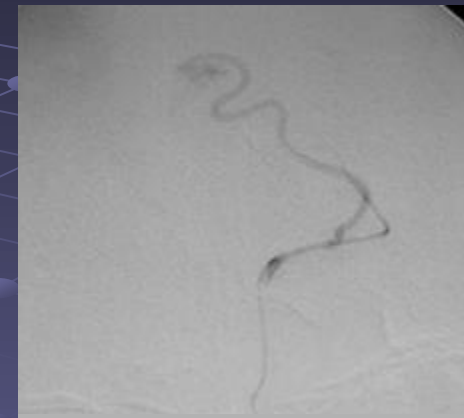Left deep AVM – intraventricular compartment
presented with HEADACHES



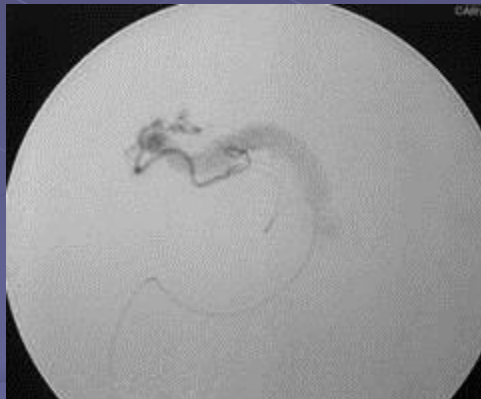Left lenticulostriate



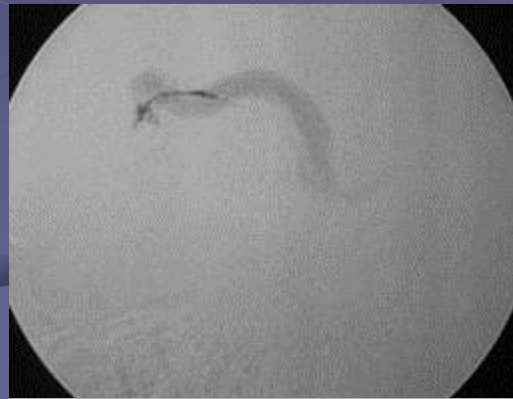Left posterior choroidal 1



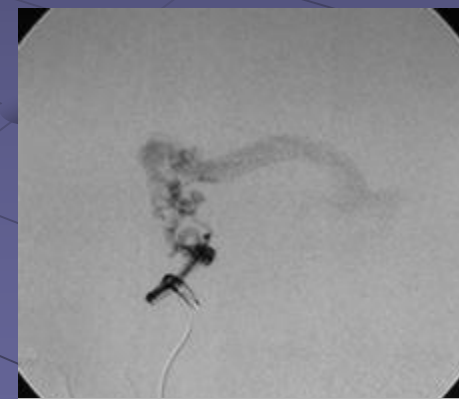Left anterior choroidal



Right posterior choroidal



Left posterior choroidal 2



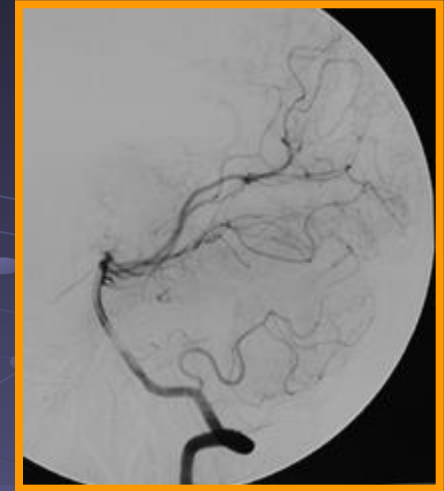
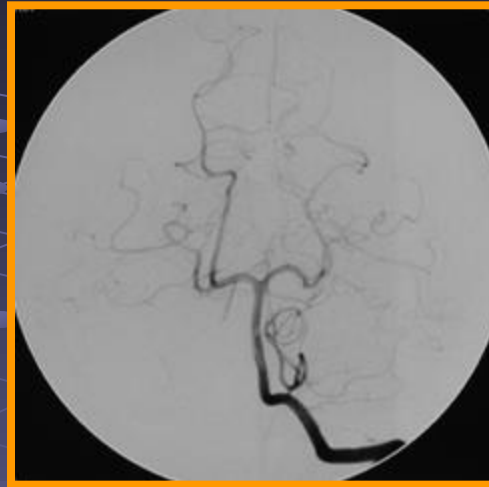
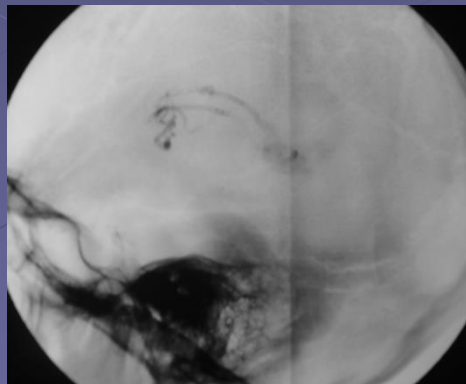
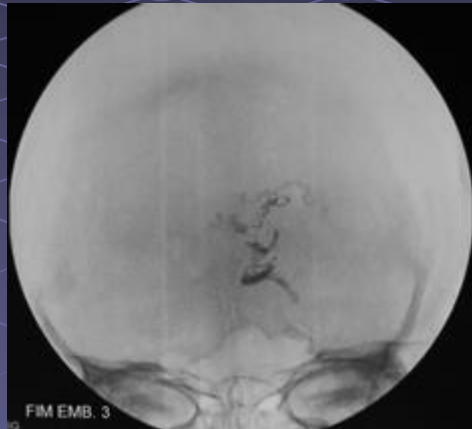Left P1

Brain Arteriovenous Malformations

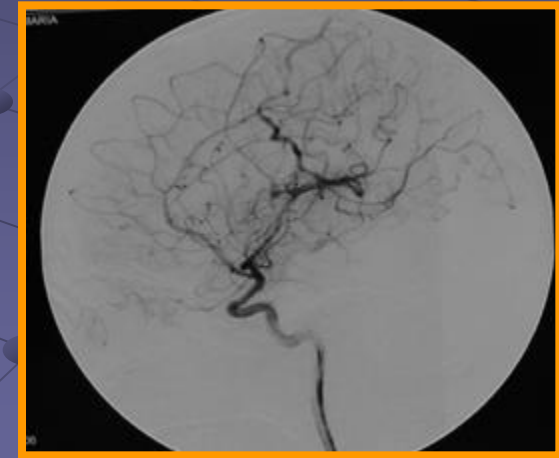
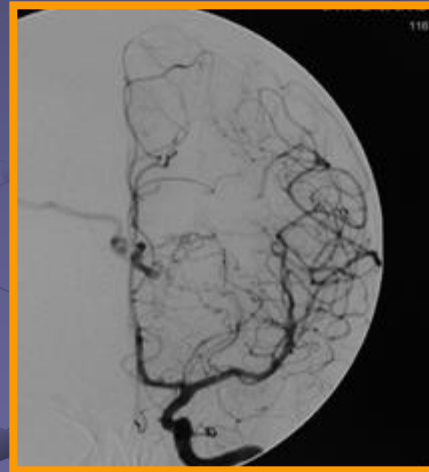
Endovascular Therapy and Associated Therapeutic Protocols

Left deep AVM – intraventricular compartment
presented with HEADACHES

G
L
U
B
R
A
N



Frontal and lateral left vertebral angiogram pos embolization



Frontal and lateral left carotid angiogram pos embolization

Brain Arteriovenous Malformations

Endovascular Therapy and Associated Therapeutic Protocols

TECHNICAL CONSIDERATIONS

- **General anesthesia**
- **Heparin 10 000 U i.v. bolus plus 1 000 U / hour**
- **Intranidal microcatheterism – ONYX/SQUID/PHIL**
- **Feeder artery microcatheterism or high flow fistulae – IBCA or GLUBRAN**
- **Post embolization – pharmacological medication – steroids, fraxiparine if venous thrombosis**
- **Surgery and Radiotherapy timing**

Brain Arteriovenous Malformations

Endovascular Therapy and Associated Therapeutic Protocols

THERAPEUTIC PROTOCOLS

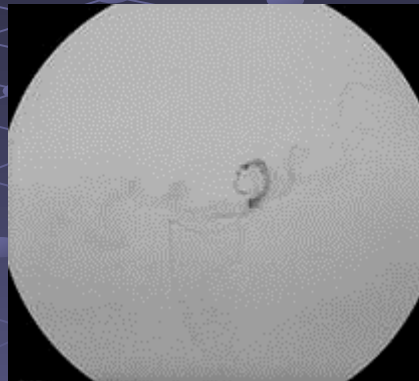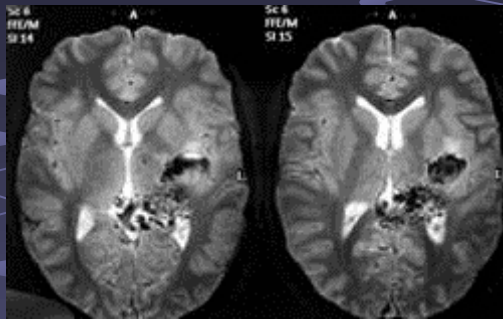
- **PALIAIVE INTRAARTERIAL EMBOLIZATION**
- **CURATIVE INTRAARTERIAL EMBOLIZATON**
- **PRE SURGICAL INTRAARTERIAL EMBOLIZATION**
- **PRE RADIOTHERAPY INTRAARTERIAL EMBOLIZATION**
- **PRE SURGICAL and PRE RADIOTHERAPY INTRAARTERIAL EMBOLIZATION**

Brain Arteriovenous Malformations

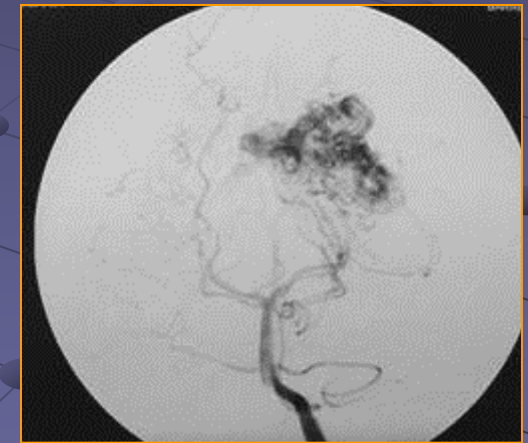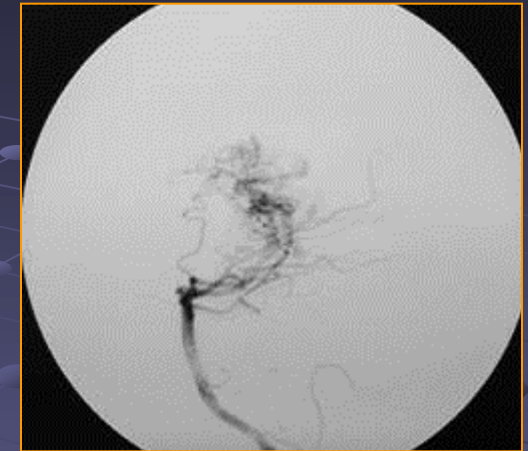Endovascular Therapy and Associated Therapeutic Protocols

Left deep AVM – ventricular / thalamus – presenting with deep left hematoma

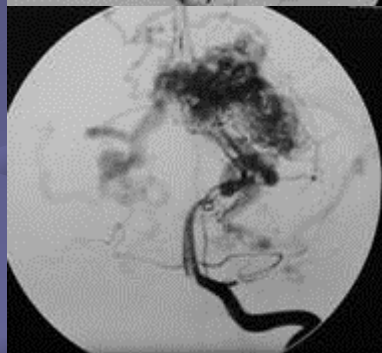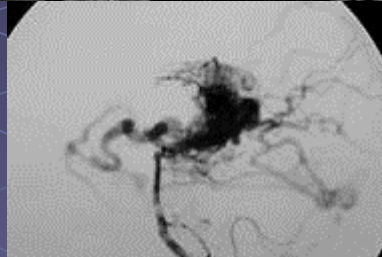
1st embolization - GLUBRAN



Posterior choroidal feeders



Frontal and lateral left vertebral artery angiogram pos embolization



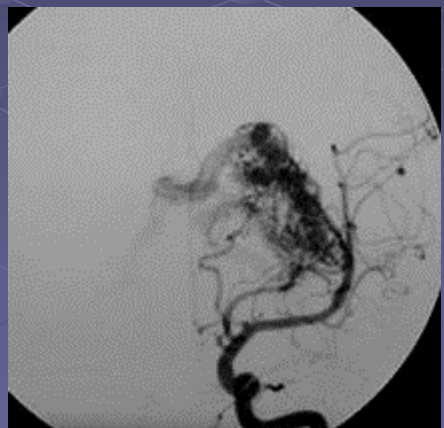
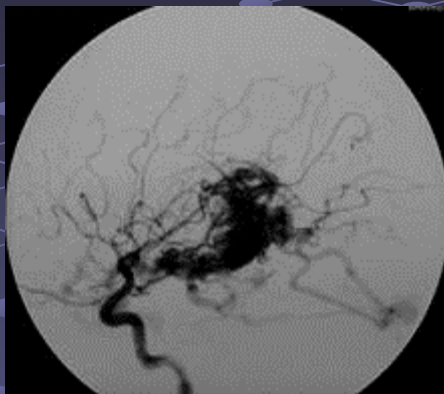
Frontal and lateral left vertebral artery angiogram pre-embolization

Brain Arteriovenous Malformations

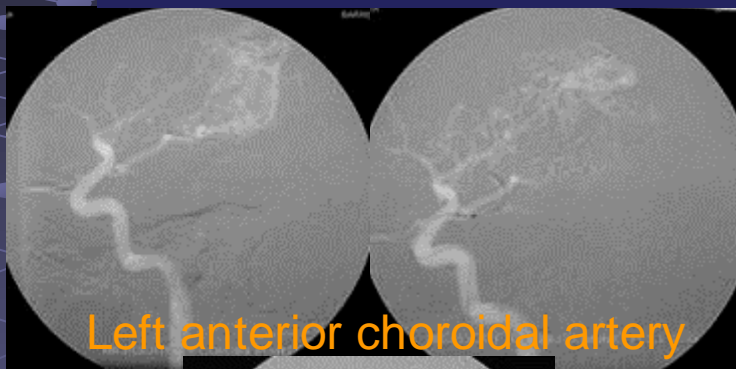Endovascular Therapy and Associated Therapeutic Protocols

Left deep AVM – ventricular / thalamus – presenting with deep left hematoma

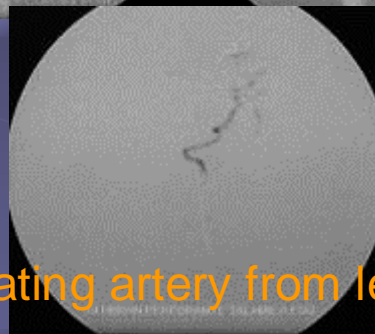
2nd embolization - GLUBRAN



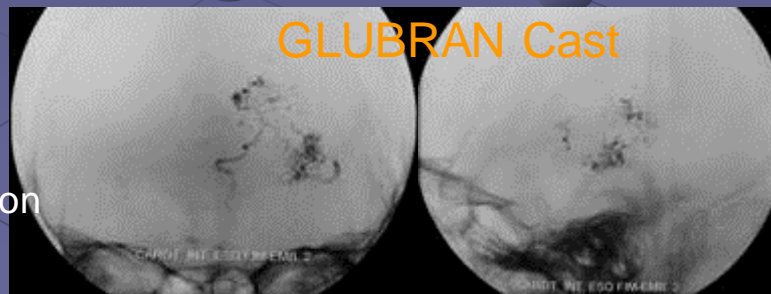
Frontal and lateral left carotid artery angiogram pre-embolization



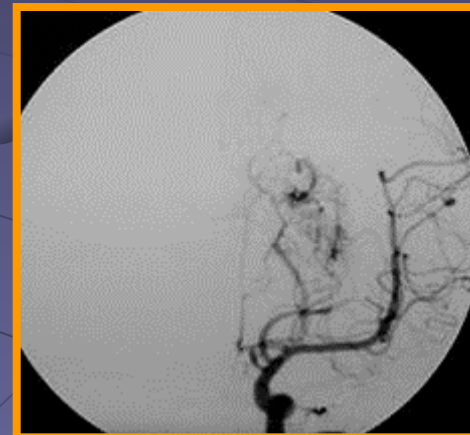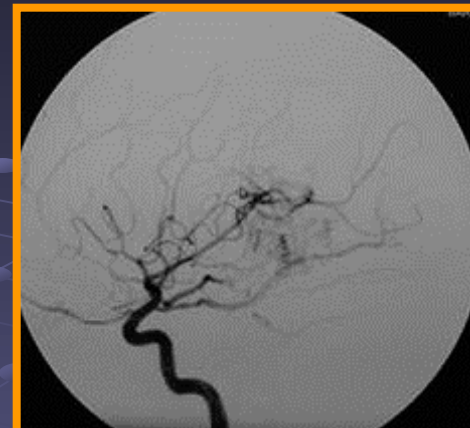Left anterior choroidal artery



Perforating artery from left Pcom



GLUBRAN Cast

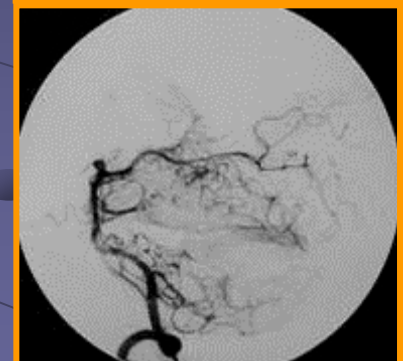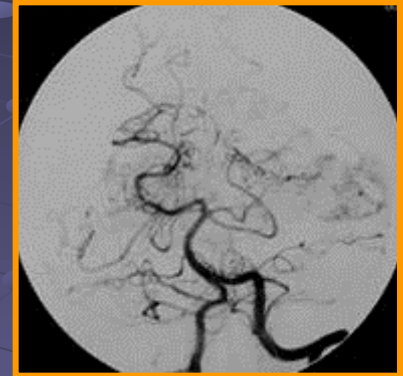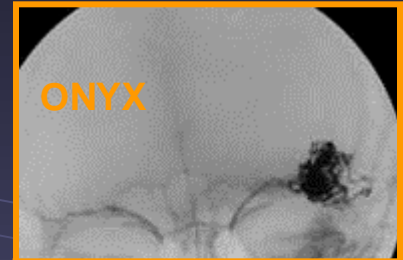
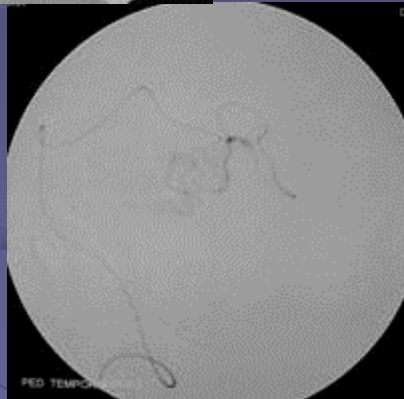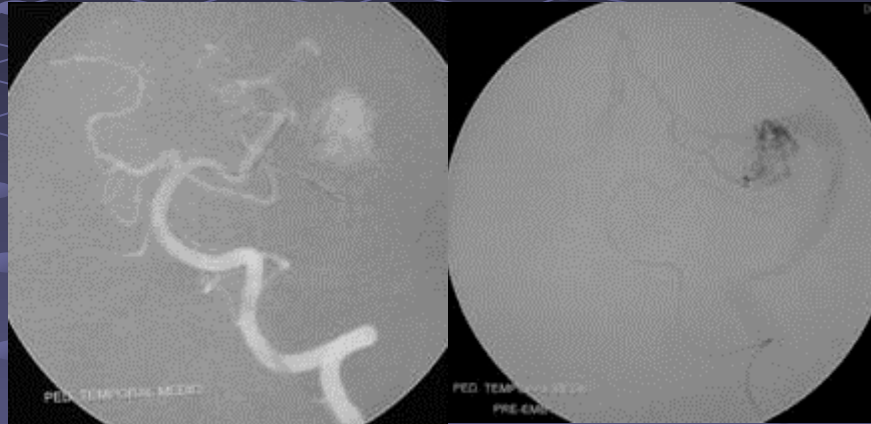
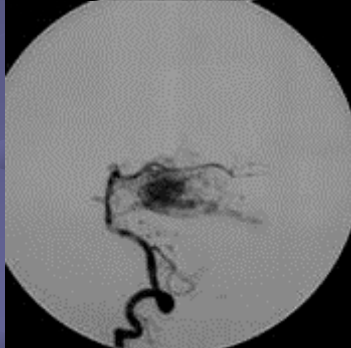
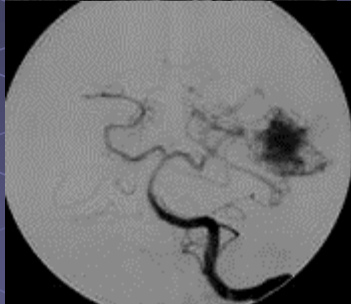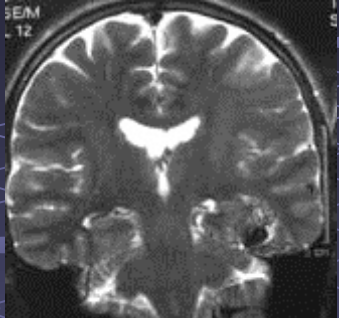


Frontal and lateral left carotid artery angiogram pos embolization

Brain Arteriovenous Malformations

Endovascular Therapy and Associated Therapeutic Protocols

Left inferior temporal AVM presenting with seizures



Frontal and lateral left vertebral artery angiogram pre-embolization

Feeders from left posterior cerebral artery – temporal branches

Frontal and lateral left vertebral artery angiogram pos embolization

Brain Arteriovenous Malformations

Endovascular Therapy and Associated Therapeutic Protocols

164 patients	
73 female	91 male
45%	55%

Age		
Up to 20	26	16%
21 up to 40	84	51%
41 up to 60	44	27%
61 up to 80	10	6%

Brain Arteriovenous Malformations

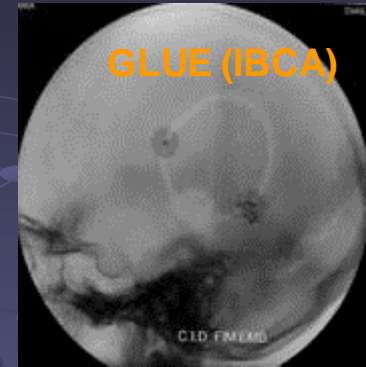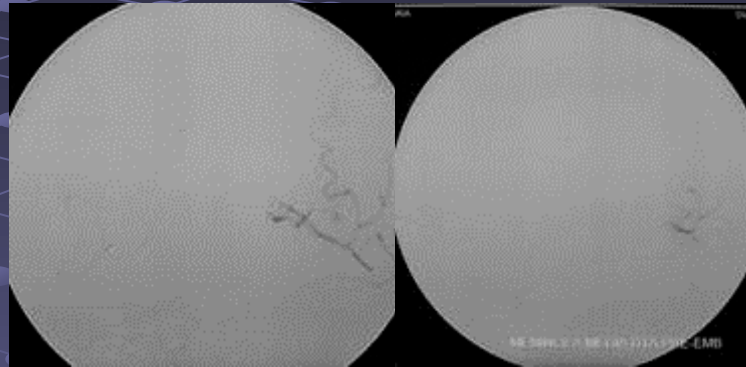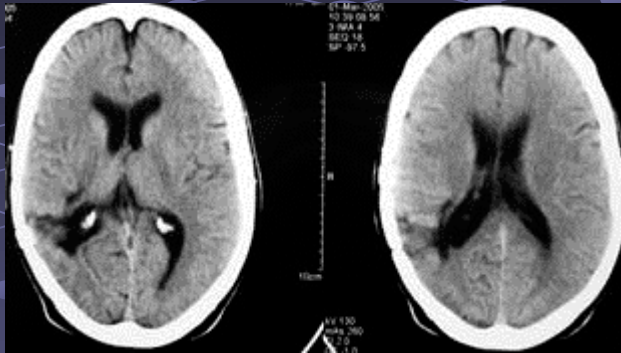
Endovascular Therapy and Associated Therapeutic Protocols

164 patients – Presenting symptoms		
Haemorrhage	77	47%
Seizures	62	38%
Progressive neurologic deficit	2	1%
Headache and Acidental	23	14%

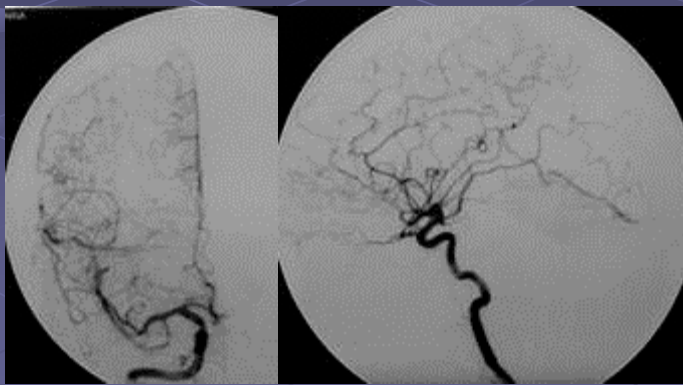
Brain Arteriovenous Malformations

Endovascular Therapy and Associated Therapeutic Protocols

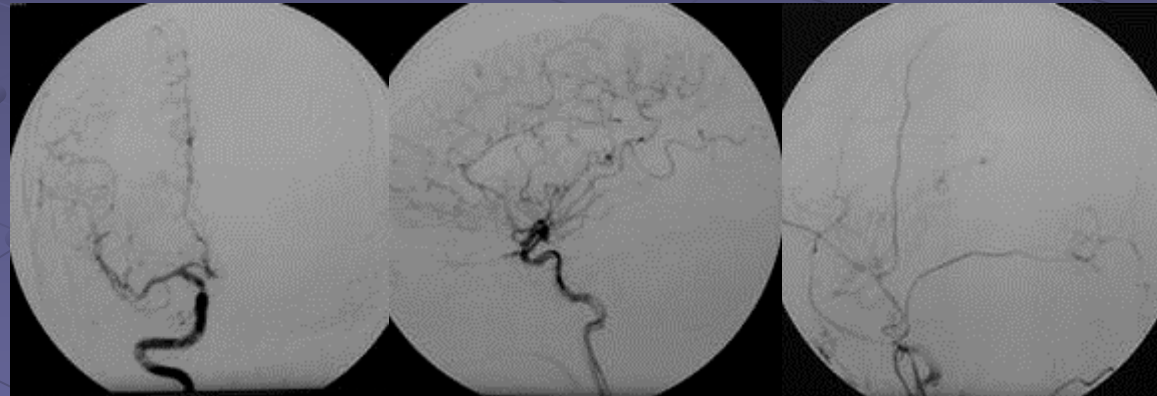
Right temporal AVM – pial fistulae presenting with temporal hematoma



Right anterior temporal and middle meningeal arteries



Frontal and lateral carotid artery angiogram pre-embolization



Frontal and lateral carotid artery angiogram pos-embolization

External carotid pos embolization

Brain Arteriovenous Malformations

Endovascular Therapy and Associated Therapeutic Protocols

AVM Localization		164 patients	
Frontal	31	19%	Right 8 Left 23
Parietal	40	24%	Right 20 Left 20
Temporal	47	29%	Right 21 Left 20
Occipital	15	9%	Right 4 Left 6
Corpus callosum	4	2%	
Basal ganglia	7	4%	
Cerebellum	20	13%	

Brain Arteriovenous Malformations

Endovascular Therapy and Associated Therapeutic Protocols

First Therapeutic Strategy	164 patients	
Pre operative embolization	44	27%
Pre radiosurgery embolization	61	37%
Pre operative and radiosurgery embolization	7	4%
Curative embolization	37	23%
Partial targeted embolization (palliative)	15	9%

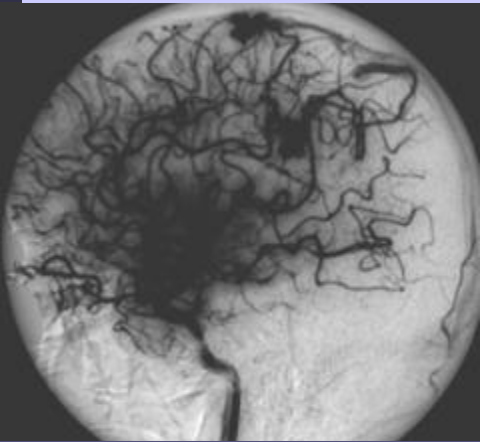
16 patients remain in treatment or waiting follow-up angiogram (10%)
8 patients lost for follow-up (5%)

Brain Arteriovenous Malformations

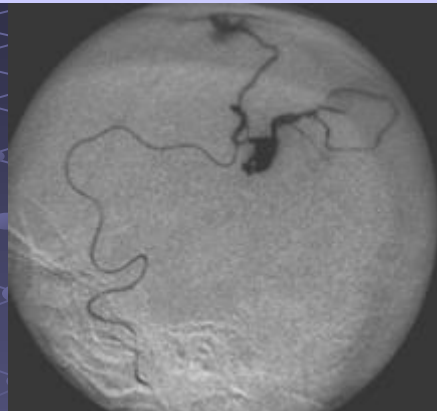
Endovascular Therapy and Associated Therapeutic Protocols

Right parietal AVM presented with hemorrhage

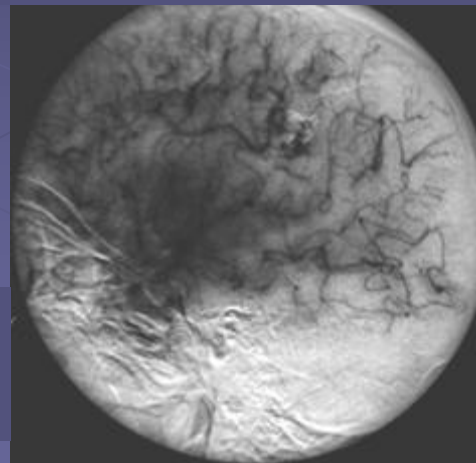
CURATIVE EMBOLIZATION - CYANOCRILATE



Lateral right carotid artery angiogram pre-embolization

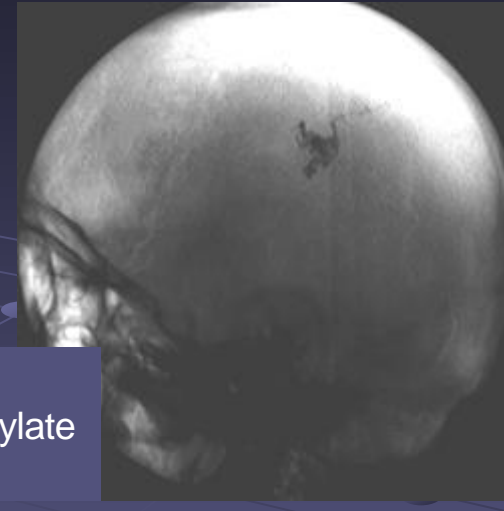


Microcatheterism of the nidus

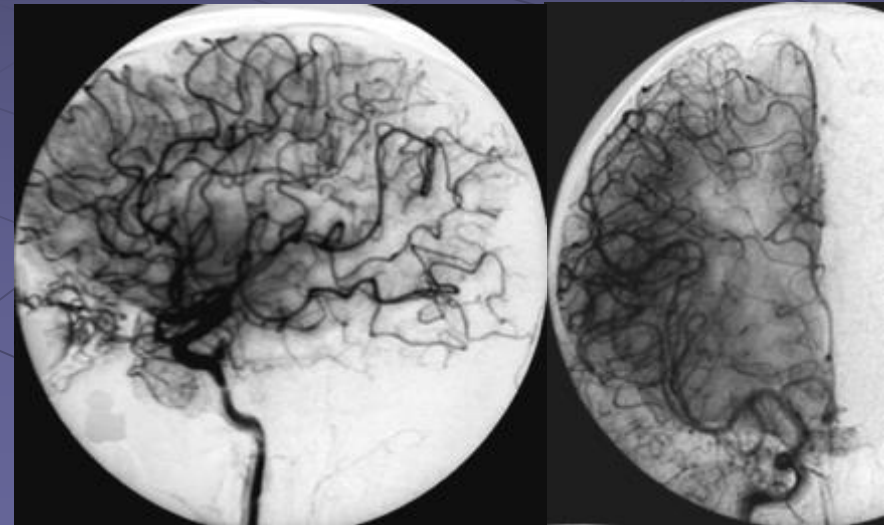


Lateral right carotid artery angiograms post-embolization (glue)

Lateral X-Ray without subtraction - cyanocrylate cast



Follow-up right and frontal carotid artery angiogram five years post-embolization and radiosurgery



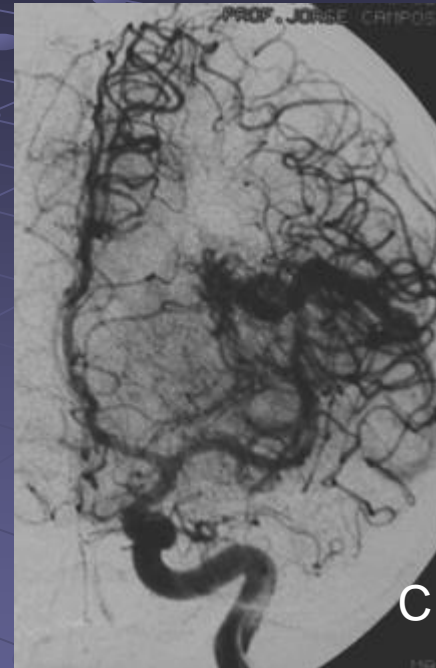
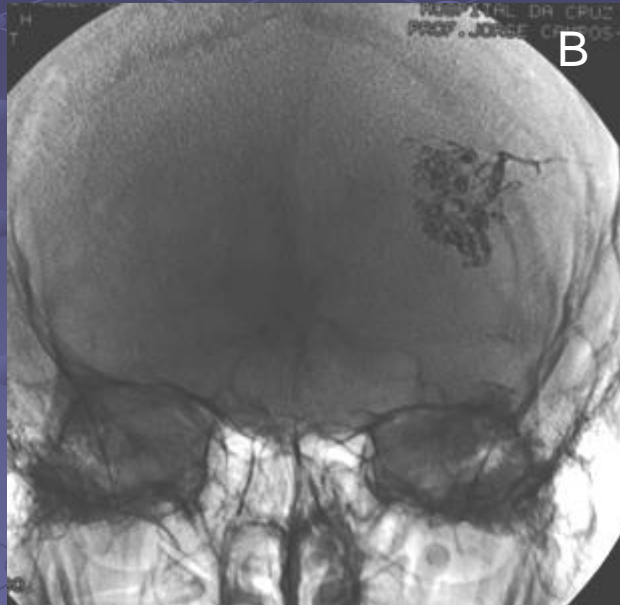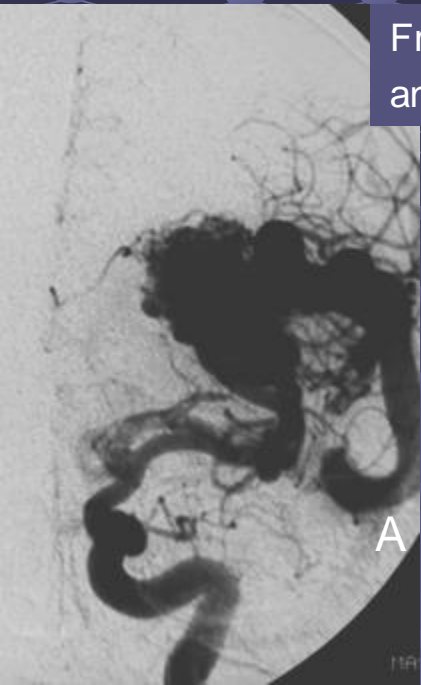
Brain Arteriovenous Malformations

Endovascular Therapy and Associated Therapeutic Protocols

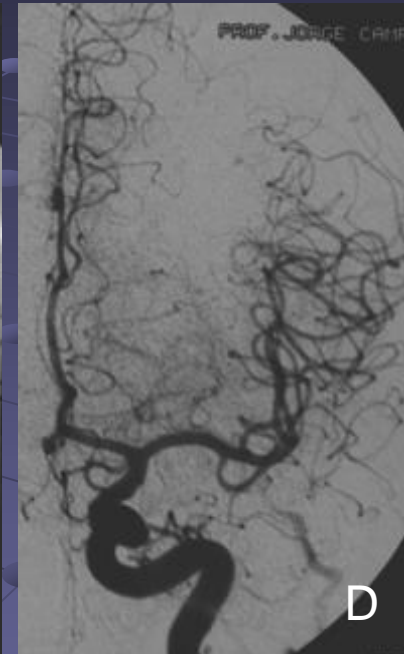
Left parietal / temporal AVM with seizures

PRE RADIOSURGERY EMBOLIZATION - CYANOCRILATE

Frontal left carotid artery angiogram pre-embolization



Frontal left carotid artery angiogram post-embolization (glue)



Follow-up left carotid artery angiogram three years post-embolization and radiosurgery

Frontal X-Ray without subtraction – cyanocrylate cast

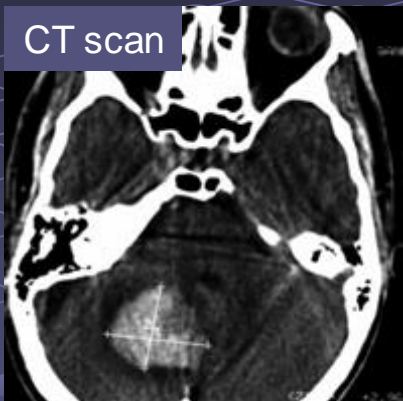
Brain Arteriovenous Malformations

Endovascular Therapy and Associated Therapeutic Protocols

Right cerebellum AVM presented with hemorrhage

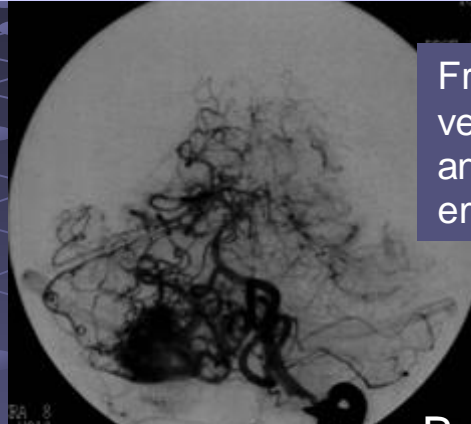
PRE SURGERY EMBOLIZATION - CYANOCRILATE

CT scan



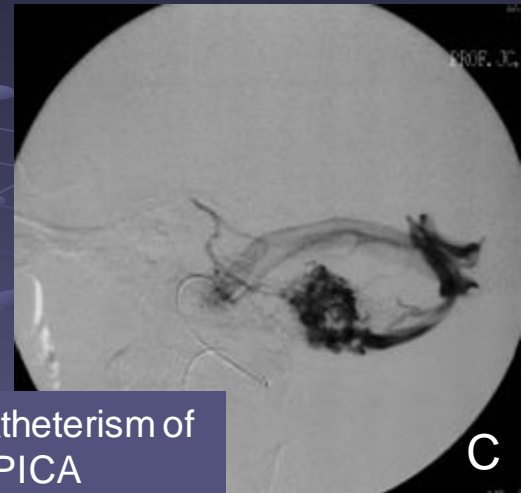A

Frontal left vertebral artery angiogram pre-embolization



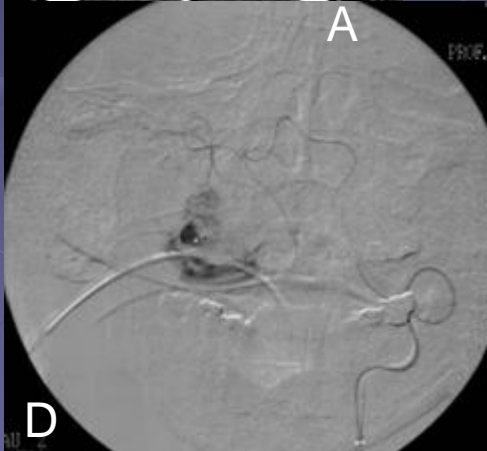B

Microcatheterism of the left PICA

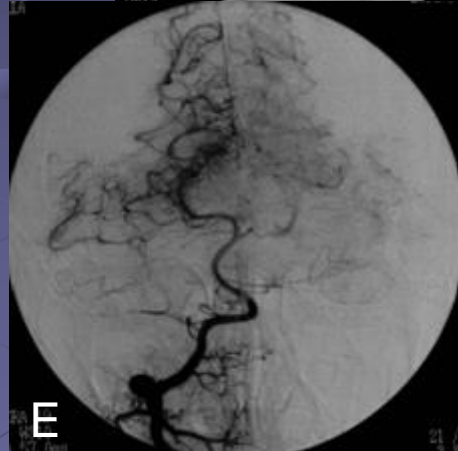

C

Frontal left vertebral artery angiogram post-embolization (glue) and surgery

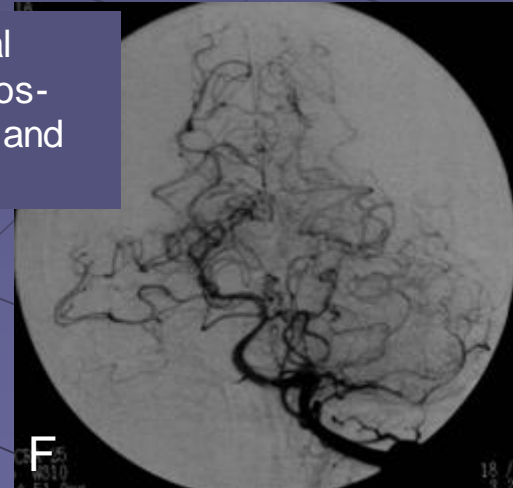


D



E

Frontal right vertebral artery angiogram post-embolization (glue) and surgery



F

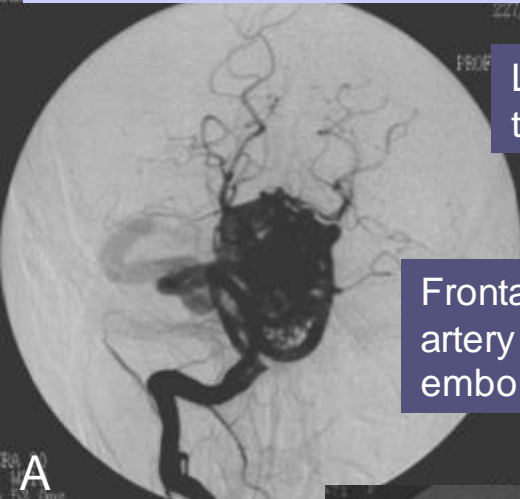
Microcatheterism of the right AICA – shows a small intranidal aneurism

Brain Arteriovenous Malformations

Endovascular Therapy and Associated Therapeutic Protocols

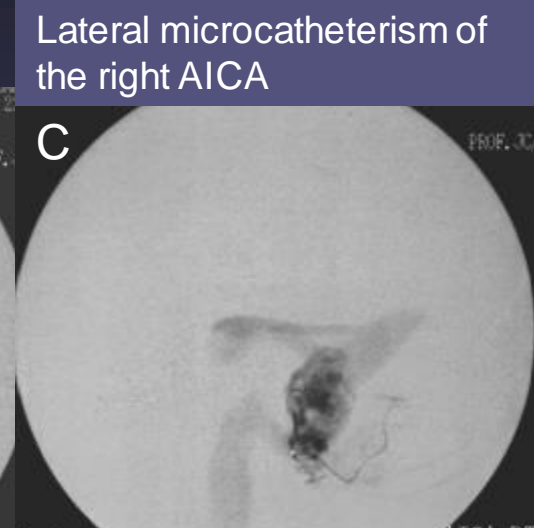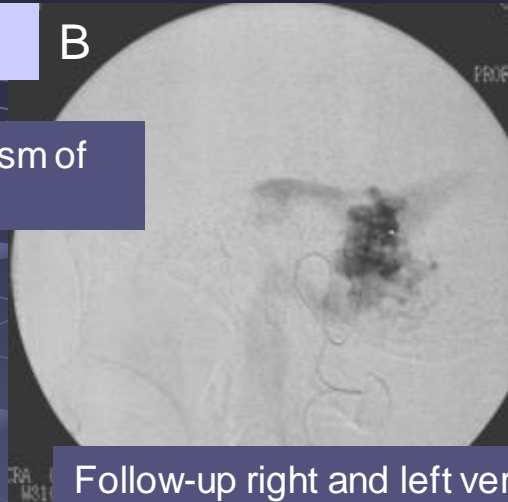
Vermian AVM presented with headache

CURATIVE EMBOLIZATION - ONYX



Lateral microcatheterism of the right PICA

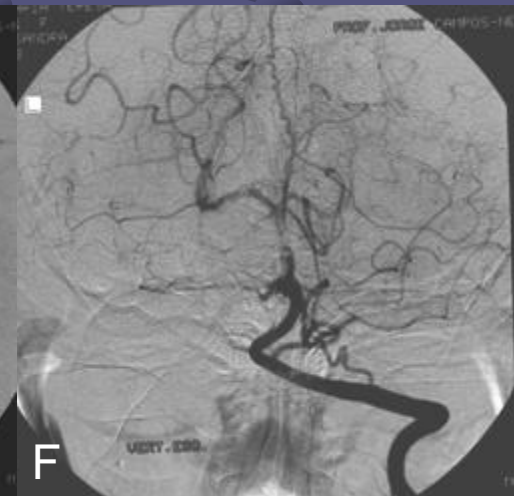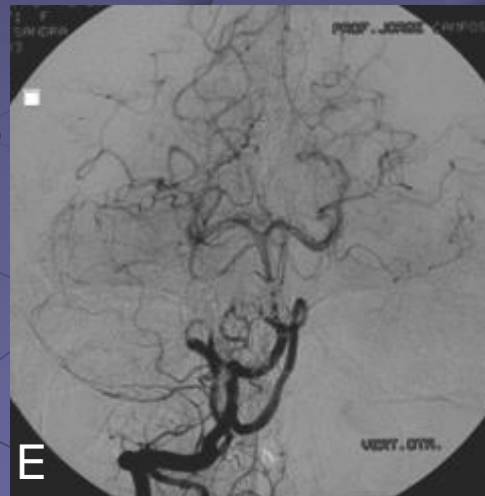
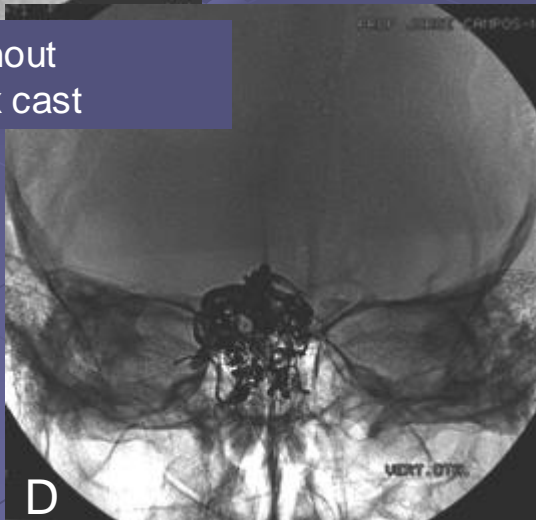
Frontal right vertebral artery angiogram pre-embolization



Lateral microcatheterism of the right AICA

Follow-up right and left vertebral artery angiograms one year pos-embolization (onyx)

Frontal X-Ray without subtraction – onyx cast



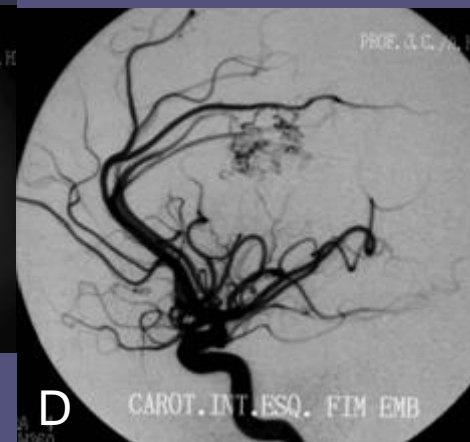
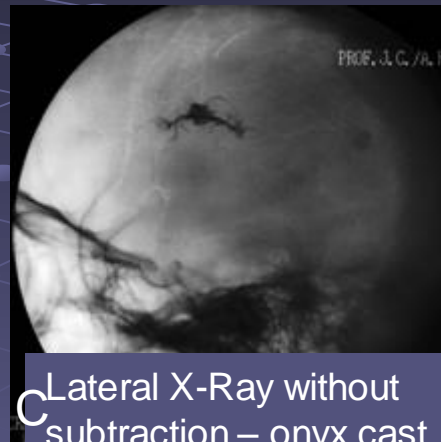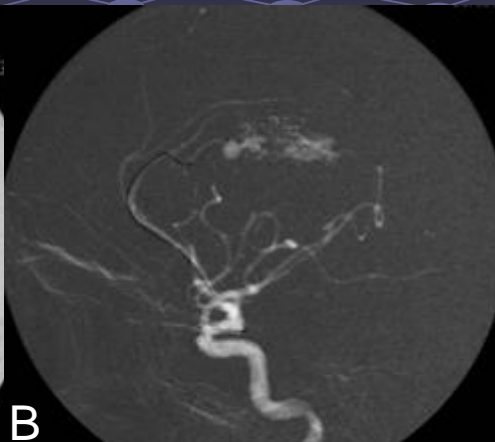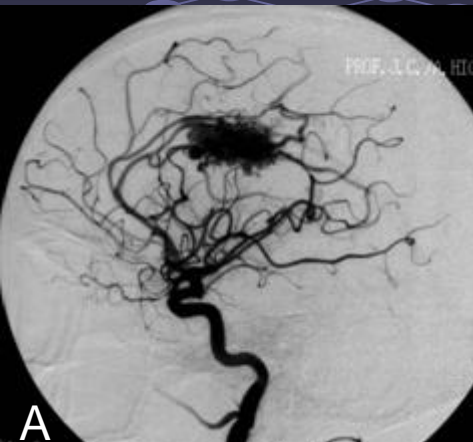Brain Arteriovenous Malformations

Endovascular Therapy and Associated Therapeutic Protocols

Left frontal AVM presented with hemorrhage

PRE-SURGERY EMBOLIZATION - ONYX

Lateral left carotid artery angiogram pos-embolization (onyx)



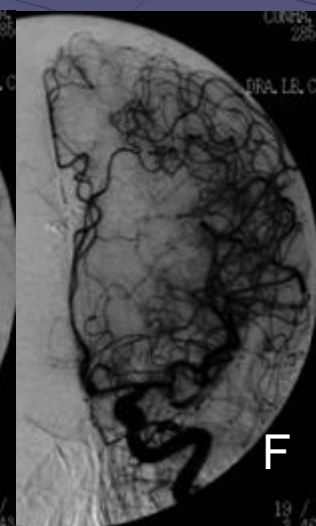
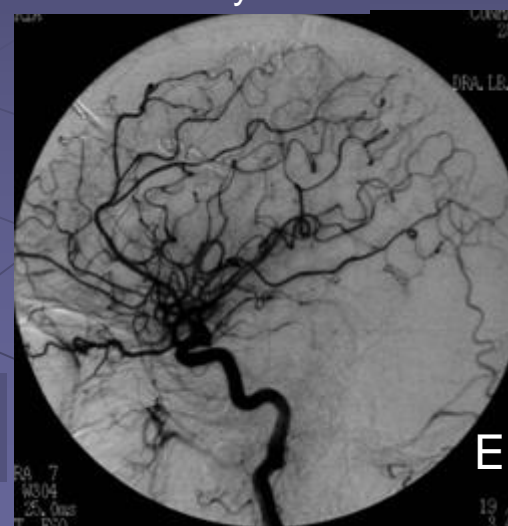A Lateral left carotid artery angiogram pre-embolization

B Microcatheterism of the nidus – shows a proximal aneurysm in the feeder artery

C Lateral X-Ray without subtraction – onyx cast

D Lateral left carotid artery angiogram pos-embolization (onyx)

E Lateral and frontal left carotid artery angiograms pos-embolization and surgery



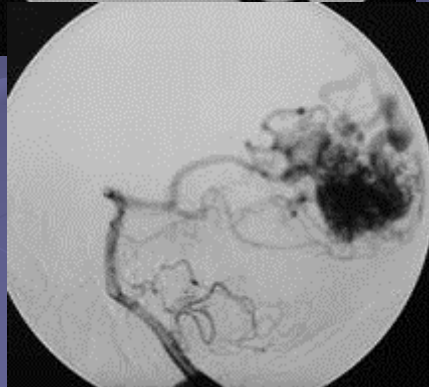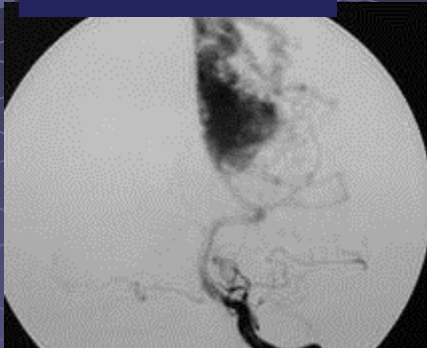
Brain Arteriovenous Malformations

Endovascular Therapy and Associated Therapeutic Protocols

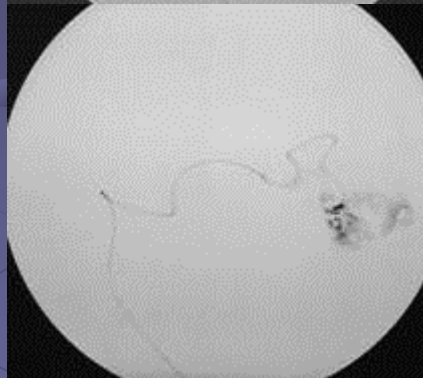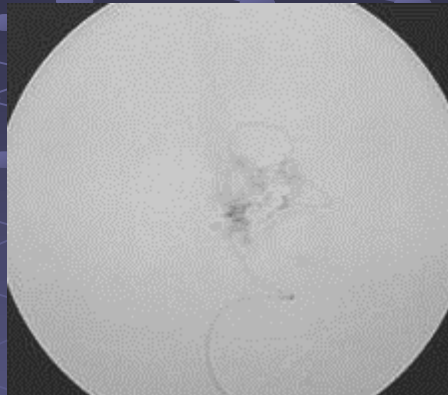
Left occipital AVM presenting with seizures

PRE-SURGERY EMBOLIZATION - ONYX

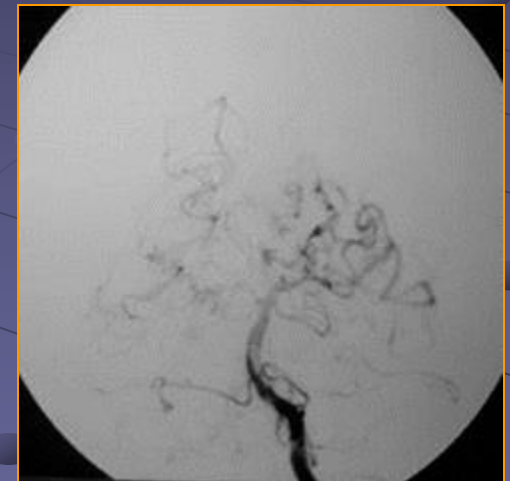
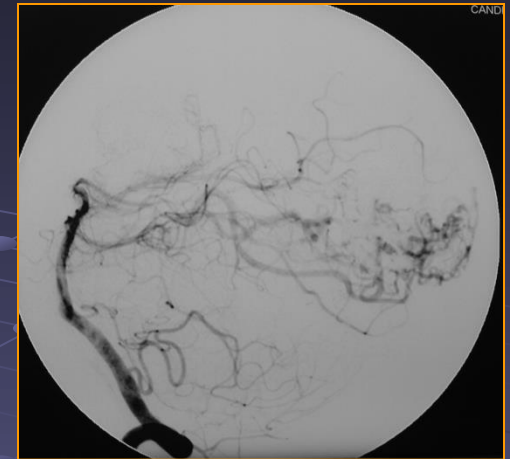
Embolization



Frontal and lateral left vertebral angiogram



Left occipital and parieto-occipital feeders



Onyx – exclusion > 90%

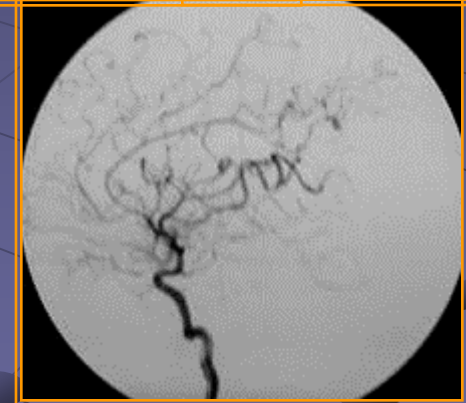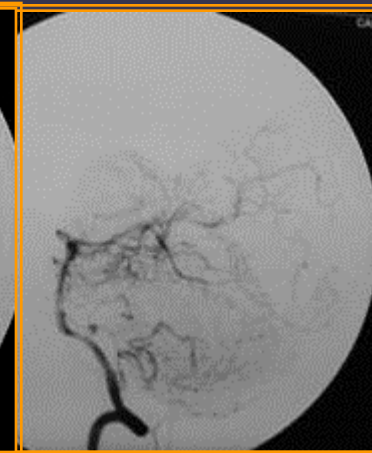
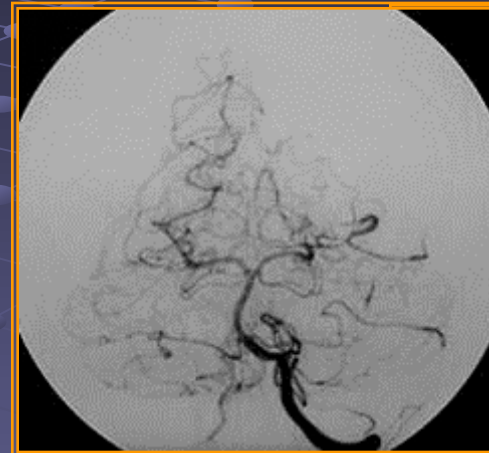
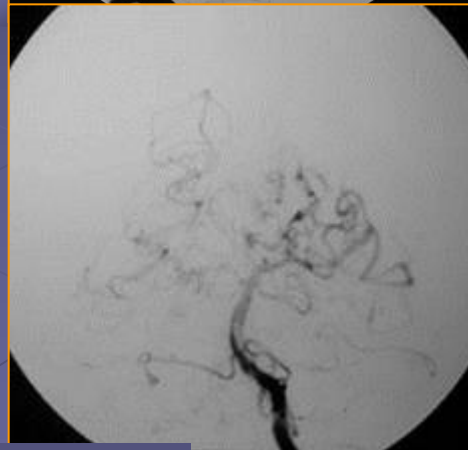
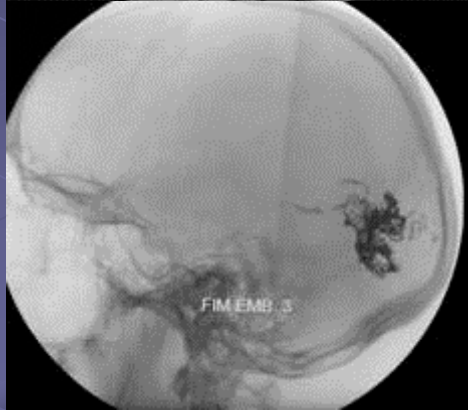
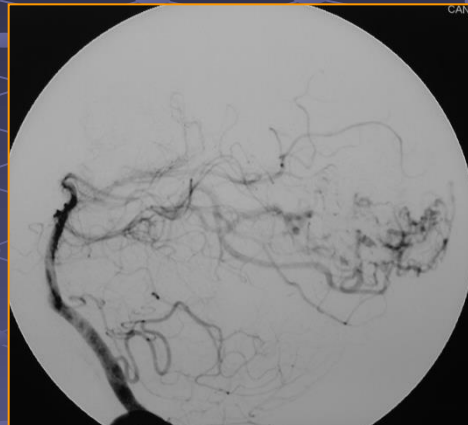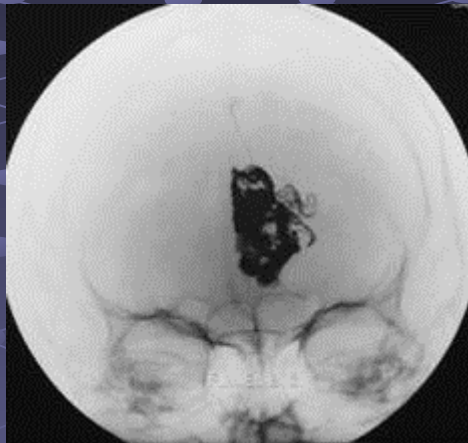Brain Arteriovenous Malformations

Endovascular Therapy and Associated Therapeutic Protocols

Left occipital AVM presenting with seizures

PRE-SURGERY EMBOLIZATION - ONYX

Surgery



Onyx – exclusion > 90%

Surgery – complete exclusion

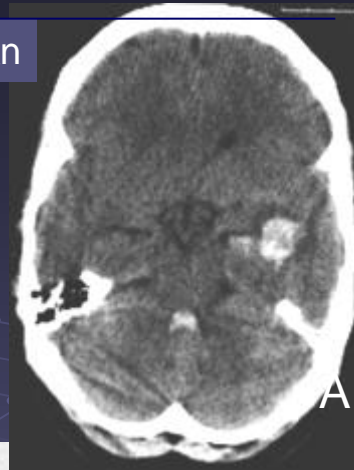
Brain Arteriovenous Malformations

Endovascular Therapy and Associated Therapeutic Protocols

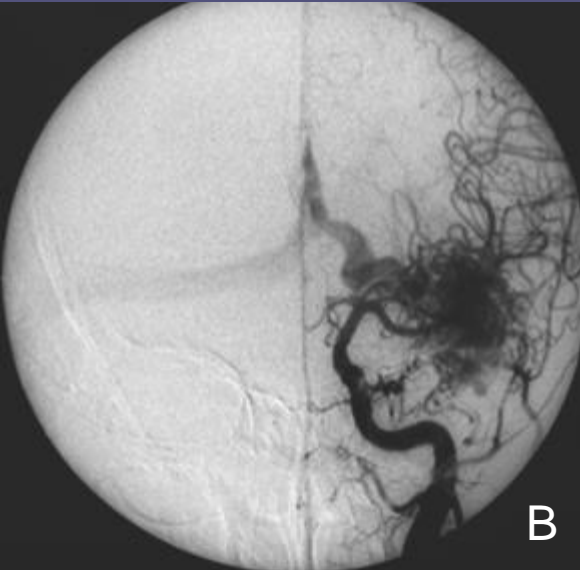
Left temporal AVM presented with hemorrhage

EMBOLIZATION + SURGERY + RADIOSURGERY
CYANOCRILATE

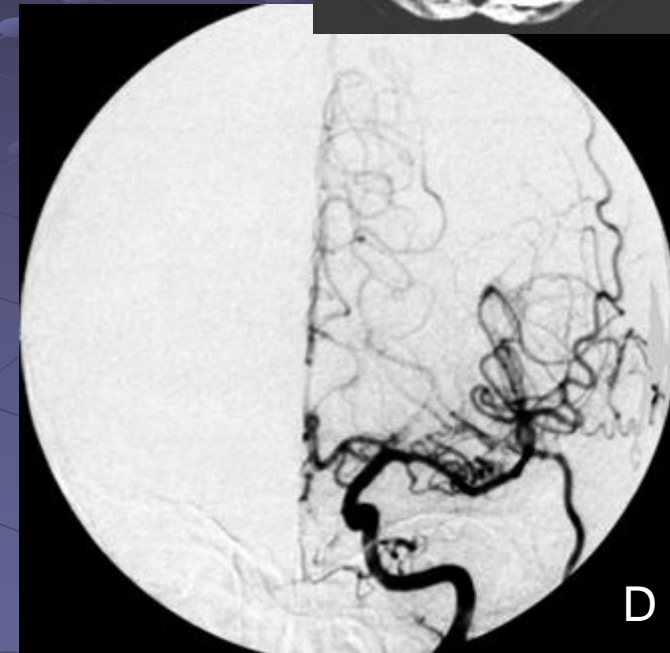
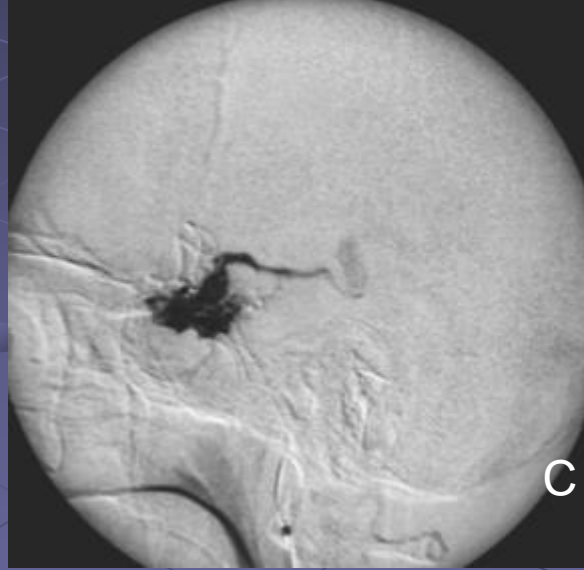
CT scan



Frontal left carotid artery
angiogram pre-embolization



Microcatheterism of the left
anterior temporal artery.



Follow-up left carotid artery angiogram six years post-embolization (glue), surgery and radiosurgery

Brain Arteriovenous Malformations

Endovascular Therapy and Associated Therapeutic Protocols

Intraarterial embolization – embolic material

164 patients

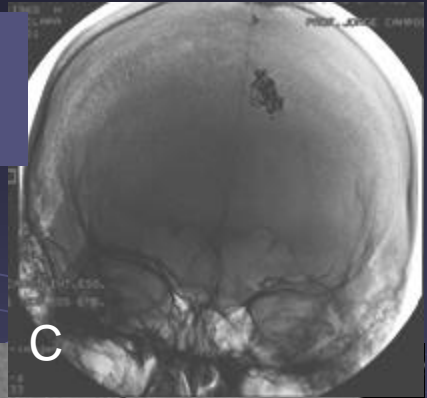
GLUE	113 cases	69 %
Ethylene-vinyl alcohol copolymer – ONYX/SQUID	35 cases	21 %
GLUE + ONYX/SQUID	16 cases	10 %

Brain Arteriovenous Malformations

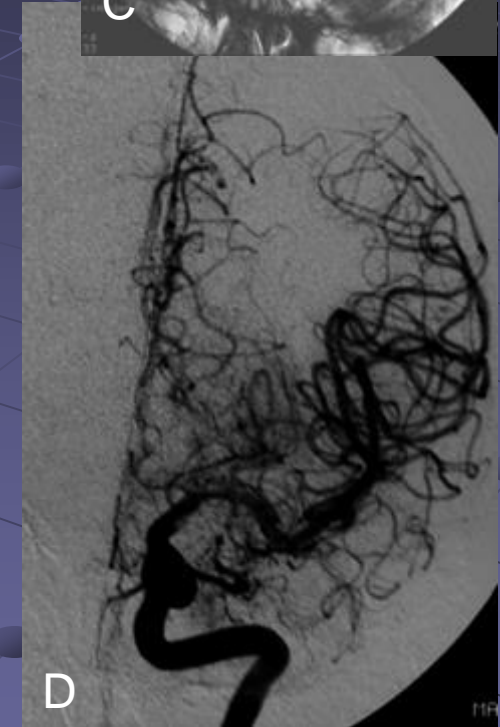
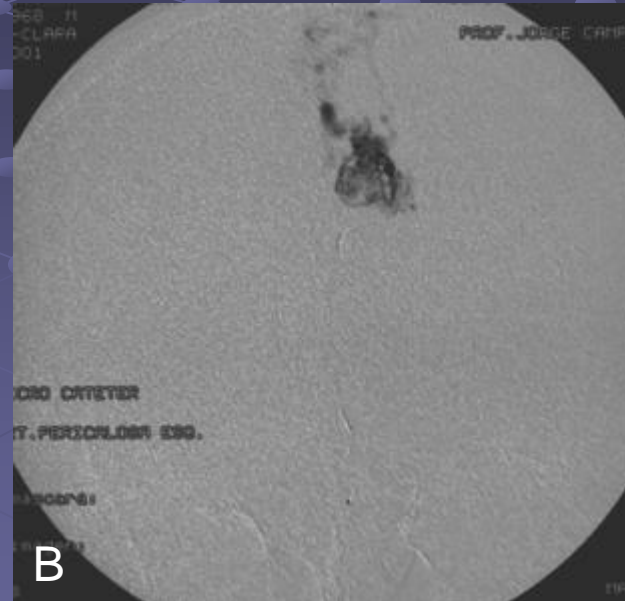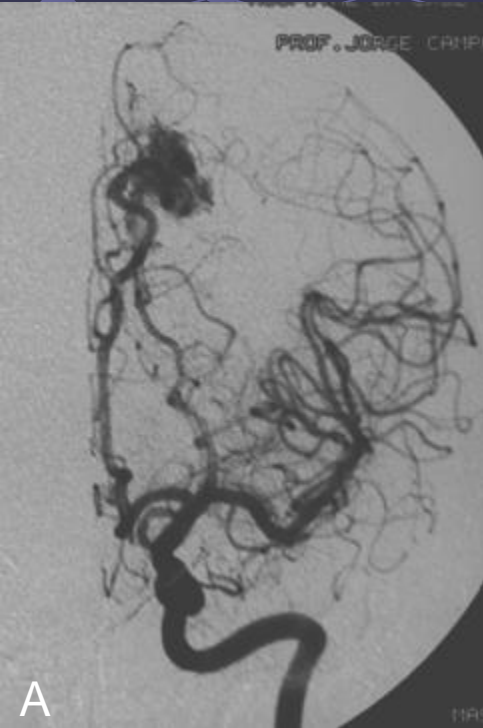
Endovascular Therapy and Associated Therapeutic Protocols

Left parietal AVM presented with seizures

Frontal X-Ray without subtraction – cyanocrylate cast



**CURATIVE EMBOLIZATION
CYANOCRILATE**



Frontal left carotid artery angiogram pre-embolization

Microcatheterism of the nidus – frontal view

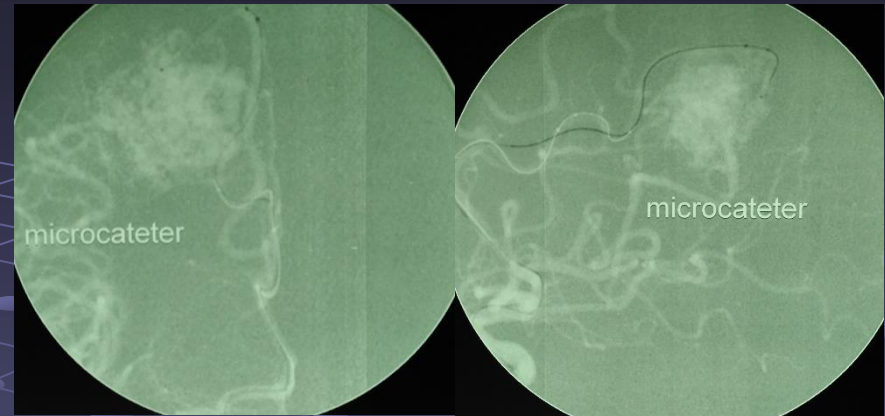
Follow-up left carotid artery angiogram, one month post-embolization (glue)

Brain Arteriovenous Malformations

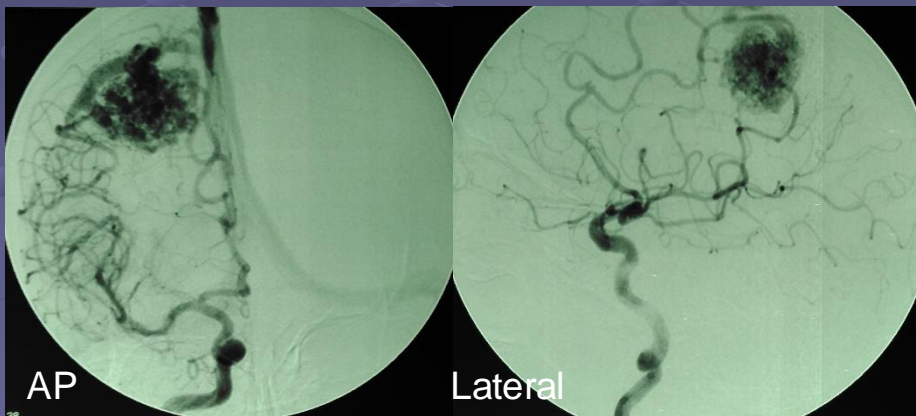
Endovascular Therapy and Associated Therapeutic Protocols

Male, 49
Epilepsy
Right Internal
Parietal AVM

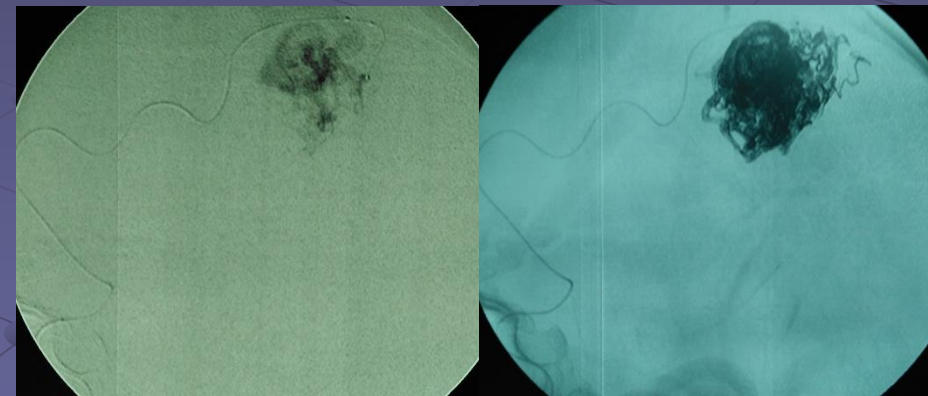
**CURATIVE INTRANIDAL
ONYX EMBOLIZATION**



Microcatheterization right A2 – Parietal feeder



Right Carotid Angiograms



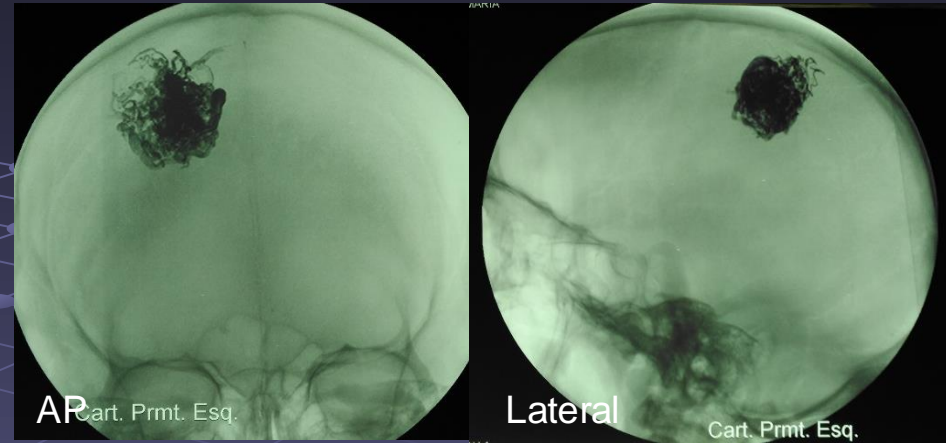
Intranidal angiography – Onyx cast

Brain Arteriovenous Malformations

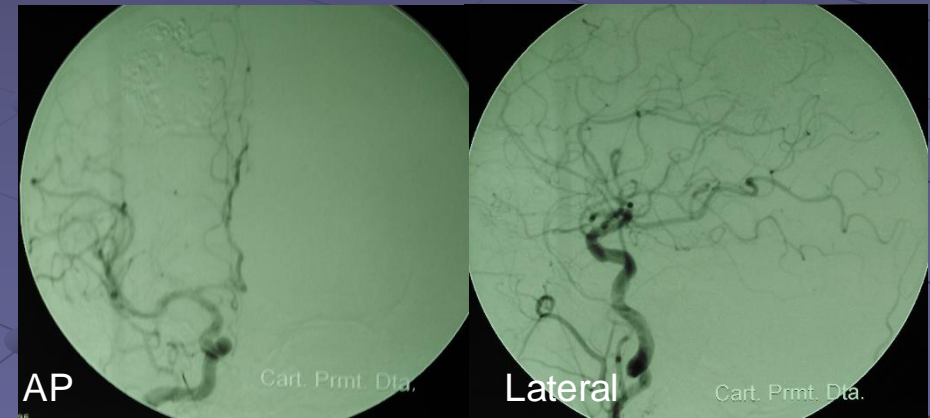
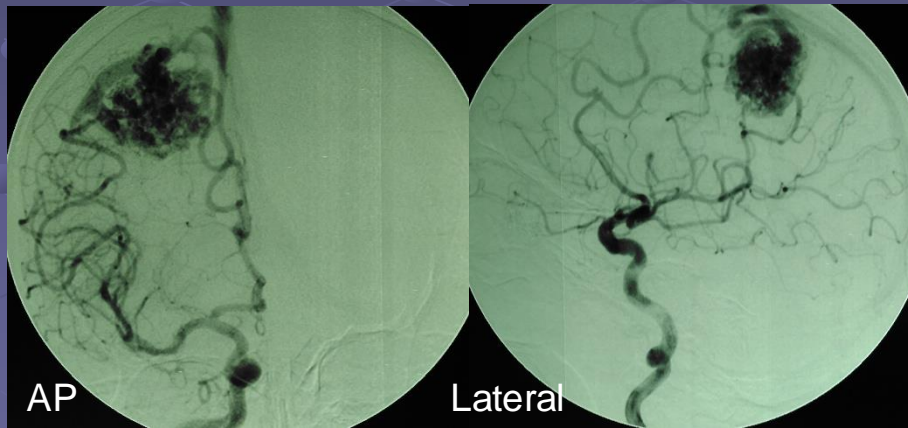
Endovascular Therapy and Associated Therapeutic Protocols

Male 49
Epilepsy
Right Internal
parietal AVM

**CURATIVE INTRANIDAL
ONYX EMBOLIZATION**



Onyx Cast



9 months follow-up

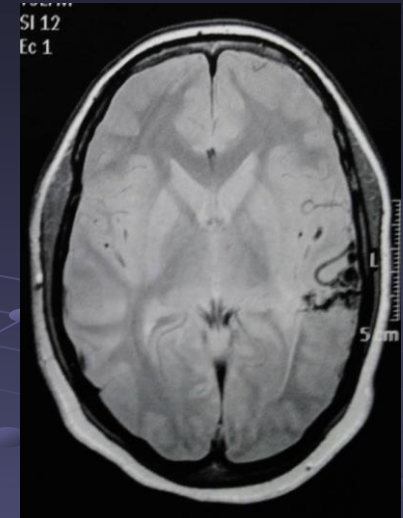
Right carotid artery
angiogram
Preembolization

Brain Arteriovenous Malformations

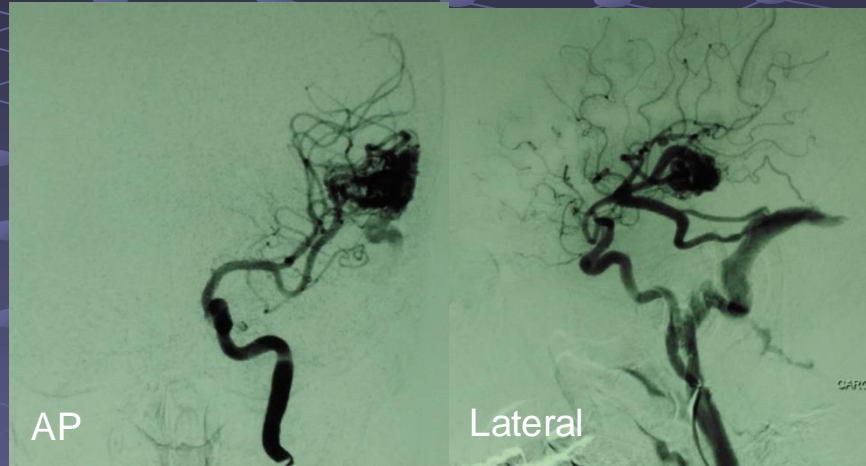
Endovascular Therapy and Associated Therapeutic Protocols

Female, 43
Epilepsy
Left temporal AVM

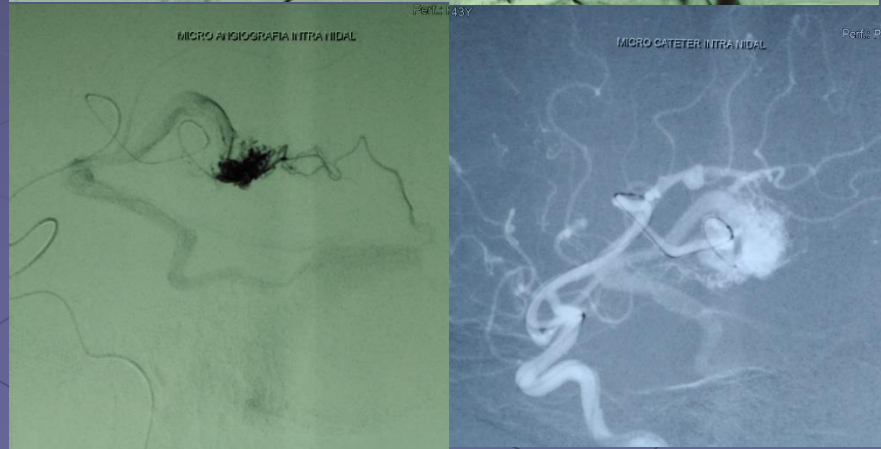CURATIVE INTRANIDAL SQUID EMBOLIZATION



Left carotid artery
angiogram



Intranidal
microcatheterization

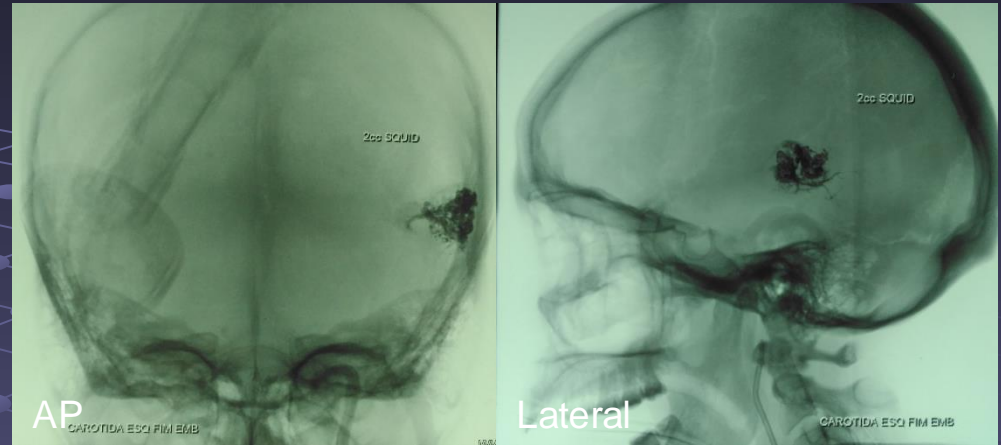


Brain Arteriovenous Malformations

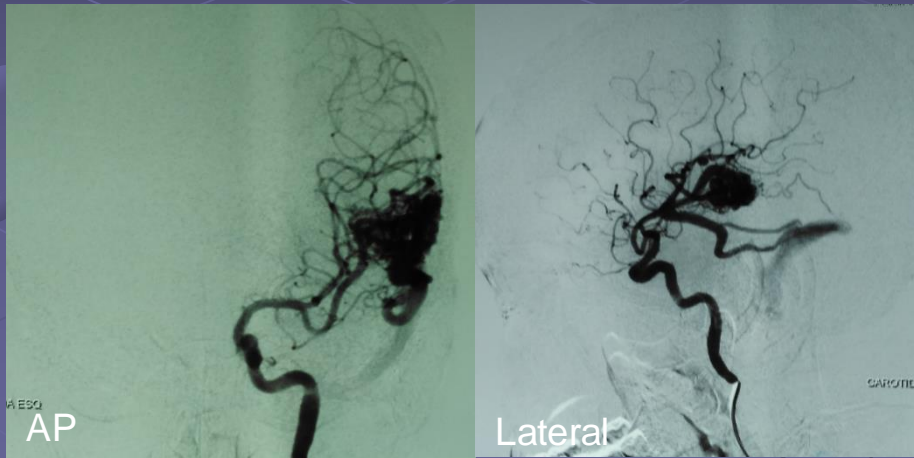
Endovascular Therapy and Associated Therapeutic Protocols

Female, 43
Epilepsy
Left Temporal AVM

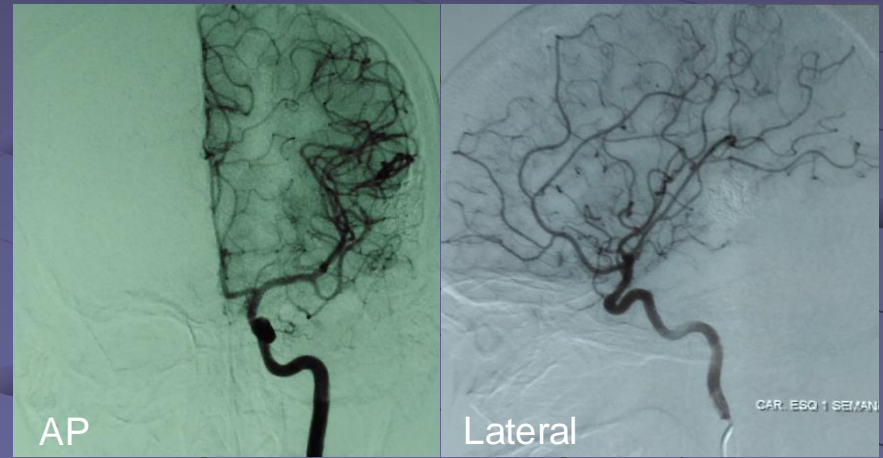
**CURATIVE INTRANIDAL
SQUID EMBOLIZATION**



Squid cast



Left carotid artery angiogram
Pre Embolization



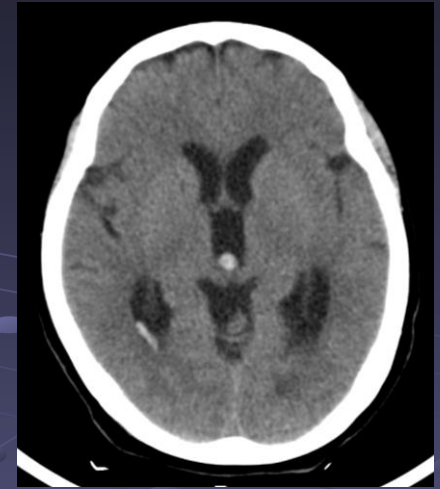Left carotid artery angiogram
One week Pos Embolization

Brain Arteriovenous Malformations

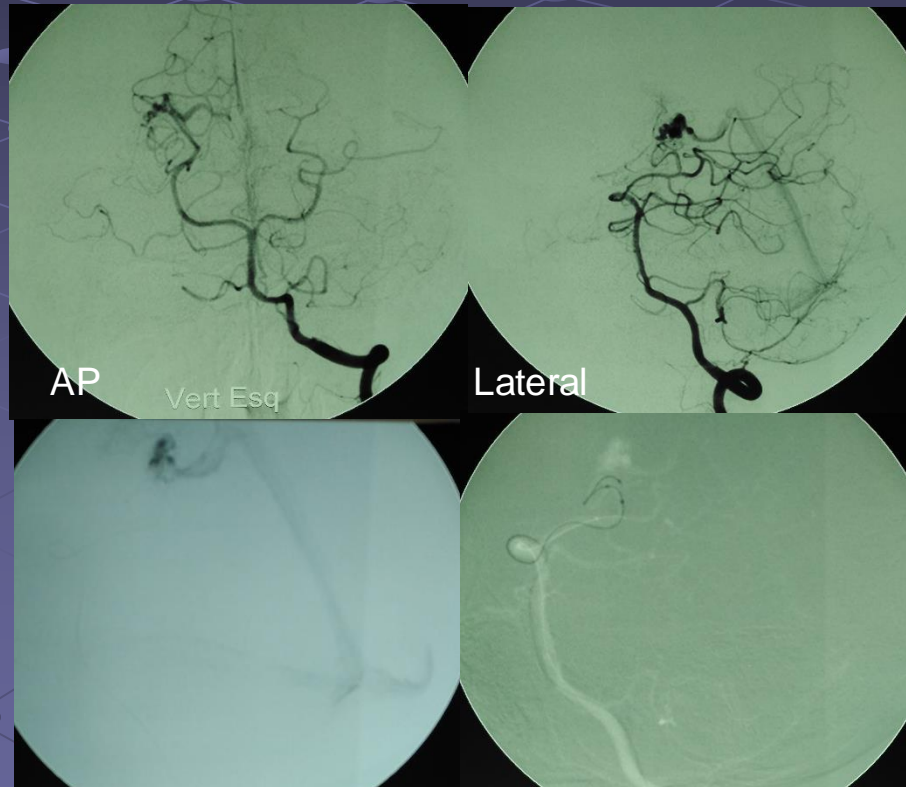
Endovascular Therapy and Associated Therapeutic Protocols

Female, 55
Intraventricular
Hemorrhage
Right Lateral
Ventricle AVM

**CURATIVE INTRANIDAL
SQUID EMBOLIZATION**



Left vertebral artery
angiogram



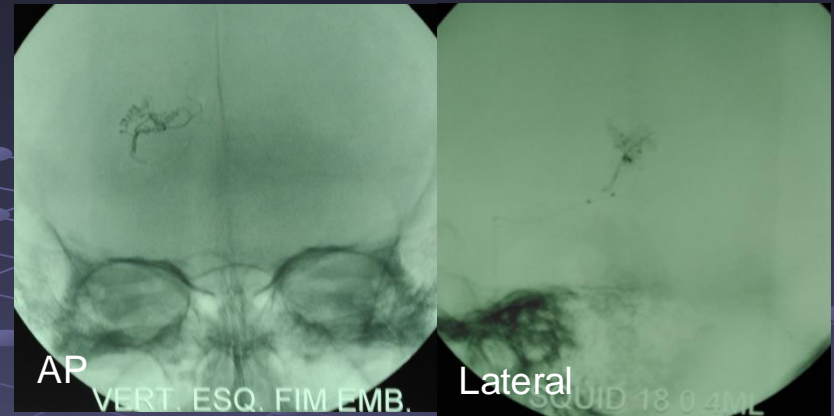
Microcatheterization
Right posterior lateral
choroid artery

Brain Arteriovenous Malformations

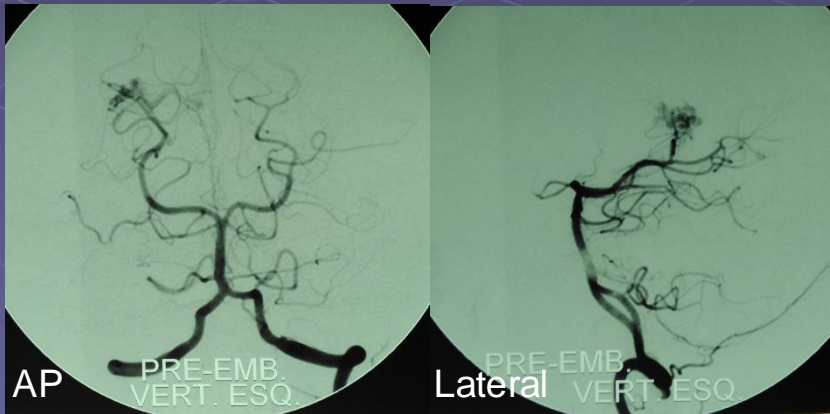
Endovascular Therapy and Associated Therapeutic Protocols

Female, 55
Intraventricular Hemorrhage
Right Lateral Ventricle AVM

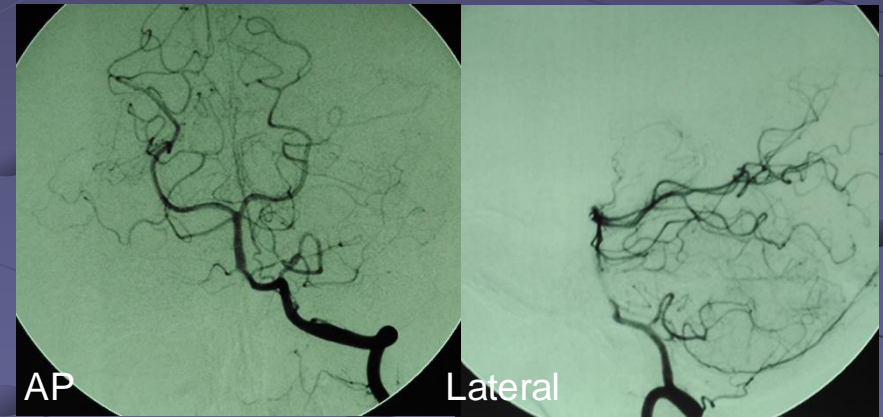
**CURATIVE INTRANIDAL
SQUID EMBOLIZATION**



Squid Cast



Left vertebral artery angiogram
Pre Embolization



Left vertebral artery angiogram
Follow up 9 months

Brain Arteriovenous Malformations

Endovascular Therapy / Results from 164 patients

Curative Embolization			
Total 37 (23%)	Angiographic Exclusion	In treatment	Lost for Follow-up
Glue (21)	21	0	0
Onyx (14)	14	0	0
Squid (2)	2	0	0

Embolization + Radiosurgery			
Total 61 (37%)	Angiographic Exclusion	In treatment	Lost for Follow-up
Glue (34)	26	4	4
Onyx (13)	6	7	0
Onyx + Glue (13)	7	4	2
Squid (1)	0	1	0

Brain Arteriovenous Malformations

Endovascular Therapy / Results from 164 patients

Embolization + Surgery			
Total 44 (27%)	Angiographic Exclusion	In treatment	Lost for Follow-up
Glue (36)	35	0	1
Onyx (4)	4	0	0
Onyx + Glue (3)	3	0	0
Squid (1)	1	0	0

Embolization + Radiosurgery			
Total 7 (4%)	Angiographic Exclusion	In treatment	Lost for Follow-up
Glue	6	0	1

Paliative Embolization
Total 15 (9%)
Glue (15)

Brain Arteriovenous Malformations

Endovascular Therapy and Associated Therapeutic Protocols

Radiological Angiographic Results

164 patients

Complete Angiographic Exclusion	125 cases	76 %
Incomplete Angiographic Exclusion (remaining in treatment)	16 cases	10 %
Paliative Embolization	15 cases	9 %
Lost for follow-up	8 cases	5%

Brain Arteriovenous Malformations

Endovascular Therapy and Associated Therapeutic Protocols

Radiological Angiographic Results

141 patients that completed treatment

Complete Angiographic Exclusion	141 cases	89 %
---------------------------------	-----------	------

Brain Arteriovenous Malformations

Endovascular Therapy and Associated Therapeutic Protocols

Clinical Complications

164 patients

Morbidity

Permanent neurologic defice	4 patients	2 %
ischemic	2 cases	
haemorrhage	2 cases	

Only one patient dependent

Brain Arteriovenous Malformations

Endovascular Therapy and Associated Therapeutic Protocols

Intraarterial embolizations	Mortality 2 %
(164 patients)	
4 patients	
Severe hematoma probably caused by venous outflow occlusion	4 cases
glue – 3	
onyx - 1	

CONCLUSIONS

Intra-arterial embolization holds a central point in therapeutic protocol of brain AVM – used on its own (curative and palliative) or associated with surgery and / or radiosurgery

The enormous progress in microcatheter and microguiding systems and new embolic materials – GLUBRAN and ONYX/SQUID + Phil -made possible that a higher percentage of patients with excellent clinical outcome and the reduction of morbidity and mortality

New long term retrospective and prospective studies are needed to evaluate the new therapeutic reality of brain AVMs

The End