

# **BIFURCATION INNOMINATE ARTERY DISEASE (ENDOVASCULAR MANAGEMENT)**

**DR TARUN MADAN (MD,DNB,MNAMS)  
ASST. PROFESSOR  
GUJARAT, INDIA**

# Disclosure Statement of Financial Interest

**I, (DR TARUN MADAN) DO NOT have a financial interest/arrangement or affiliation with one or more organizations that could be perceived as a real or apparent conflict of interest in the context of the subject of this presentation.**

# HISTORY

- MALE , 58 YRS, SMOKER
- HYPERTENSIVE , NONDIABETIC
- *DIZZINESS ON RT. ARM MOVEMENTS*
- *ABSENT RT. UPPER LIMB PULSATATIONS*
- *NORMAL OTHER LIMB,S PULSATATIONS*
- S/O SUBCLAVIAN STEAL SYNDROME

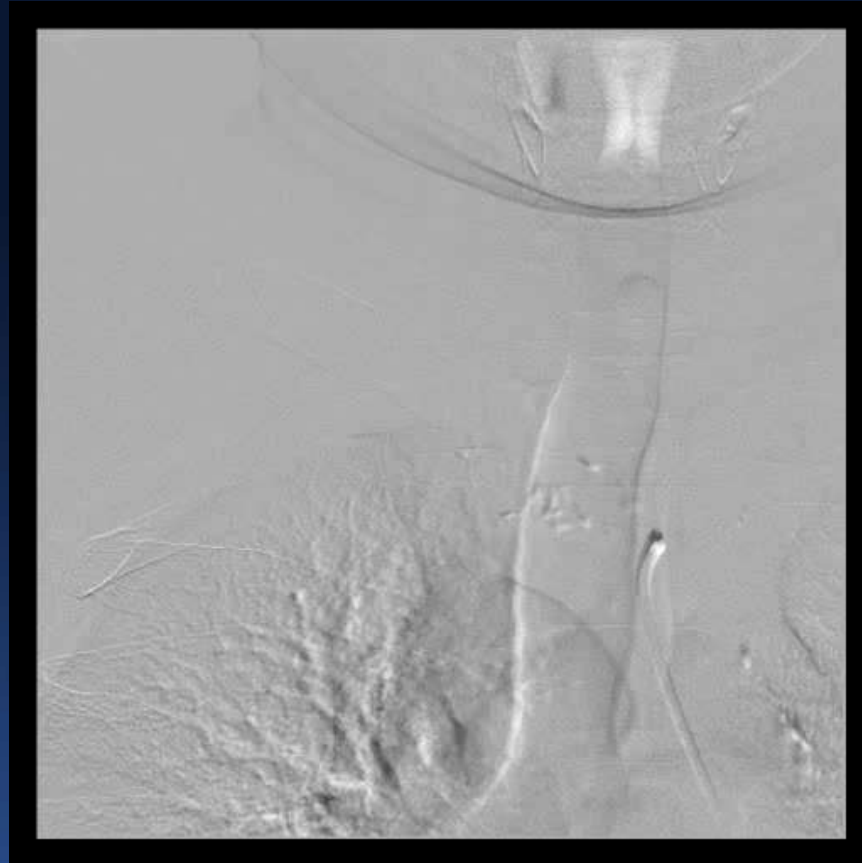# INVESTIGATIONS

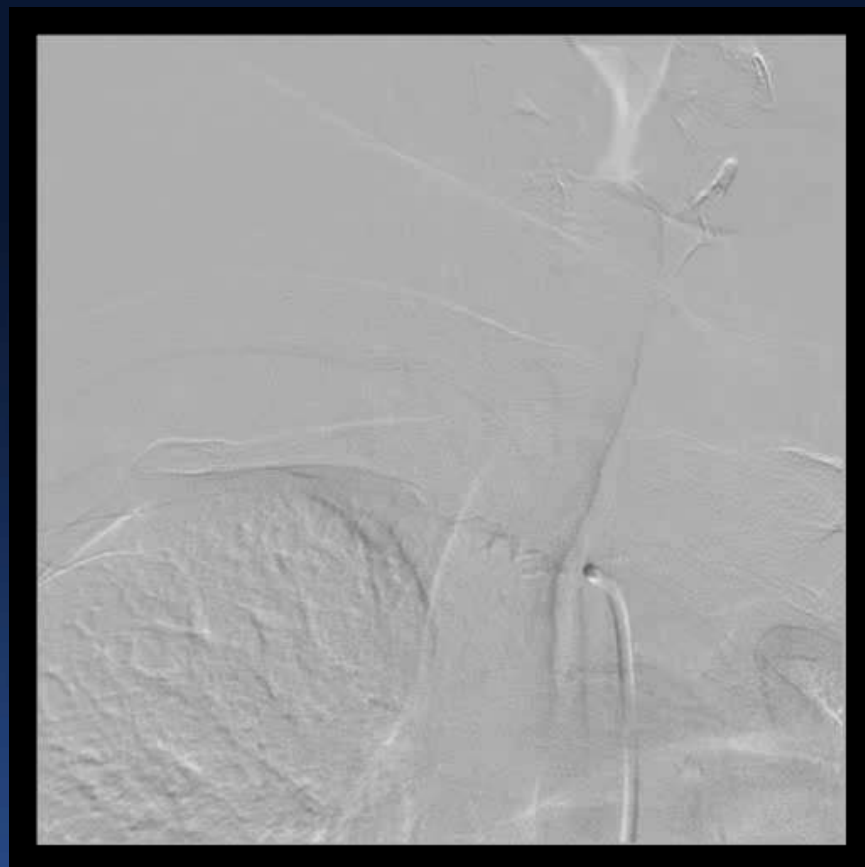
- **DUPLEX SCAN S/O DISTAL INNOMINATE ARTERY, OSTIAL RSCLA & RCCA STENOSIS AND RETROGRADE FILLING OF RT. VERTEBRAL ARTERY**
- **CT ANGIO SHOWED SIMILAR FINDINGS**
- **NORMAL RFT,CBC & COAGULATION PROFILE**
- **DYSLIPIDEMIC ( LDL ↑ )**

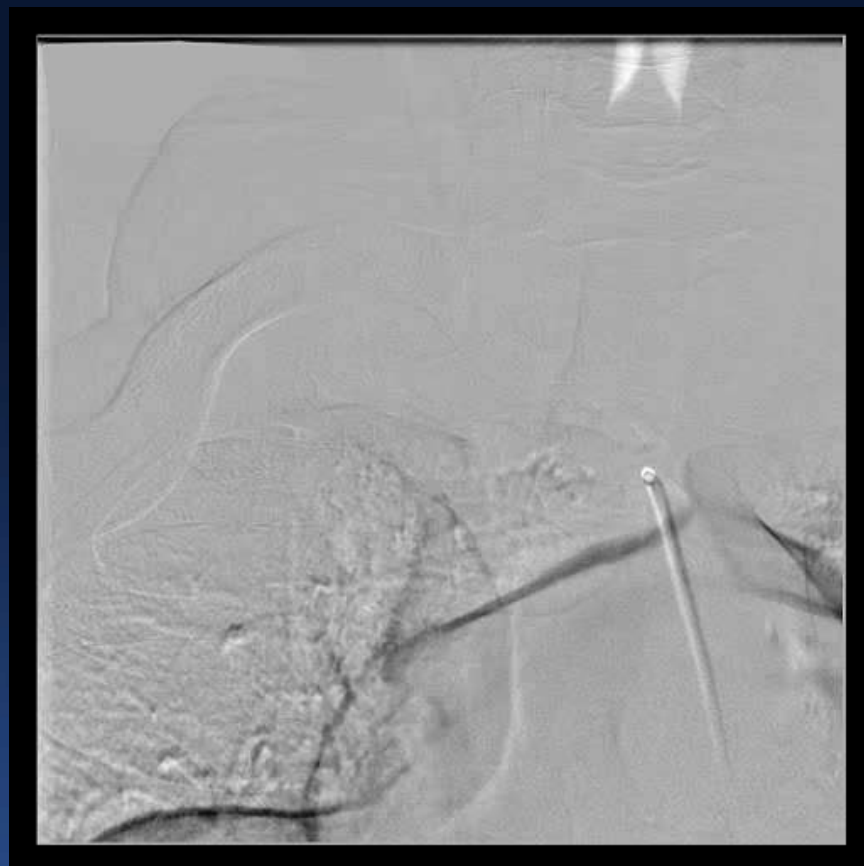# PROCEDURE

- **BILATERAL FEMORAL ARTERY ACCESS**
- **GUIDE CATHETER ( 7F & 8F)**
- **WIRES J TIP TERUMO (0.035'' ) & BMW (0.014'' )**
- **BALLOON DILATATION CATHETER ( 2.0/12, 6/18 mm )**
- **DPD ( ANGIOGUARD- 7 mm , Cordis )**

# FIRST ANGIO







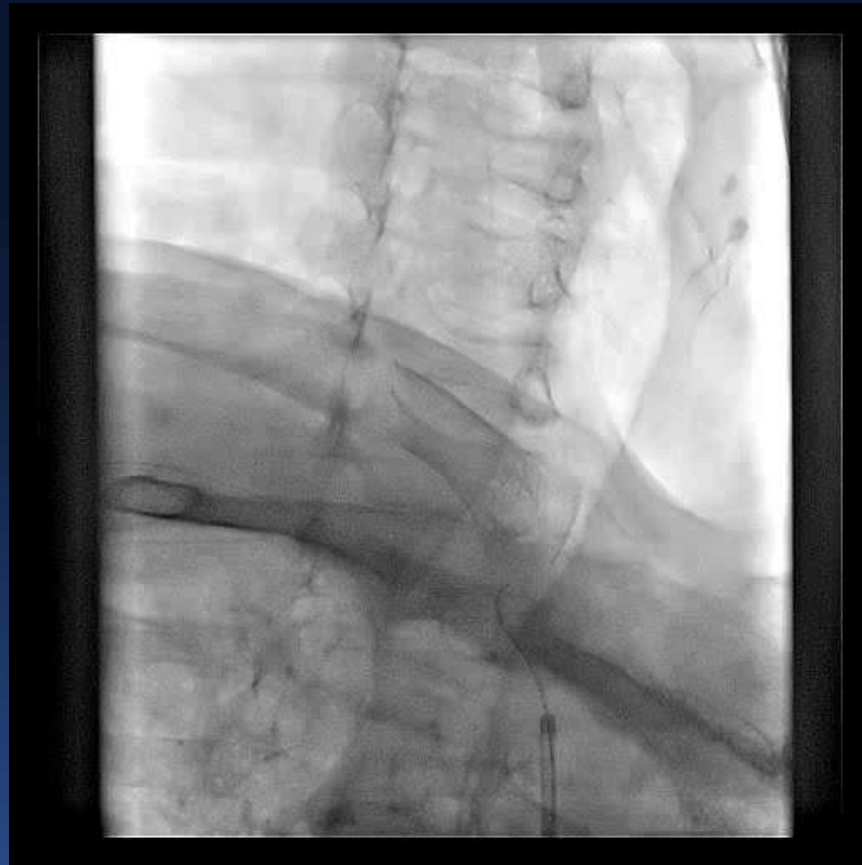



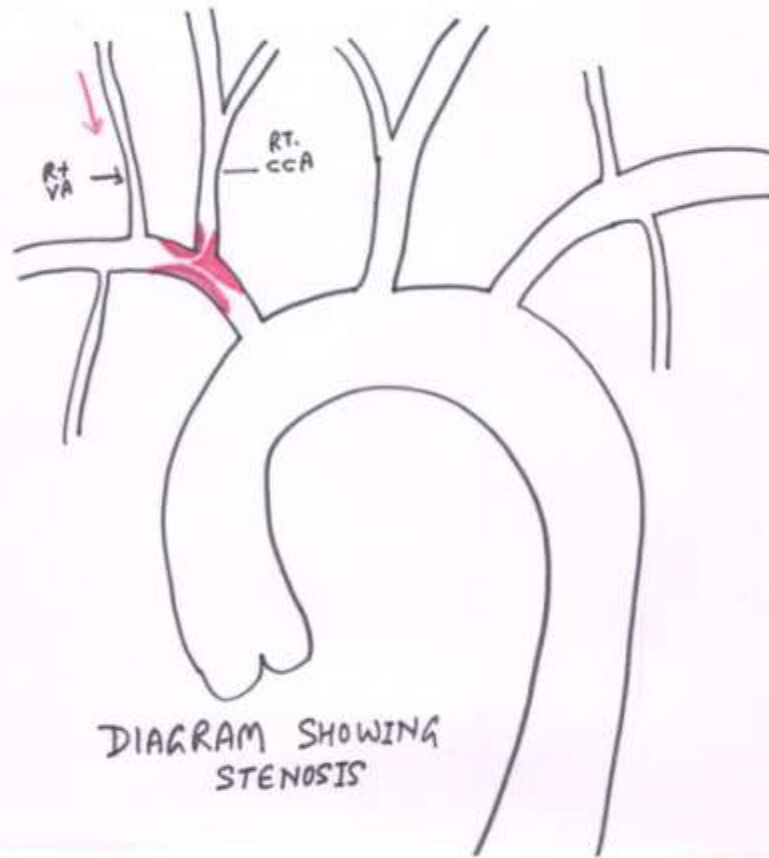
# INTRACRANIAL



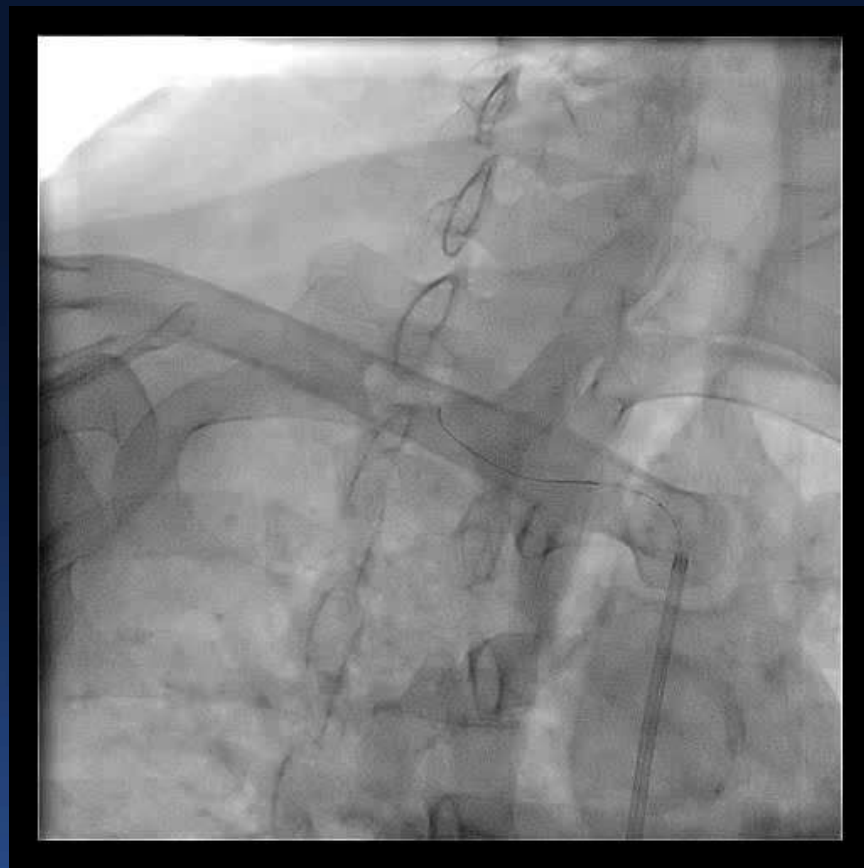


# WIRING RCCA

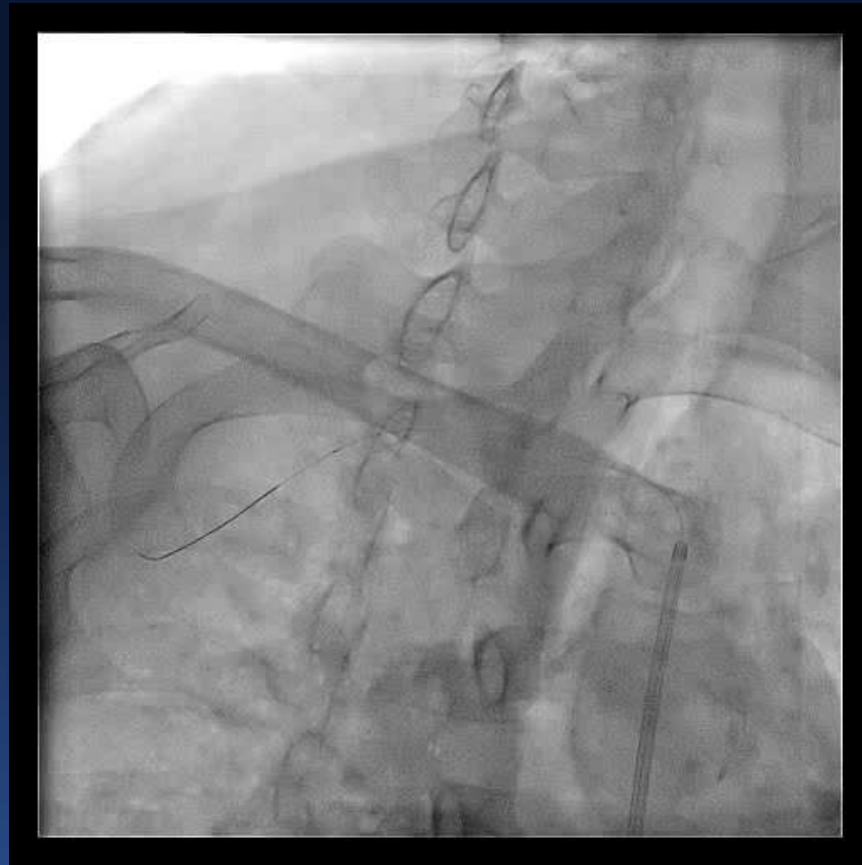



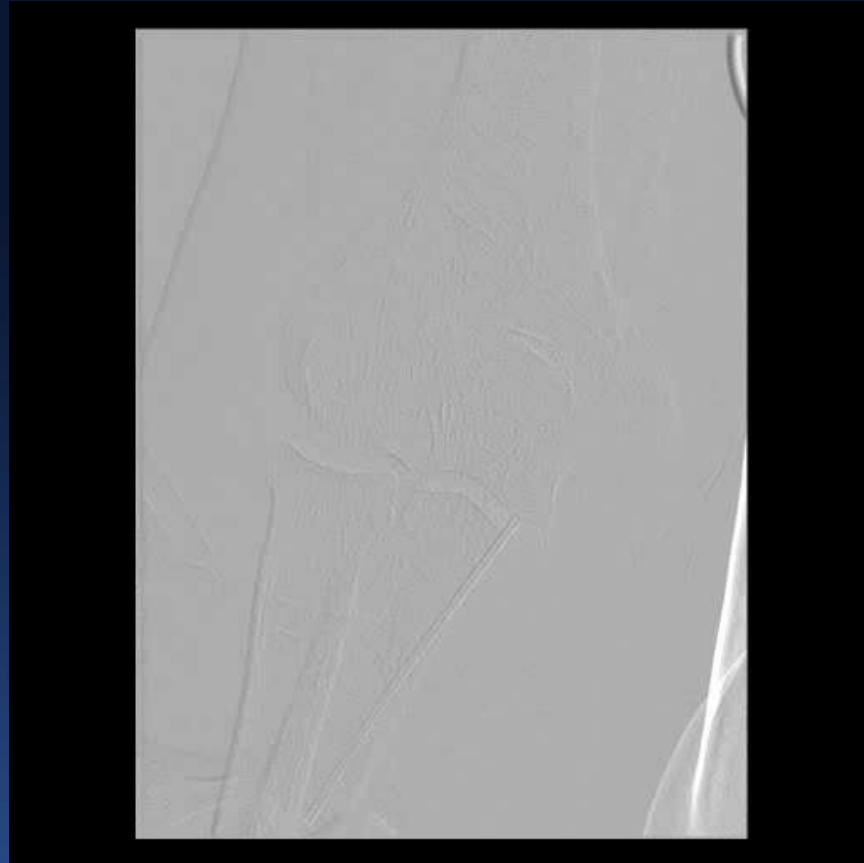
# WIRE FAILED TO GO TO RCCA



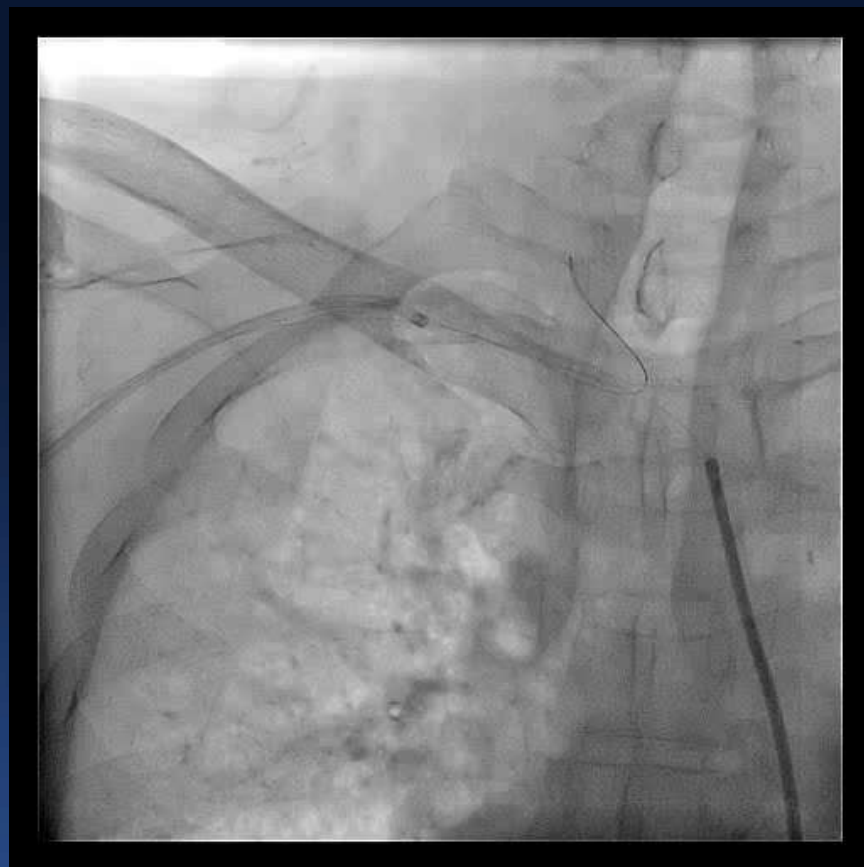
# ***PARKED WIRE IN RSCLA DISTALLY***



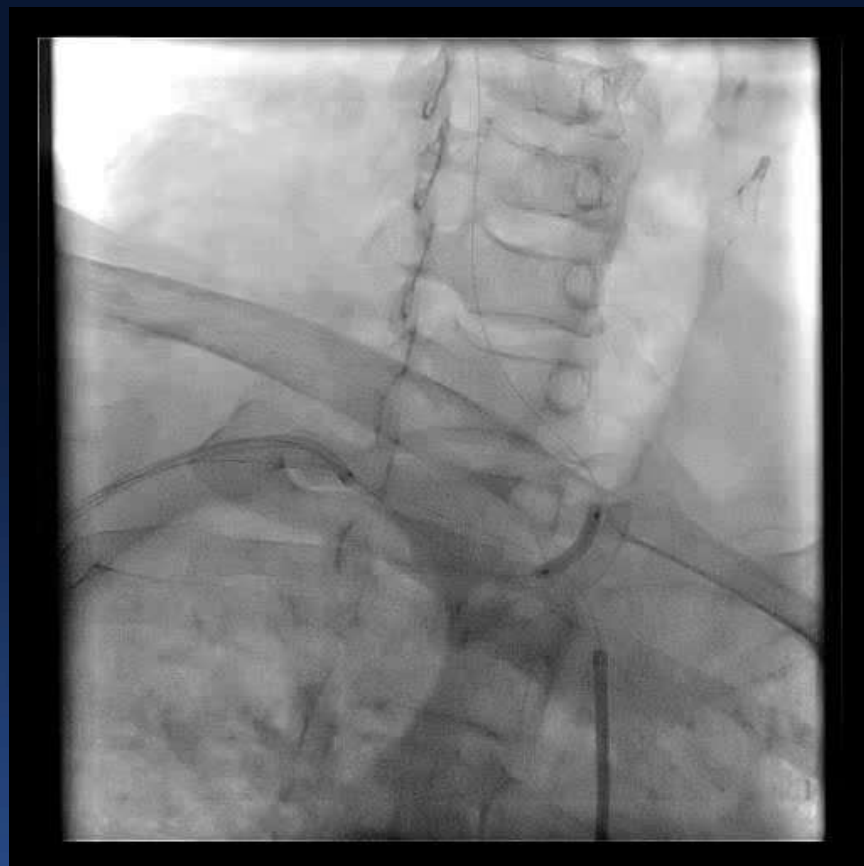
# ***RT. BRACHIAL ART. ACCESS***

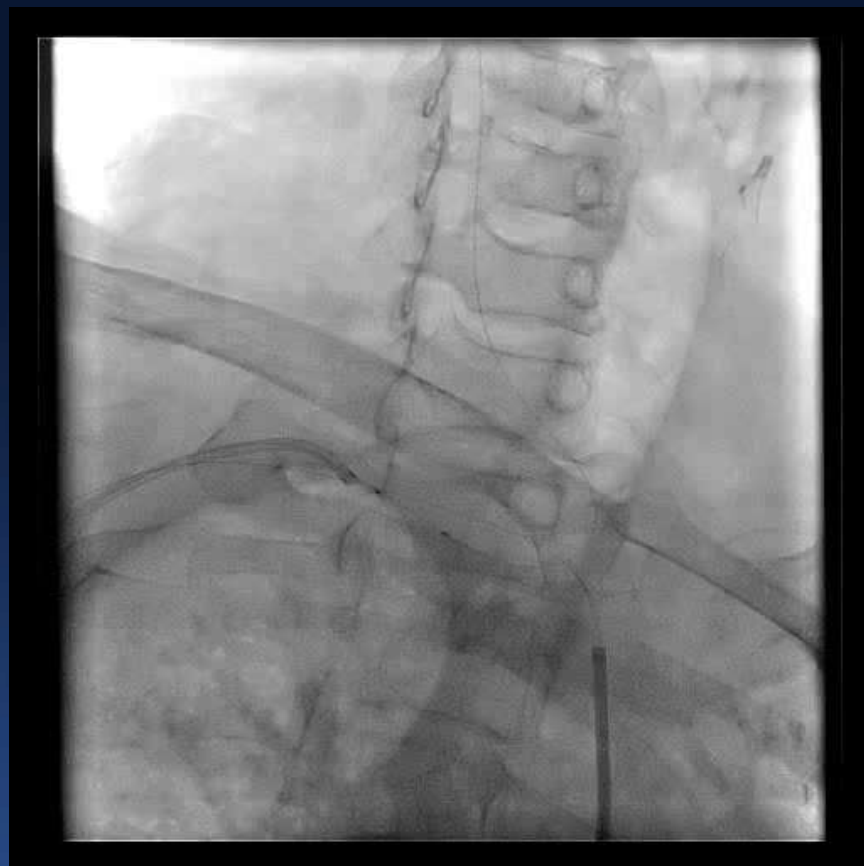


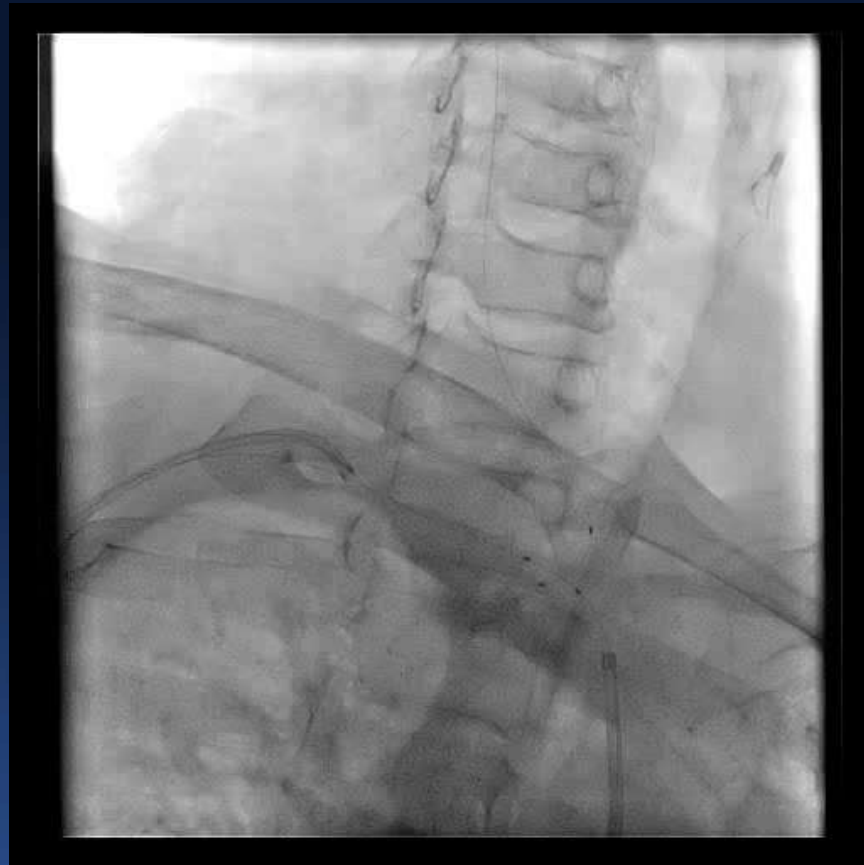# WIRE VIA RT. BRACHIAL TO RCCA



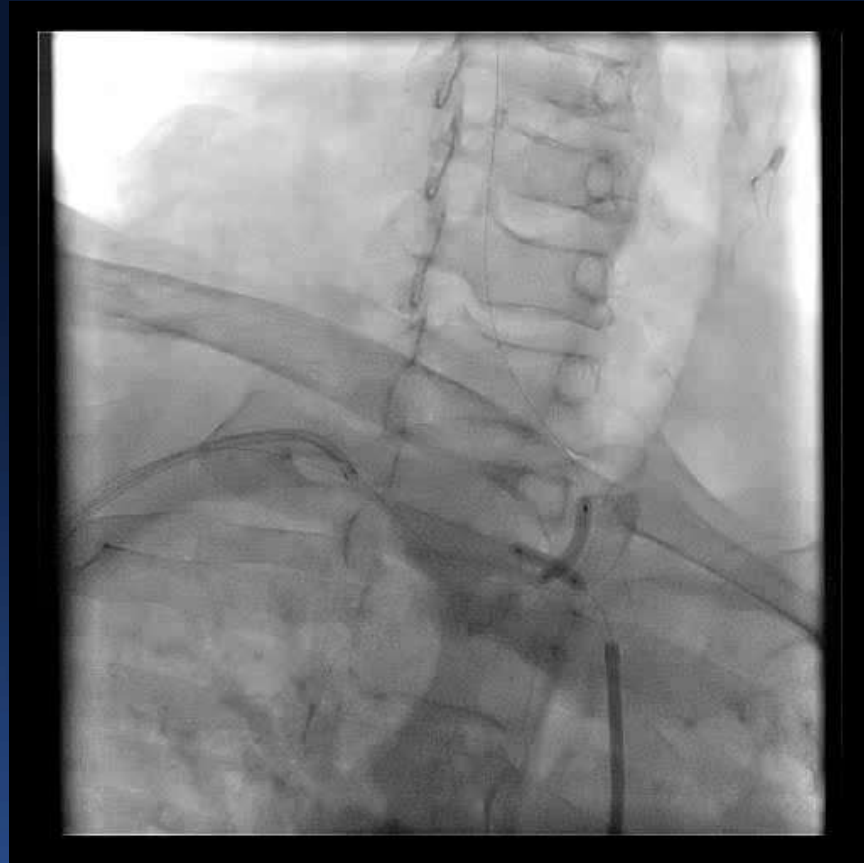


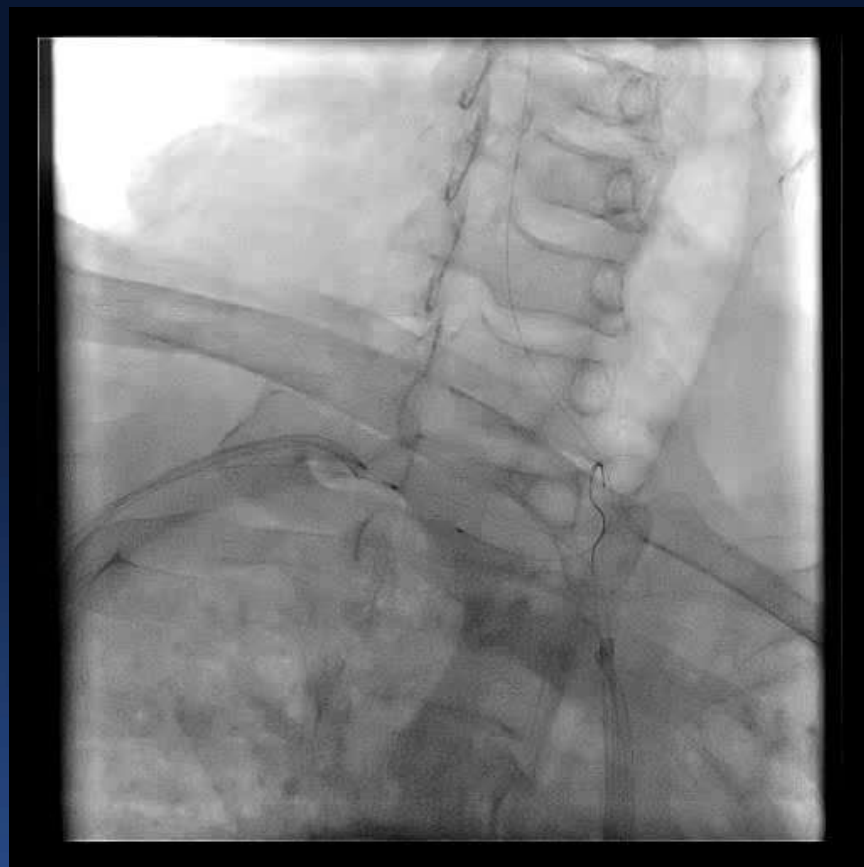




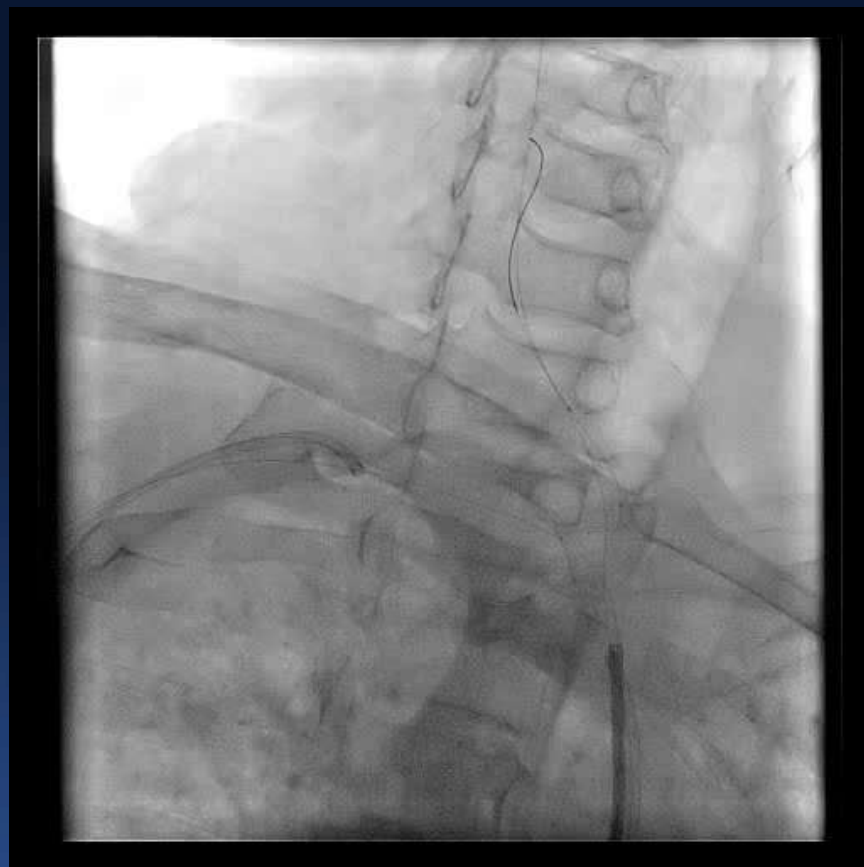


# KISSING BALLOON

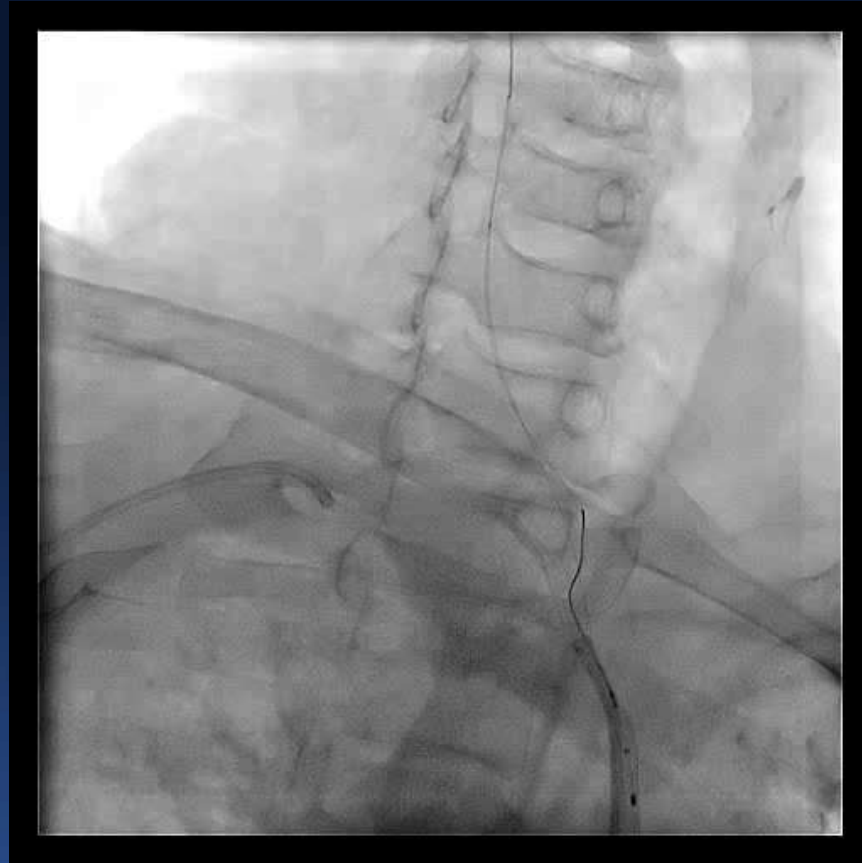


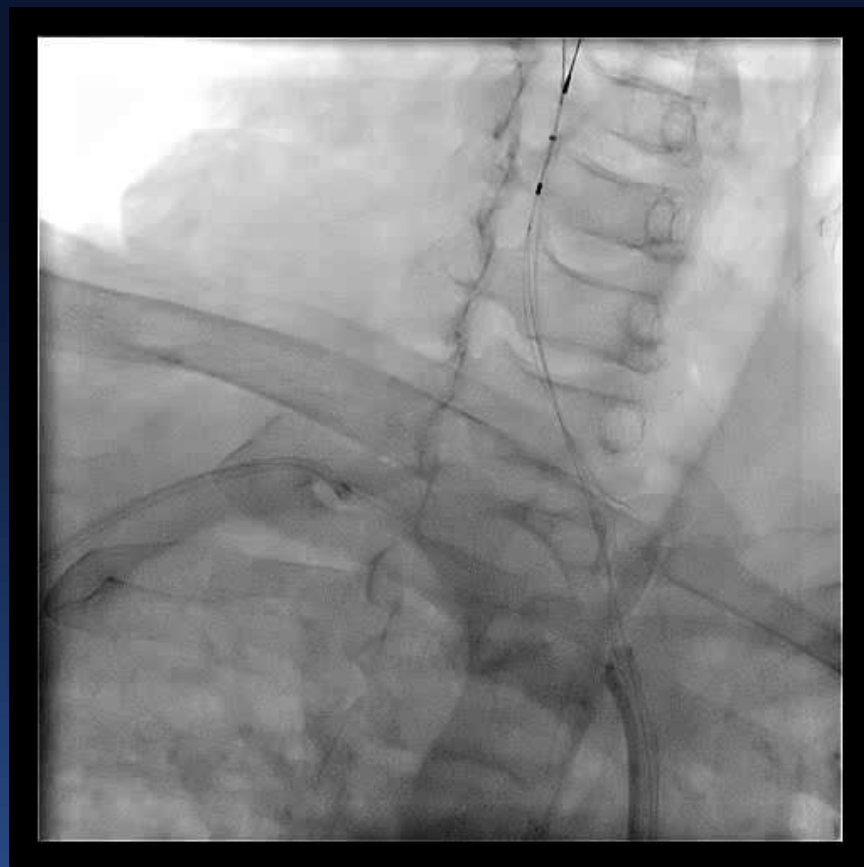


# REMOVAL OF RT. UL WIRE

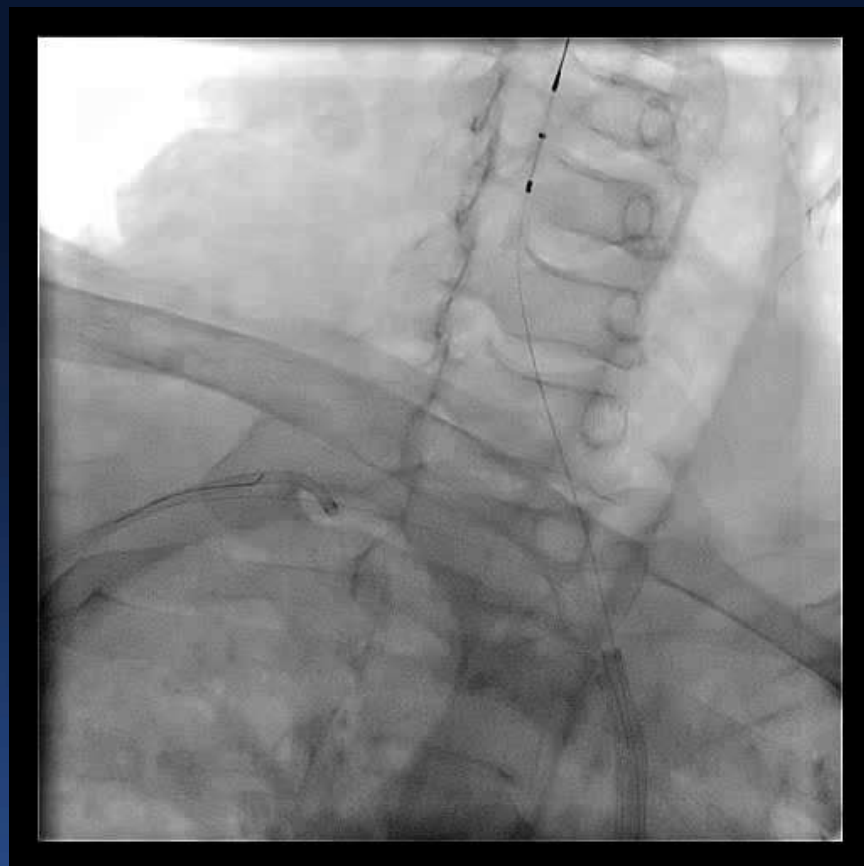


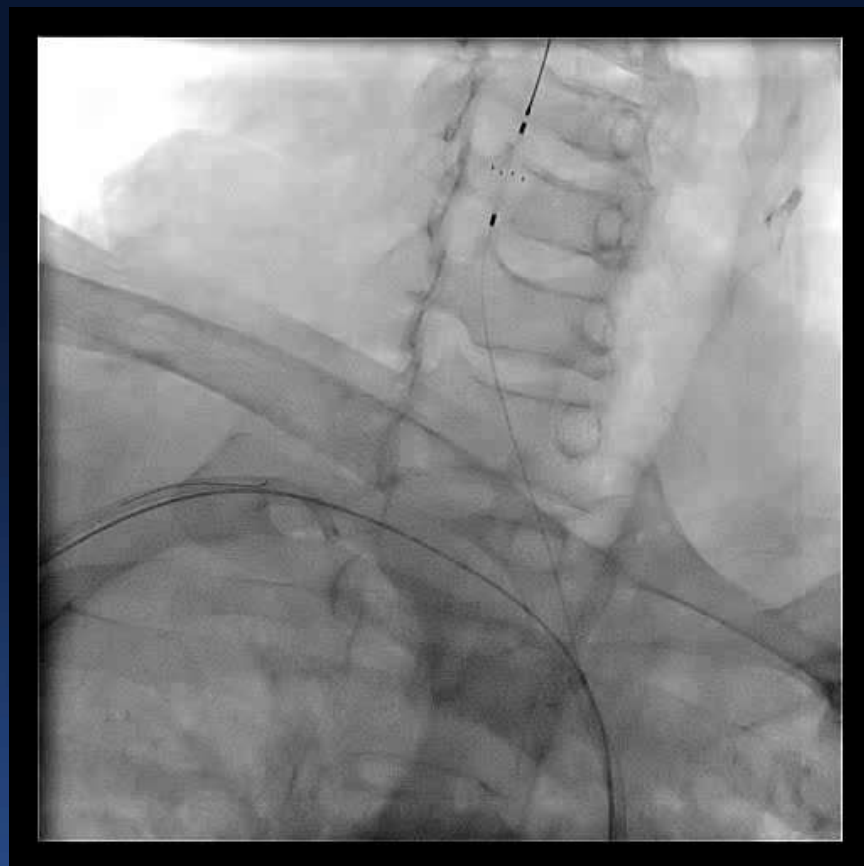
# ANGIOGUARD, 7mm



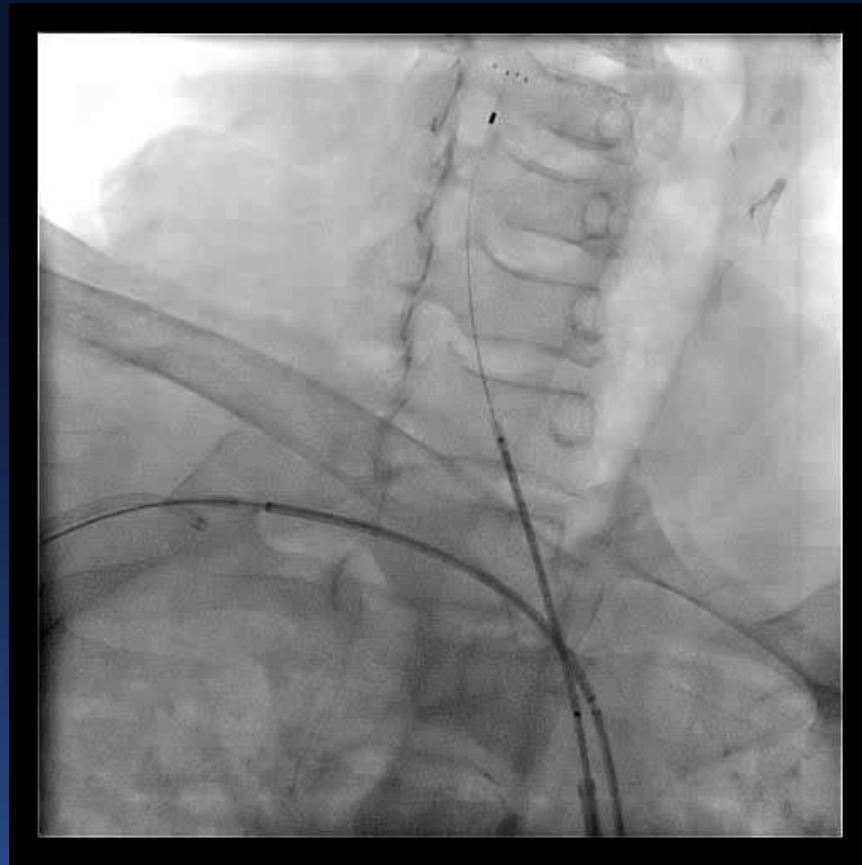


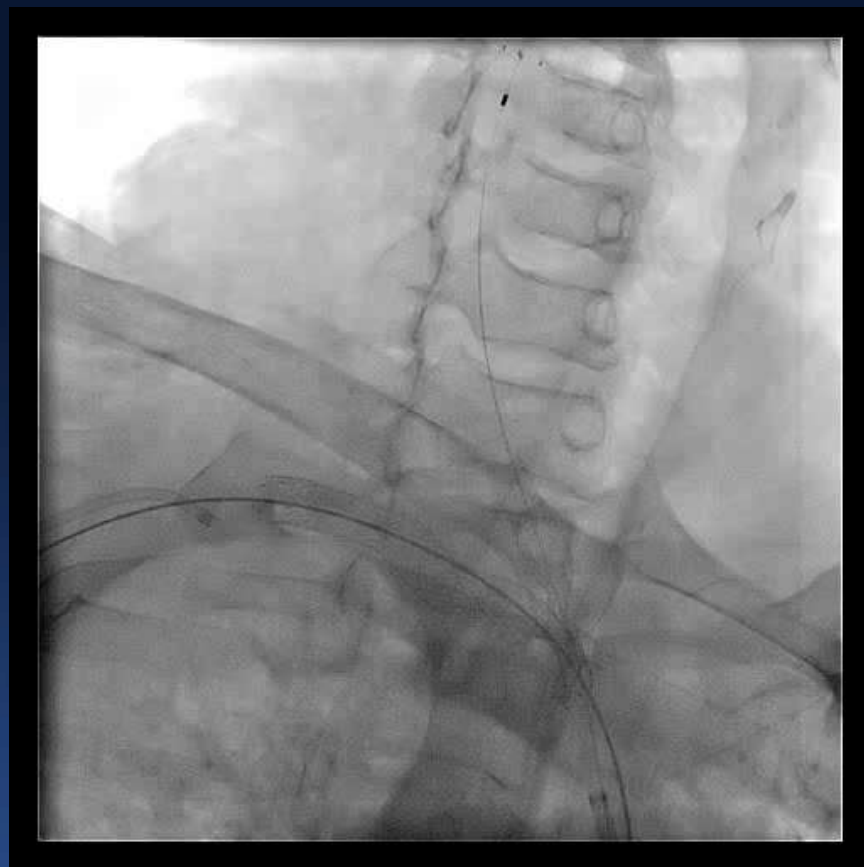




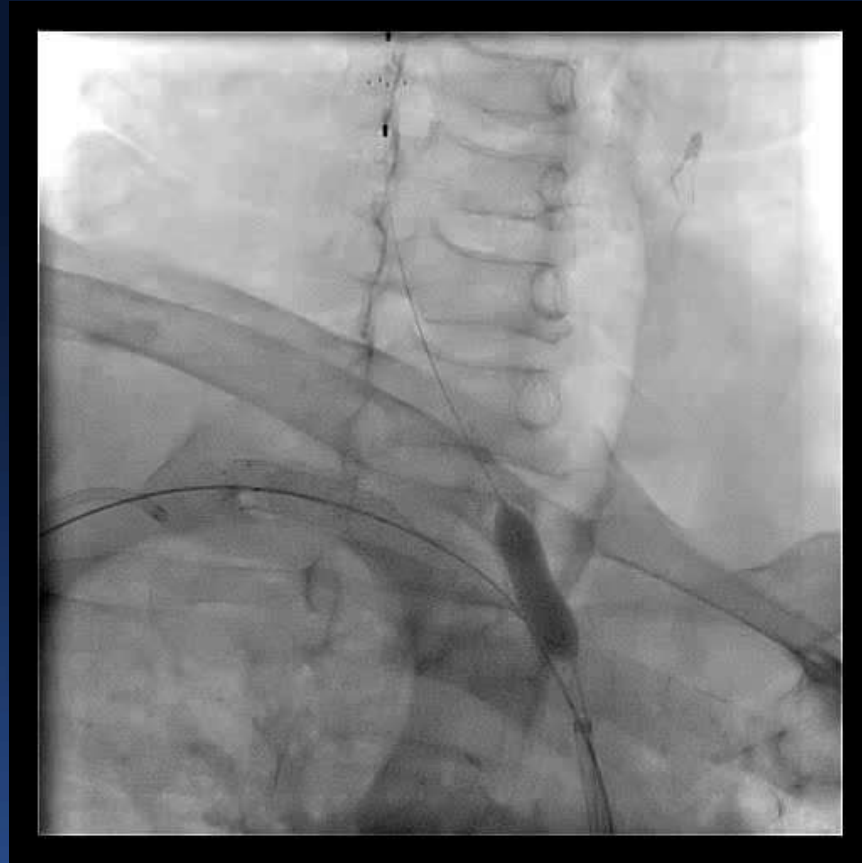


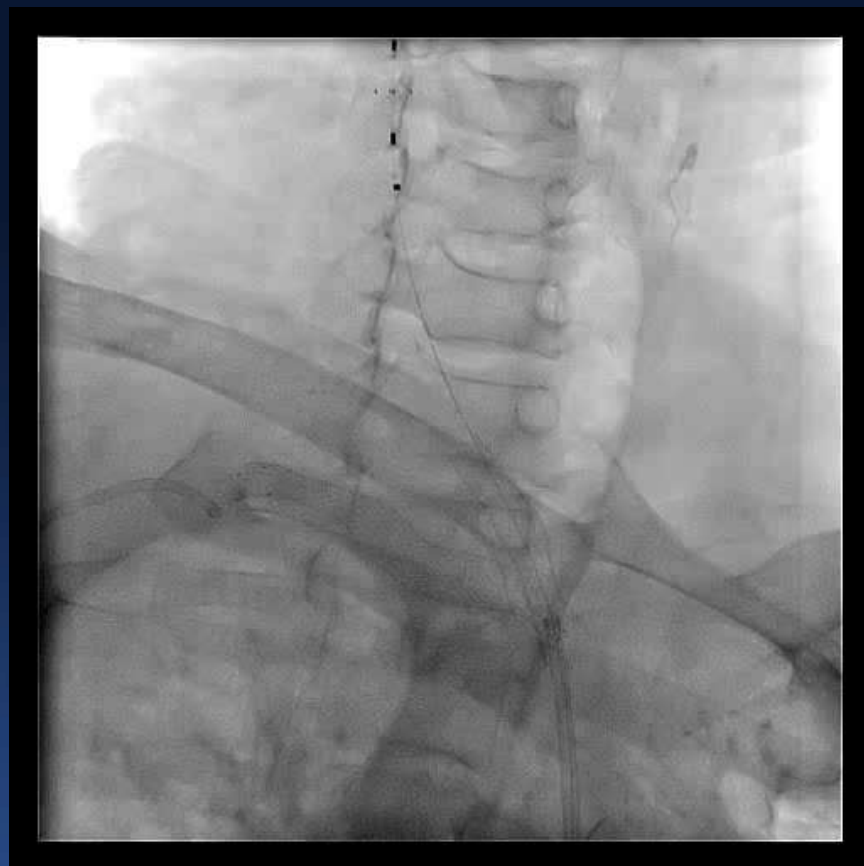
# TWO SES 7/40 & 7/30 mm





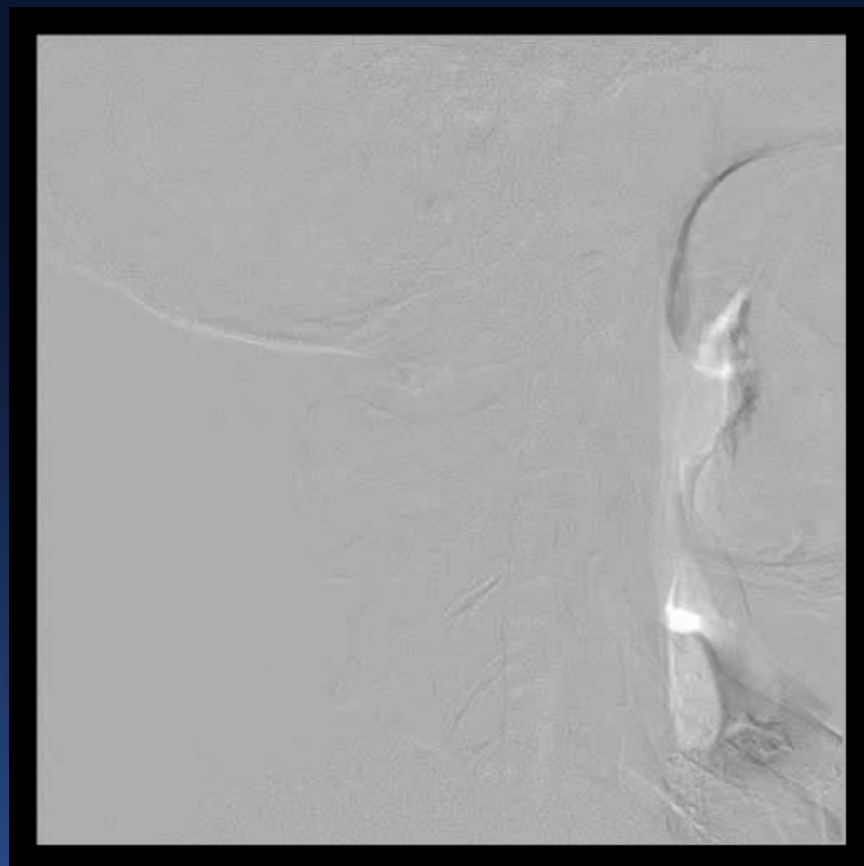
# POST DILATION



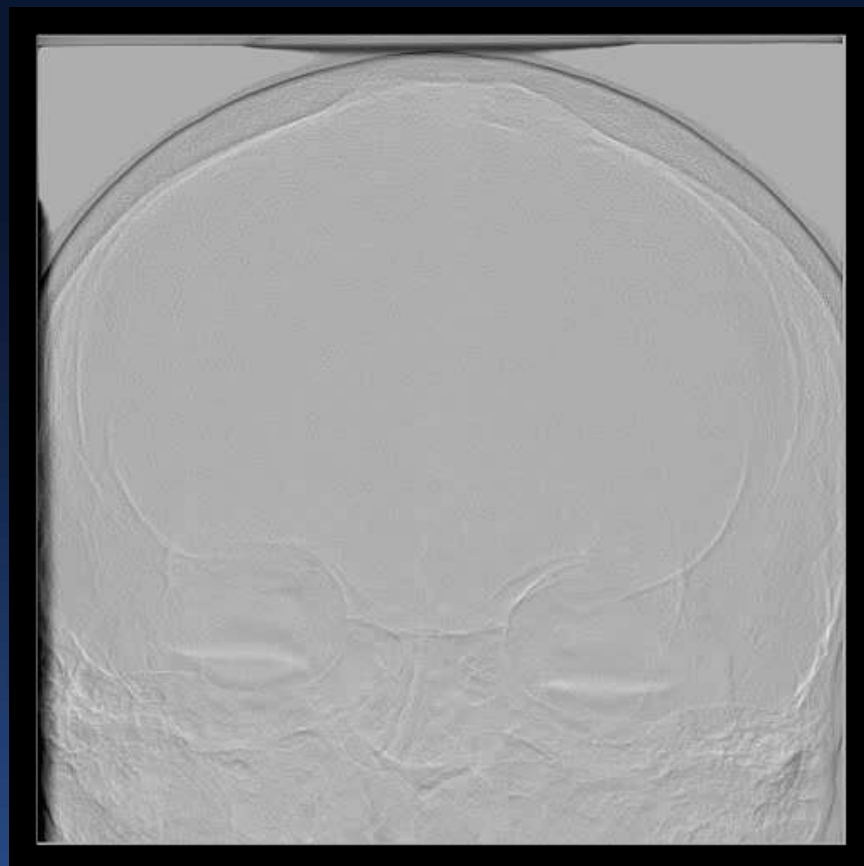


# FINAL ANGIO









- **POST PROCEDURE SYMPTOMS RECOVERED**
- **PRESSURES EQUALISED IN BOTH ARMS**
- **NO NEUROLOGICAL COMPLICATION**
- **ONE YEAR CLINICAL F/UP**

