



Alex Abou-Chebl, MD

Director of Neurointerventional Services

Associate Professor of Neurology and Neurosurgery

University of Louisville School of Medicine



ACUTE STROKE: CASE PRESENTATION




Disclosures

- Speakers Bureau BMS
- 



Case Presentation


- 58yr AAF with Hx of HTN, HLD, CAD
 - Cardiac Cath. for exertional angina with pain radiating into left arm
 - Procedural Meds
 - Versed
 - Pretreated with ASA
 - Plavix 300mg Load
 - Heparin
 - Findings
 - Mid RCA 70-80% stenosis proximal first diagonal
- 

Post Cath. While on Table

- Decreasing Mental Status
- Dysarthric speech
- What is the Next Step?
 - A- Call the cardiologist
 - B- Prepare Flumazenil to reverse Versed
 - C- Check the BP
 - D- Check Blood Sugar
 - E- Perform neurological assessment
 - F- All of the Above



Neurological Exam


- Sleepy but arousable
 - Dysarthric speech
 - Not following commands
 - Left facial droop
 - Impaired vertical gaze
 - NIHSS- 21
- 

Where is the Occlusion?

- Left Carotid
- Right Carotid
- Right Middle Cerebral A.
- Right Vertebral A.
- Basilar A.
- Right Posterior Cerebral A.




What is the Next Step?

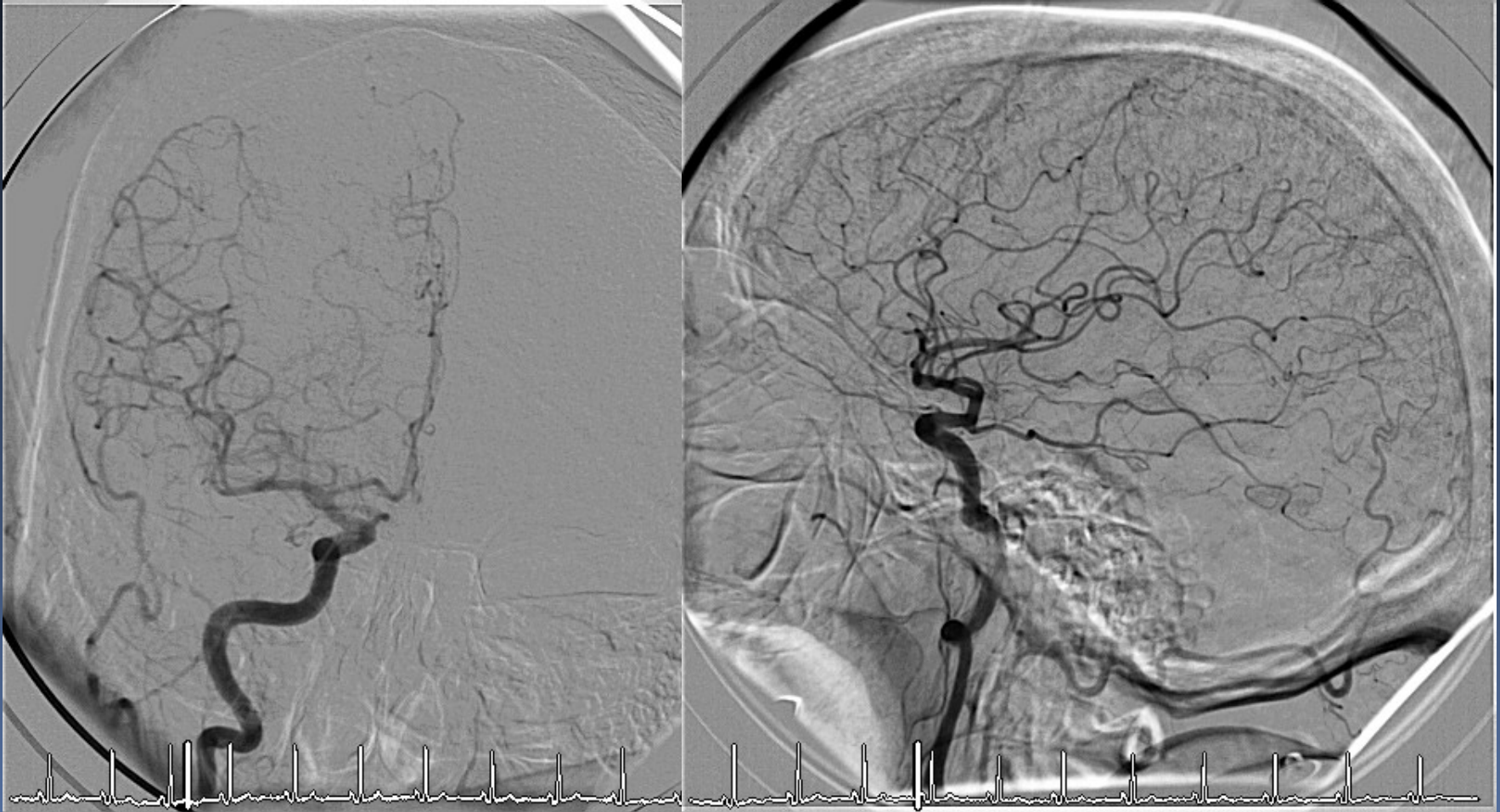
- Observe patient for 1-2 hours
 - Take the patient to CT
 - Take the patient to MRI
 - Give IV Heparin
 - Give IV tPA
 - Take patient to neurointerventional suite
- 



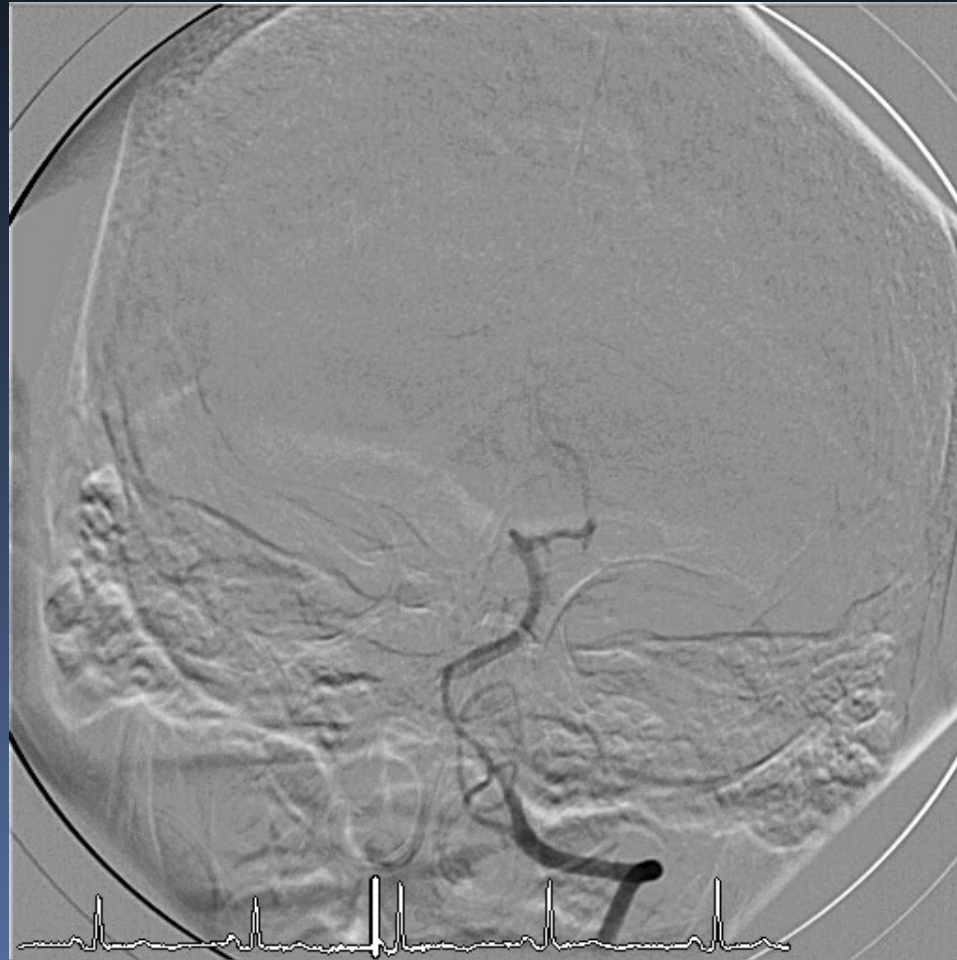
Course

- CT head negative for hemorrhage
 - No IV tPA
 - Recent ASA/Plavix load
 - Heparin during cath.
 - Recent femoral stick ?
- 

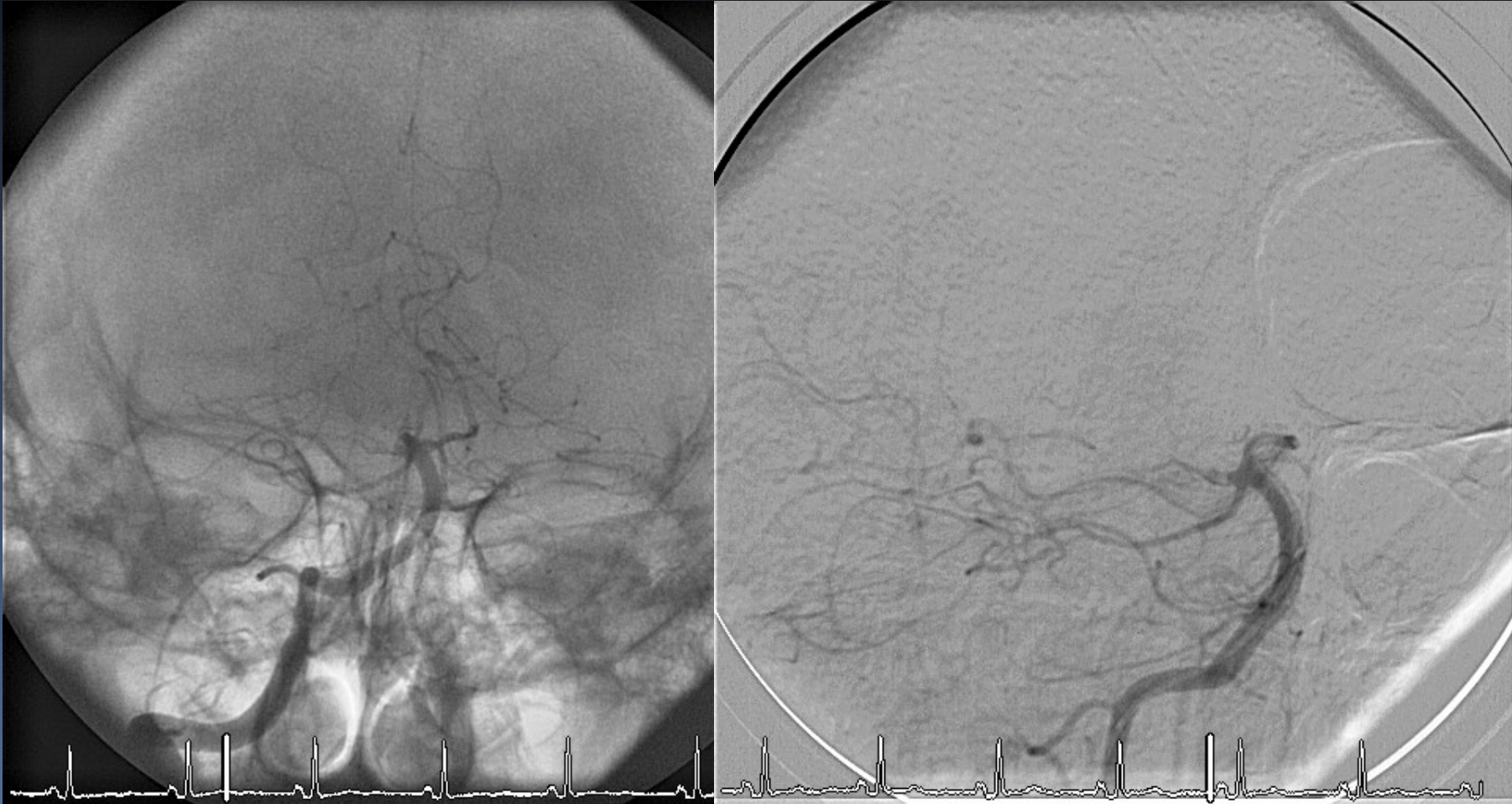Right ICA Angiogram



Left VA Angiogram



Right VA Angiogram



Intervention Preparation

- Exchange for 6F Neuro Guide in RVA
- 2000U Heparin IA
- Advance 2.3F Microcatheter over 014" hydrophilic microwire
- No sedation
- O₂
- Suction
- Boost BP
 - Fluids
 - Neo

Intervention Details




Intervention Details

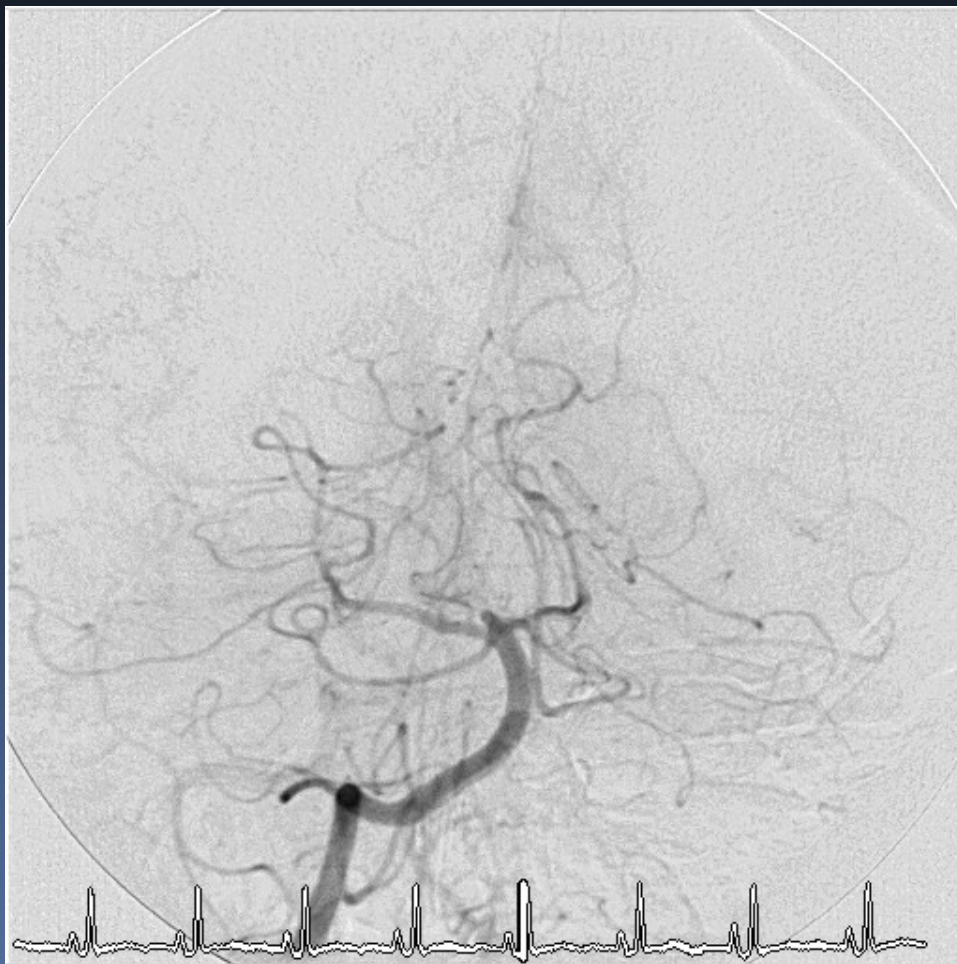- Microsimulation with PCA
- Main





Interventions Details

- Treated with IA thrombolysis
 - Over 40 Minutes
 - 6mg IA tPA
 - 6mg ReoPro
- 



Post Intervention

- Patient began to improve on Table
- SBP kept <120
- Glucose <150
- NG Inserted
- No ASA, Plavix, Heparin
- Neurologically Normal by next day
 - ▣ NIH-o Rankin-o
- Discharged to home day 2

