



Changhai Hospital

## Leo Stent Implantation for VBD

Operator : Dr. Qing-hai Huang and Kai-Jun Zhao



# Clinical Data

---

Male , 48Y

CC : Found vertebrobasilar dolichoectasia 5M ago

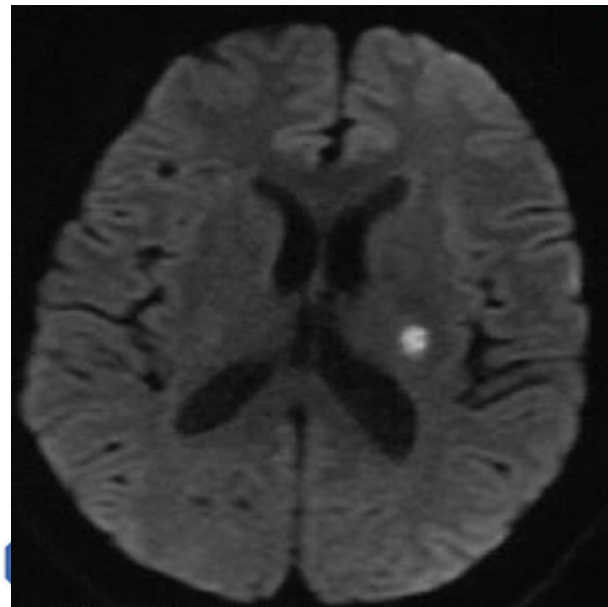
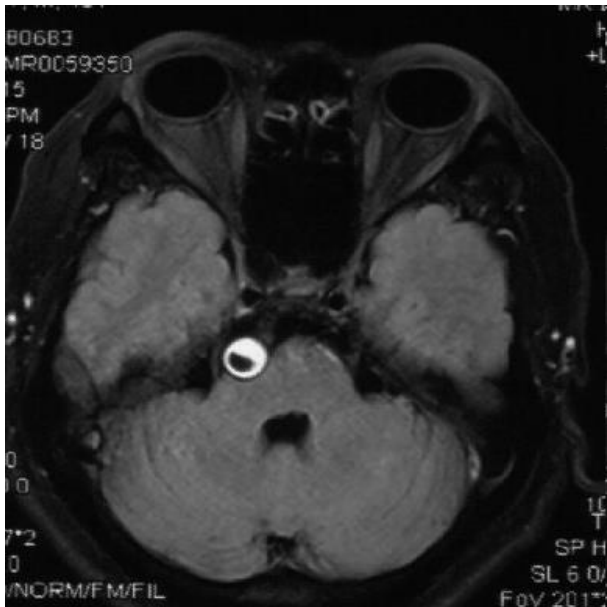
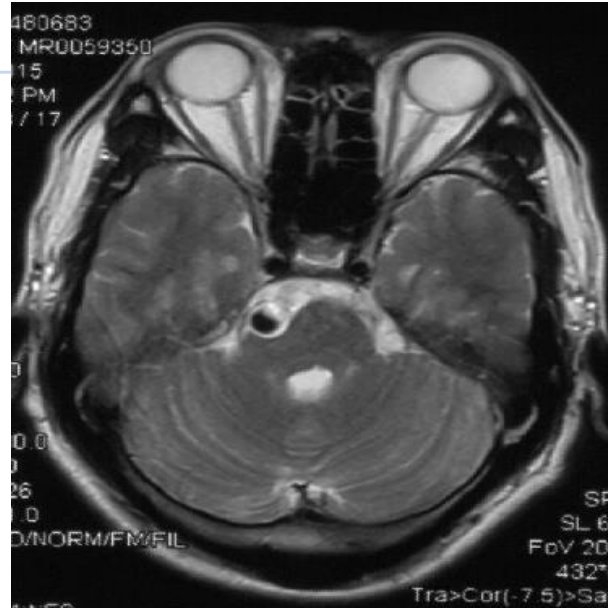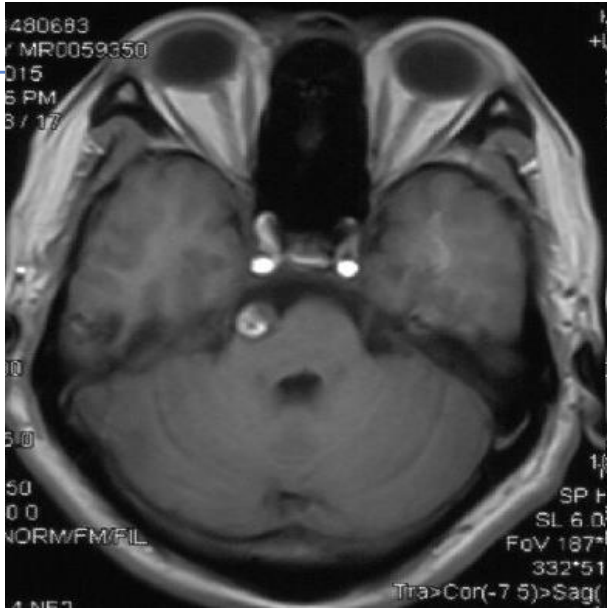PE : Right lower limb muscle strength: V-

PH : -

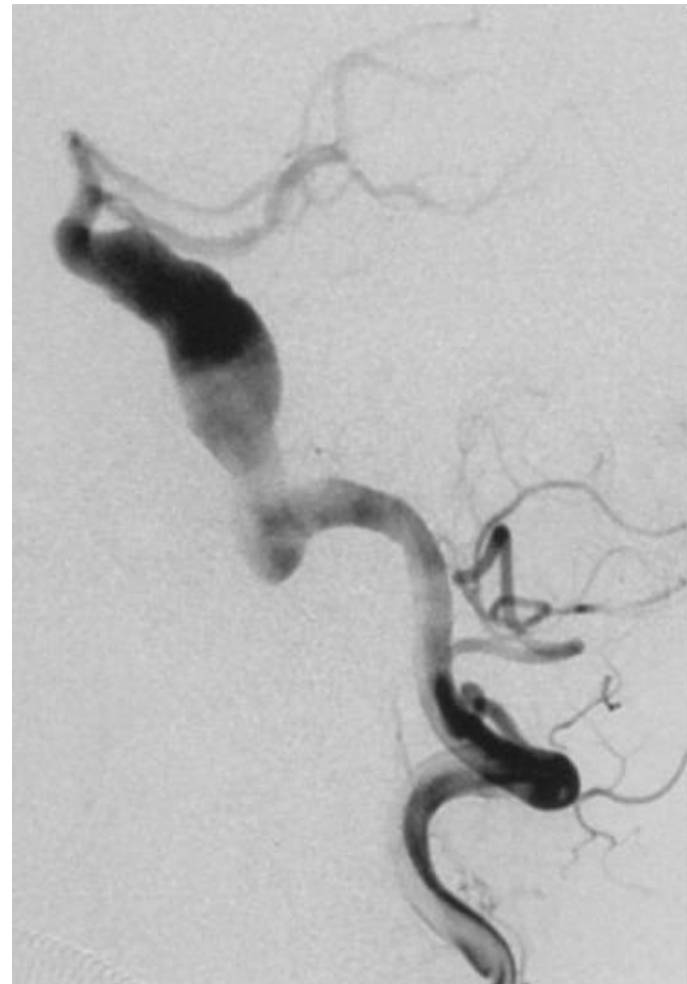
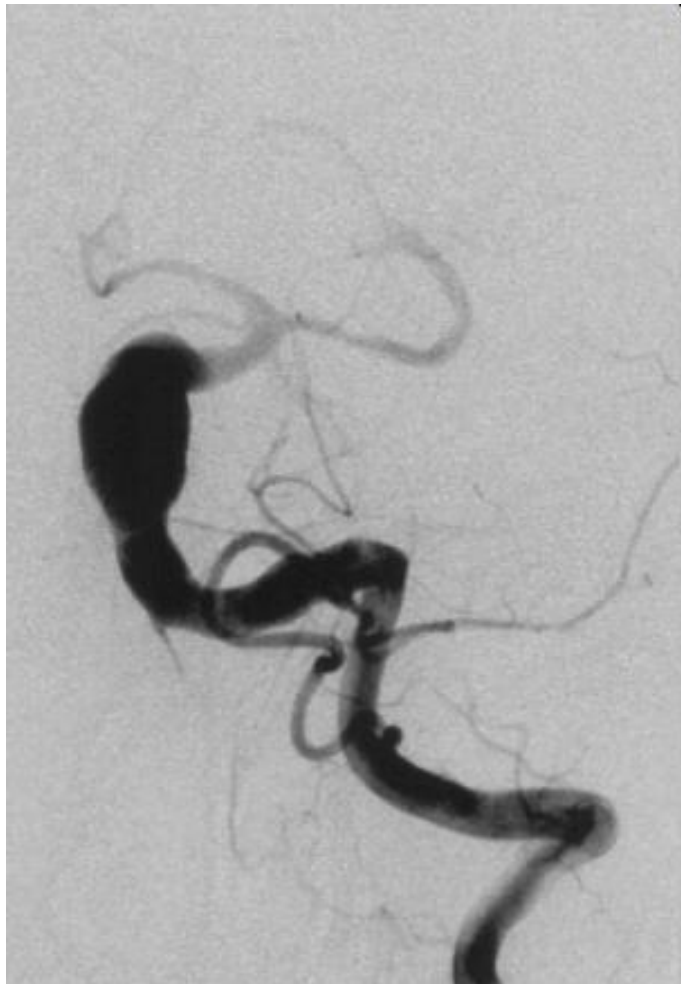
DX : Vertebrobasilar Dolichoectasia



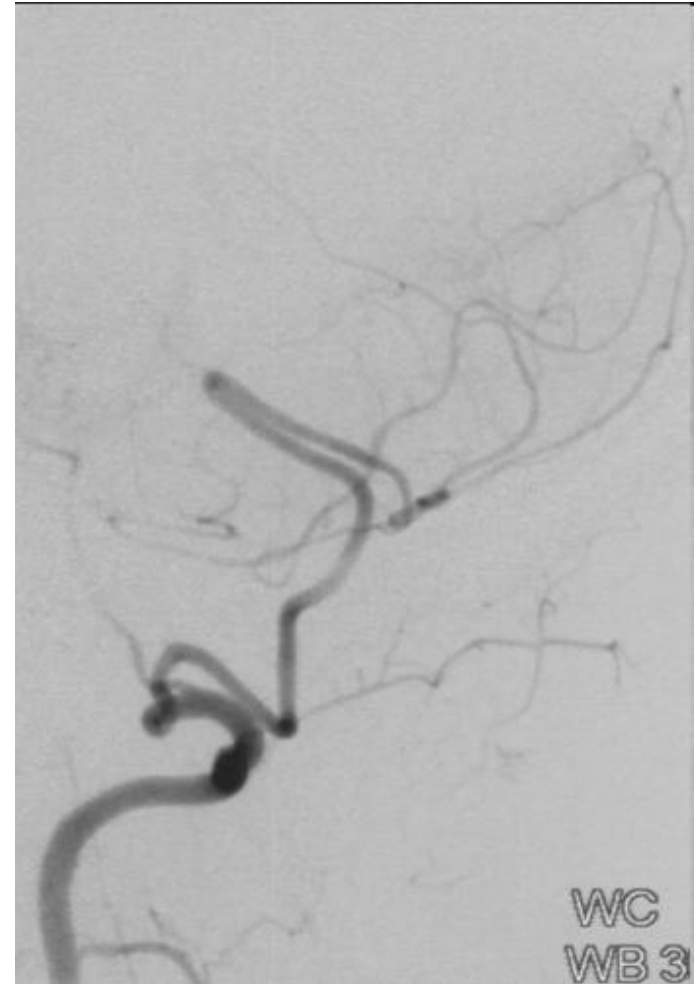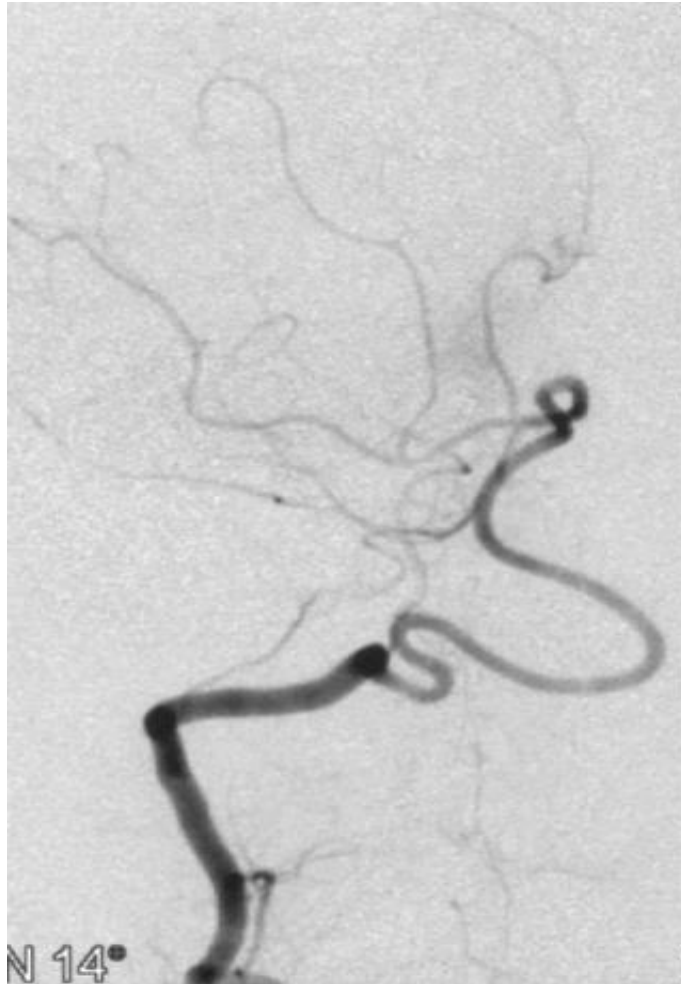# DSA 2015-09-18 Local Hospital



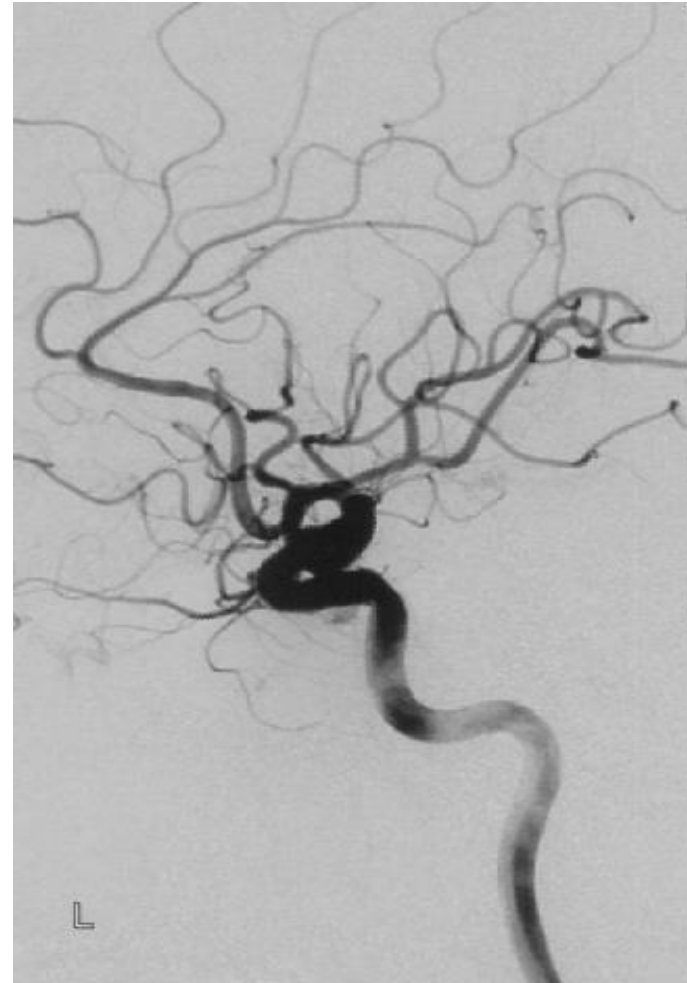
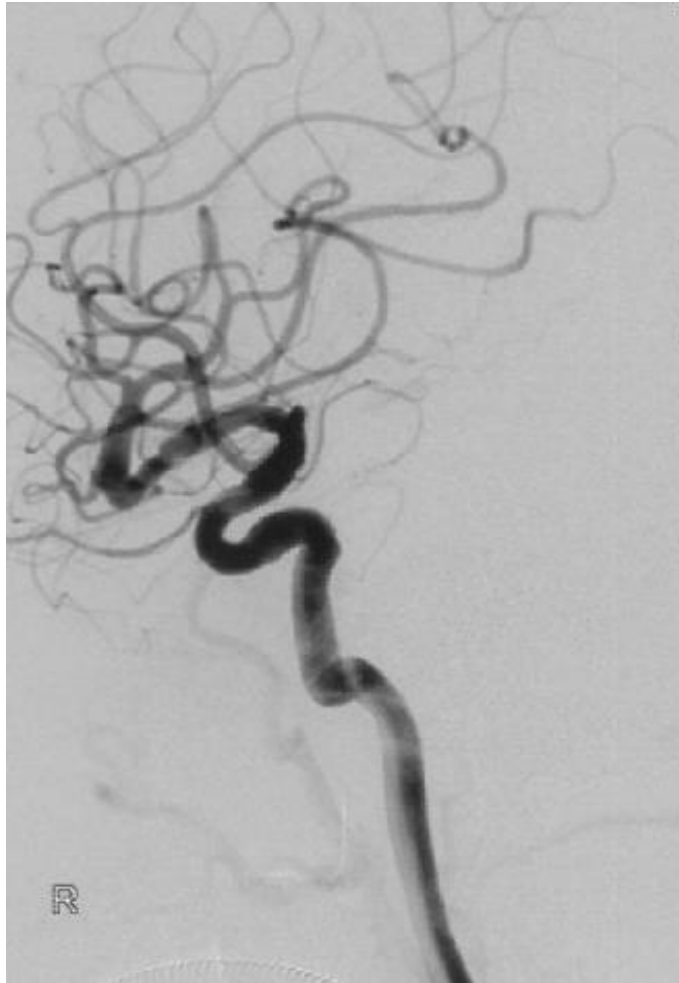# DSA 2016-02-18 L-VA



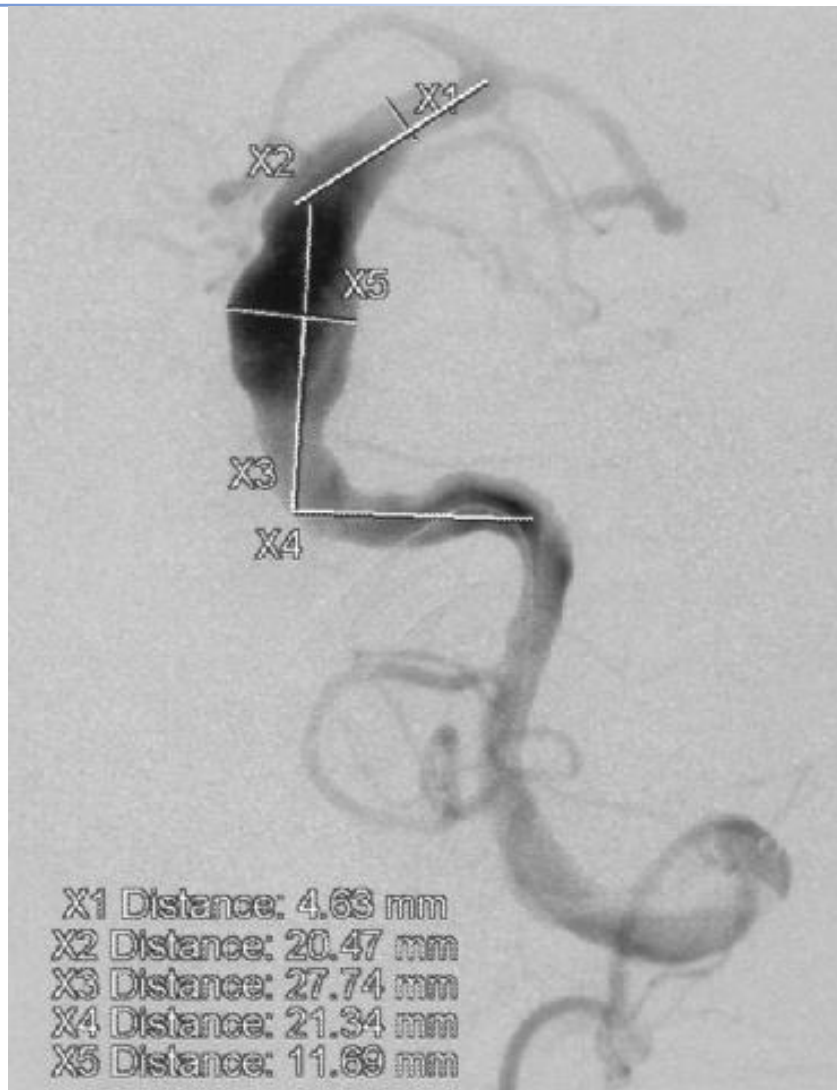# R-VA



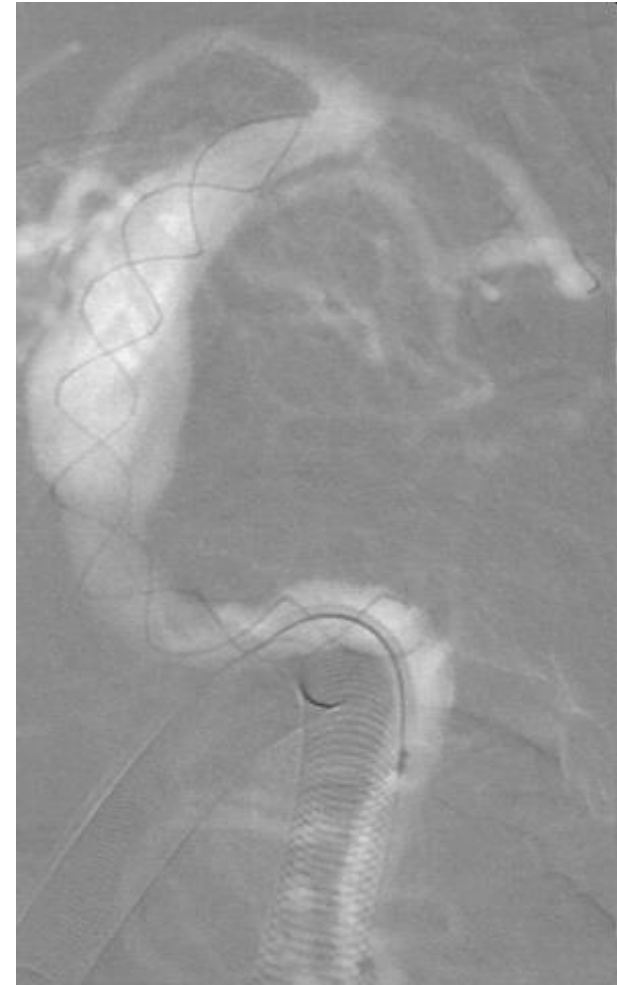
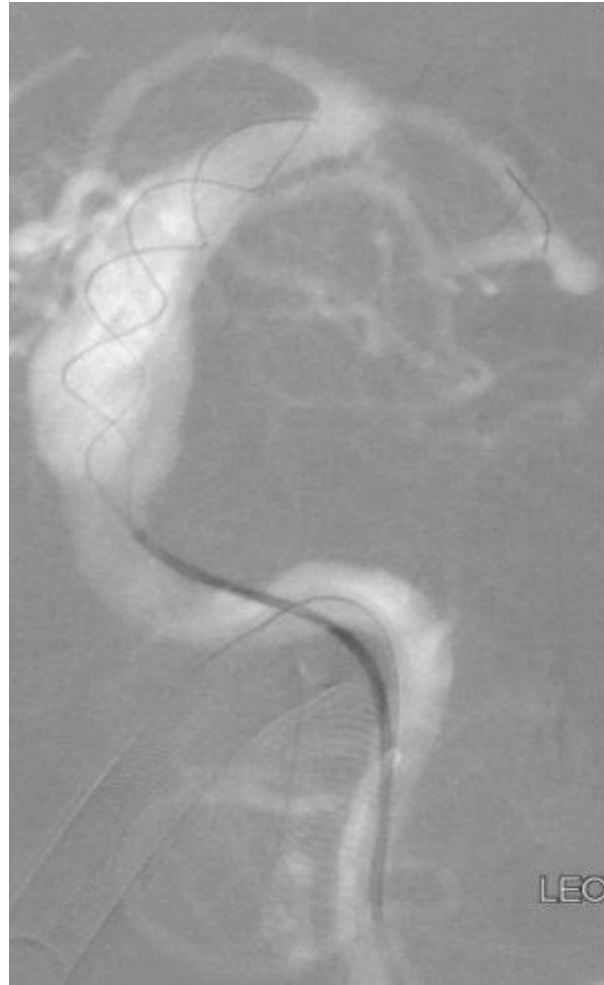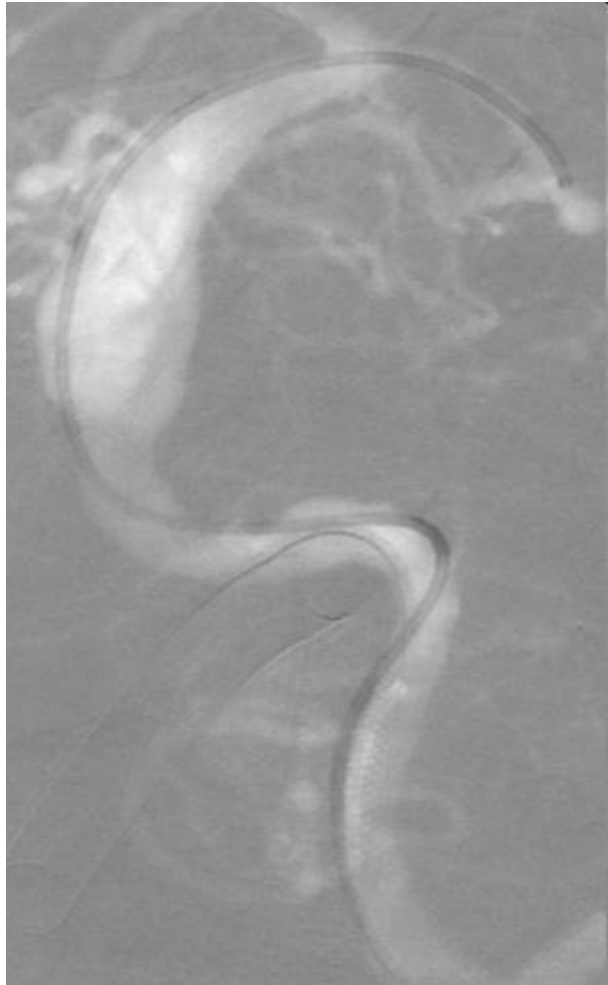
# ICA



# Length Measurement

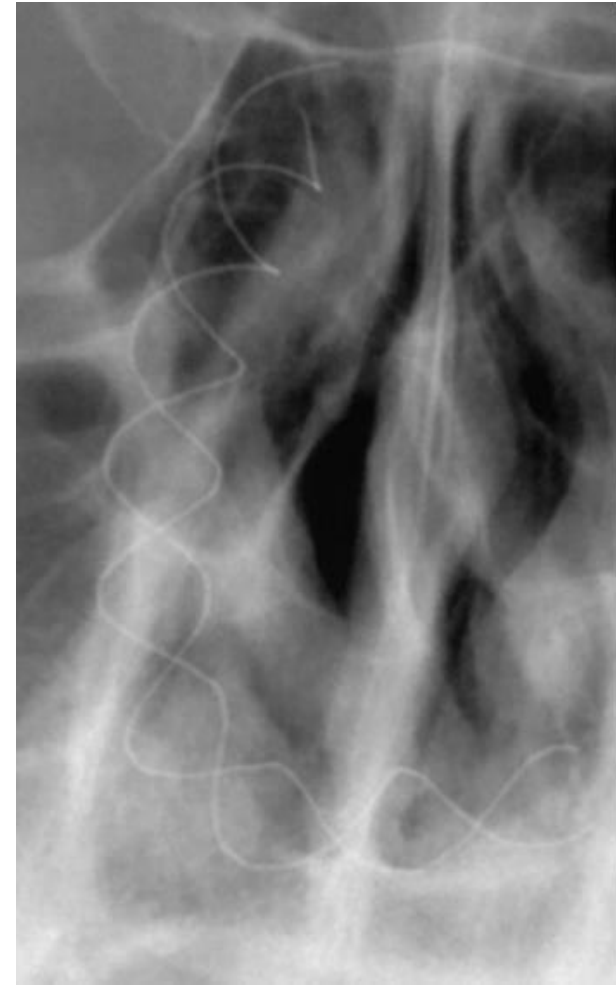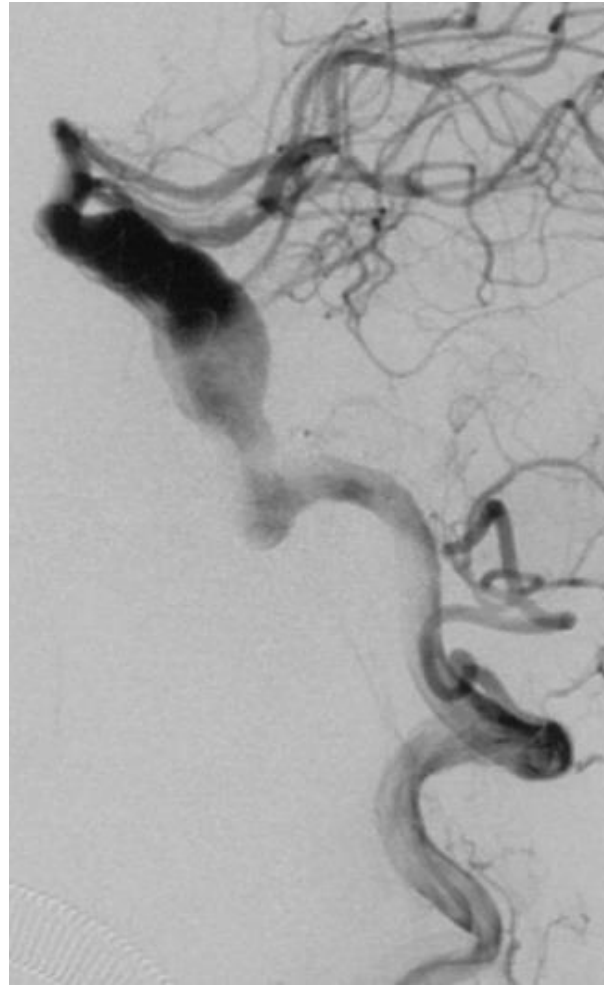
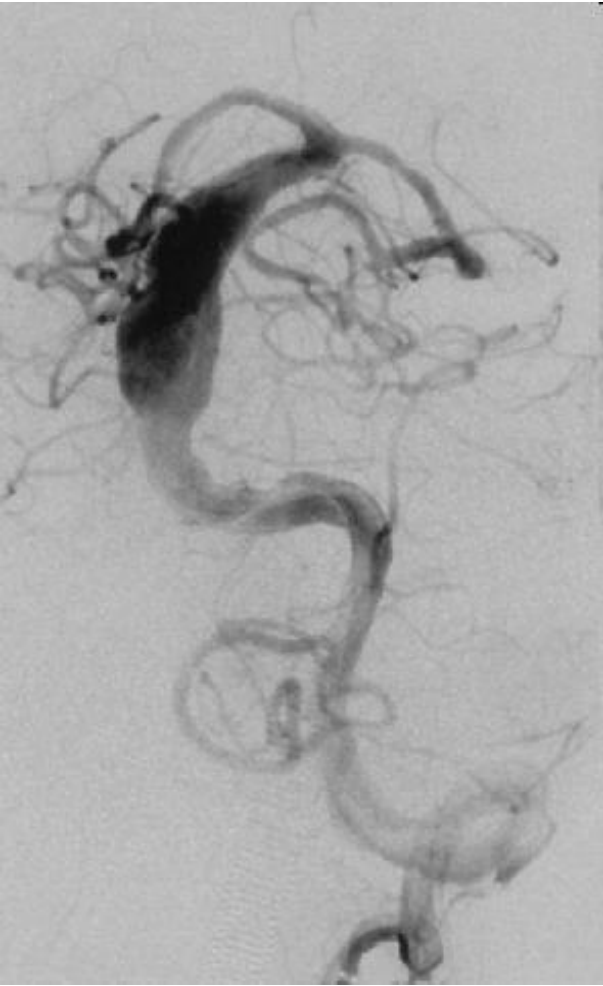


# Leo 5.5/75 stent implantation

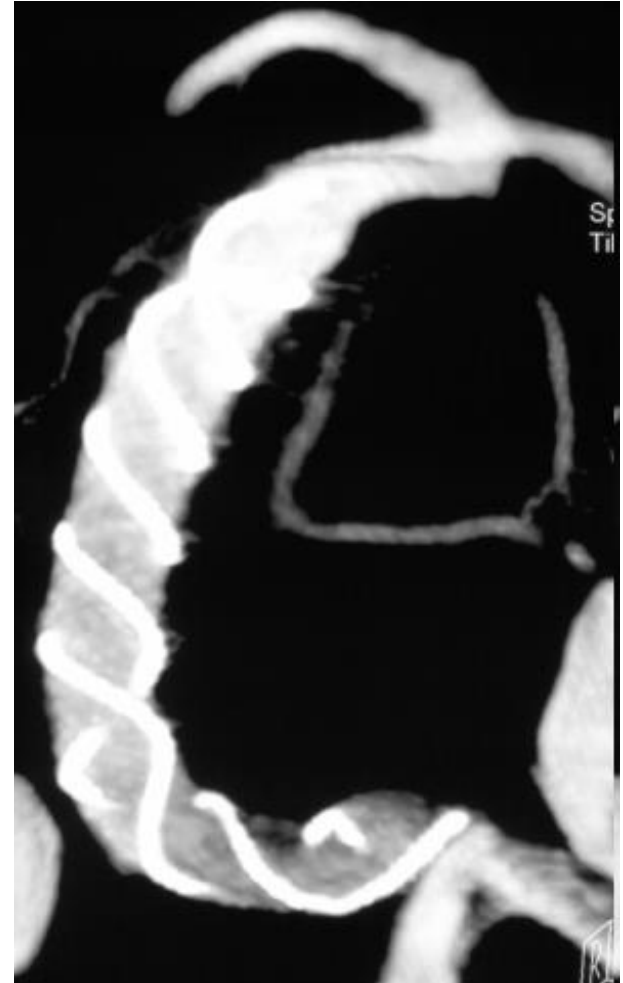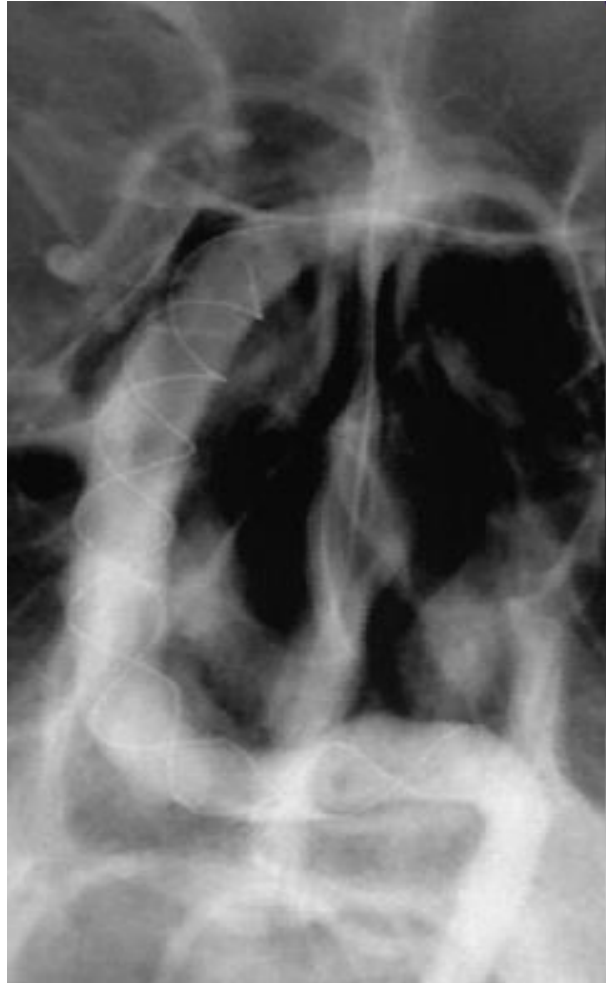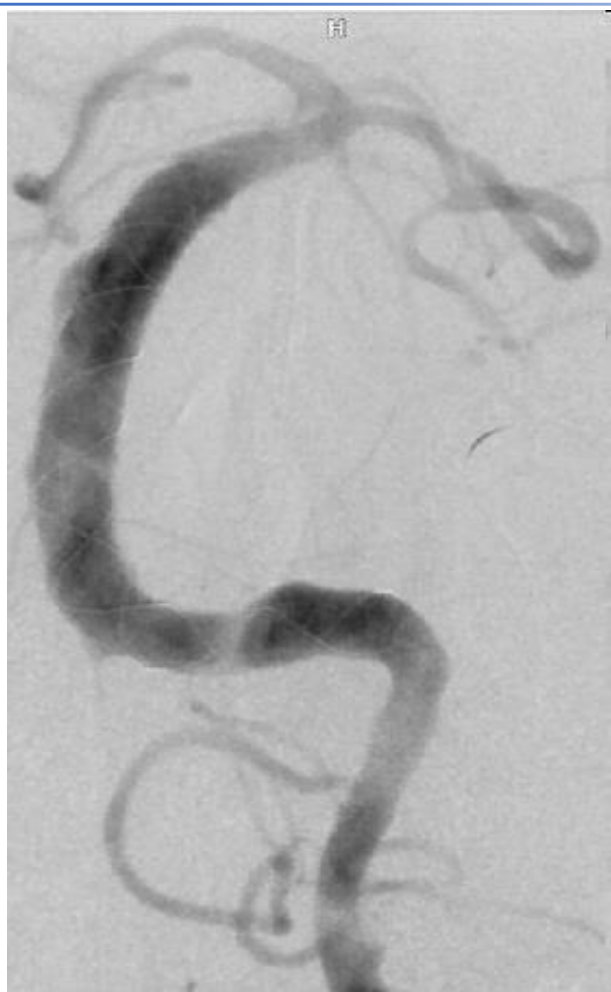




# Immediate Results



# 45 days Follow-up



# Thanks !



Changhai Hospital | Shanghai, China