



Changhai Hospital | OCIN

# Covered stent for ICA Blood Blister-like Aneurysms



# Clinical Data

---

Female , 65Y

CC : Sudden onset of headache

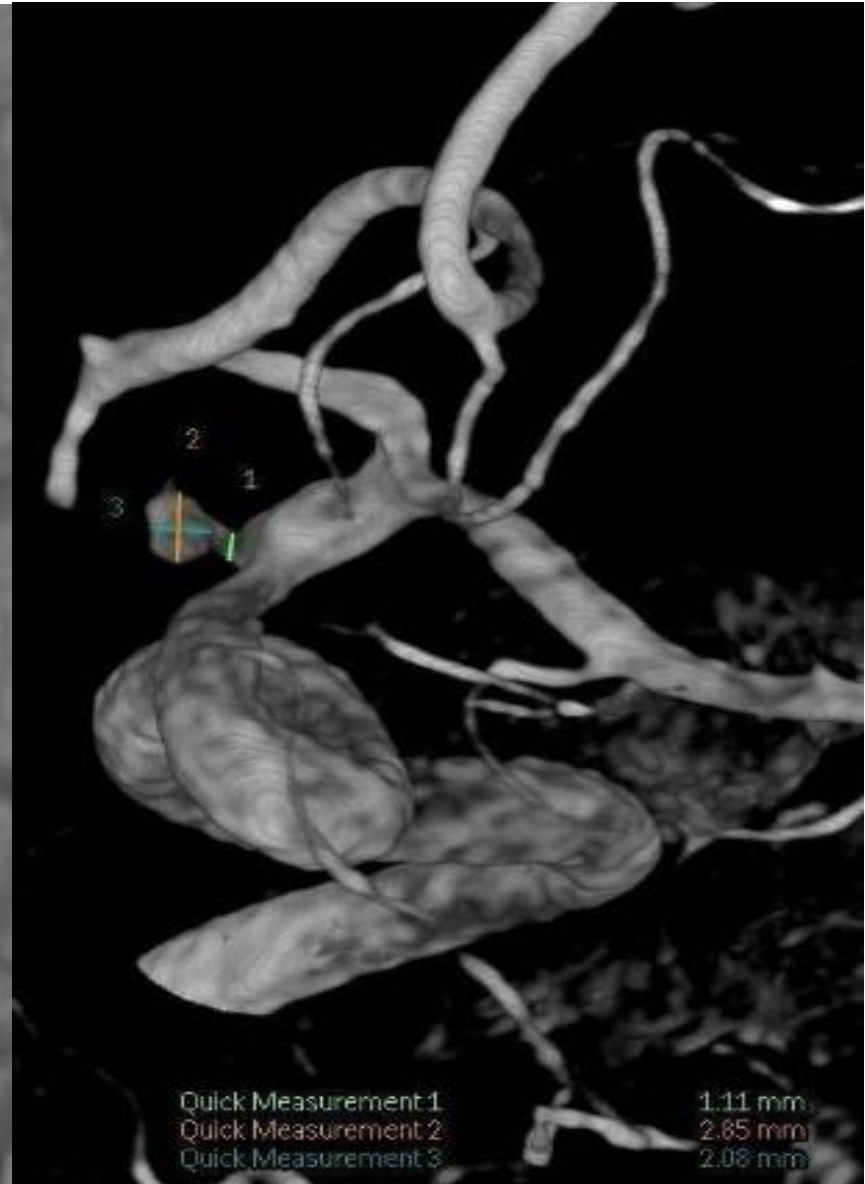
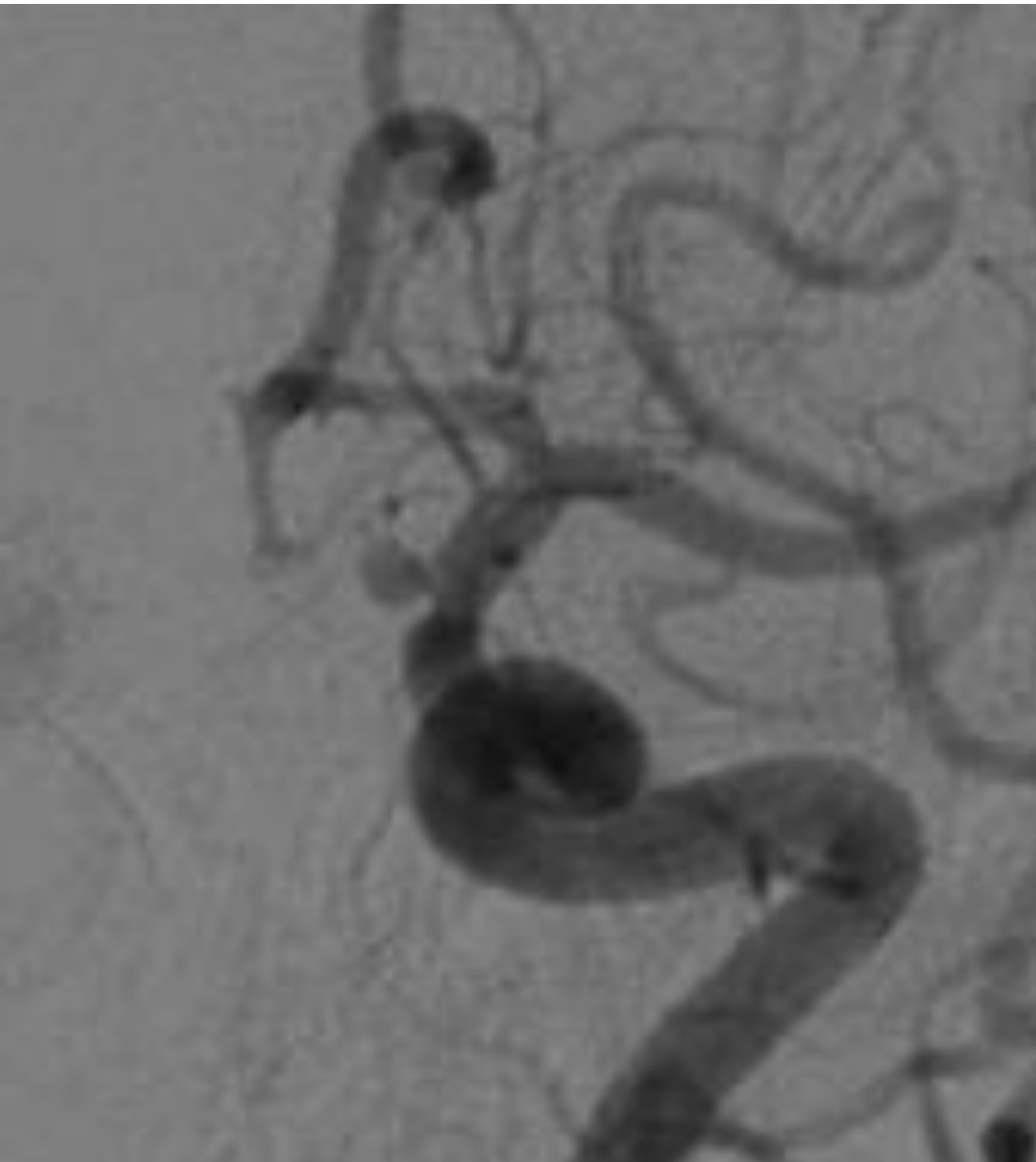
PE : H&H 2, stiff neck

PH : Hypertension, DM

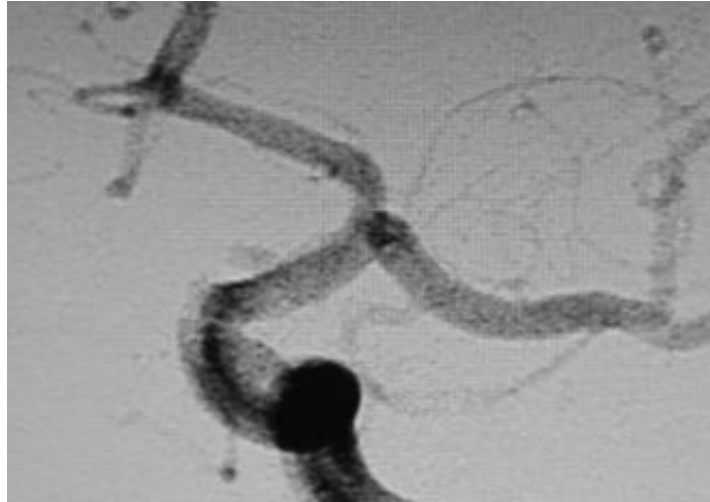
DX : Subarachnoid hemorrhage



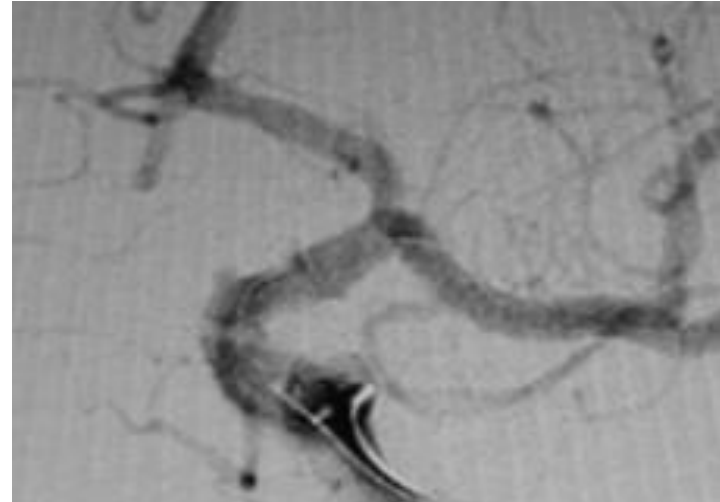
# DSA 2014-10-12



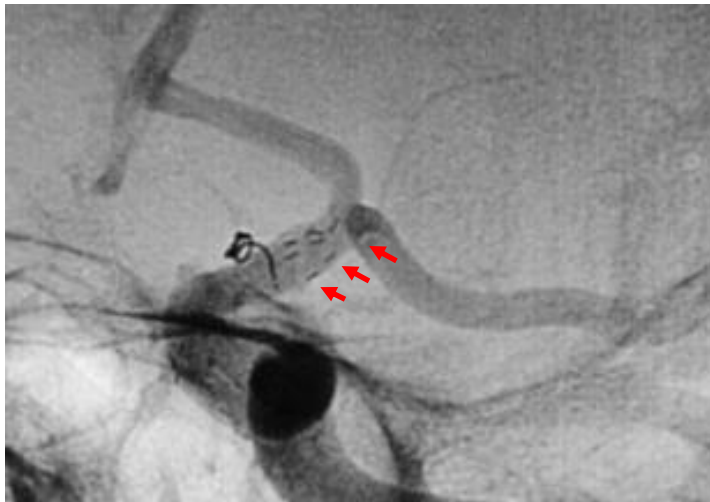
# DSA 2014-10-14



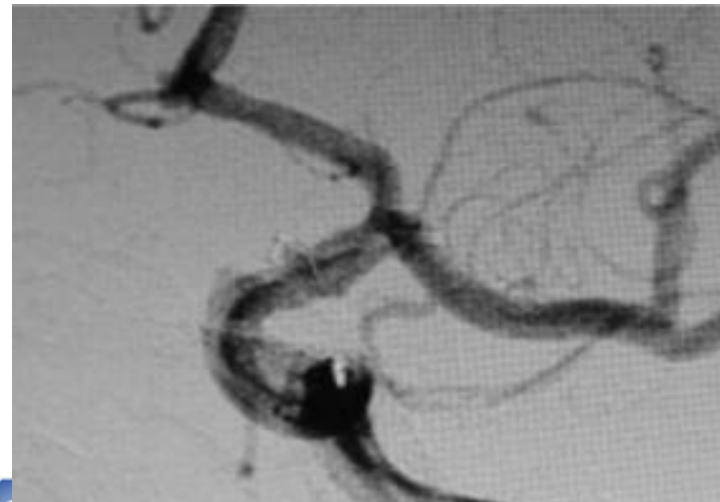
Changed aneurysm shape



Coiling under modified jailing

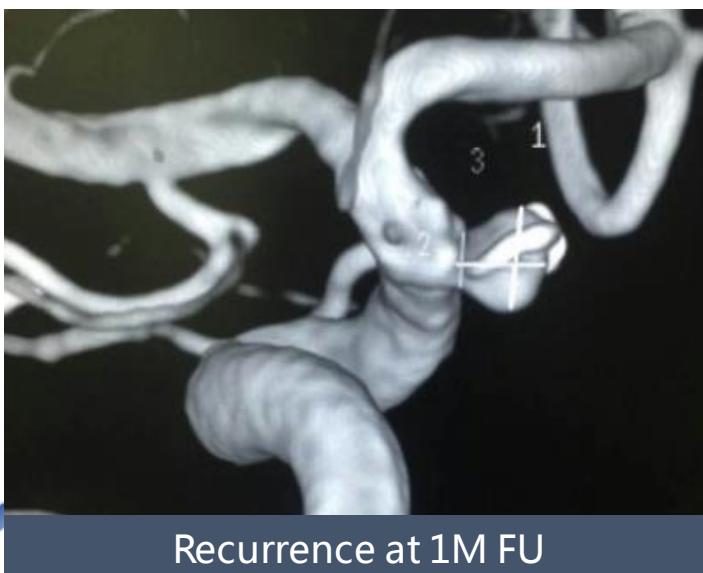
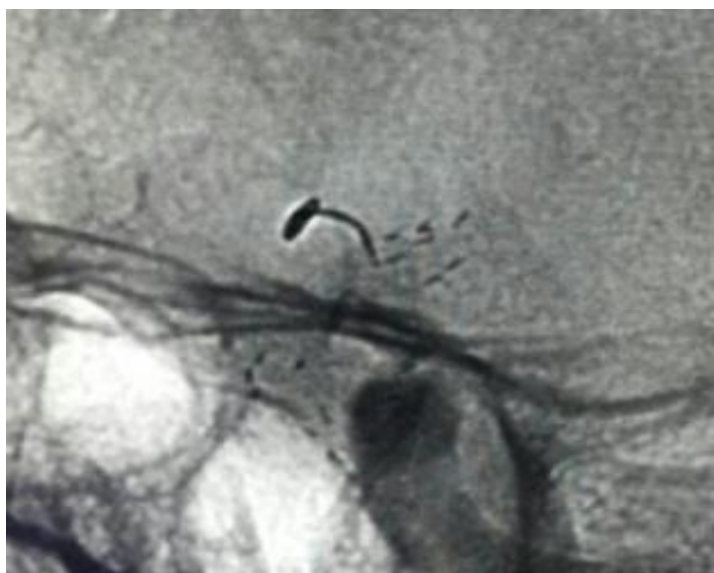
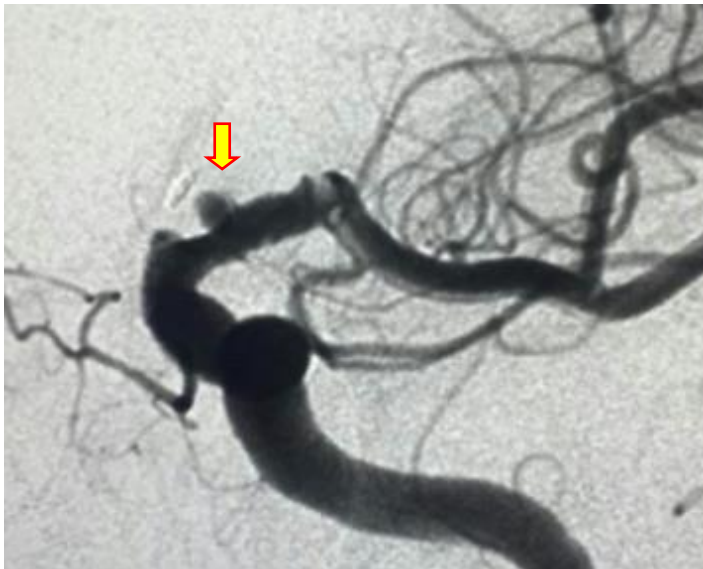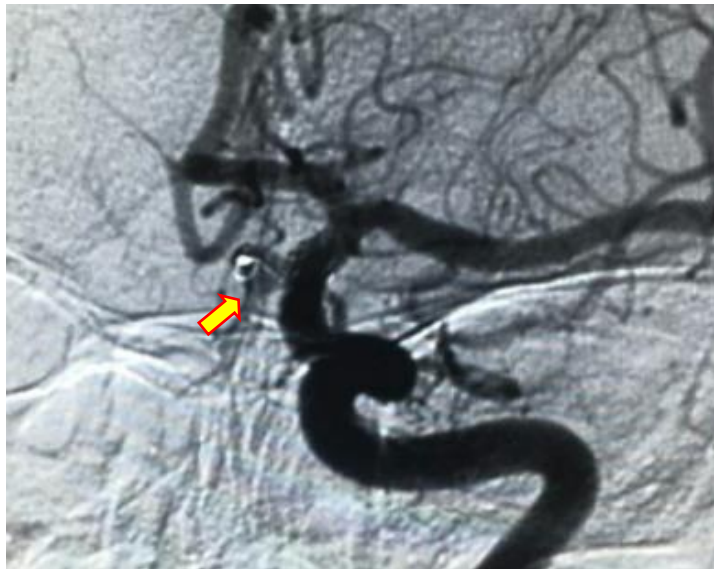Triple overlapping Enterprise stents



Final result

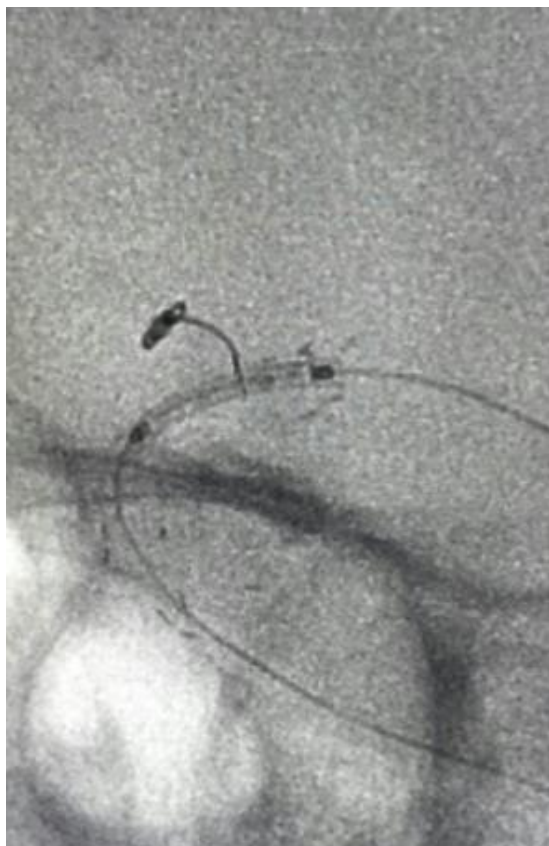
# DSA 2014-11-16



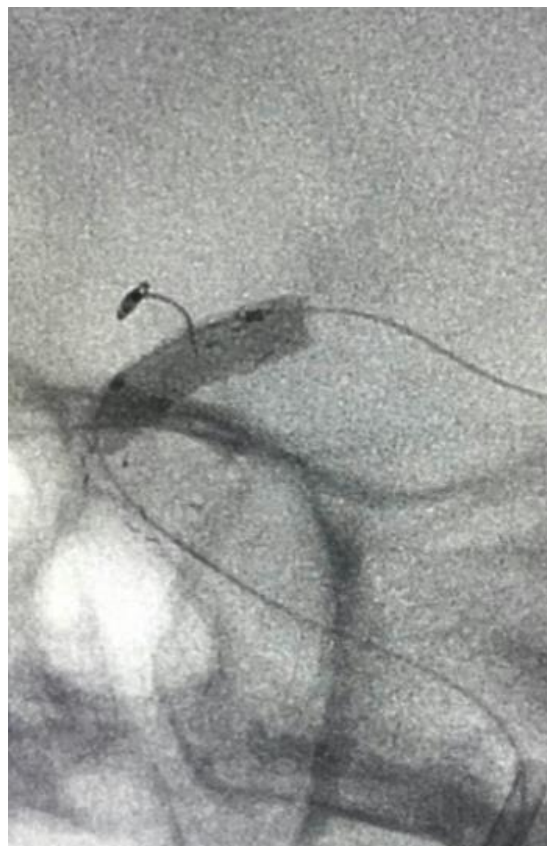
Recurrence at 1M FU

Shanghai, China

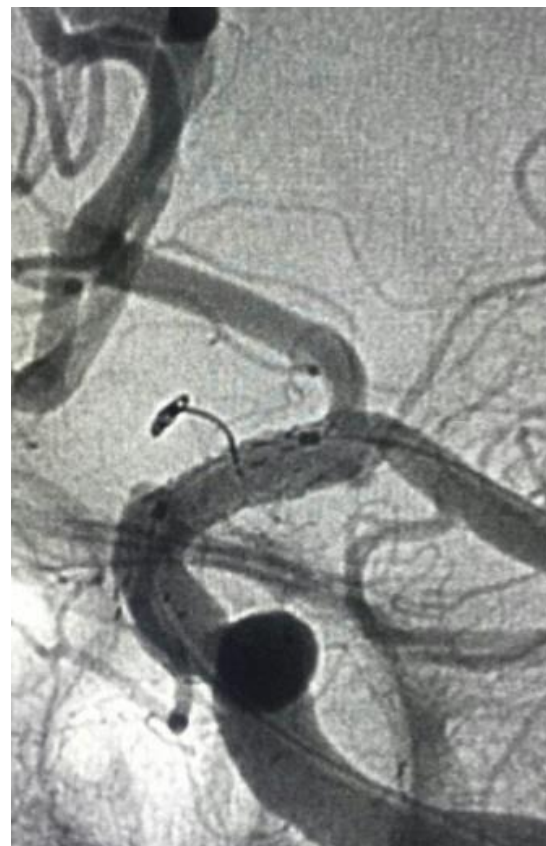# DSA 2014-11-17



Willis covered stent



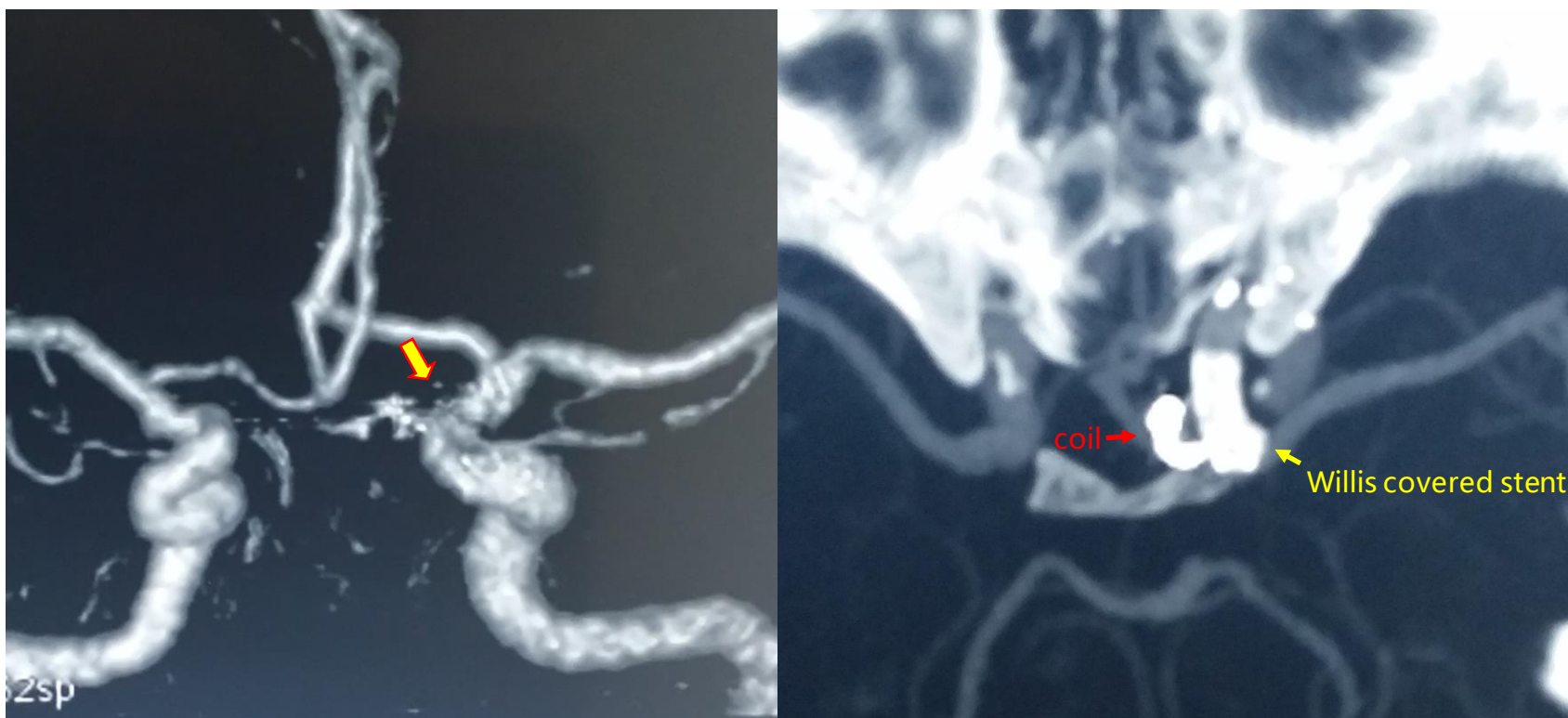
Willis covered stent



BBA totally occluded



# DSA 2015-02-02



Total occlusion at 3M CTA FU, mRS 0



# Thanks !



Changhai Hospital | Shanghai, China