



Changhai Hospital | OCIN

Overlapping stents for ICA Blood Blister-like Aneurysms



Clinical Data

Female , 44Y

CC : Sudden headache and transient unconsciousness

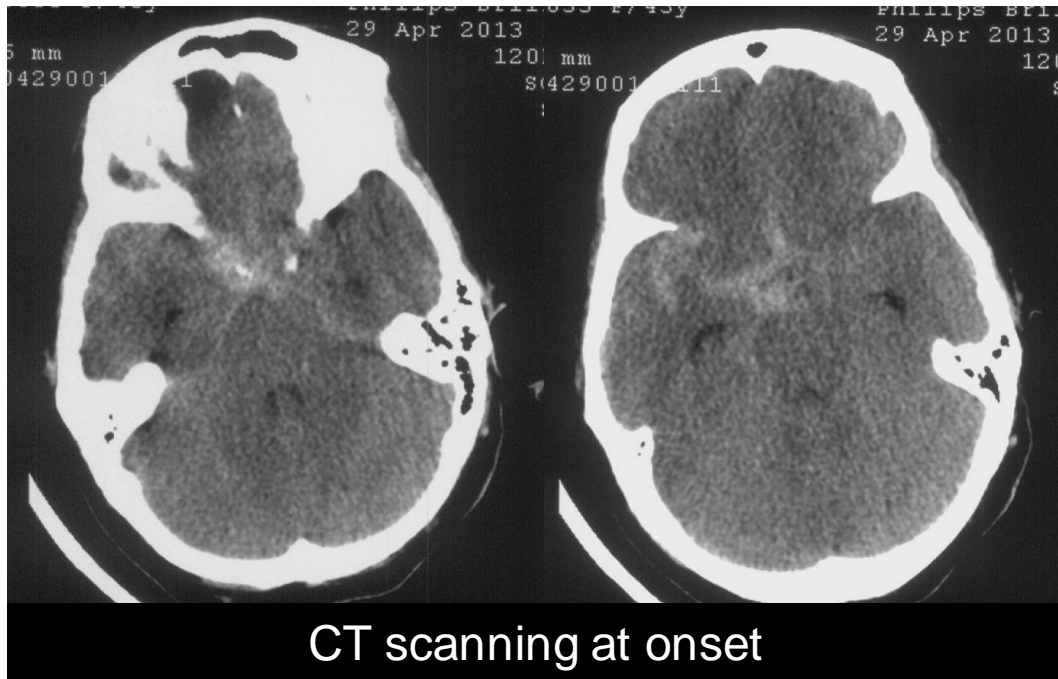
PE : H&H 3, drowsiness, stiff neck,

PH : Hypertension

DX : Subarachnoid hemorrhage



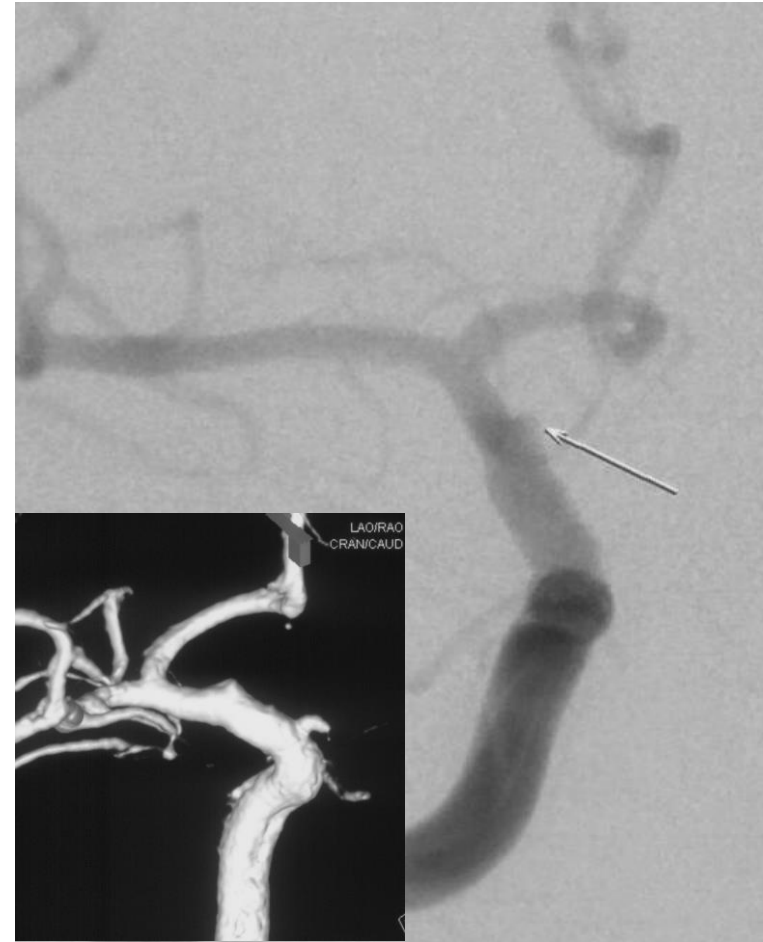DSA 2014-04-29



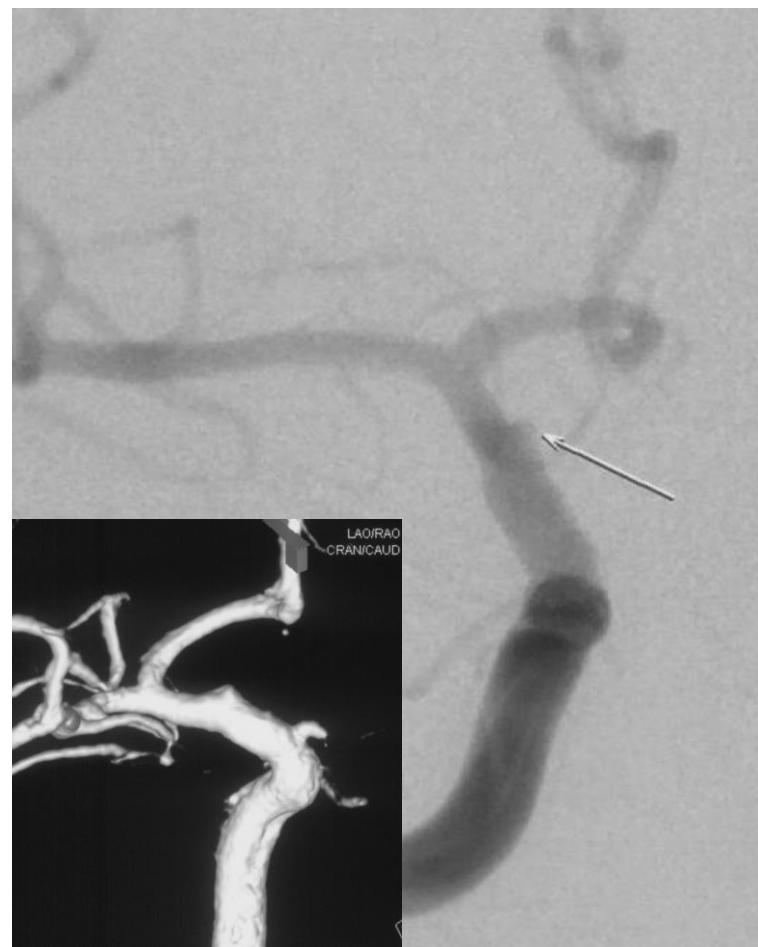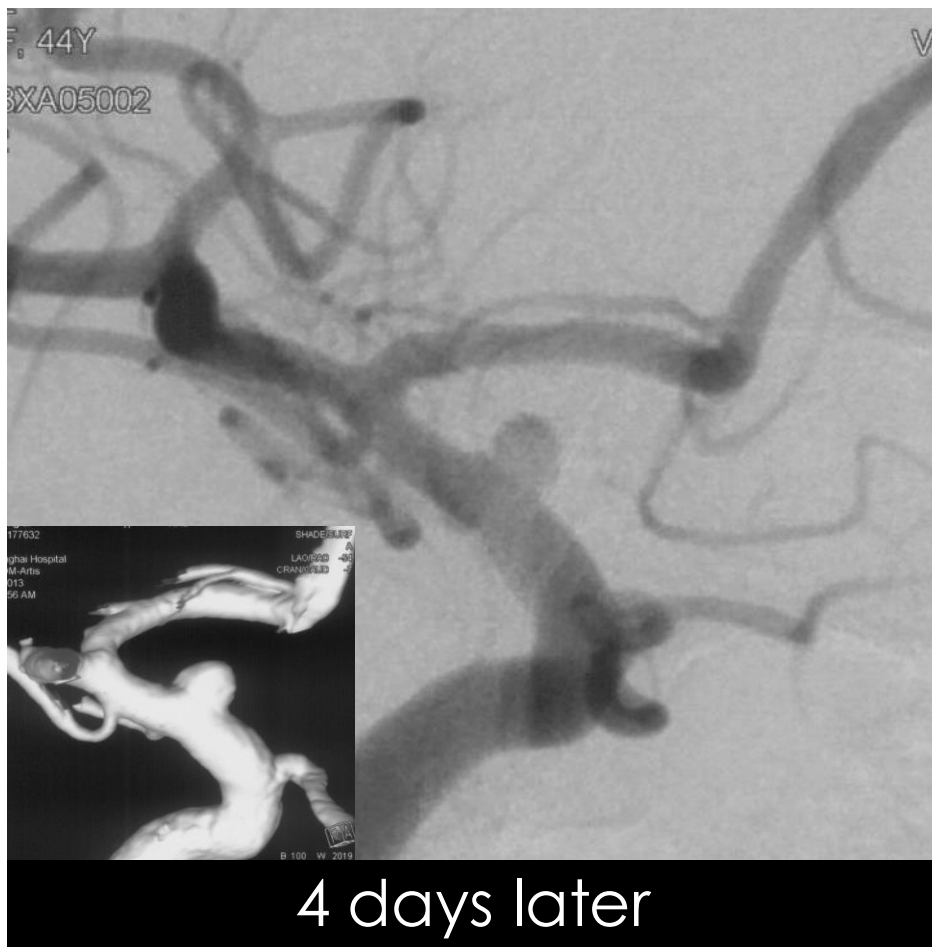Cardiopulmonary arrest after femoral puncture

No rebleeding was detected on dyna-CT.

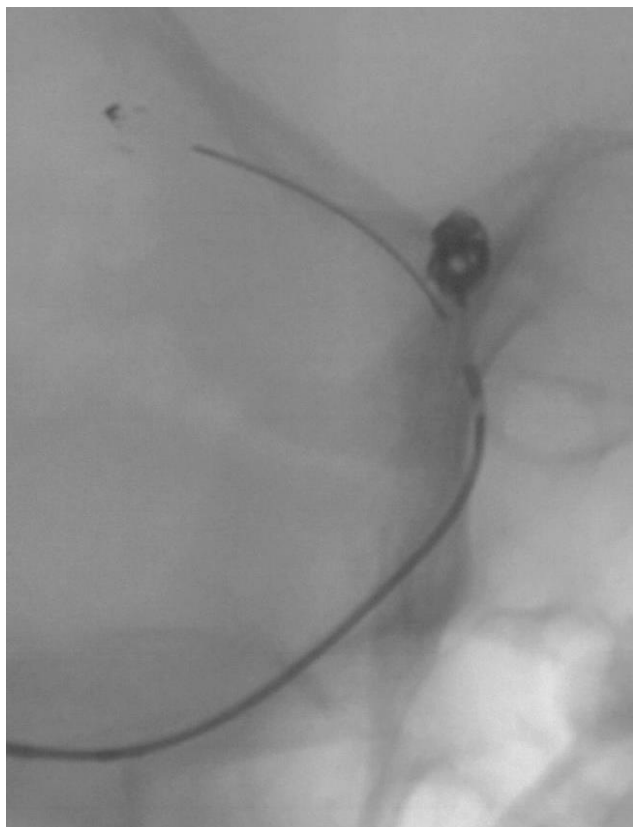
DSA revealed an anterior wall aneurysm



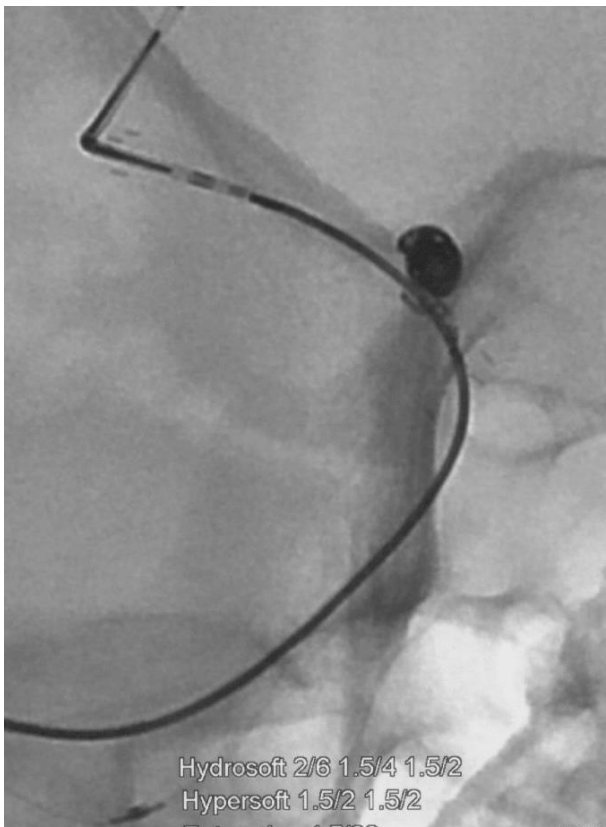
DSA 2014-05-03



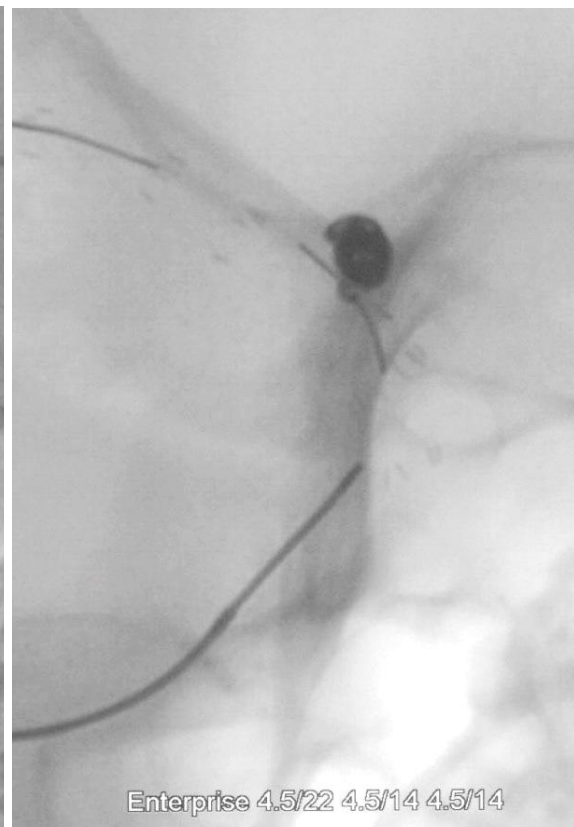DSA 2014-05-03



Coiling under modified jailing



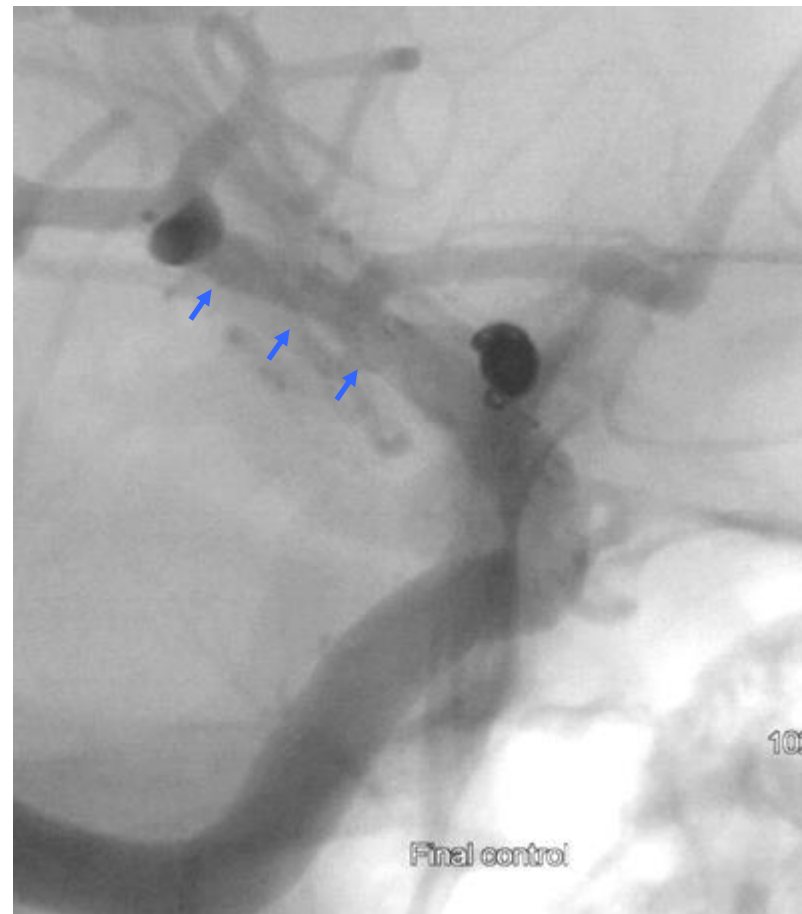
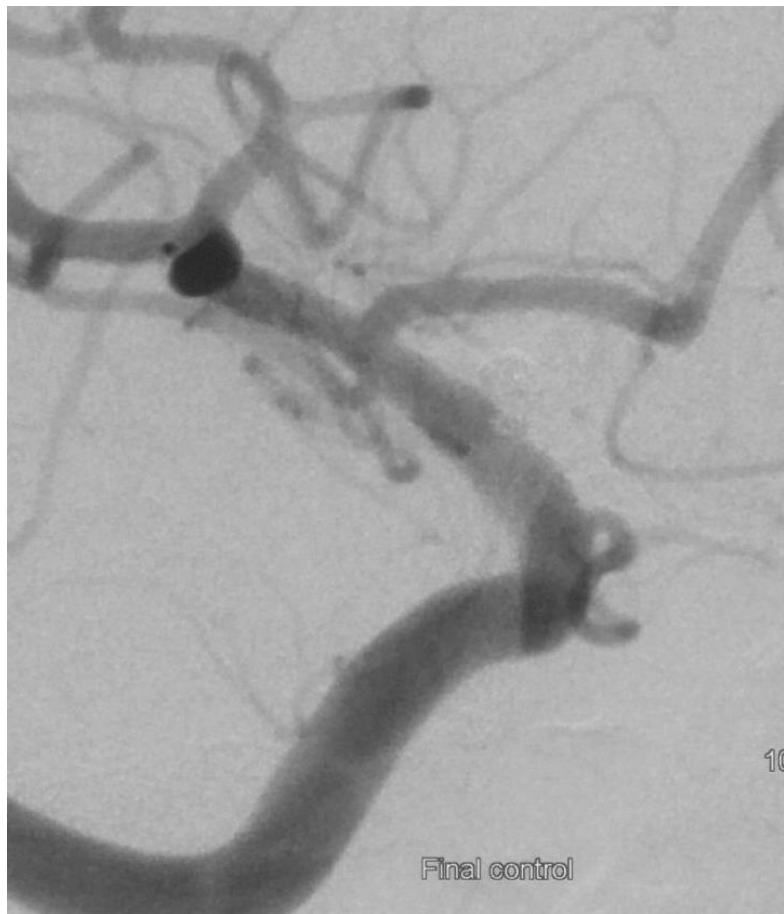
Total deployment of the stent



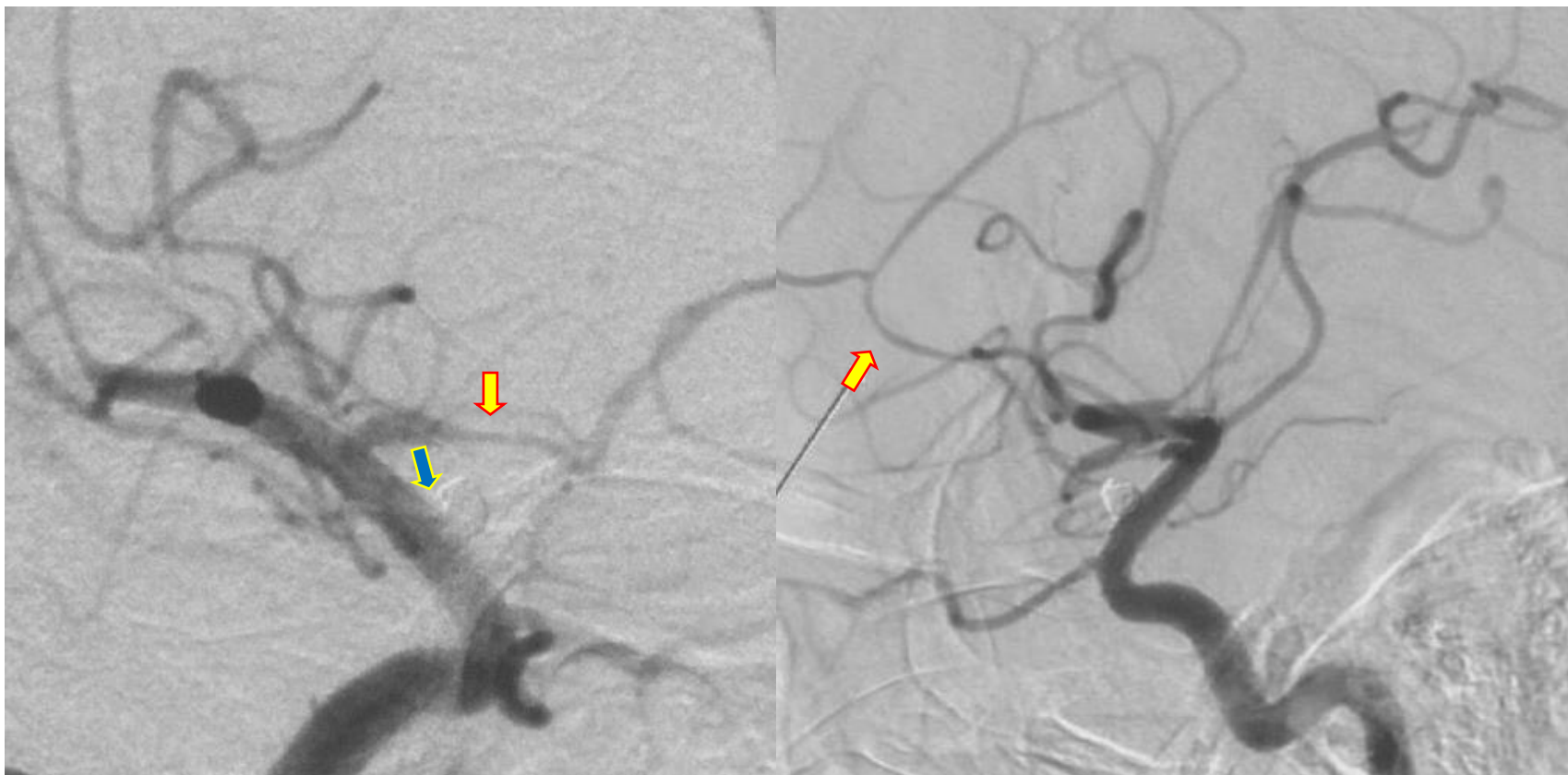Enterprise 4.5/22 4.5/14*2



DSA 2014-05-03



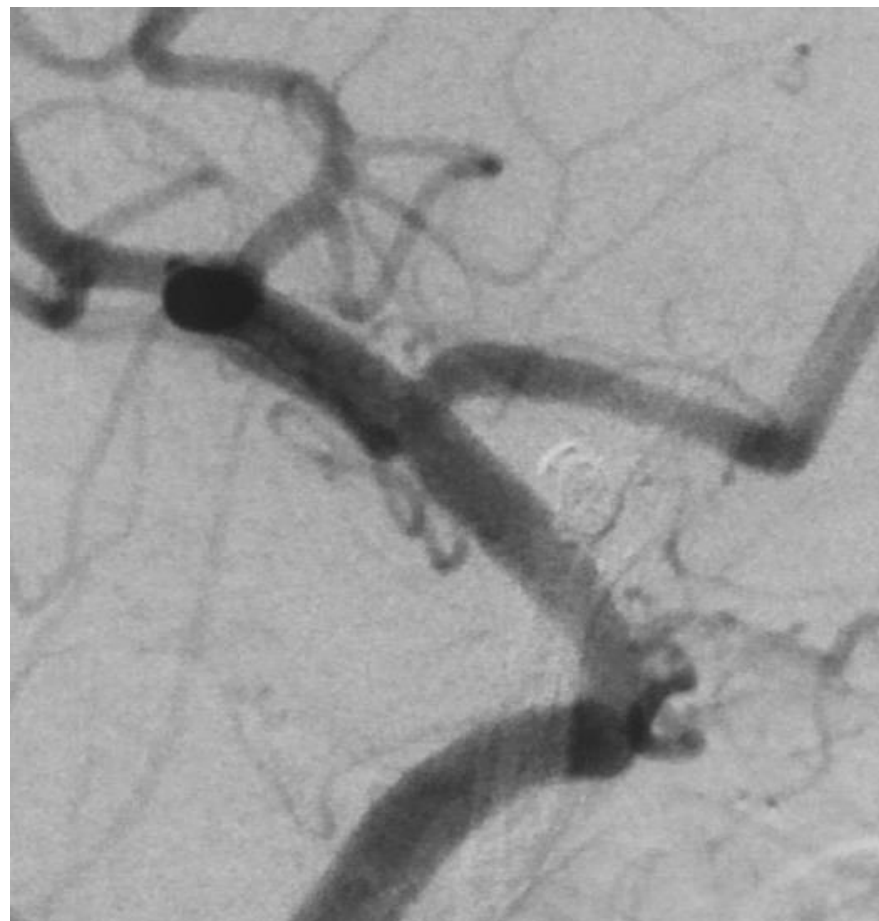
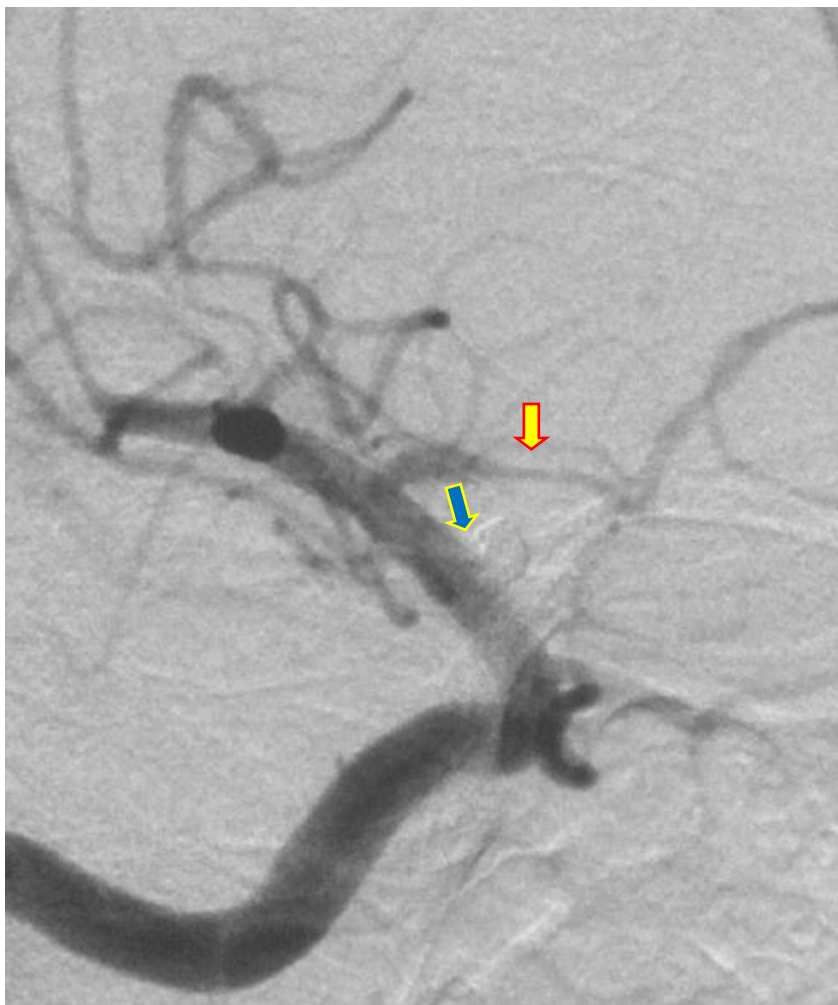DSA 2014-05-09



Total occlusion of the BBA ()
Severe CVS at bilateral ACA at 6th post-operative day ()



DSA 2014-08-03



Total occlusion at 3M FU



Thanks !



Changhai Hospital | Shanghai, China