

# Case #1

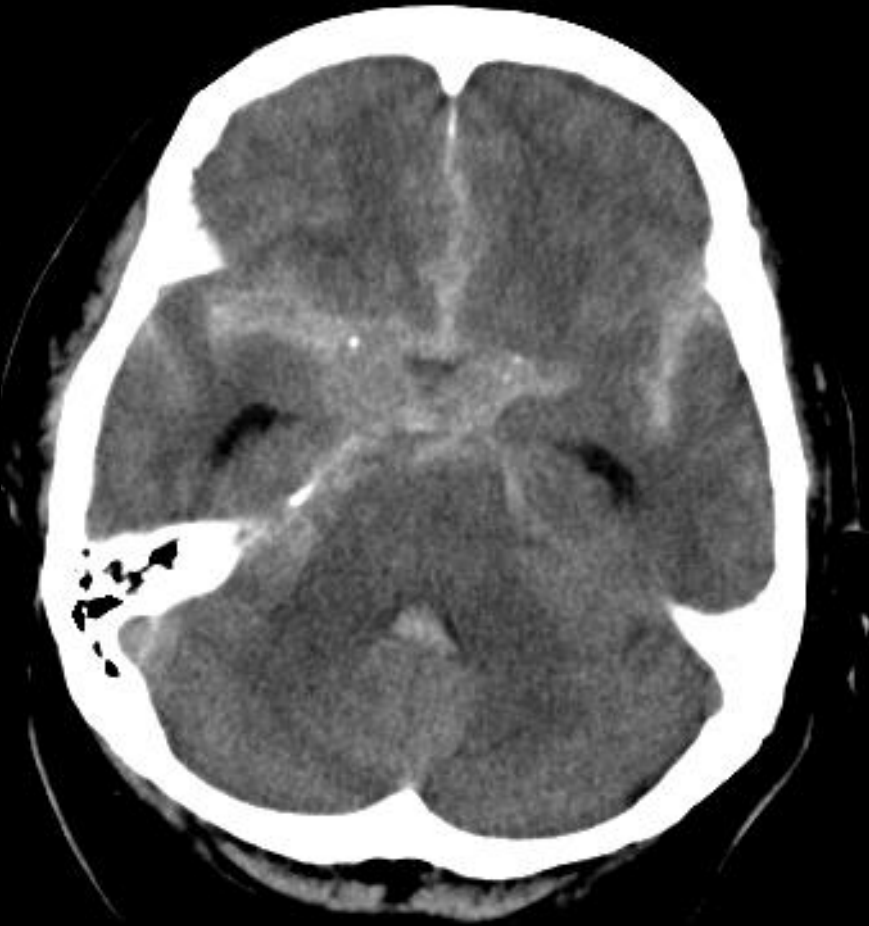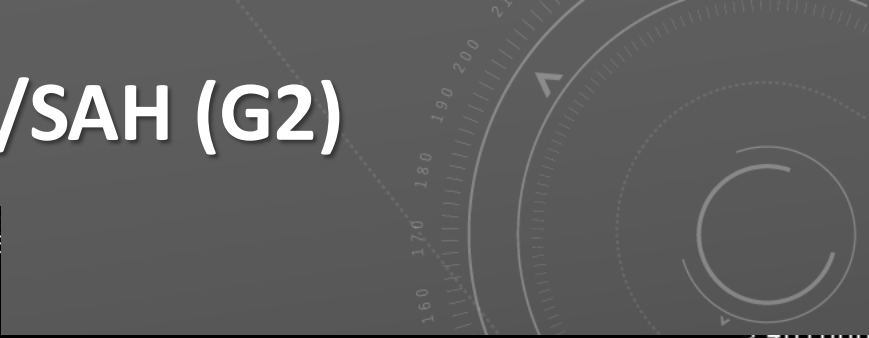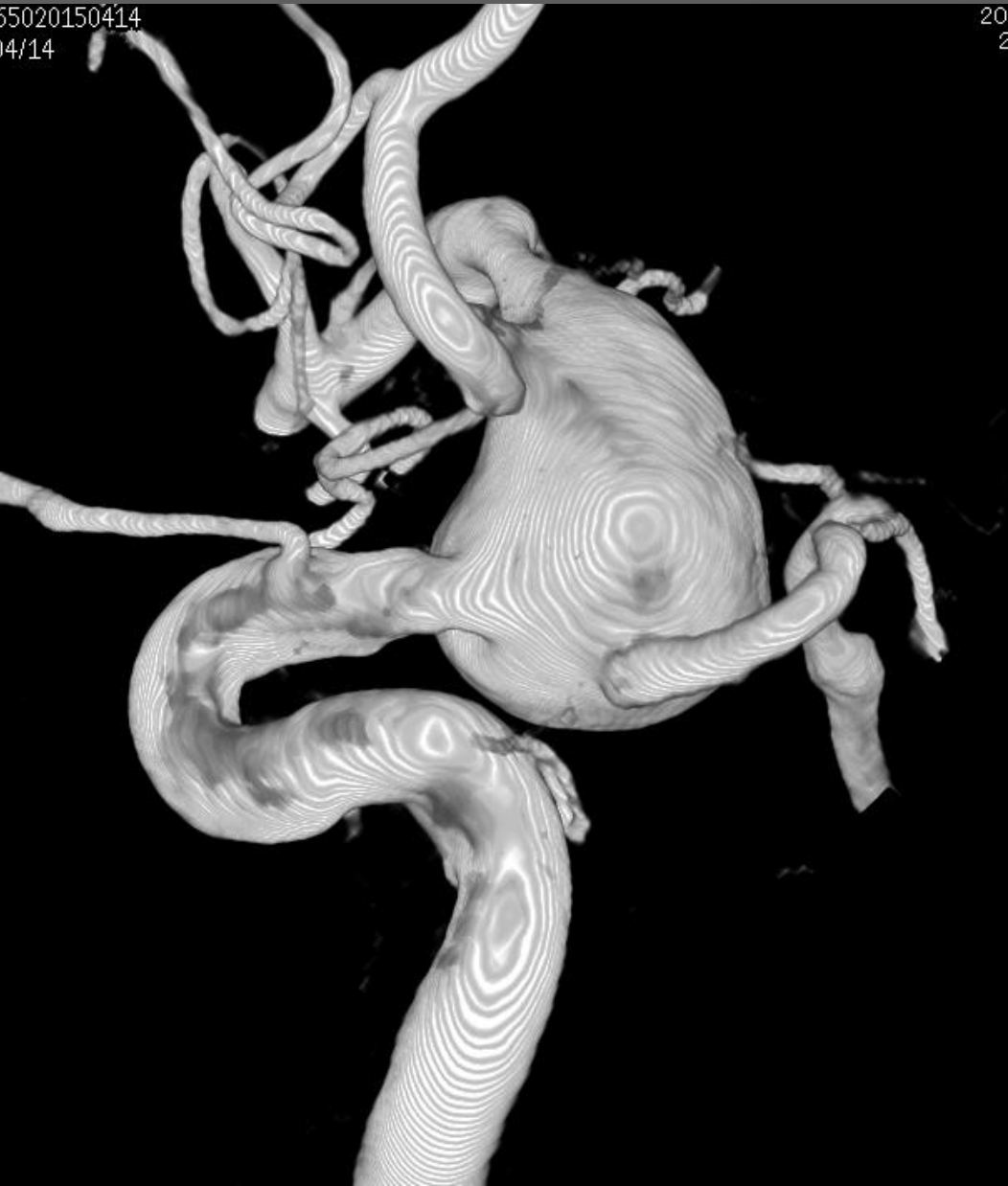
**How do you prevent rerupture with AchoA and PcomA patent?**

72F

ICA fusiform An/SAH (G2)

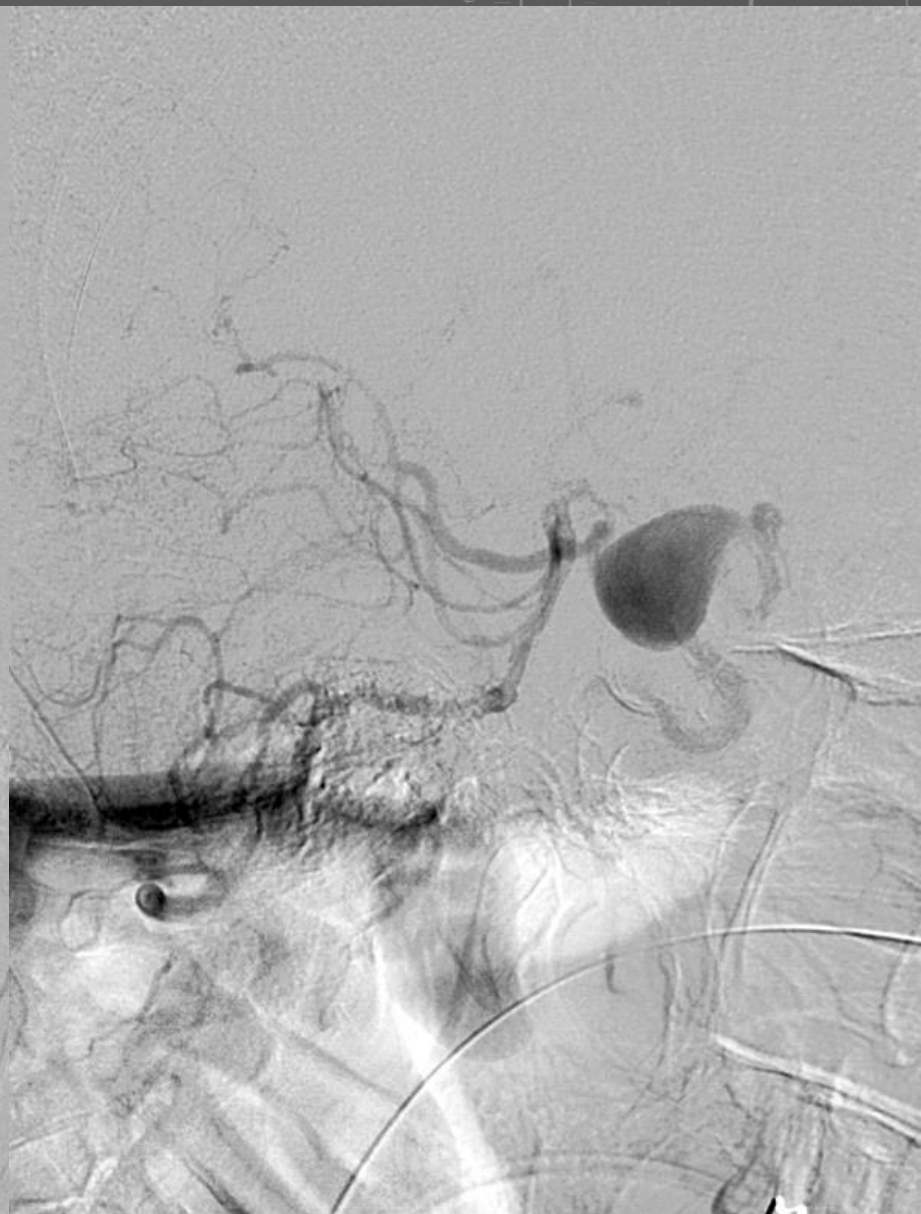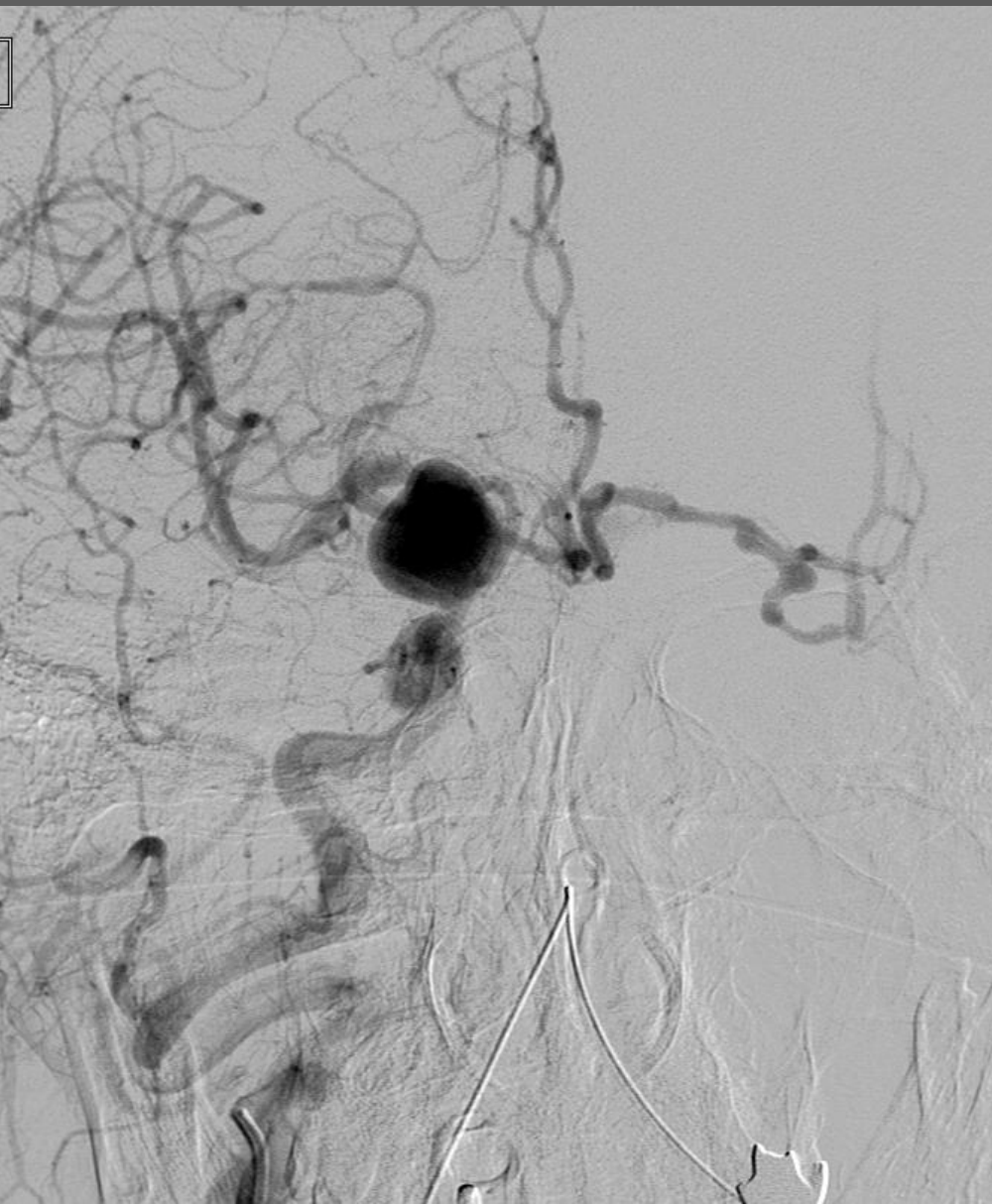
55020150414  
04/14

20  
2

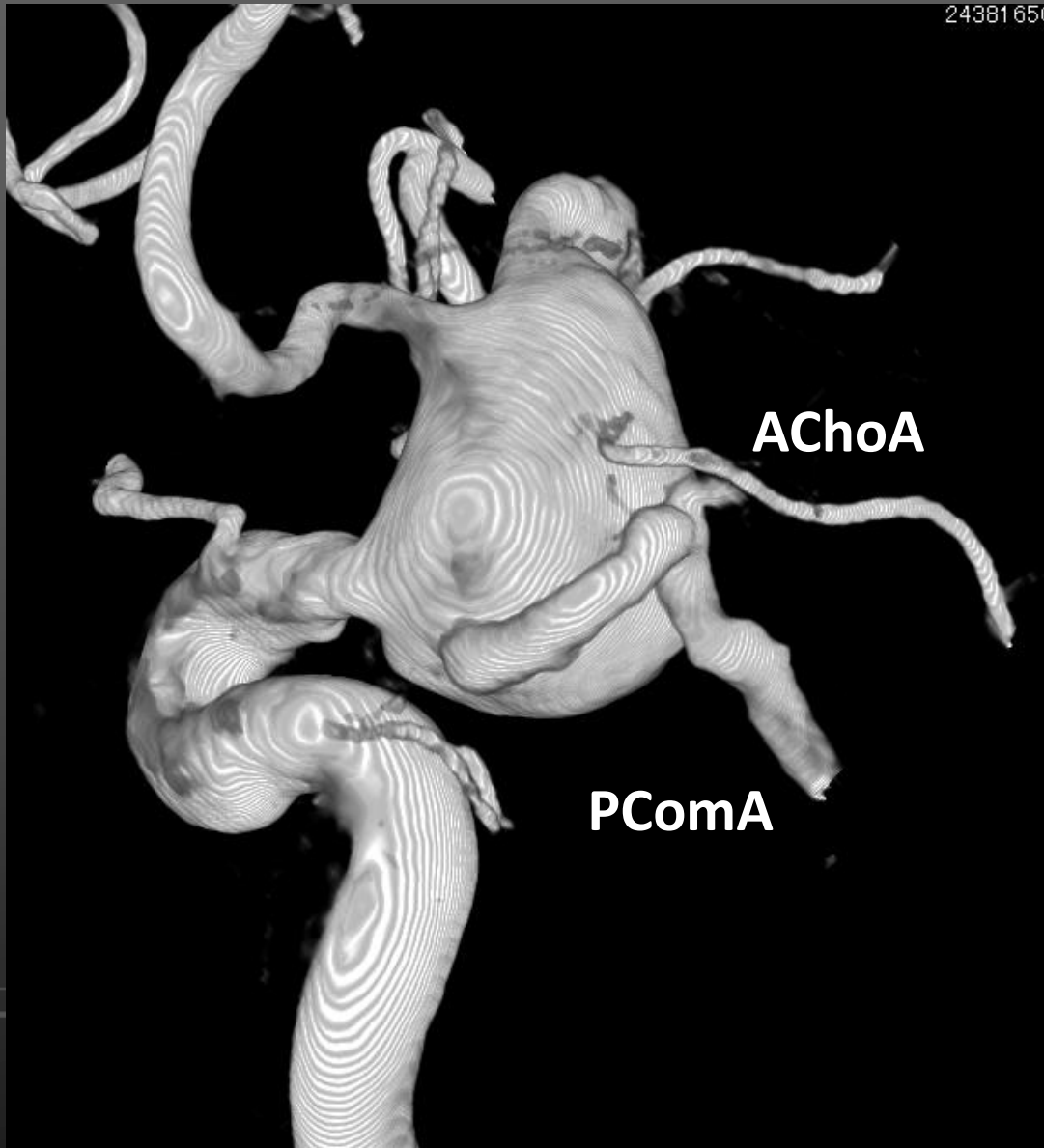


**Acom (+)**

**Pcom (+)**

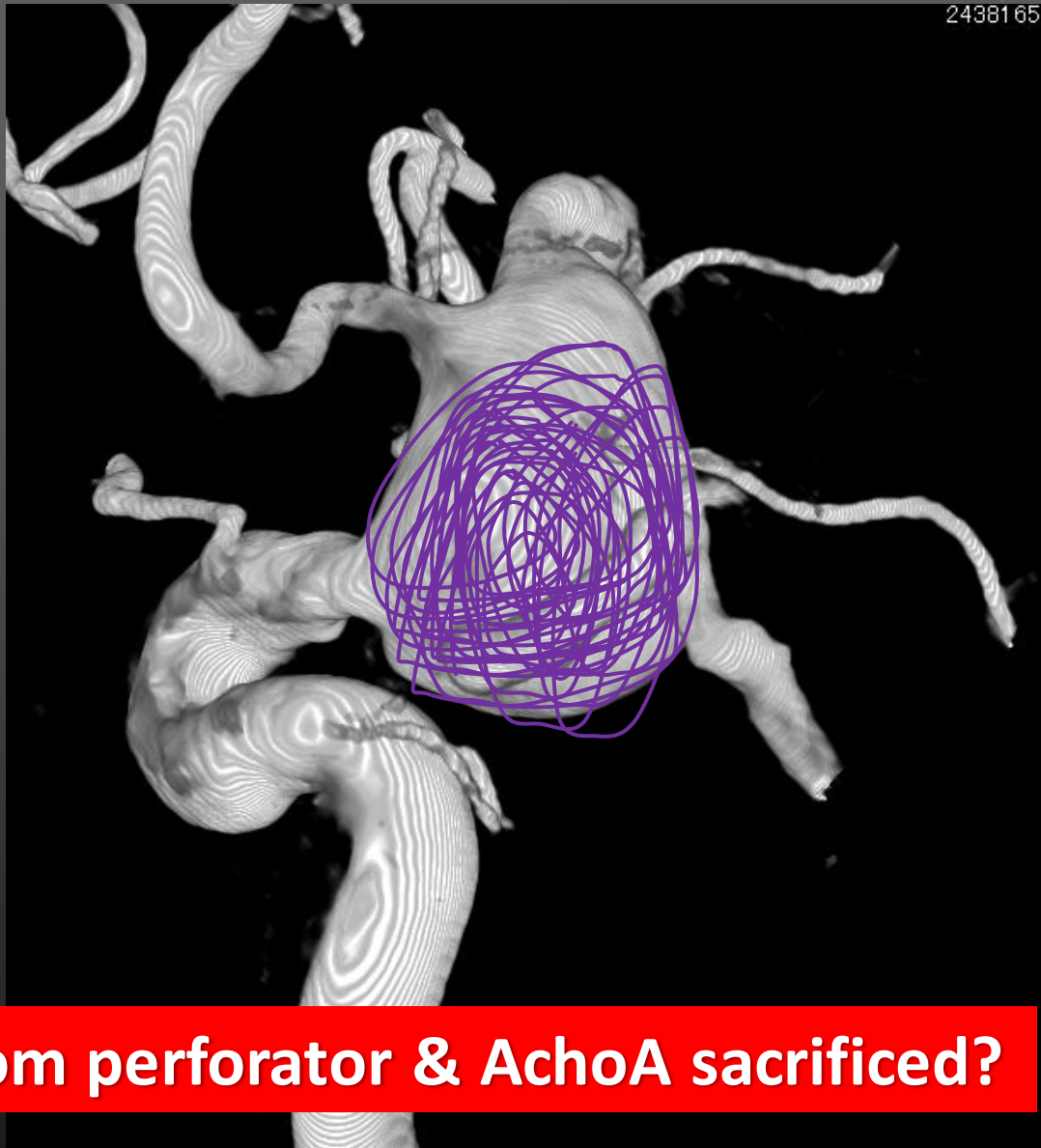

# How do you treat?



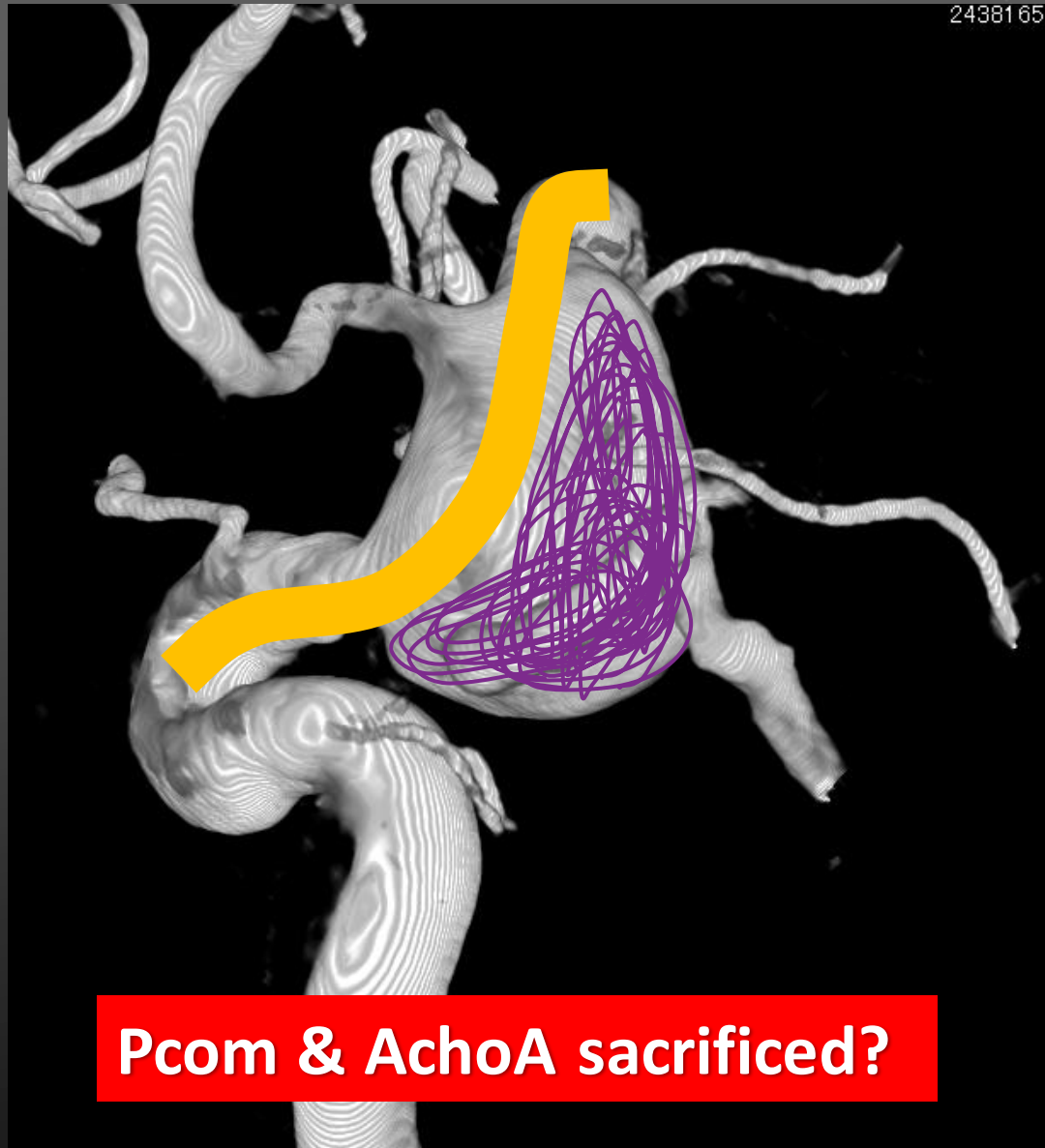- ✓ SAH (G2) 72yo
- ✓ ICA fusiform AN
- ✓ AChOA & PcomA from the dome
- ✓ Acom + PCom +
- ✓ FD inavailable at this point

# Parent artery occlusion (internal trapping)?

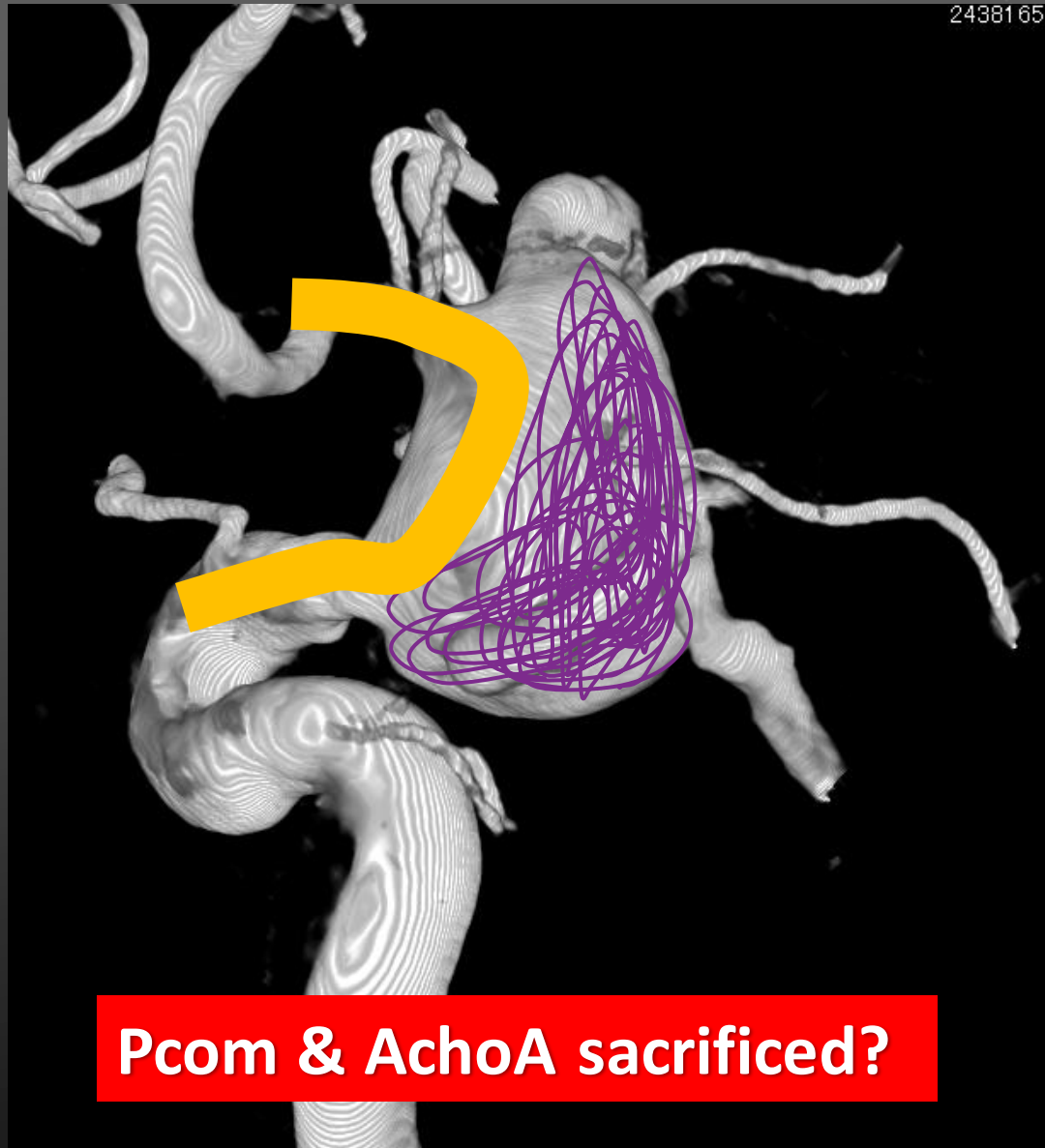

**Pcom perforator & AchoA sacrificed?**

# Stent-assisted embolization (M1 to ICA)



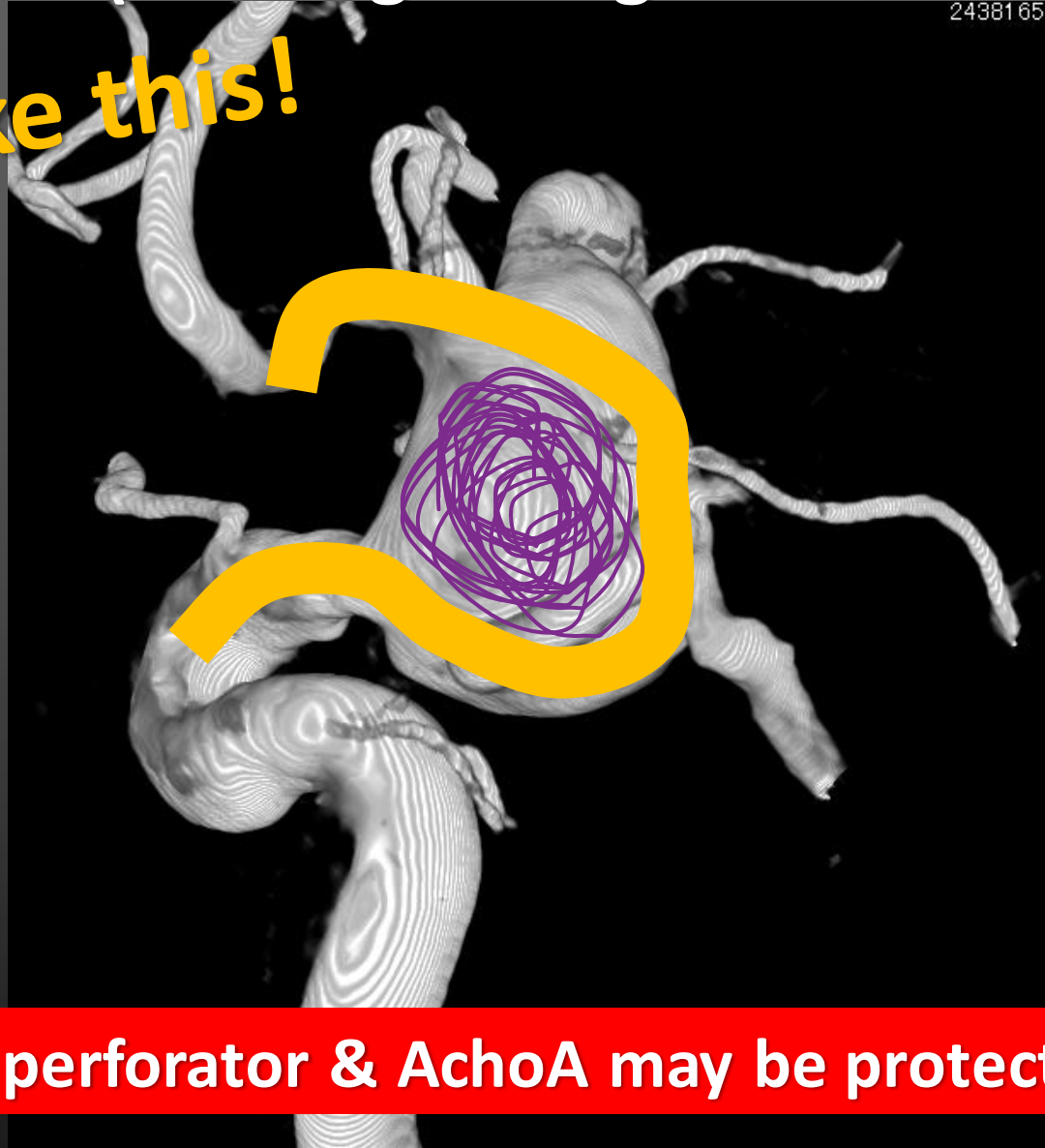# Stent-assisted embolization (A1 to ICA)



# Stent-assisted embolization (stenting through the dome)

24381650

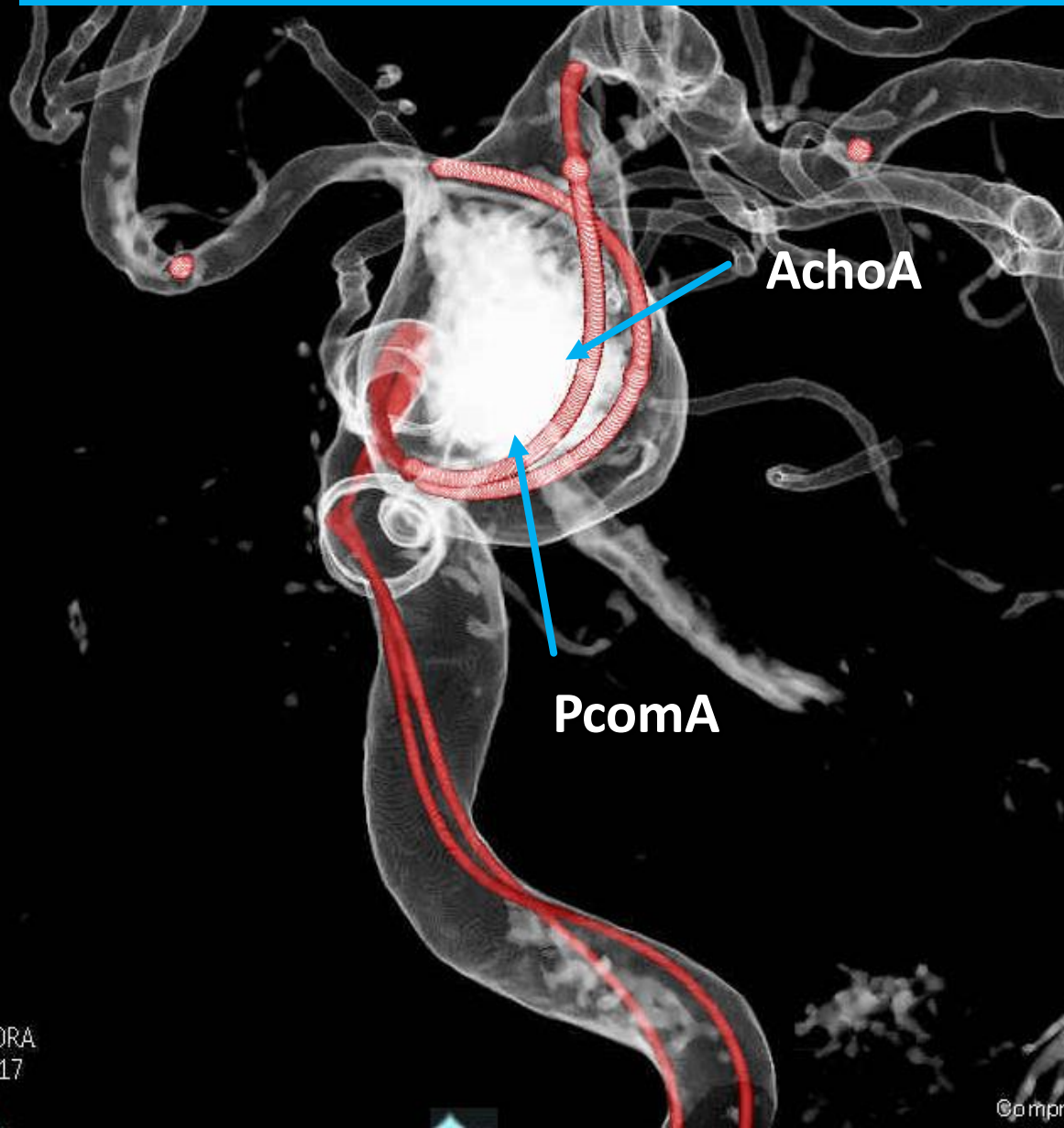
I did like this!



Pcom perforator & AchoA may be protected



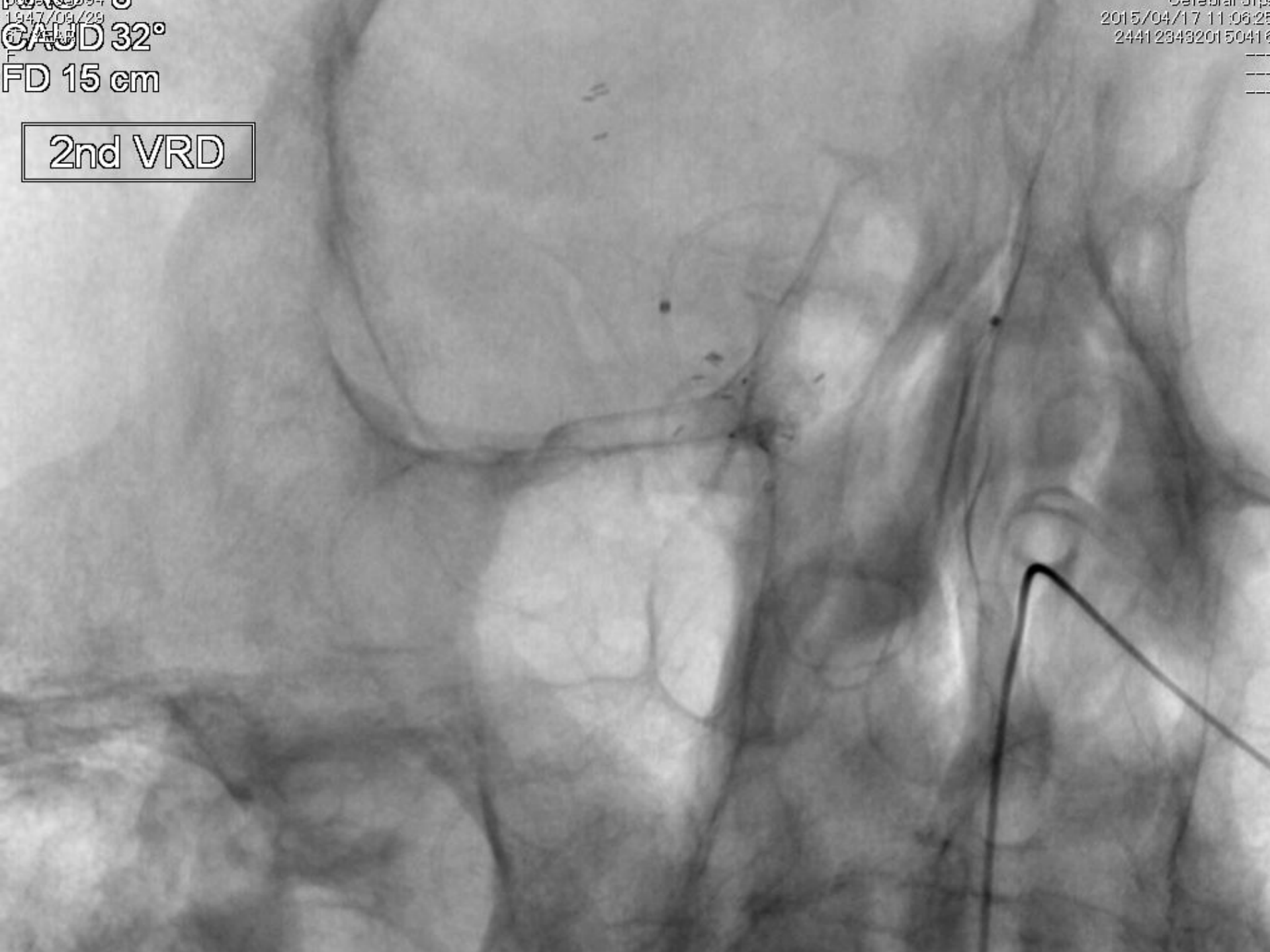Which routes are better to protect AchoA and PcomA, M1 to ICA or A1 to ICA?

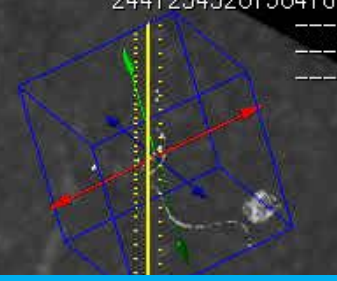

CAUD 32°  
FD 15 cm

2nd VRD

2015/04/17 11:06:25  
2441234320150416





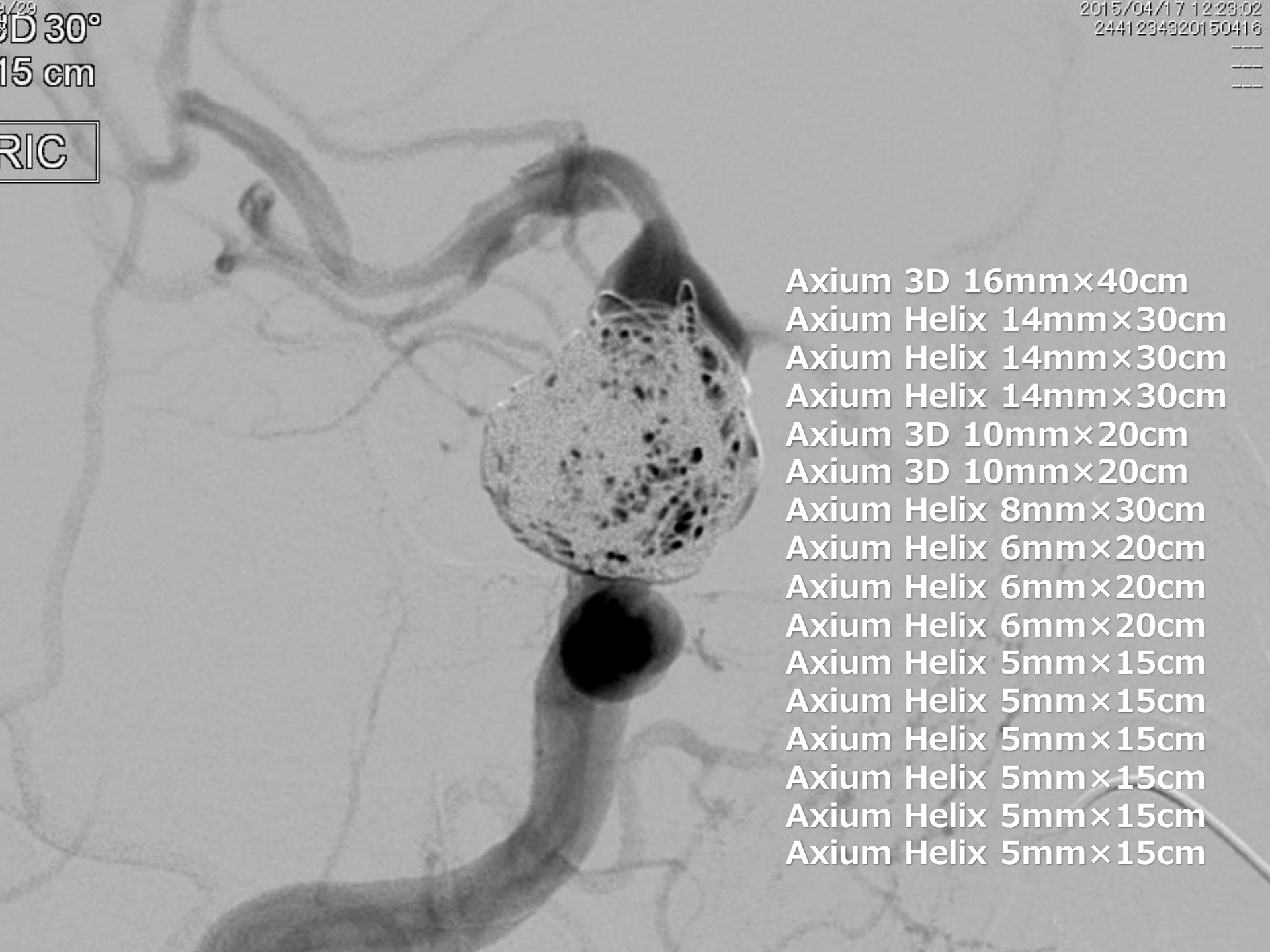
#1 EnterpriserVRD 37mm

#2 EnterpriserVRD 28mm

3D 30°  
15 cm

2015/04/17 12:28:02  
2441234320150416

RIC

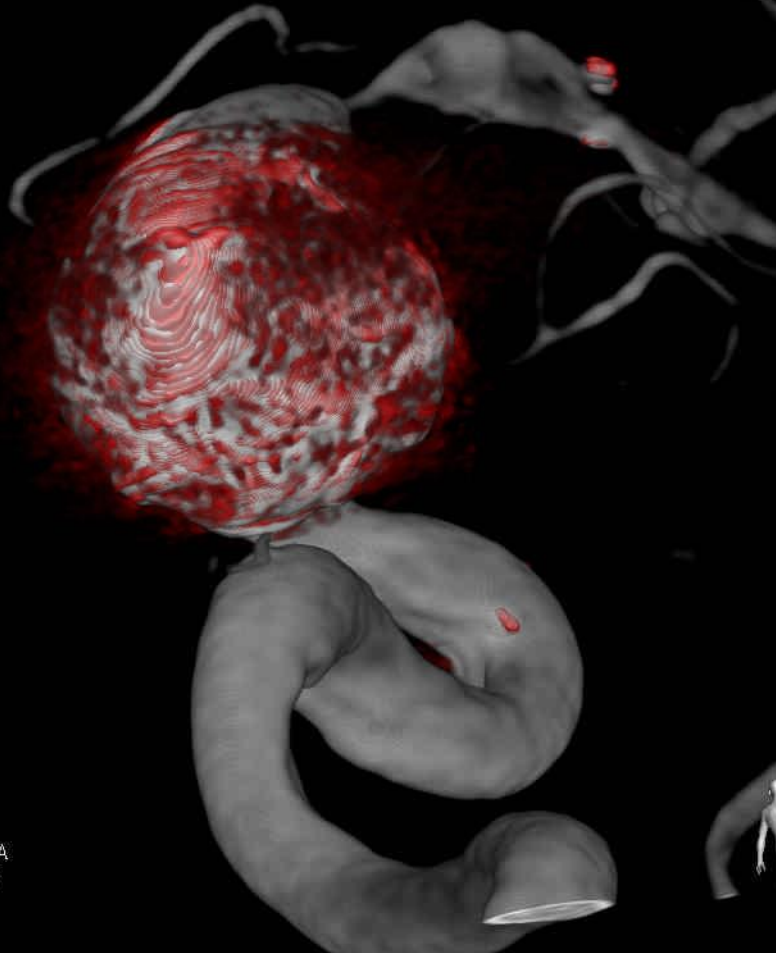


- Axium 3D 16mm×40cm
- Axium Helix 14mm×30cm
- Axium Helix 14mm×30cm
- Axium Helix 14mm×30cm
- Axium 3D 10mm×20cm
- Axium 3D 10mm×20cm
- Axium Helix 8mm×30cm
- Axium Helix 6mm×20cm
- Axium Helix 6mm×20cm
- Axium Helix 6mm×20cm
- Axium Helix 5mm×15cm
- Axium Helix 5mm×15cm
- Axium Helix 5mm×15cm
- Axium Helix 5mm×15cm
- Axium Helix 5mm×15cm
- Axium Helix 5mm×15cm

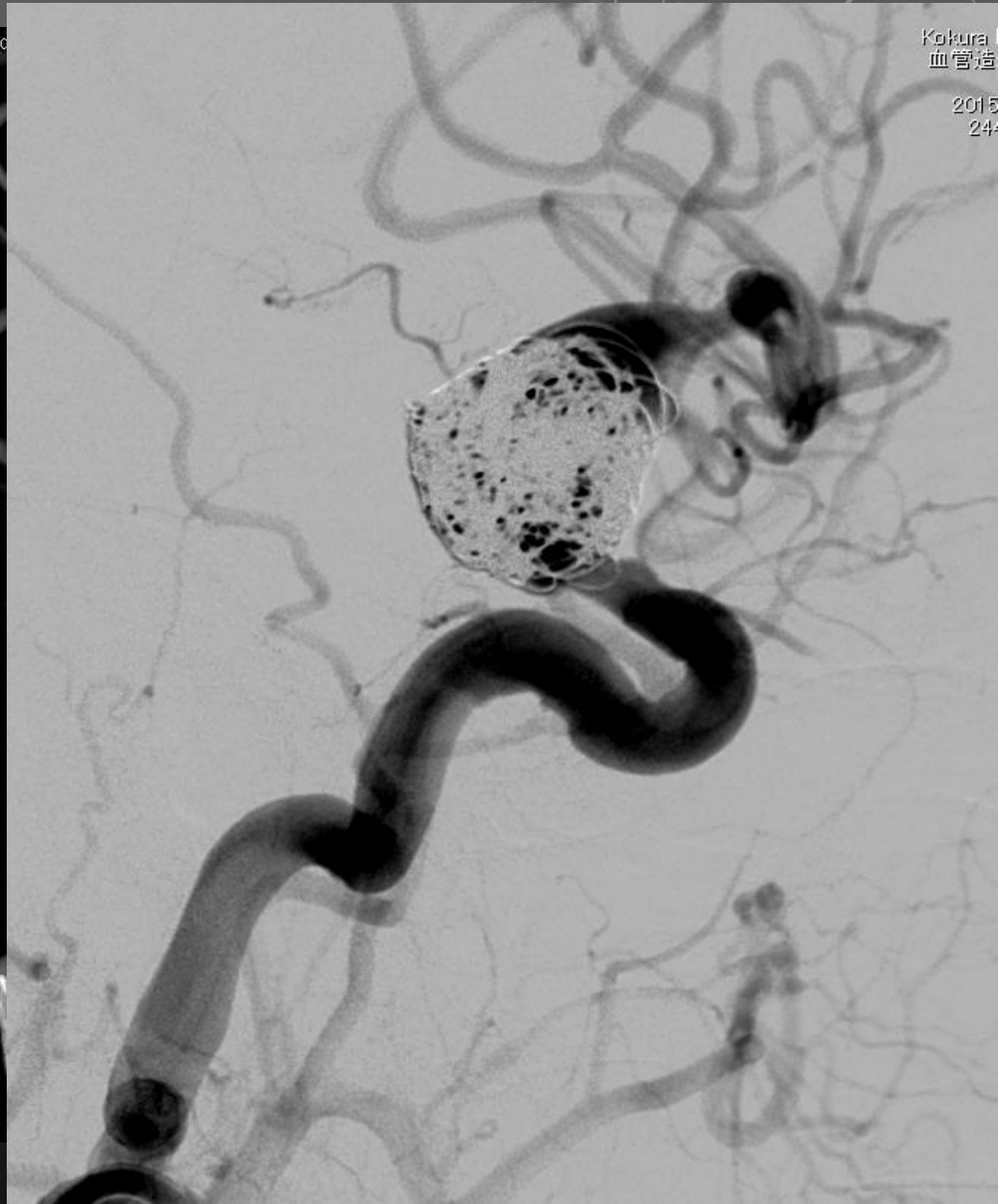
# AchA remains patent, but Pcom was occluded?

0  
1947/09/29, Female  
0005753594  
2441234320150416  
2015/04/17

Kokura Memc

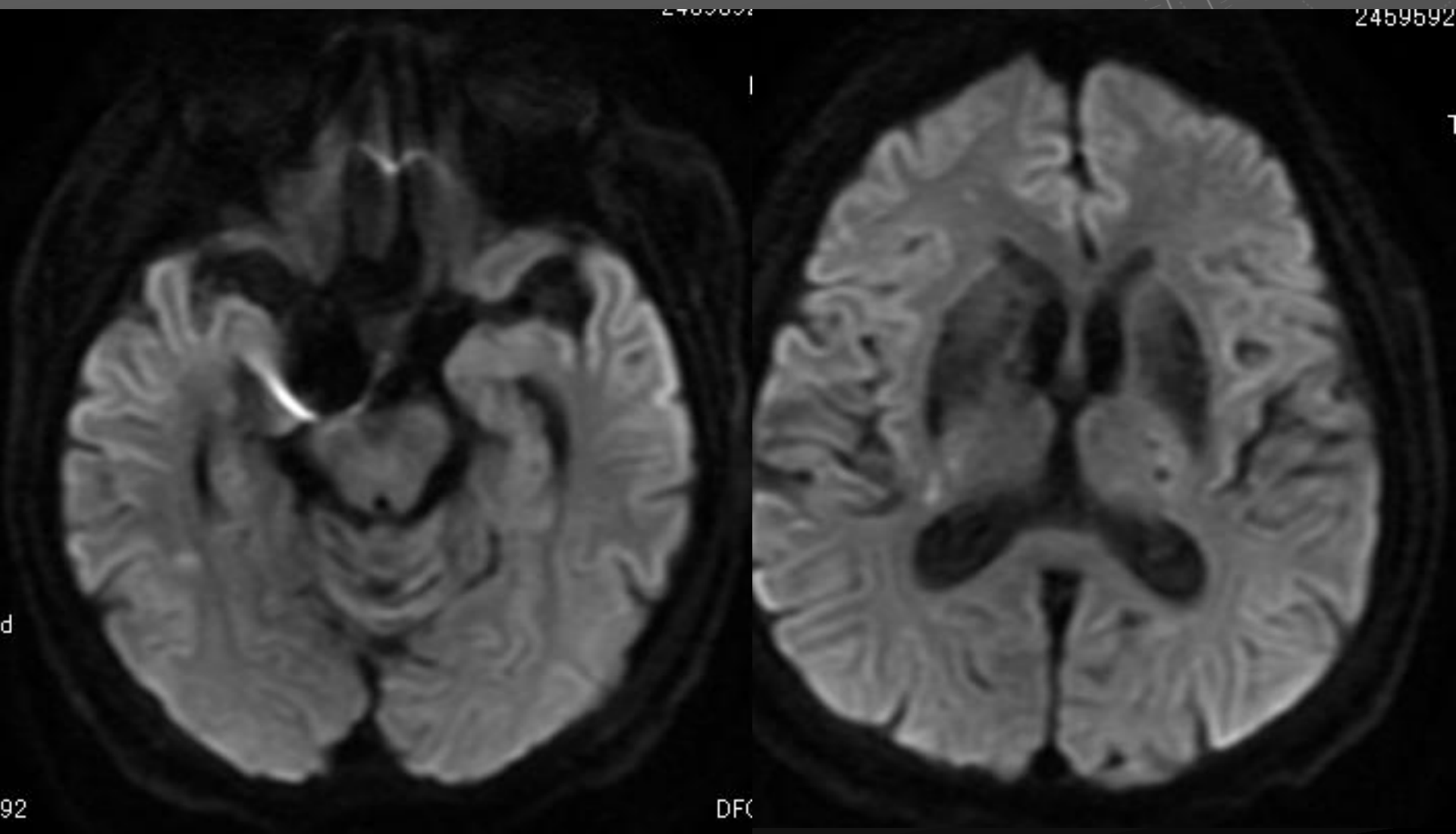


5049  
3DRA + 3DRA  
2015/04/17  
12:31:17  
52.18 mm



Kokura  
血管造  
2015  
24

# No ischemic lesion in AchoA and PcomA territories



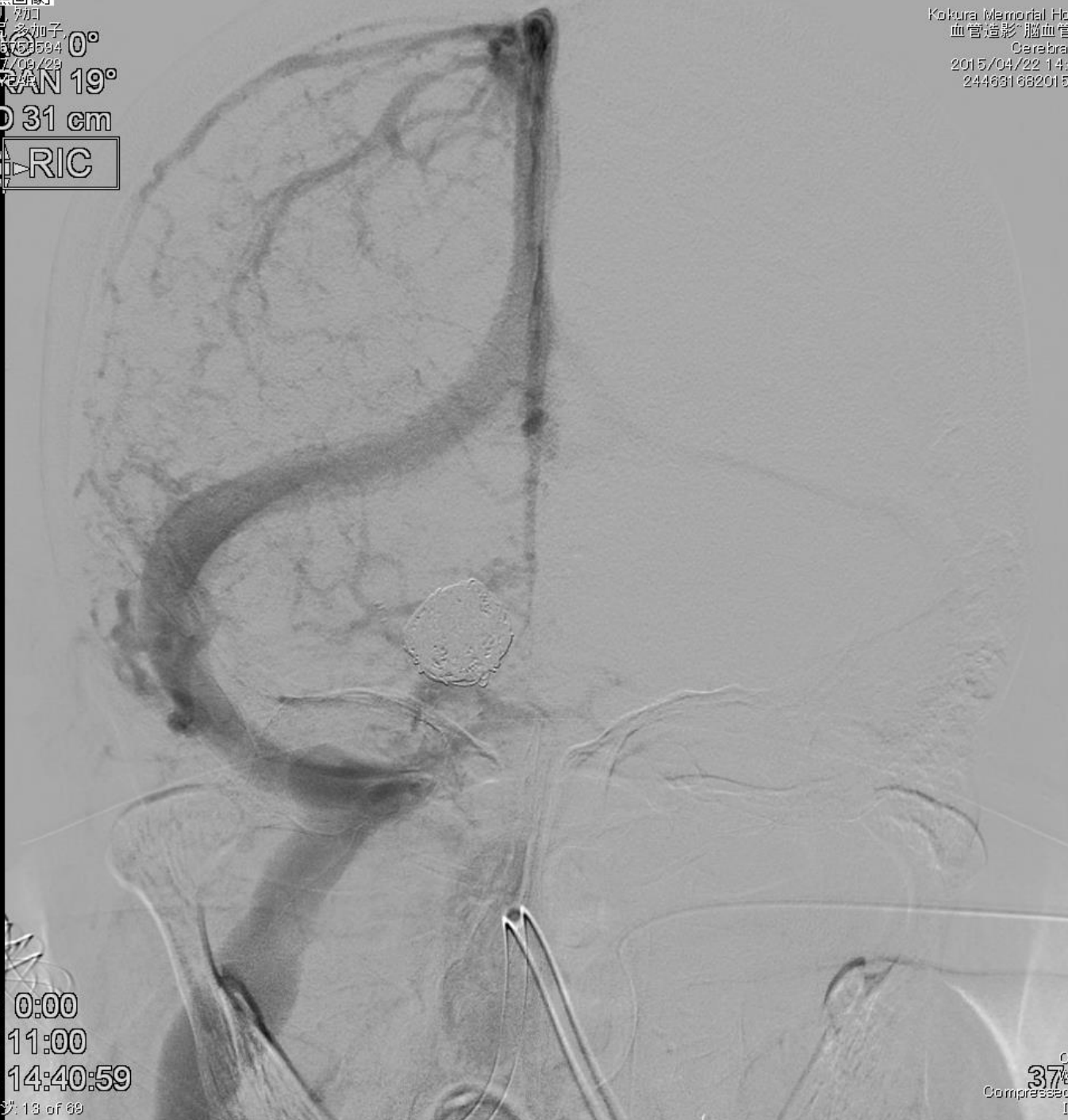POD 30days

「参照画像」  
野尻 多加子  
0064709594  
1947/09/29  
67歳  
CRAN 19°  
FD 31 cm  
RIC

Kokura Memorial Hospital  
血管造影 脳血管造影  
Cerebral 3fpa  
2015/04/22 14:41:10  
2446816820150421

0 0:00  
11:00  
14:40:59  
ページ: 18 of 69

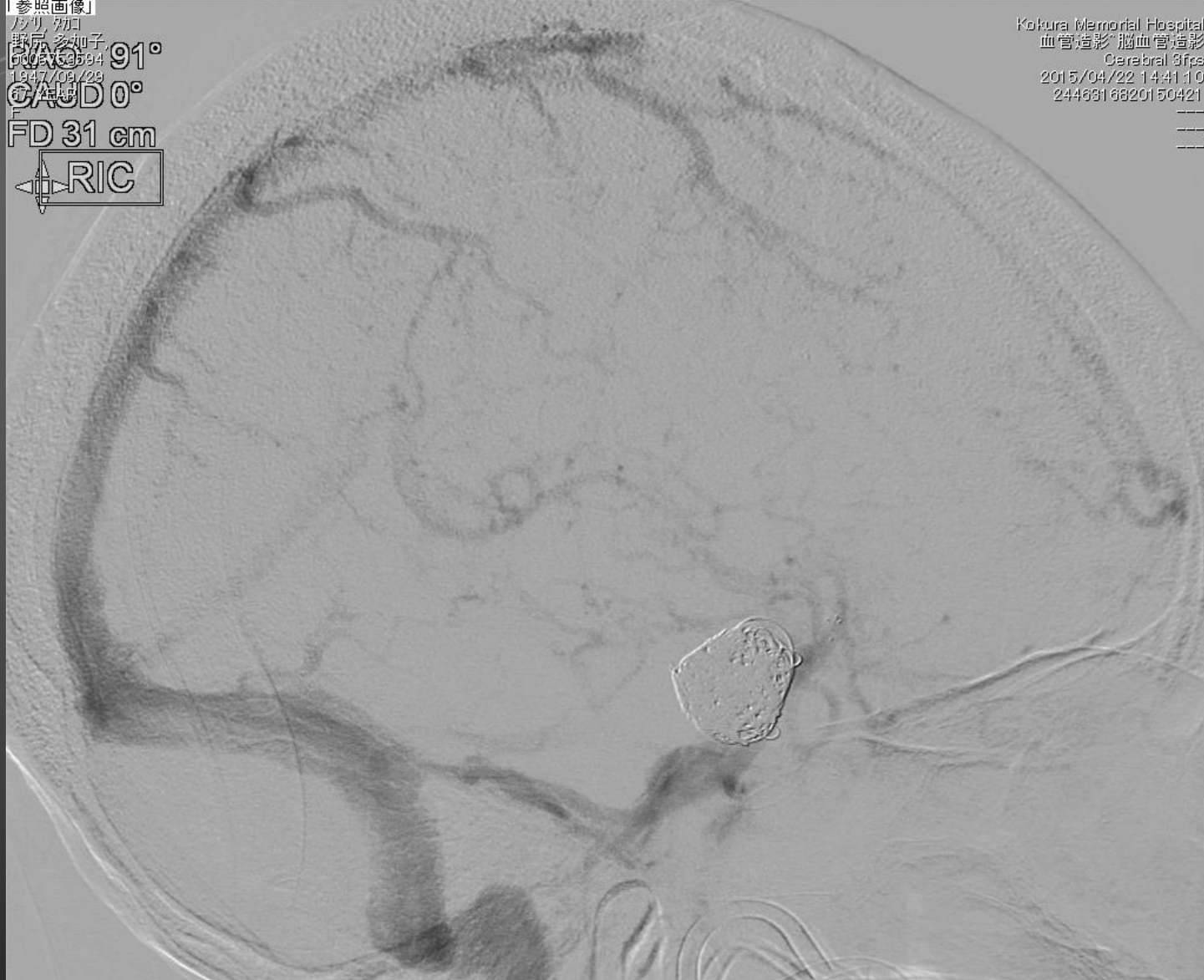Z: 1  
C: 522  
37490  
Compressed 1.31  
14: 30



POD 30days

参照画像  
氏名 多知子  
病室 594  
1947/08/29  
C/A/D 0°  
FD 31 cm  
RIC

Kokura Memorial Hospital  
血管造影 脳血管造影  
Cerebral 3fcs  
2015/04/22 14:41:10  
2446816820150421



No rerupture @ 12M

14:40:59  
14 of 69

Z: 1  
C: 522  
37430  
Compressed 1-bit  
Im: 30



**Neck-bridging stent can be placed  
as if it were a flow diverter!**

