



Changhai Hospital

Lvis Jr-assisted coiling for AcomA-AN

Operator : Dr. Qing-hai Huang and Kai-Jun Zhao



Clinical Data

Male , 52Y

CC : severe headache for 8 hours

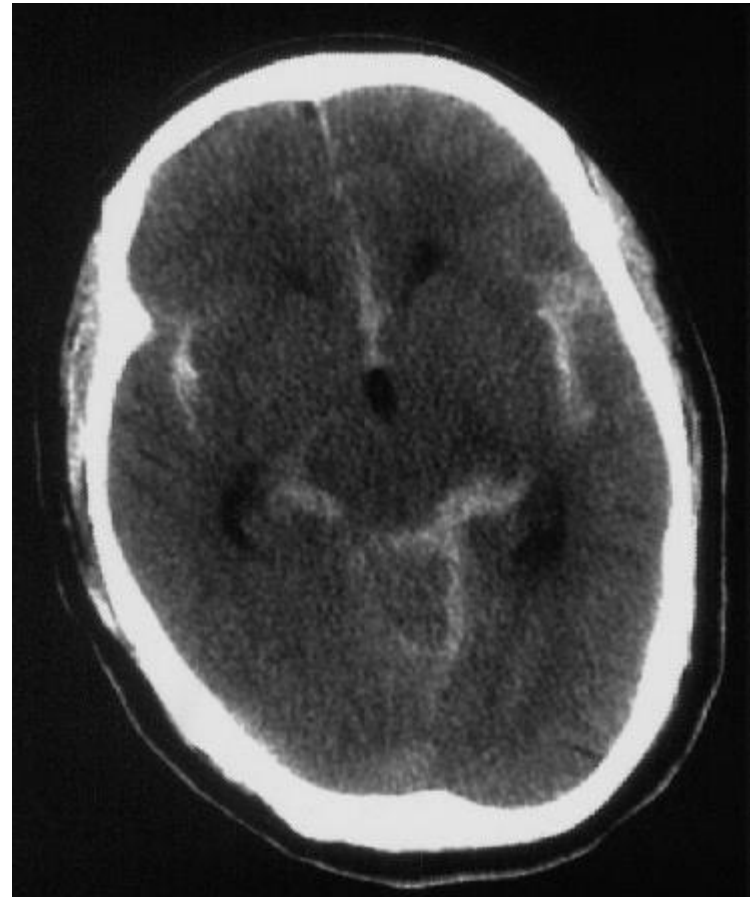
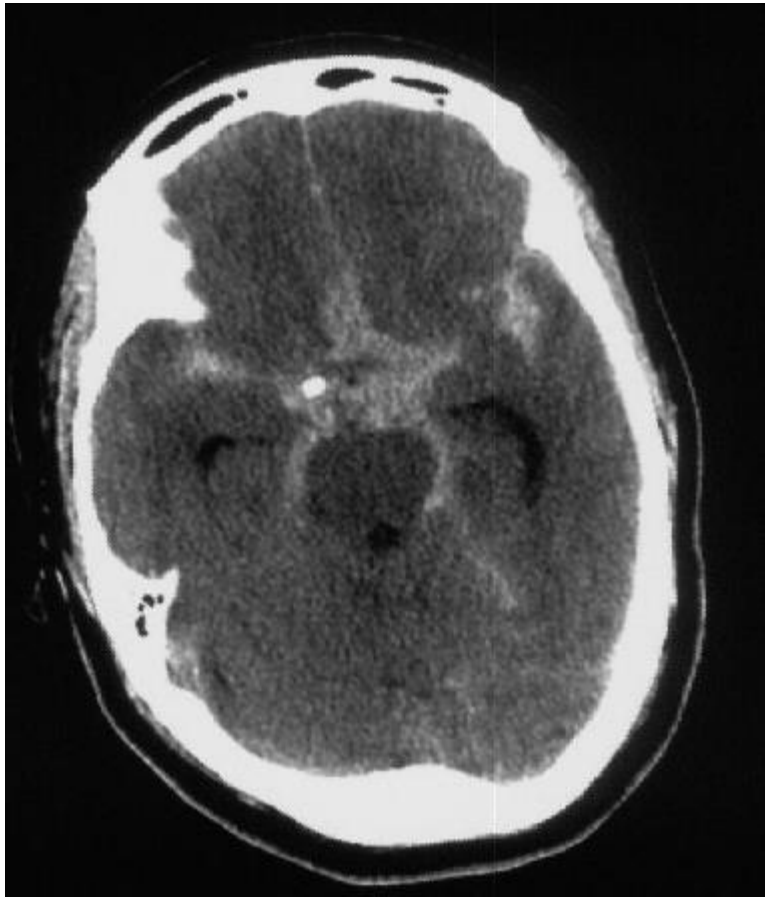
PE : Hunt-Hess: III, GCS:7' meningeal irritation sign(+)

PH : -

DX : SAH

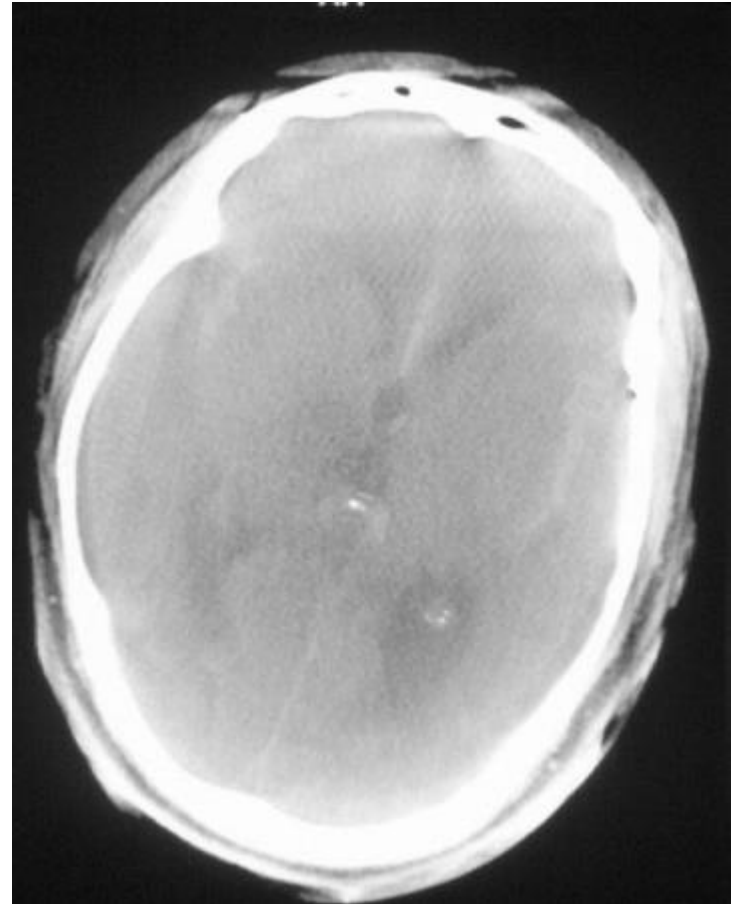
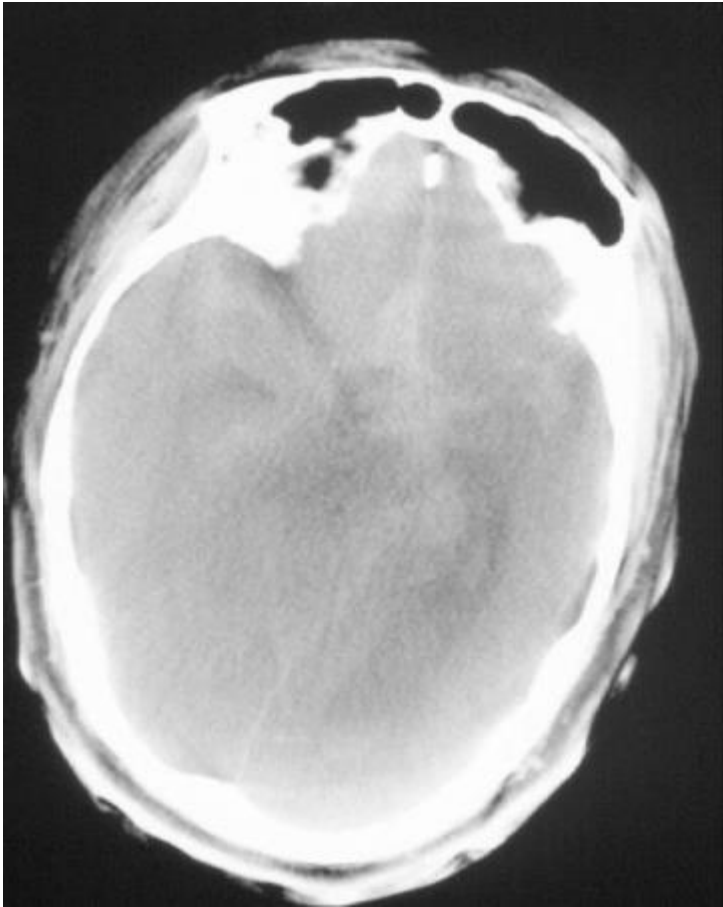


2015-05-05 Local Hospital CT : SAH

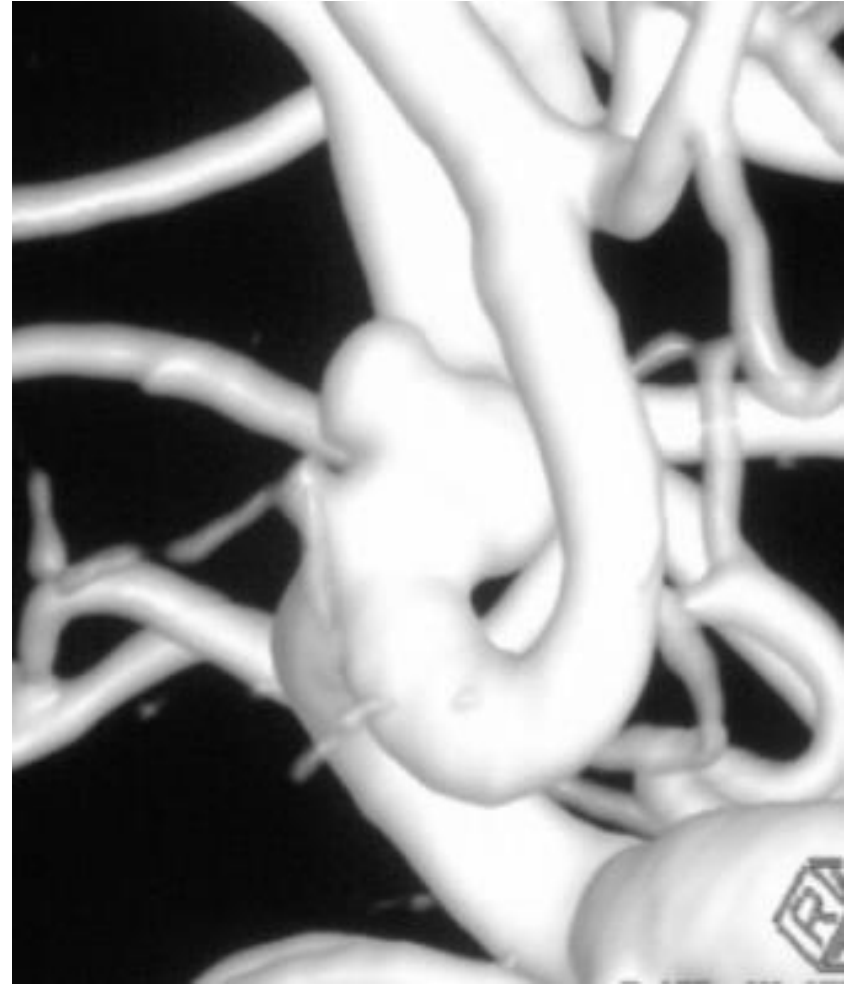
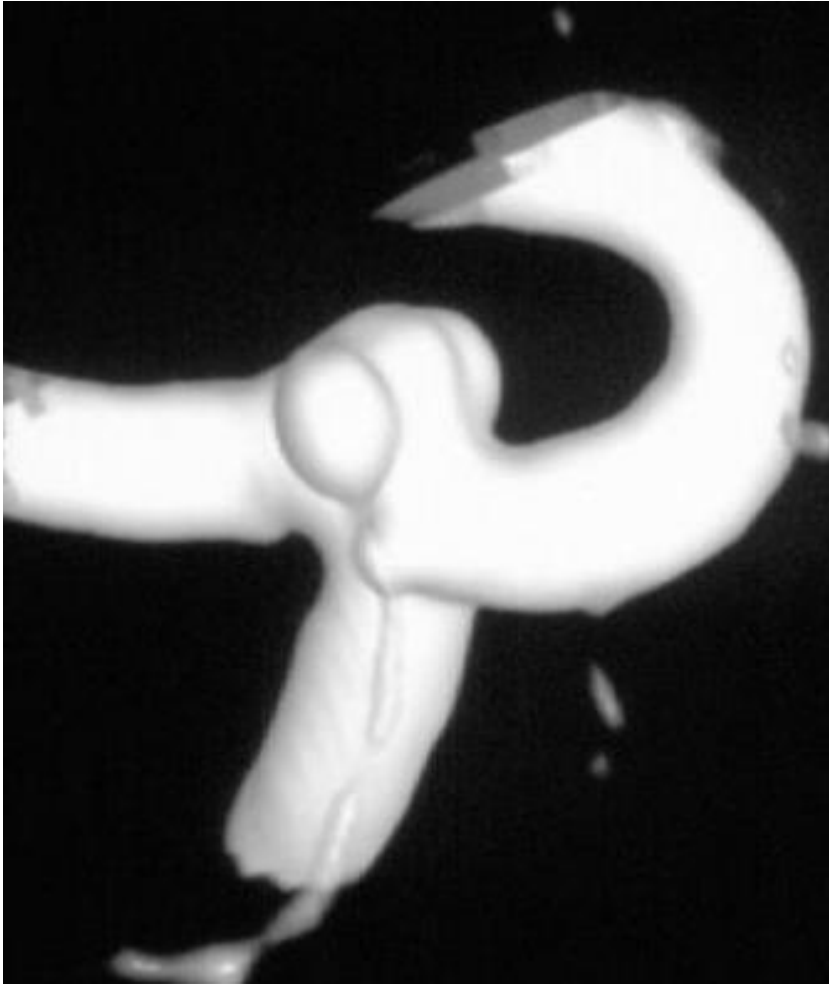


Dyna-CT before DSA

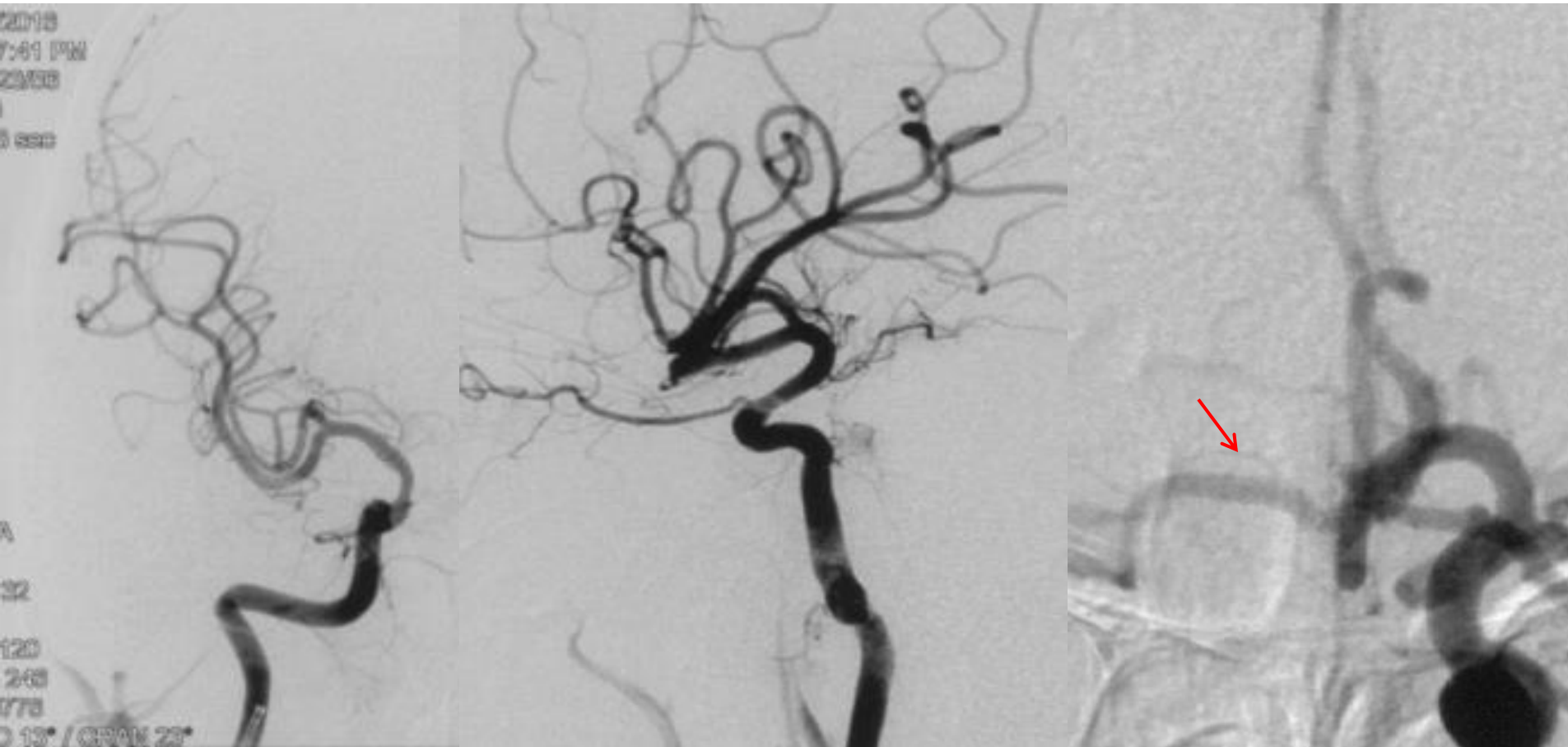
2016-05-05 19:30



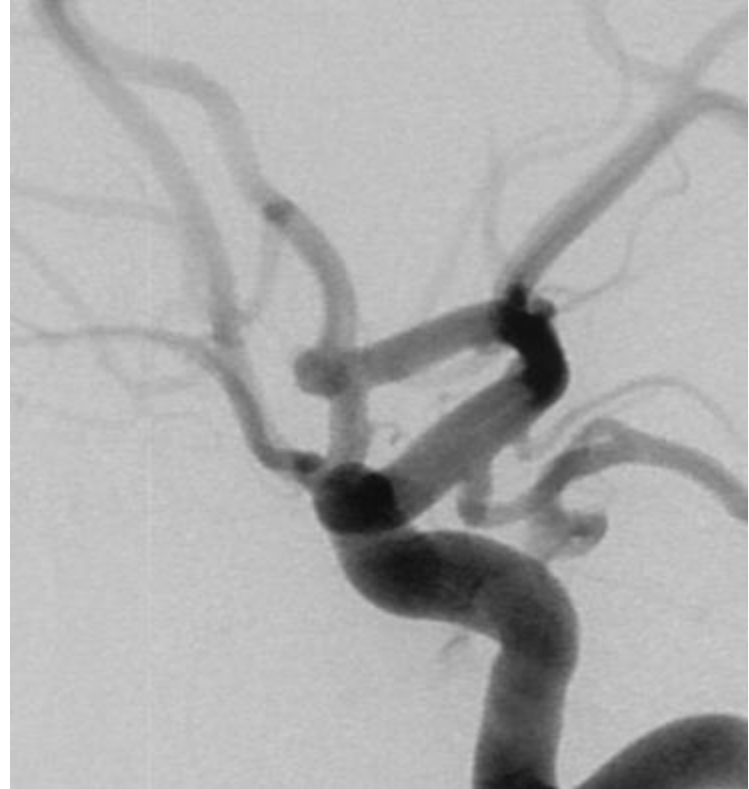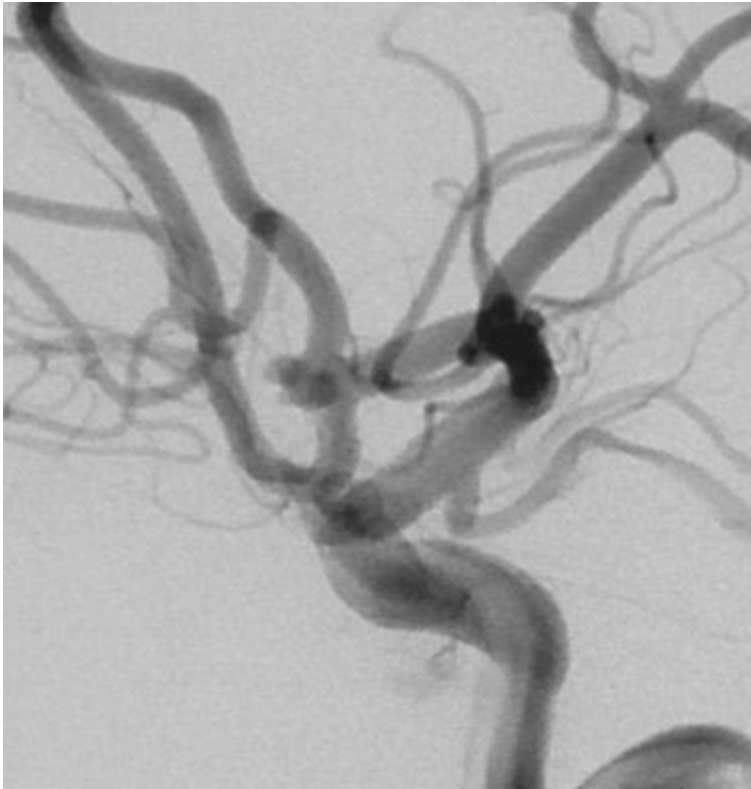
3D Reconstruction



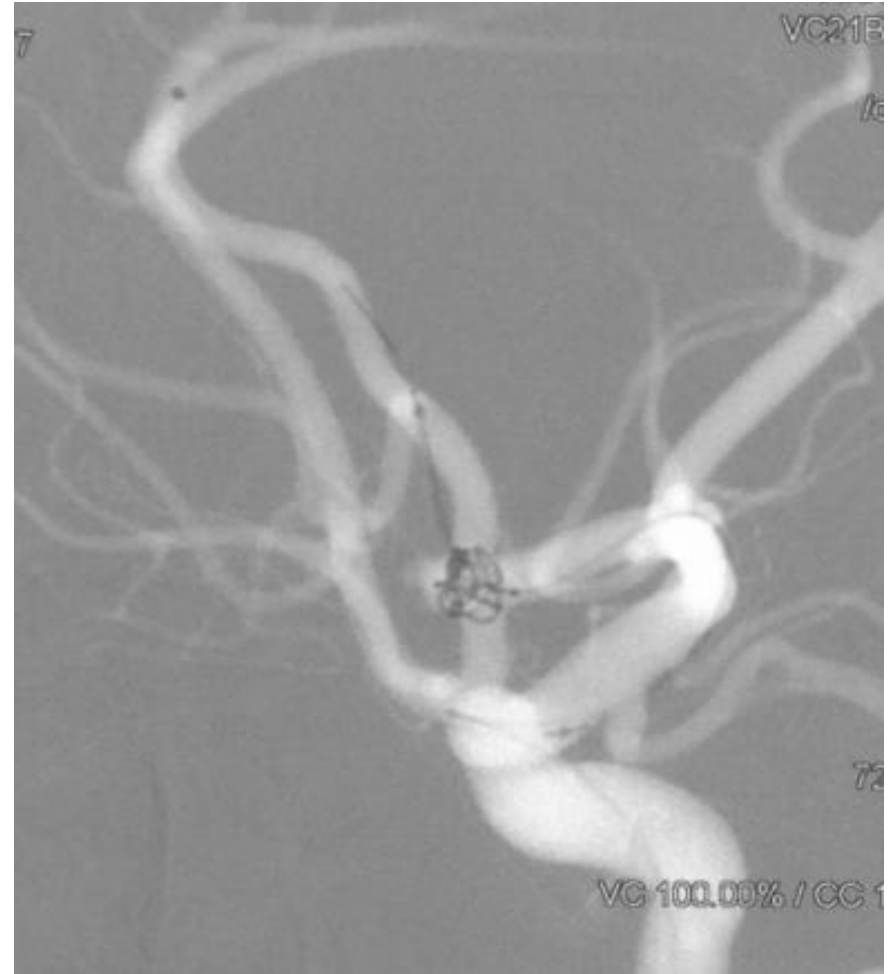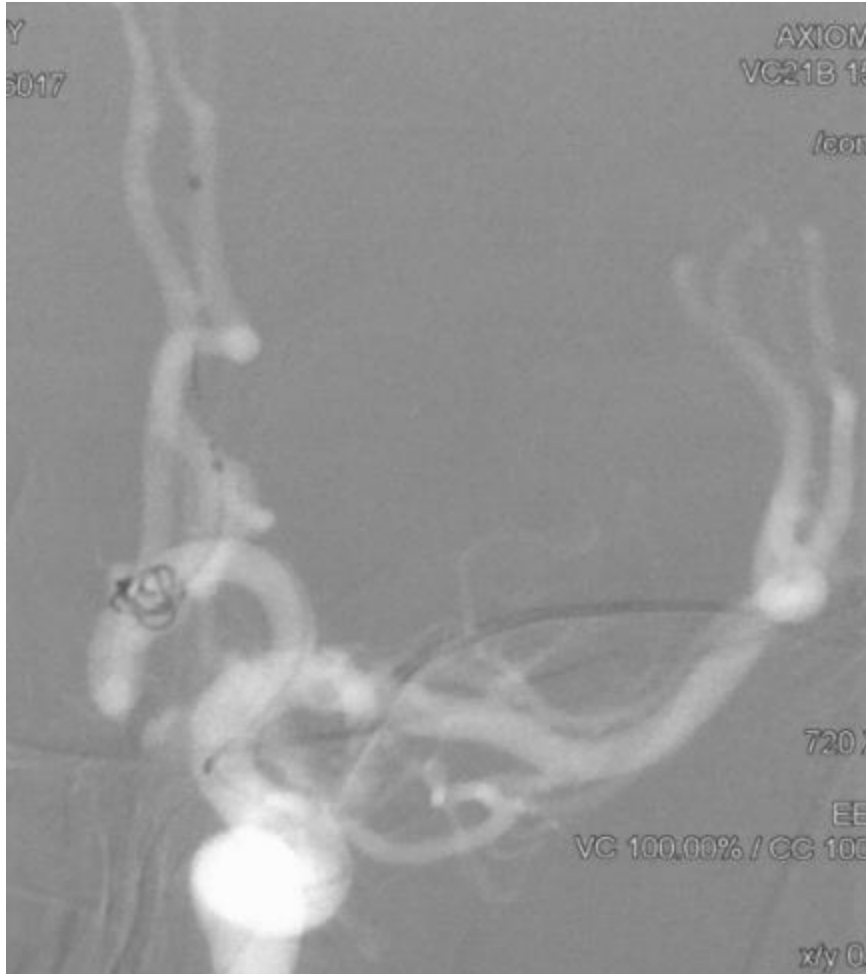R-ICA and Press-neck Test



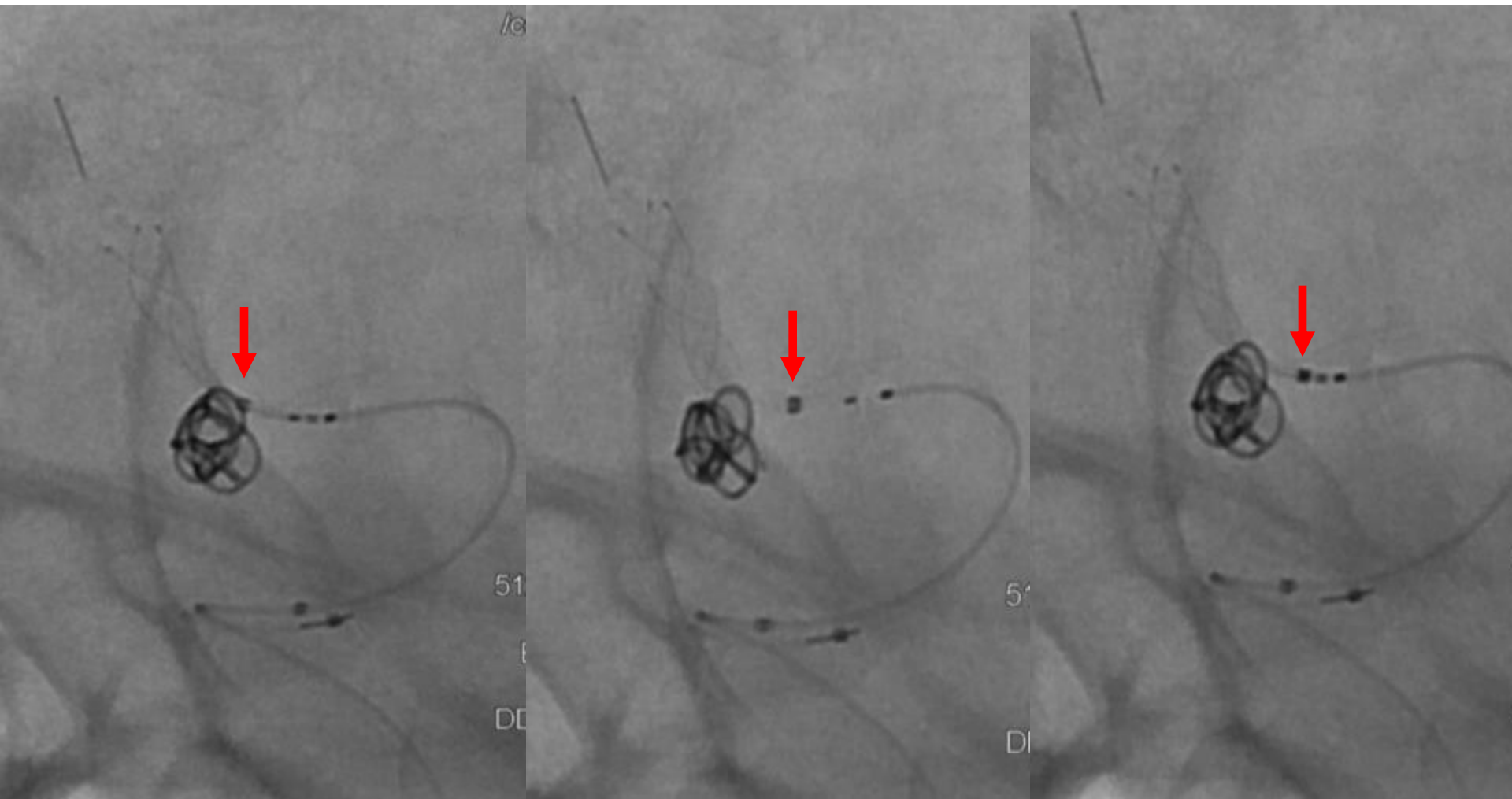
Working Projection



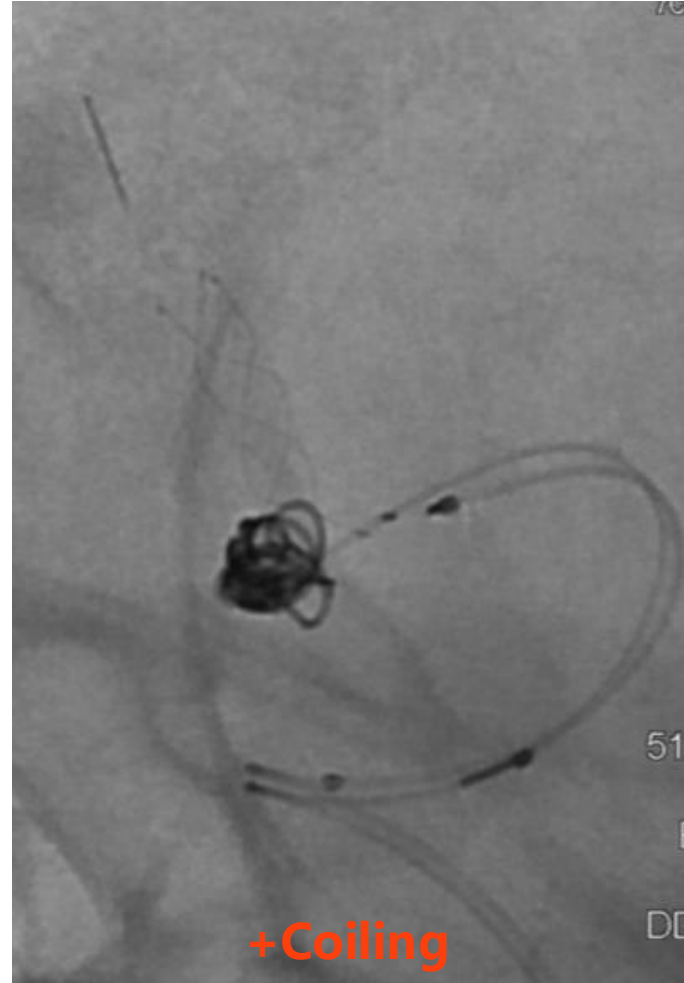
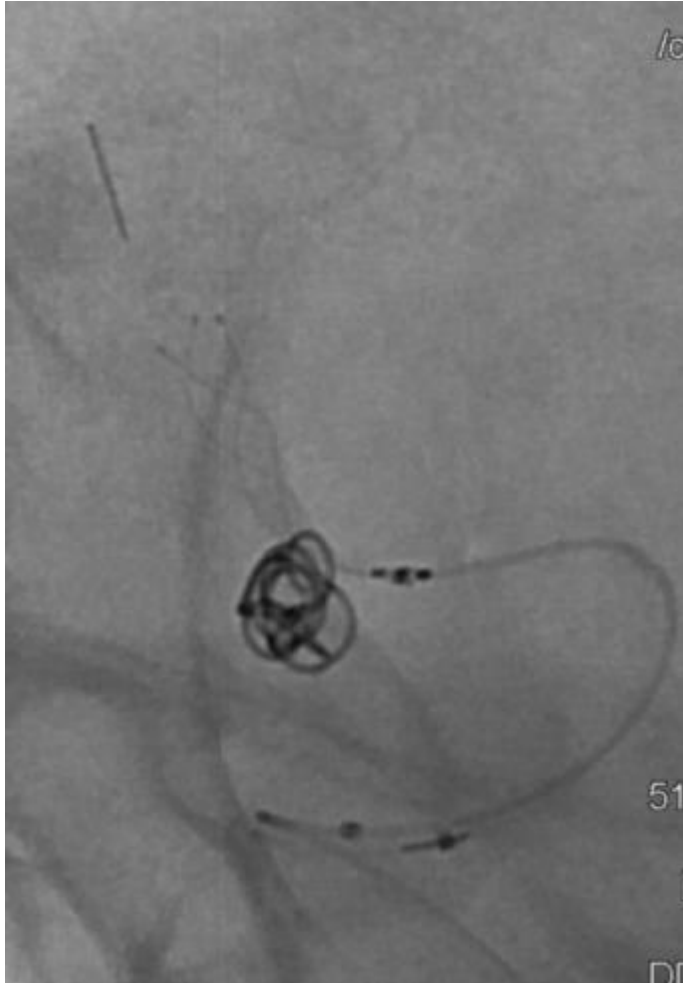
Axium 3mm/6cm 3D implantation



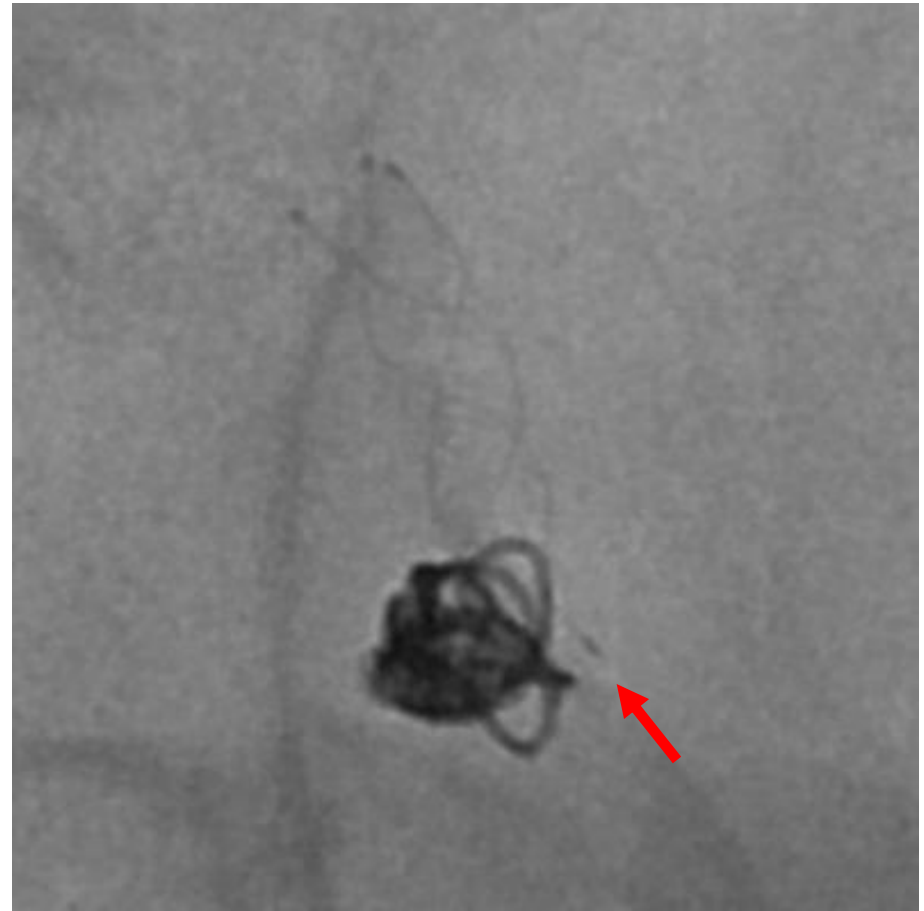
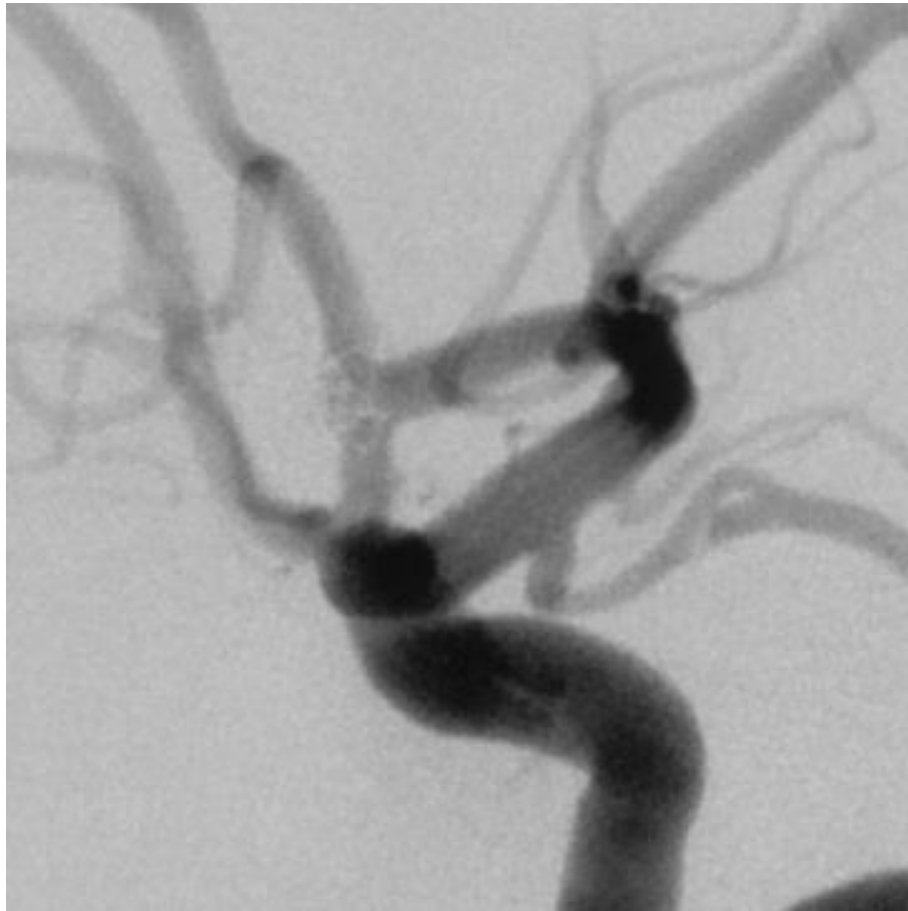Followed by LVIS jr 2.5/13 stent Release



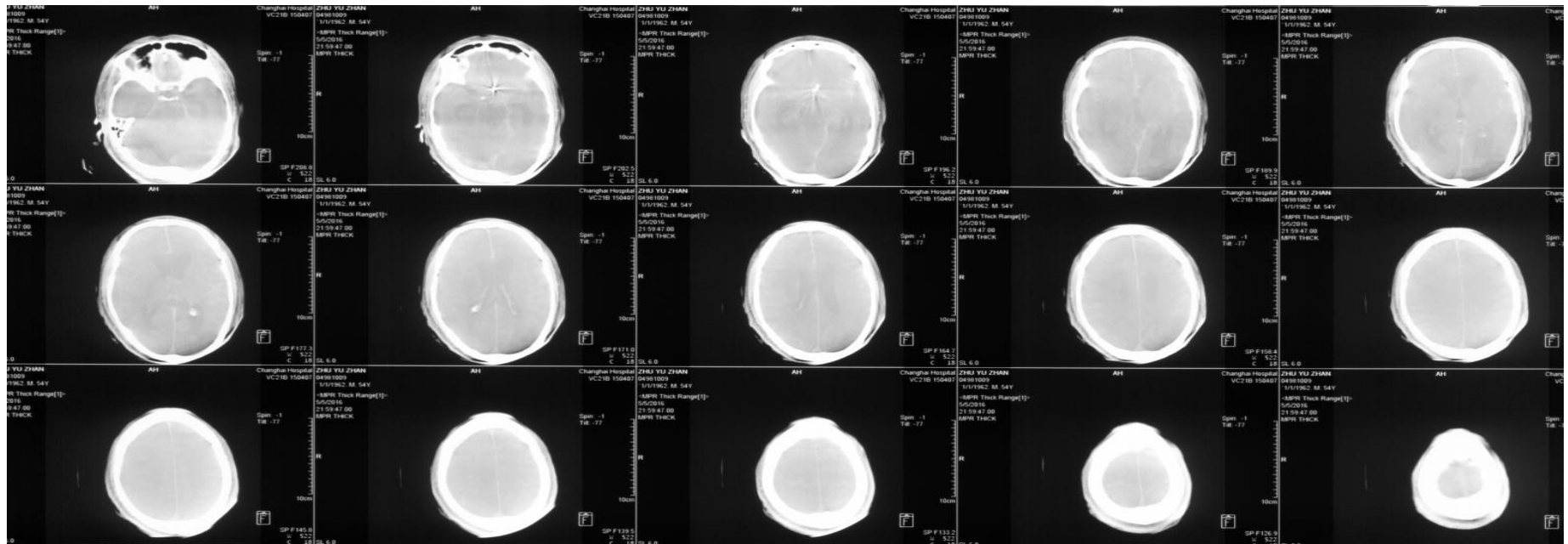
LVIS jr stent Release and Coiling



Immediate Result and **stent marker location**



Postprocedural Dyna-CT



Thanks !



Changhai Hospital | Shanghai, China