

# Fusiform PCA aneurysm treated by FD implantation

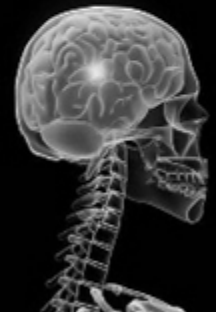
Zeleňák Kamil

Jessenius Faculty of Medicine and University Hospital  
Martin  
Slovakia

WLNC 2016

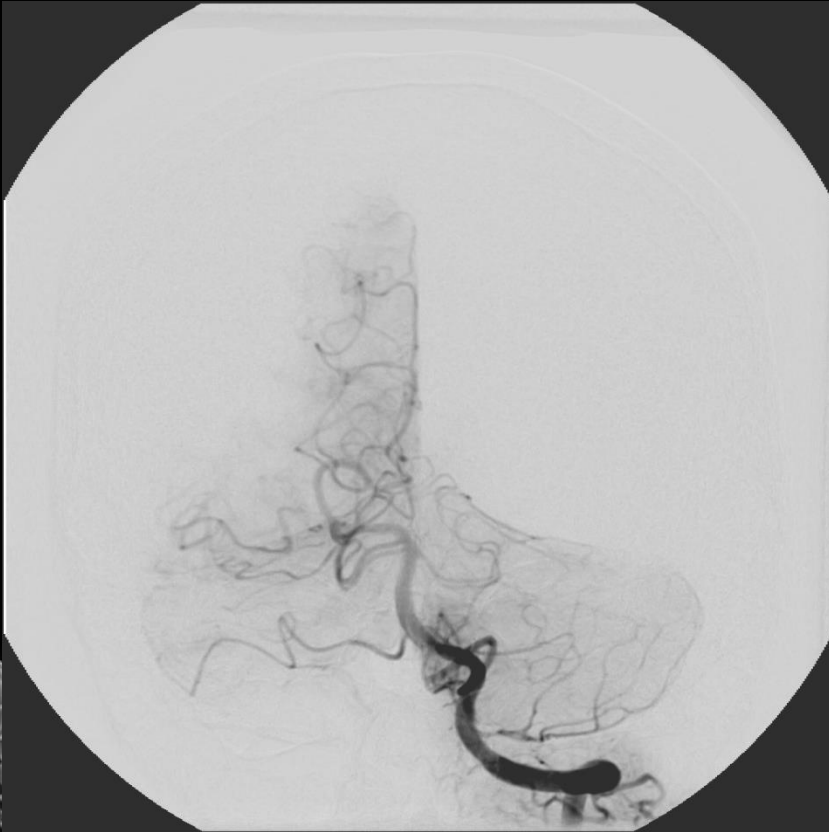May 27-29, 2016

Shanghai

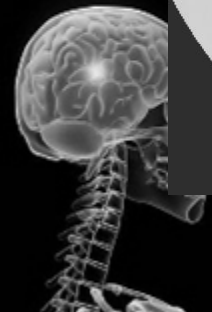
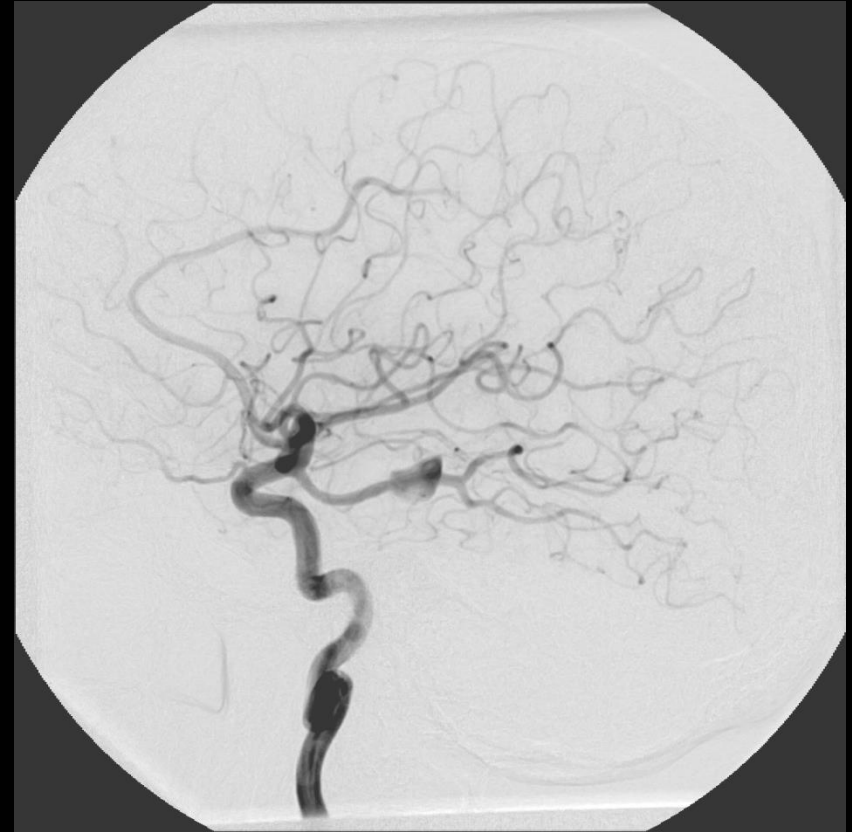

# Fusiform left PCA aneurysm

Left VA angiogram

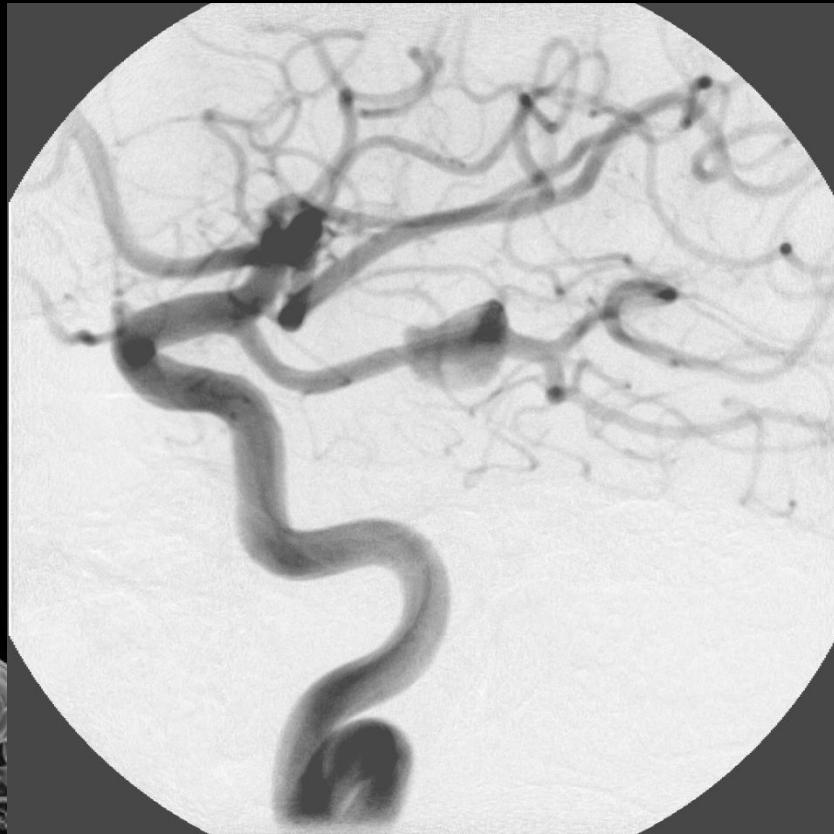


Left ICA angiogram

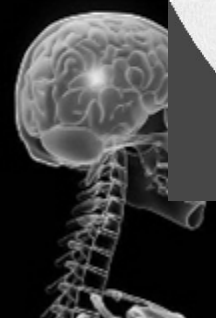
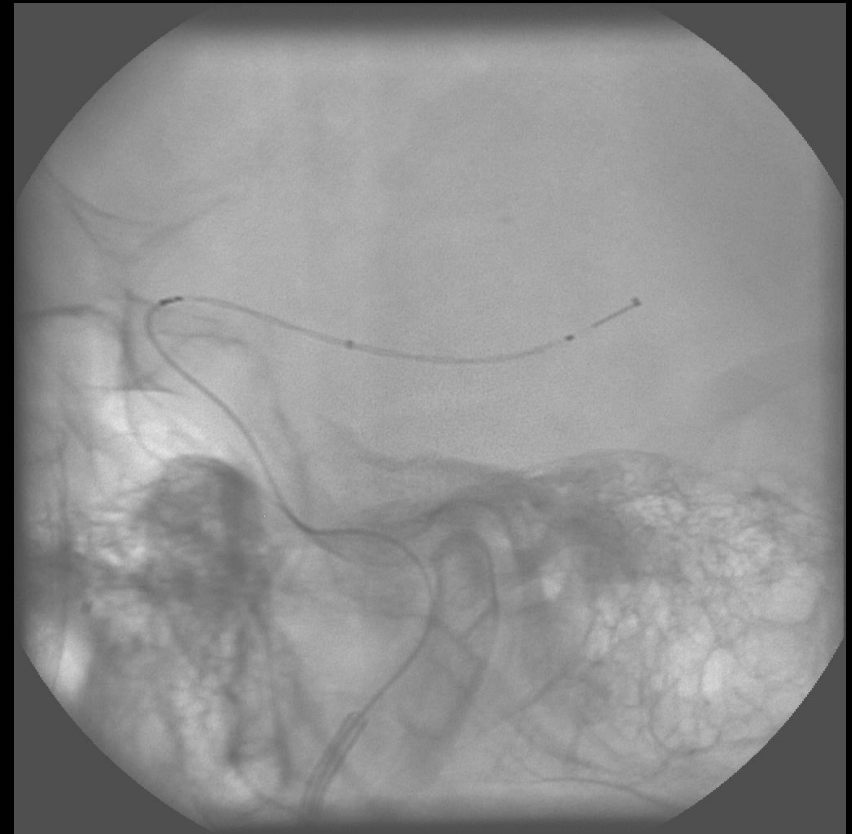
# Fusiform left PCA aneurysm

Left ICA angiogram

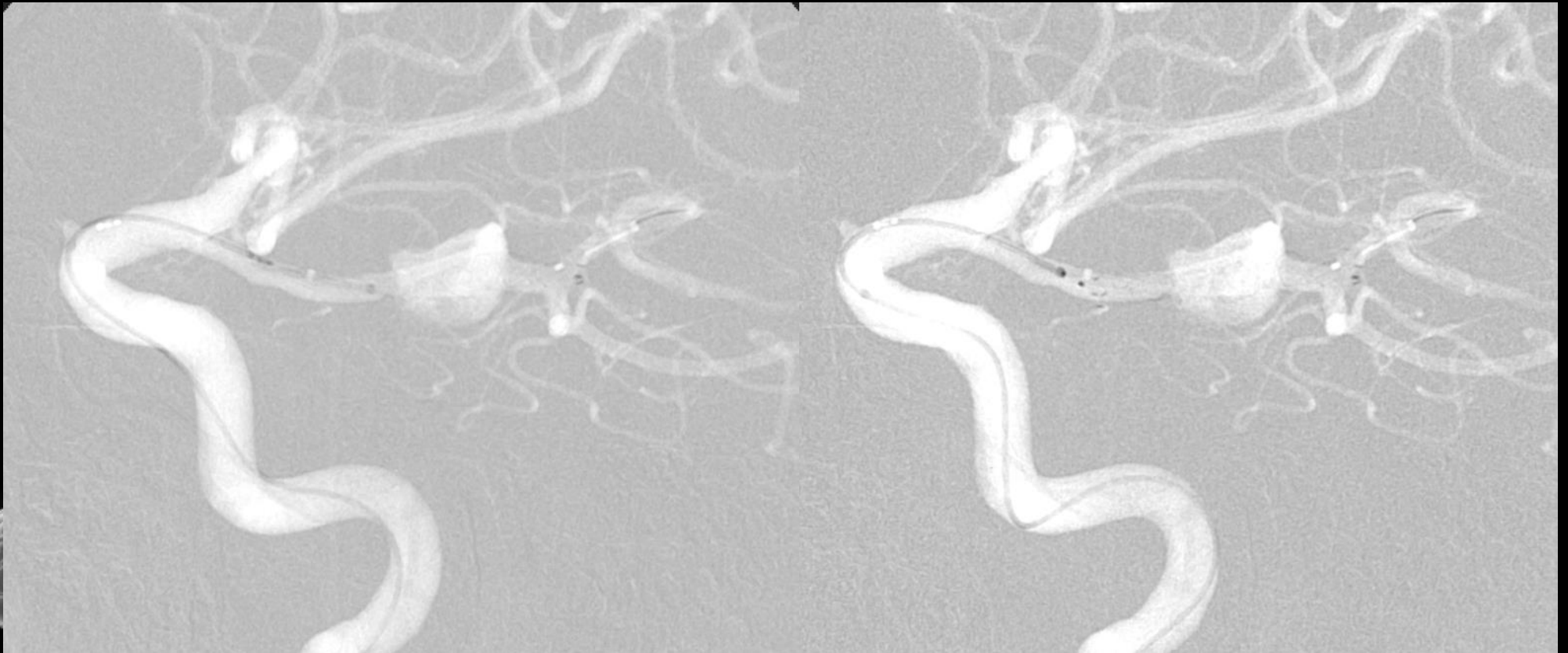

FD



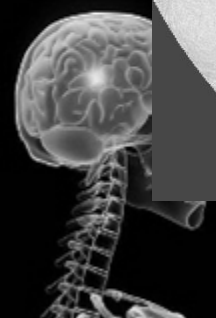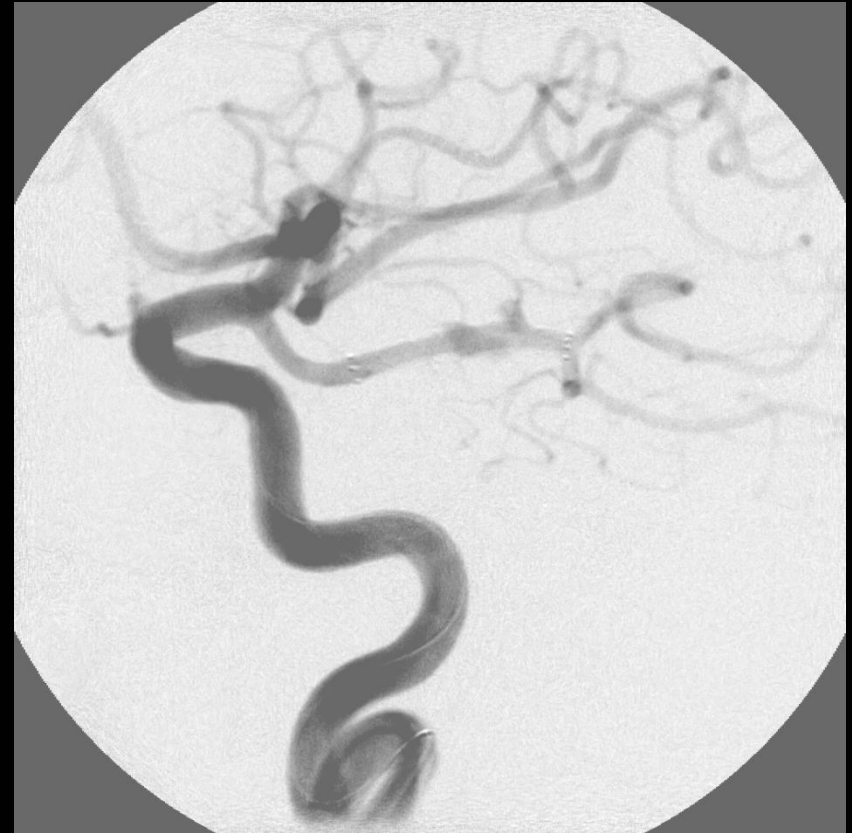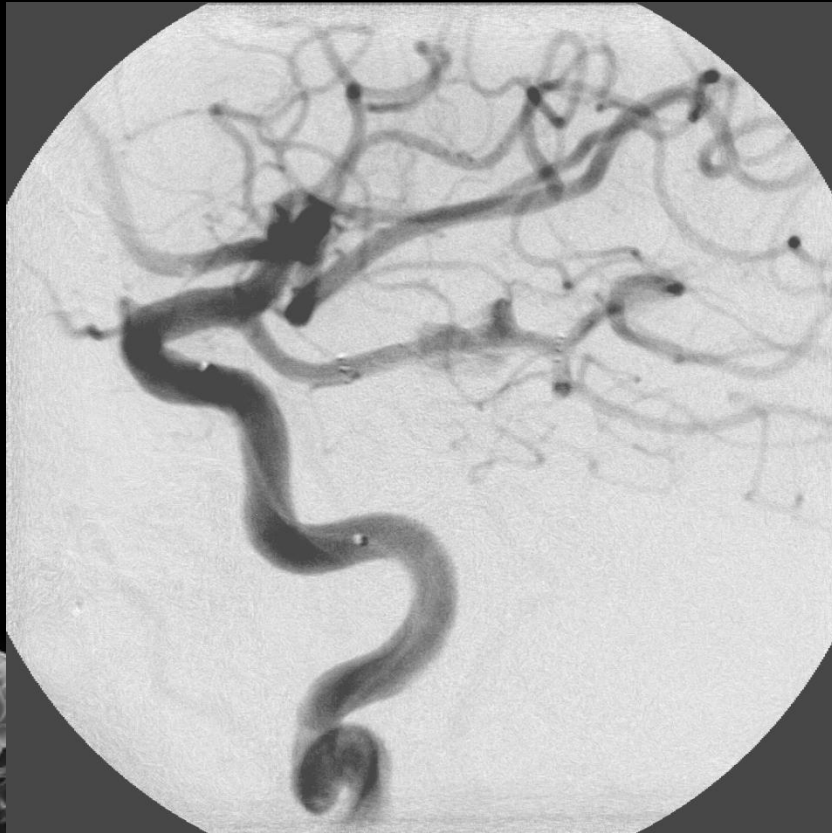# Fusiform left PCA aneurysm

**FD implantation**



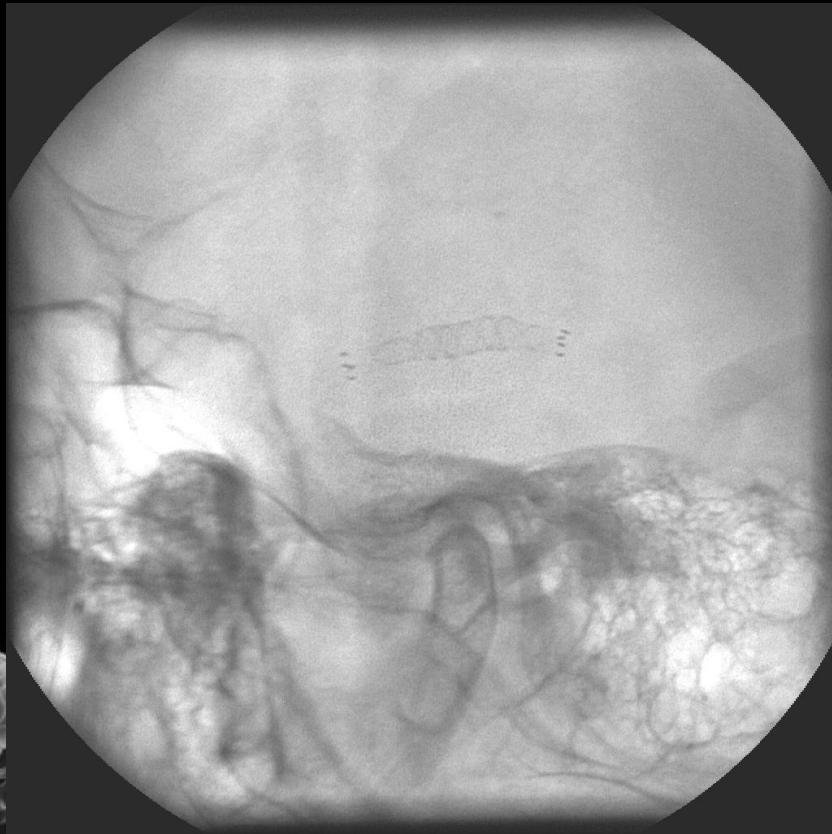# Fusiform left PCA aneurysm

After FD implantation

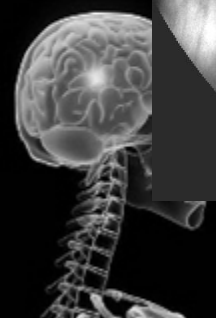
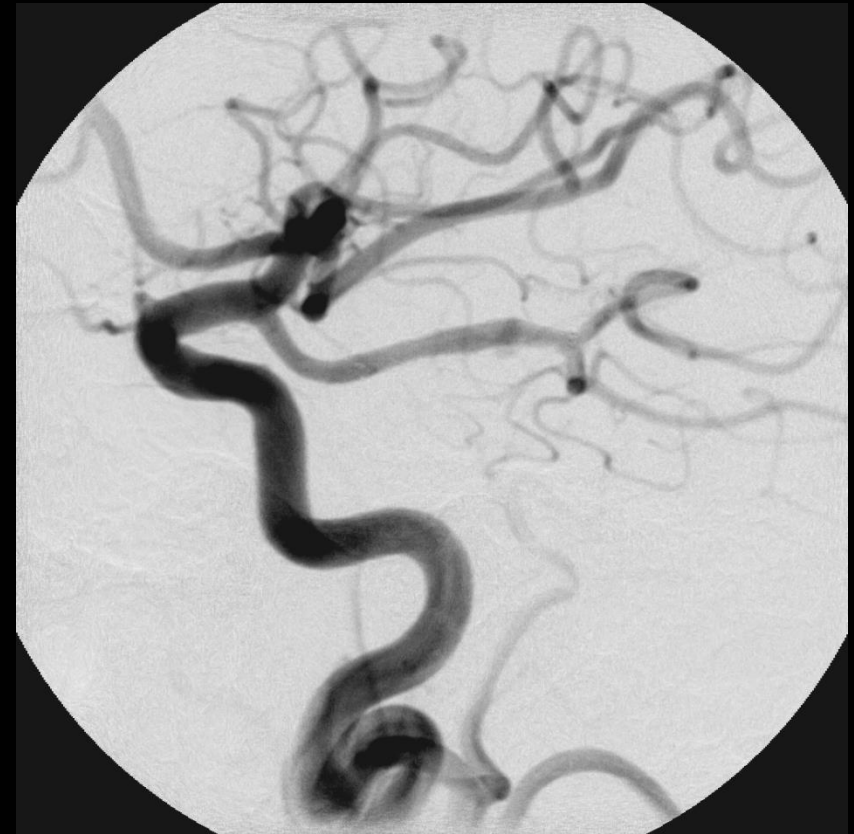

# Fusiform left PCA aneurysm

**FD**



**End of procedure**



# Fusiform left PCA aneurysm

FU

FU

