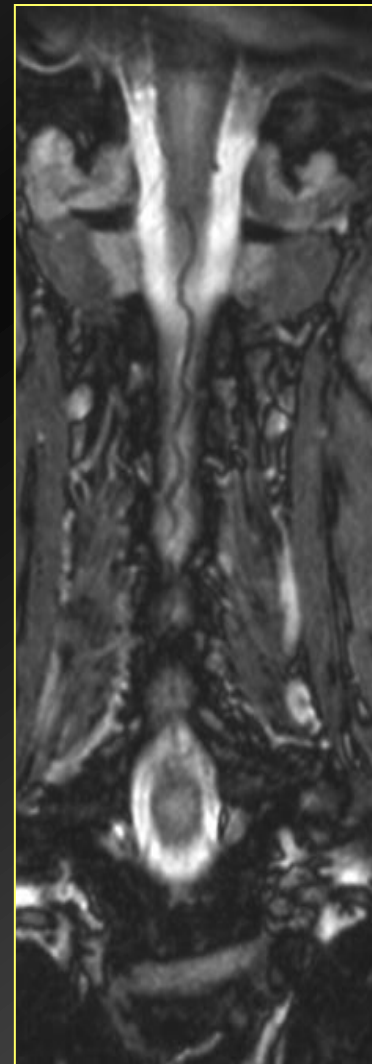
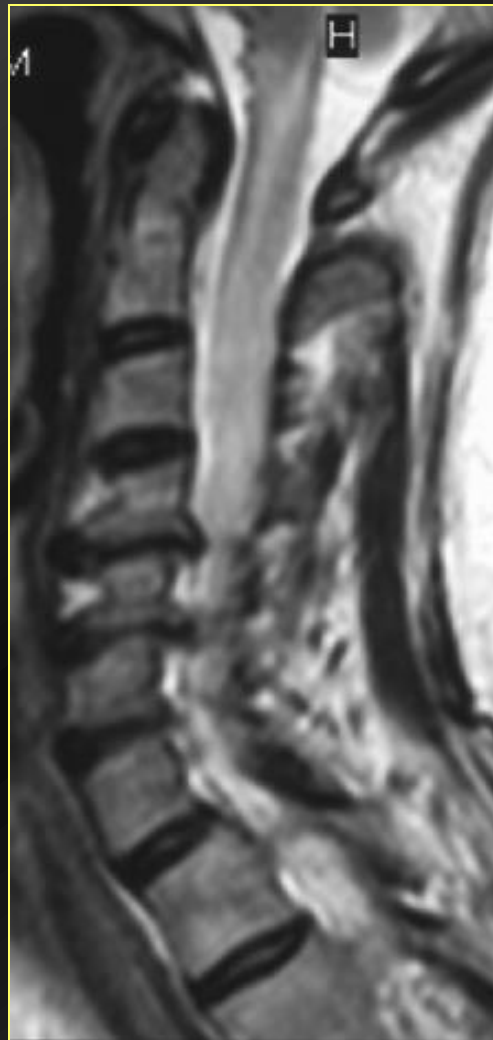
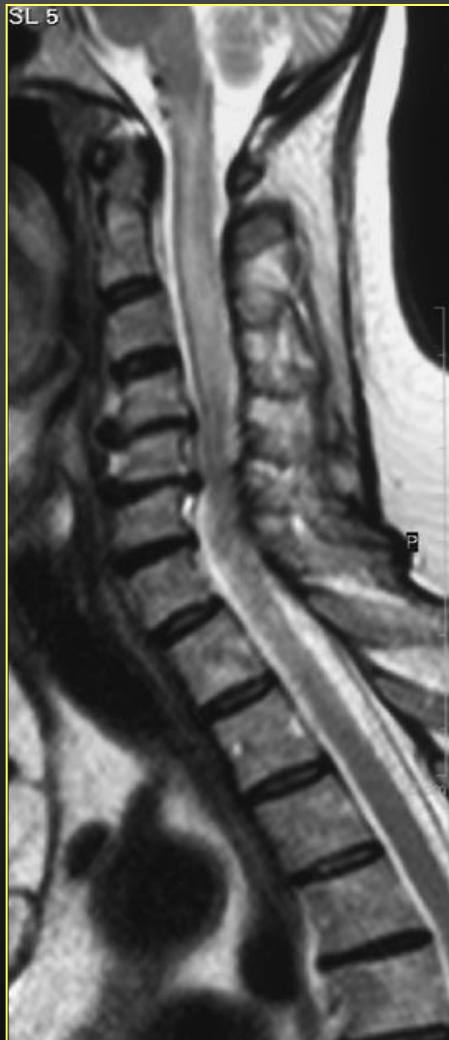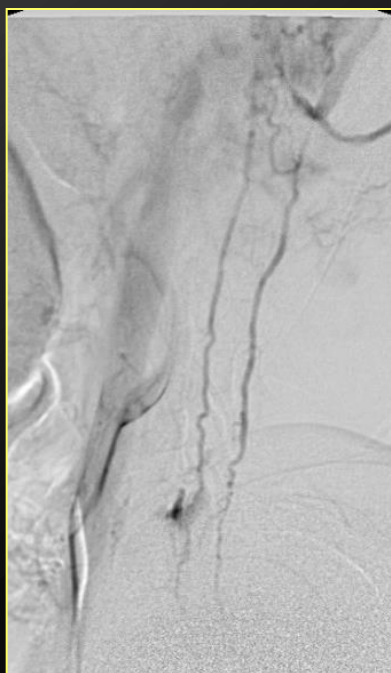
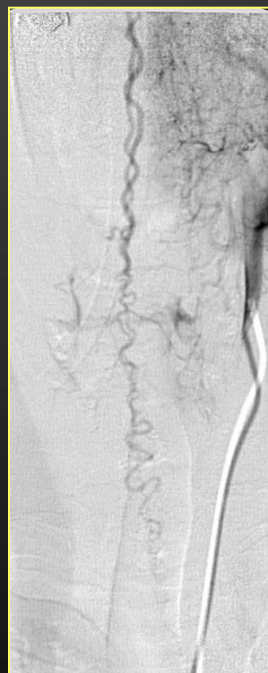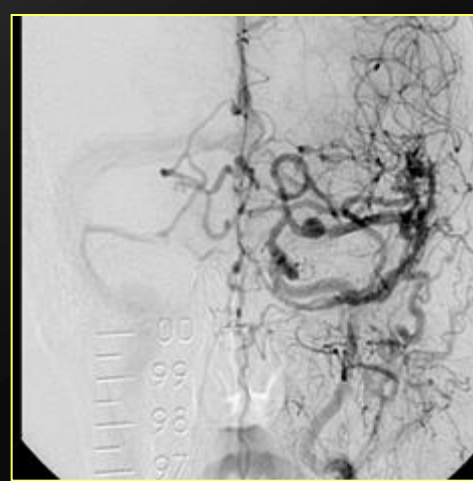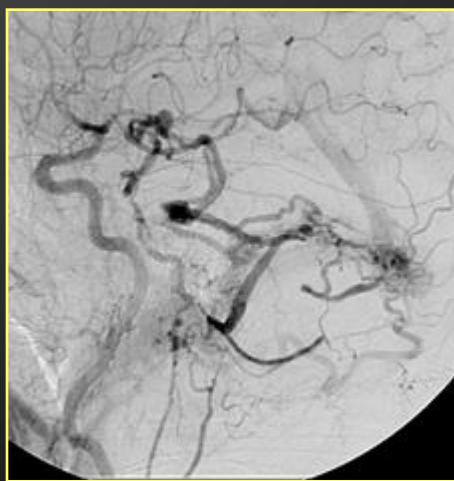
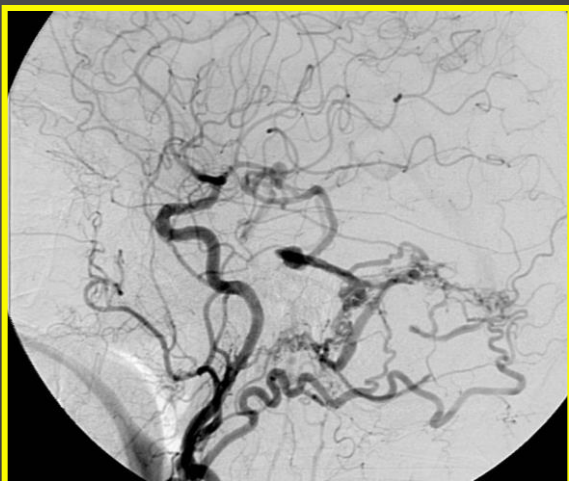
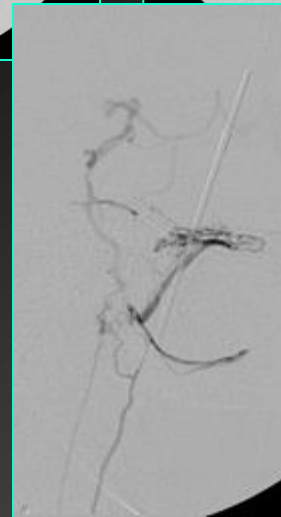
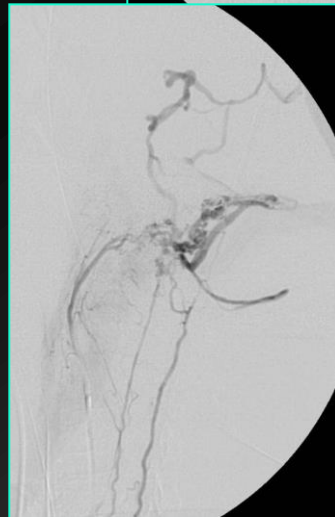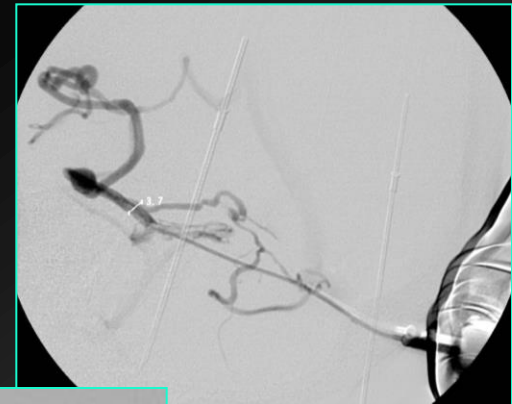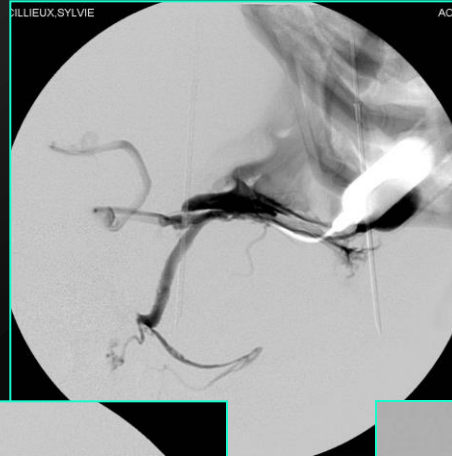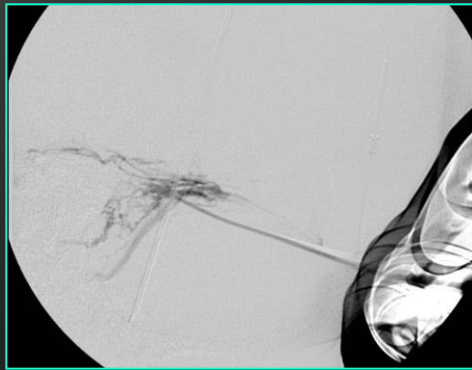
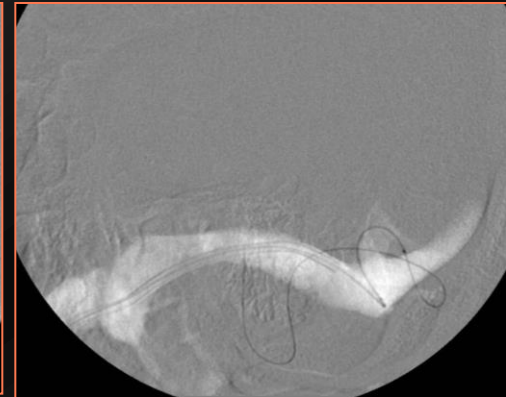
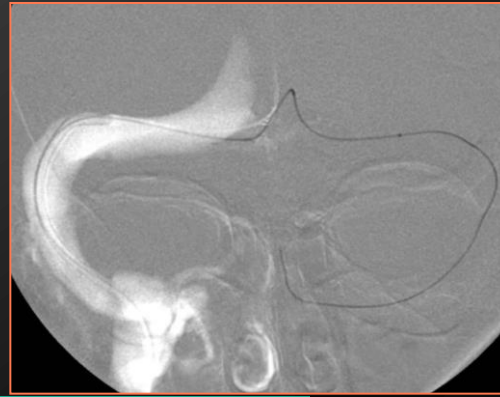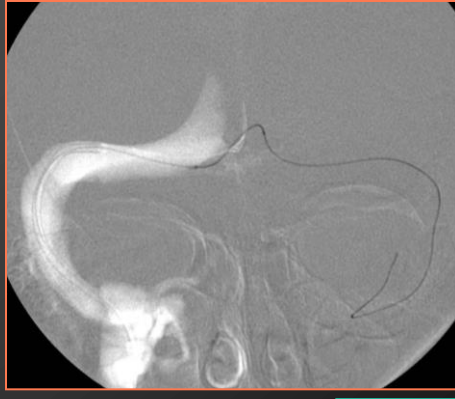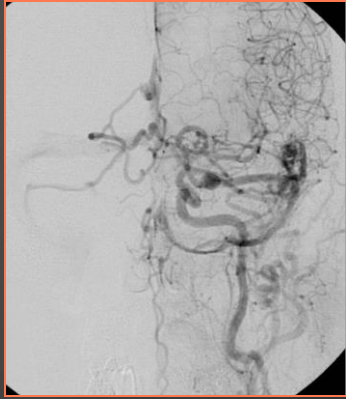


F 58 yo, almost complete tetraplegia since 2 months





Percutaneous Trans-cranial **venous** approach



Dramatic improvement after treatment

FU at 1 y : she walks with a cane, hypostenia left leg

