

# EMOBOLIZATION OF DAVF IN POSTERIOR FOSSA

**Song Donglei**

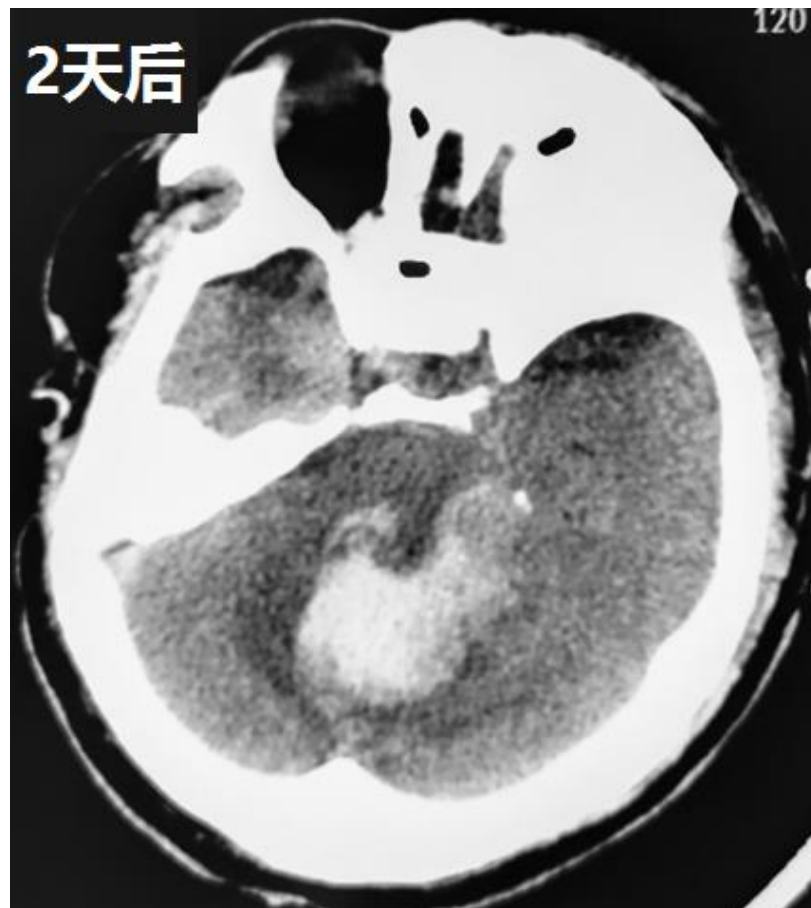
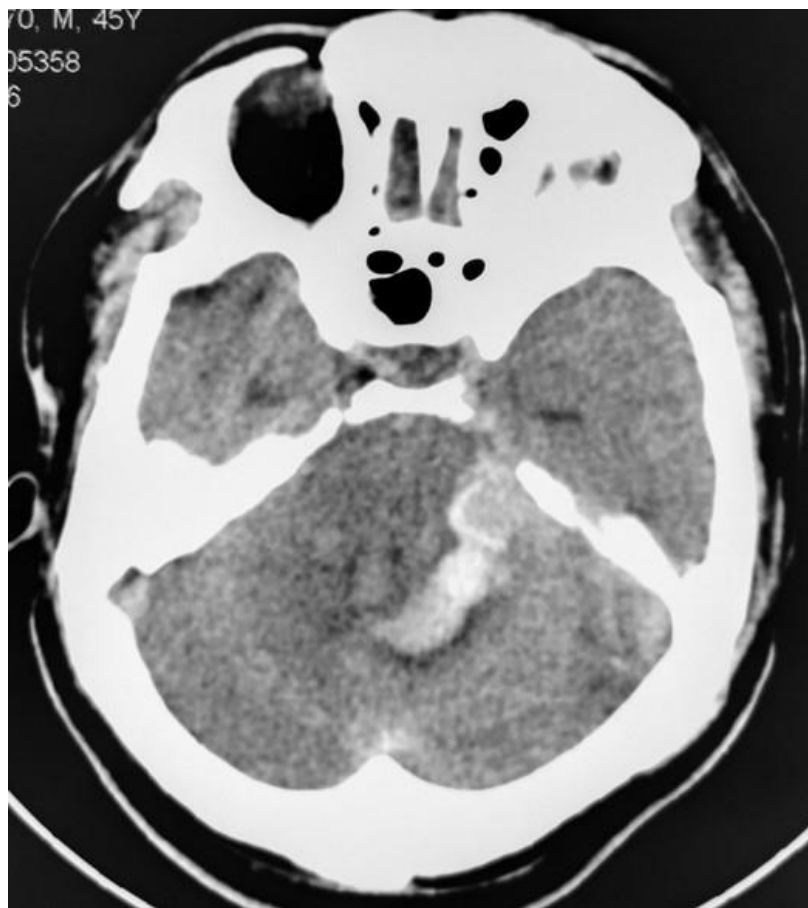**BRAIN DOCTOR GROUP**

## Case Data

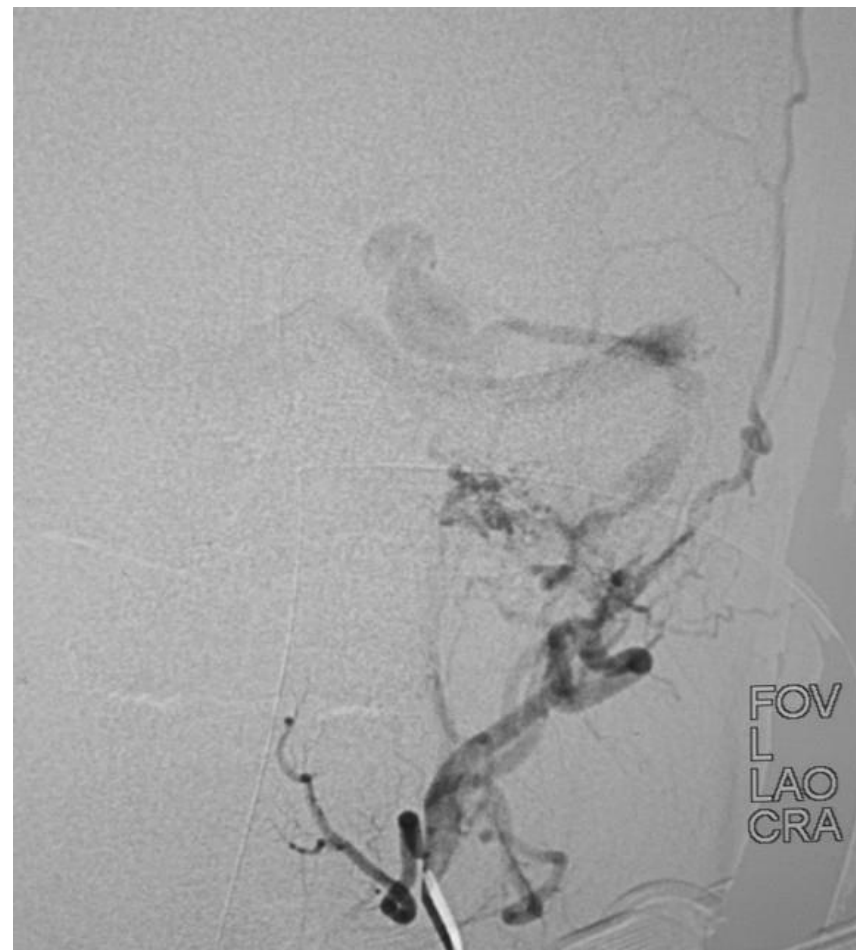
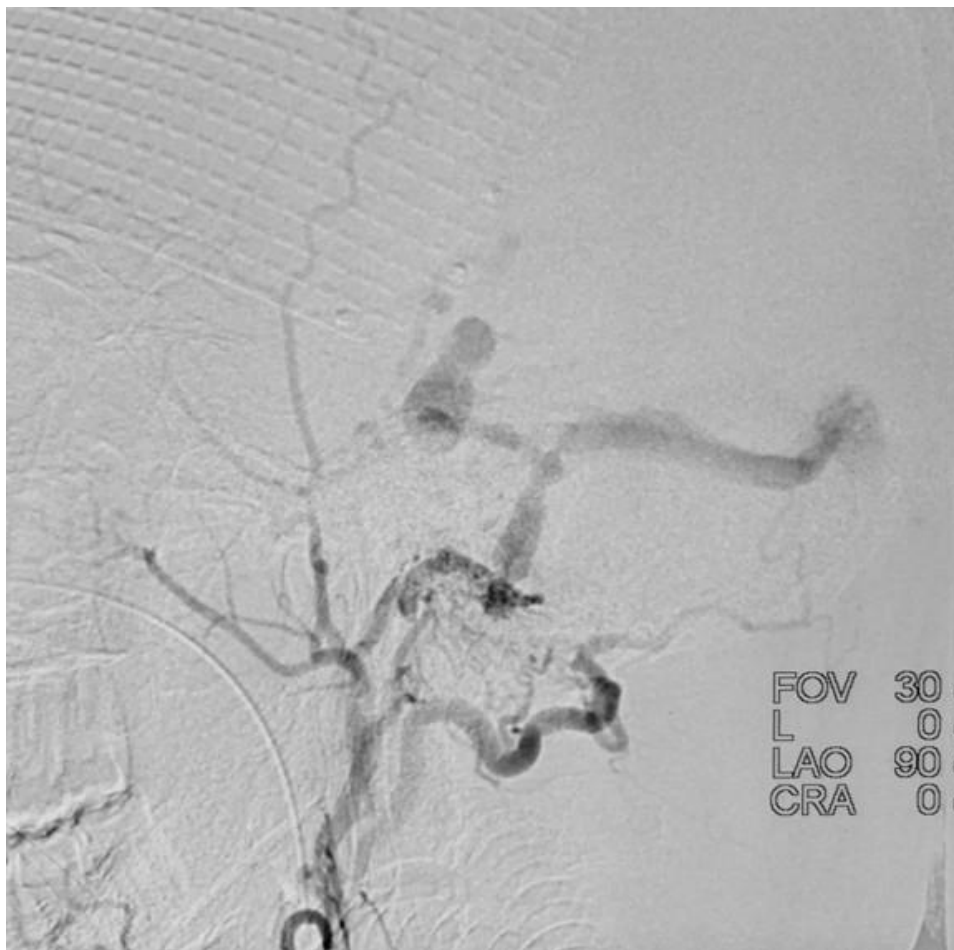
Male, 45y, coma following acute headache for a week


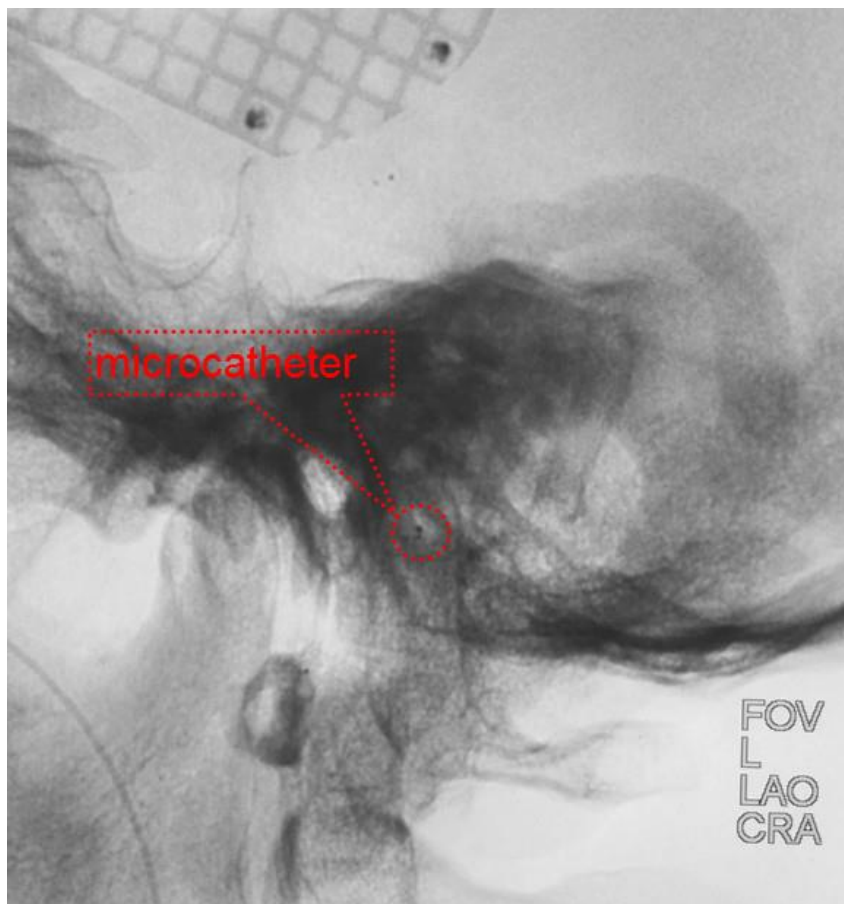
PE: GCS 6, Pupil L:R=3:3, Light reflex (+)

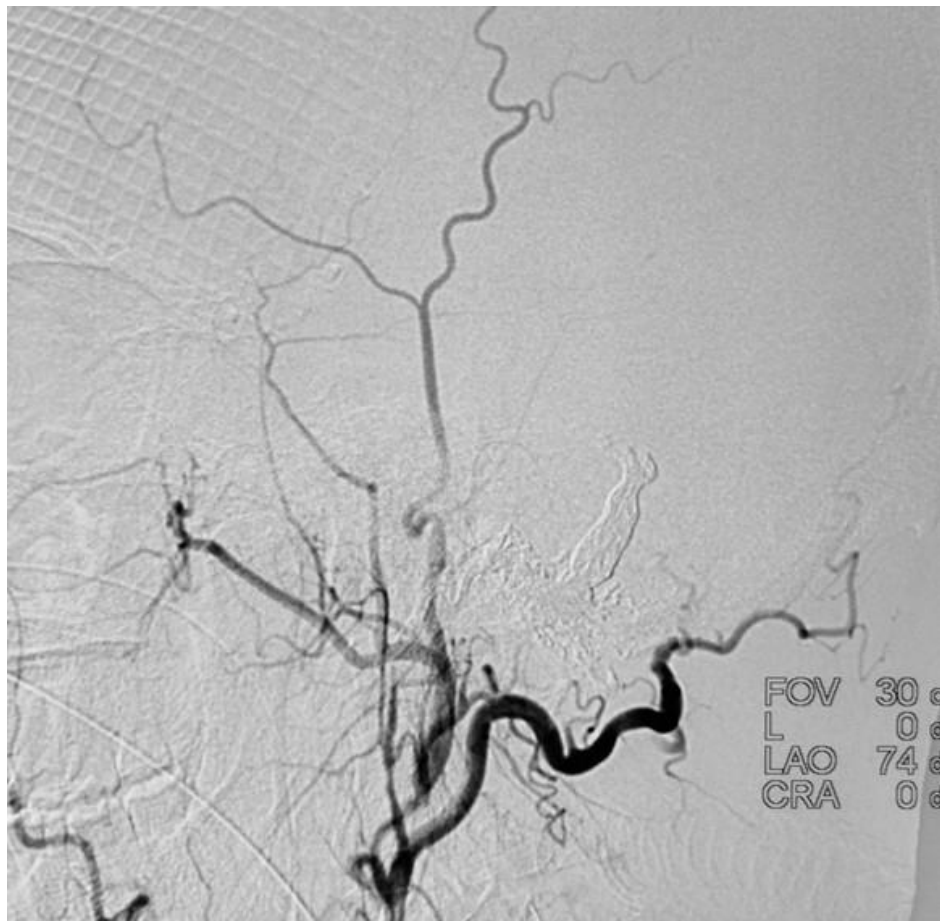
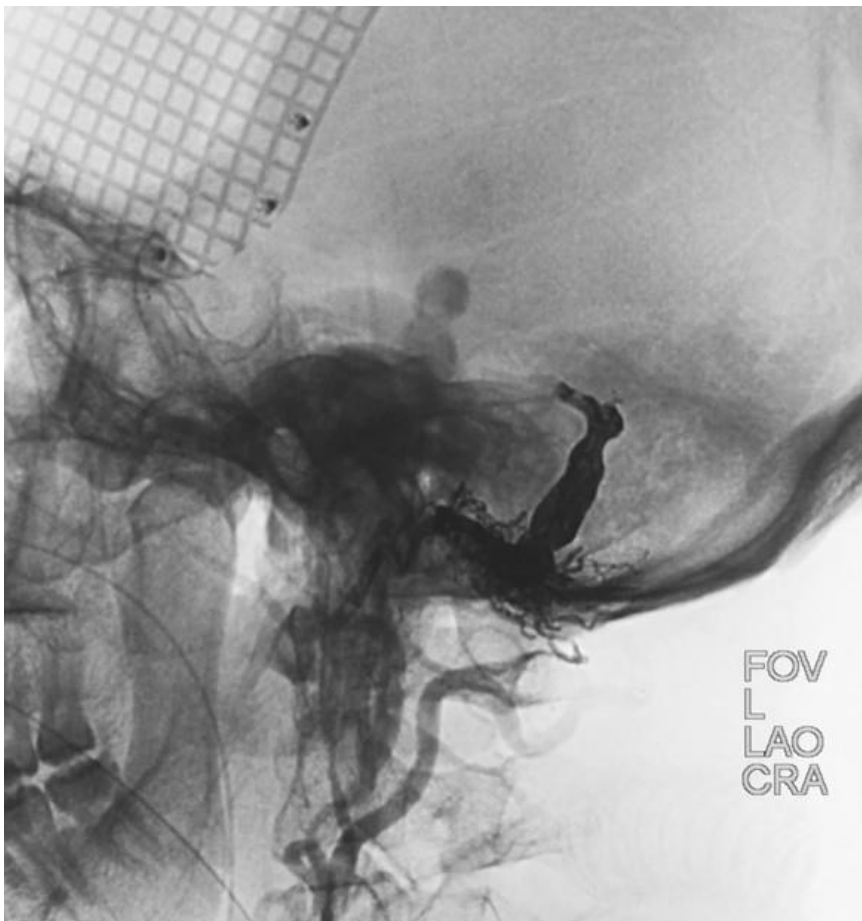PH: Brain trauma 24m ago and Cranioplasty 18m ago

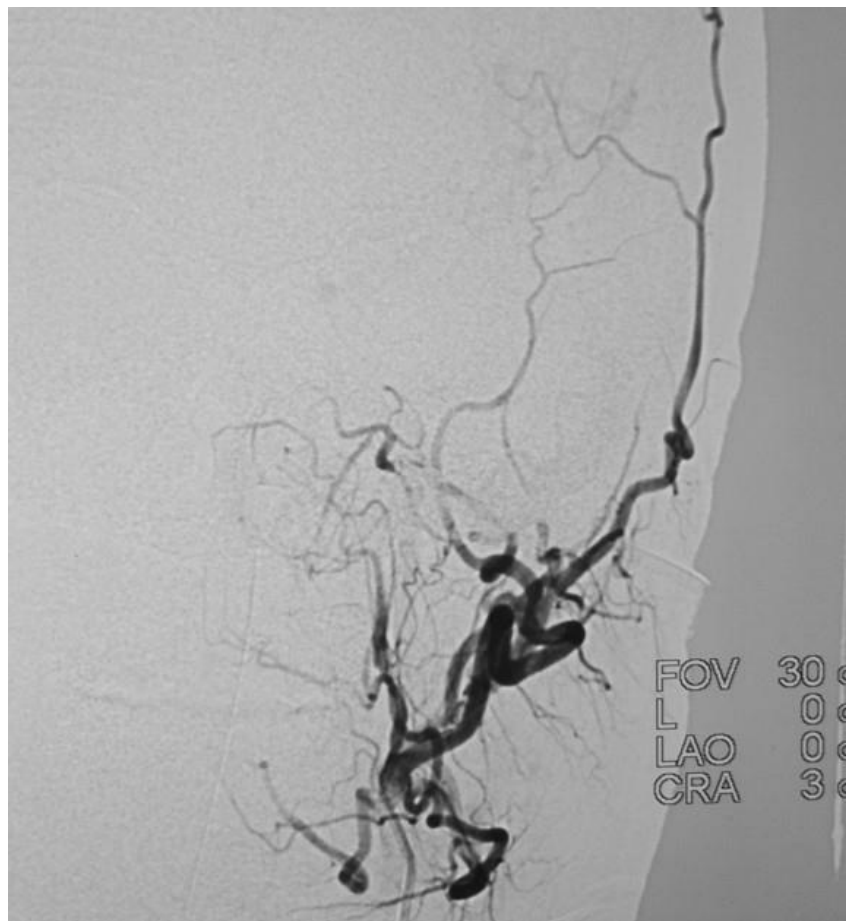
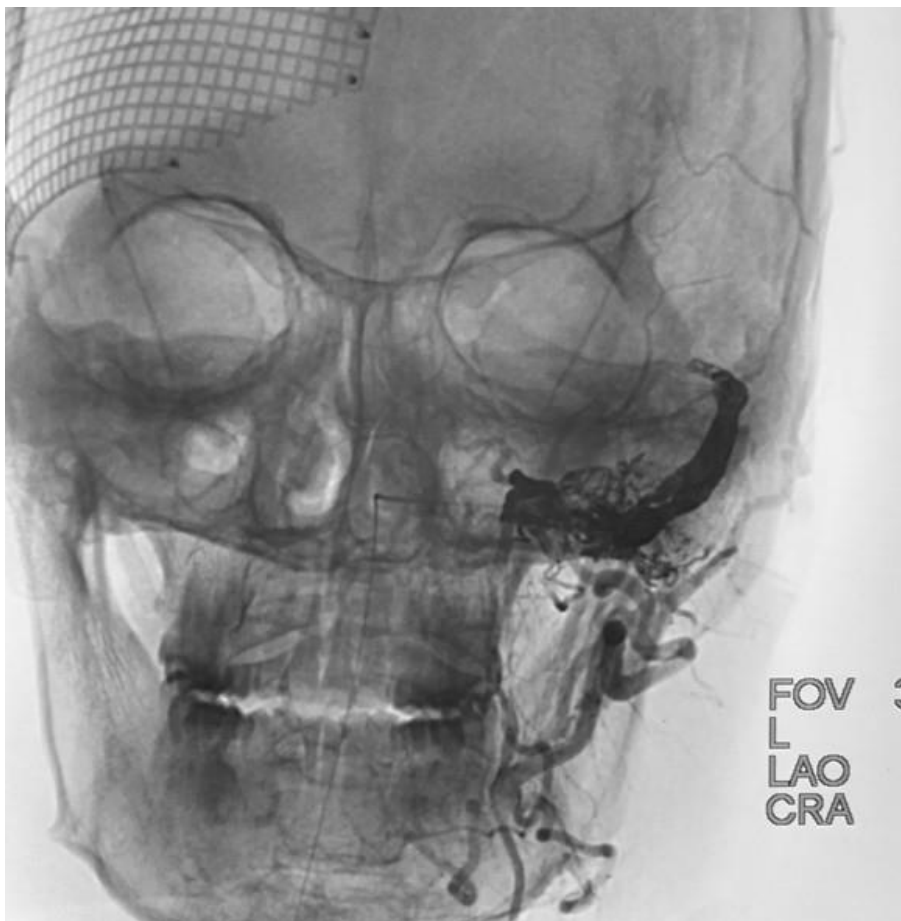

# blood supply from LECA only

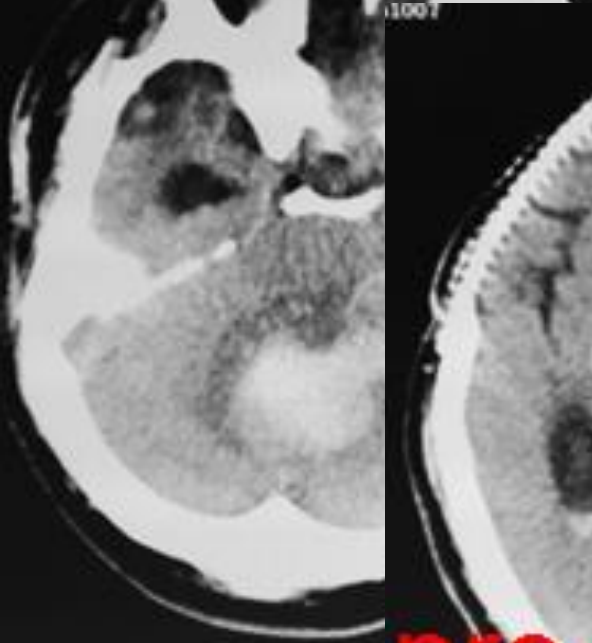
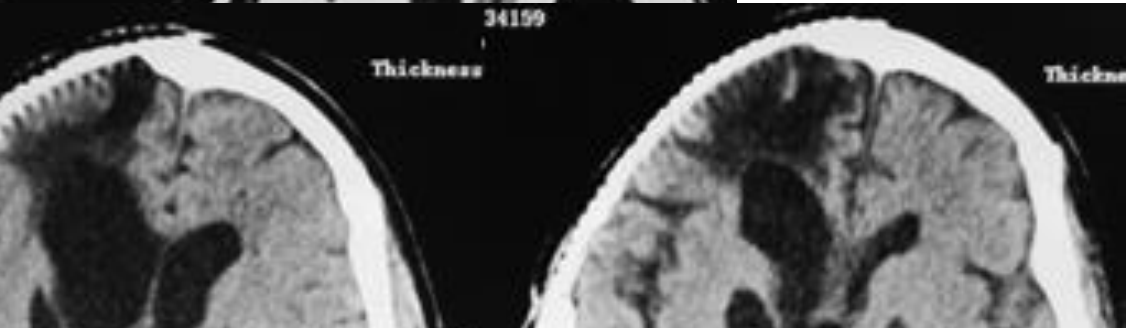
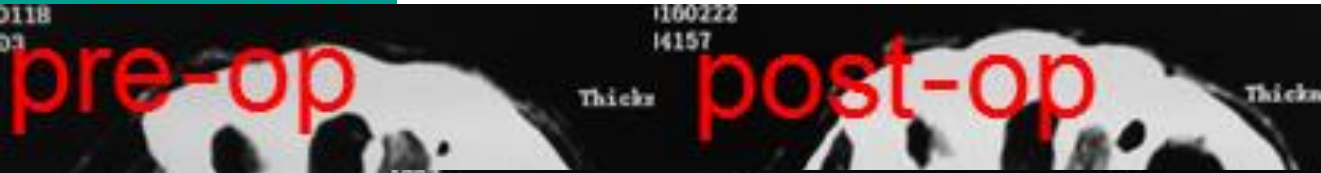


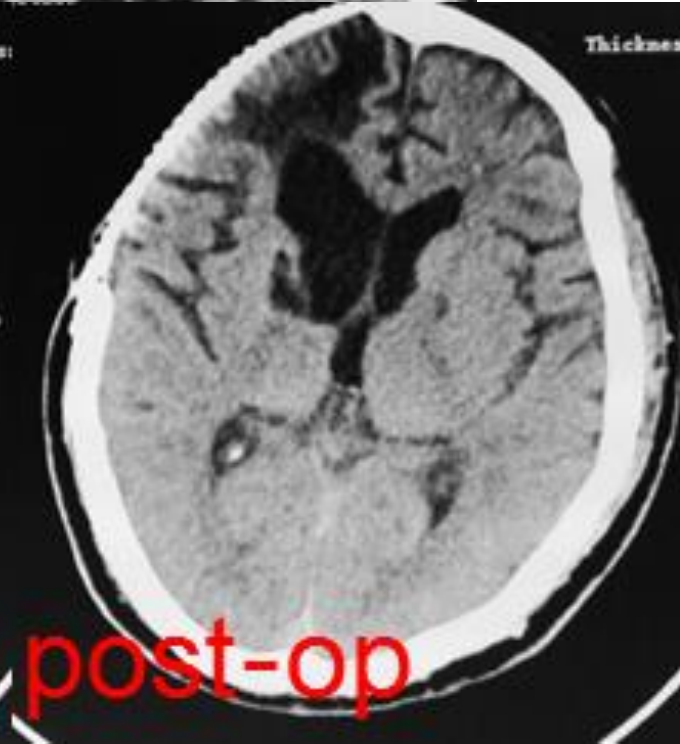
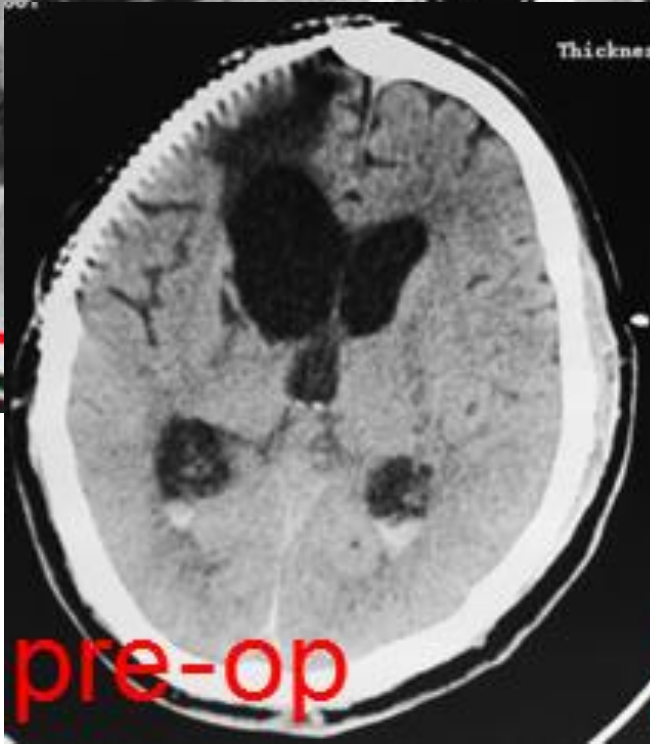




1 week



pre-



GCS15  
mRS 0

pre-op

post-op



THANK YOU VERY MUCH