

Endovascular Treatment of Cranial DAVF

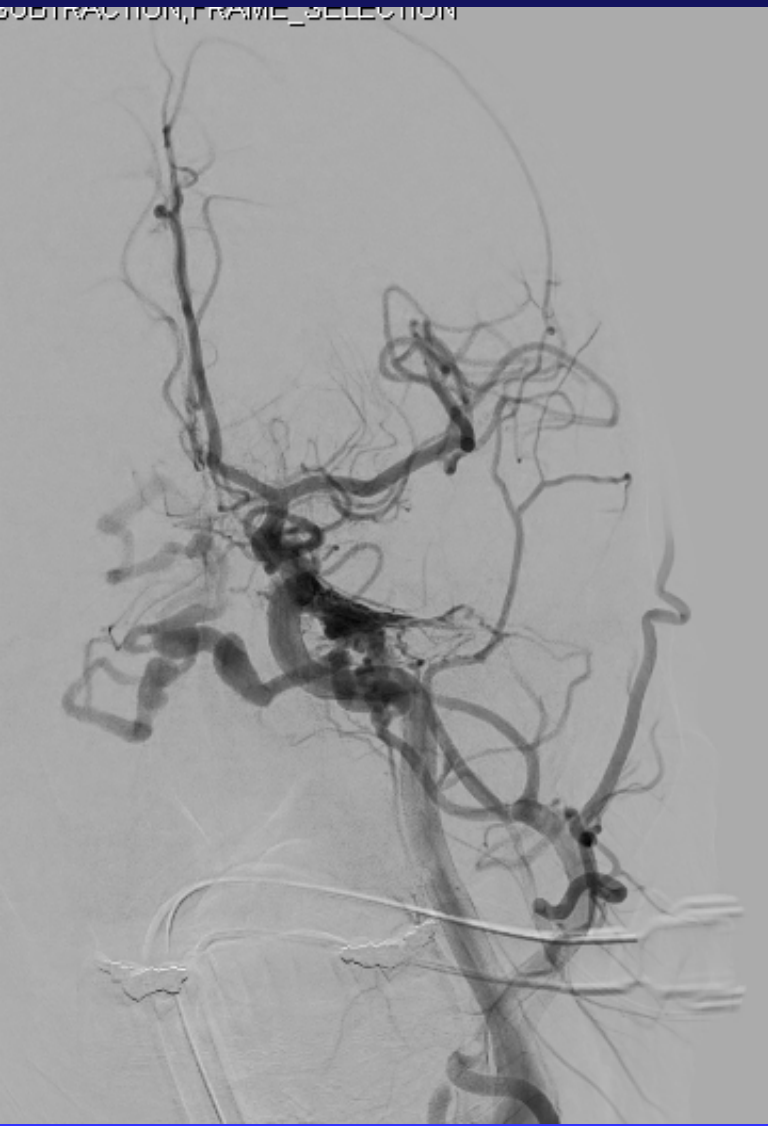
Gyula Gál

Department of Radiology
University Hospital
Odense, Denmark

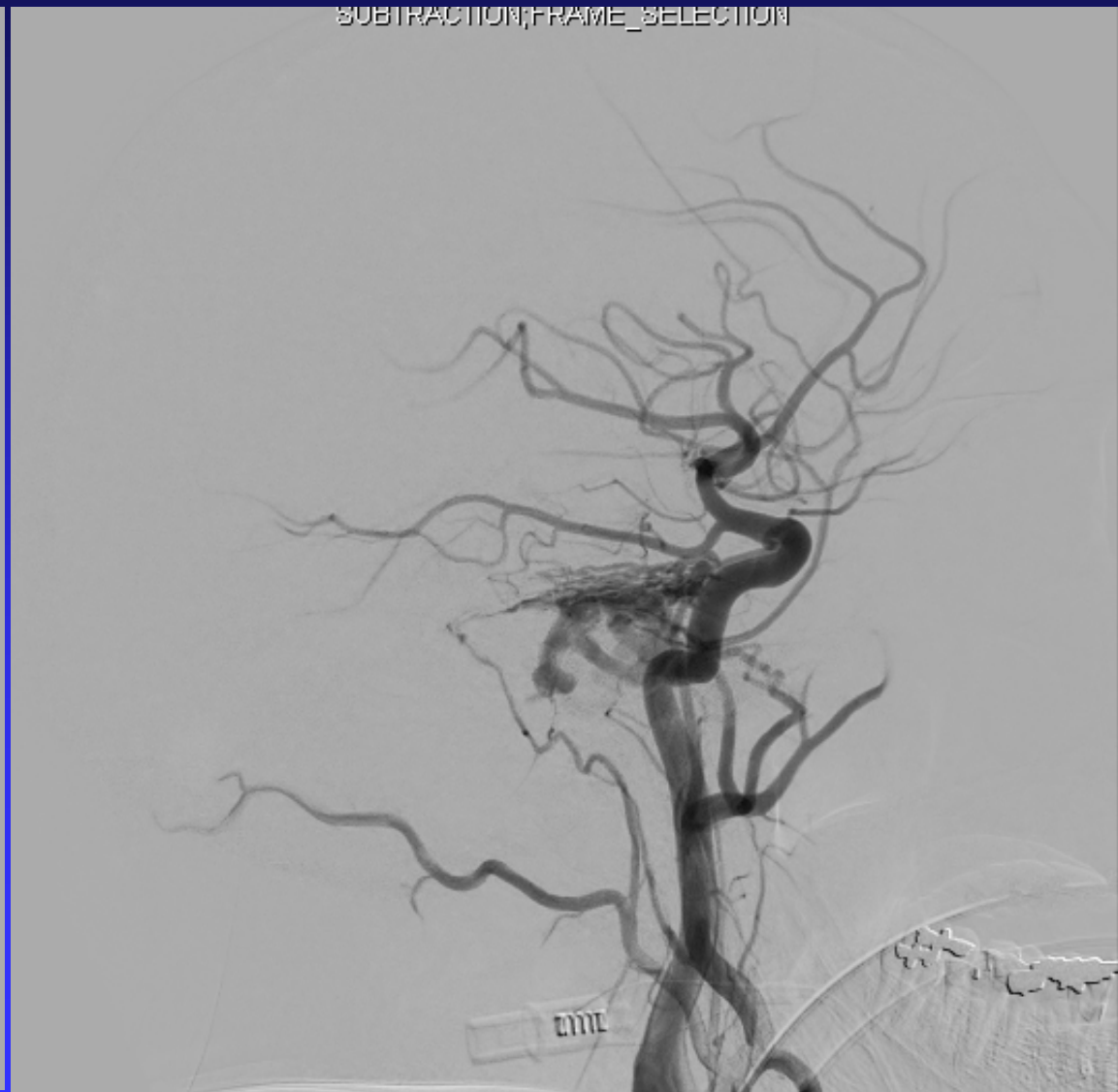


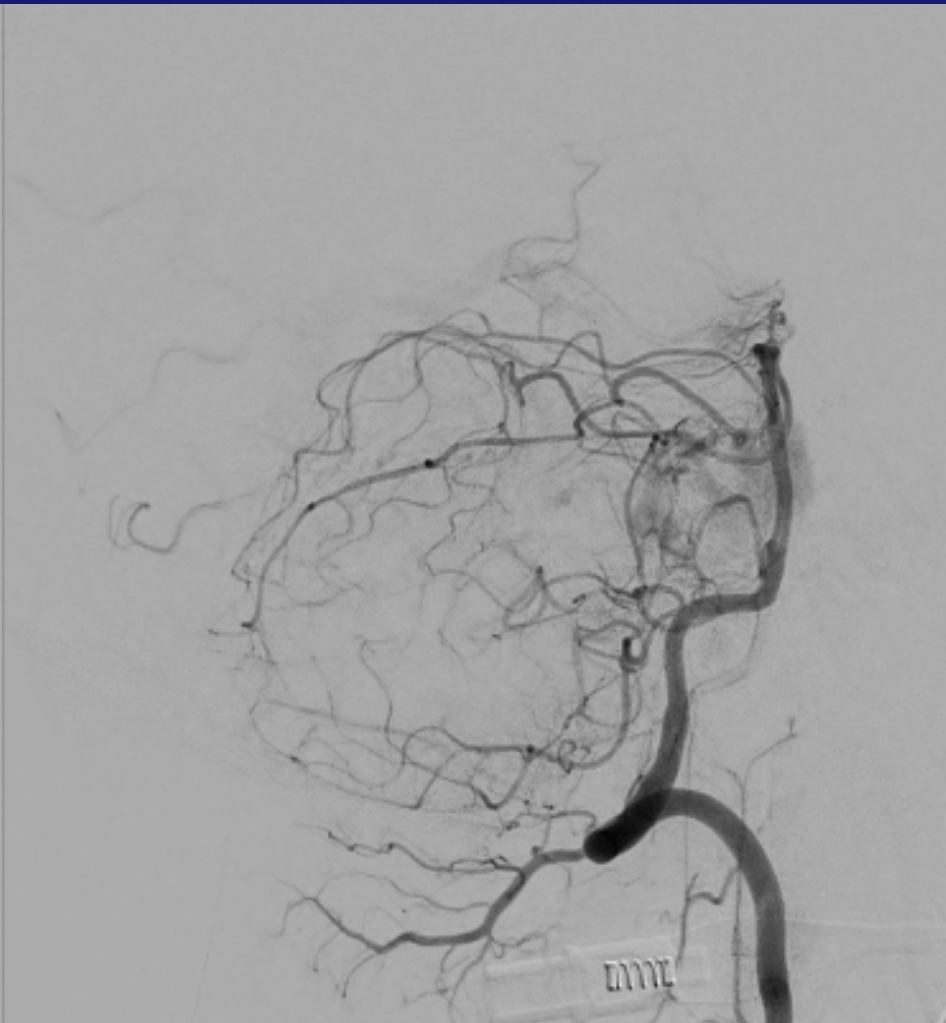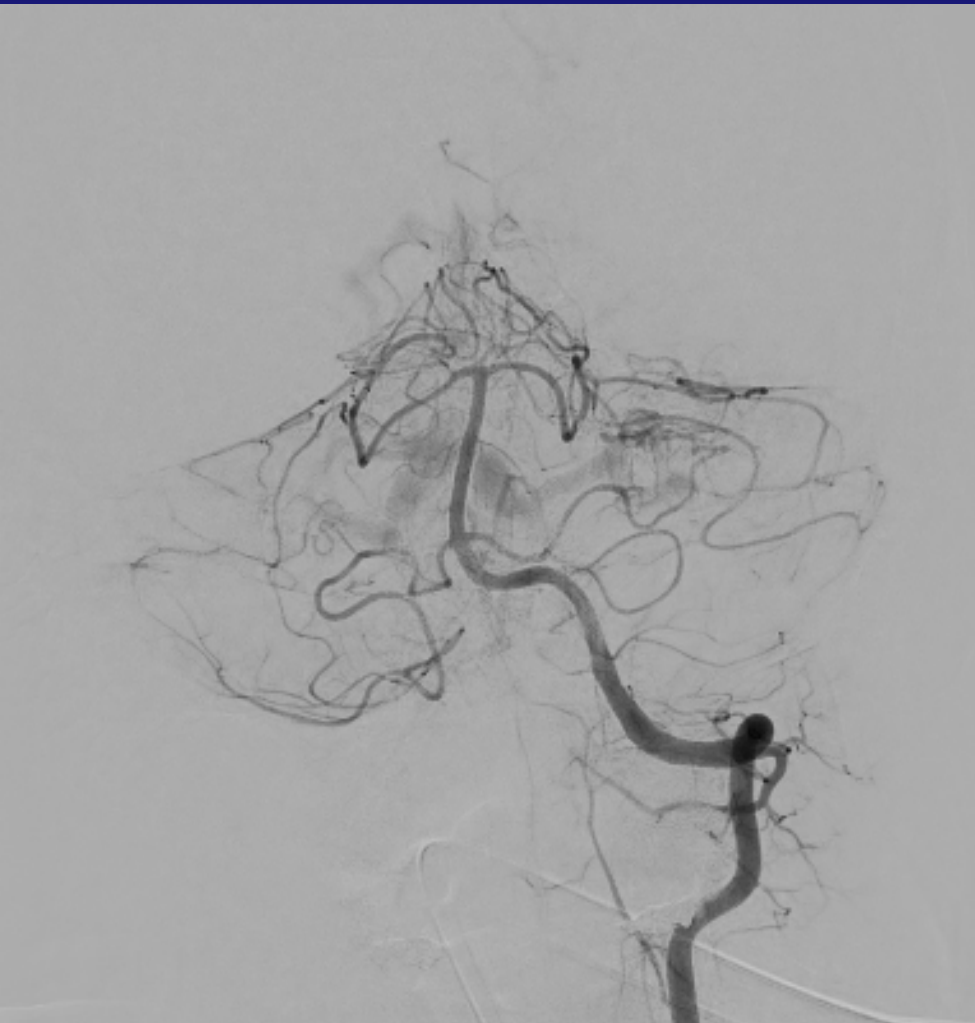
45 yrs male, ruptured

SUBTRACTION,FRAME_SELECTION

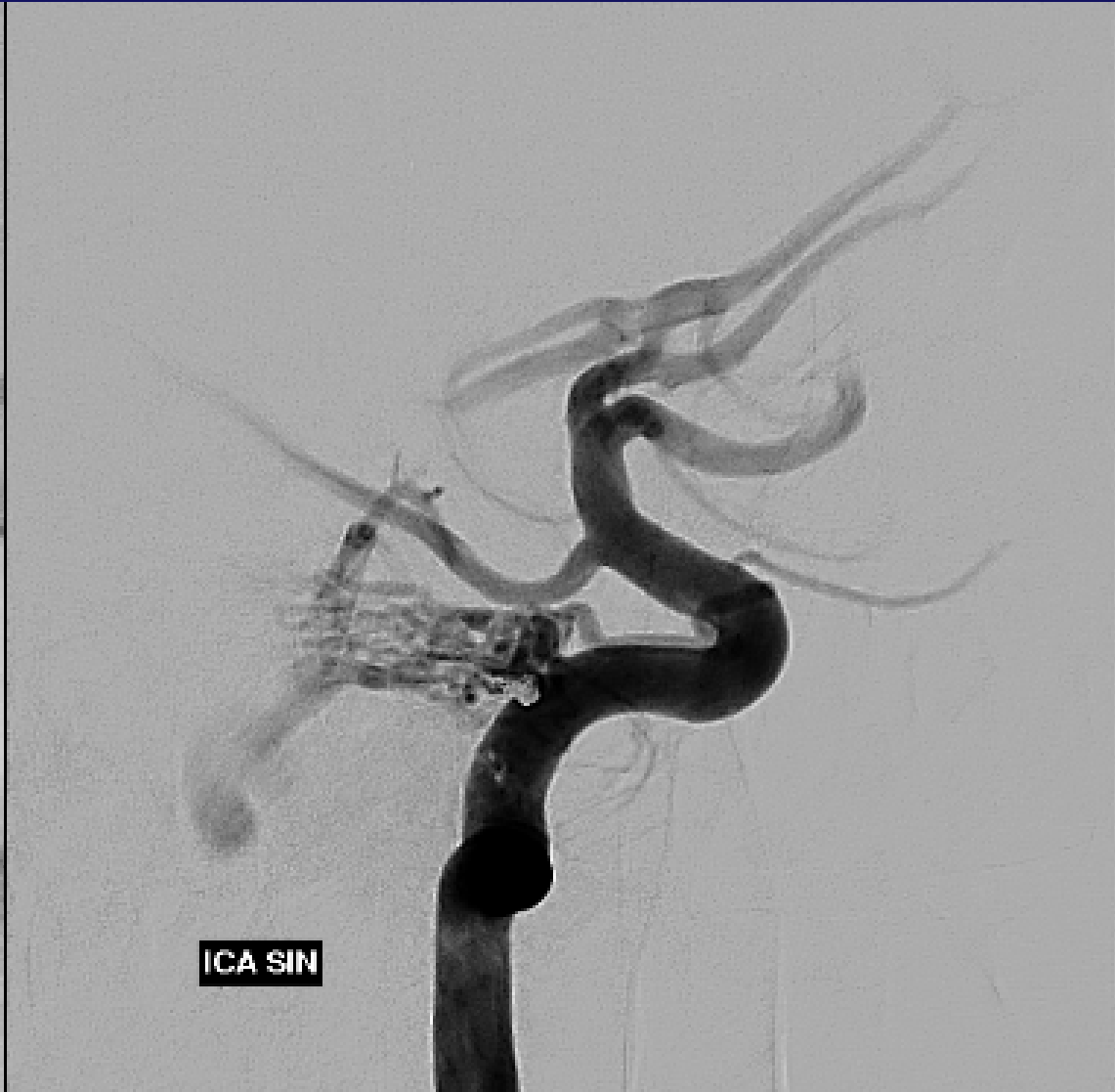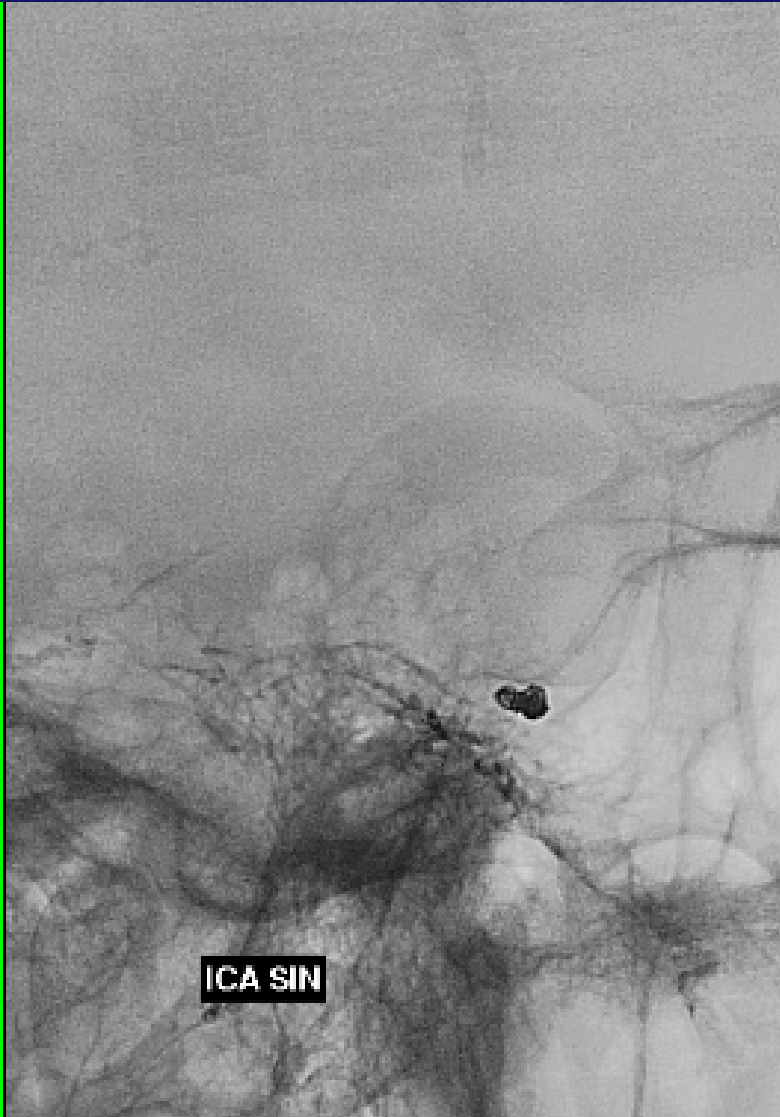


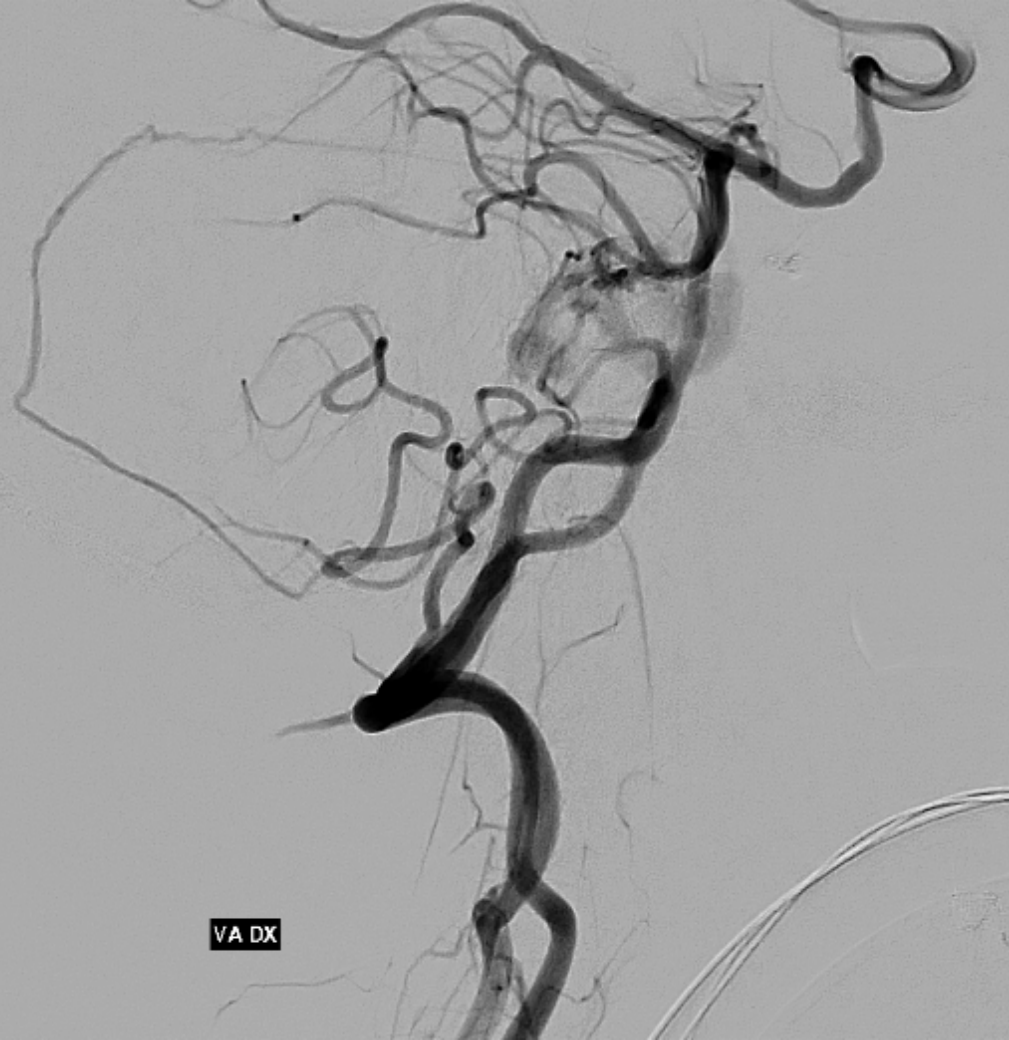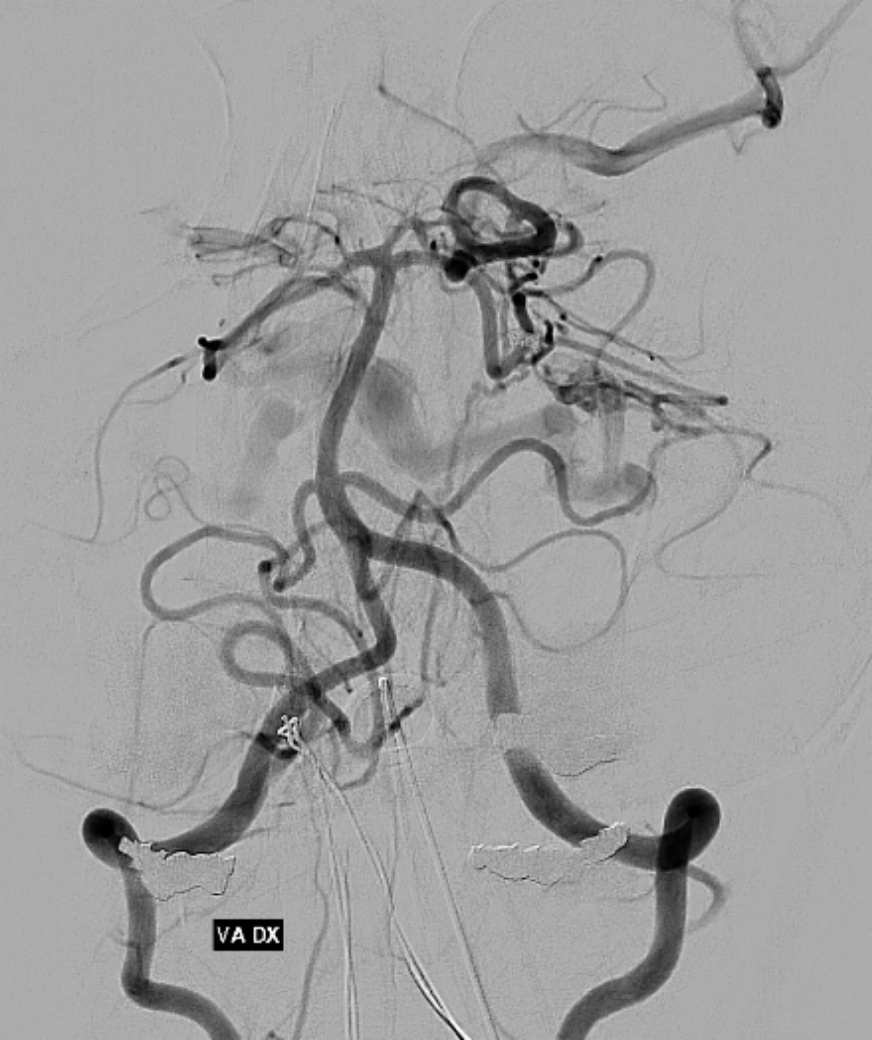SUBTRACTION,FRAME_SELECTION

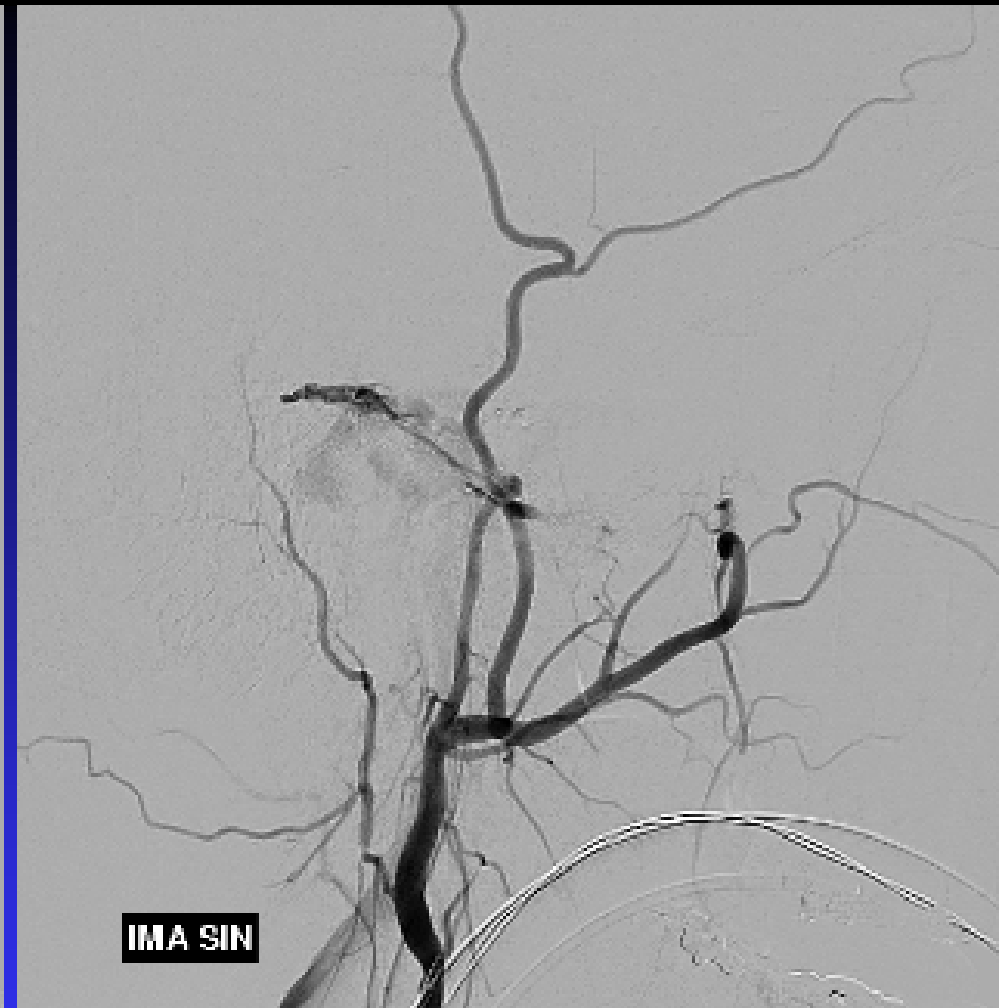
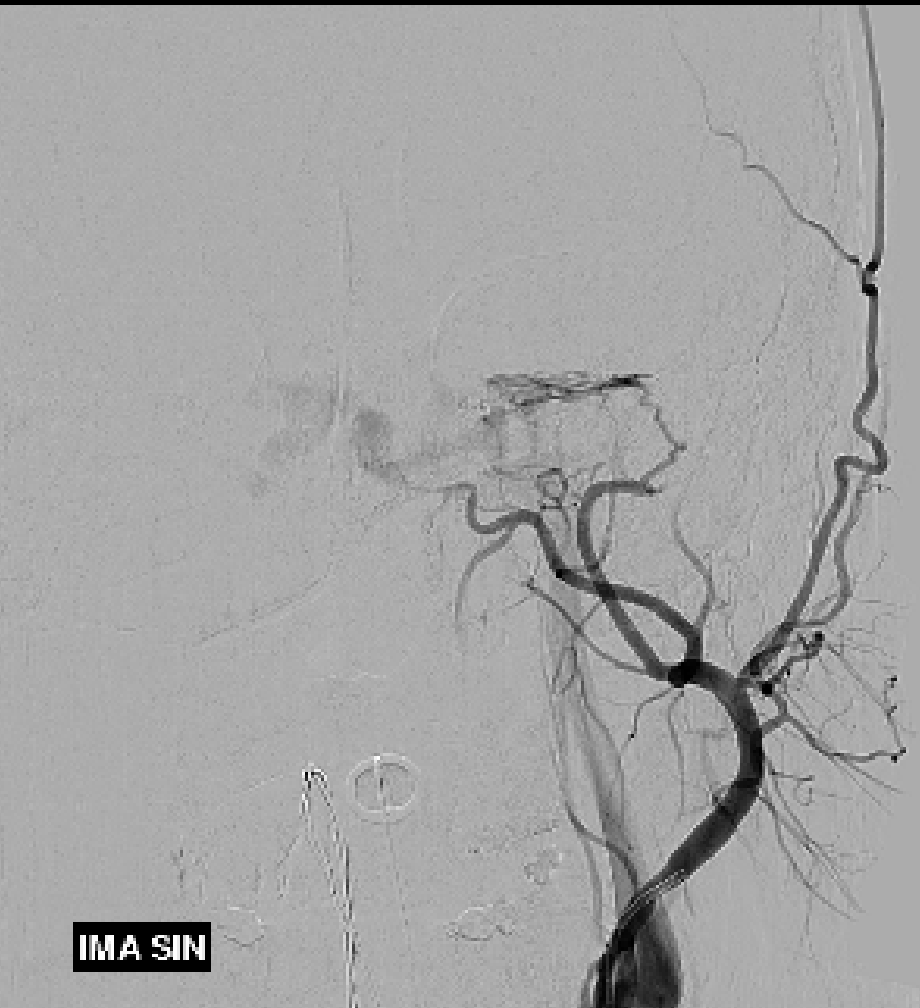


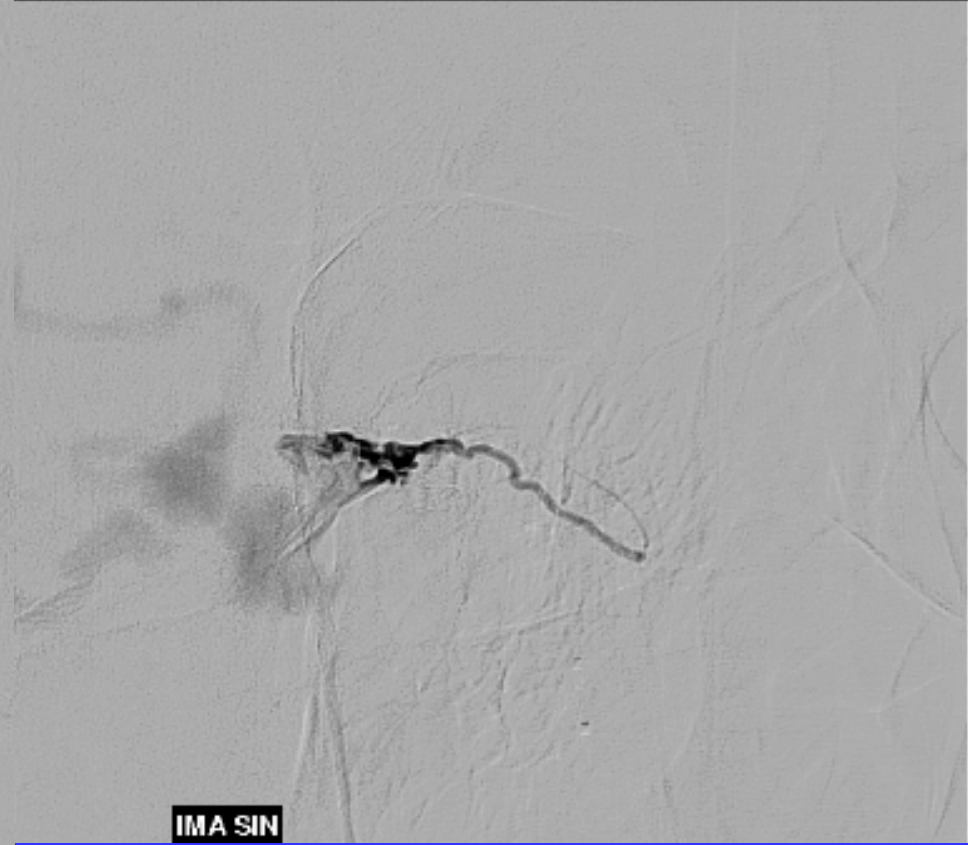
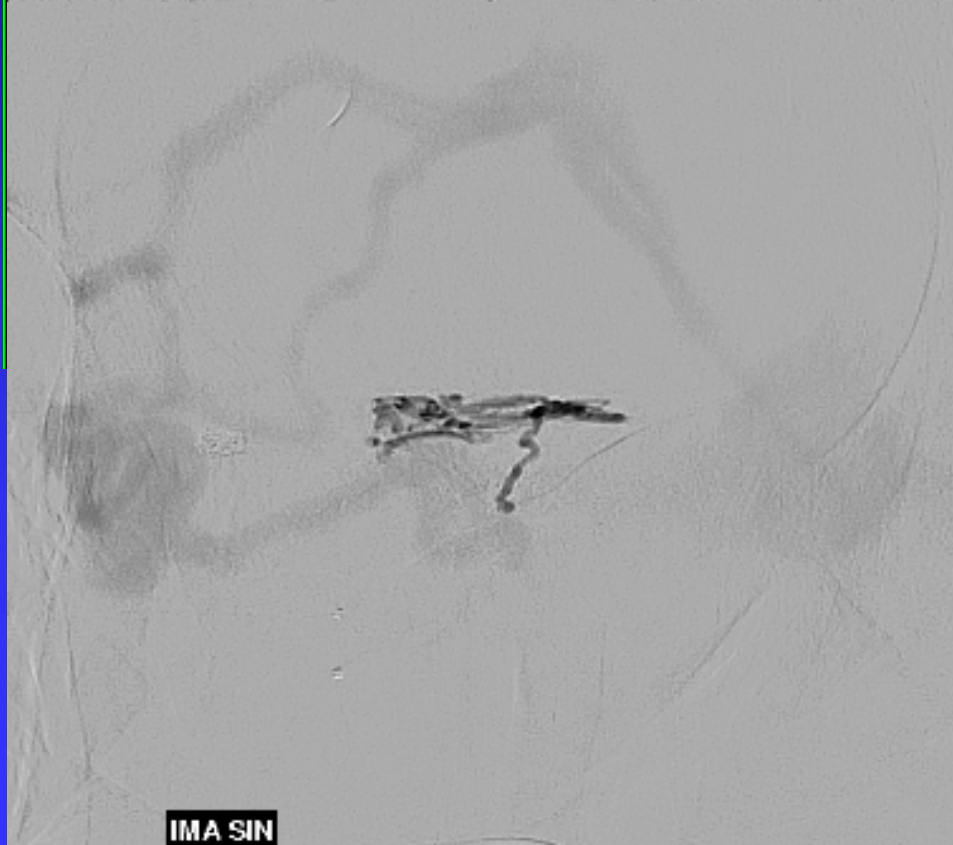
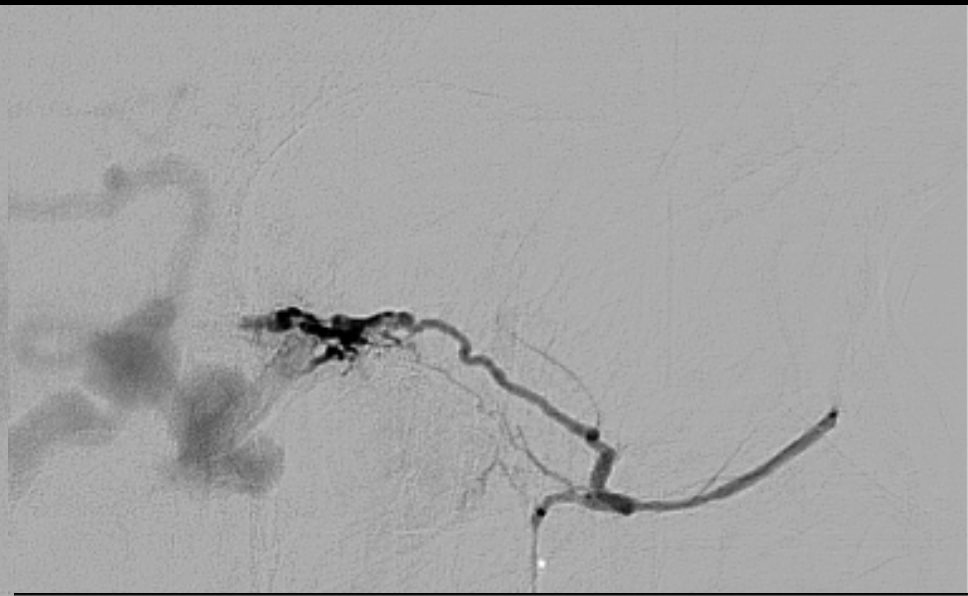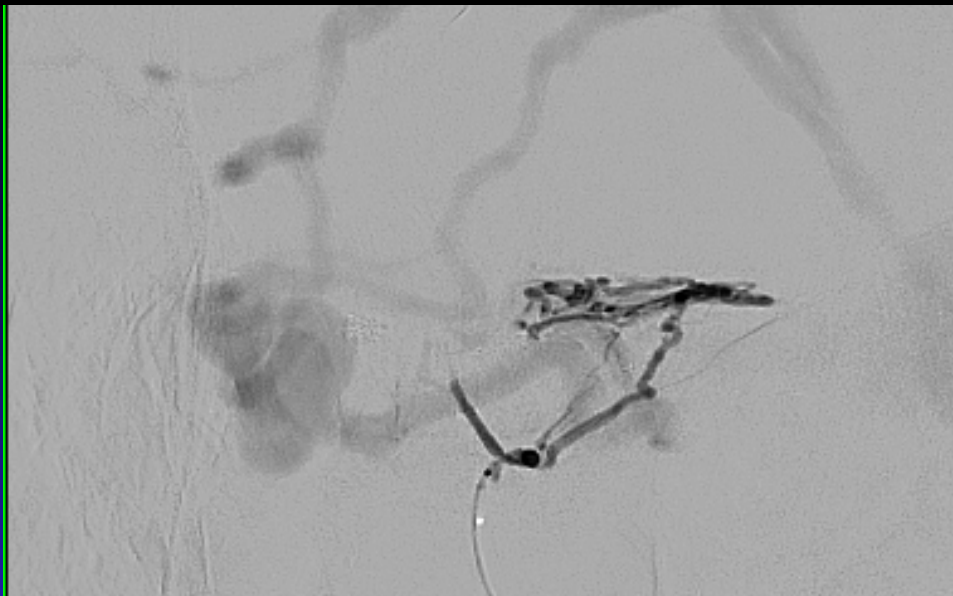After two EVTs, in another inst.



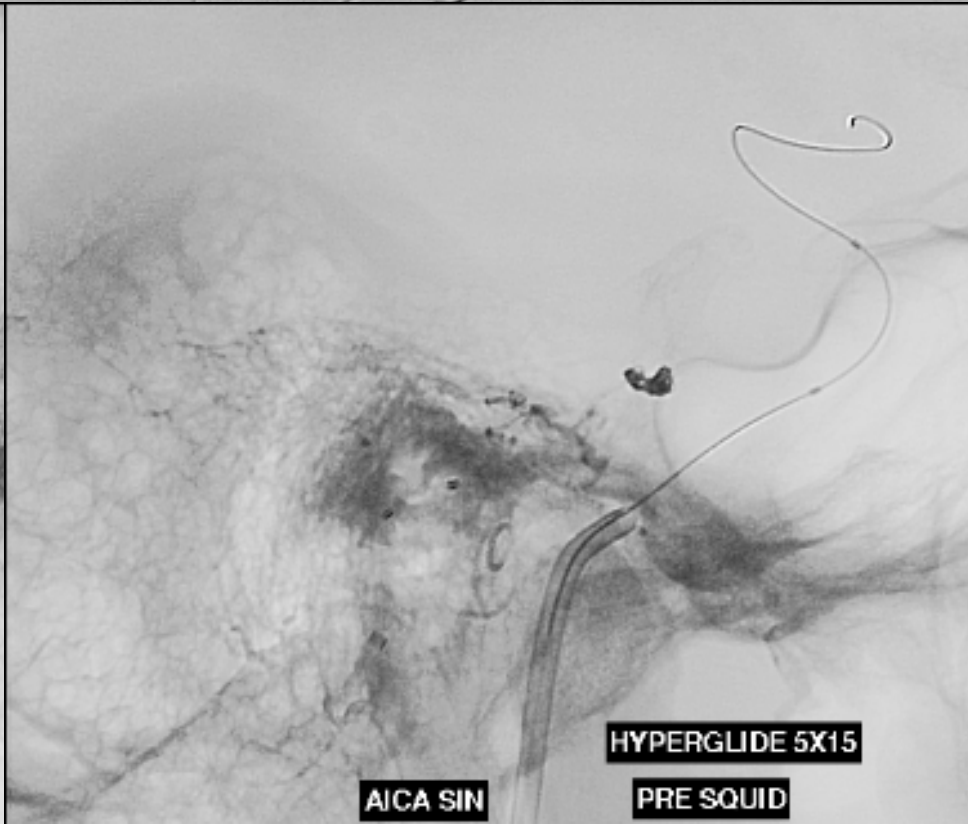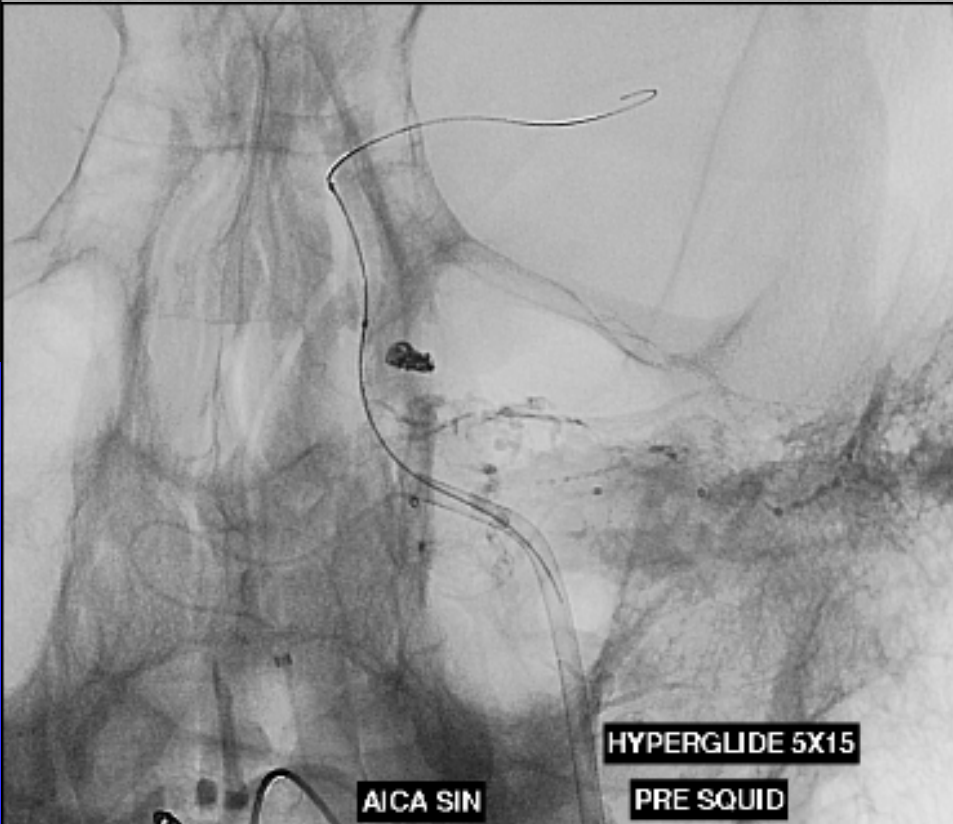
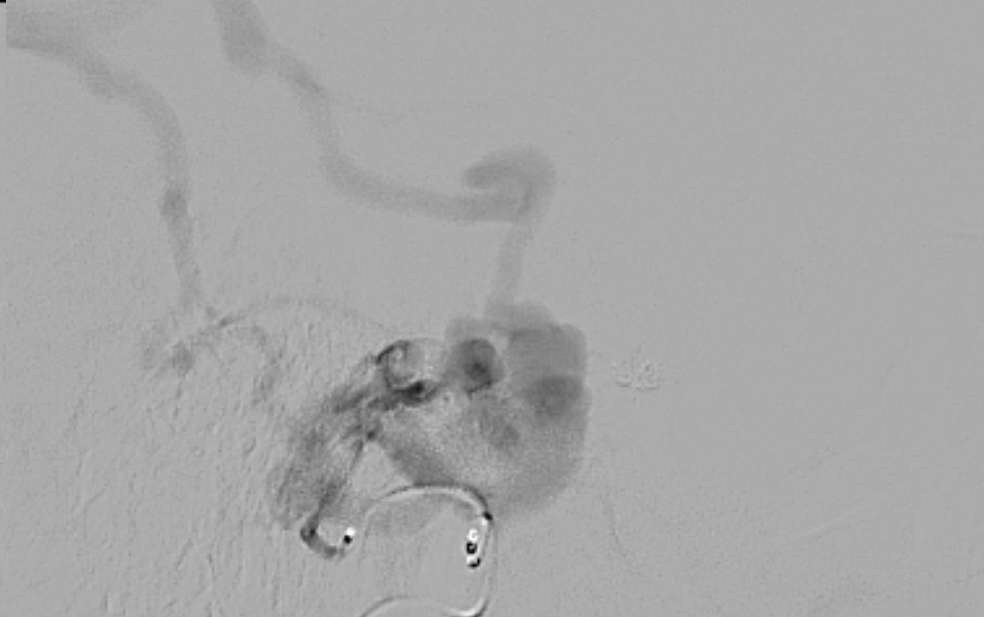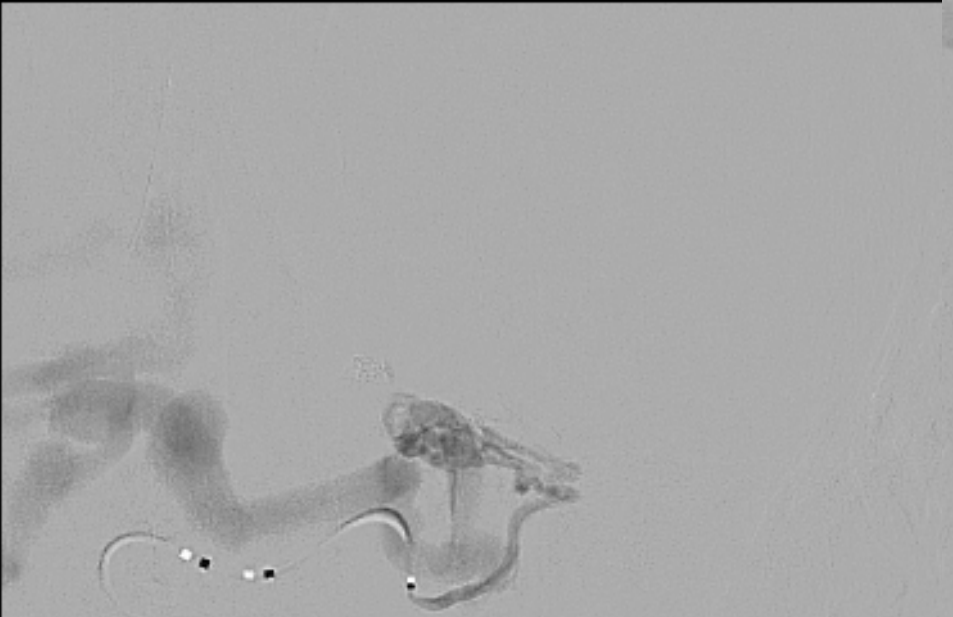




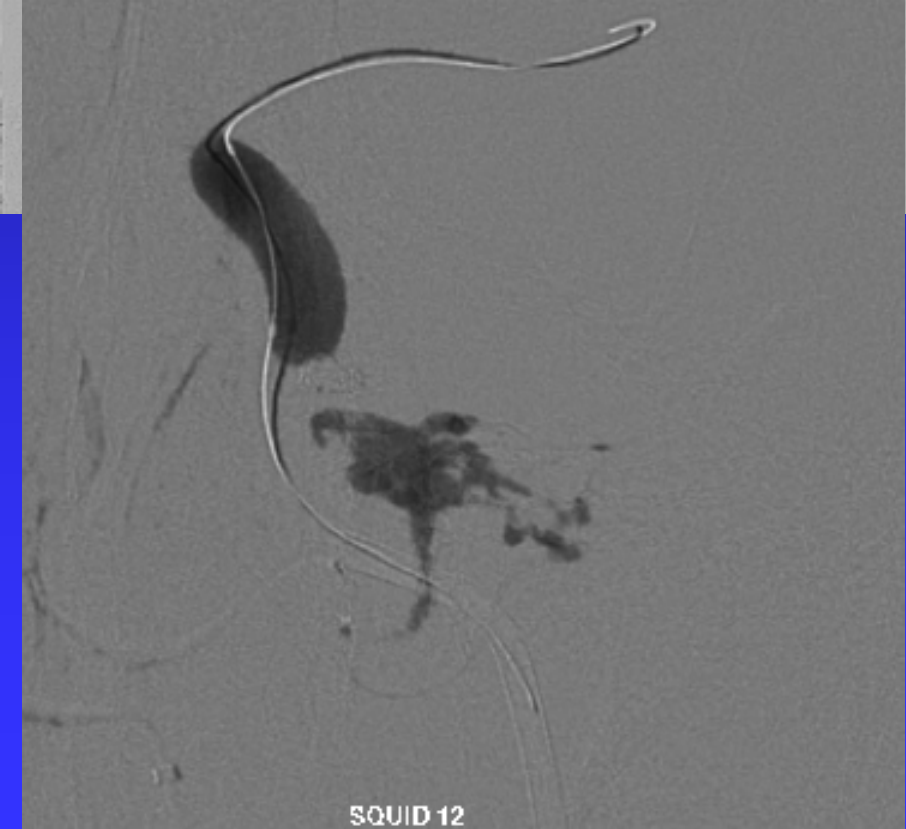
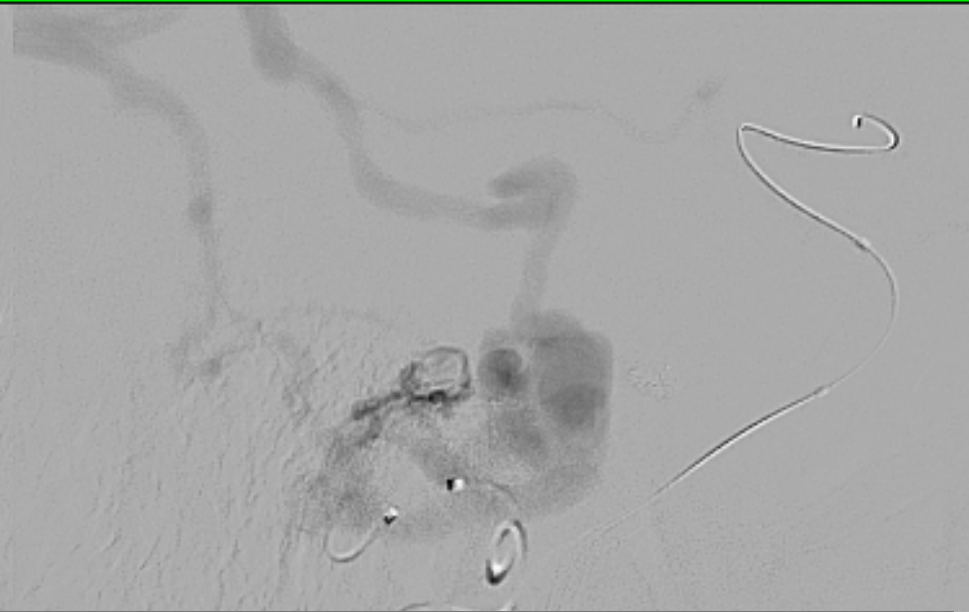
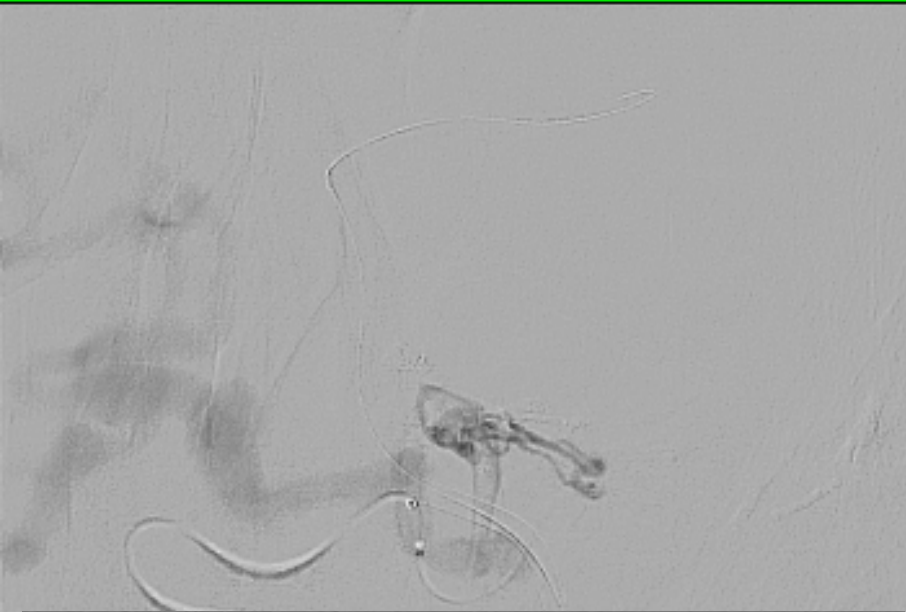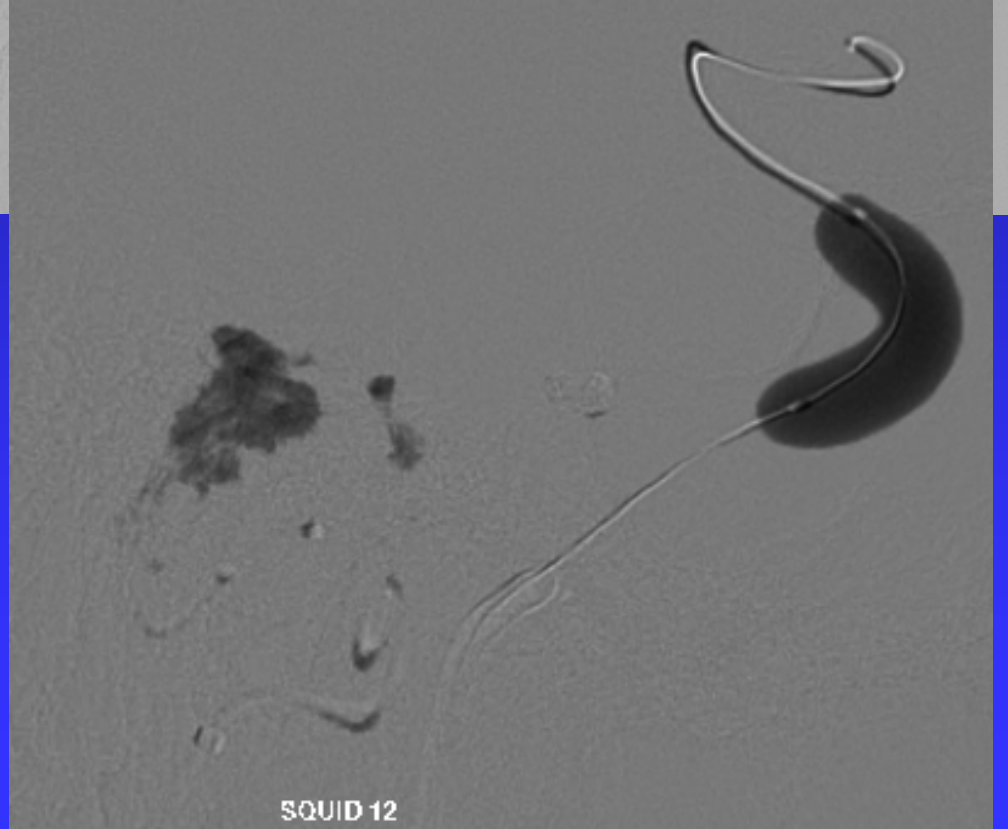
IMA SIN

IMA SIN





SQUID 12



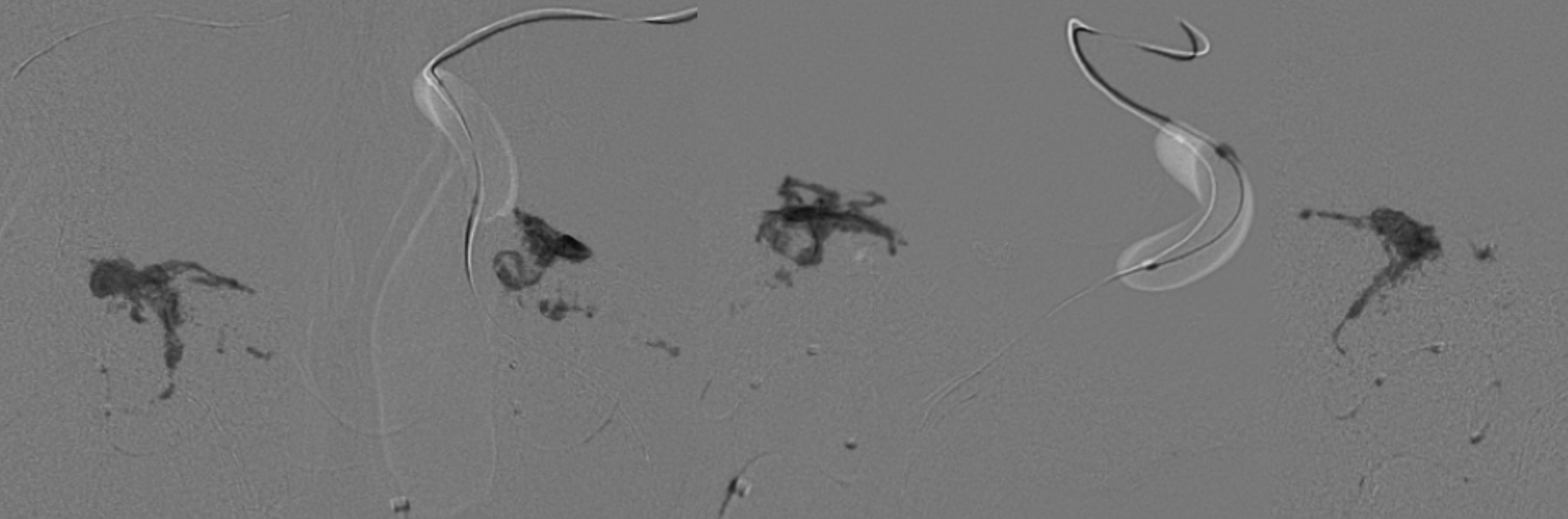
SQUID 12

SUBTRACTION

SUBTRACTION

SUBTRACTION

SUBTRACTION

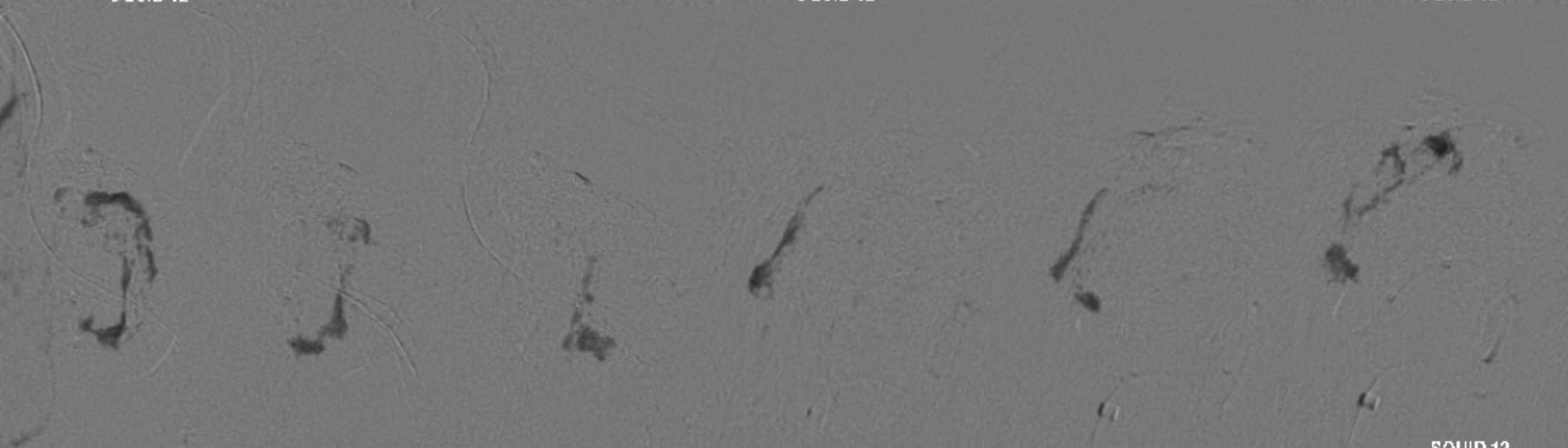


SQUID 12

SQUID 12

SQUID 12

SQUID 12



SQUID 12

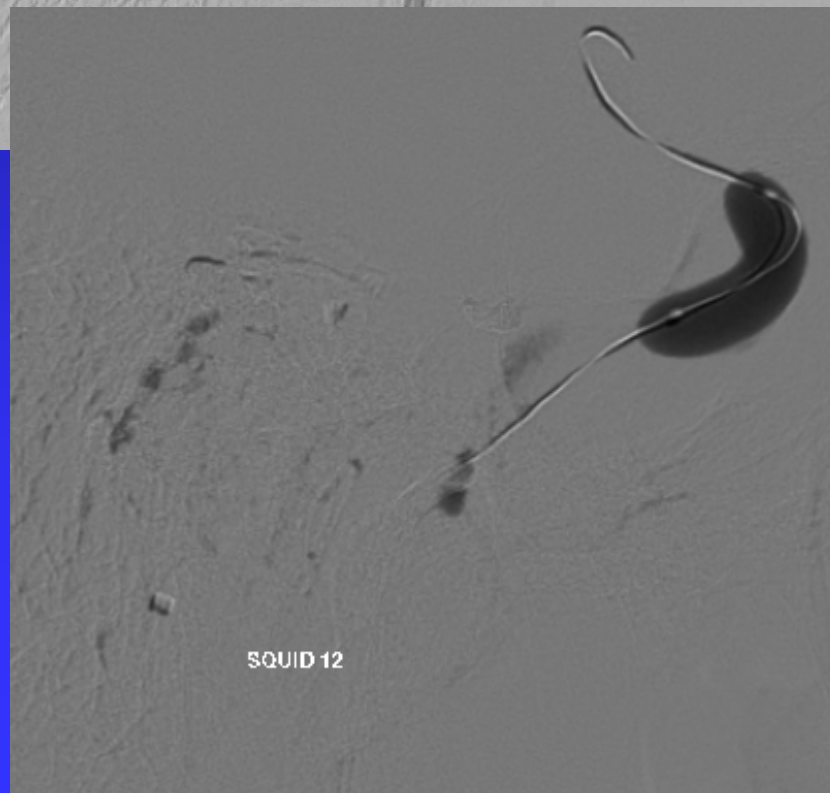
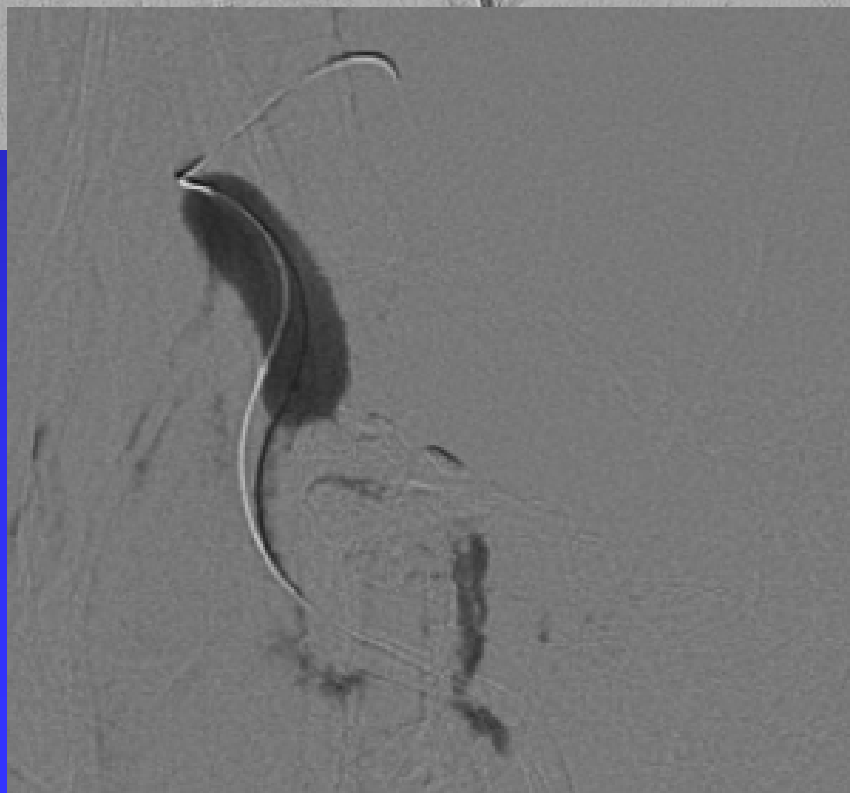
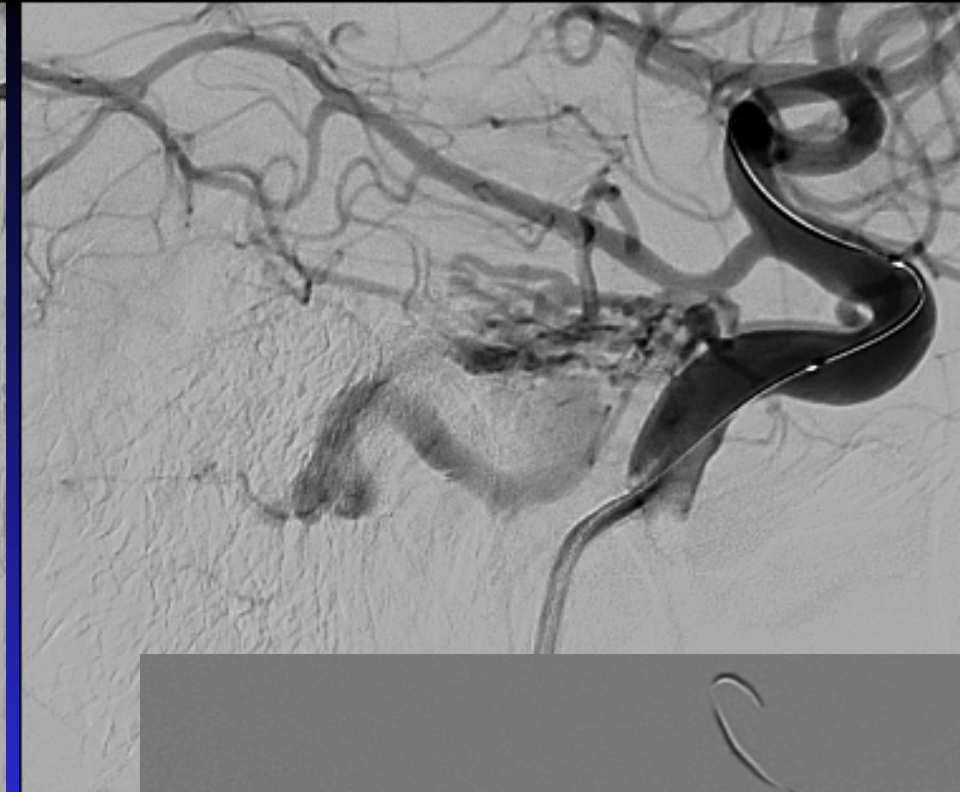
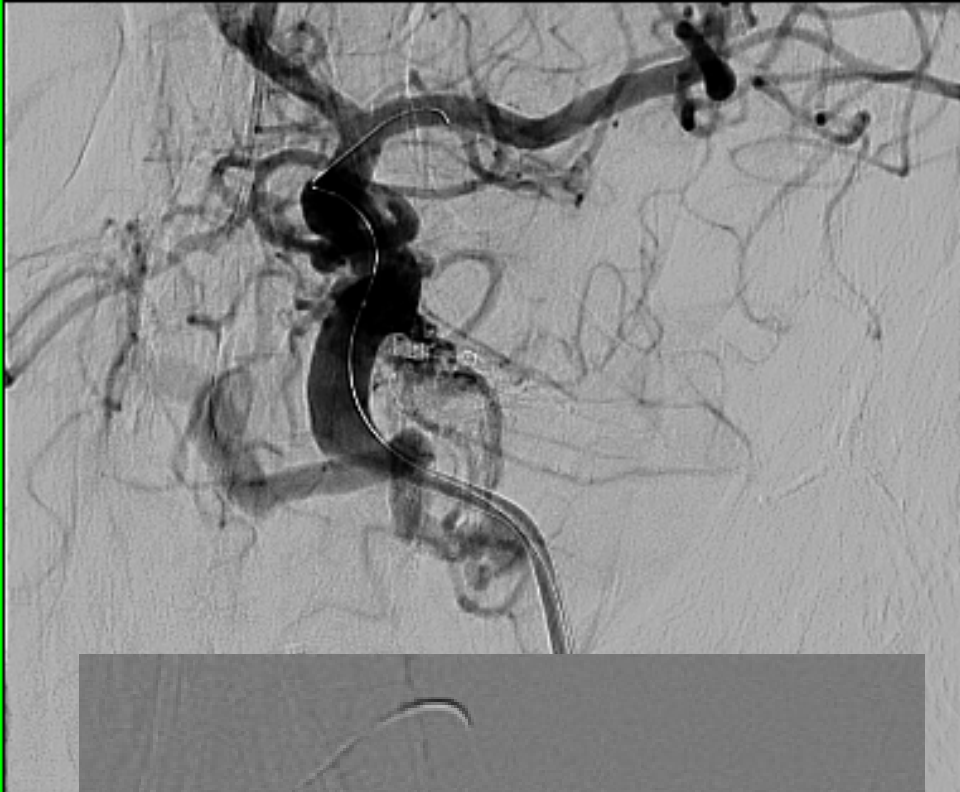
SQUID 12

SQUID 12

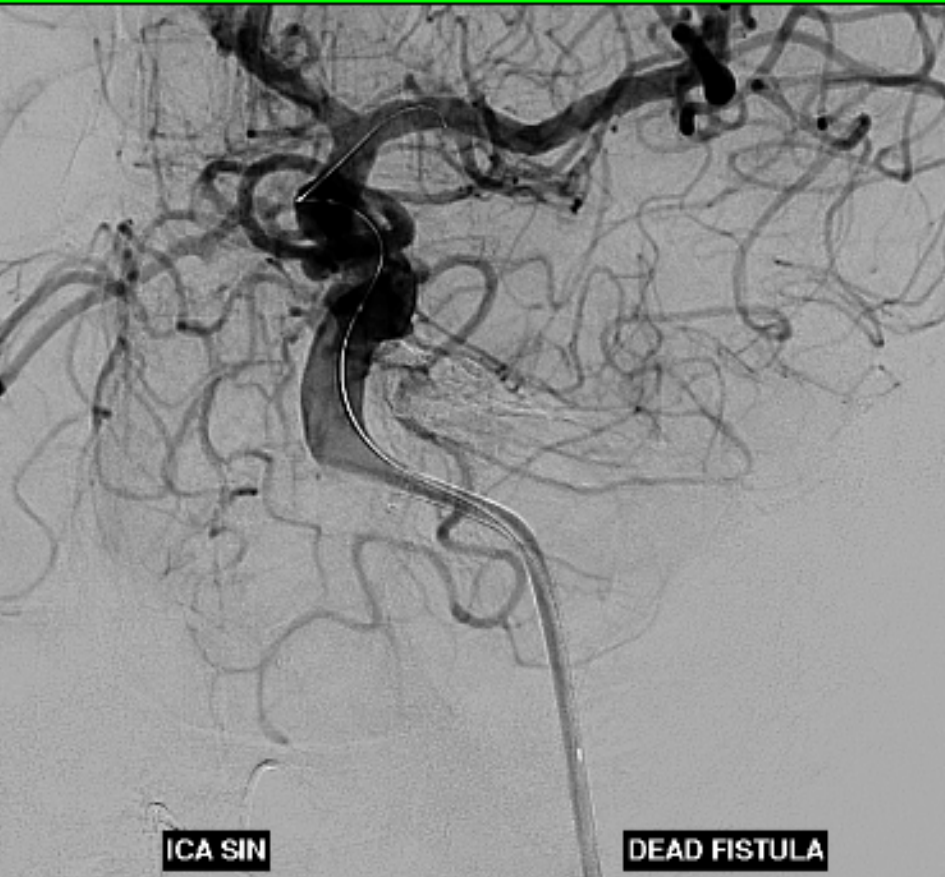
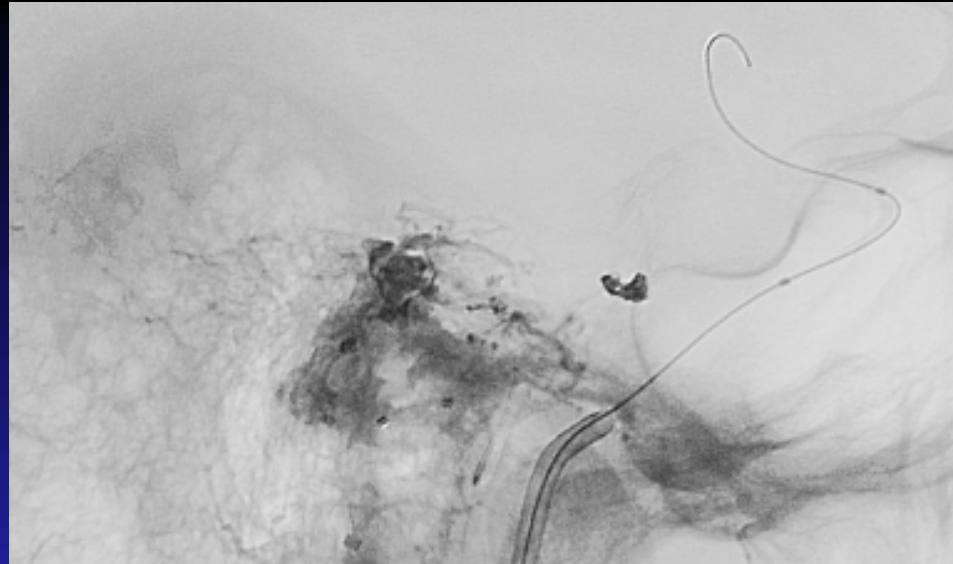
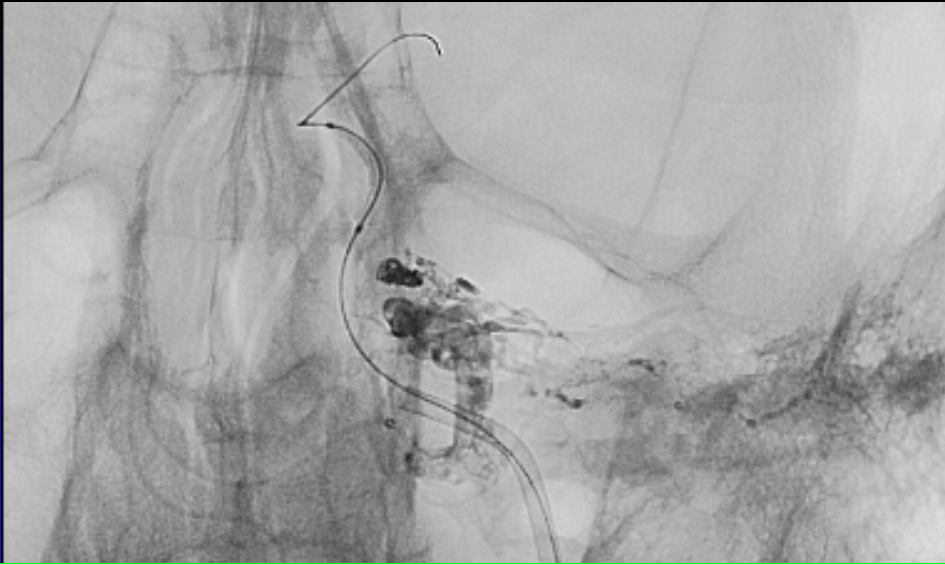SQUID 12

SQUID 12

SQUID 12

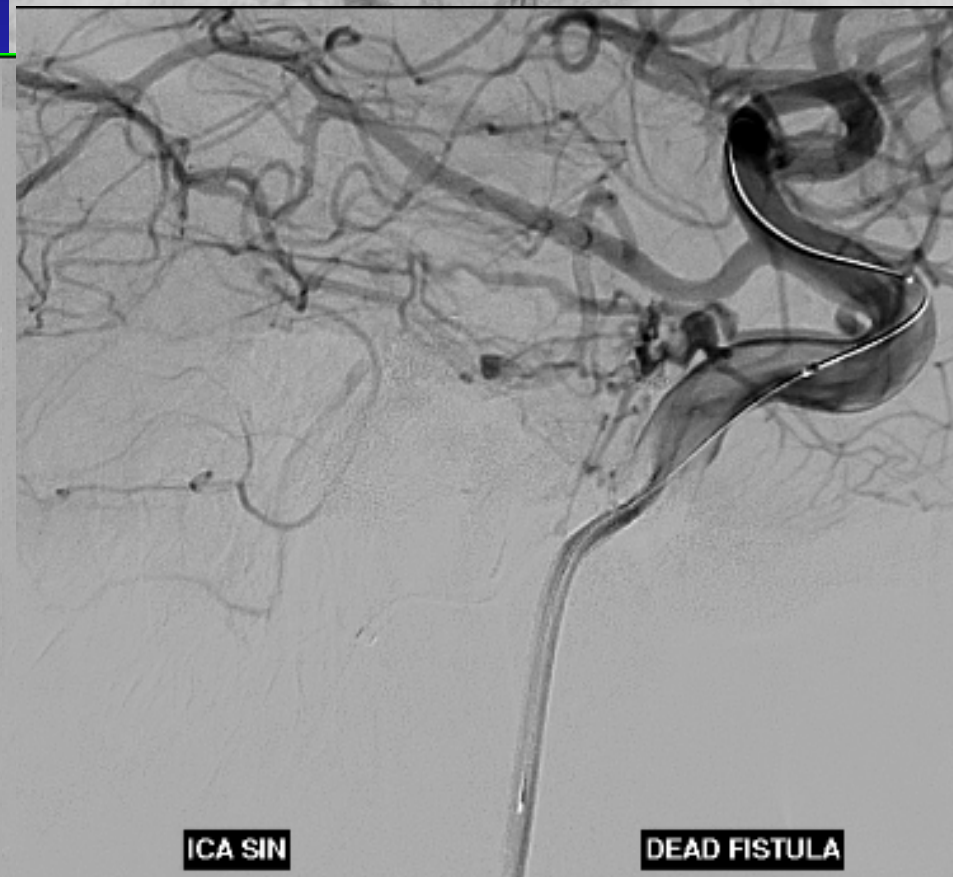


SQUID 12



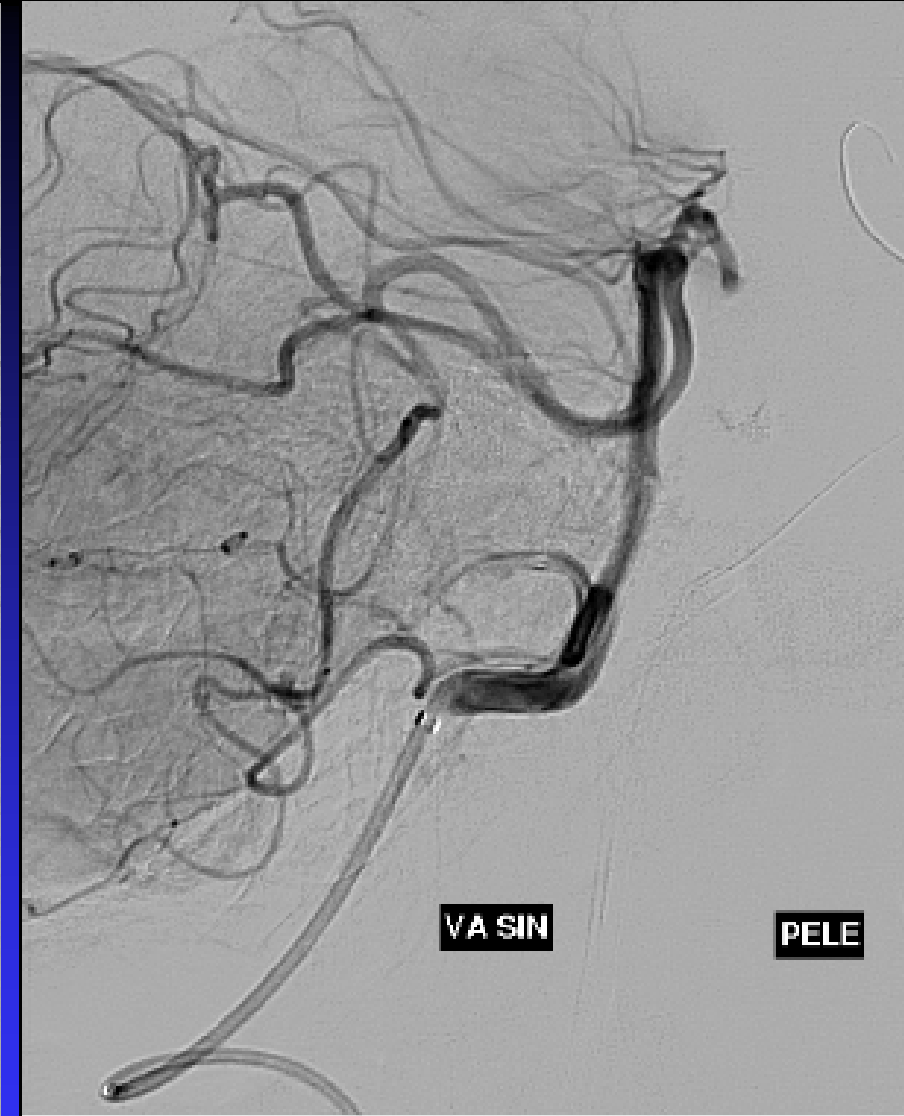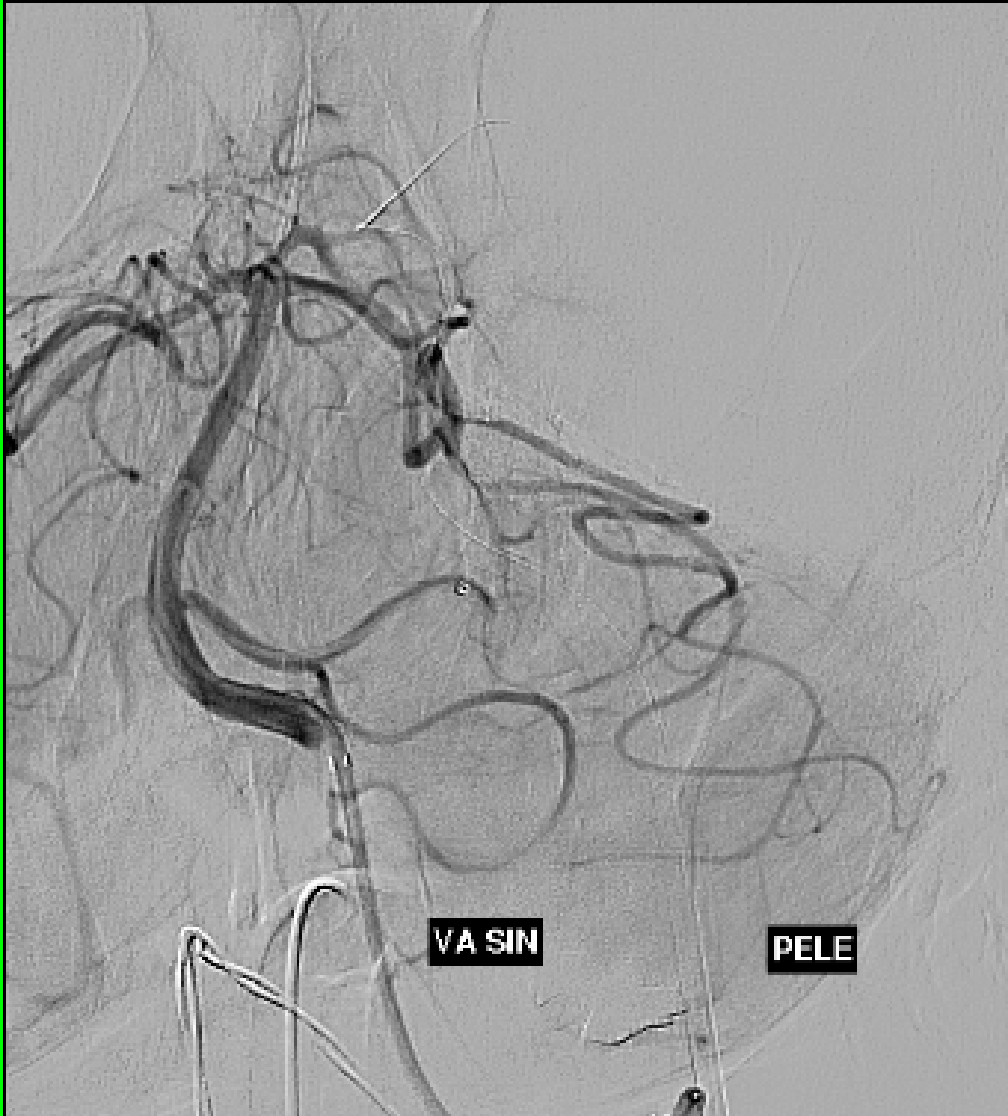
ICA SIN

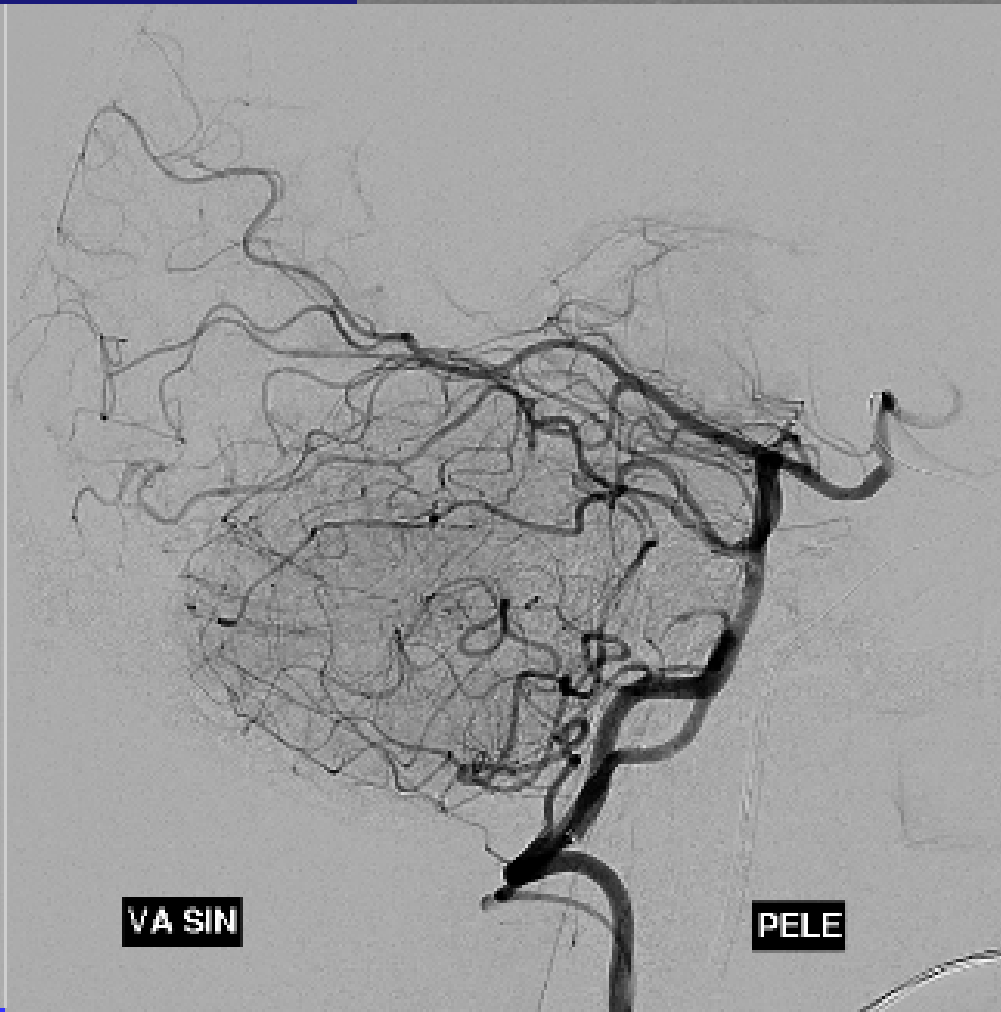
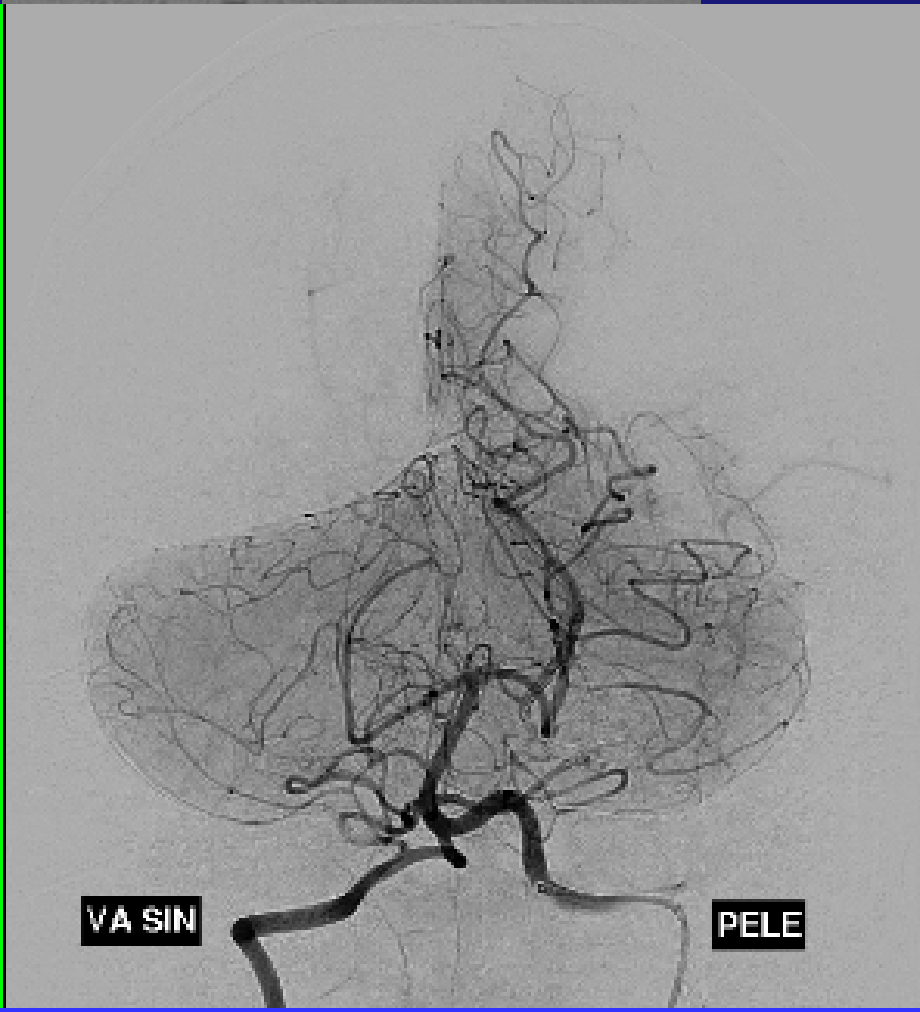
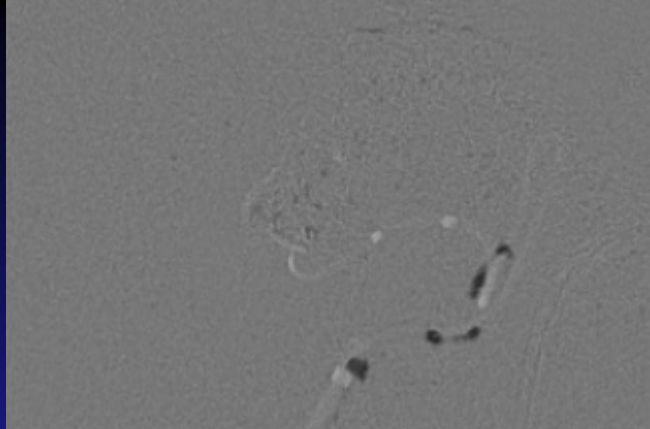
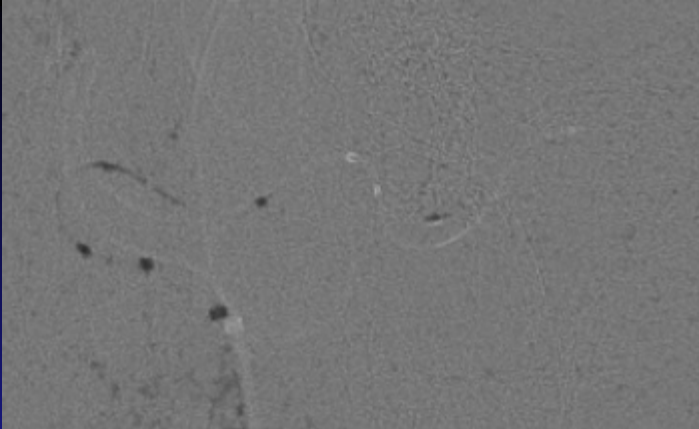
DEAD FISTULA



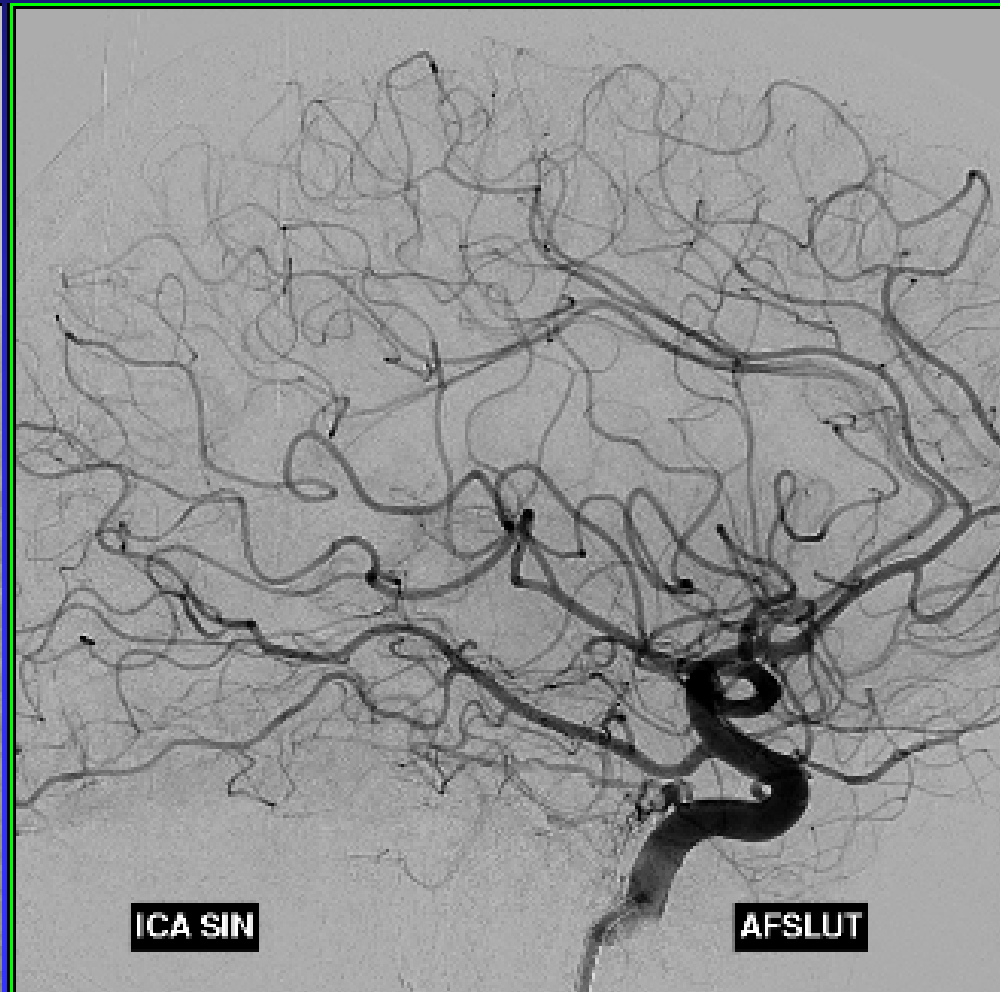
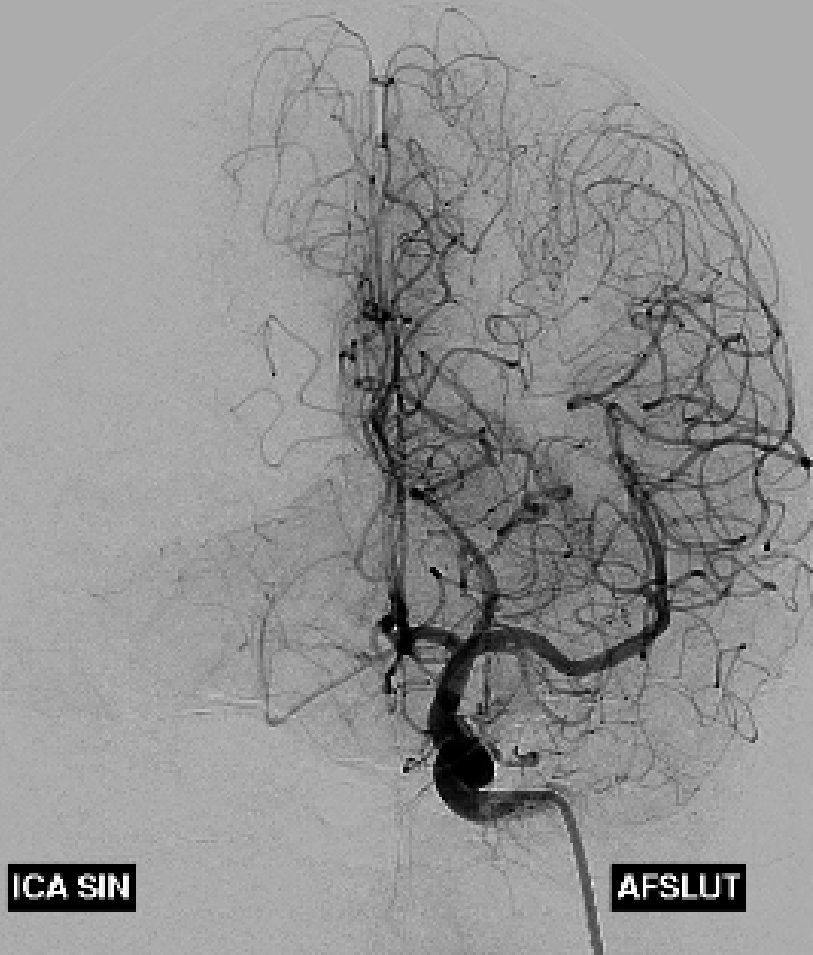ICA SIN

DEAD FISTULA





Final angiogram



Follow up at 5 m

SUBTRACTION;FRAME_SELECTION

SUBTRACTION;FRAME_SELECTION

