

Balloon Applications in Intracranial Endovascular Embolization



Guilherme Dabus MD
Director, Fellowship
NeuroInterventional Surgery
Miami Cardiac & Vascular Institute
Baptist Neuroscience Center



Herbert Wertheim
College of Medicine



Baptist Neuroscience Center
BAPTIST HEALTH SOUTH FLORIDA



Miami Cardiac & Vascular Institute
BAPTIST HOSPITAL OF MIAMI

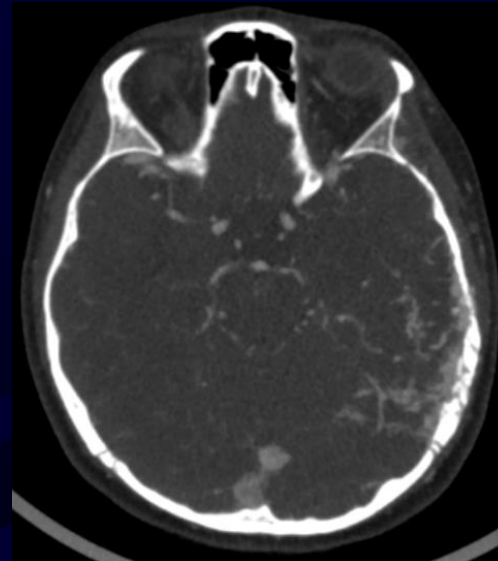
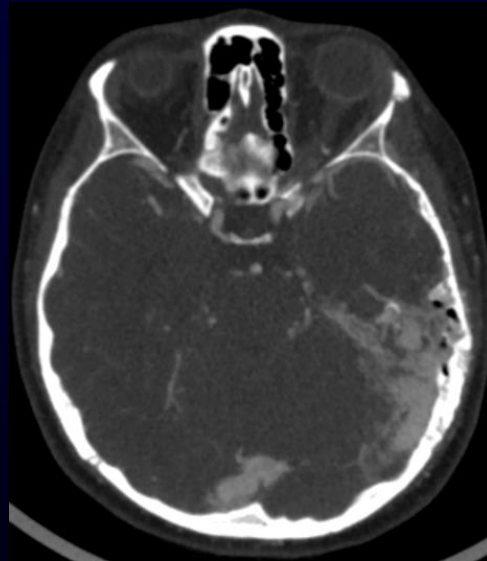
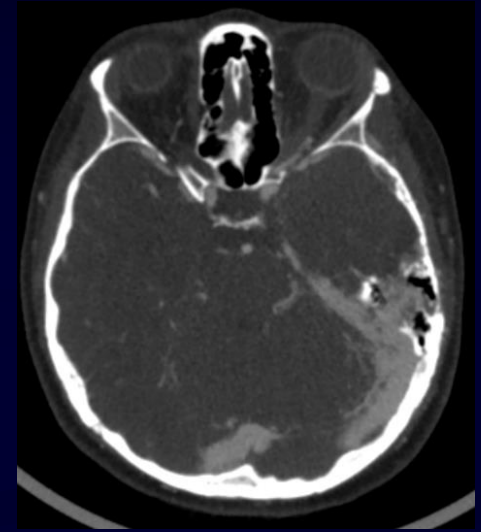
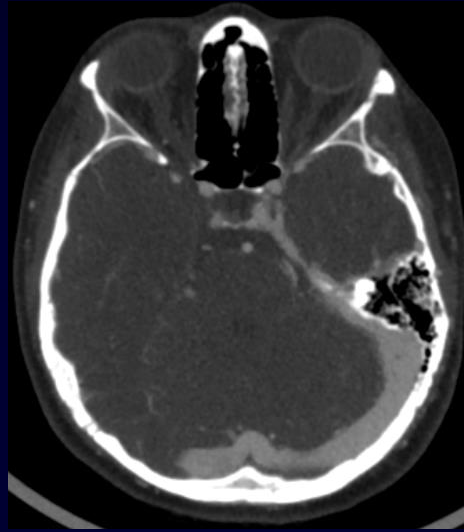
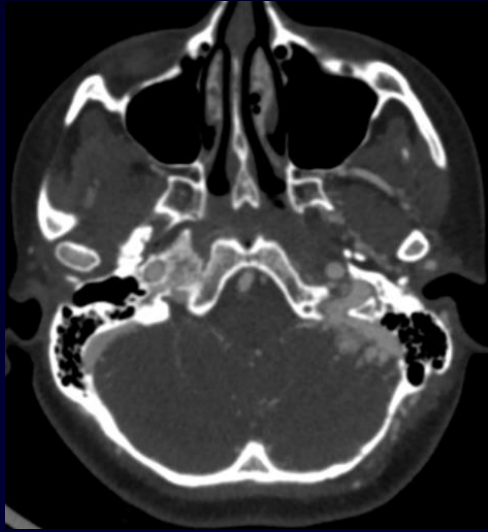
Dural AVF: treatment strategies

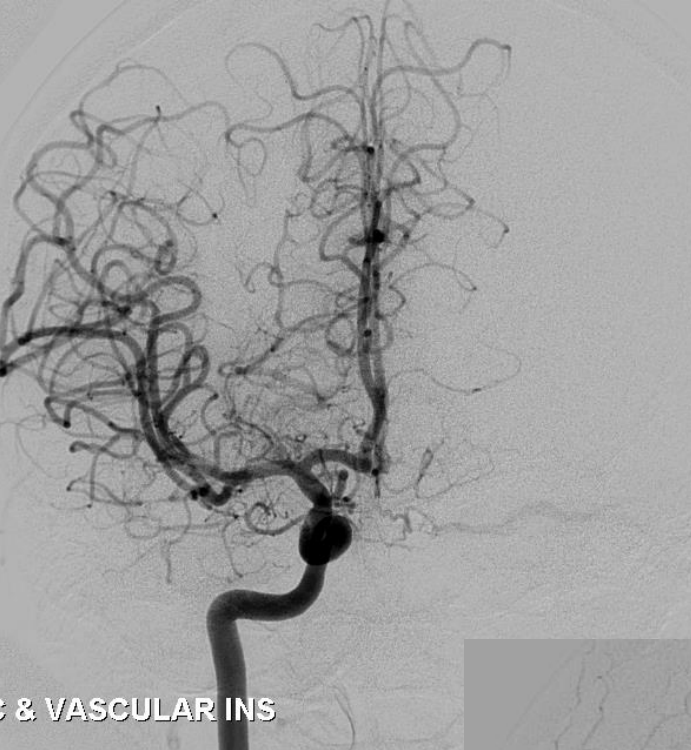
- Dual lumen balloon-assisted Onyx injection
 - balloon inflated - temporary plug
 - “pressure technique”
 - more controllable injection and reflux
 - better penetration of embolic agent
 - faster injections - decrease radiation exposure
 - lower risk of microcatheter retention

Dabus G, et al. Clin Neurol Neurosurg 2014

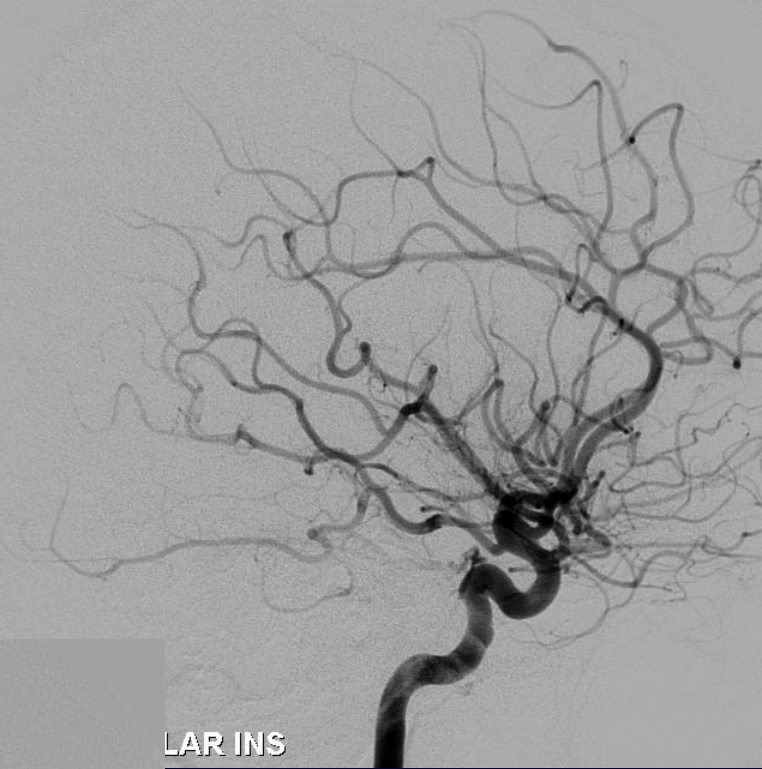

**23 F left sided pulsatile tinnitus
hx of trauma 6 months prior**

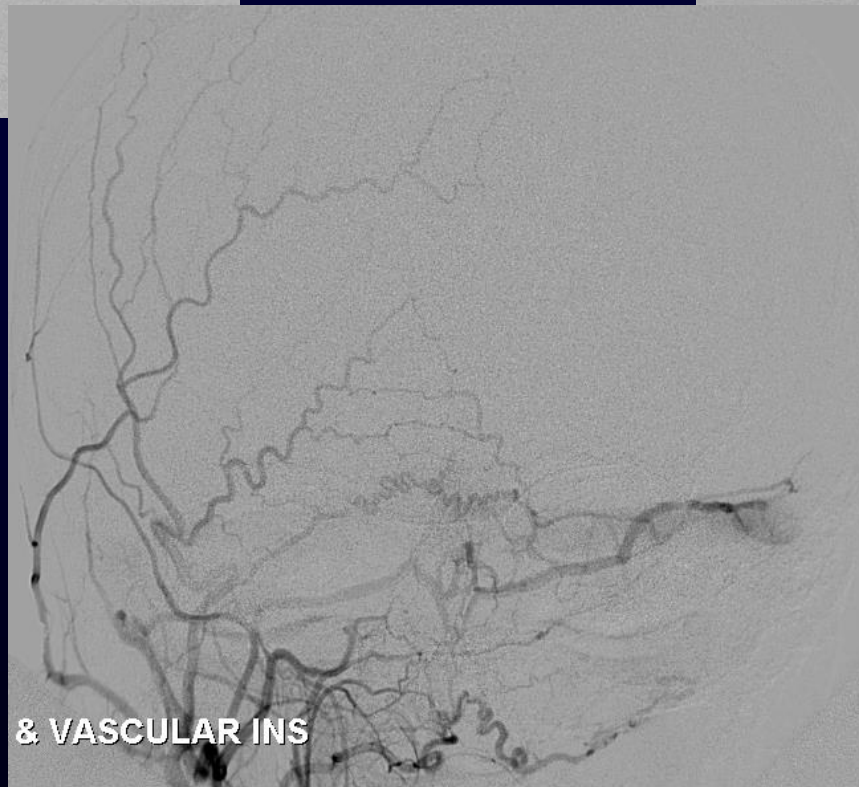




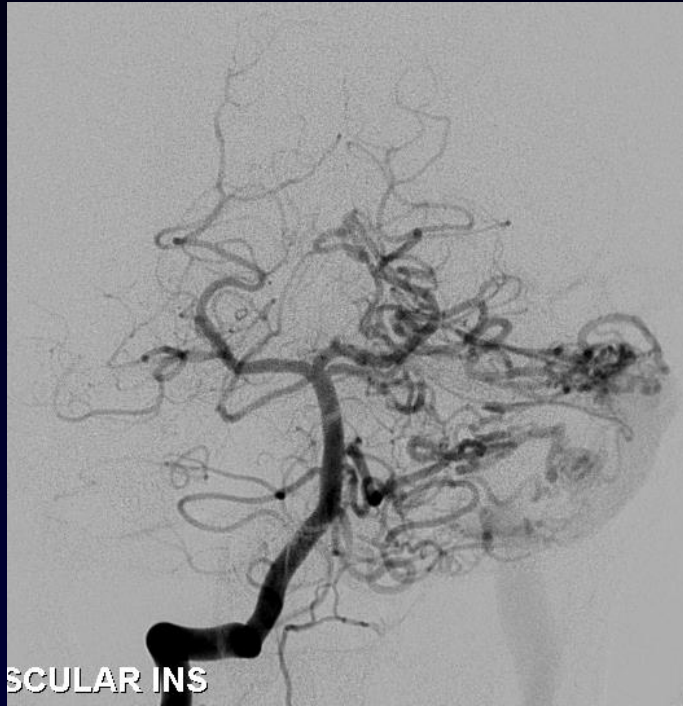
& VASCULAR INS



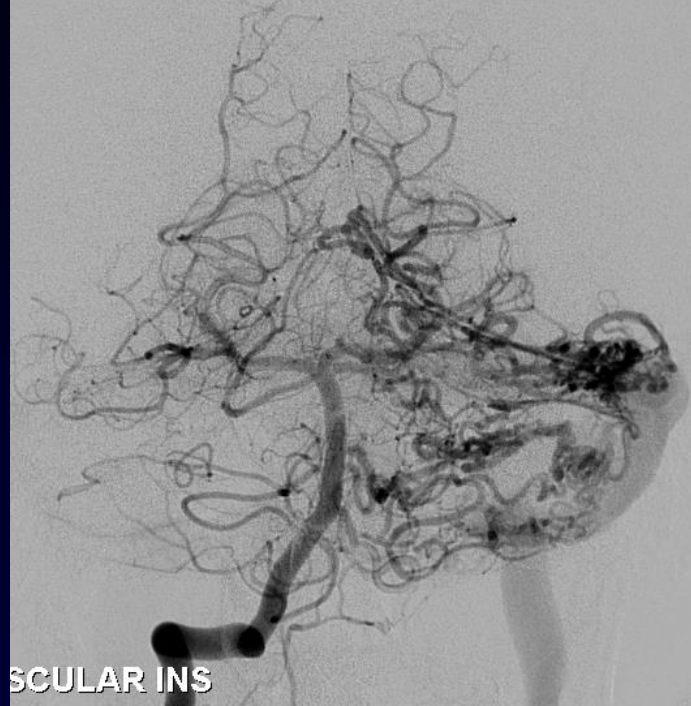
LAR INS



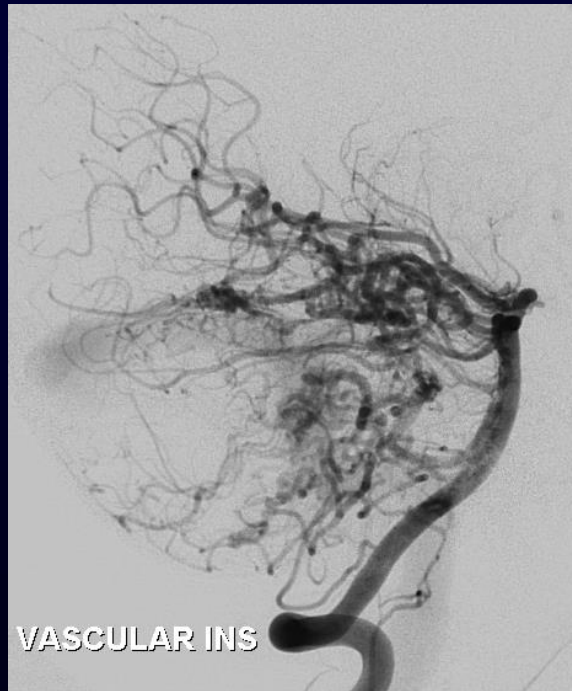
& VASCULAR INS



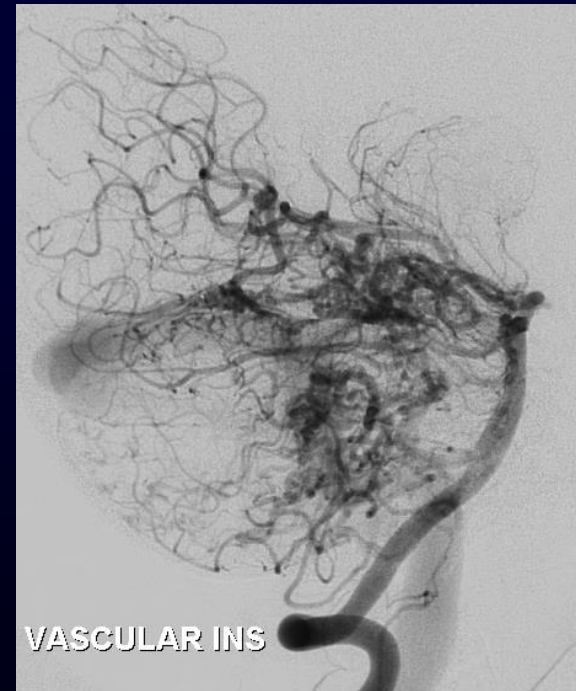
SCULAR INS



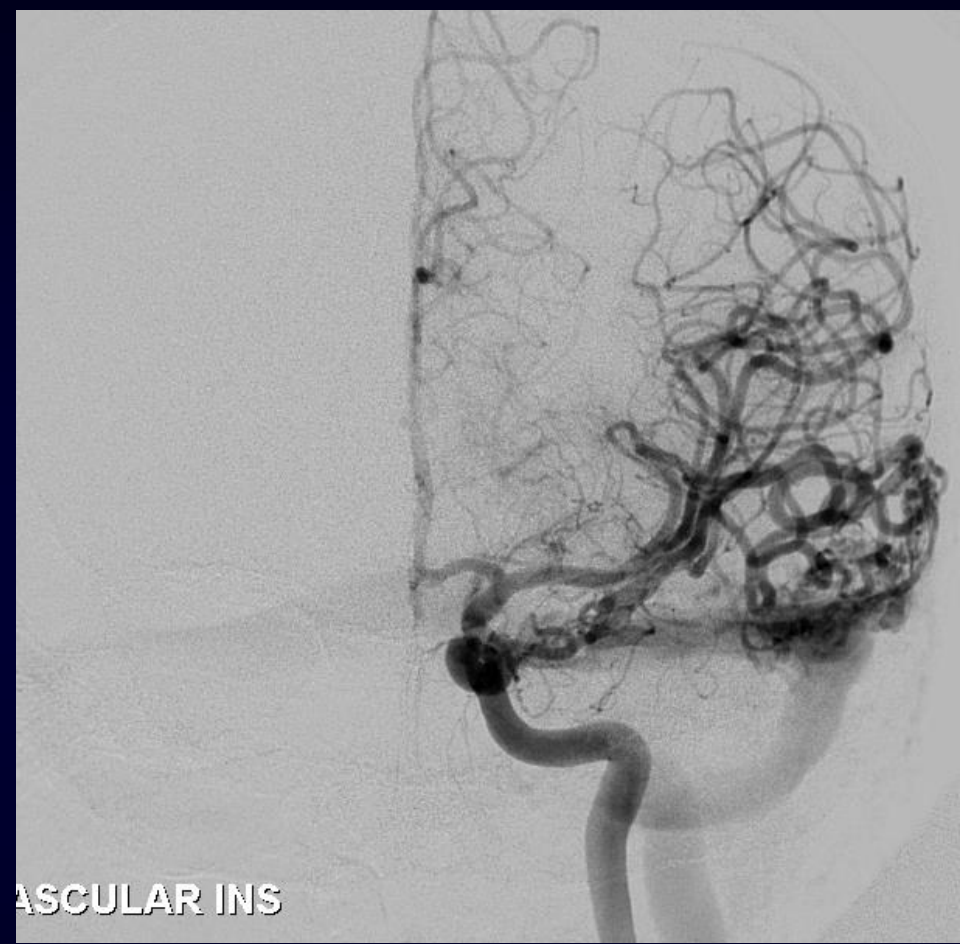SCULAR INS



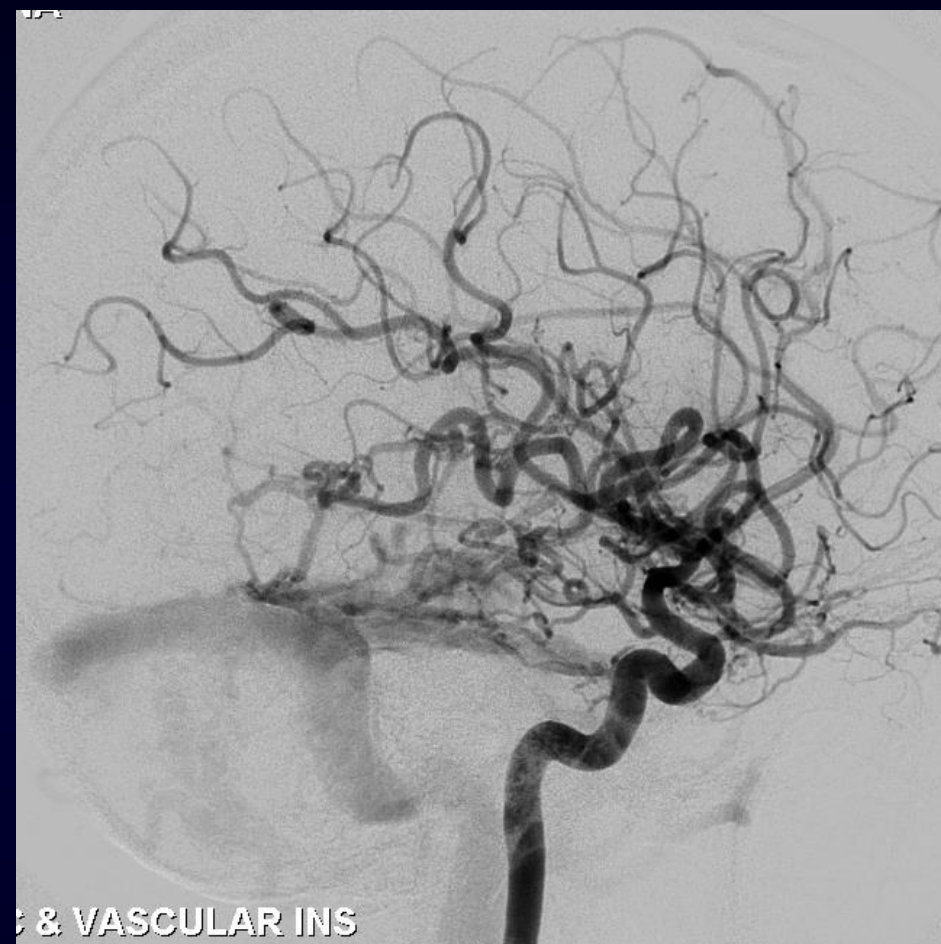VASCULAR INS



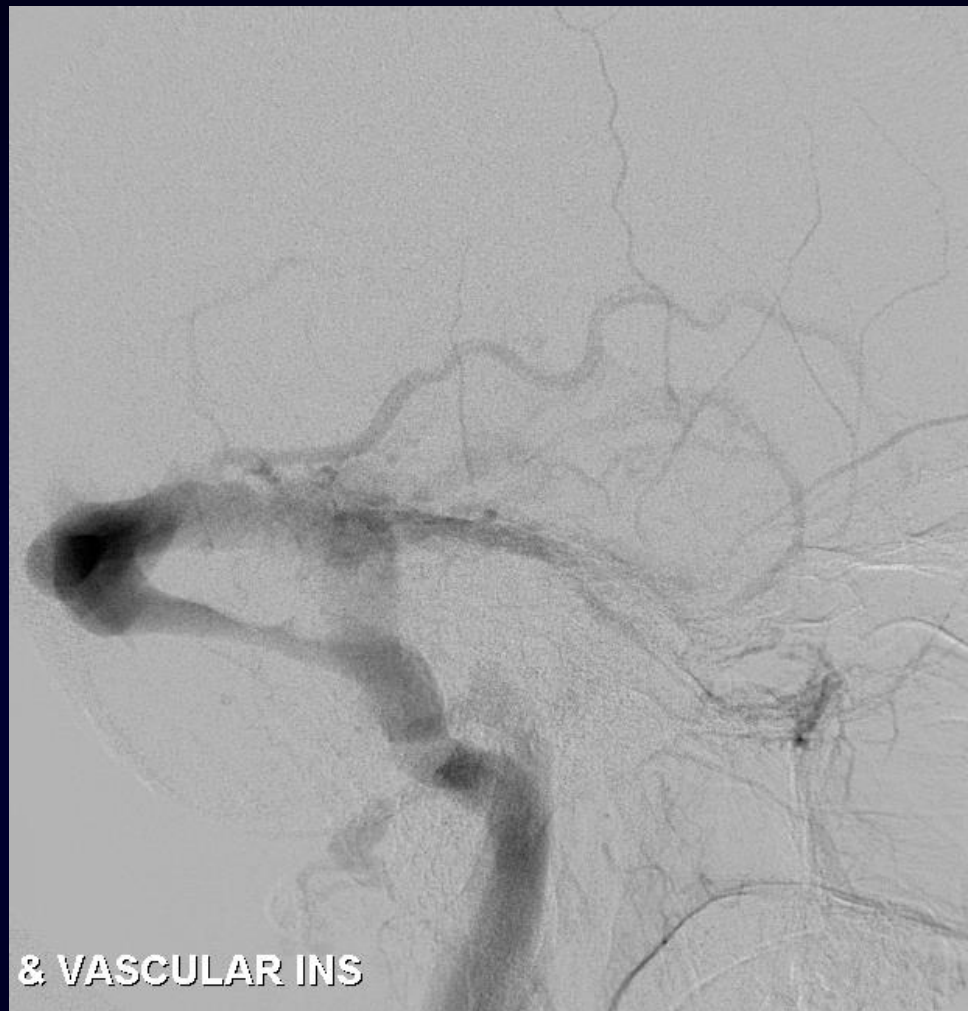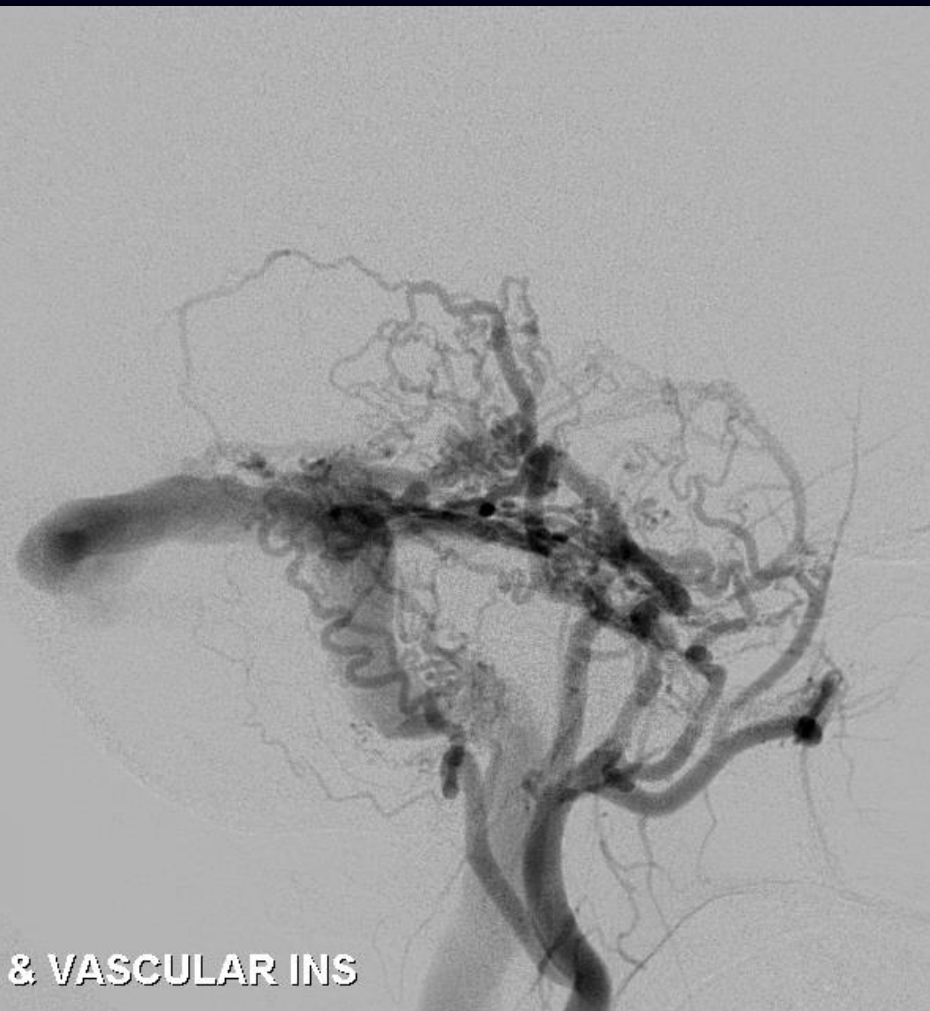VASCULAR INS



VASCULAR INS



& VASCULAR INS

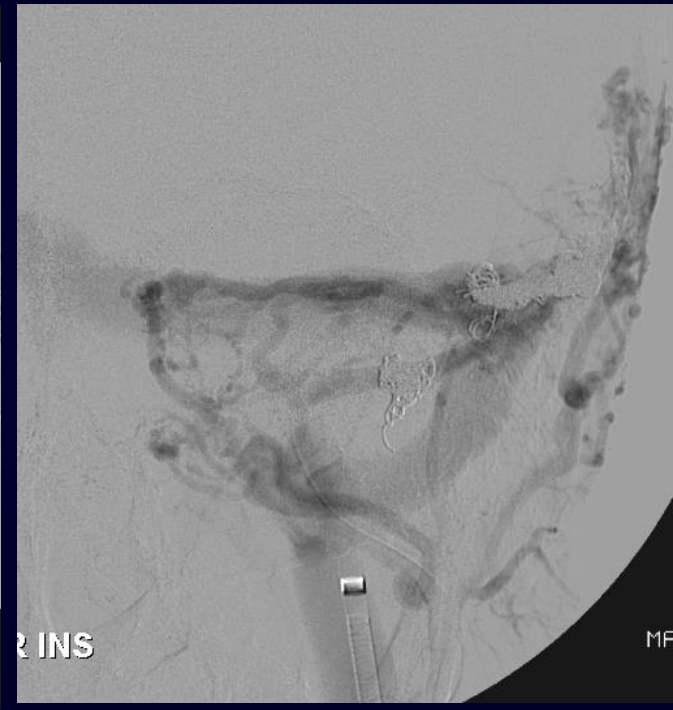
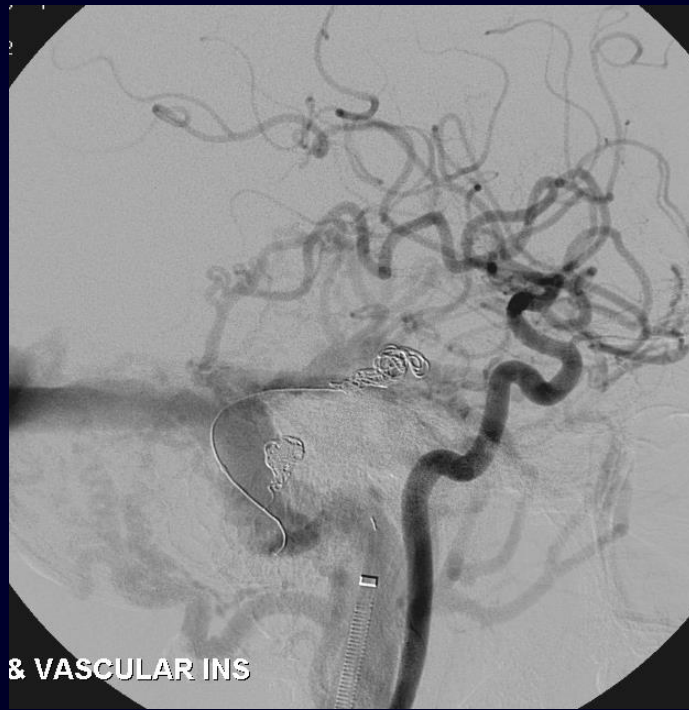
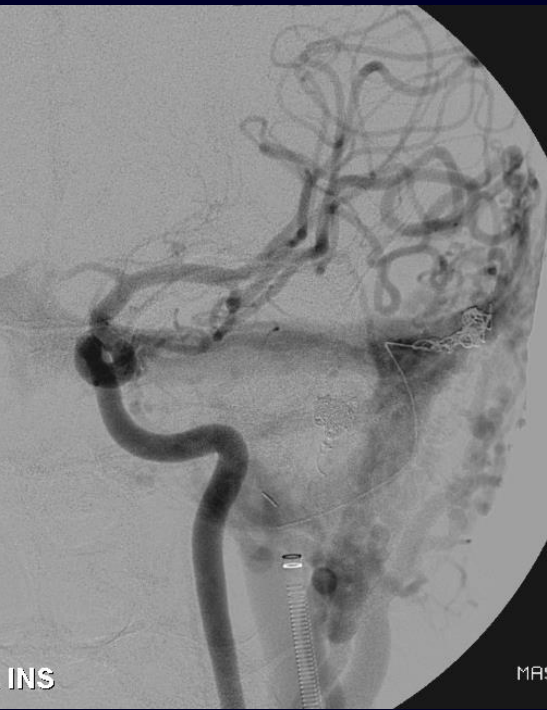




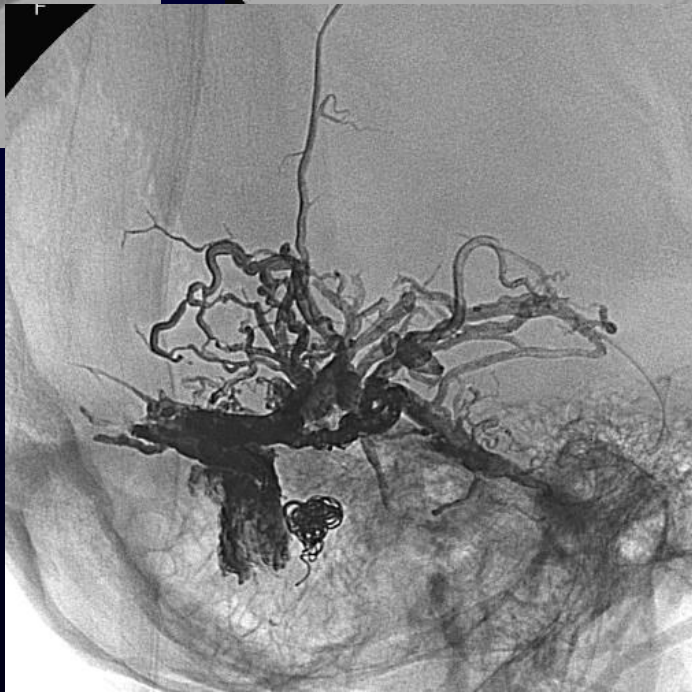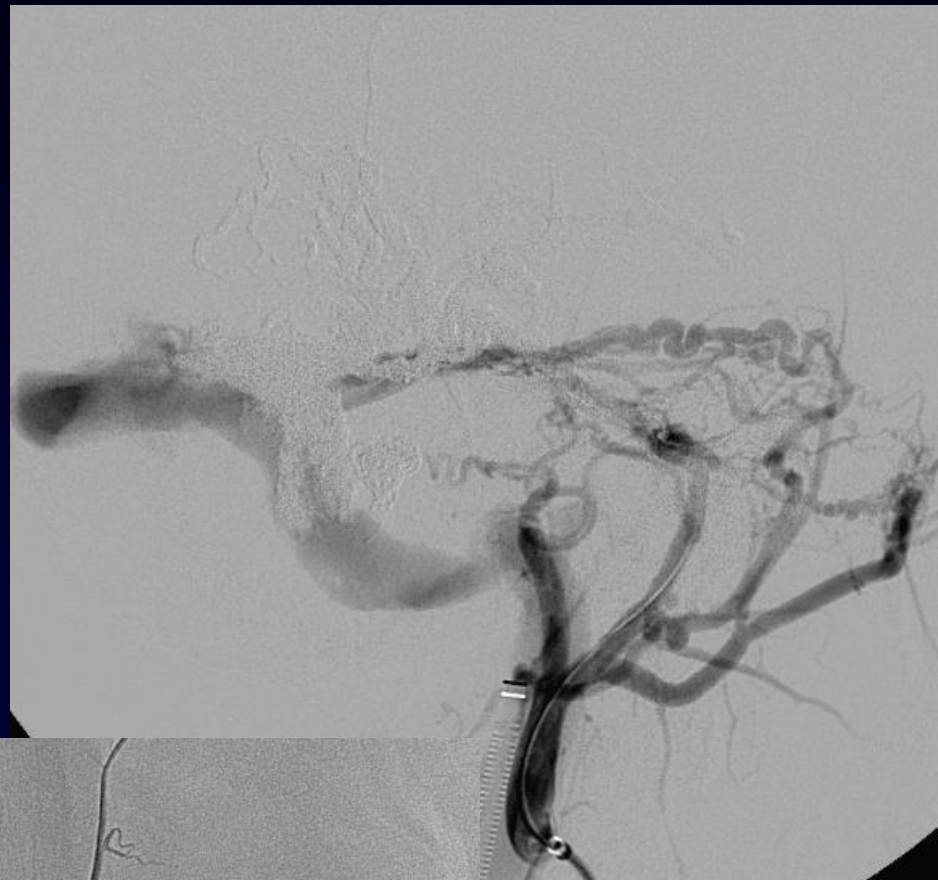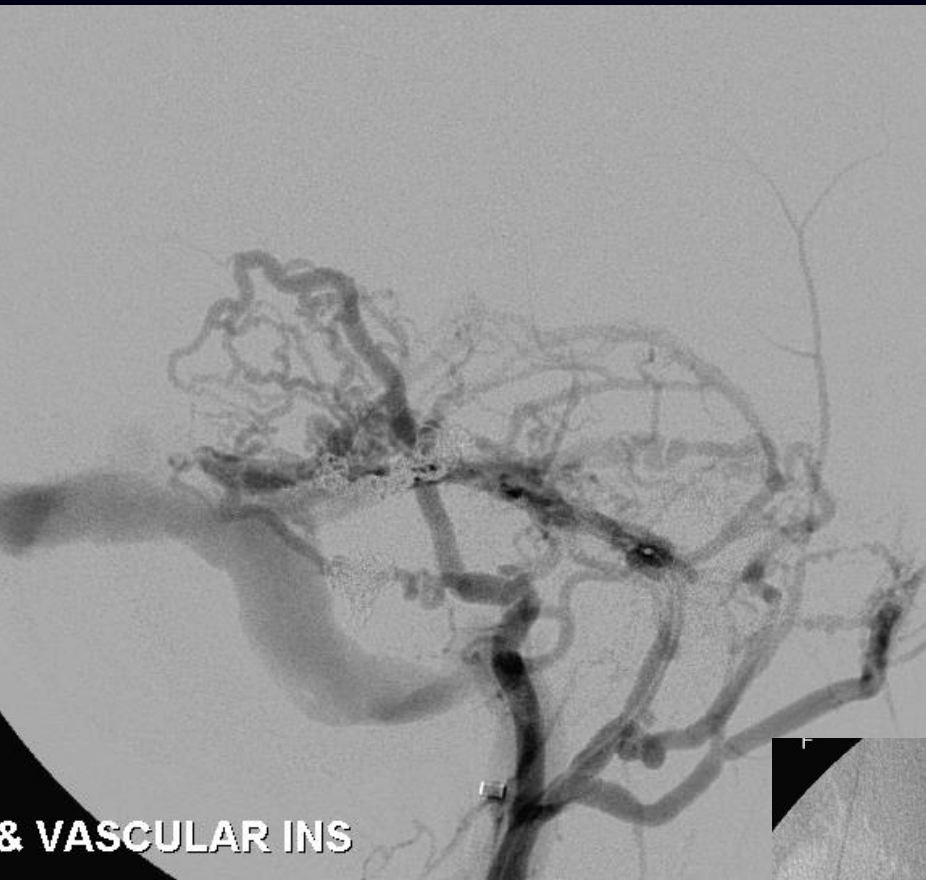R INS

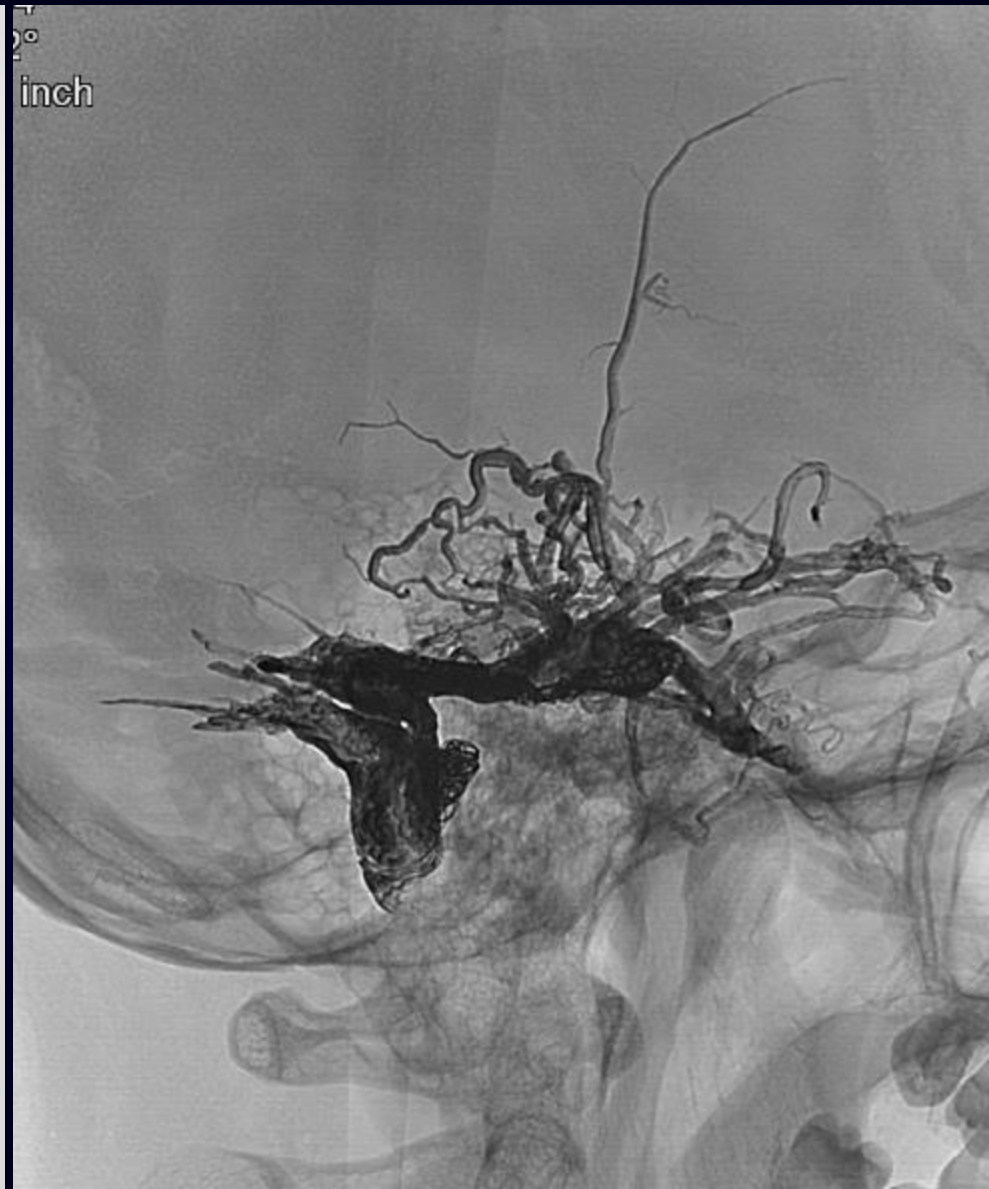
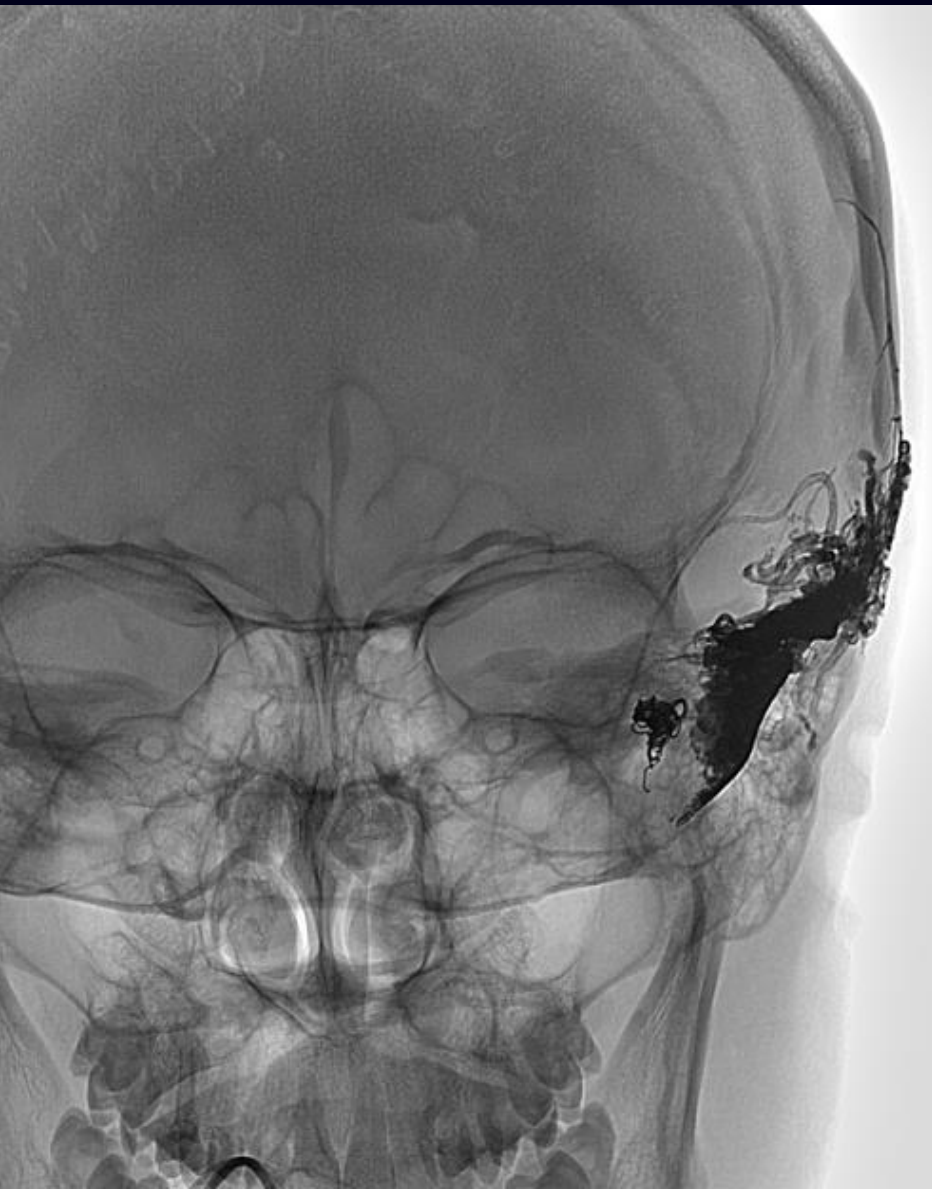


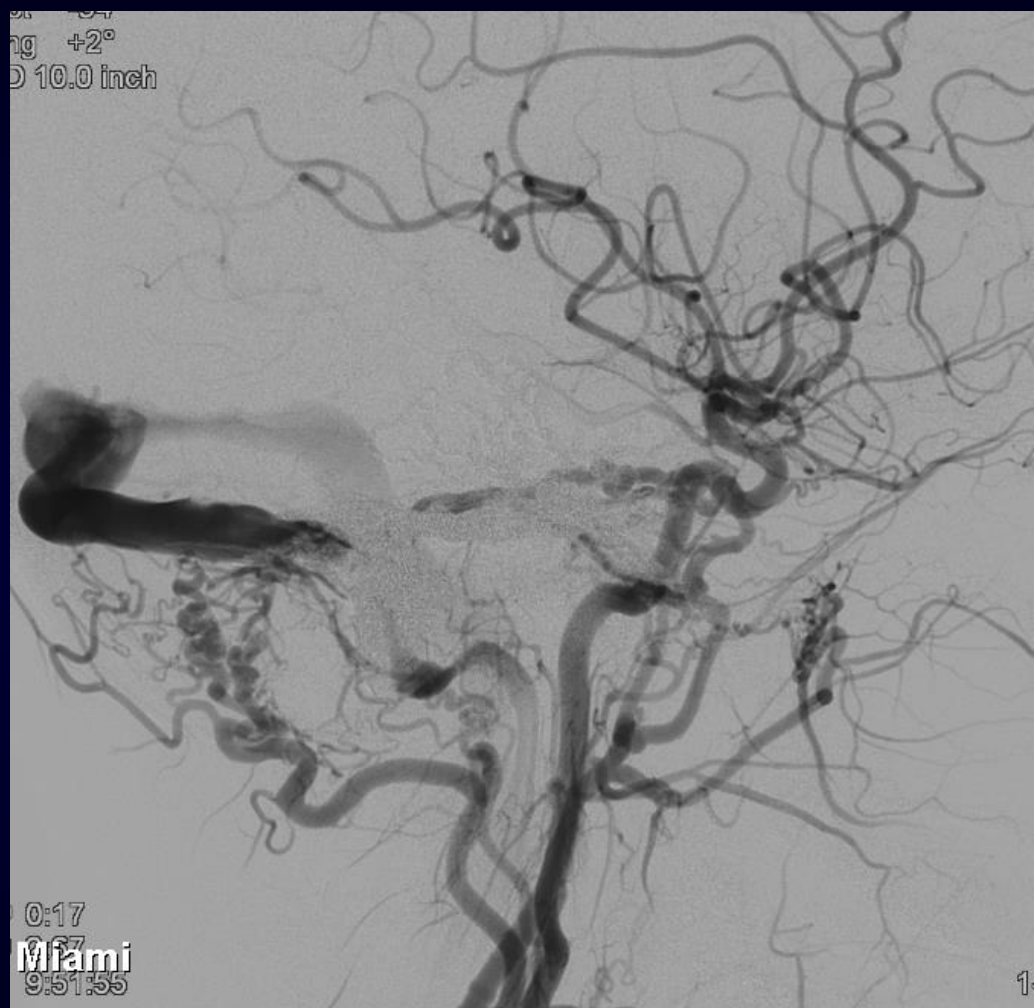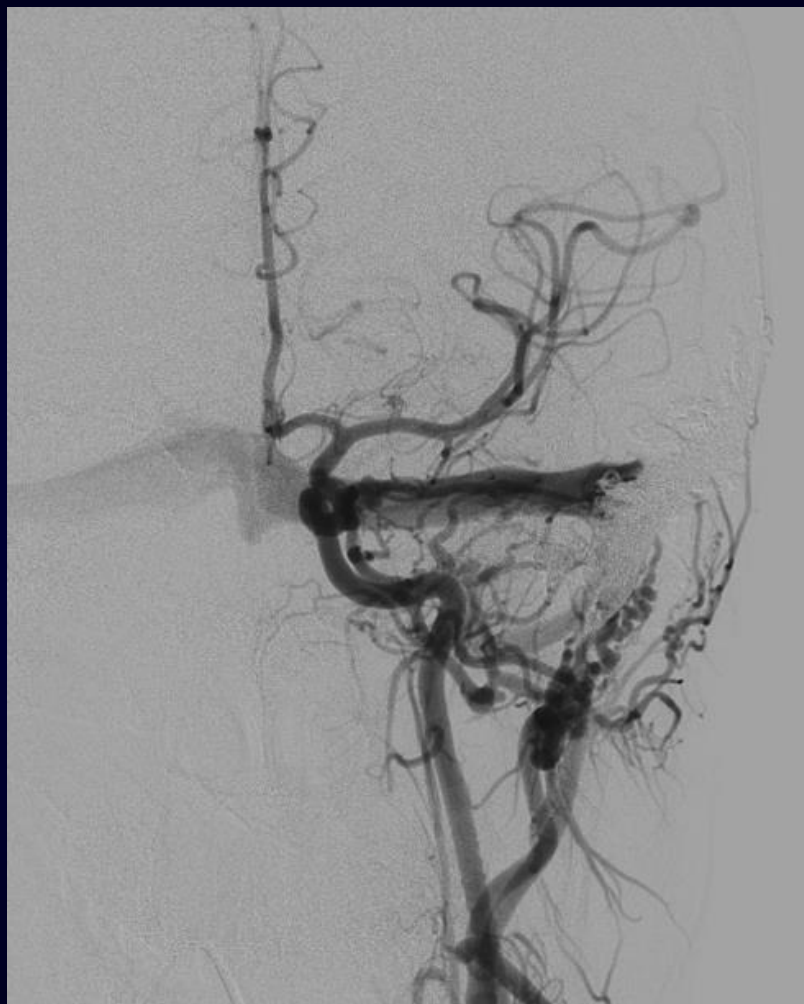& VASCULAR INS

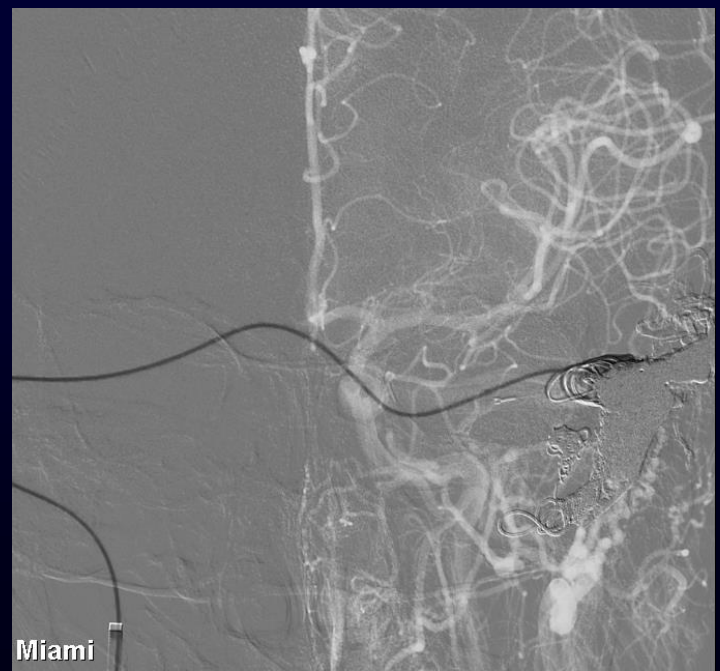
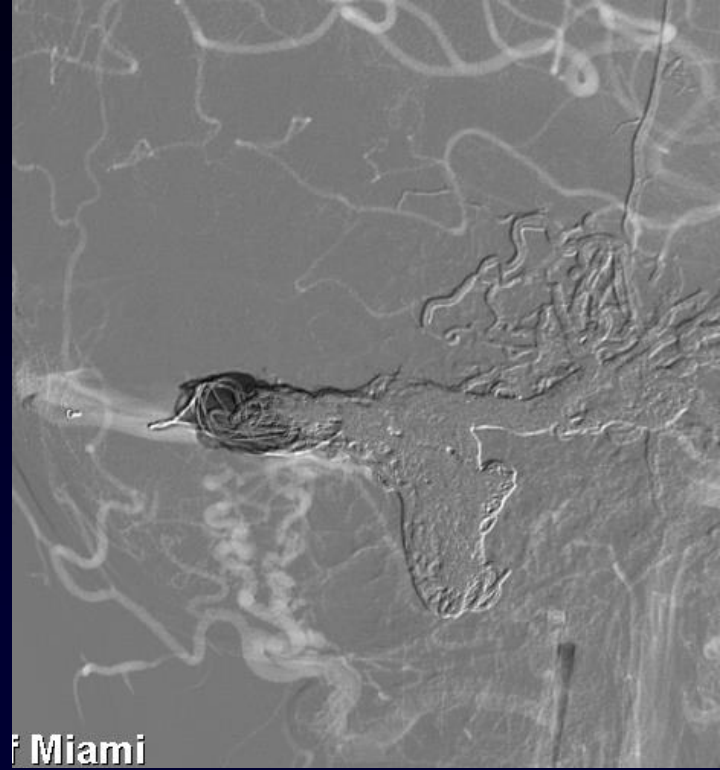
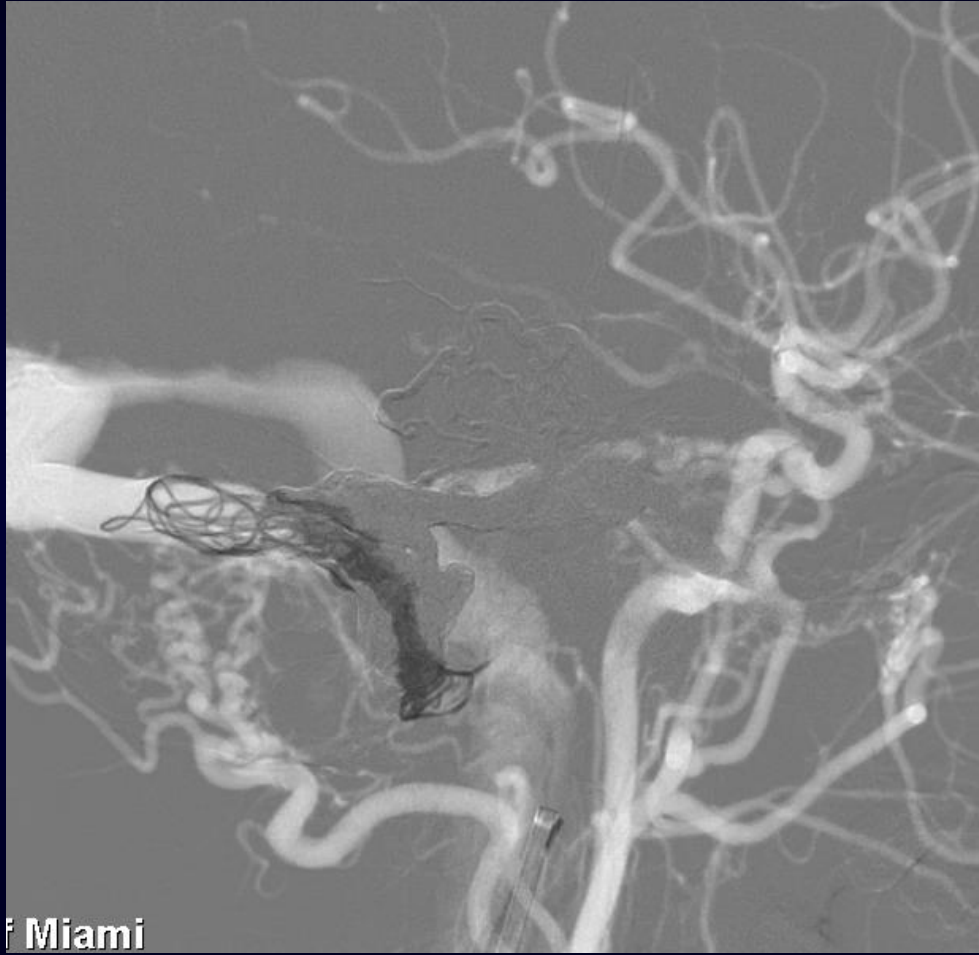


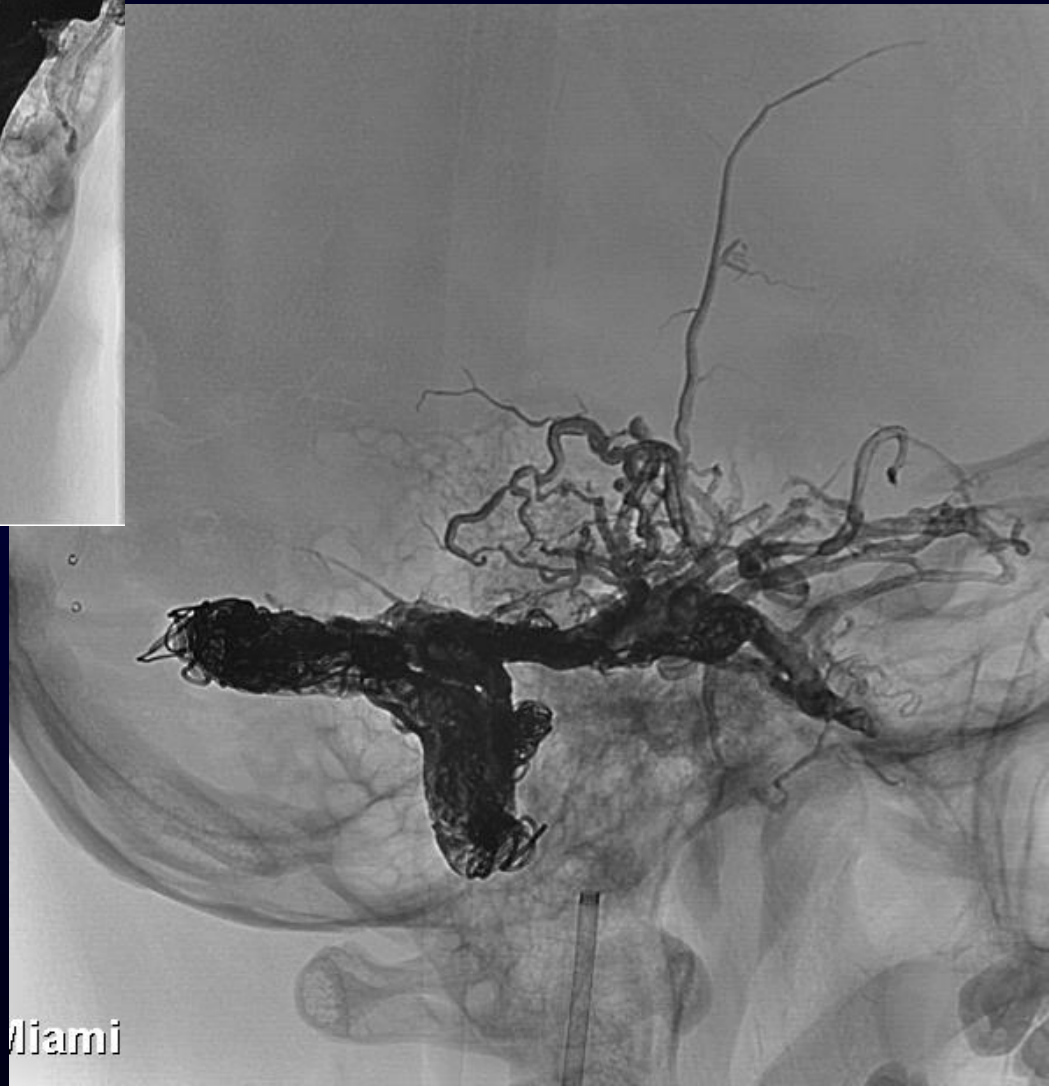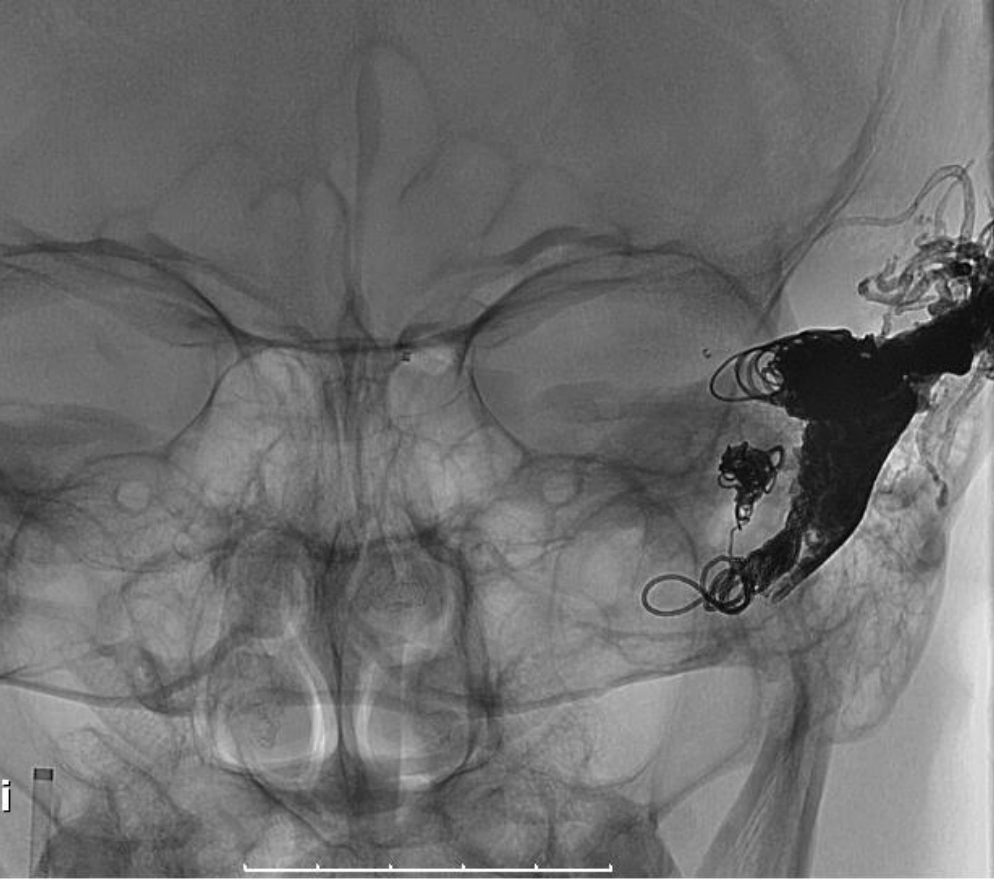& VASCULAR INS



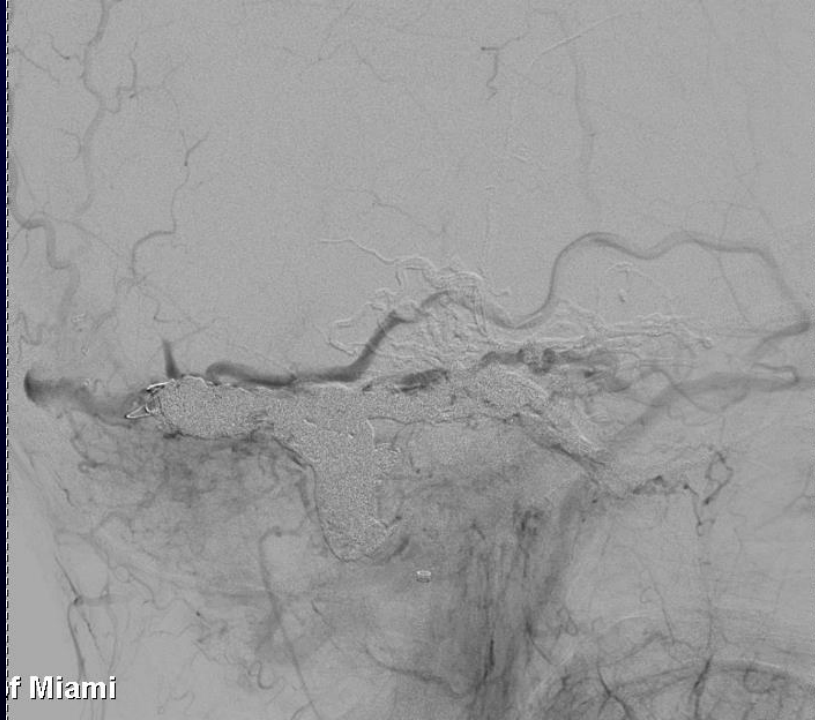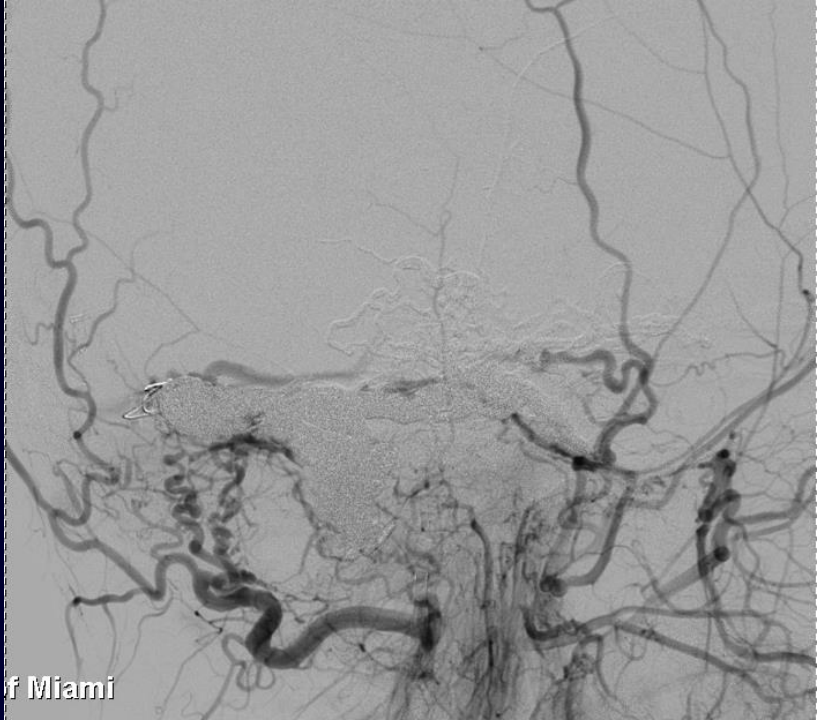
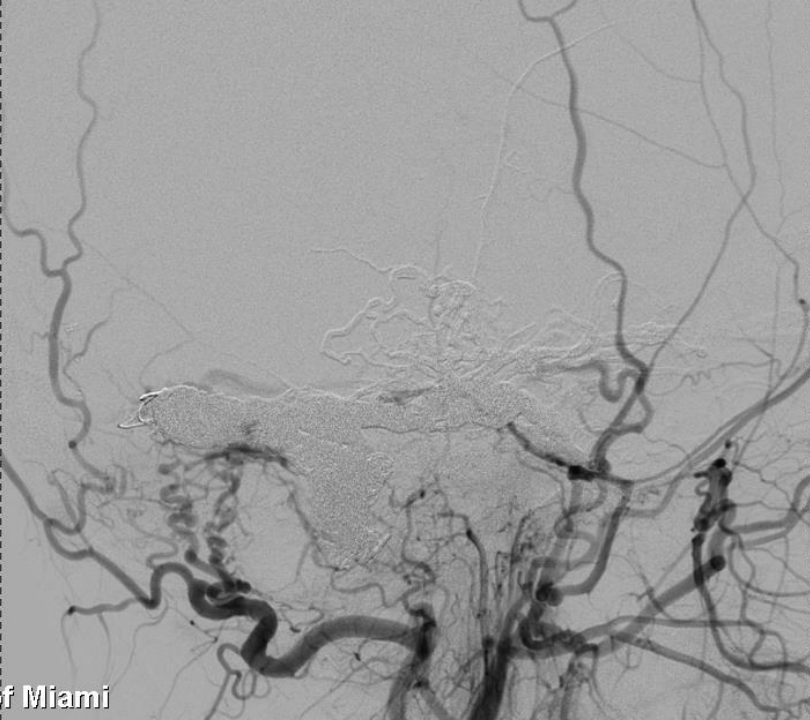




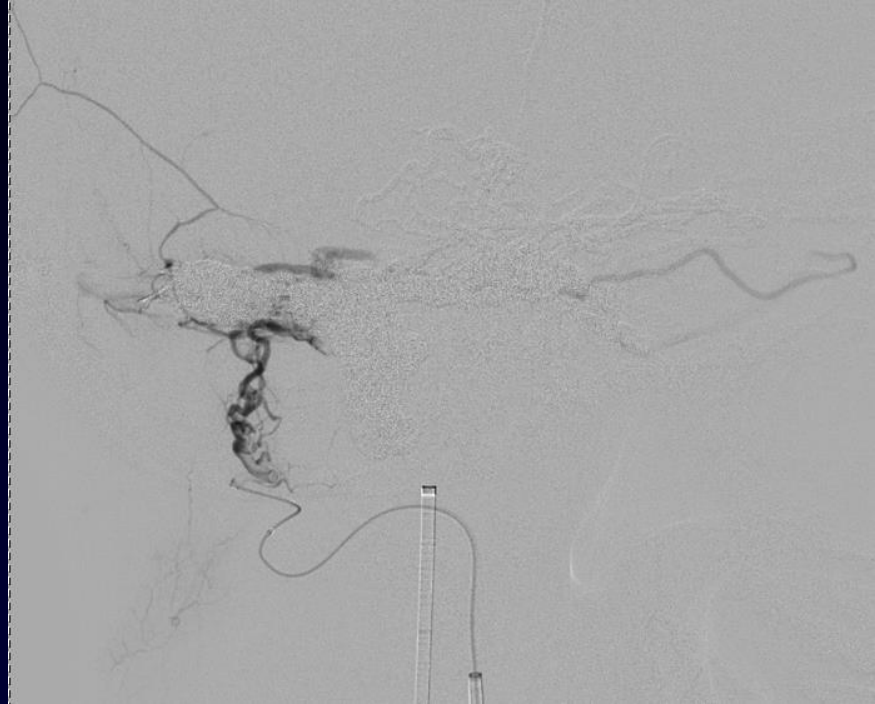

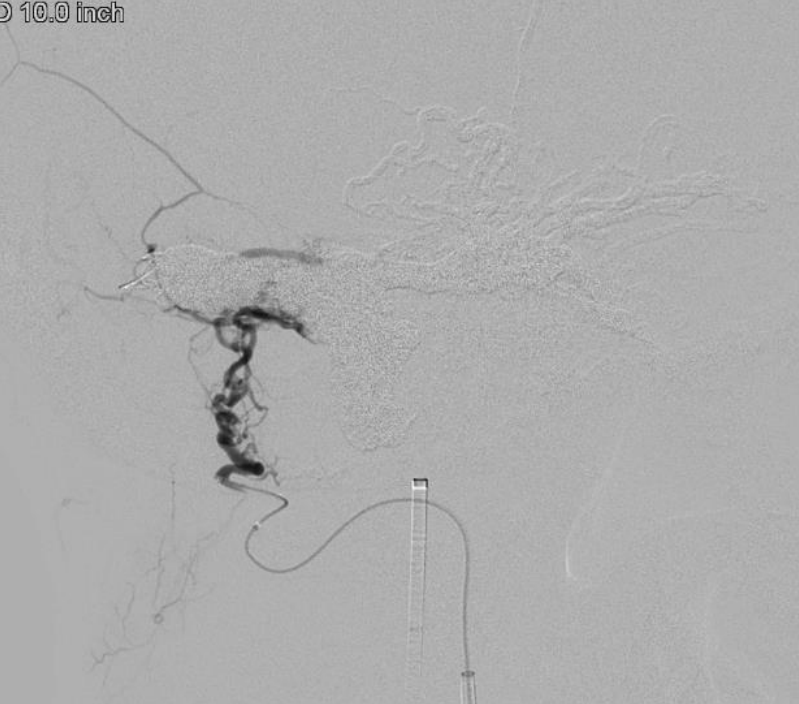


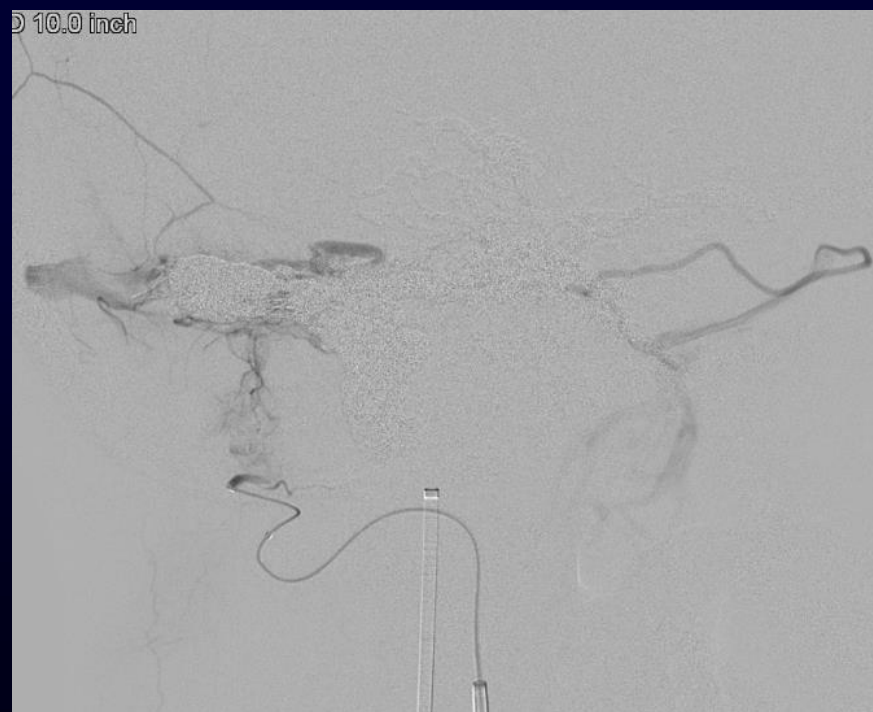Miami



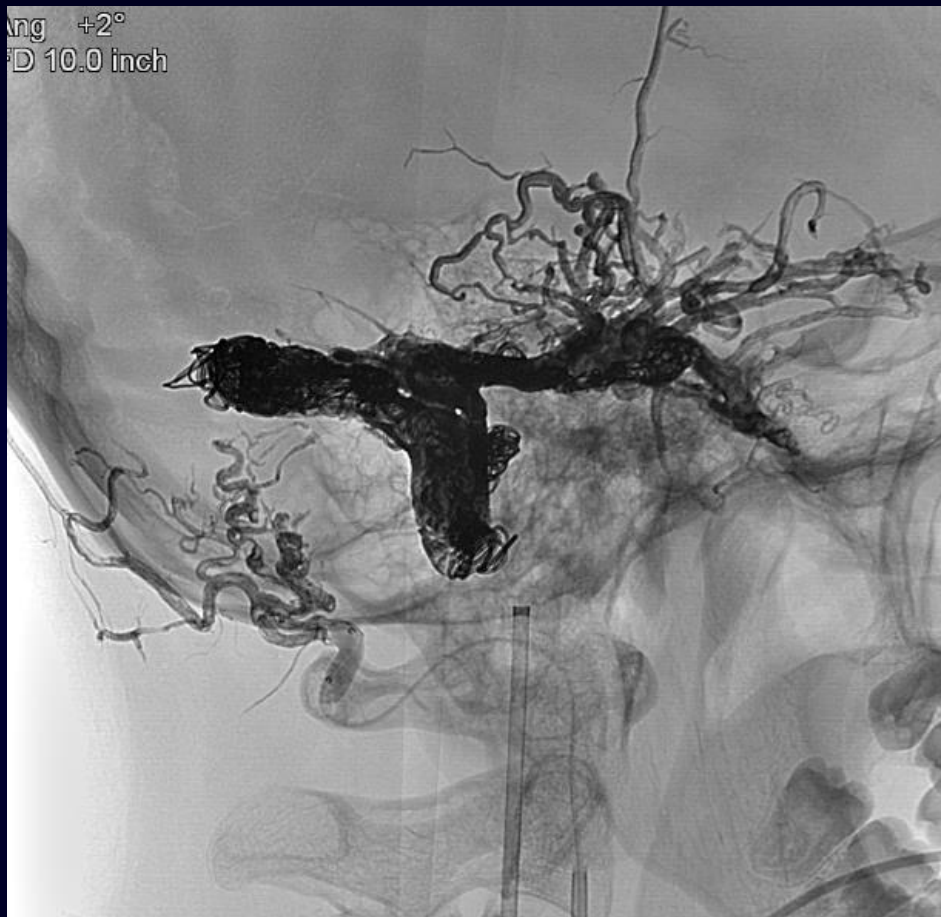D 10.0 inch



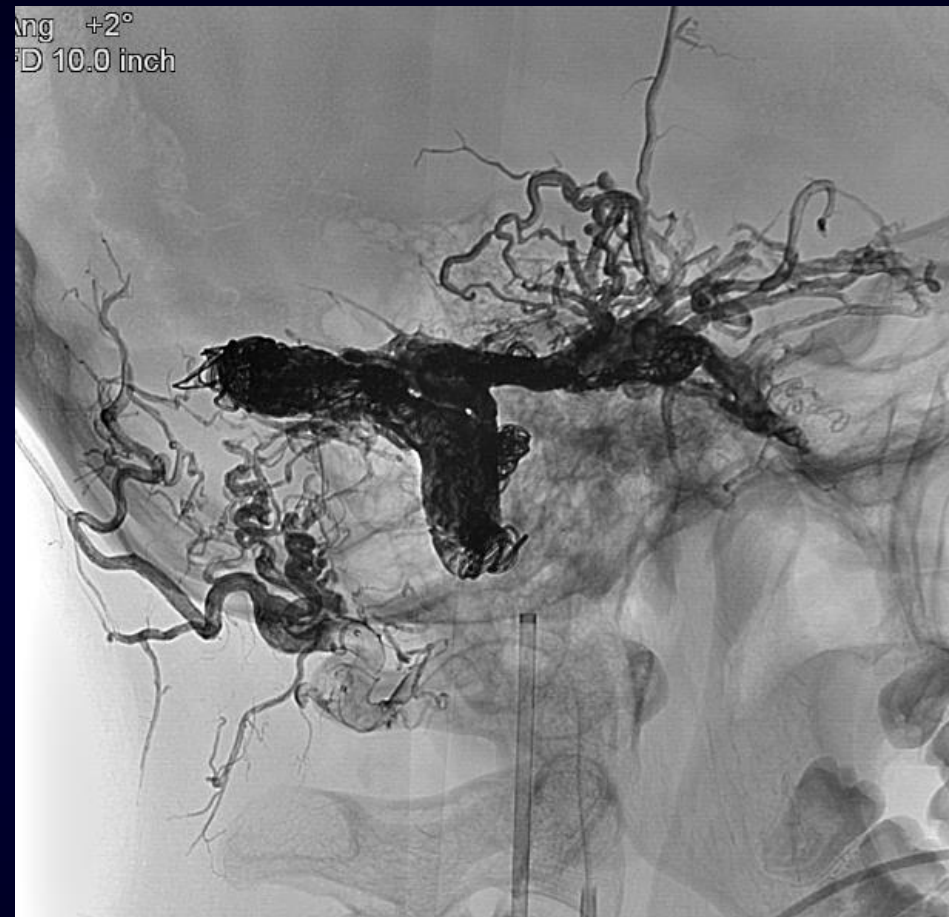D 10.0 inch

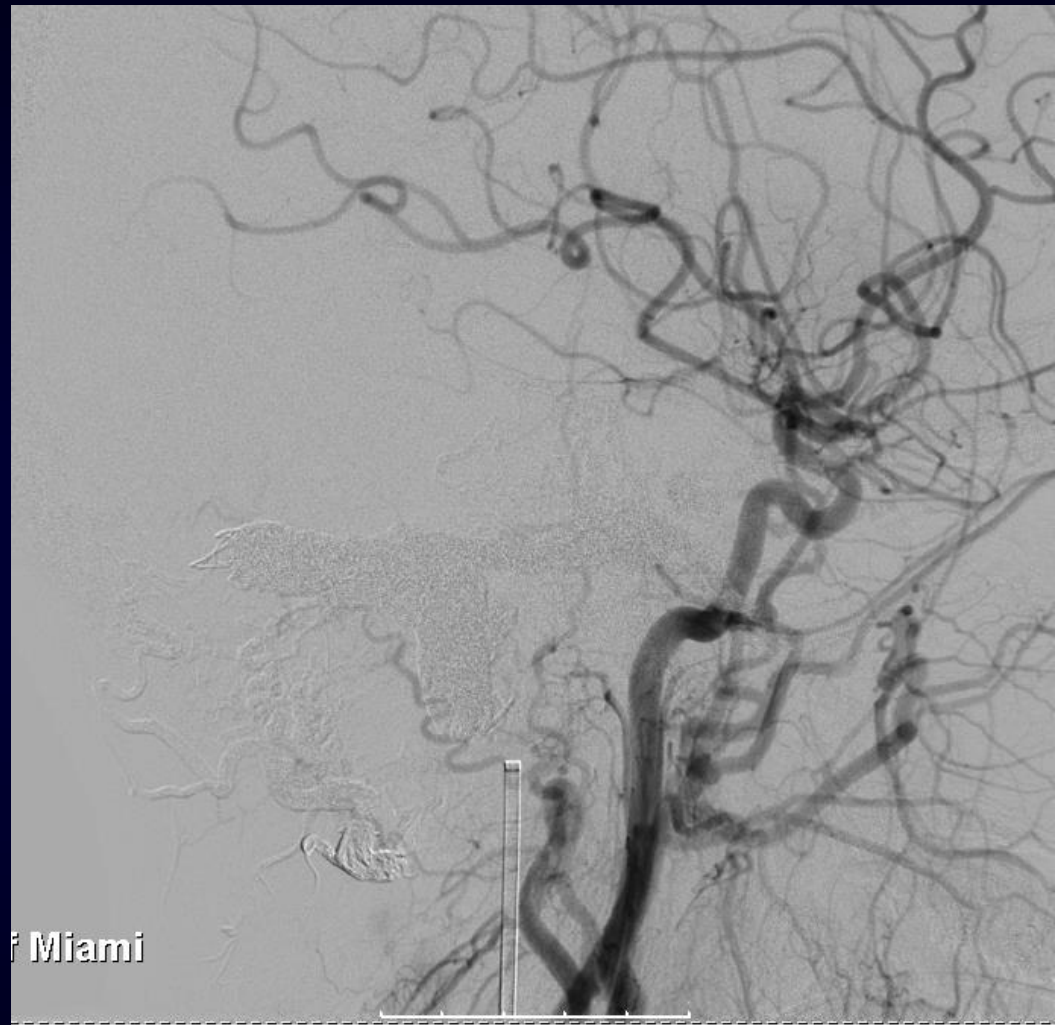
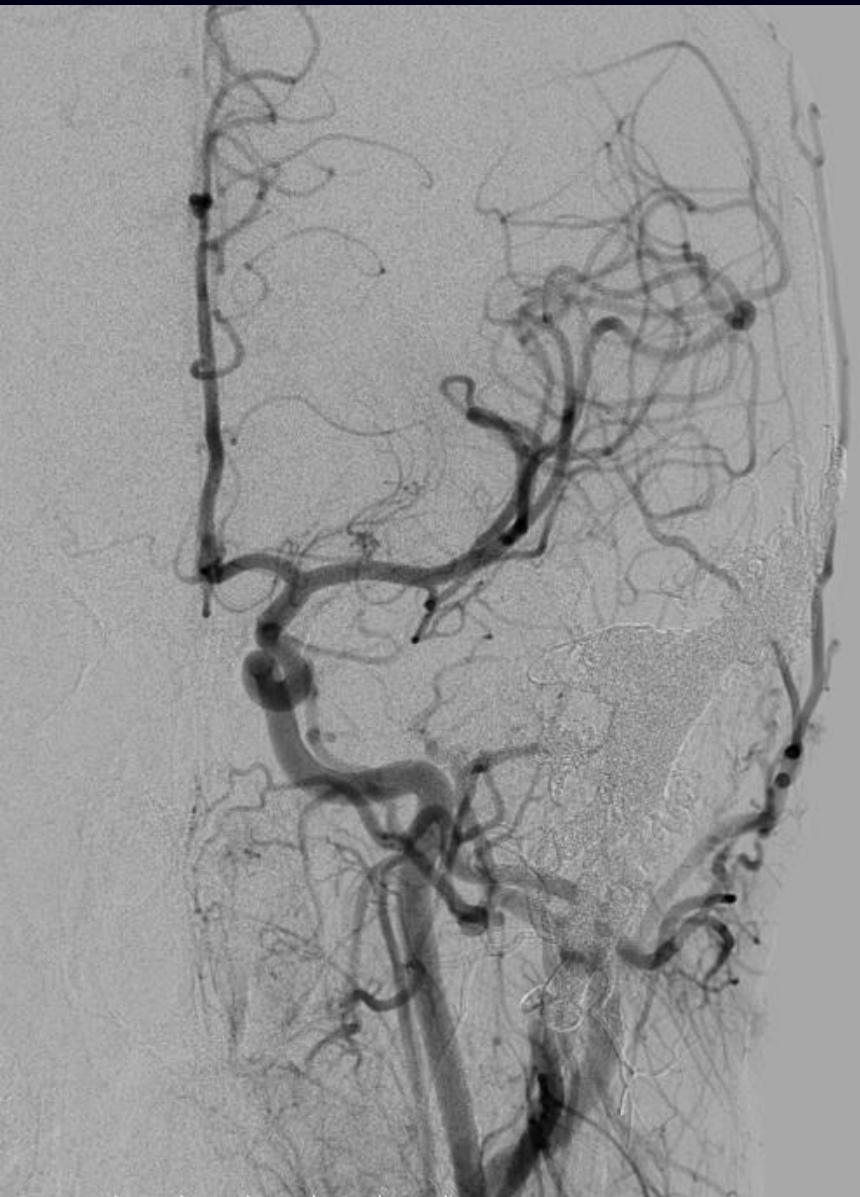

Ang +2°
FD 10.0 inch

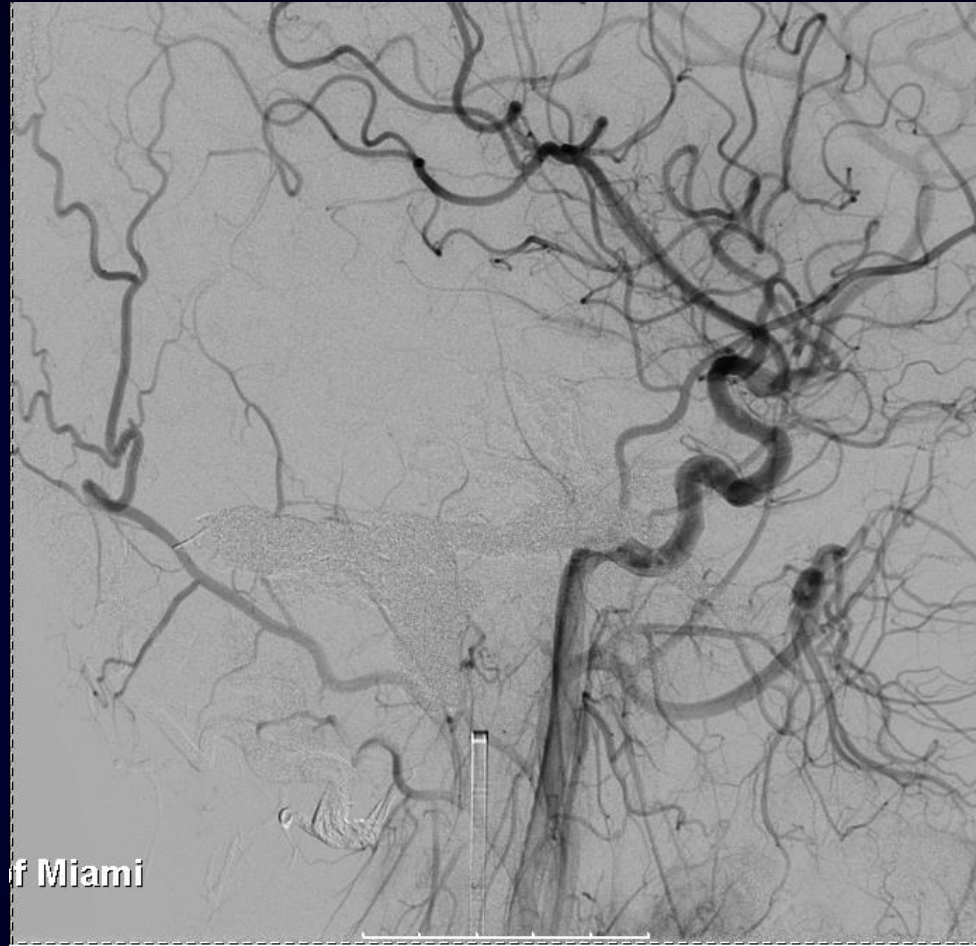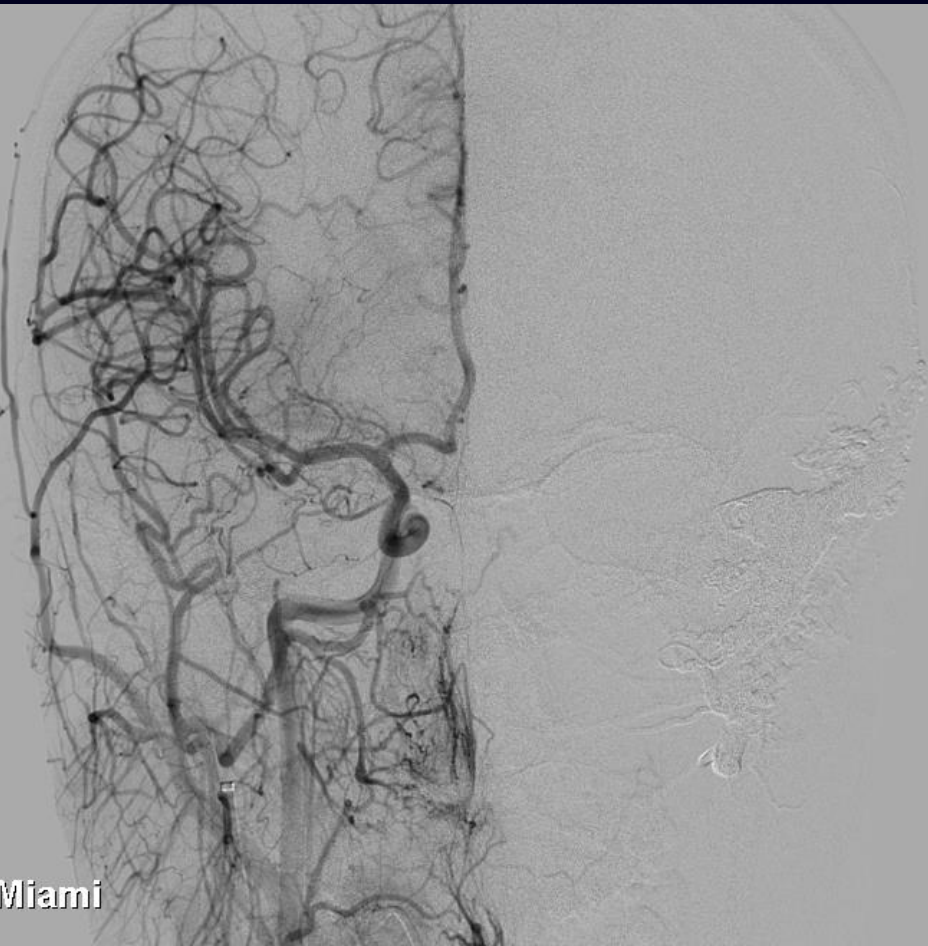


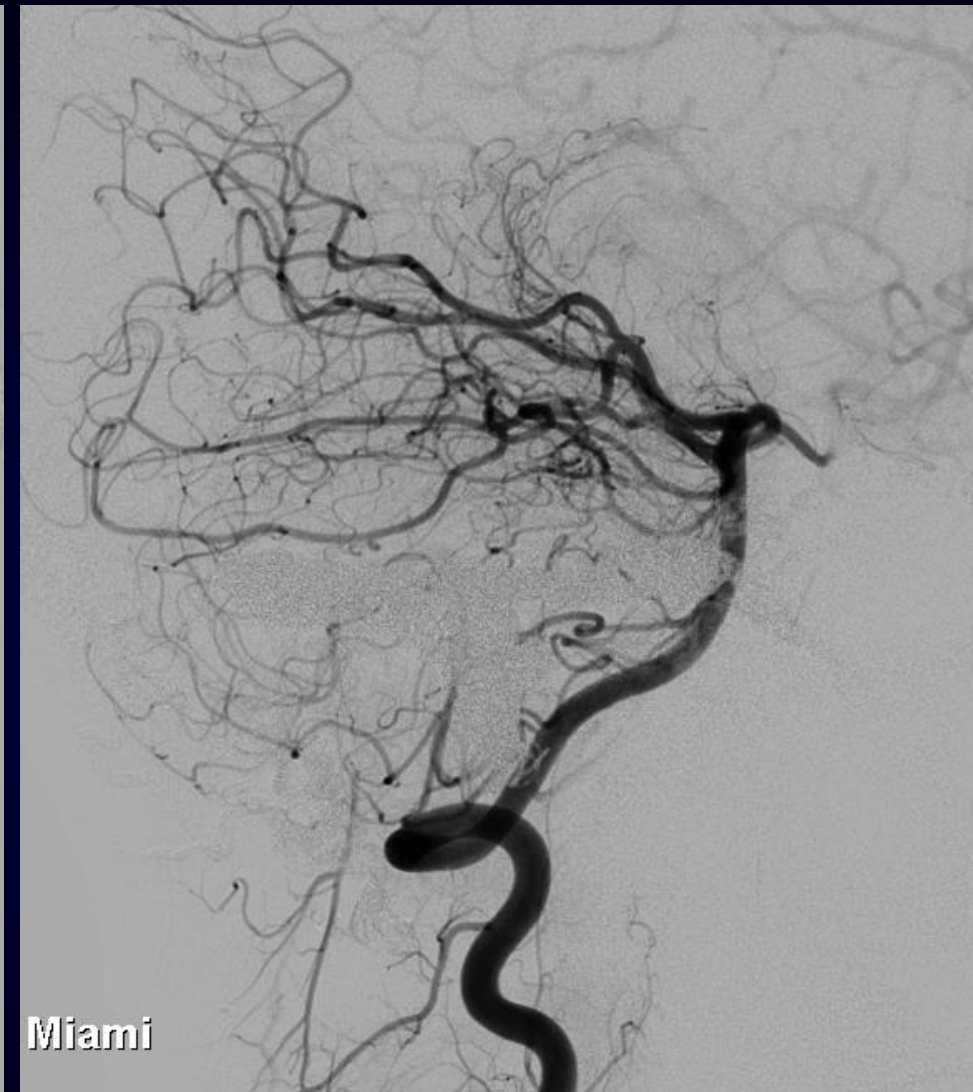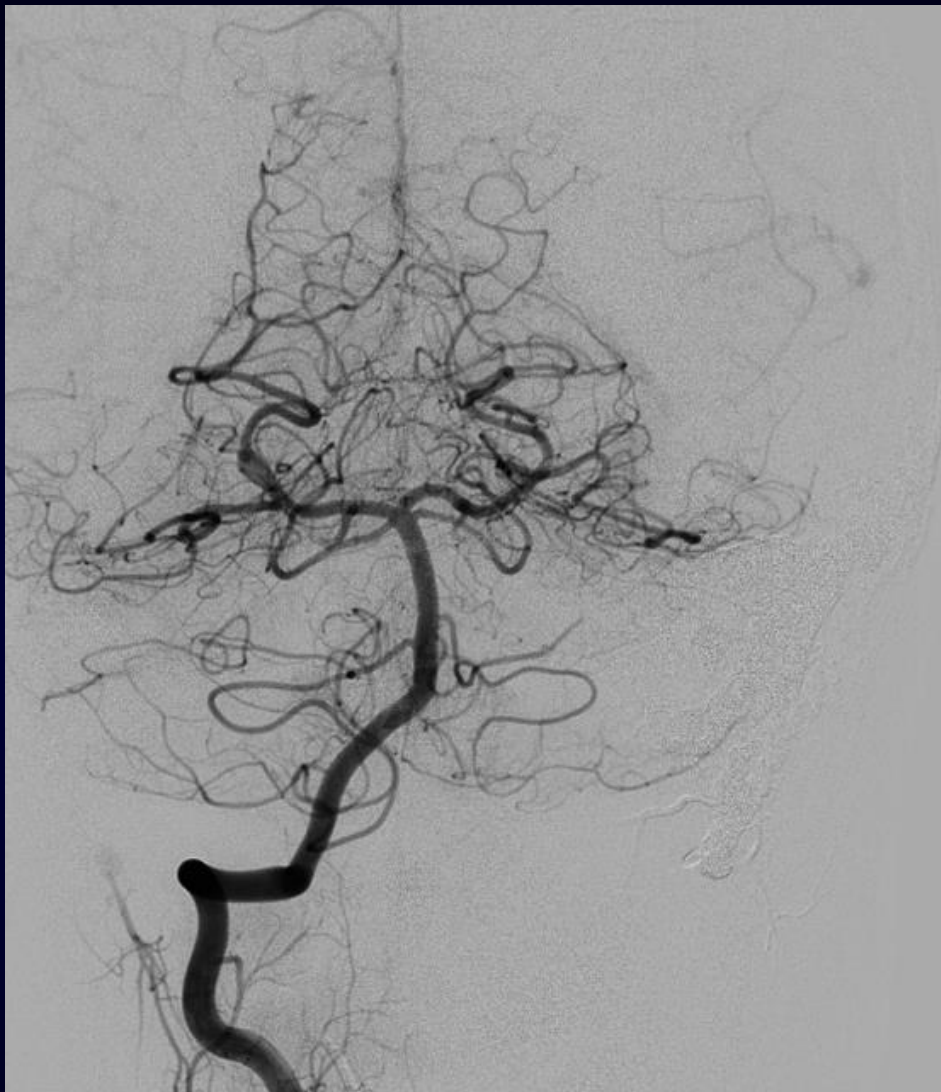Ang +2°
FD 10.0 inch



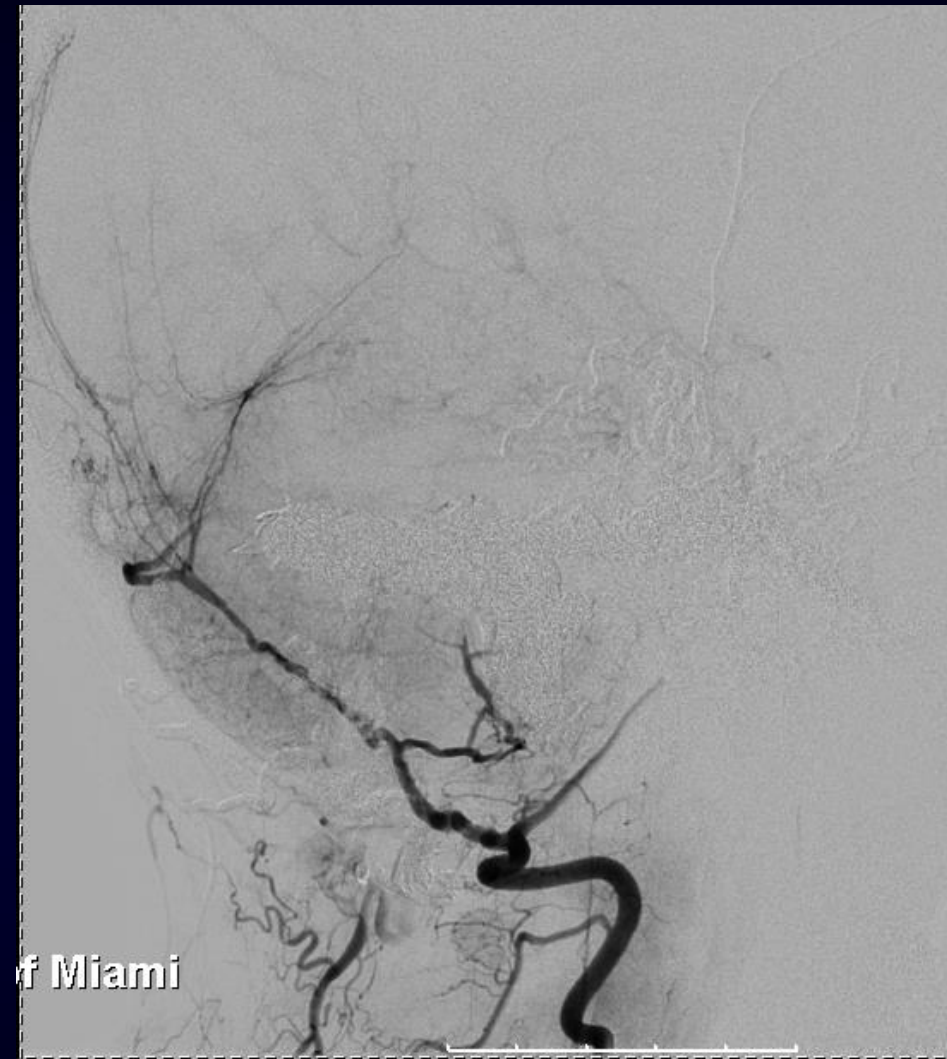
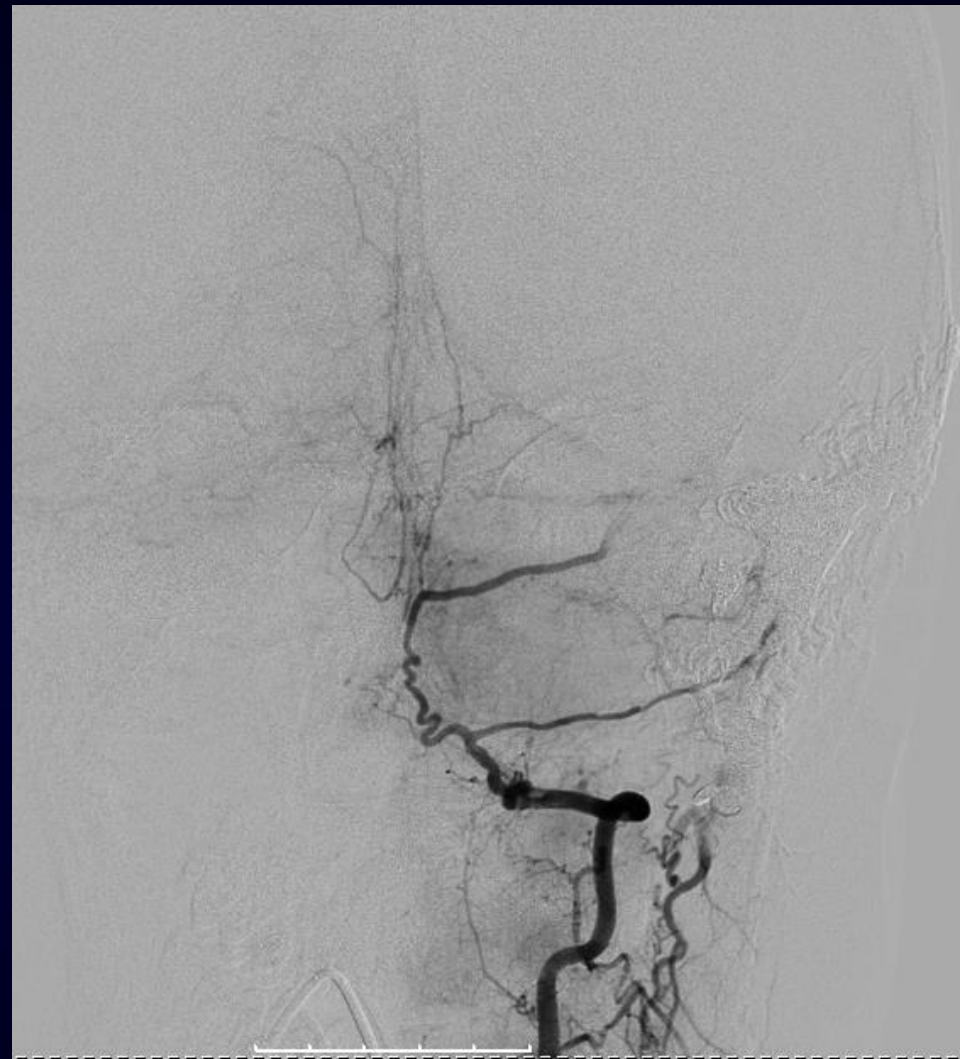
F Miami

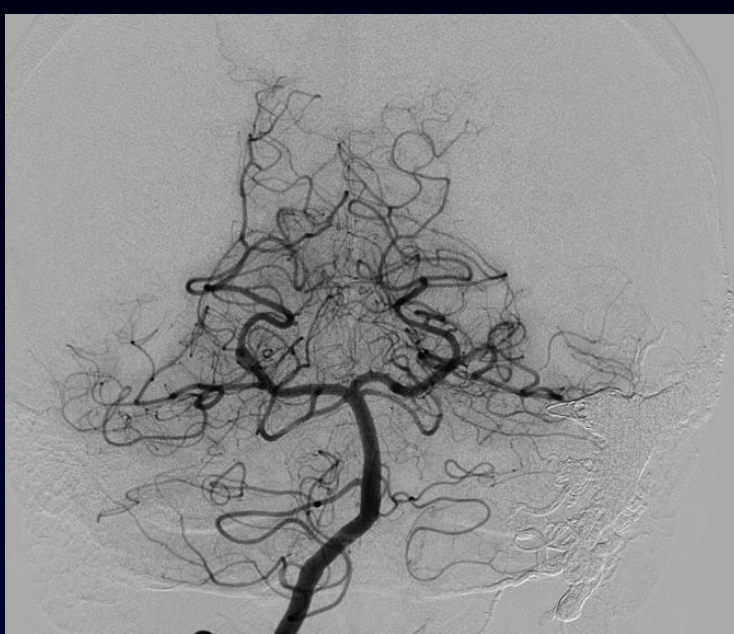



Miami

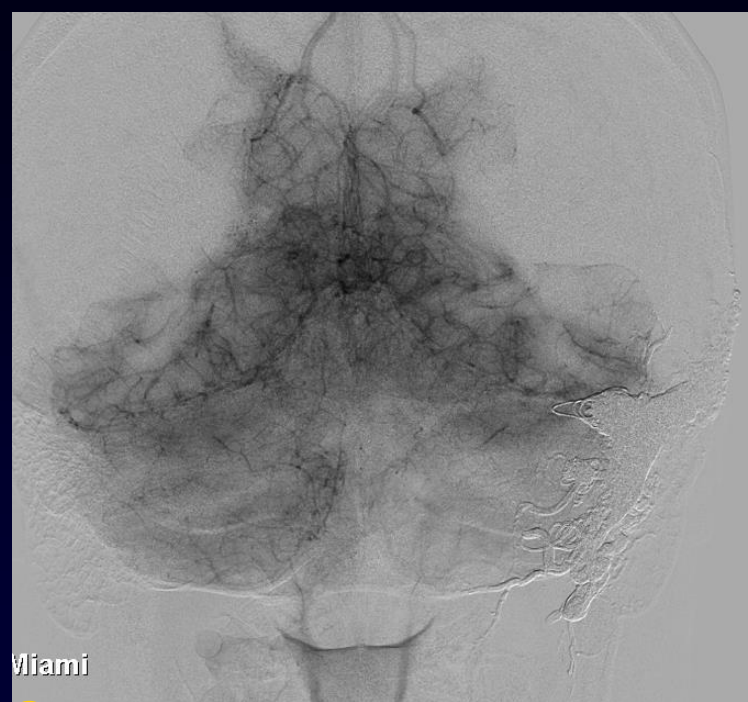


f Miami

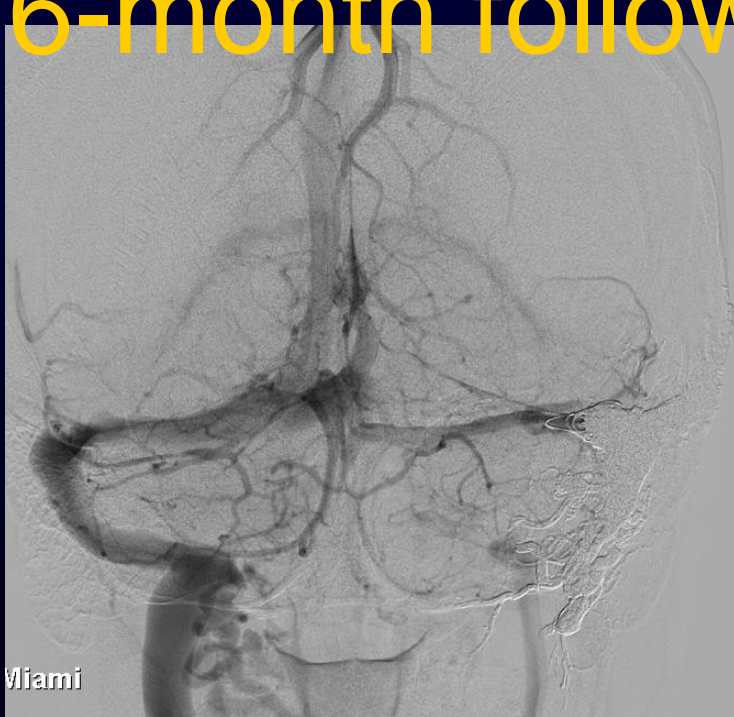

Miami

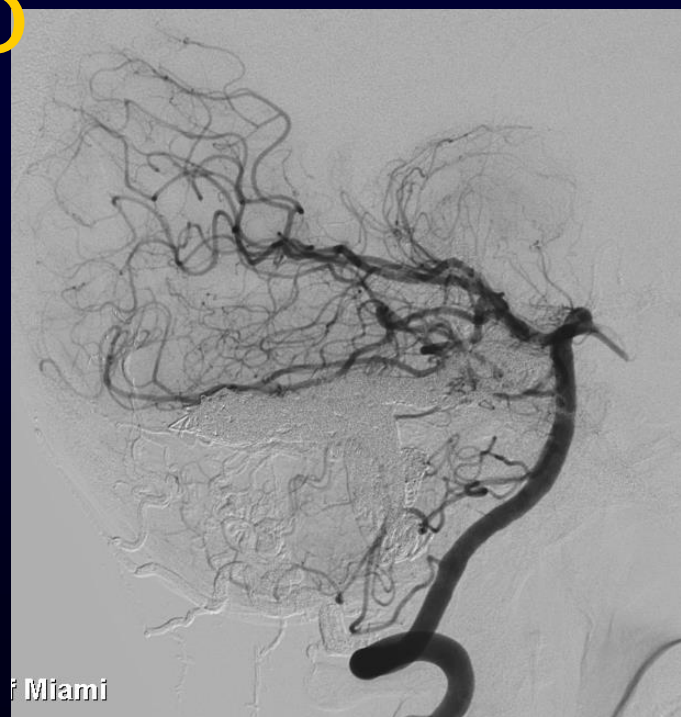6-month follow up



Miami

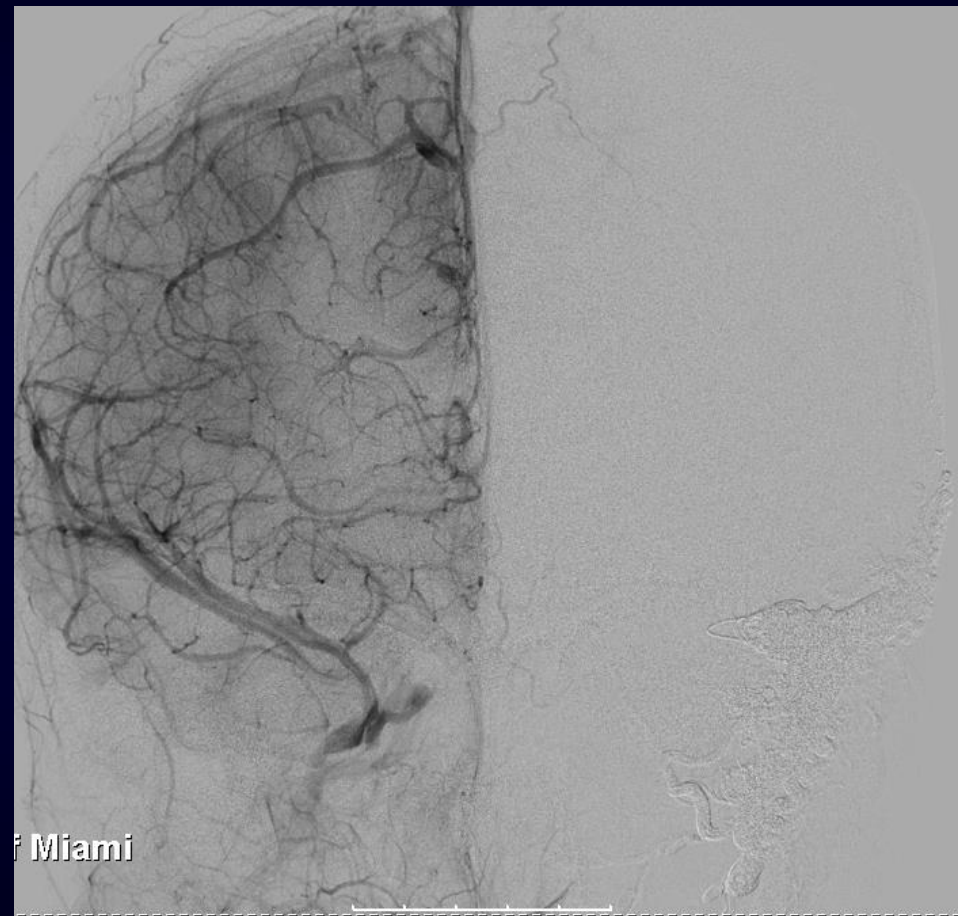
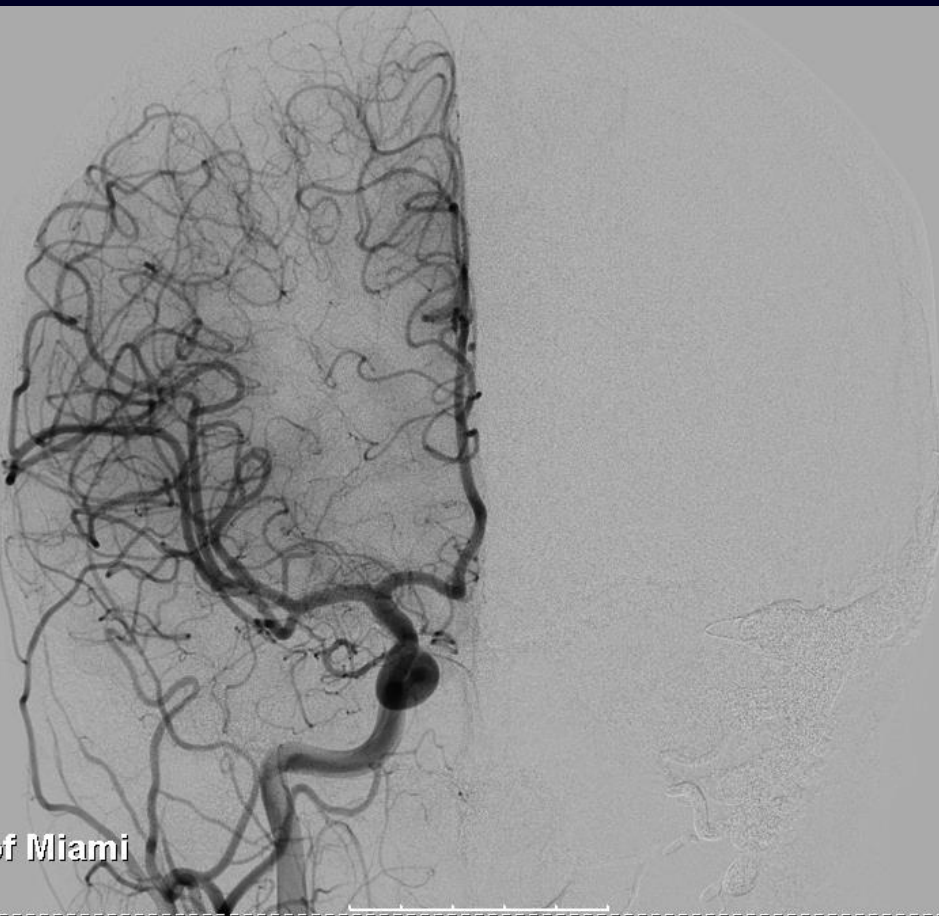

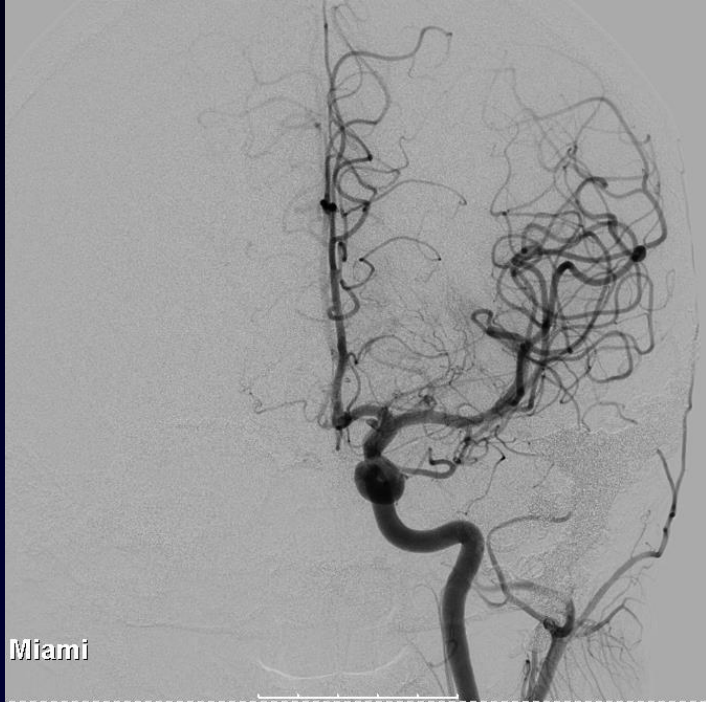Miami



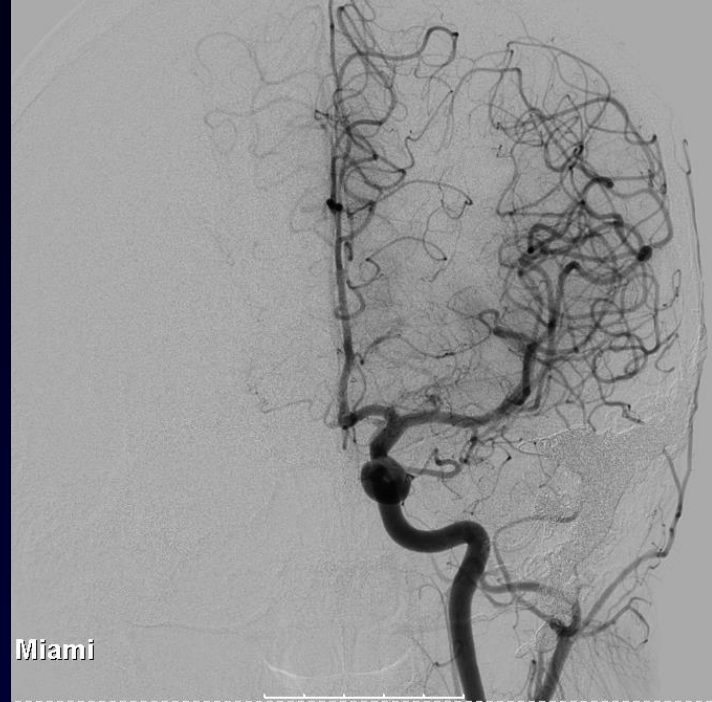Miami

6-month follow up



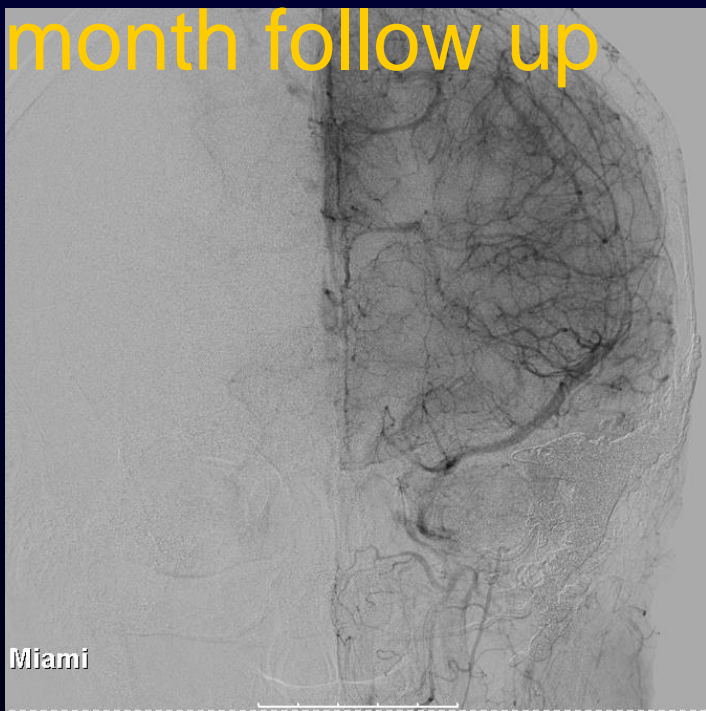

Miami

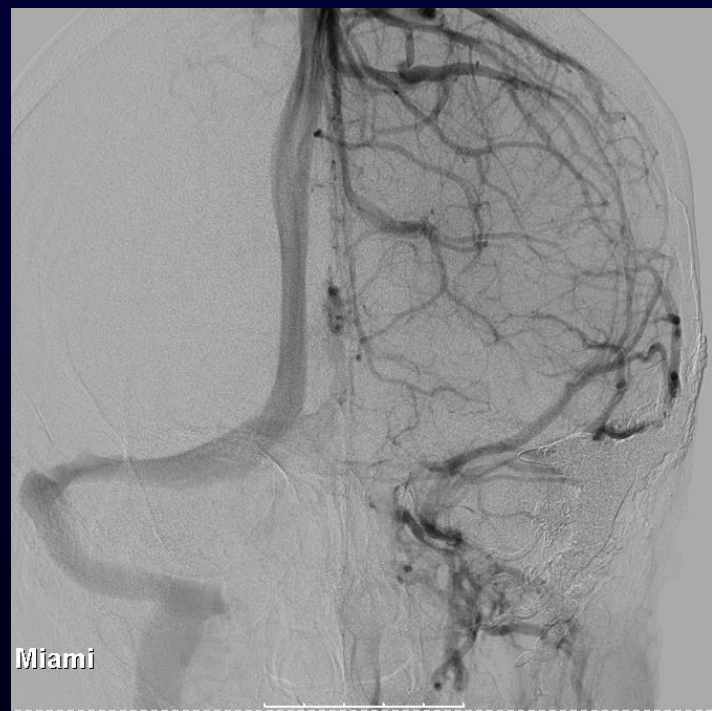

Miami

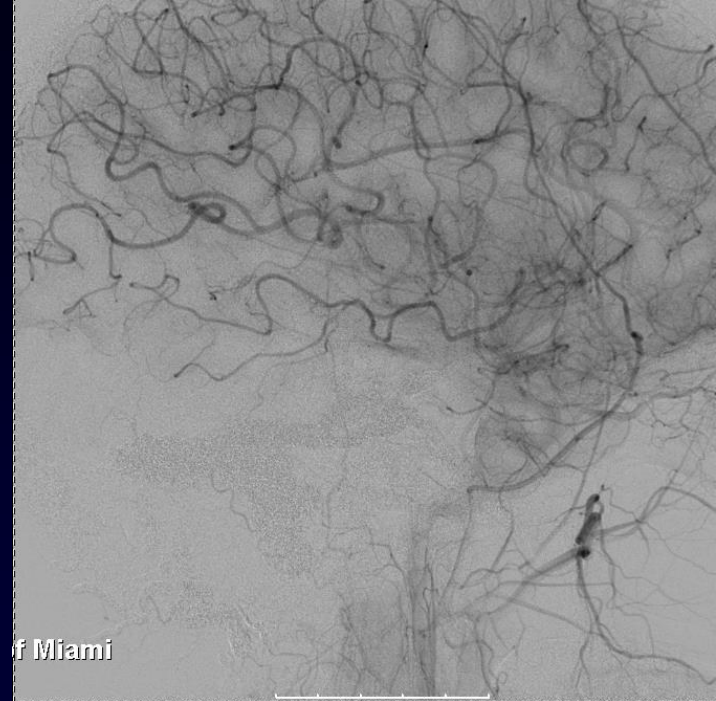
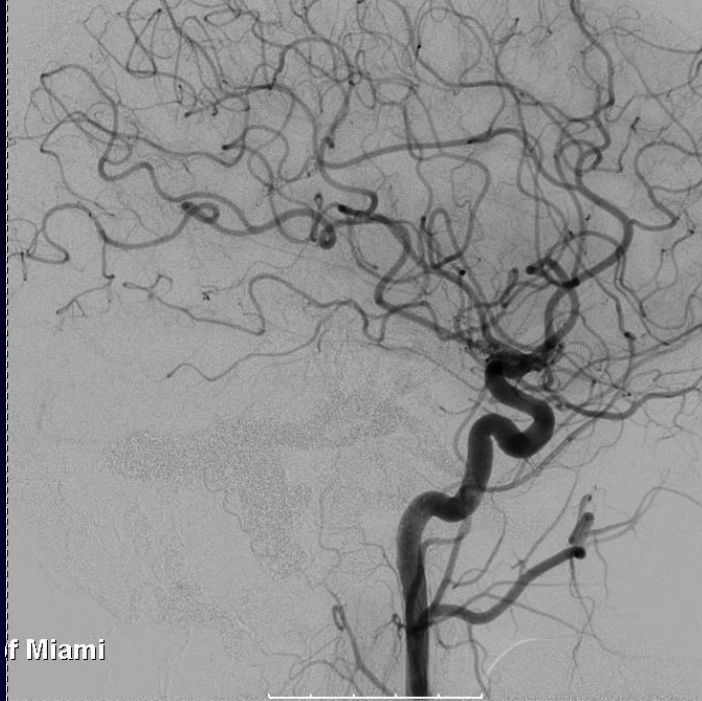6-month follow up



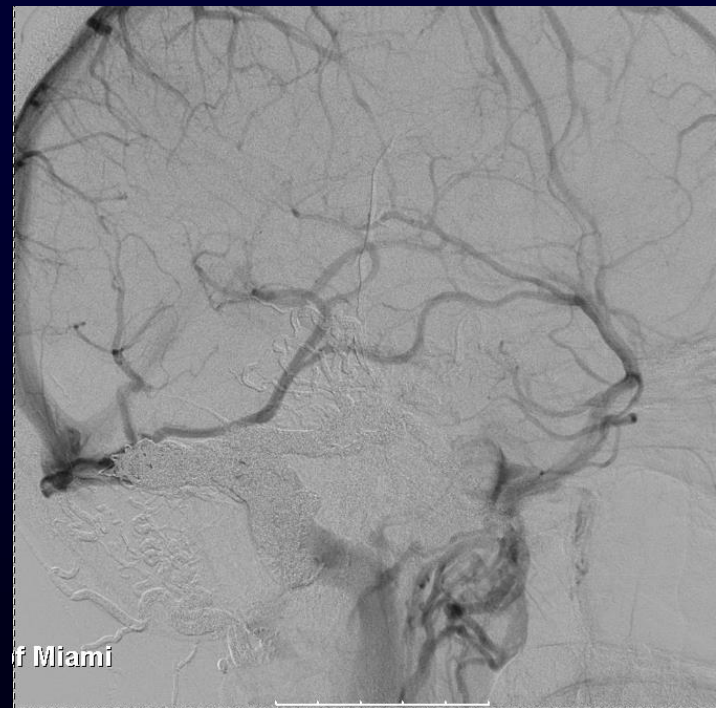
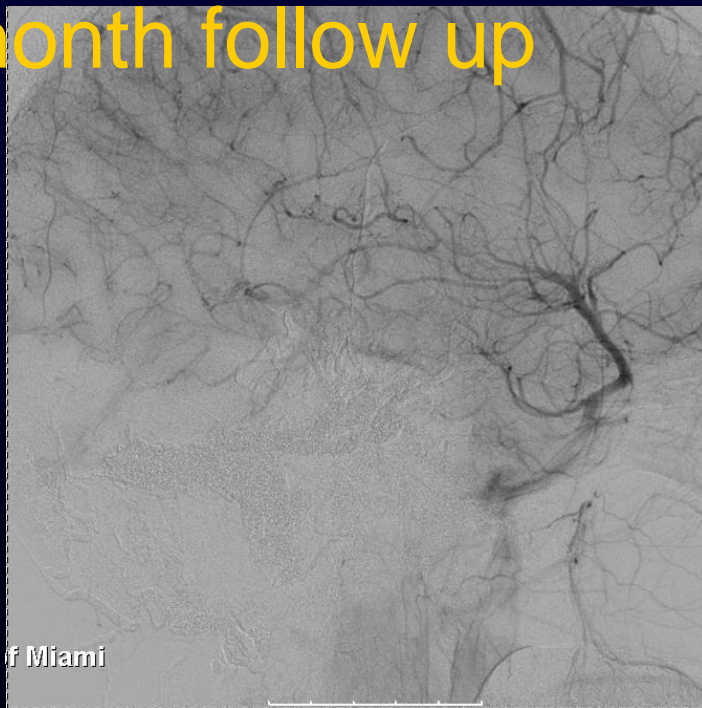
Miami

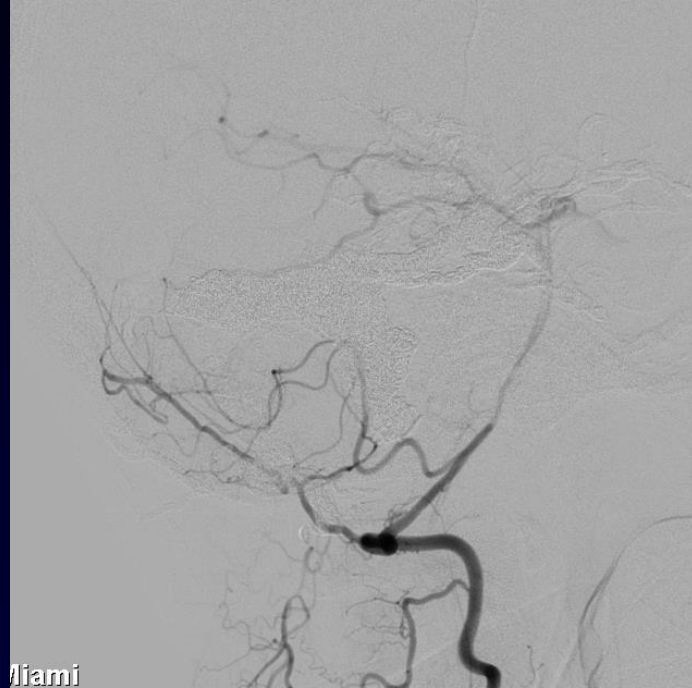

Miami

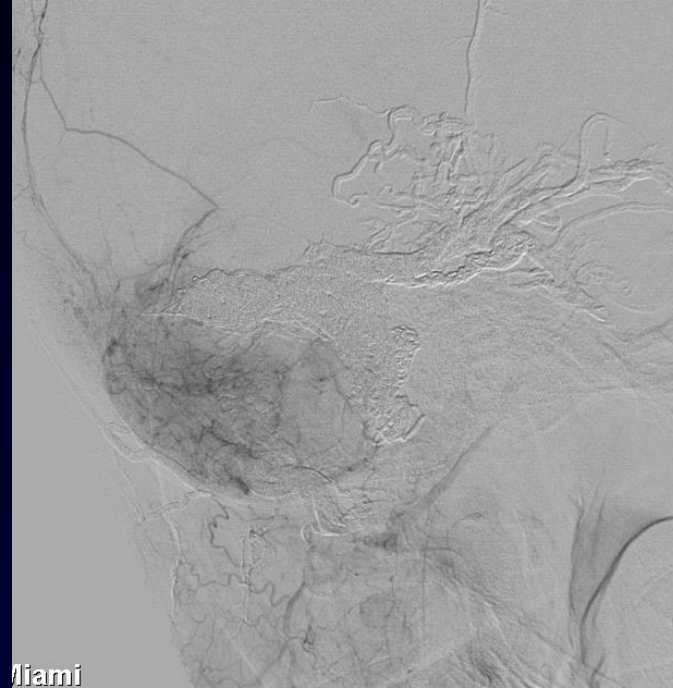


6-month follow up



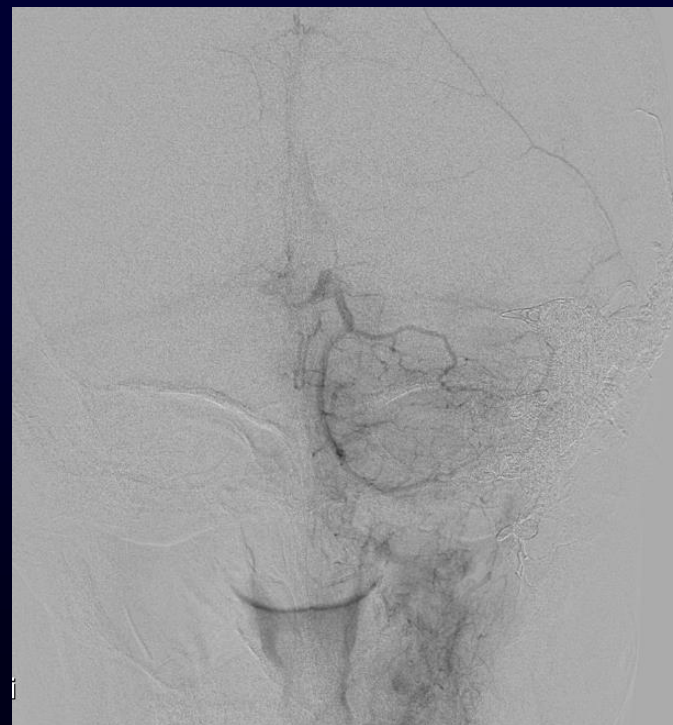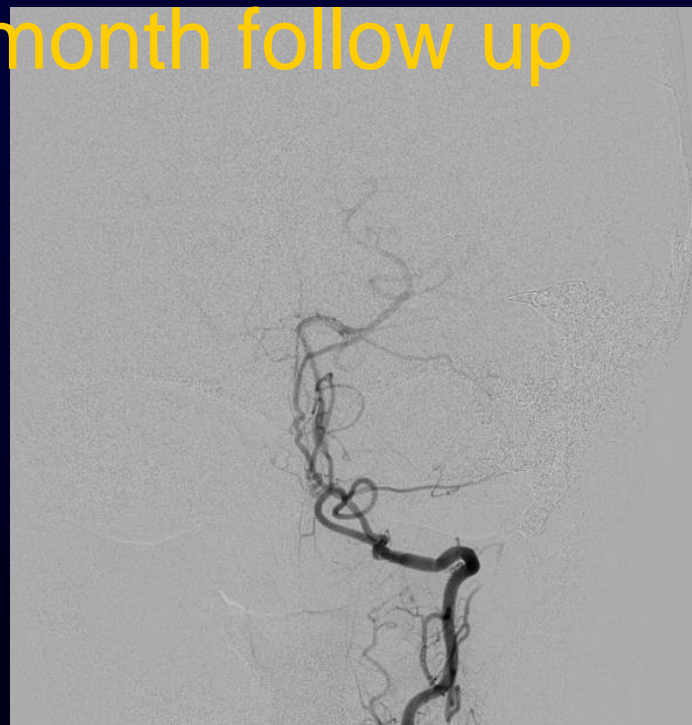


Miami

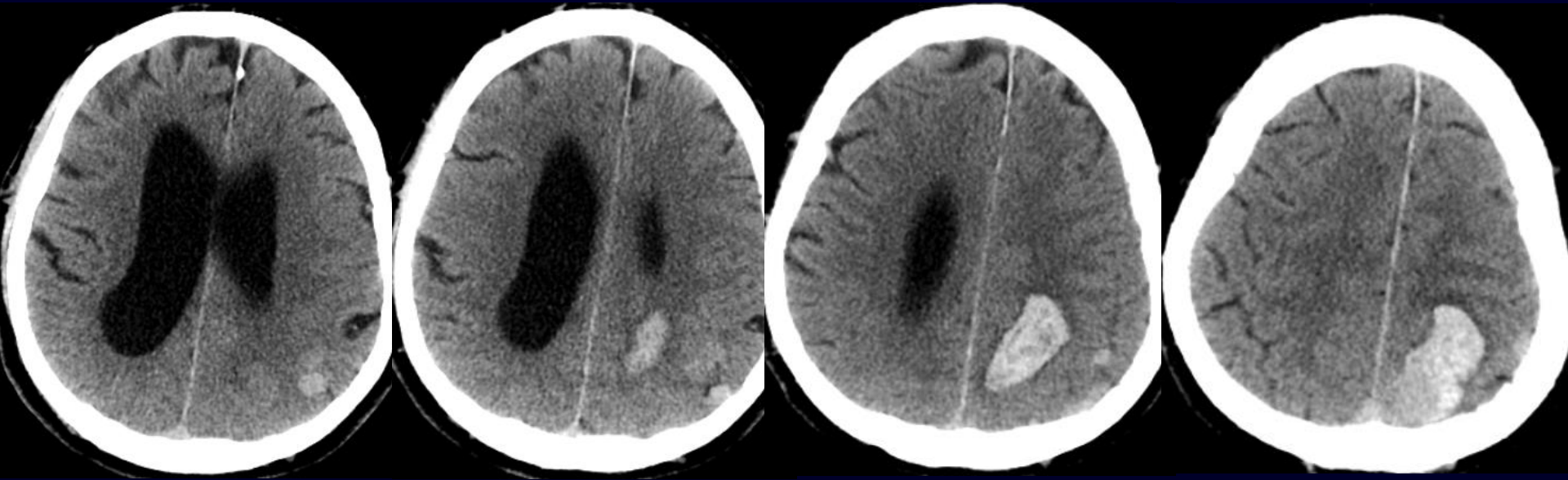


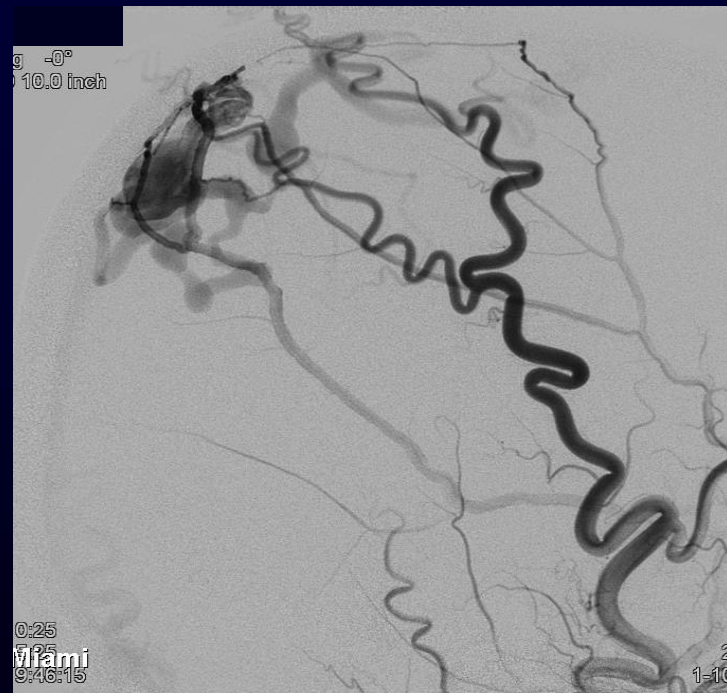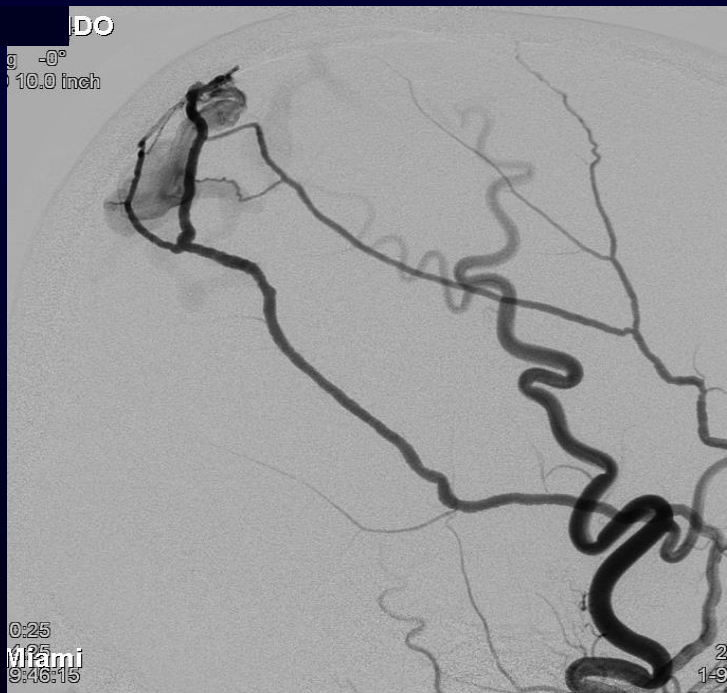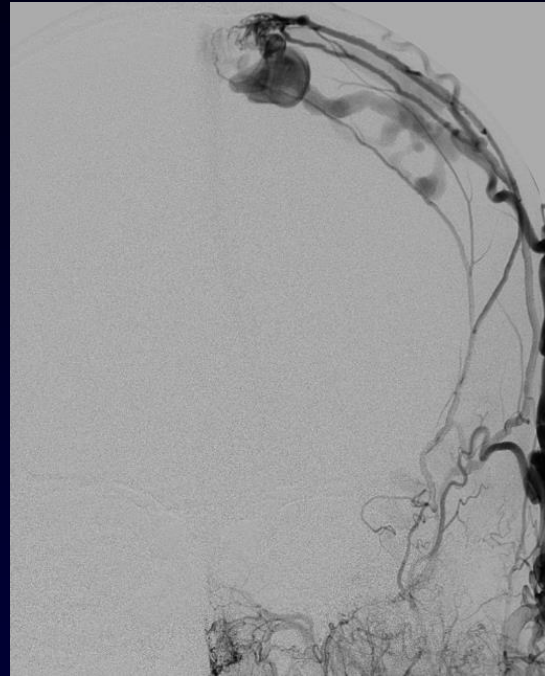
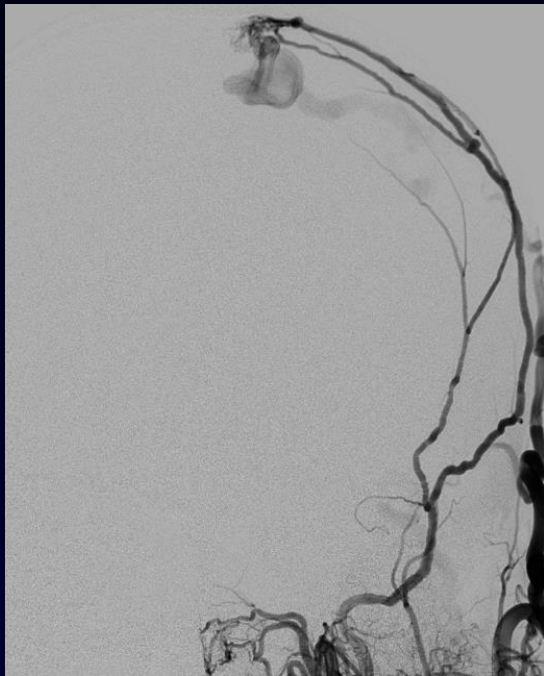Miami

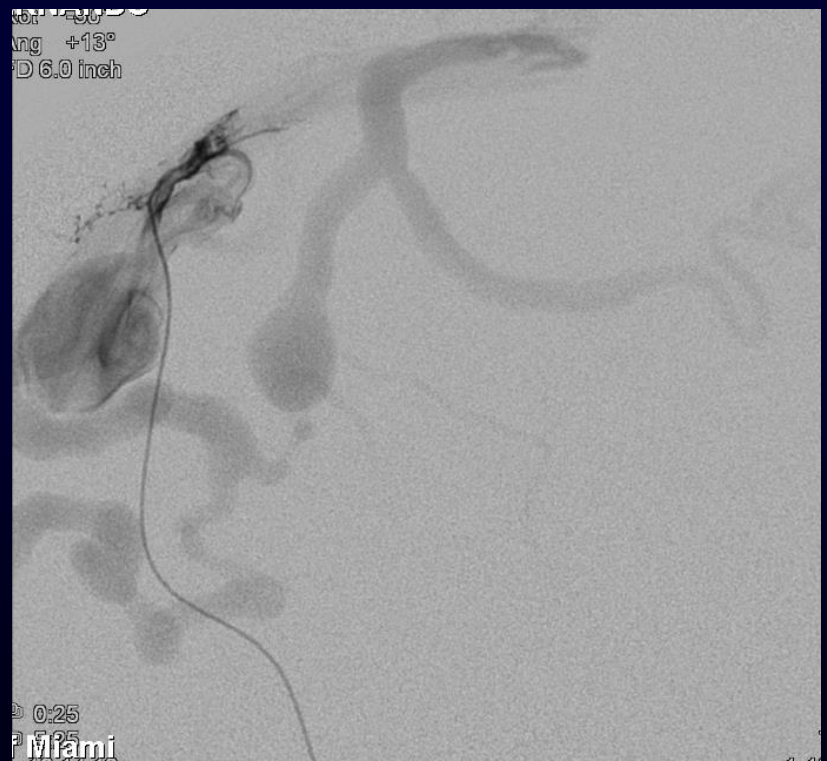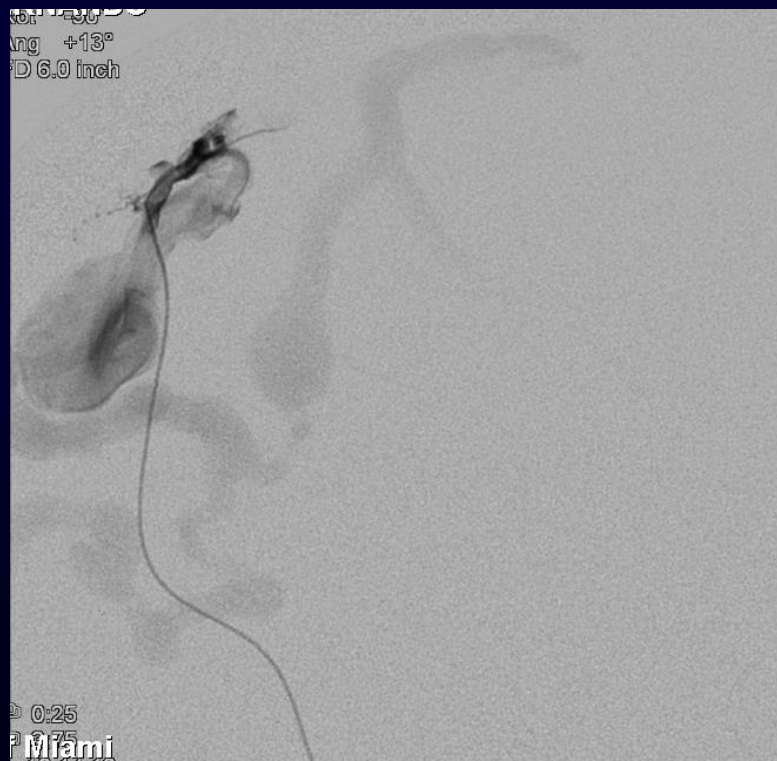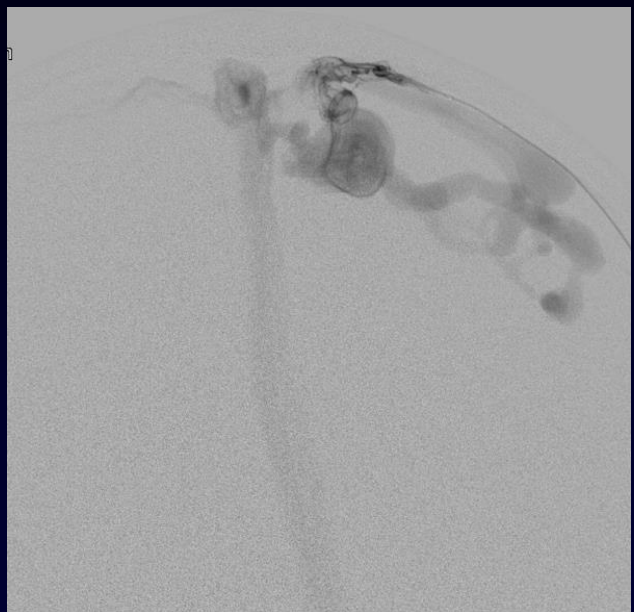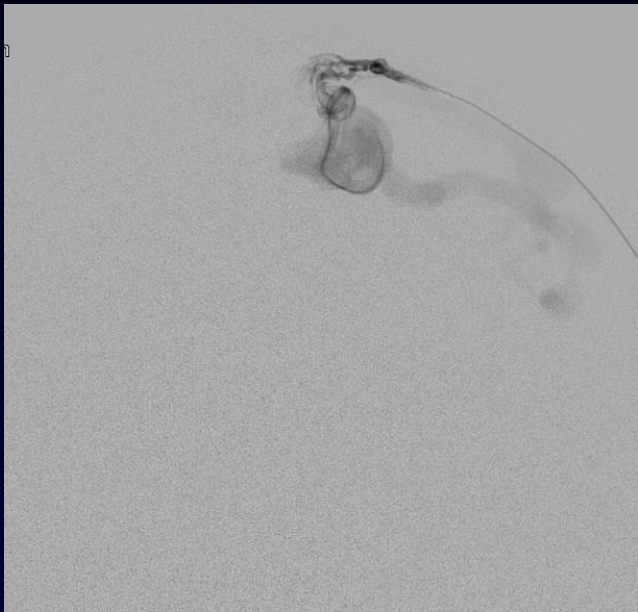
6-month follow up

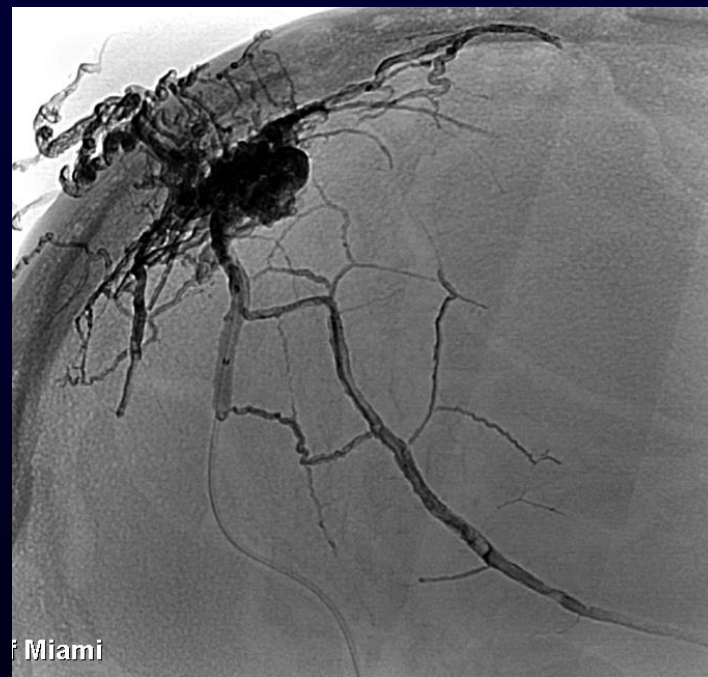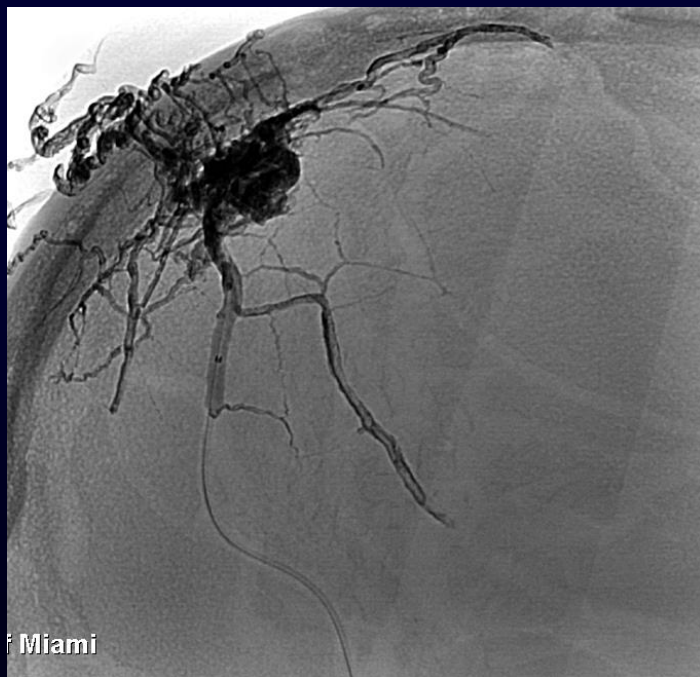
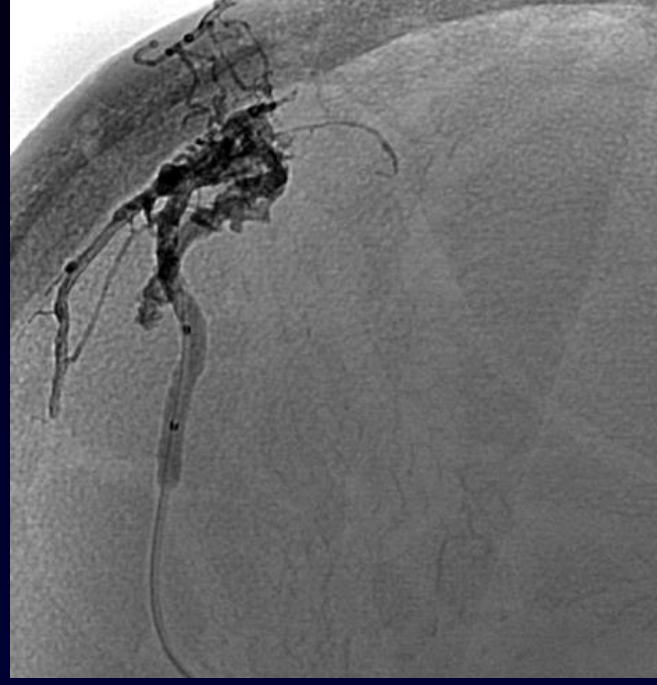
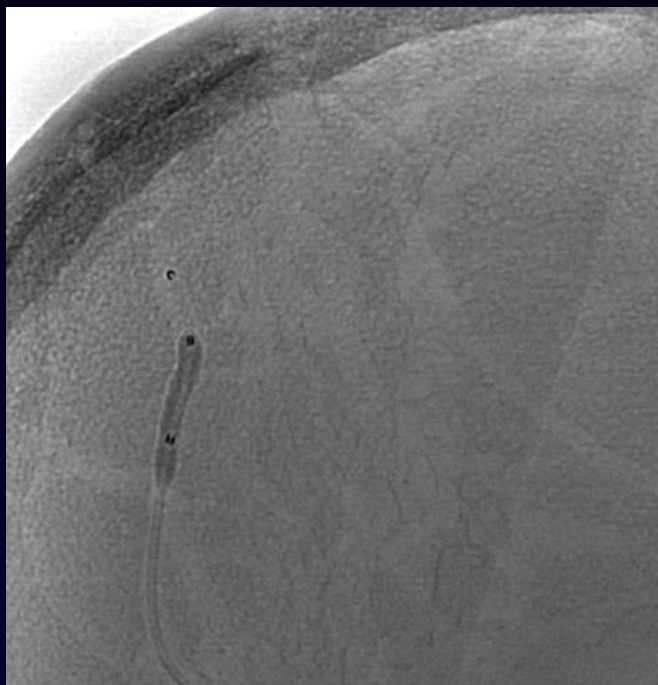


61 M presenting with HA and right side weakness

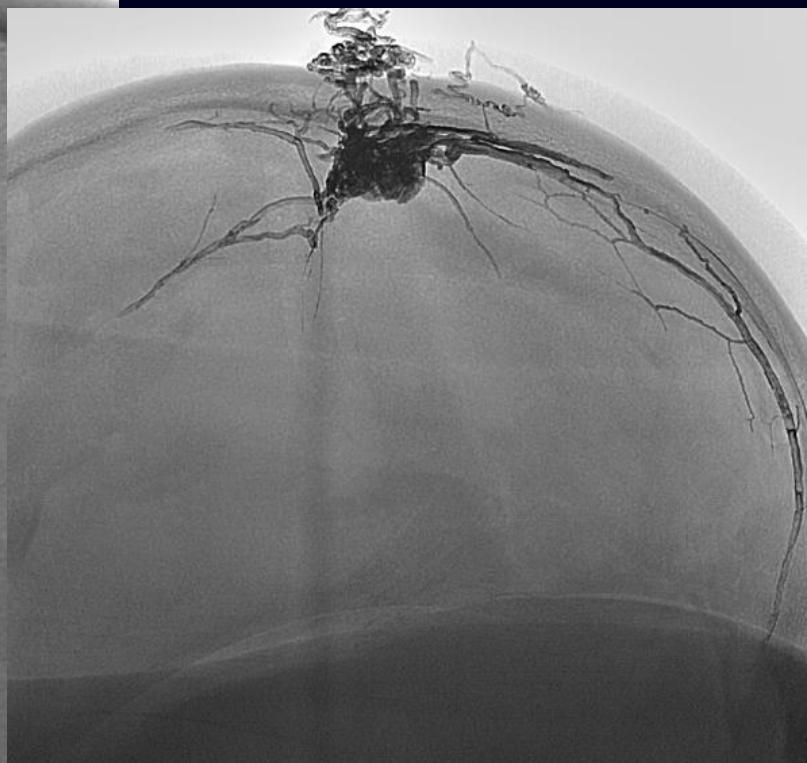
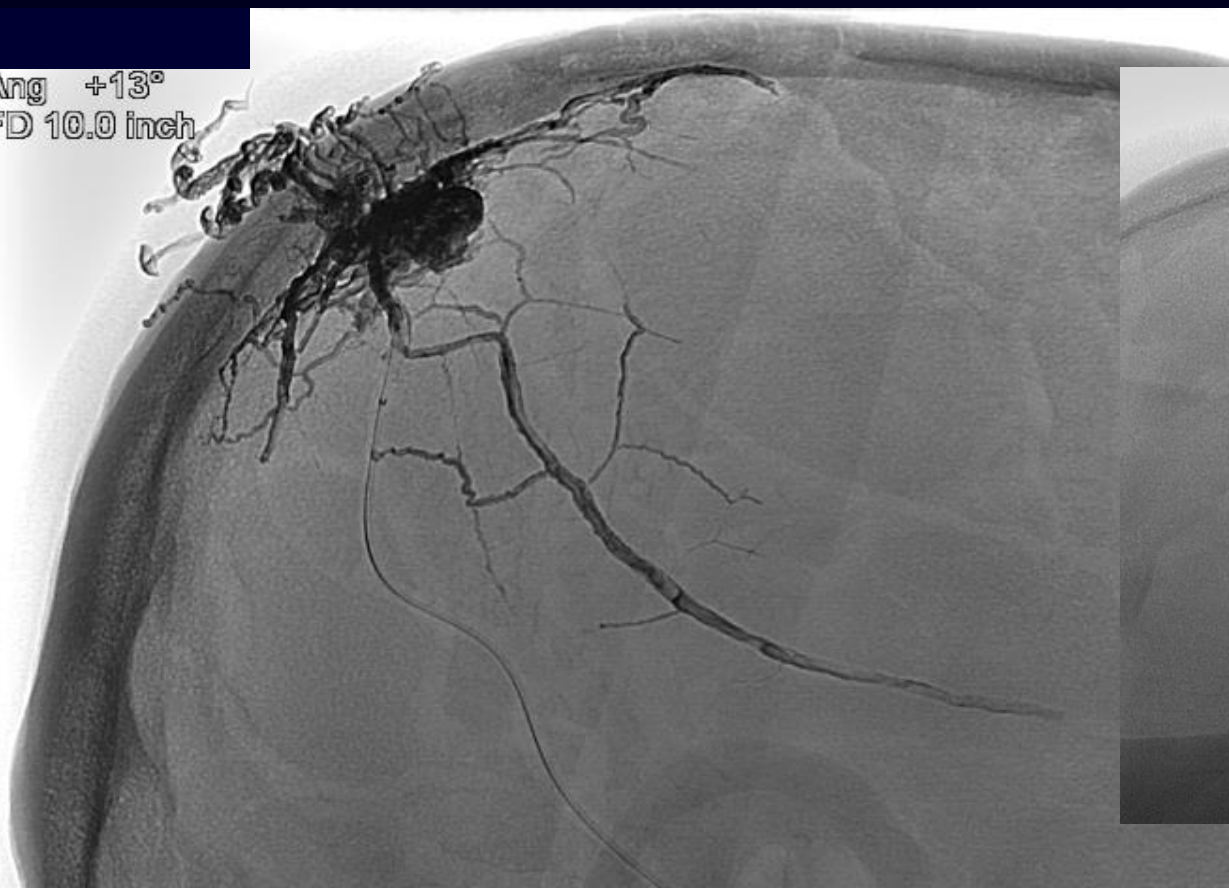


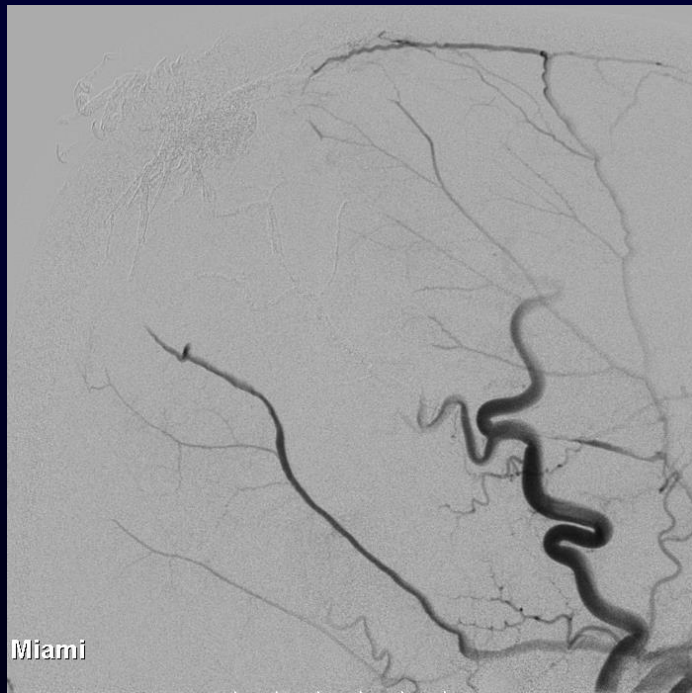
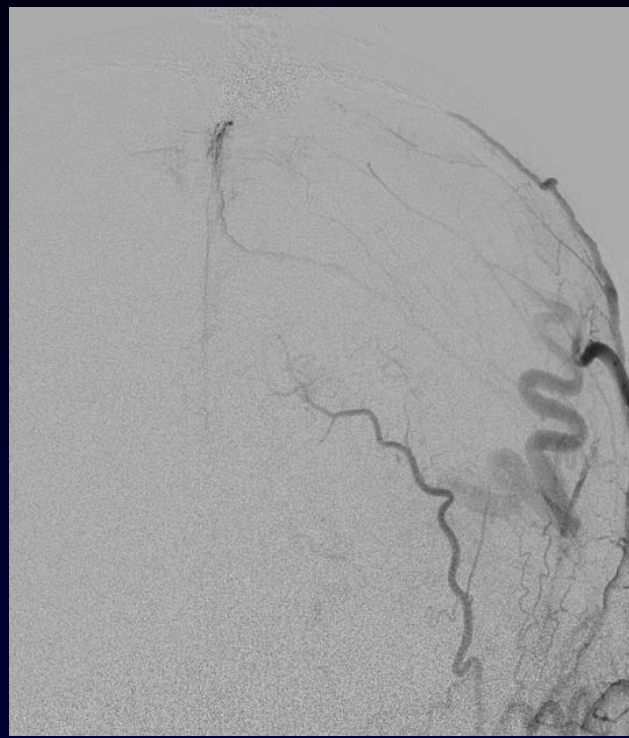
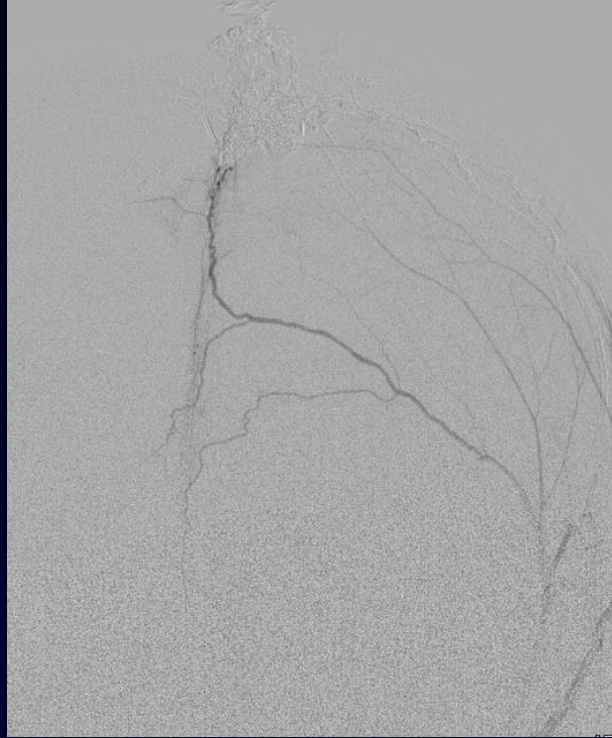




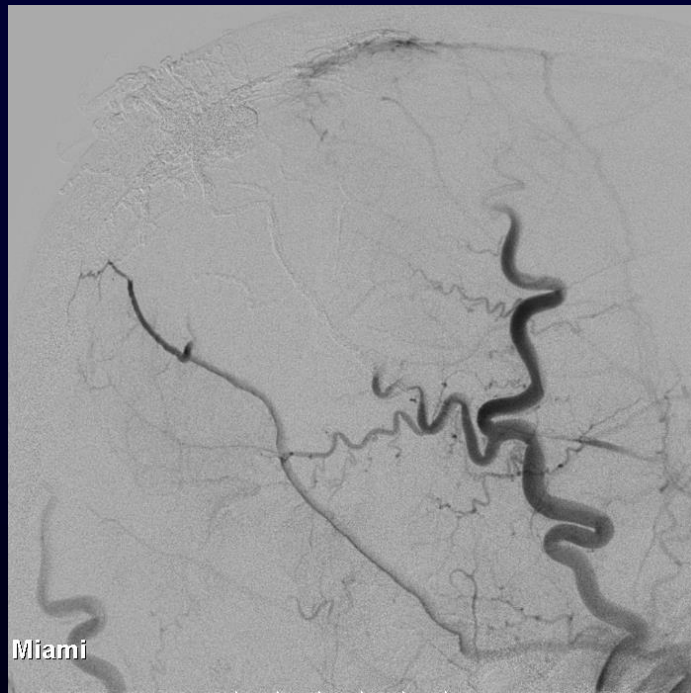

Ang +13°
FD 10.0 inch



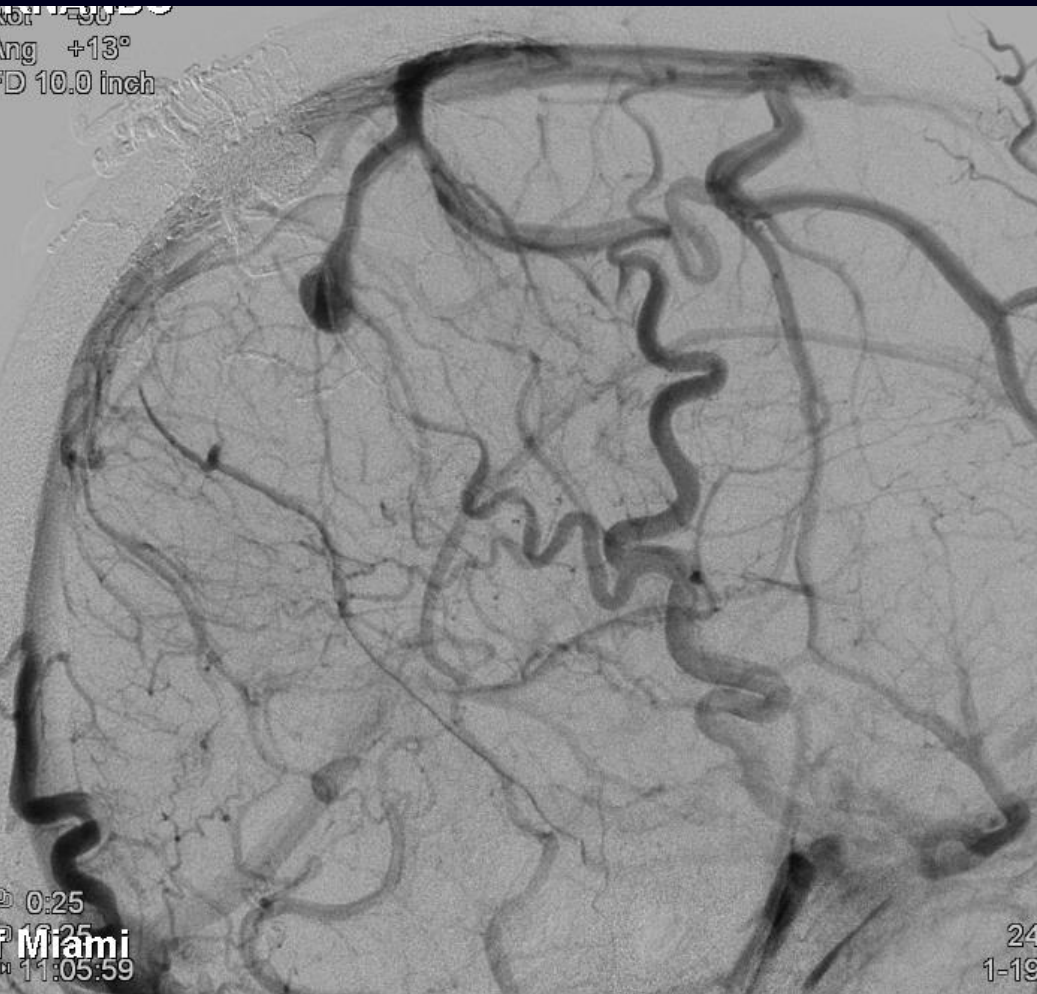

Miami



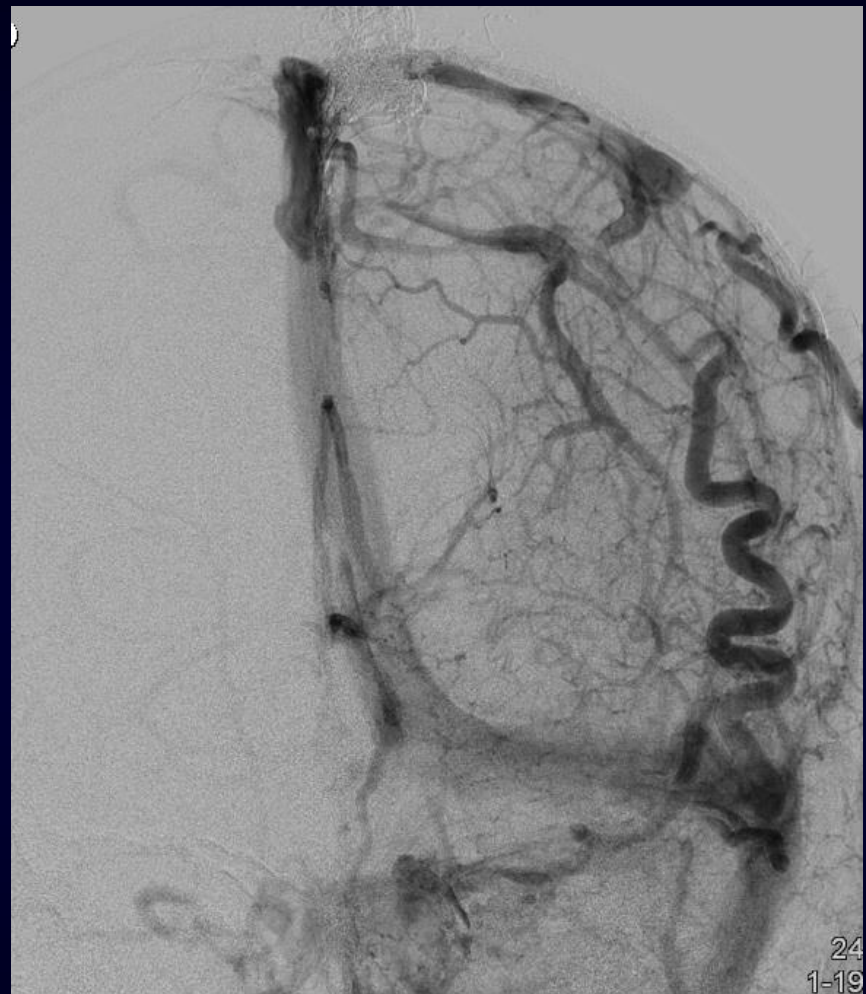Miami

0:25
ang +13°
D 10.0 inch

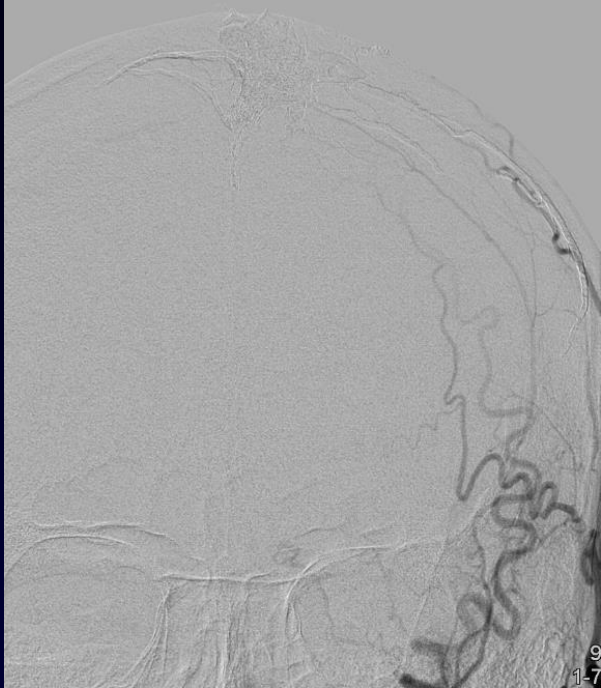


0:25
Miami
11:05:59

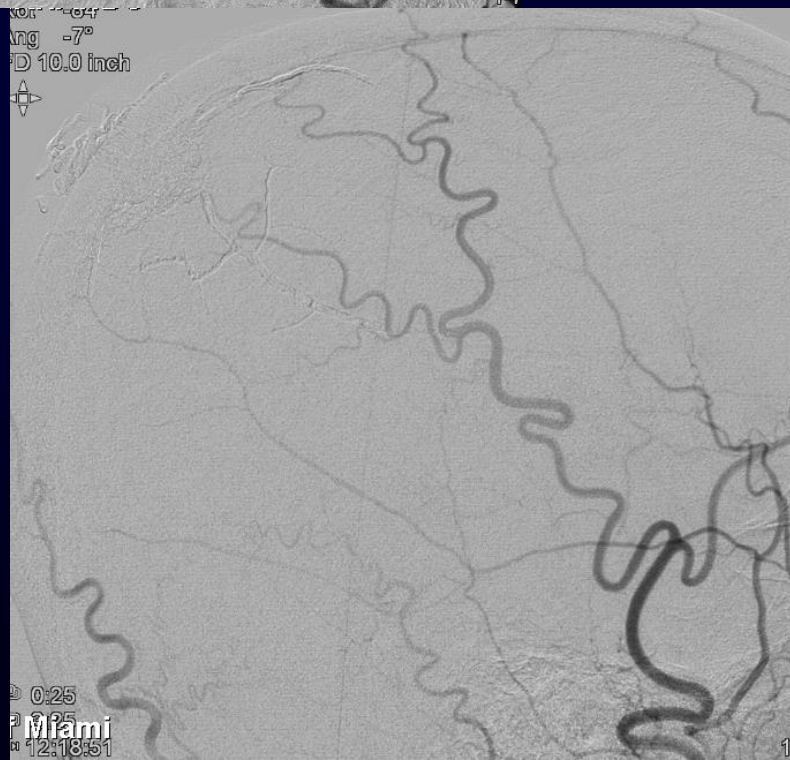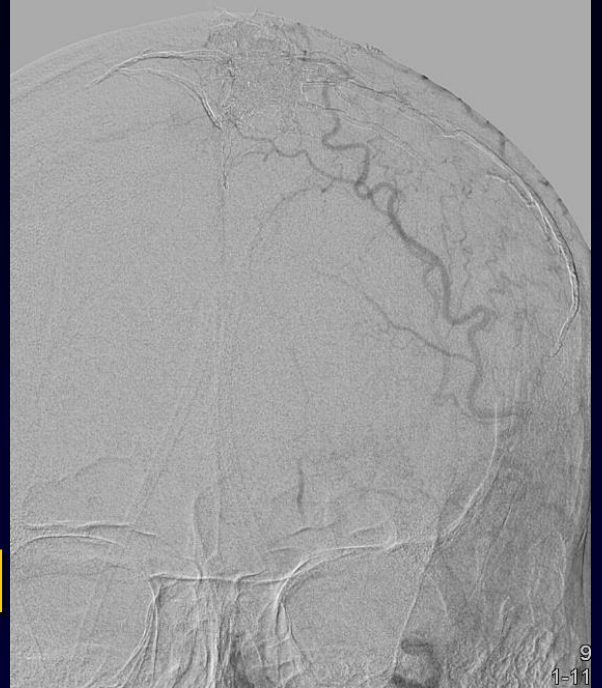
24
1-19



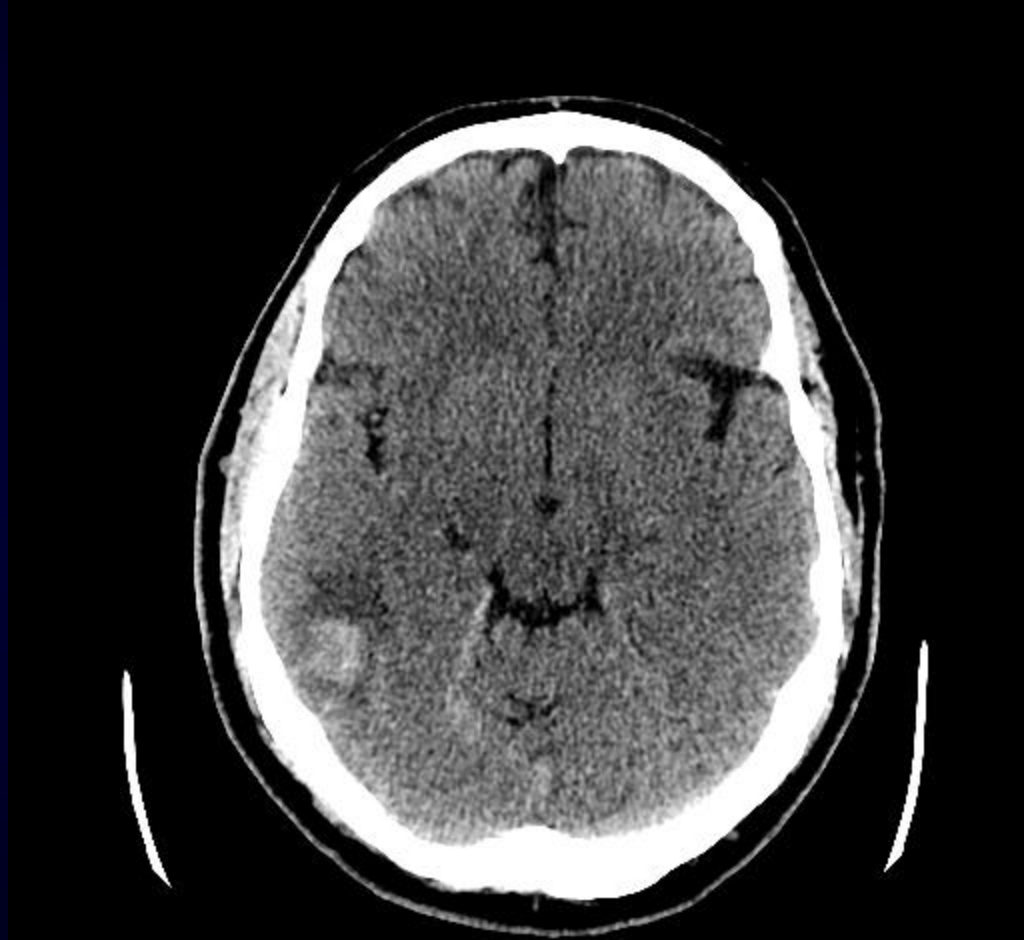24
1-19

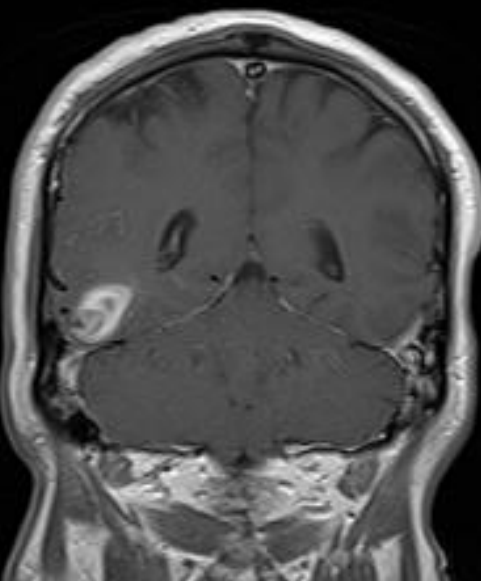
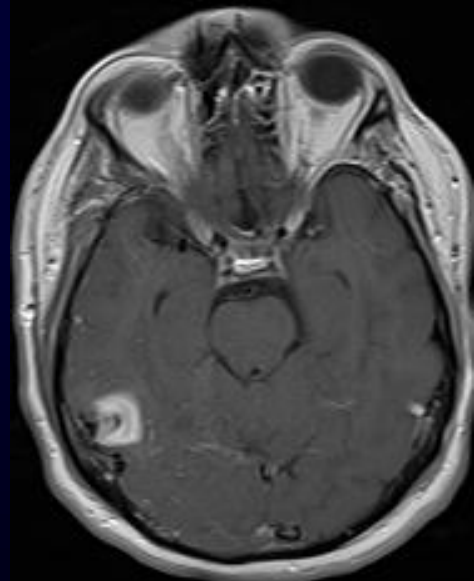
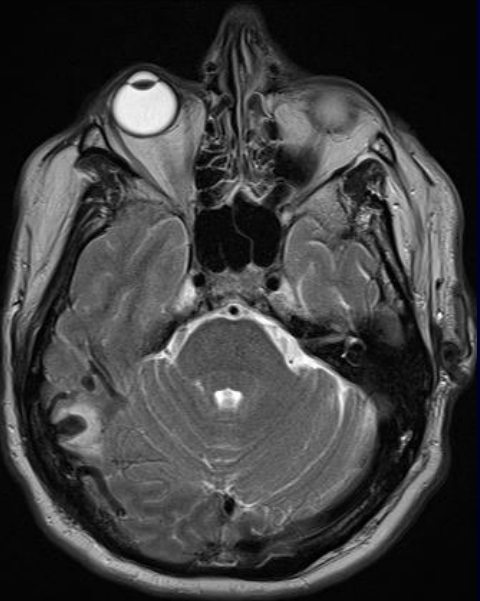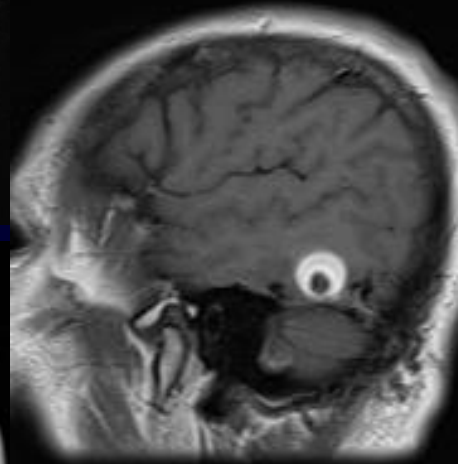
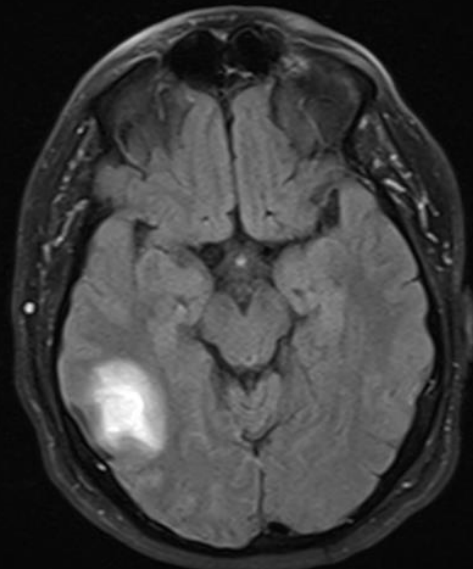
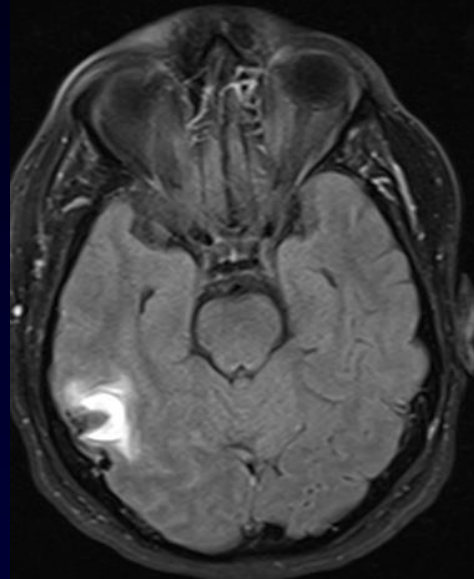
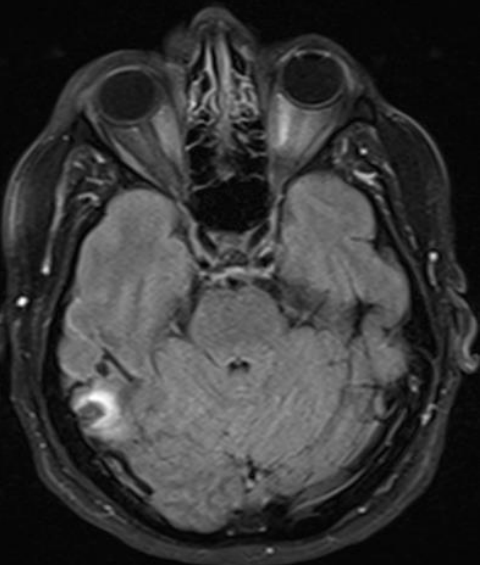


7-month f/u

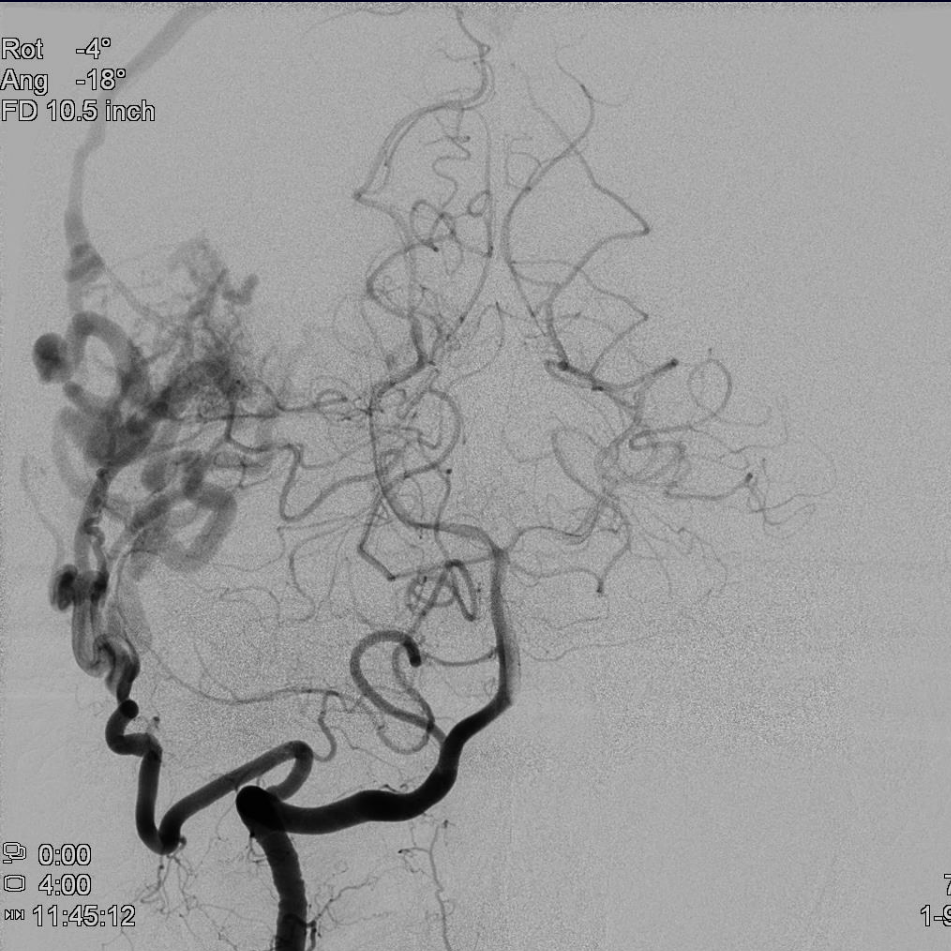

62 M presenting with partial seizures



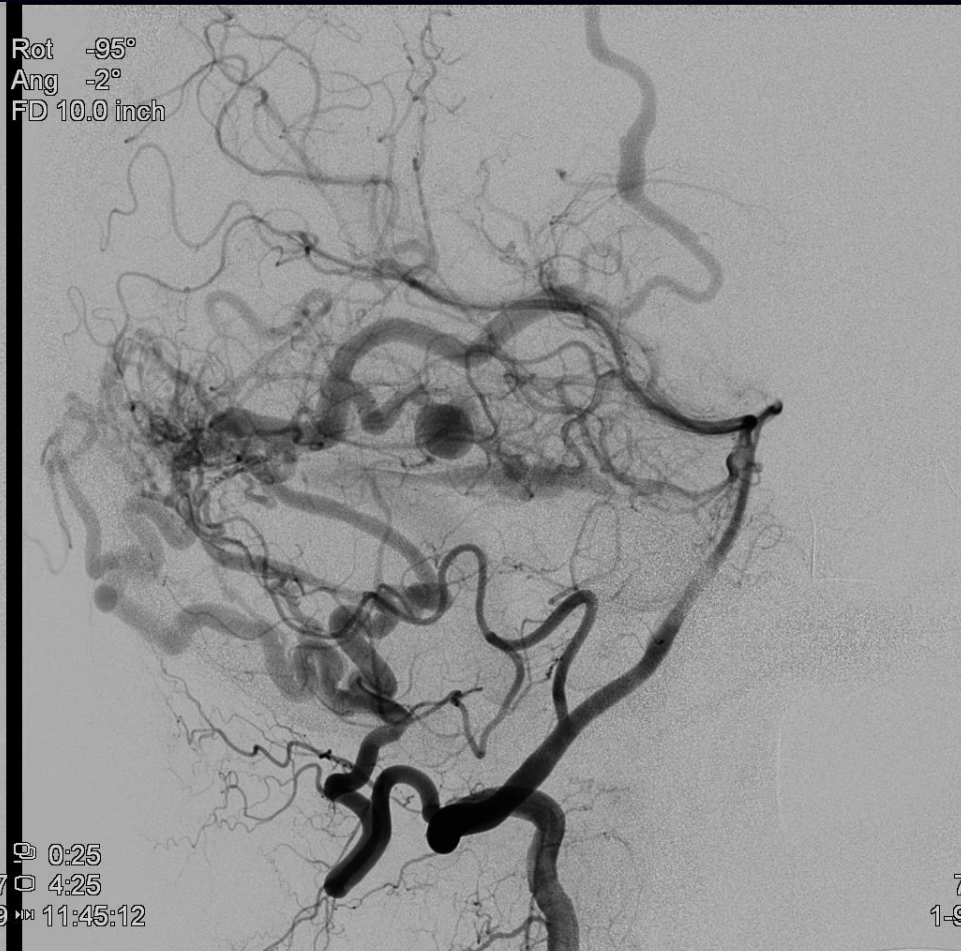

Rot -4°
Ang -18°
FD 10.5 inch



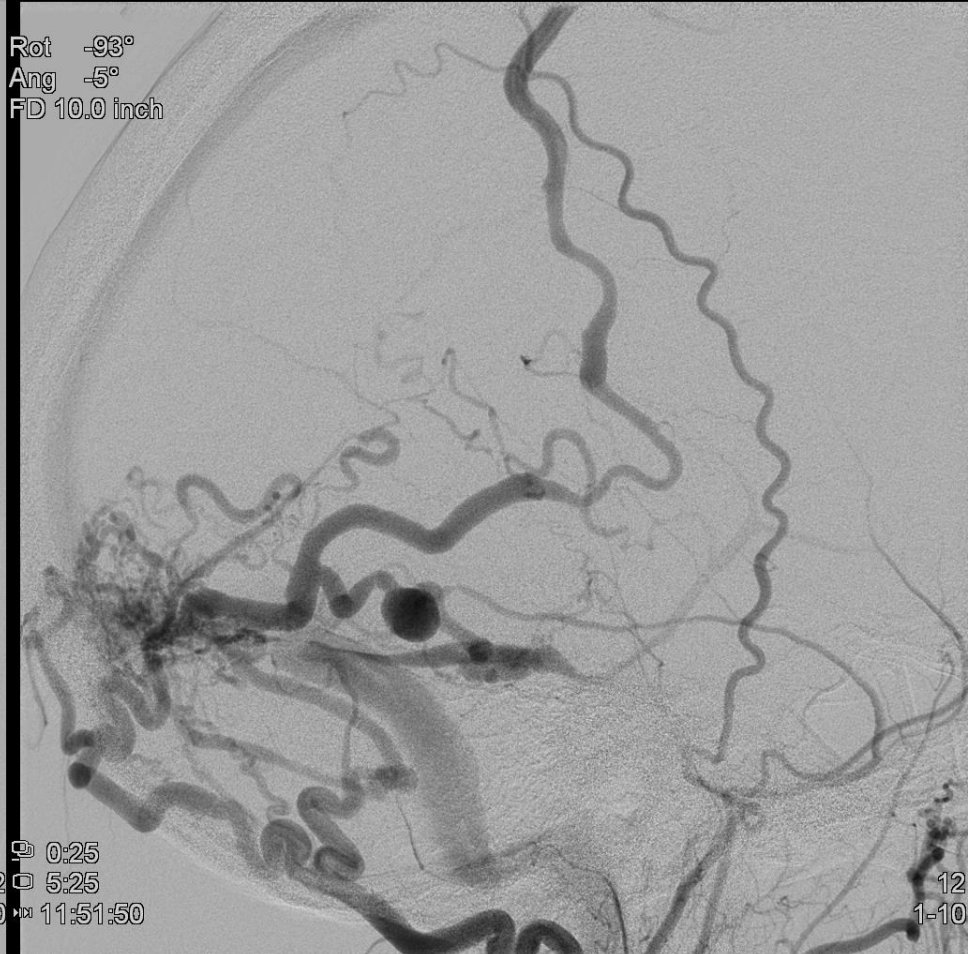
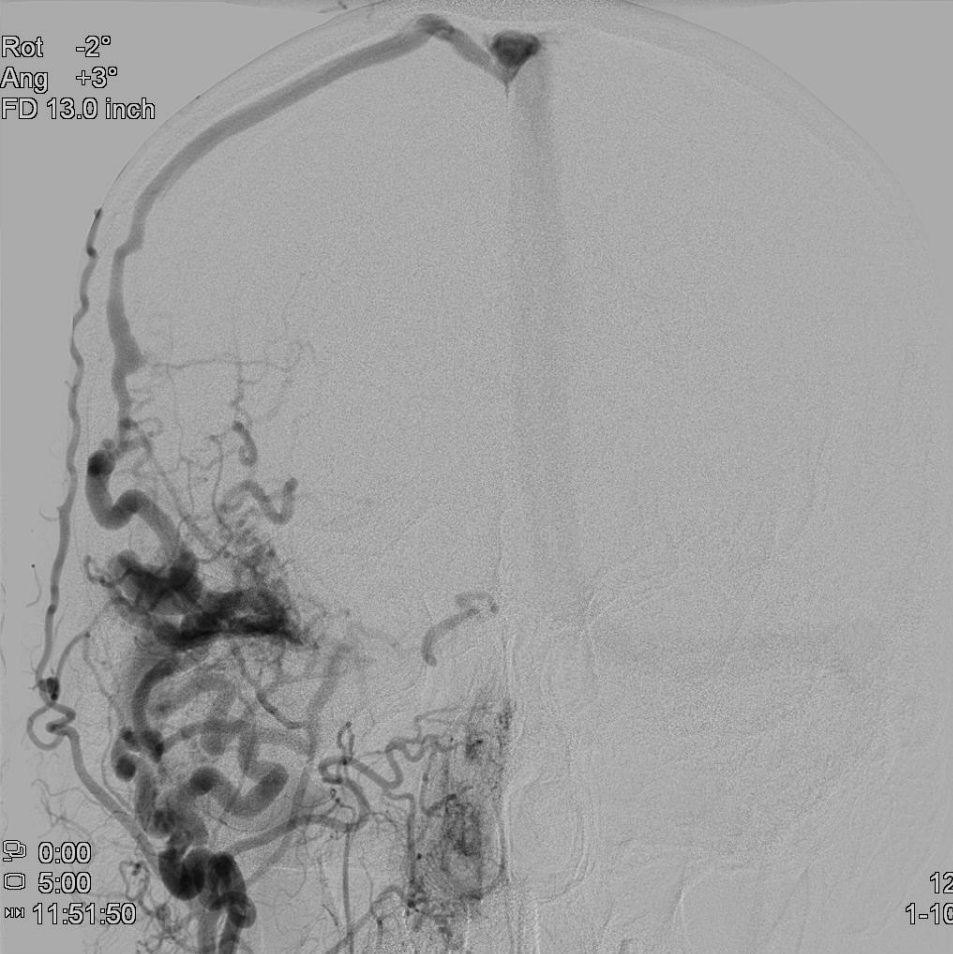0:00
4:00
11:45:12

Rot -95°
Ang -2°
FD 10.0 inch

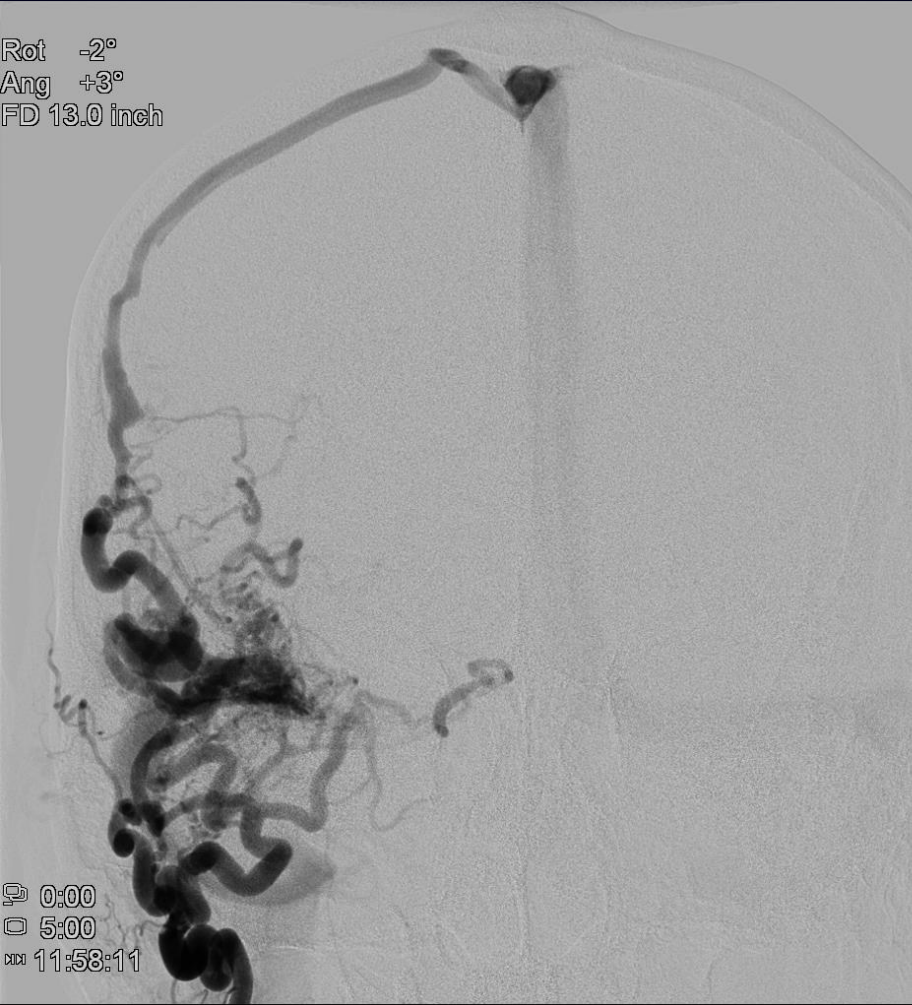


0:25
4:25
1-9 11:45:12

7
1-9

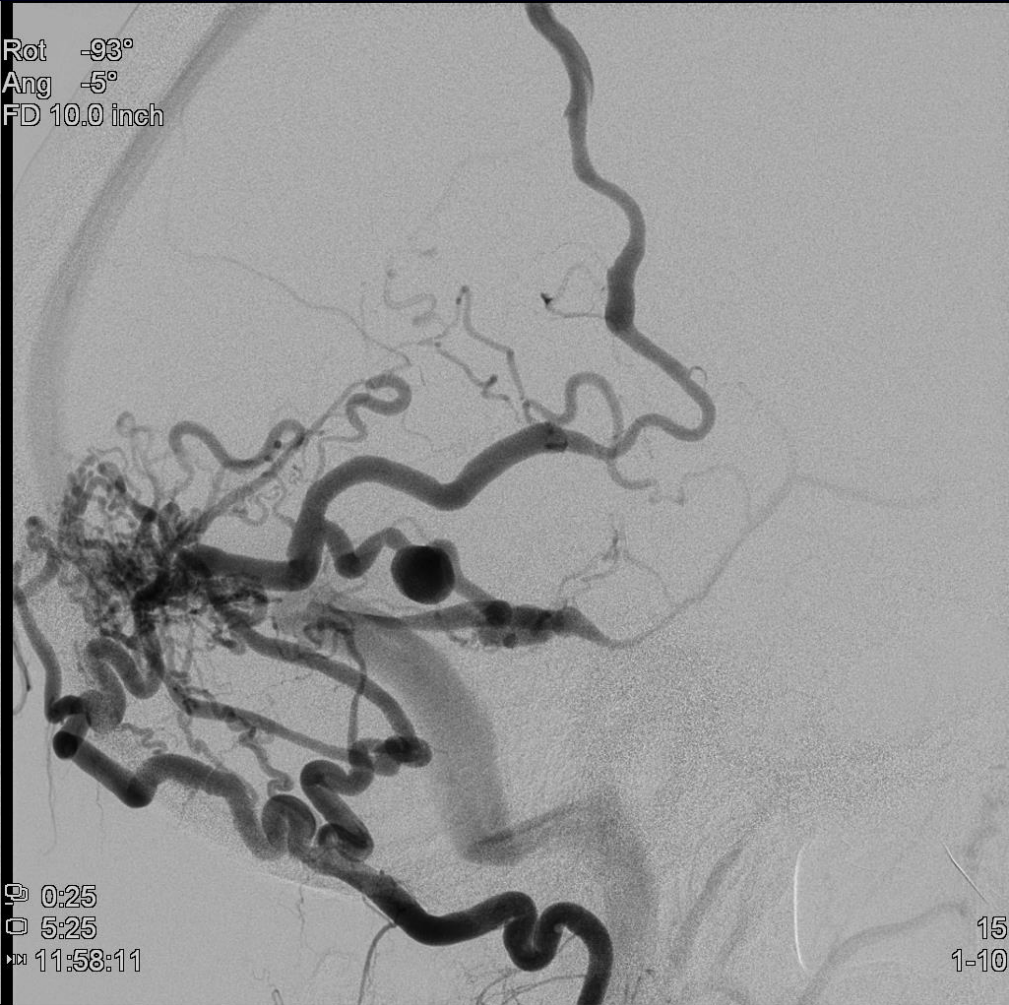

Rot -2°
Ang +3°
FD 13.0 inch



0:00
0:50
11:58:11

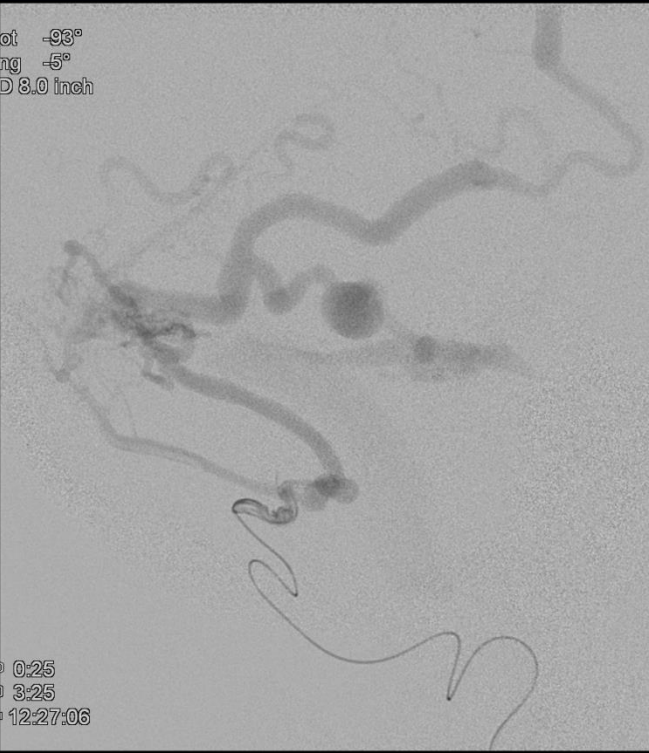
Rot -93°
Ang -5°
FD 10.0 inch



0:25
0:55
11:58:11

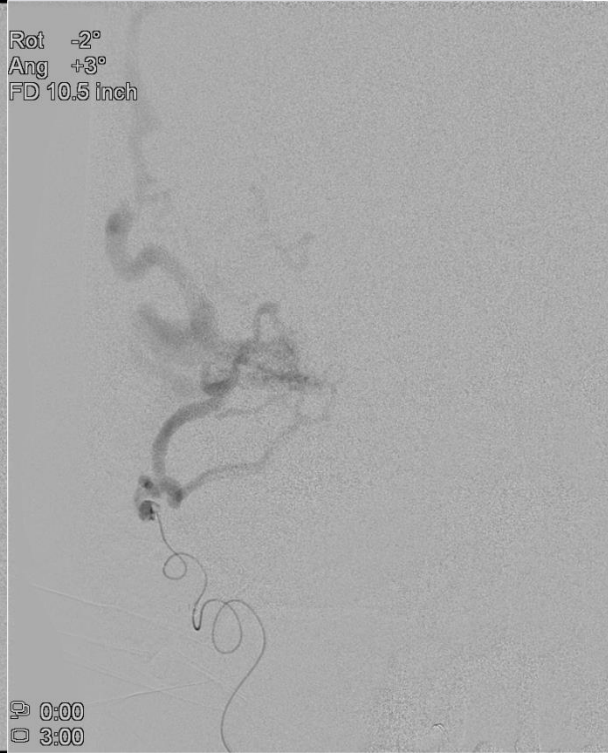
15
1-10

Rot -93°
Ang -5°
FD 8.0 inch



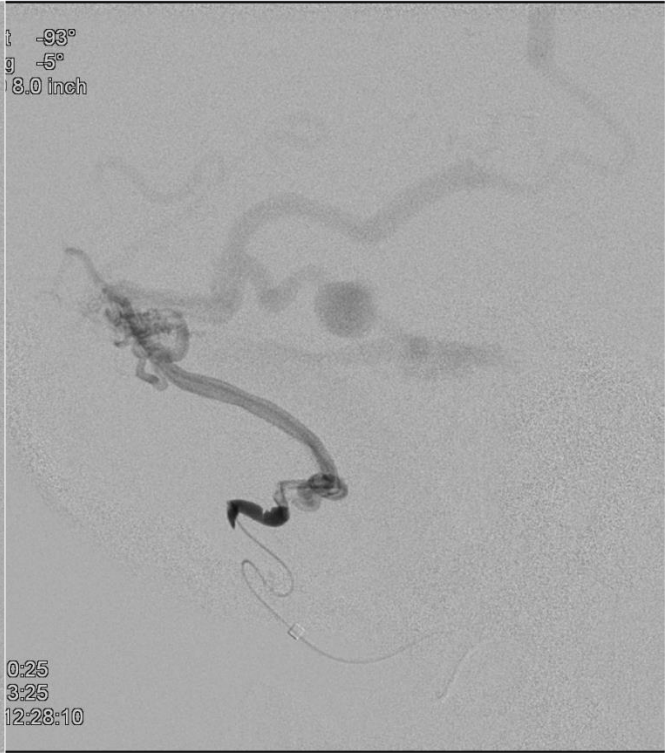
0:25
3:25
12:27:06

Rot -2°
Ang +3°
FD 10.5 inch



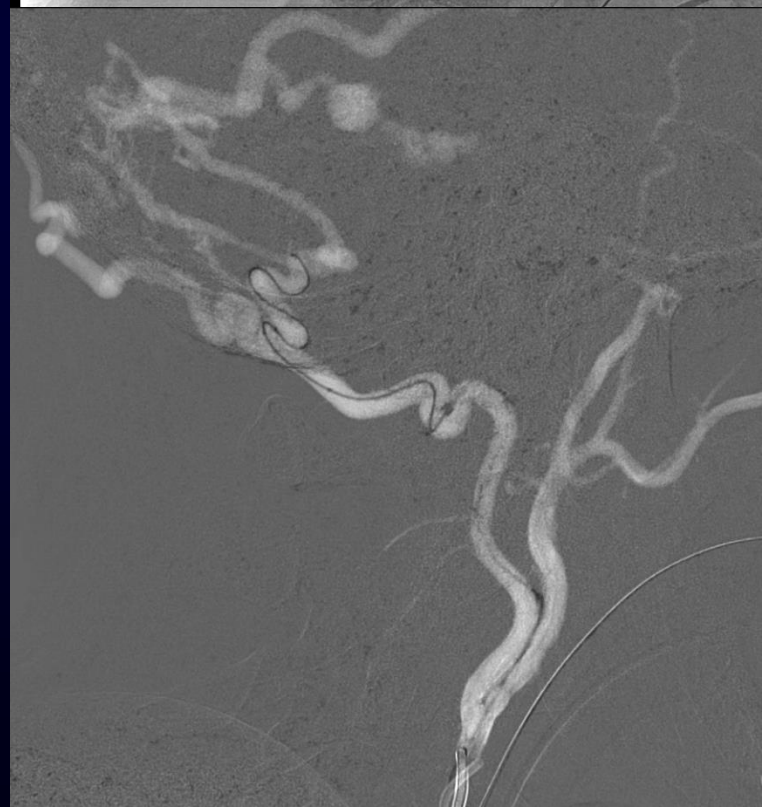
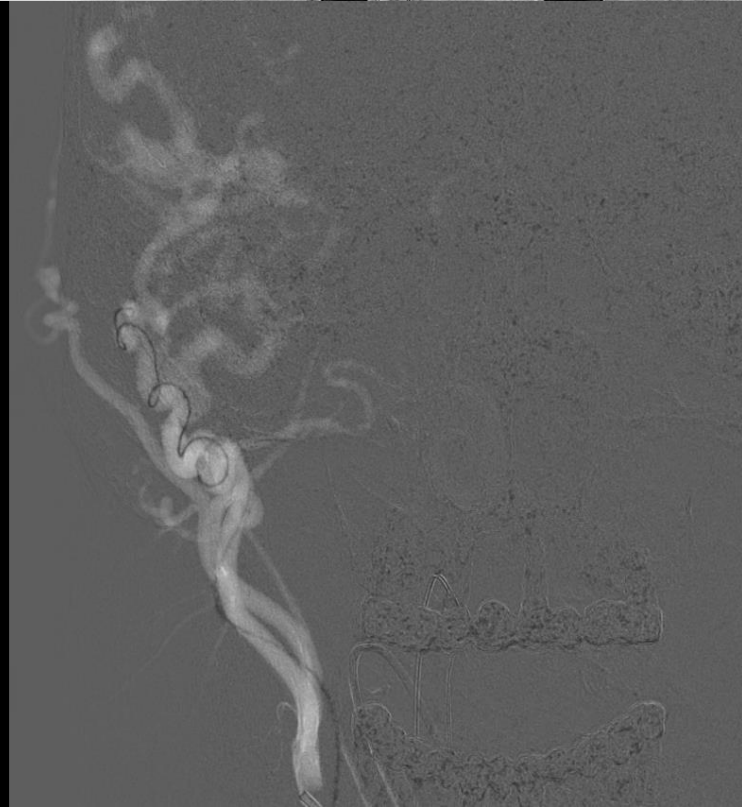
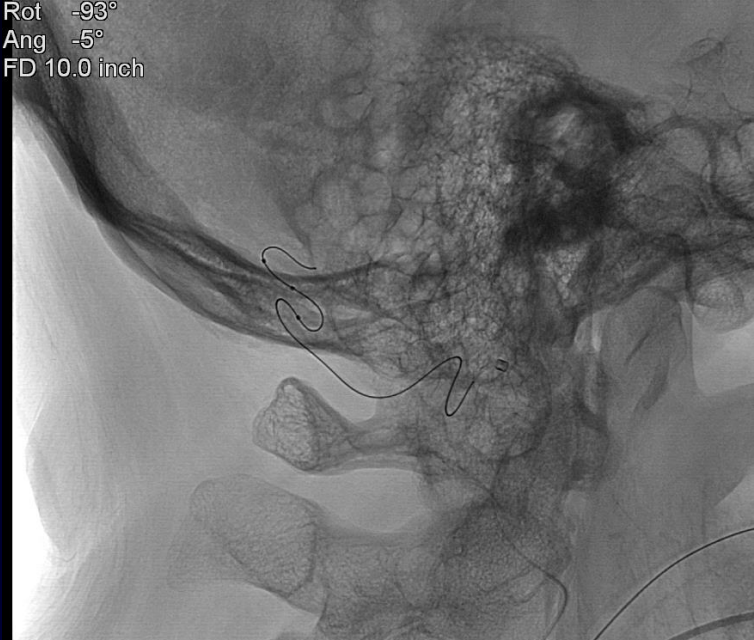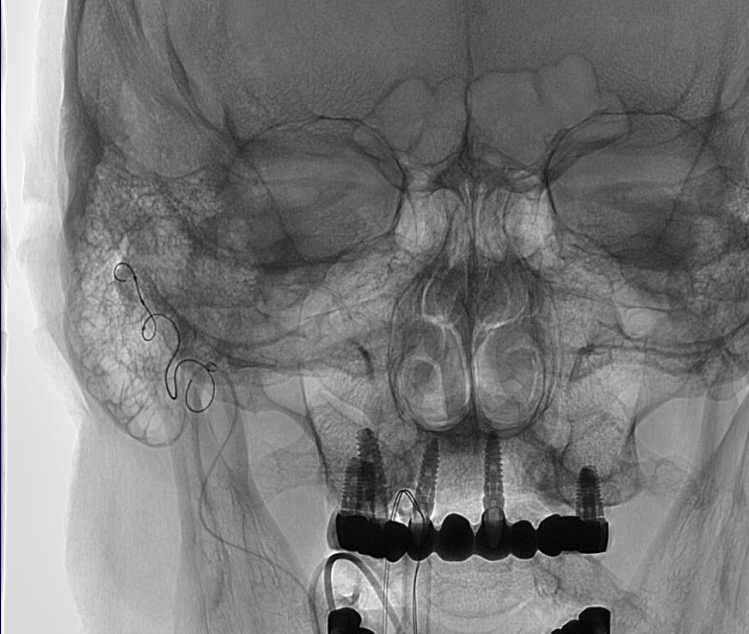
0:00
3:00

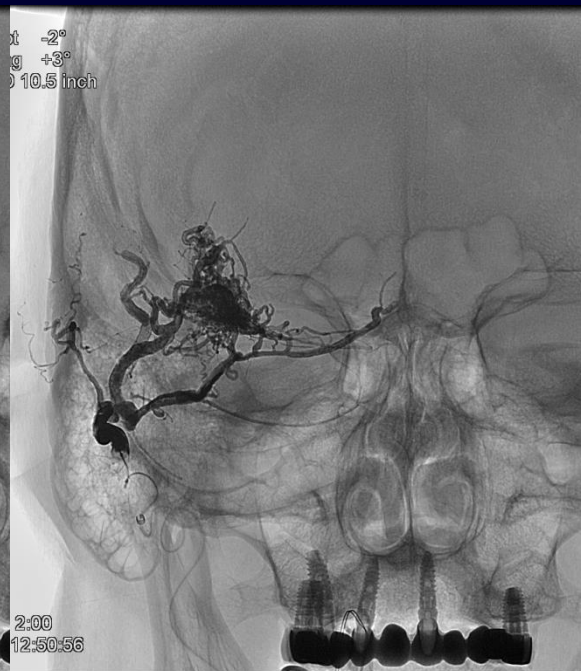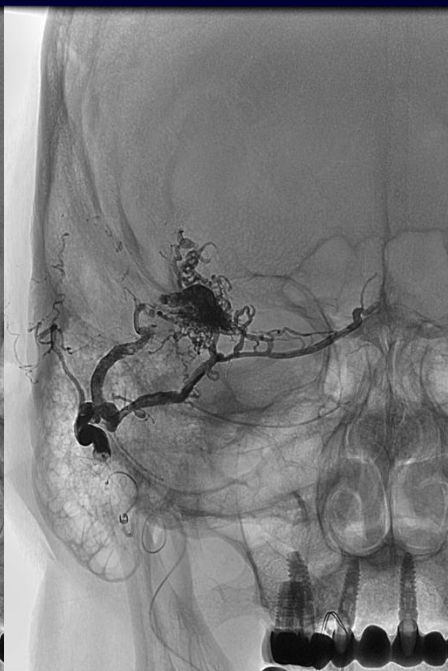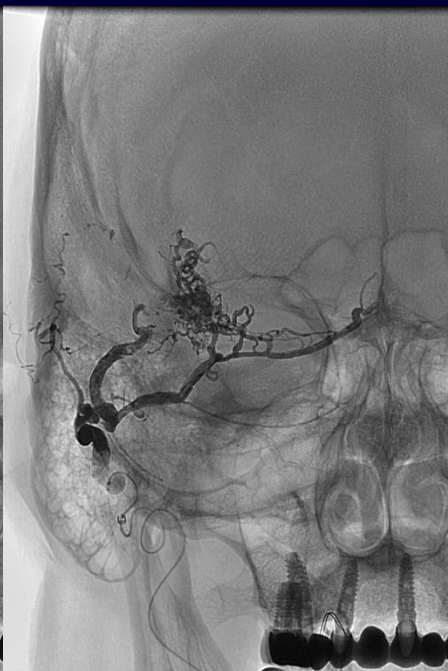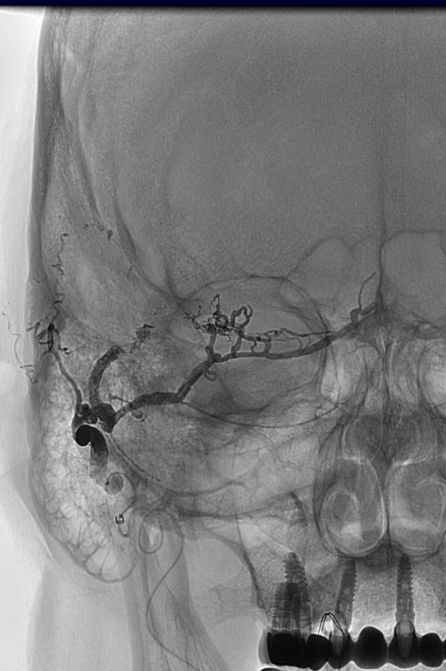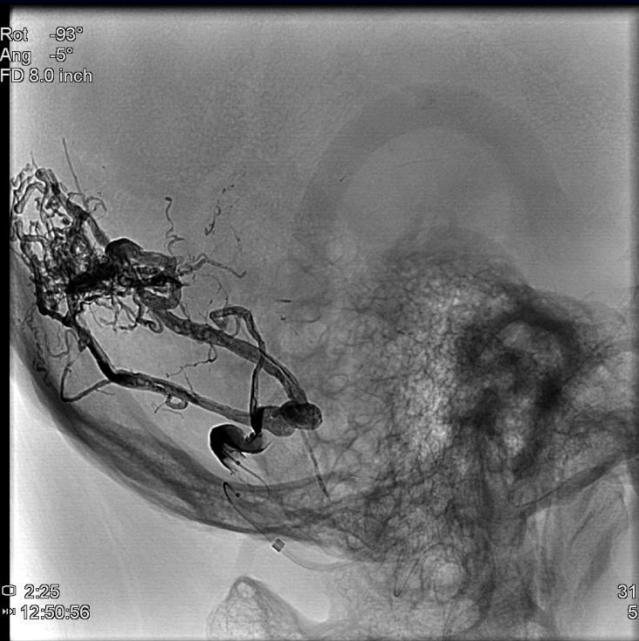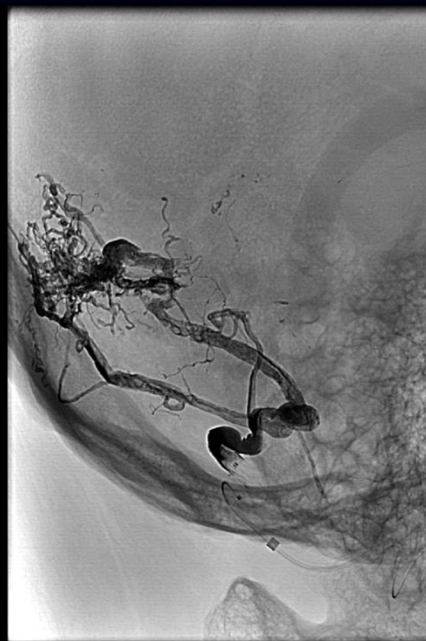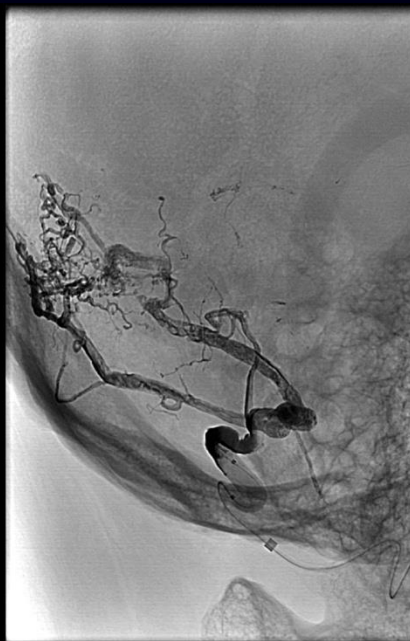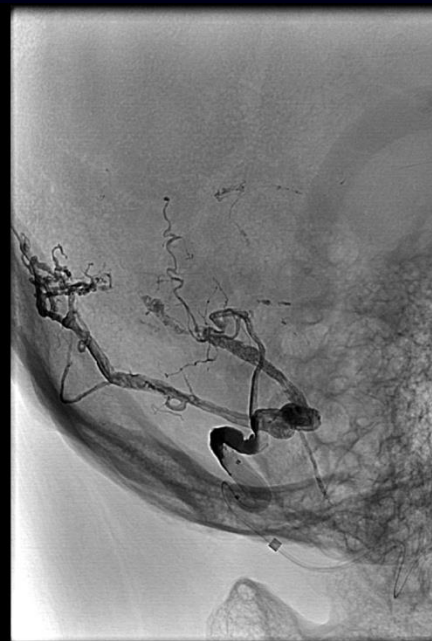Rot -93°
Ang -5°
FD 8.0 inch

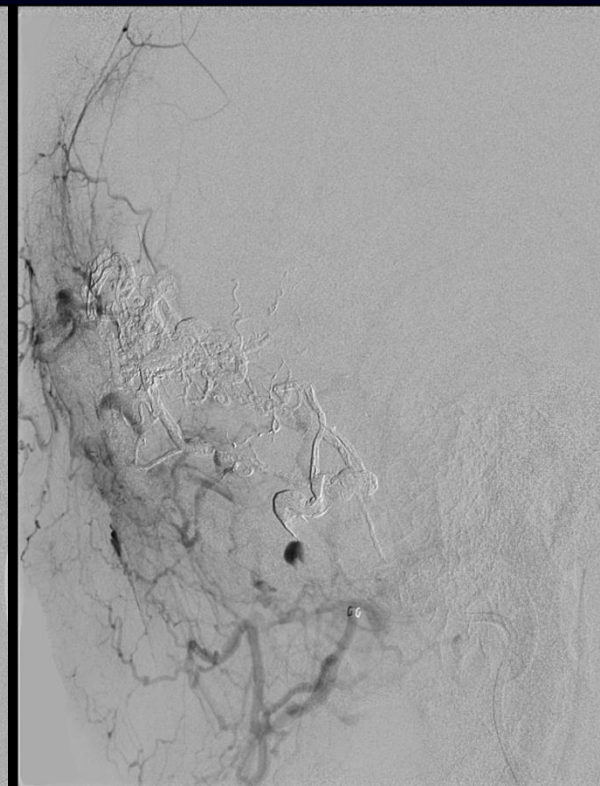
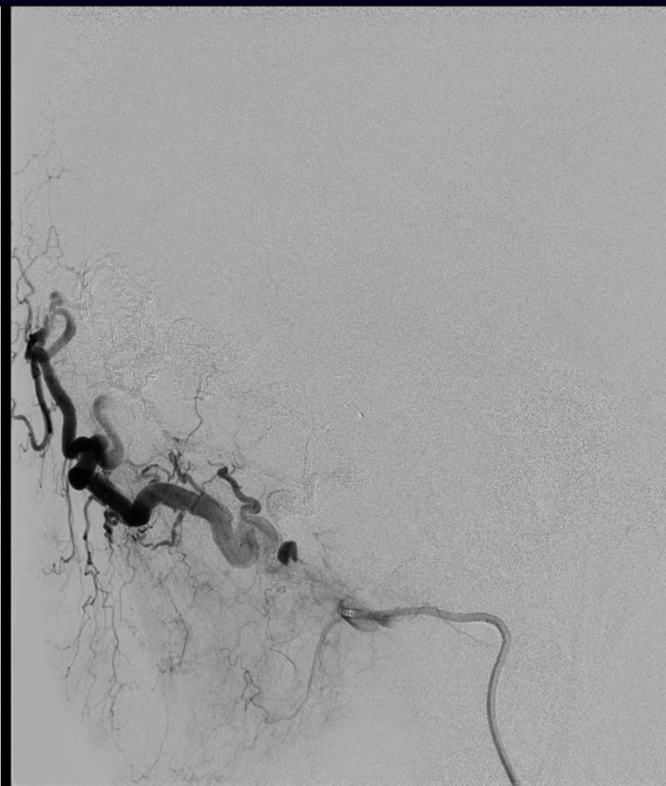
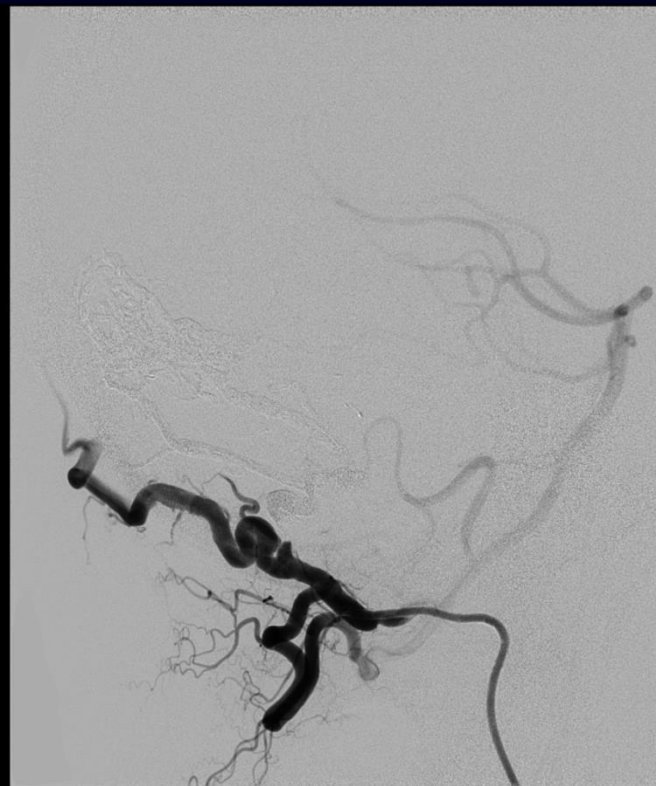

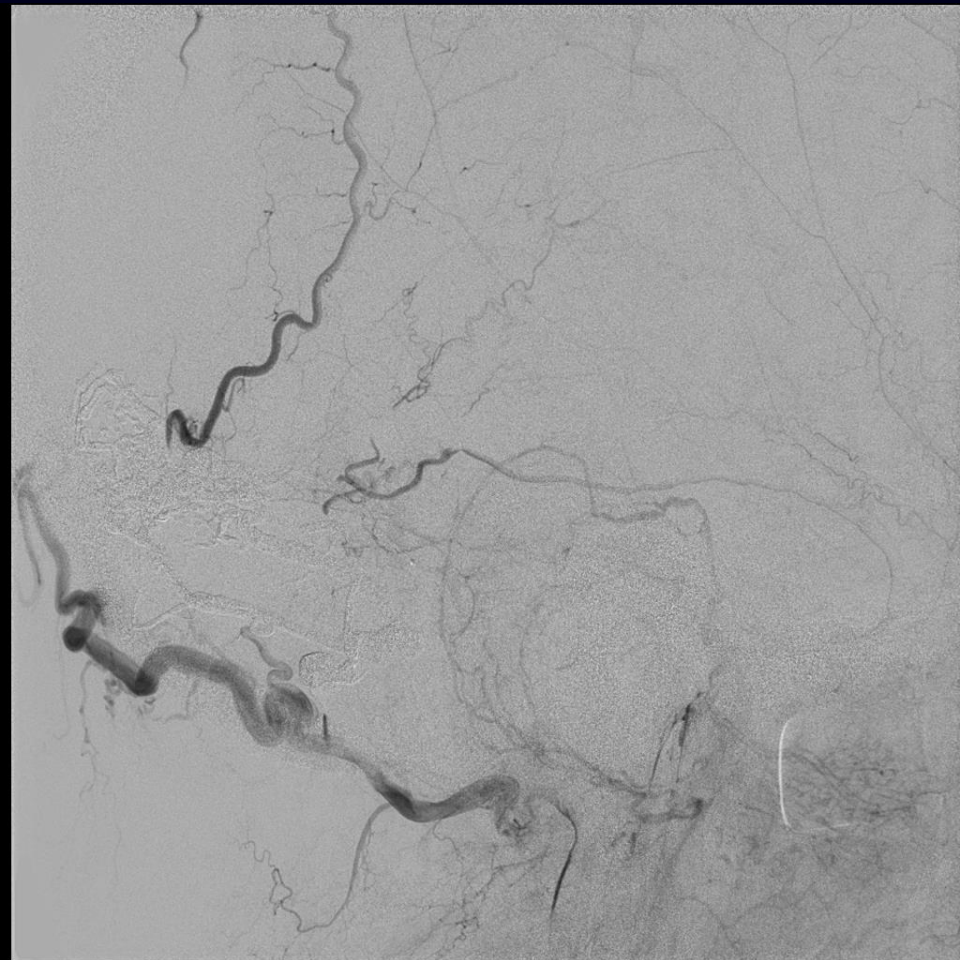
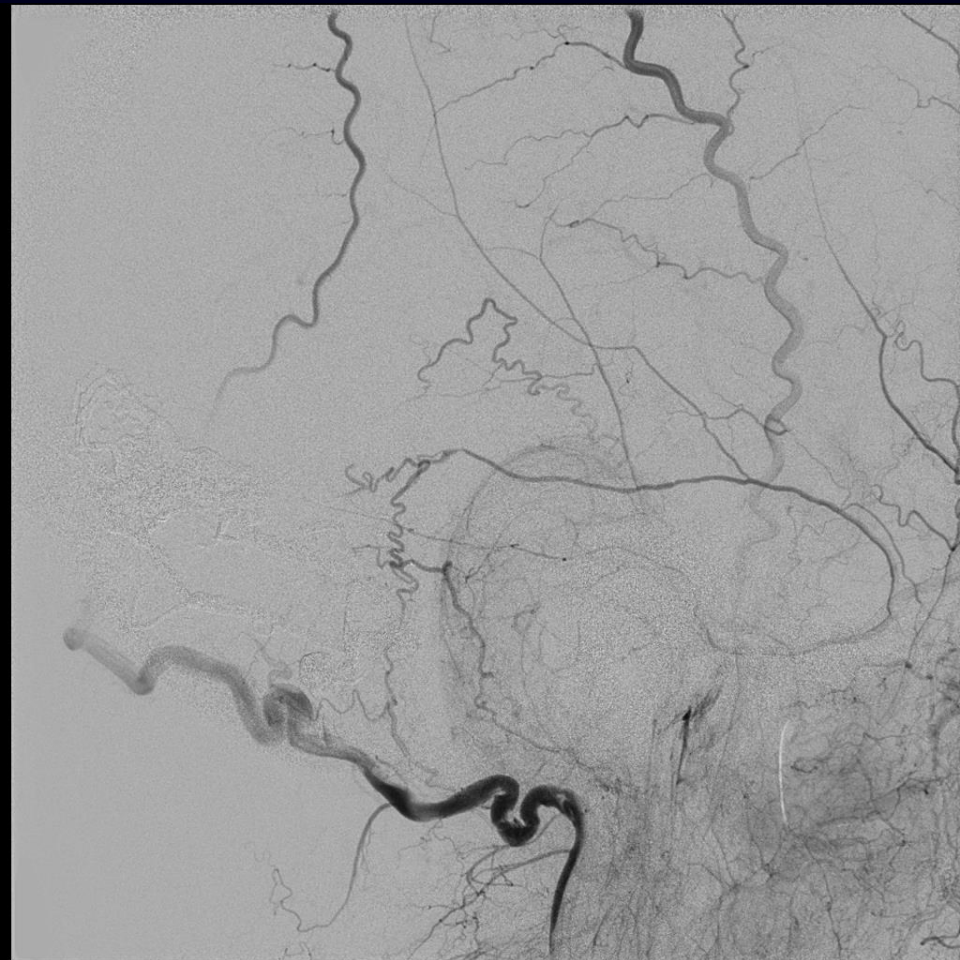
0:25
3:25
12:28:10

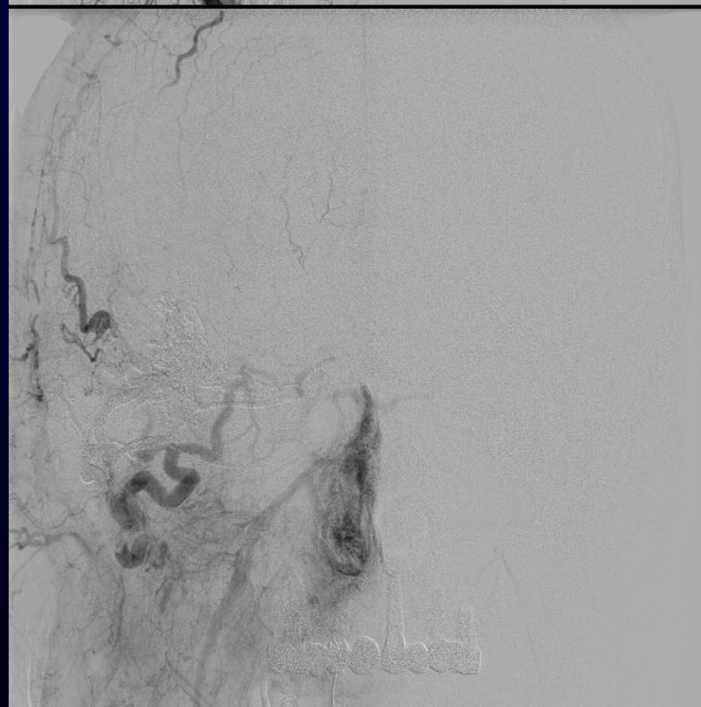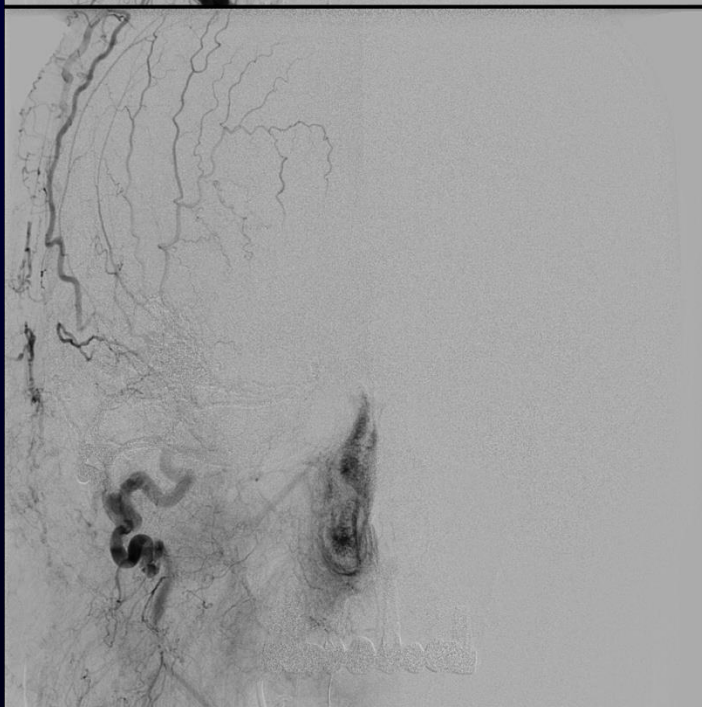
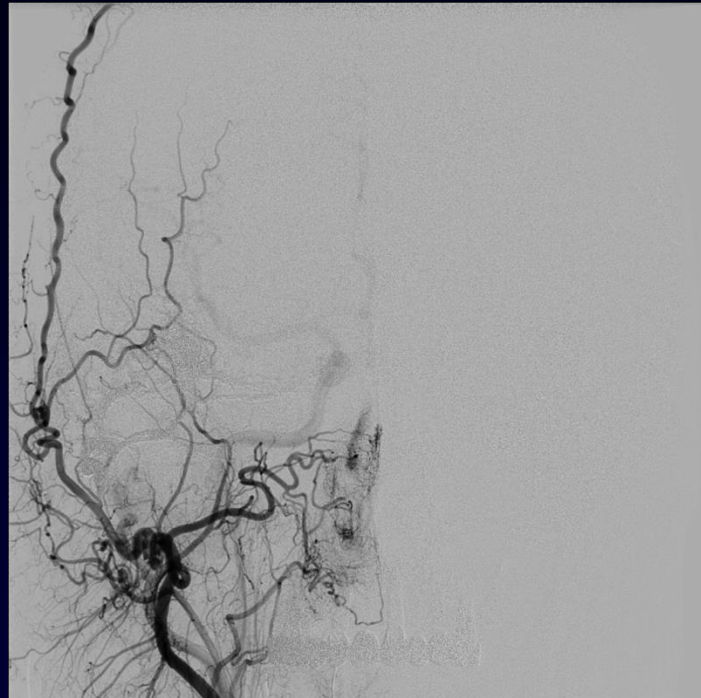
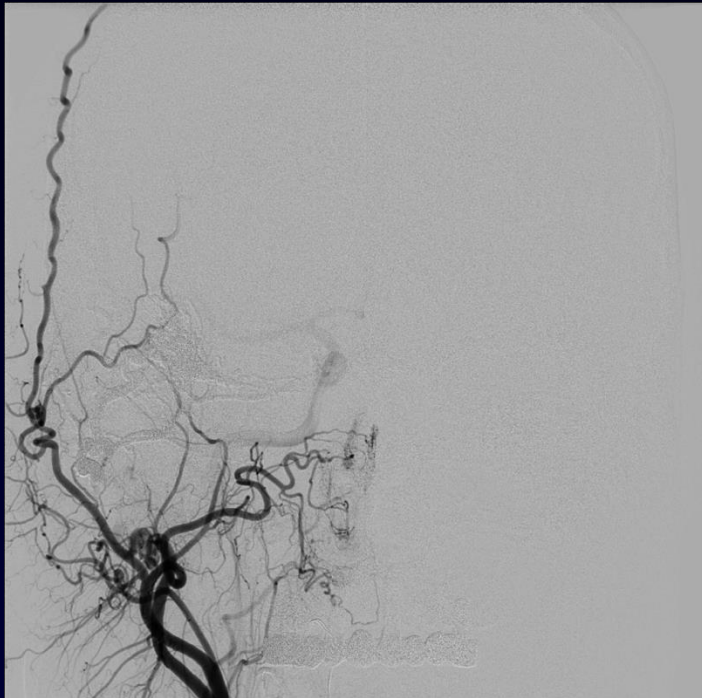Rot -93°
Ang -5°
FD 10.0 inch

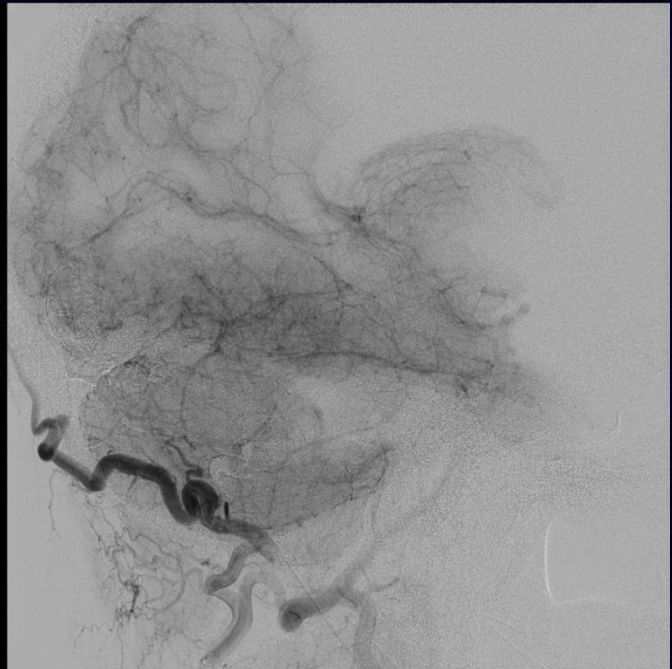
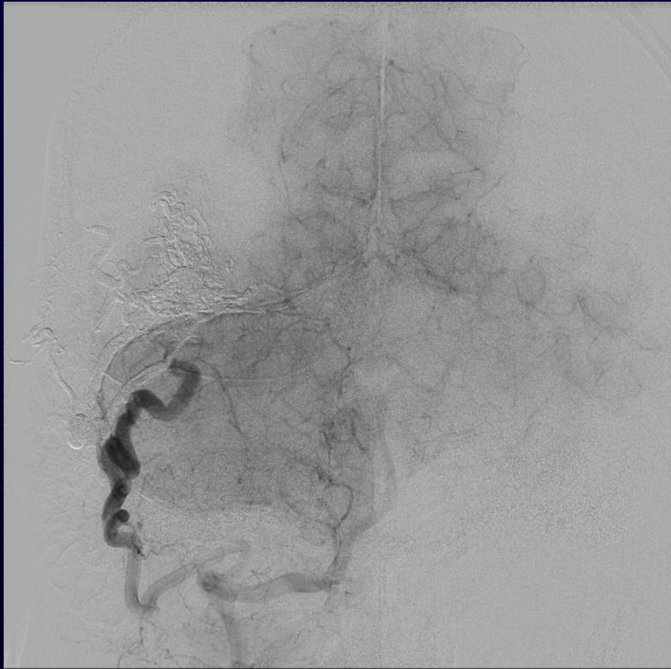
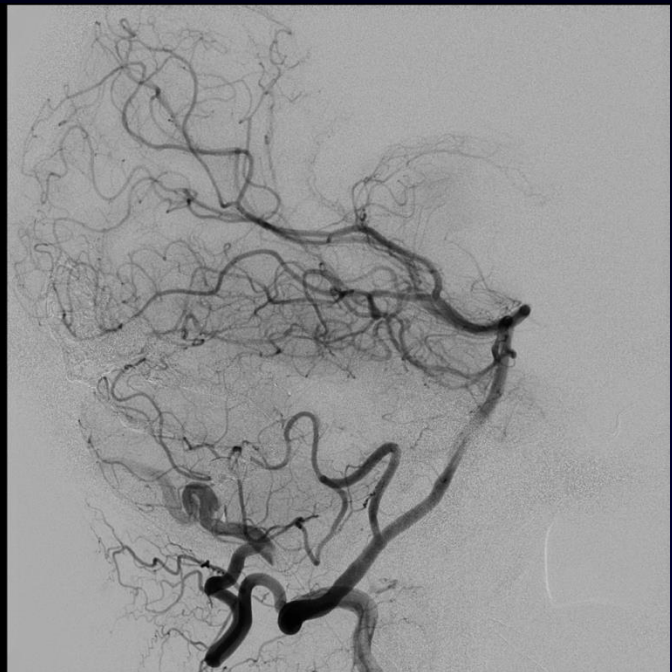
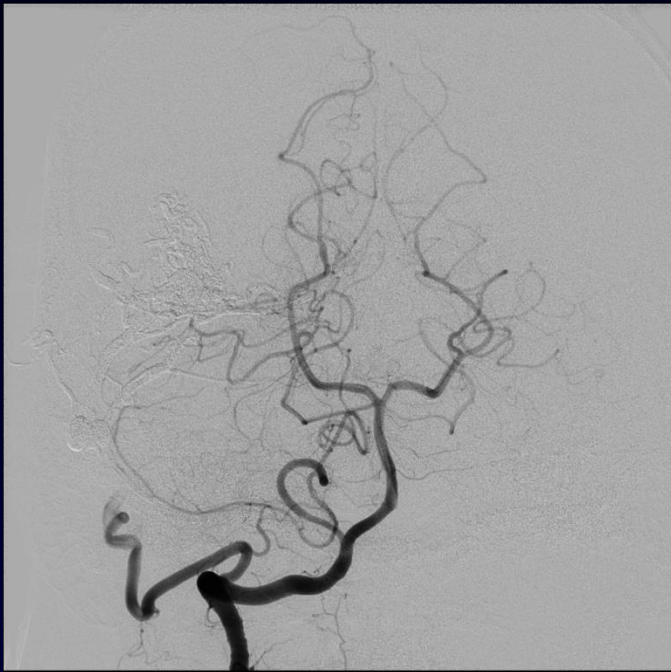

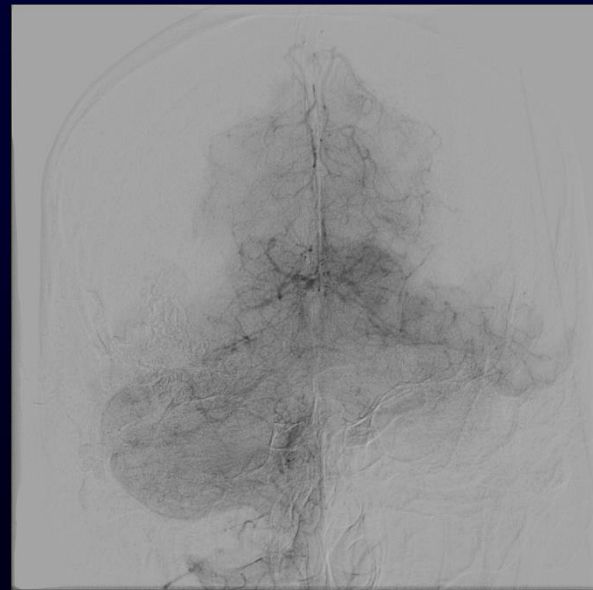
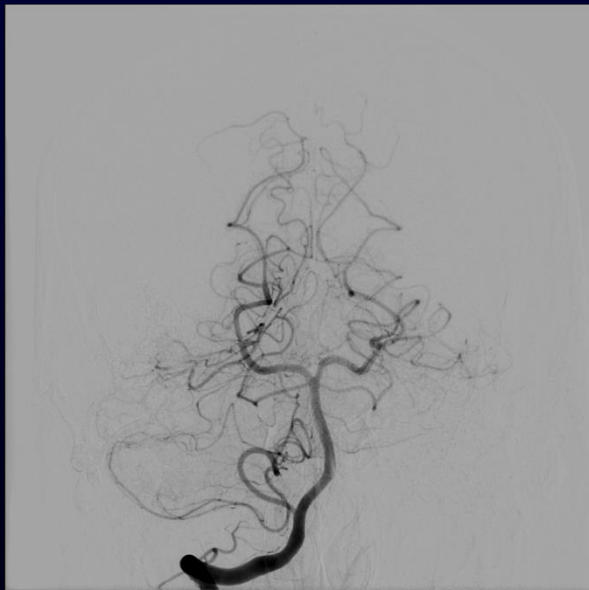
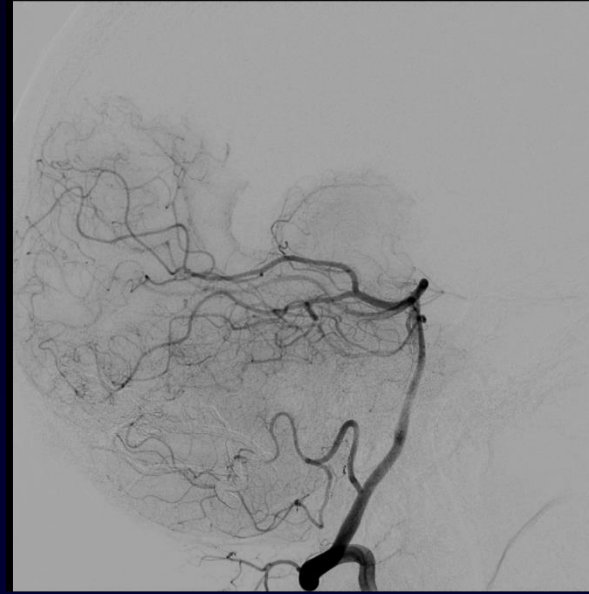



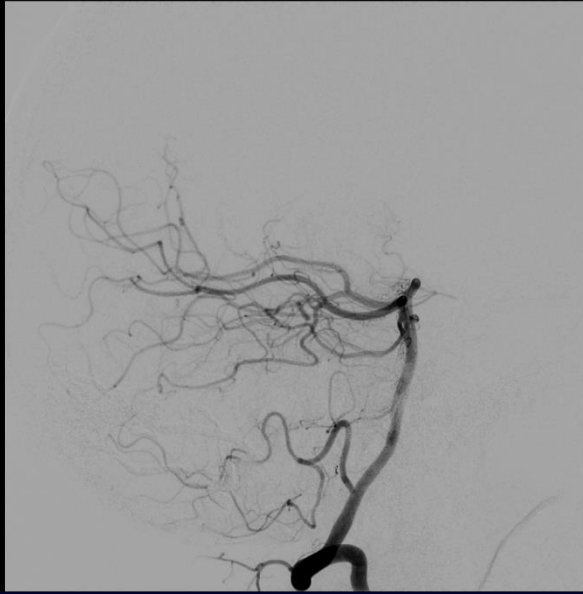
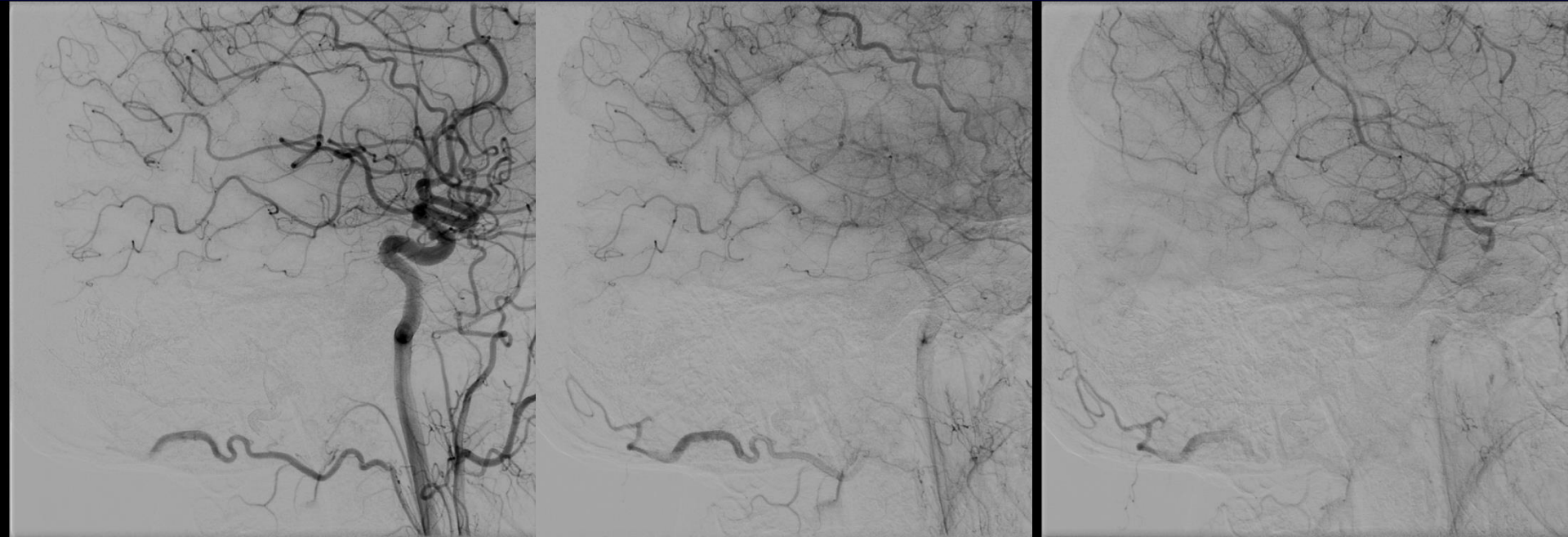




1-year follow up

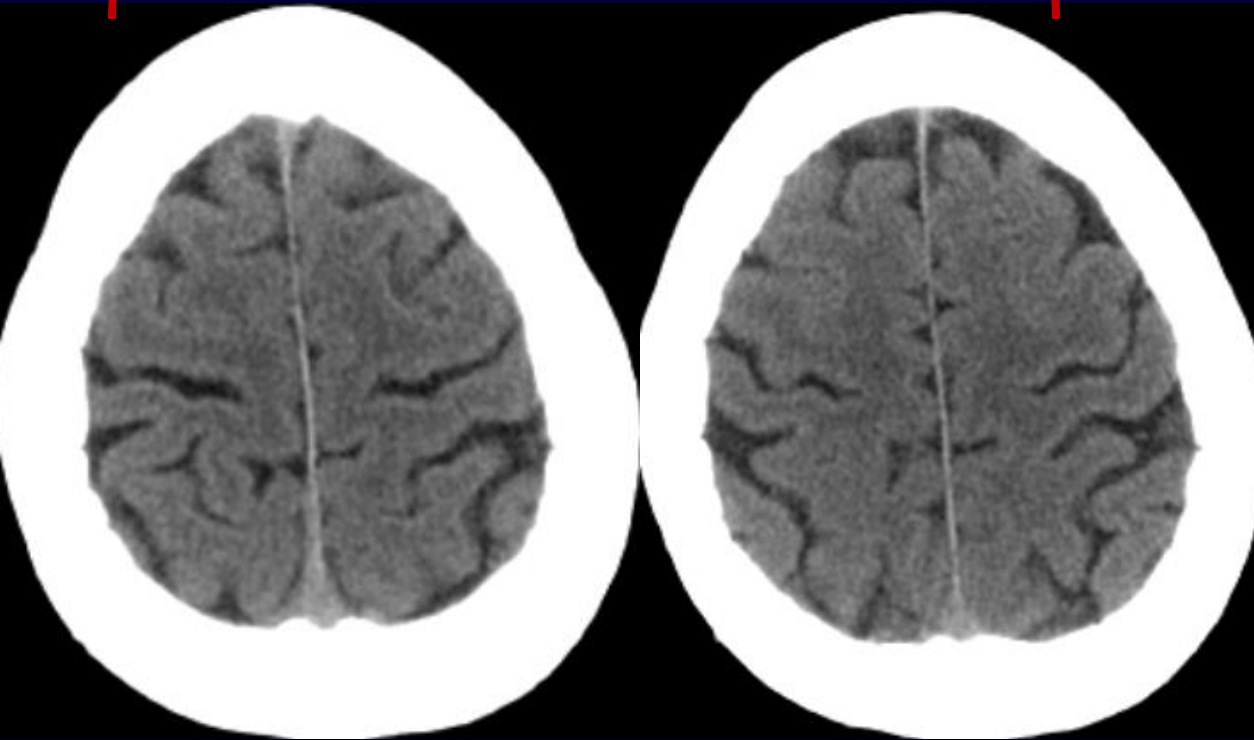
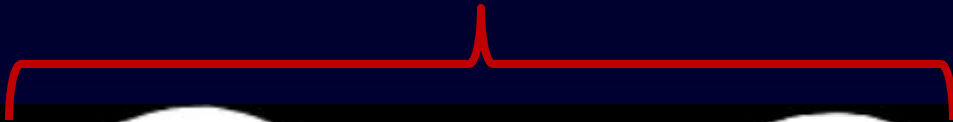


1-year follow up

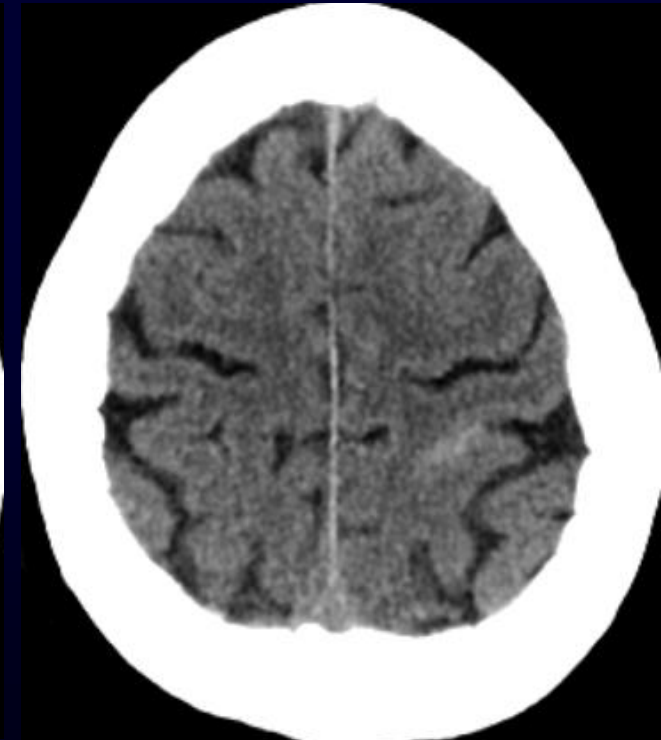


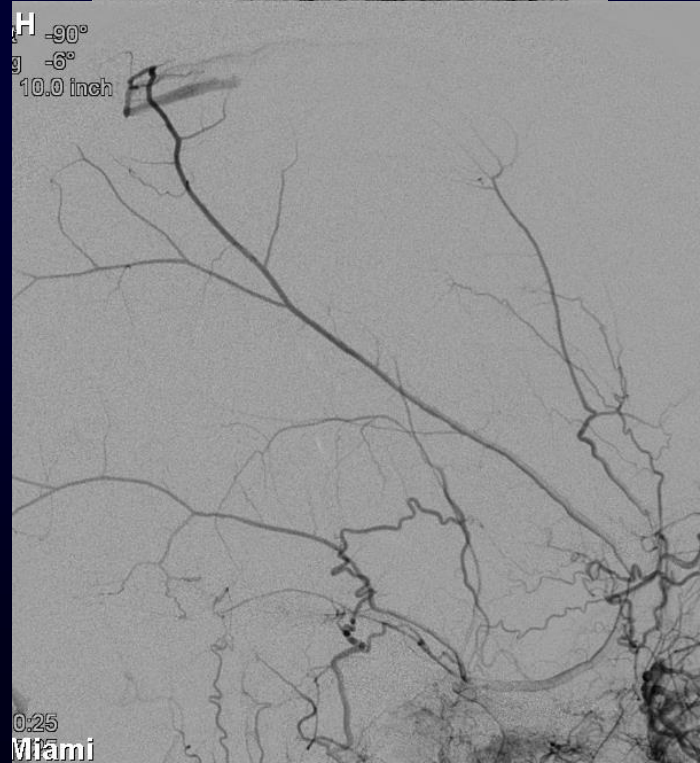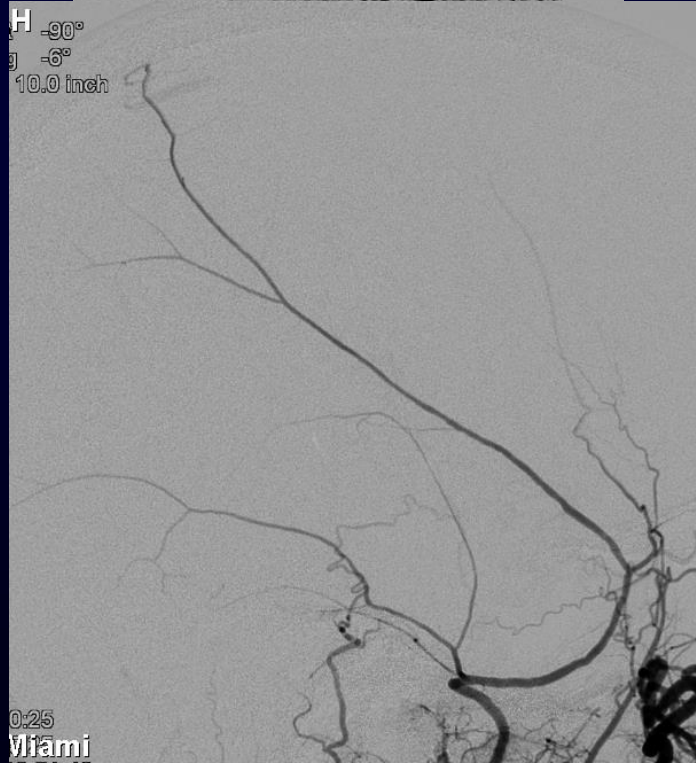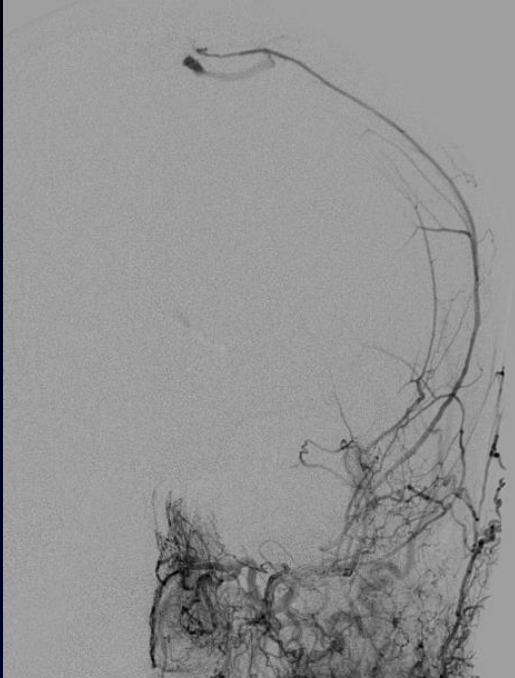
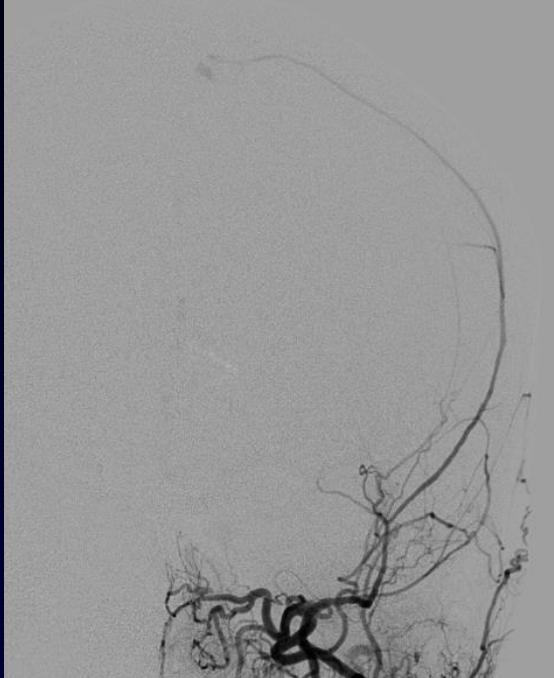62 yo F presenting to ED with sudden onset severe HA

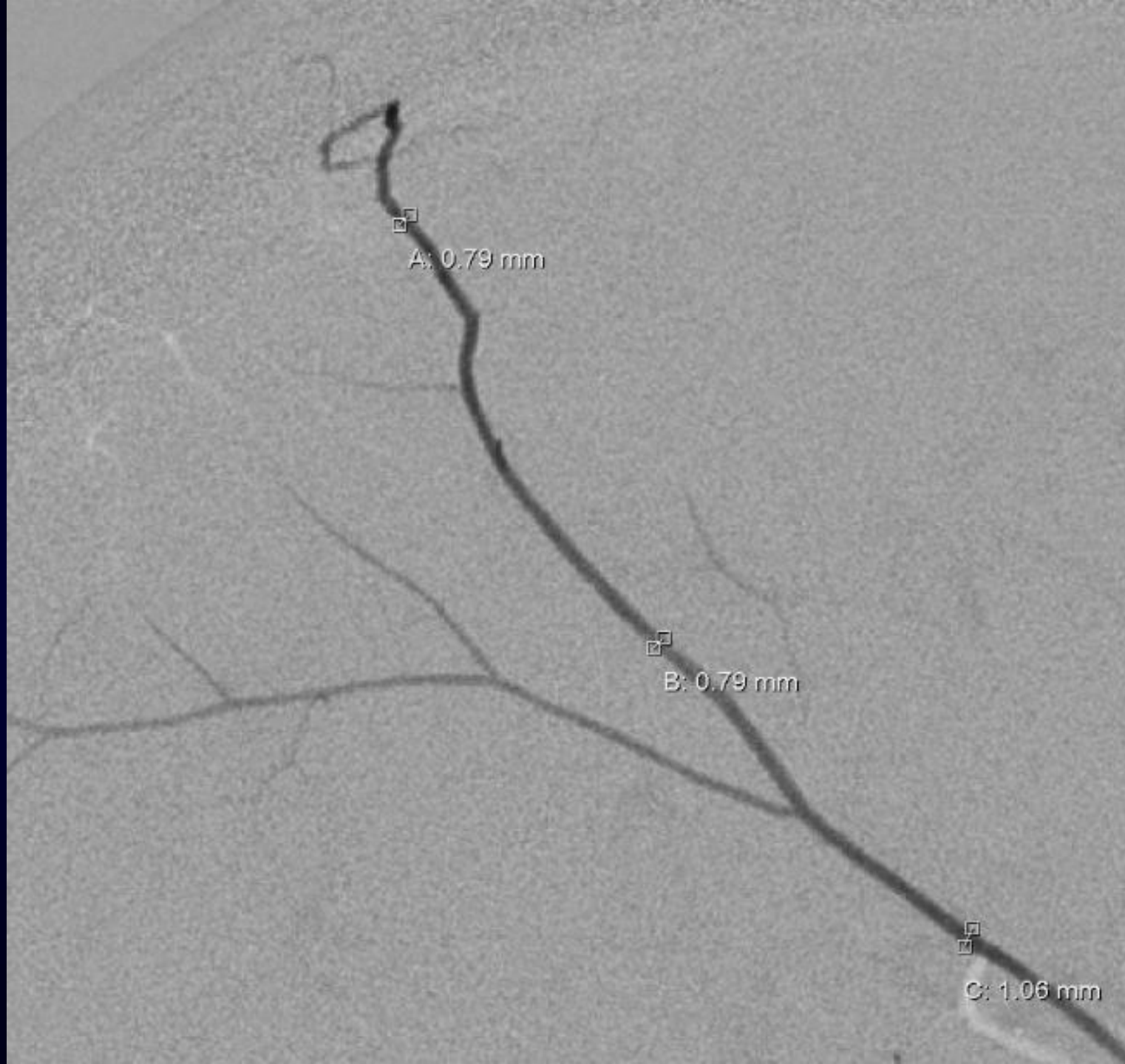
CT at initial presentation



HA continue to get worse; pt returns to ED 48h later



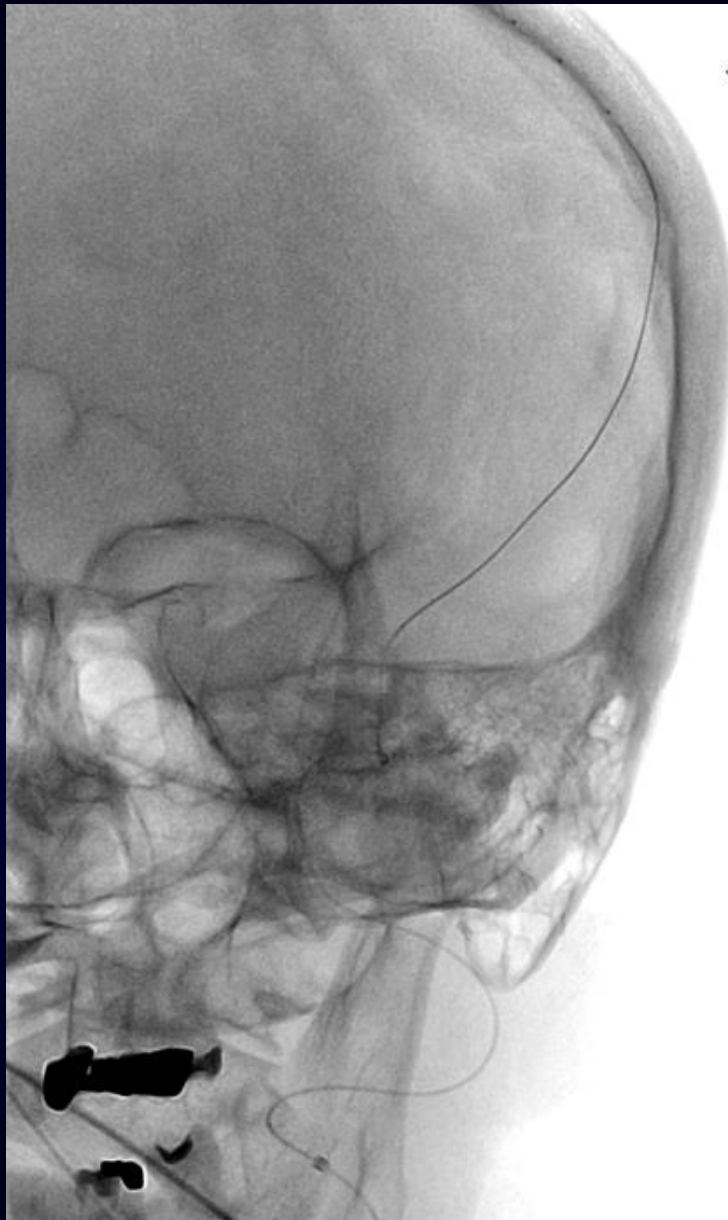




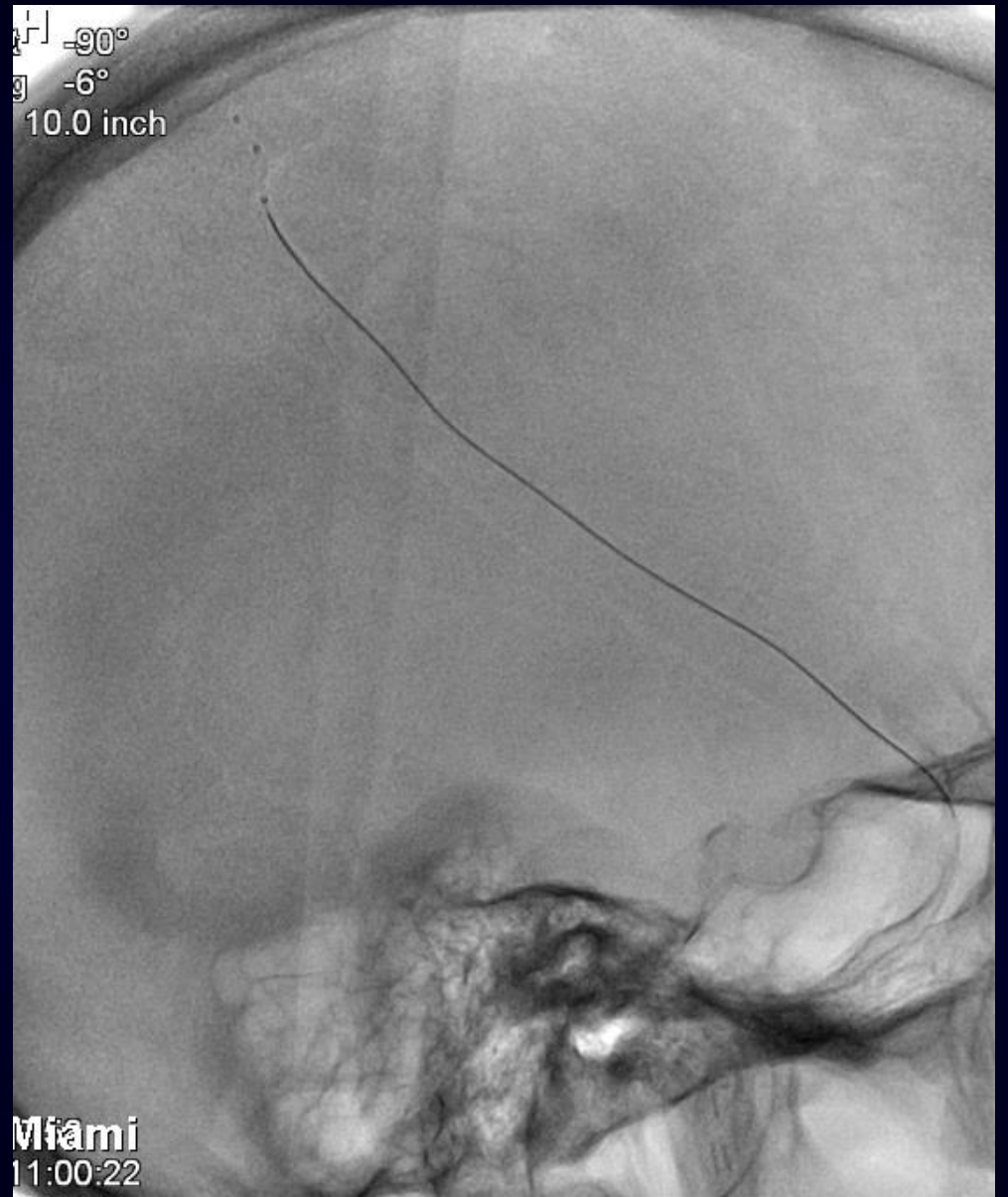
A: 0.79 mm

B: 0.79 mm

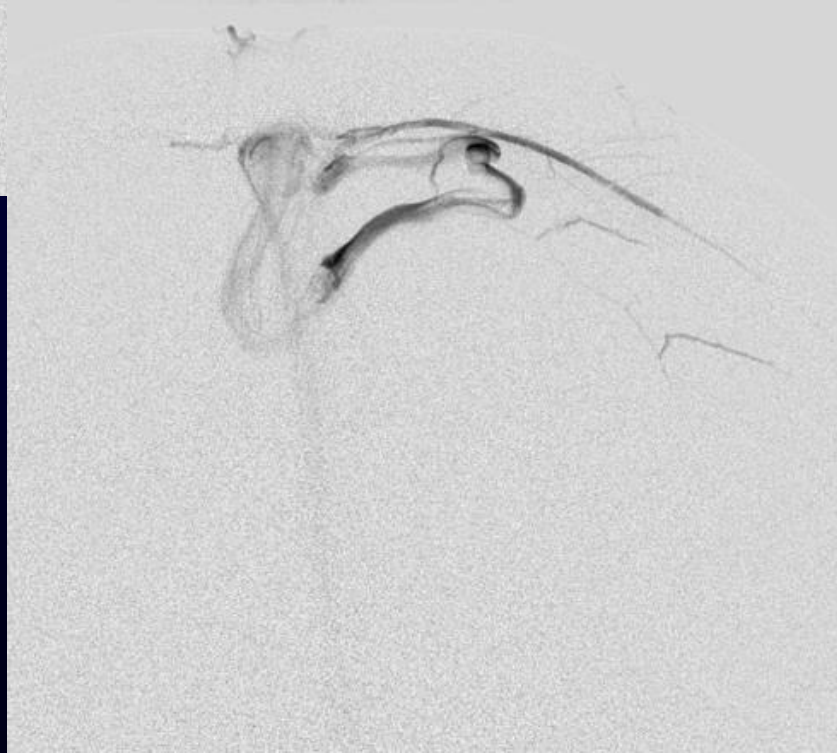
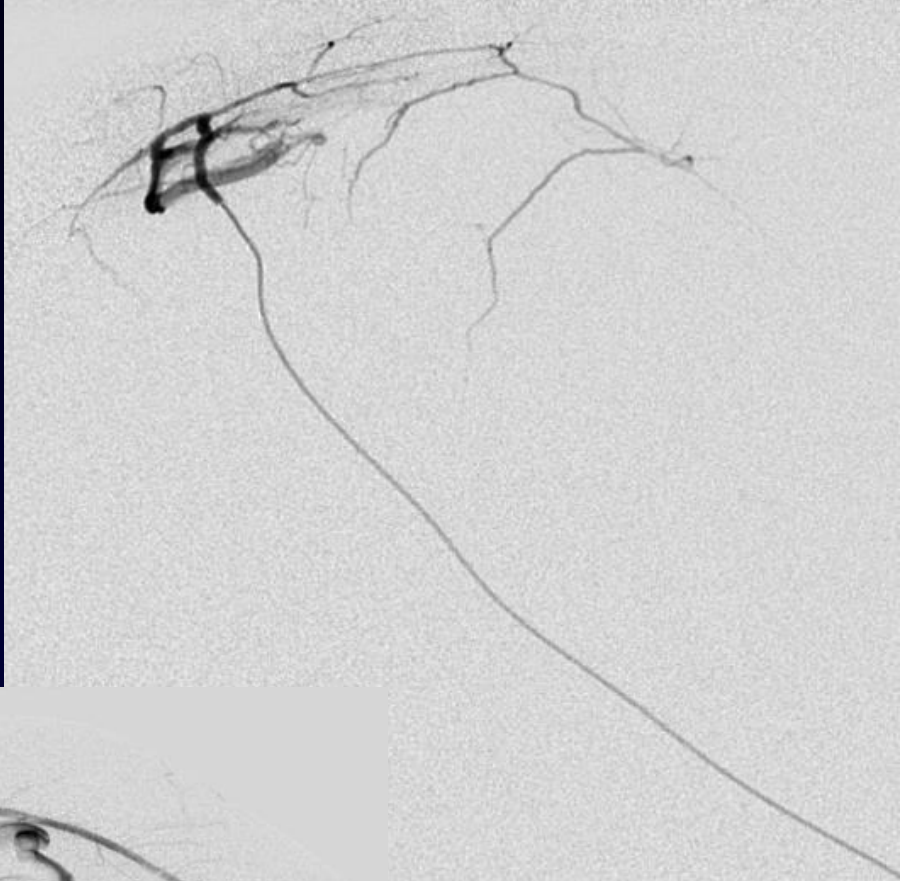
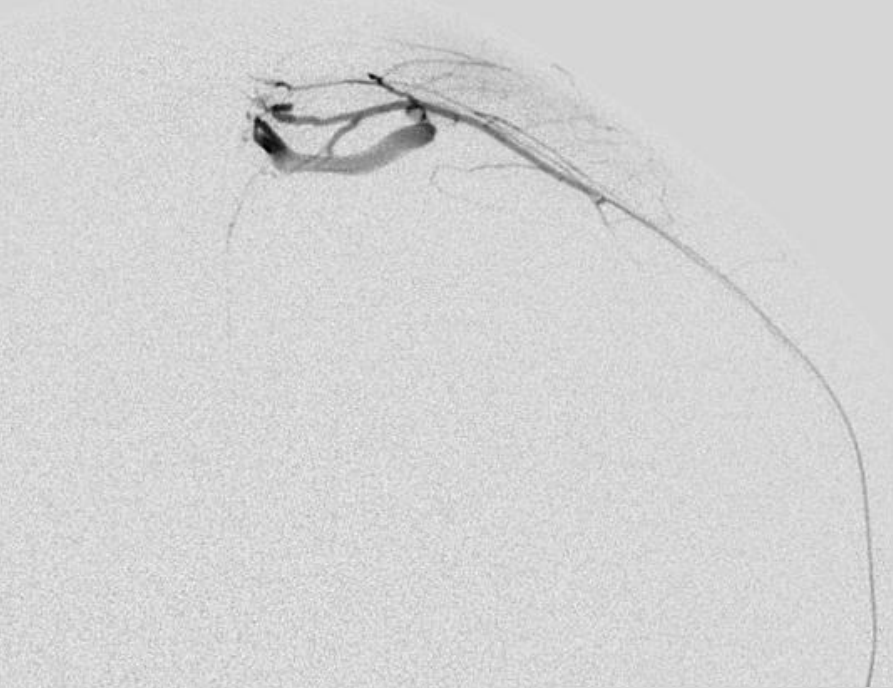
C: 1.06 mm



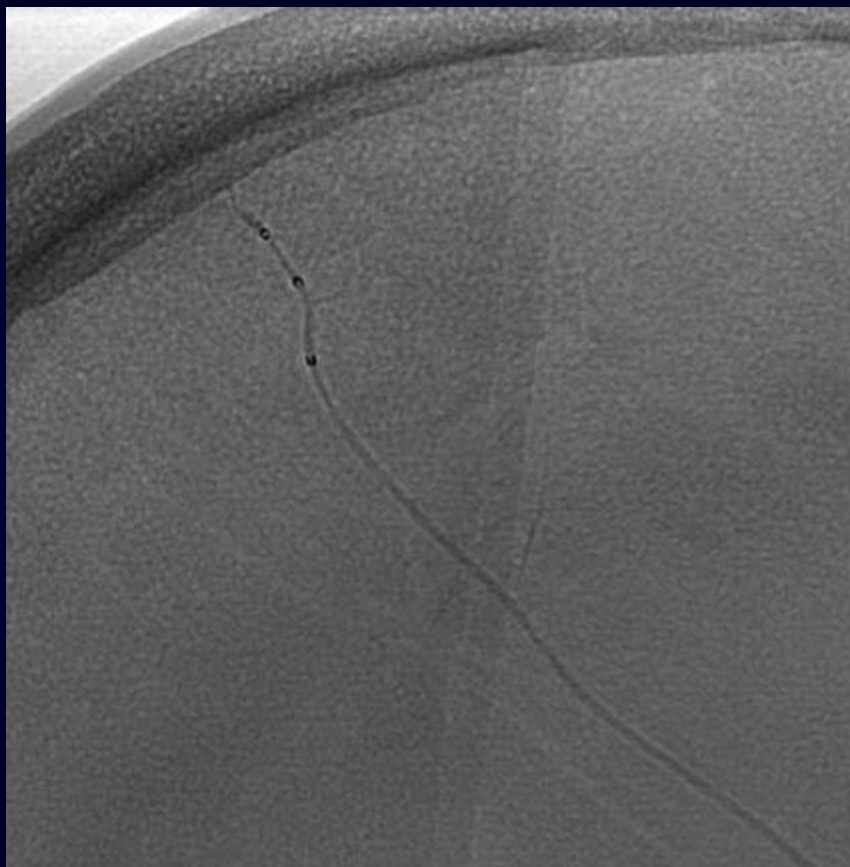
tr -90°
g -6°
10.0 inch



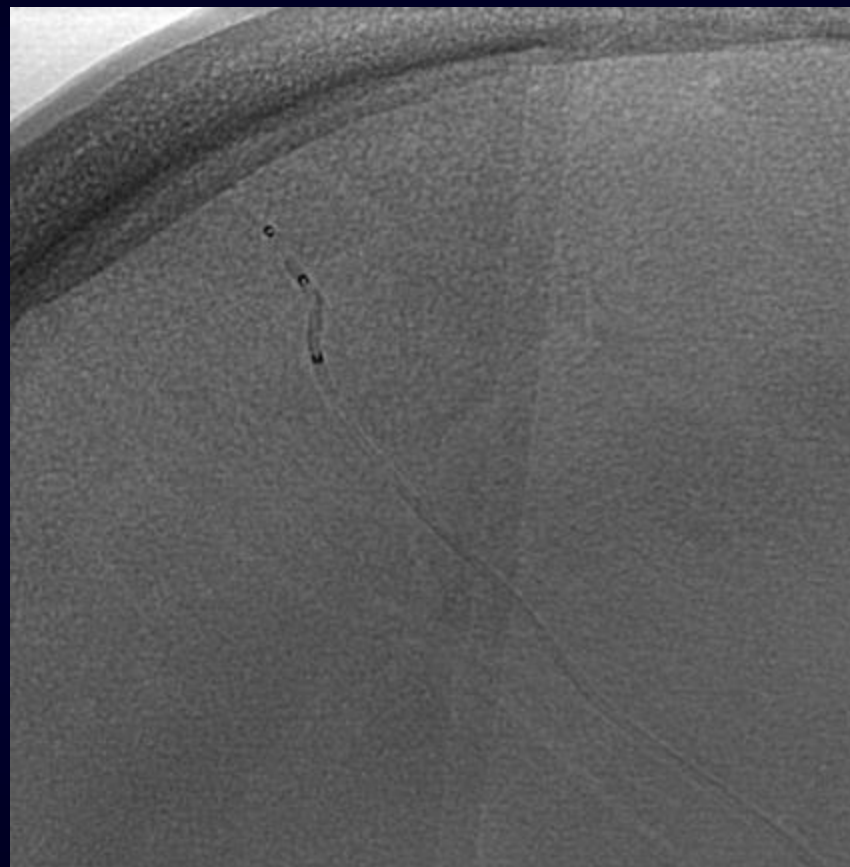
Miami
11:00:22

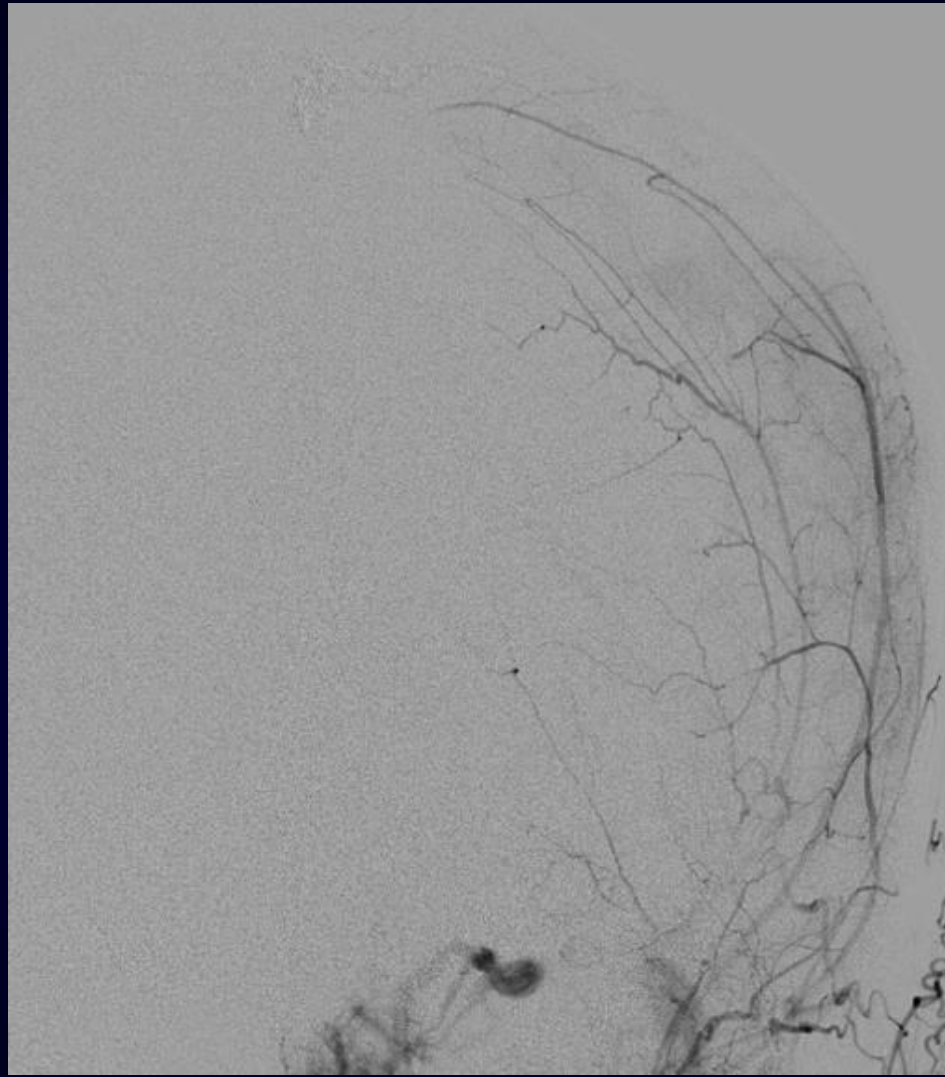
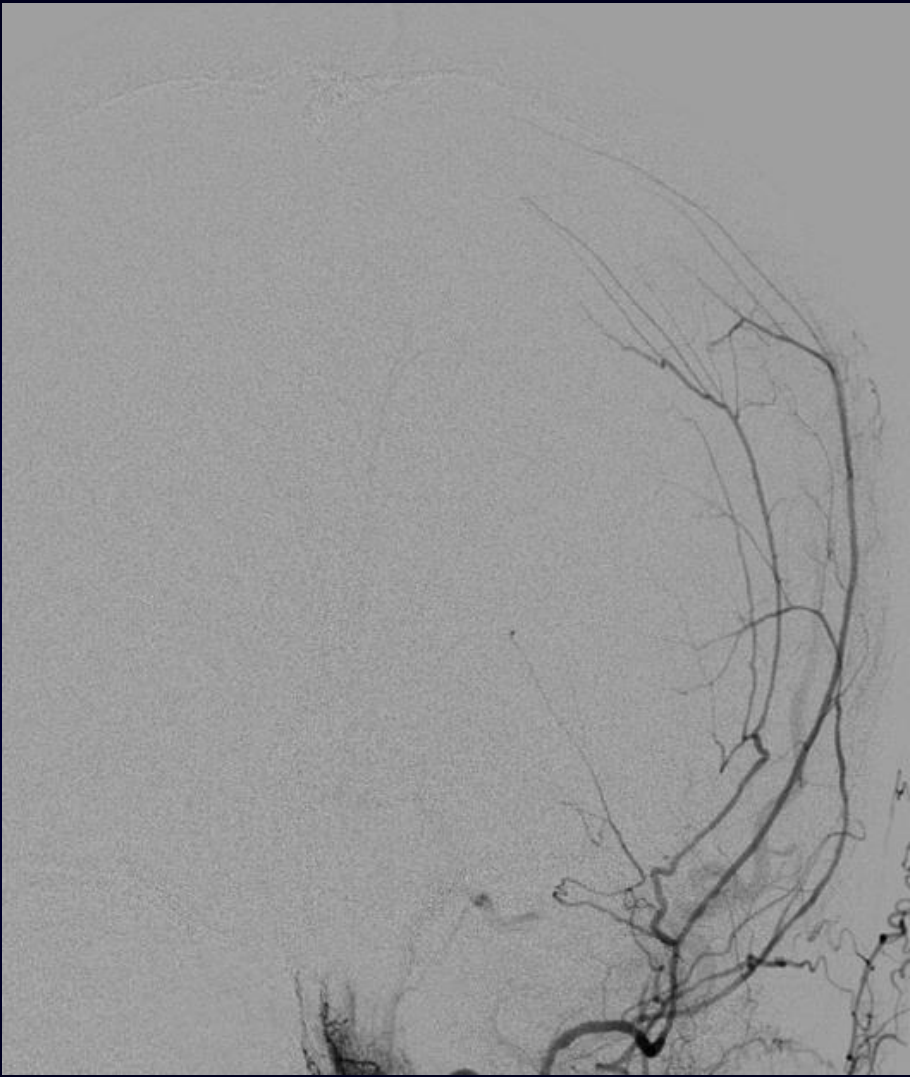


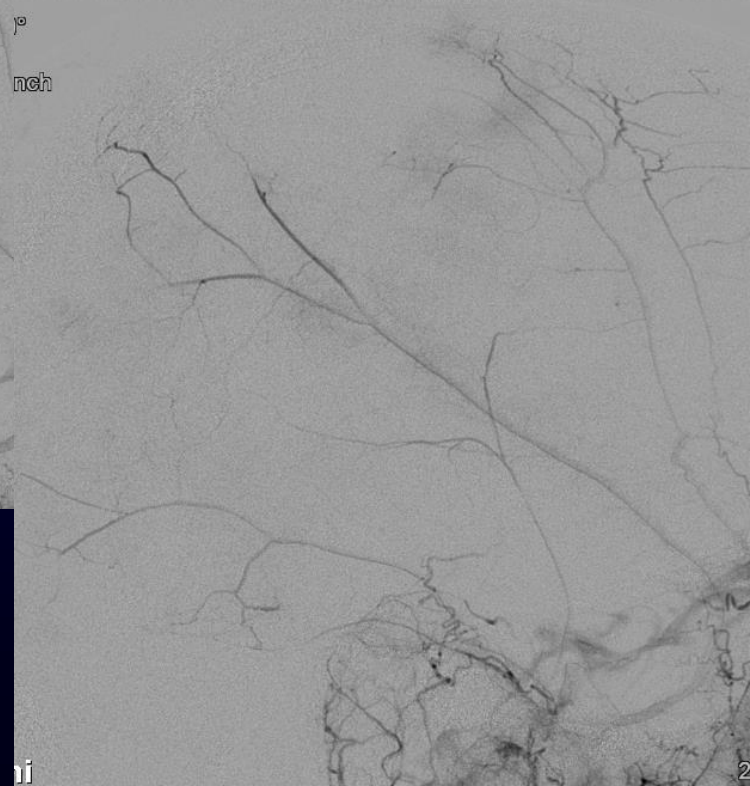
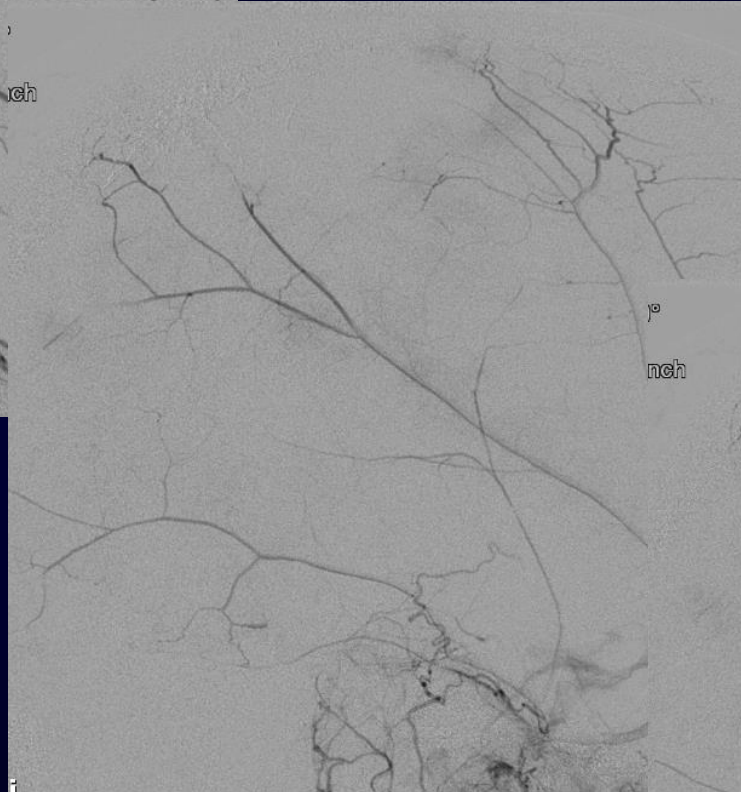
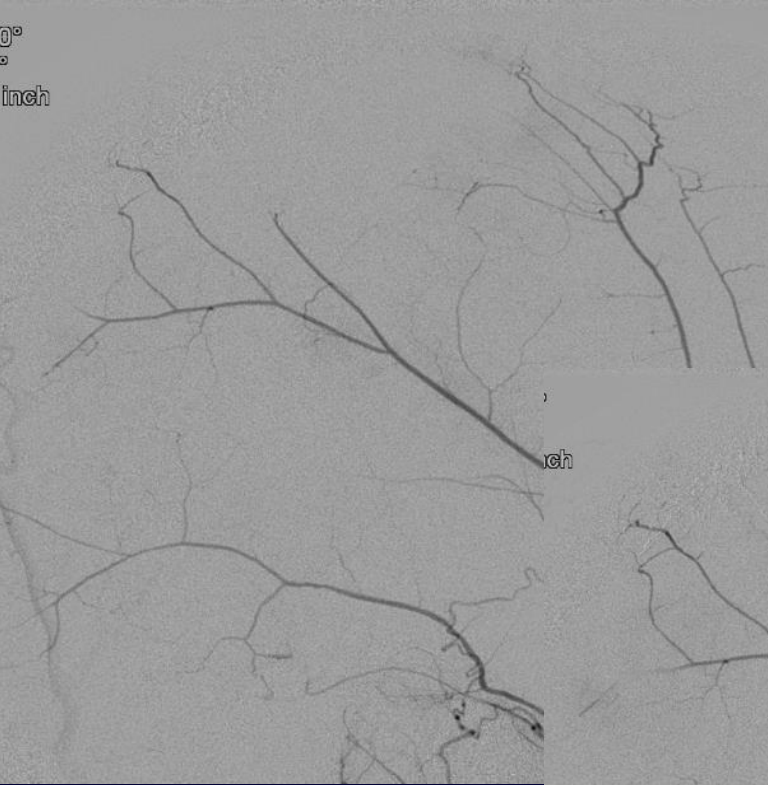
Pre-Inflation

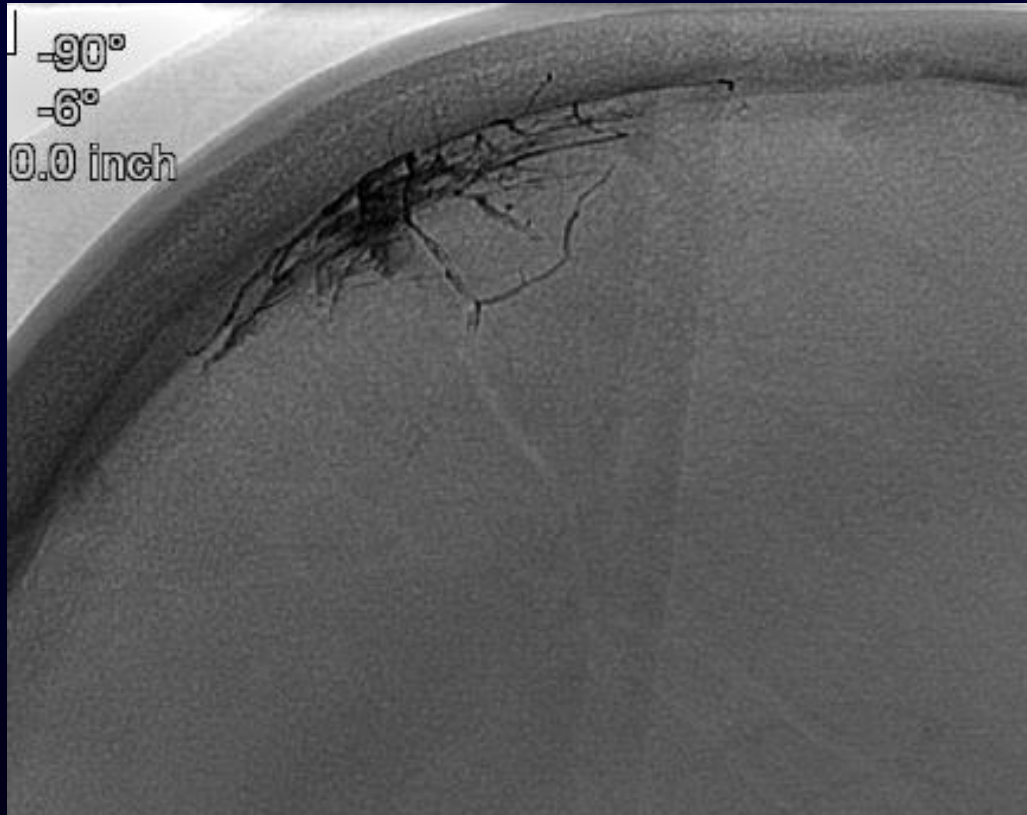
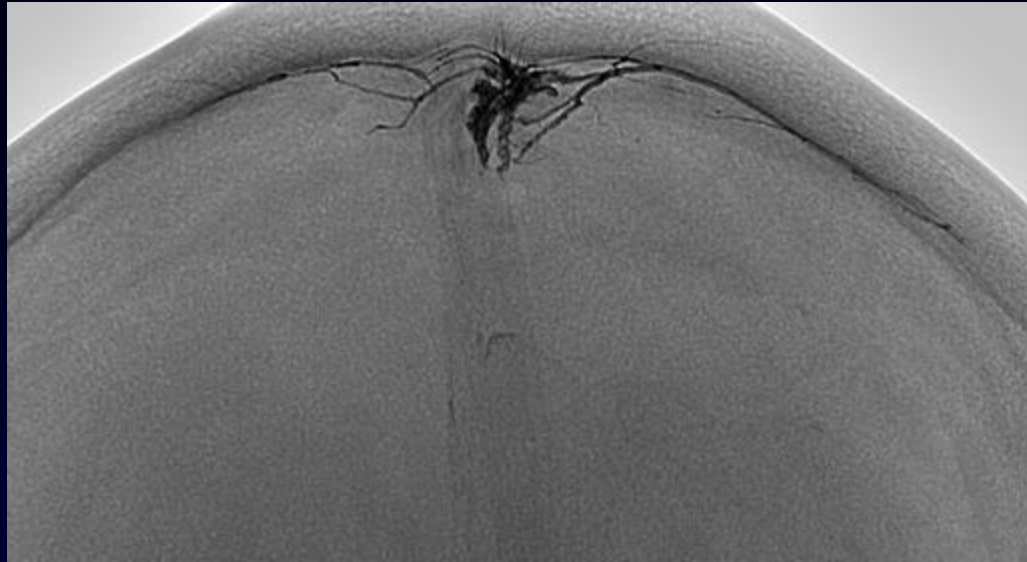
Post-Inflation

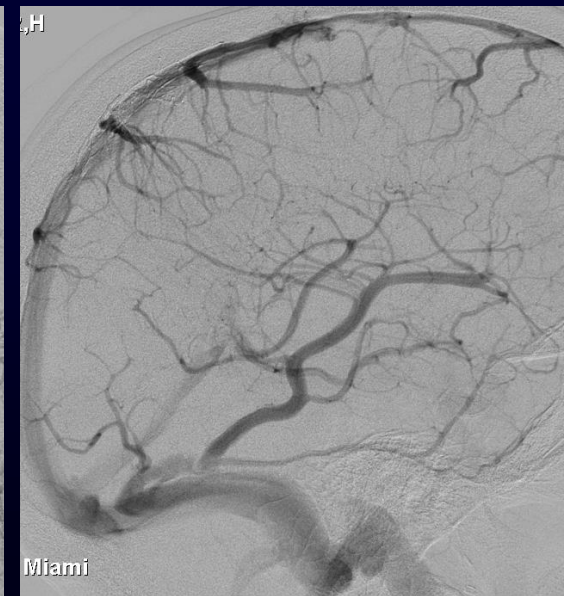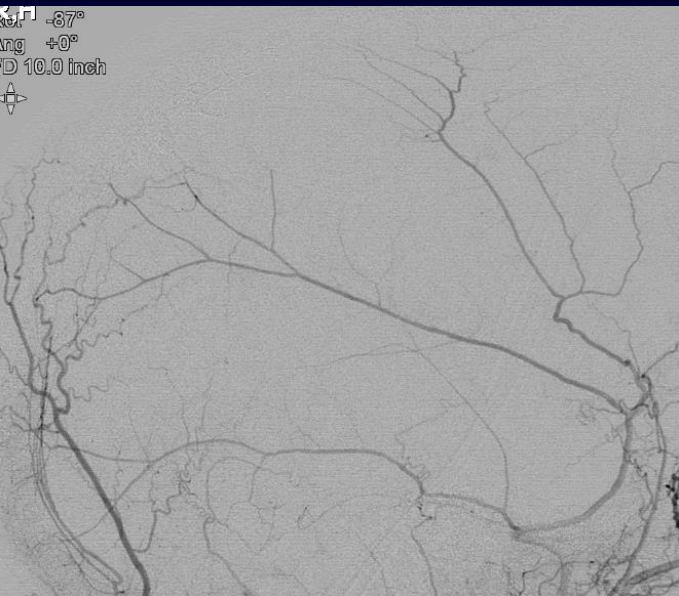
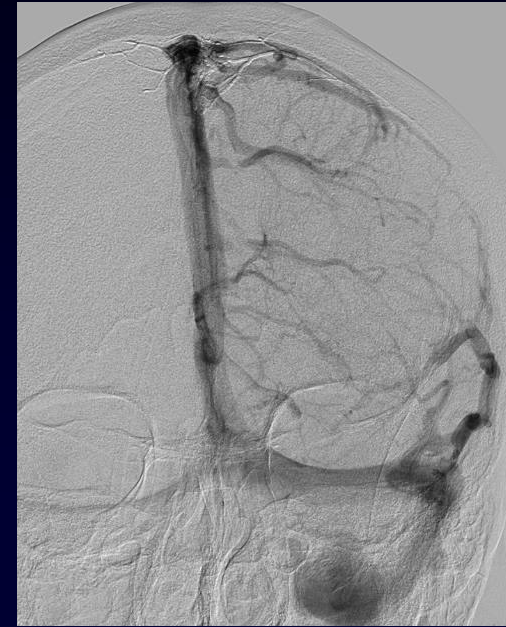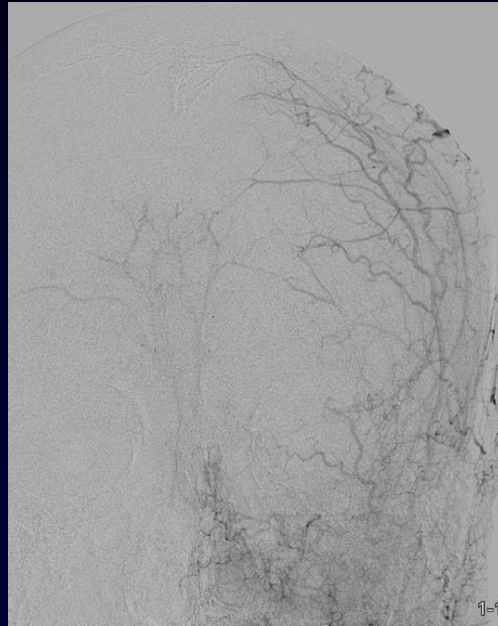
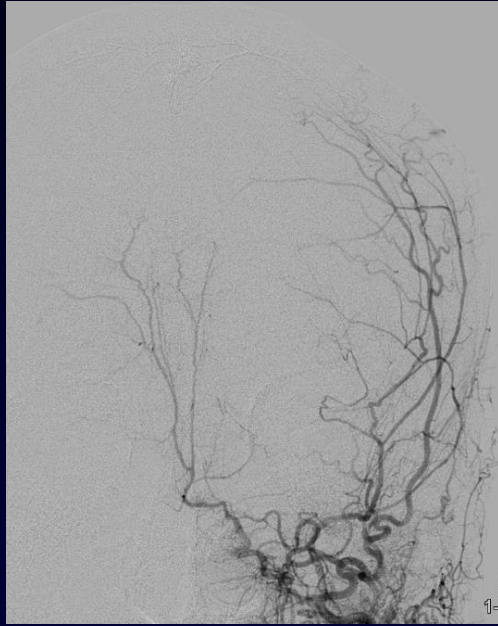






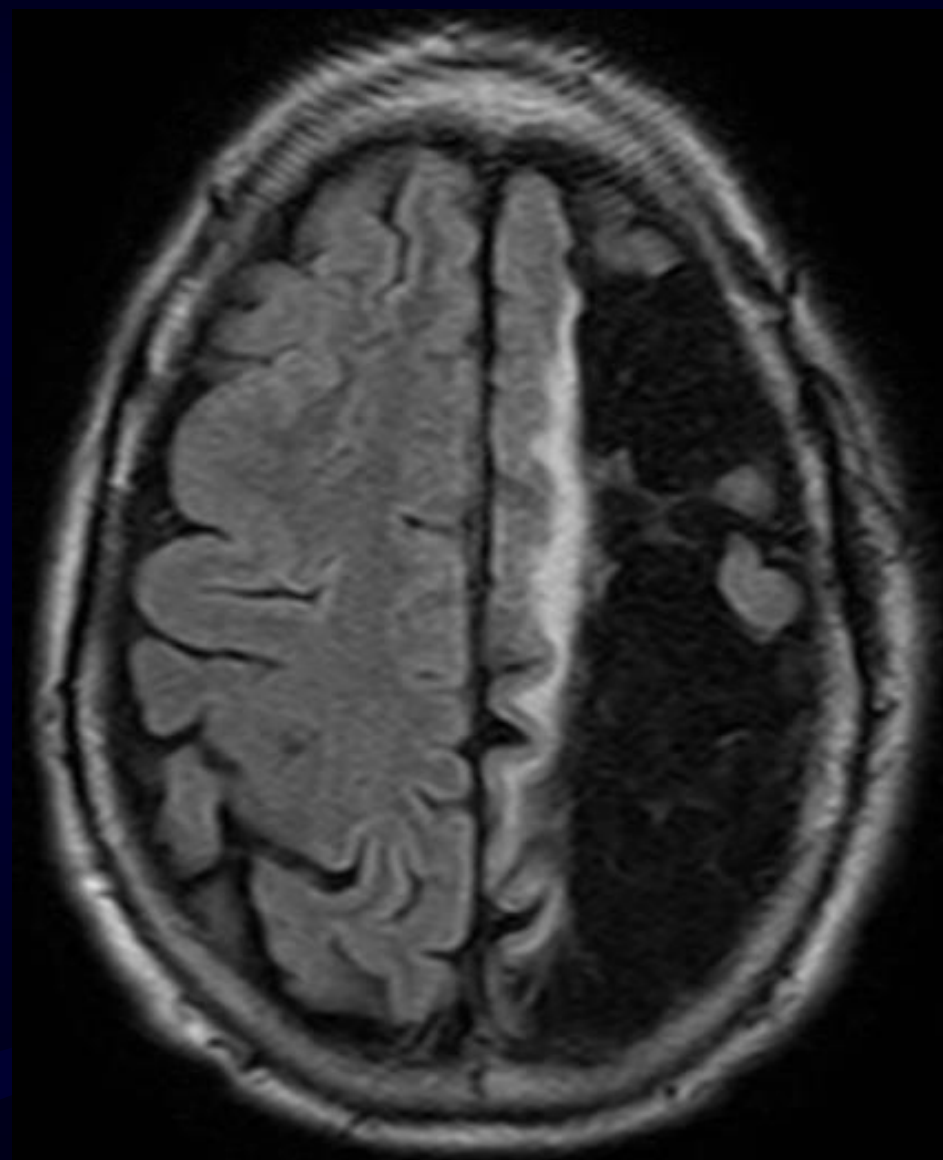
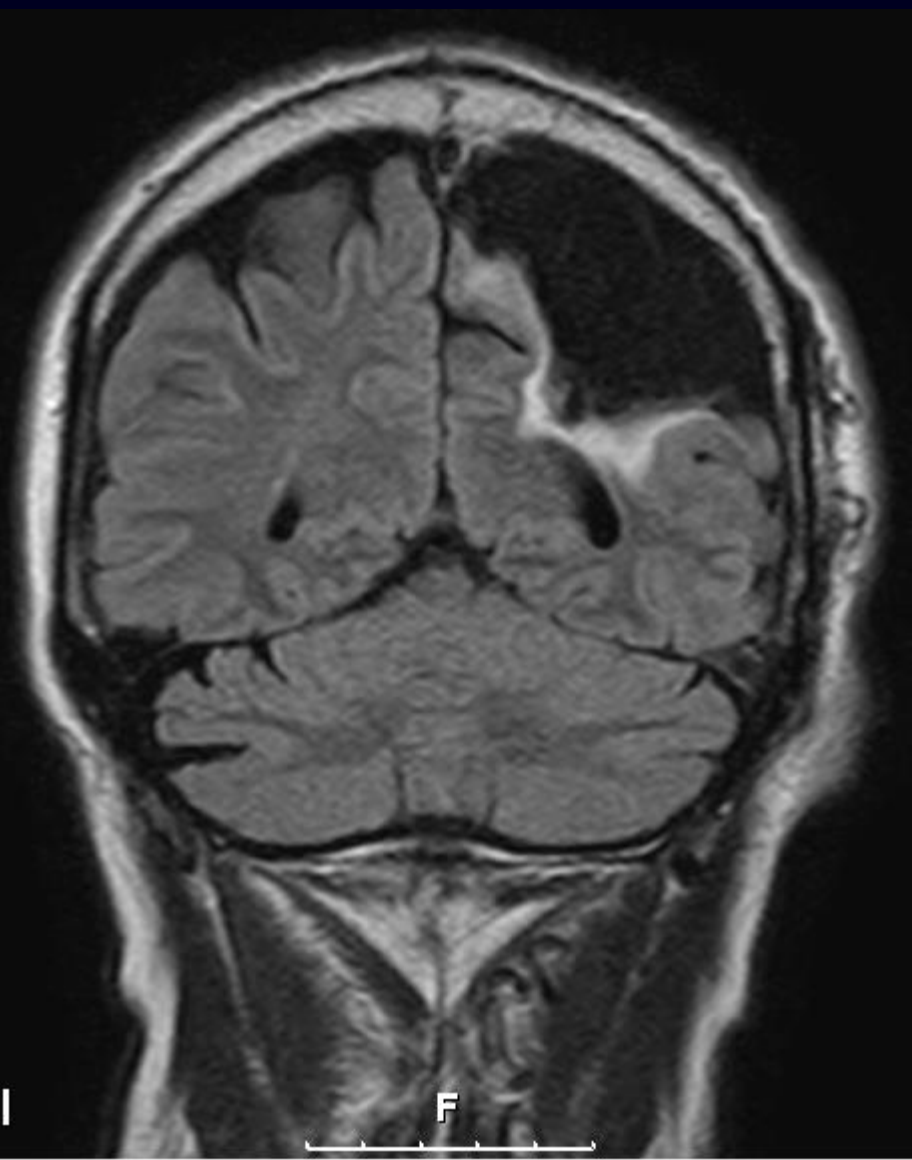


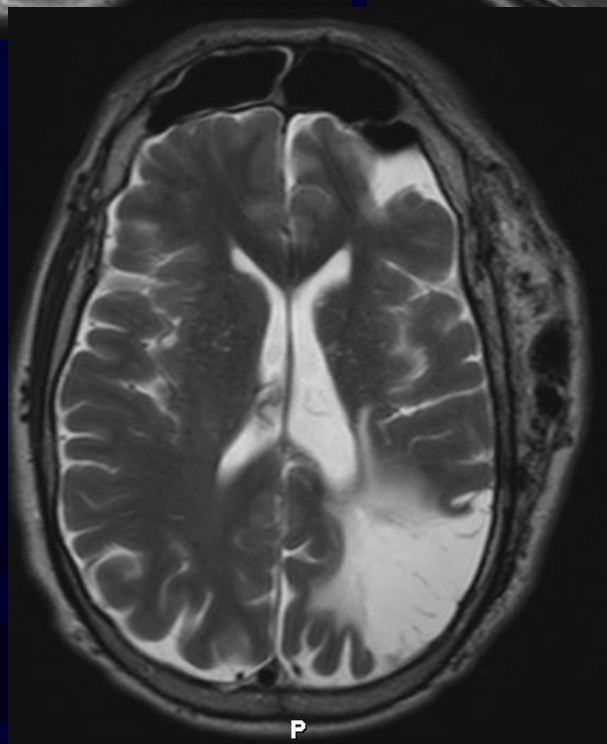
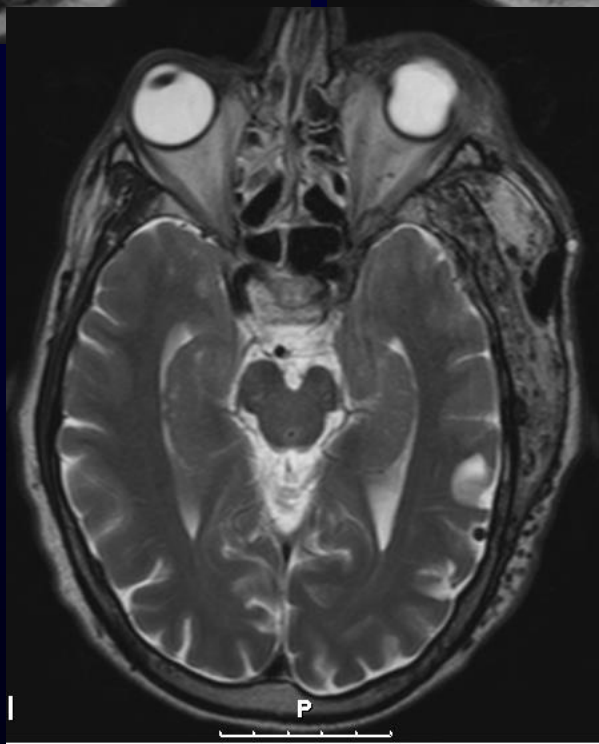
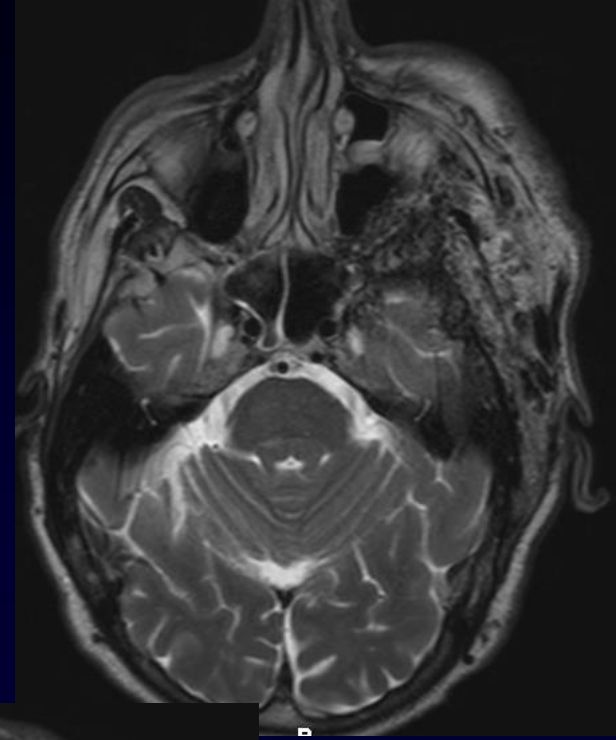
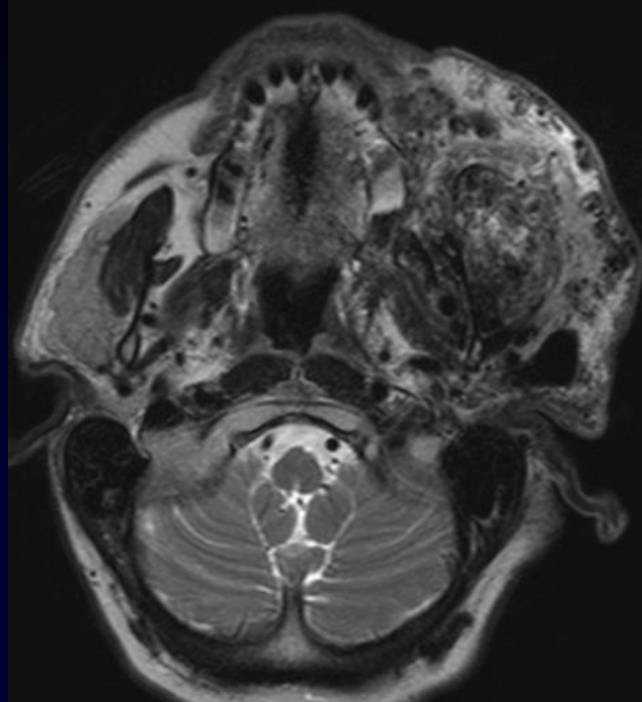
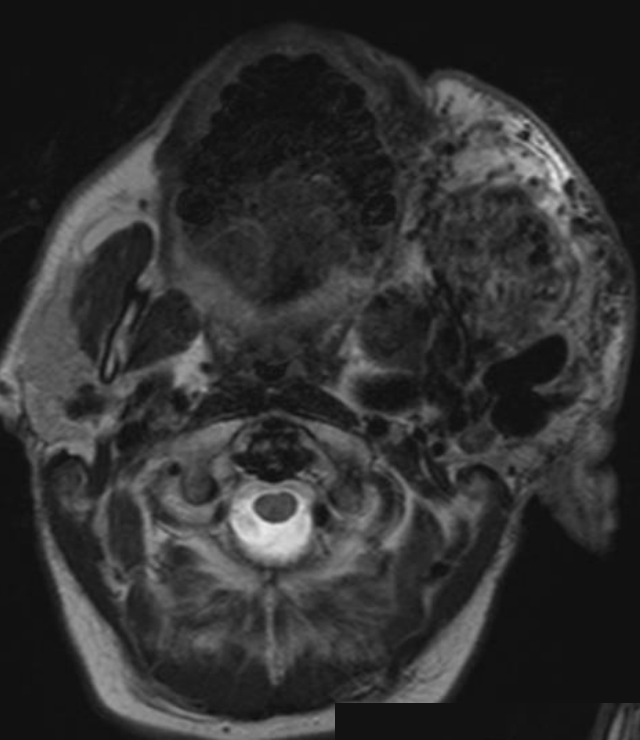
4-months follow up

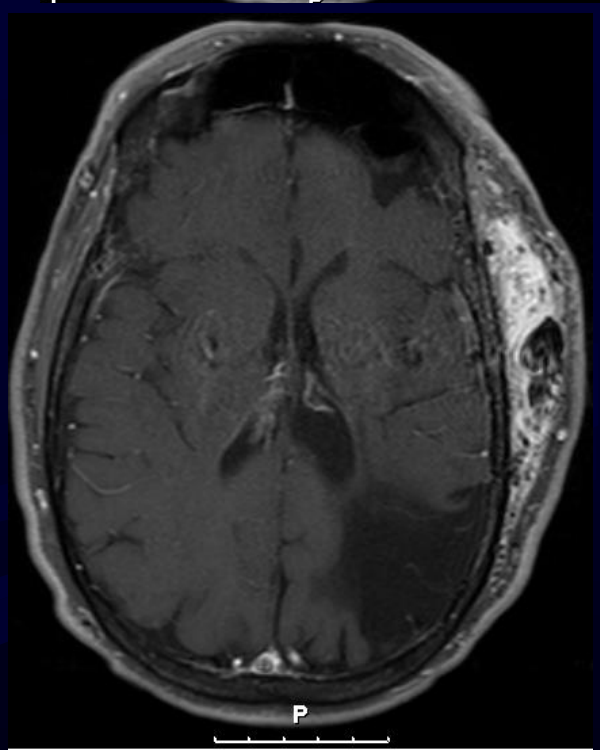
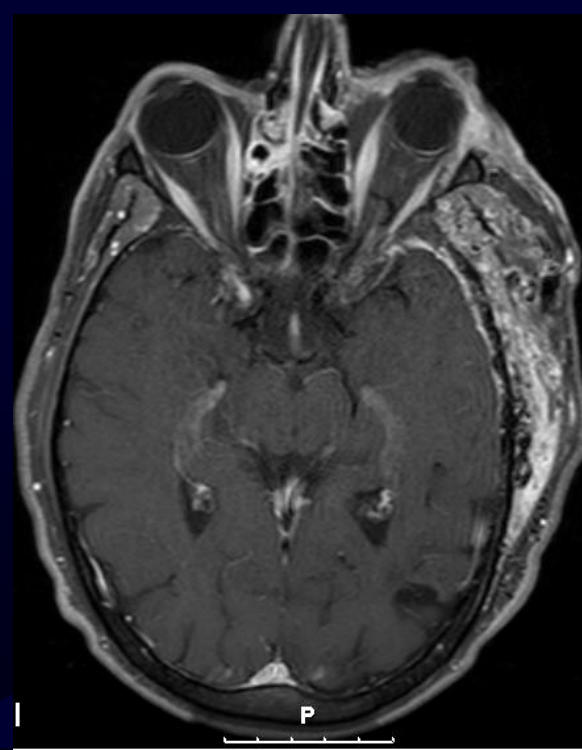
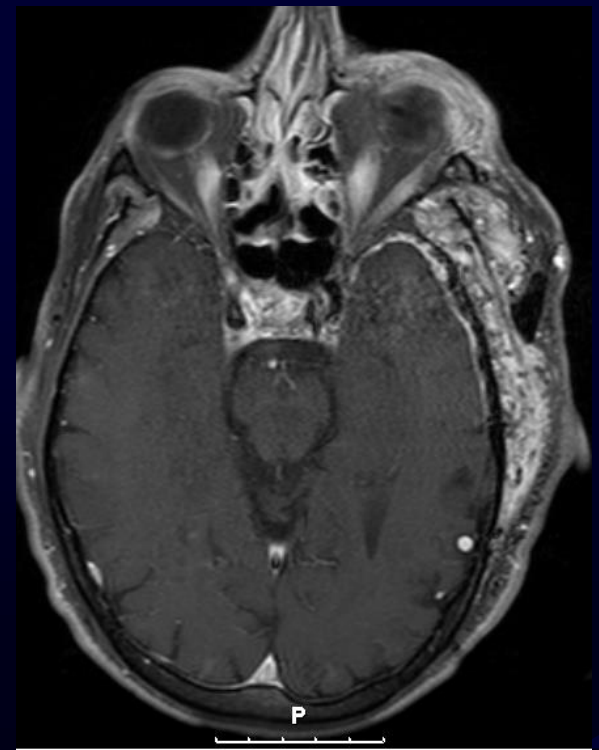
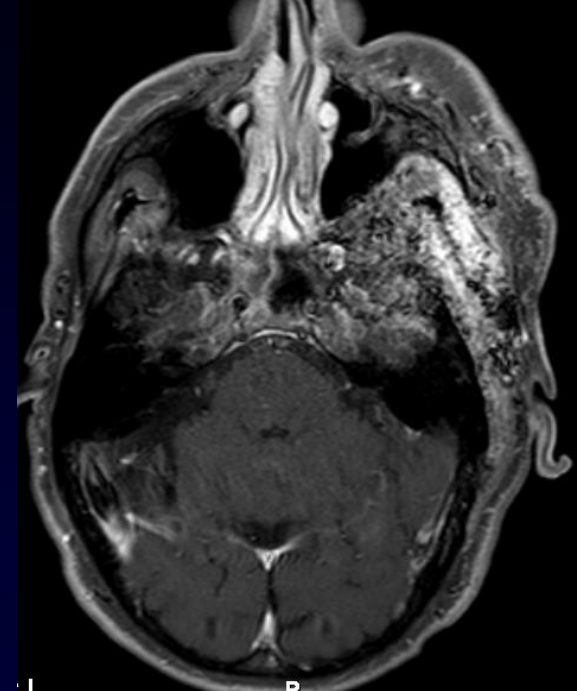
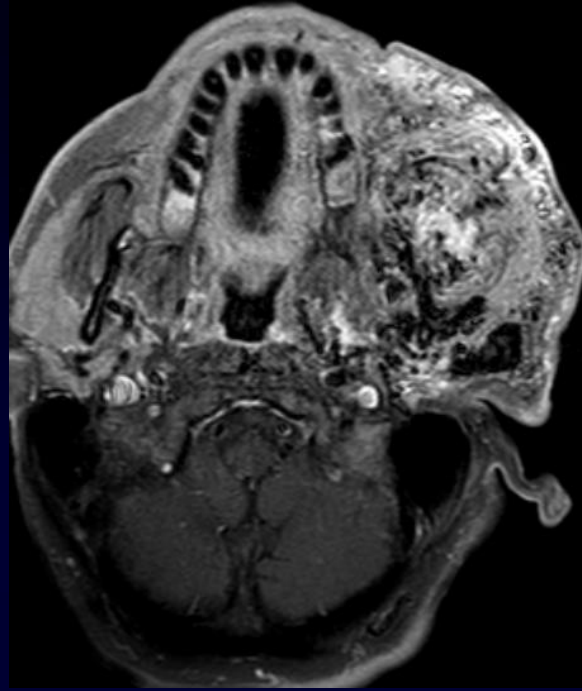
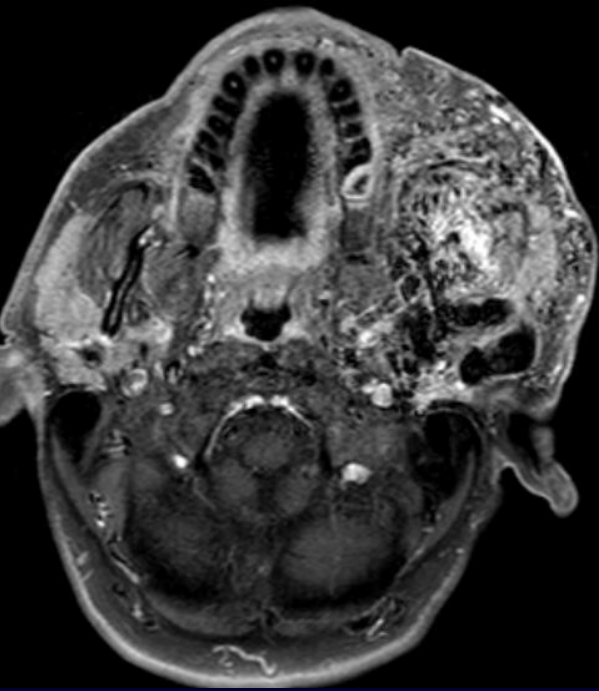


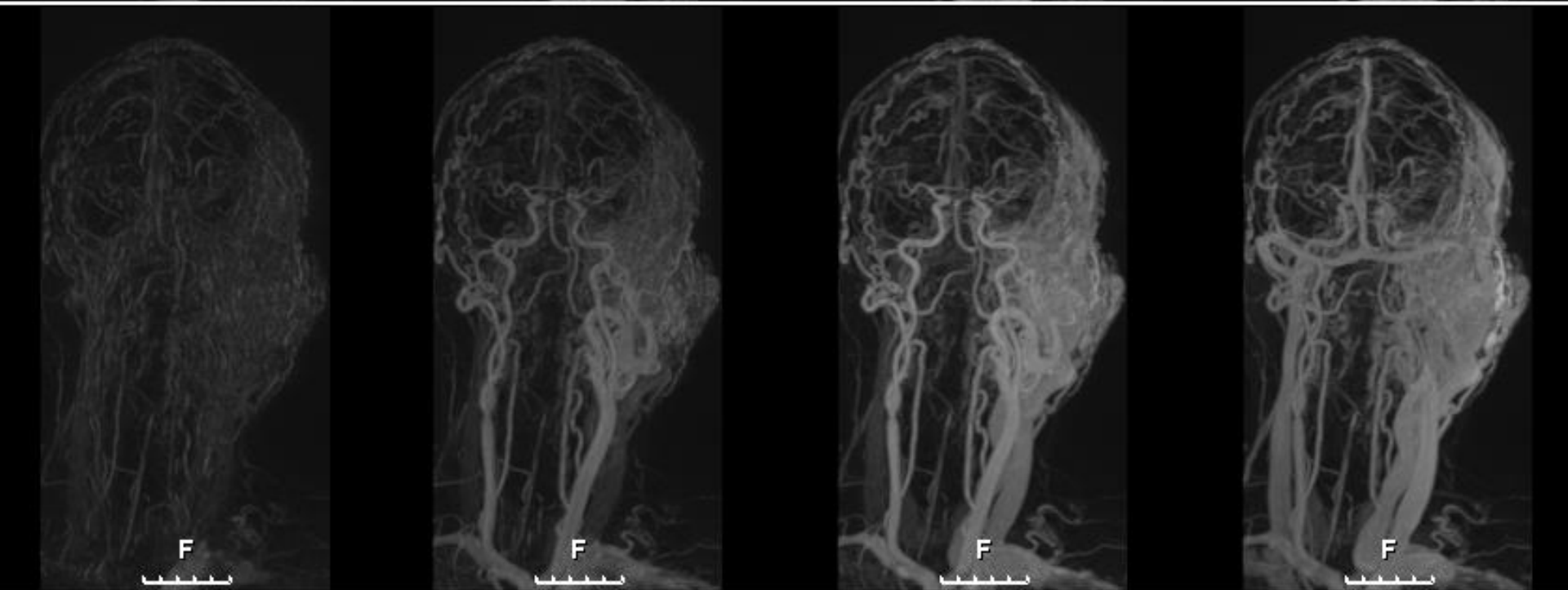
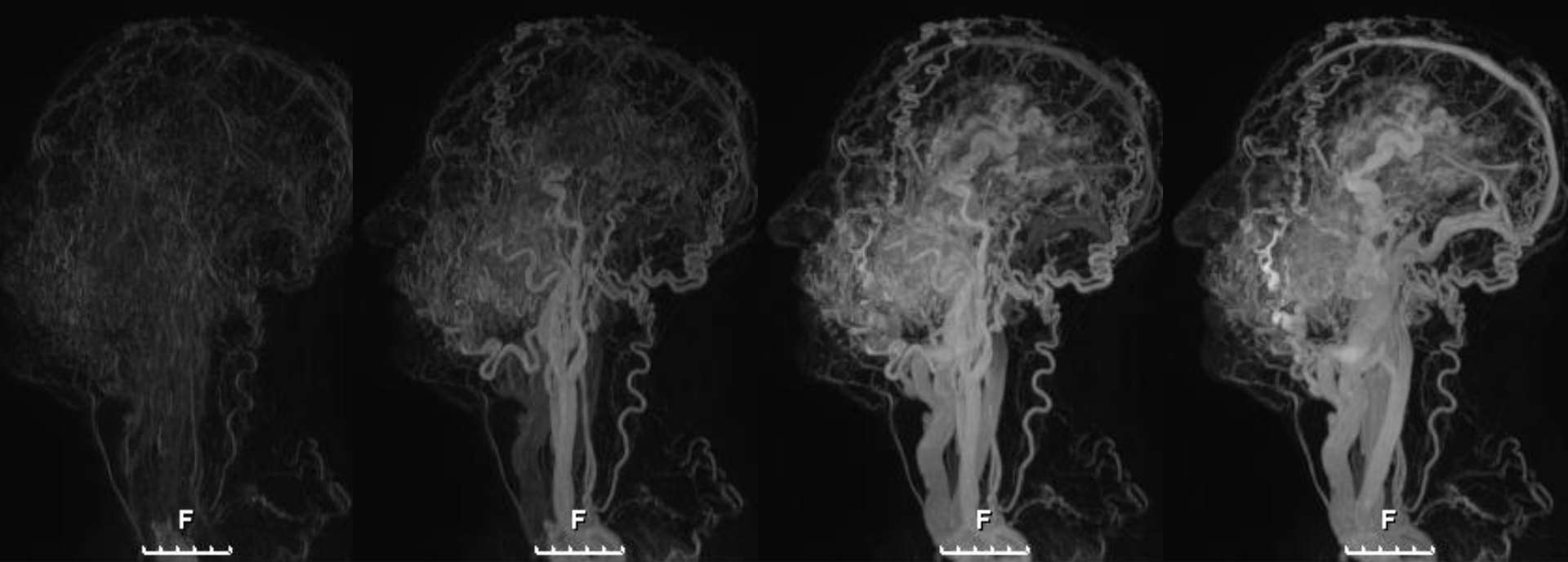
**MEN 60S KNOWN LEFT CRANIOFACIAL
AVM FOR LAST 45 YEARS – MULTIPLE
EMBOLIZATION SESSIONS PRESENTING
TO THE OFFICE WITH 2 EPISODES OF
BLEEDING THROUGH THE SKIN IN THE
LEFT CHEEK AREA**

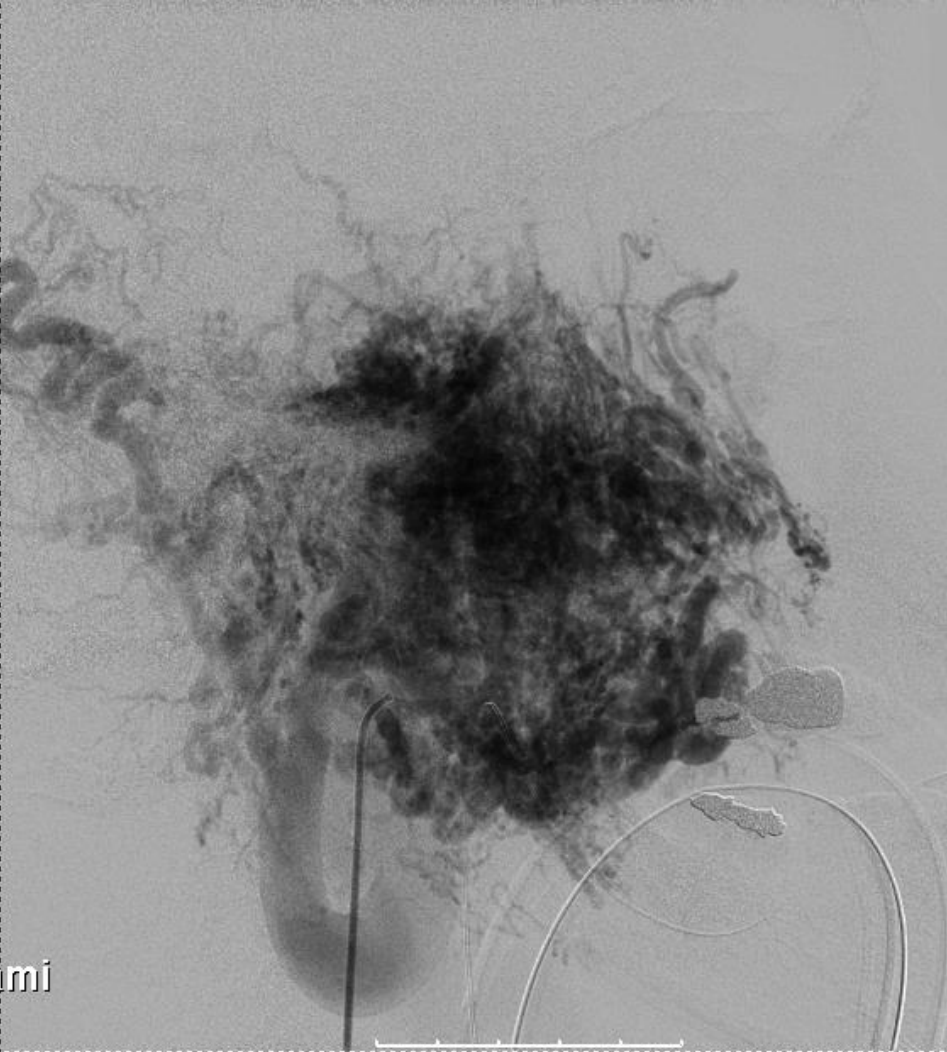
RESULT OF EMBOLIZATION IN 1983



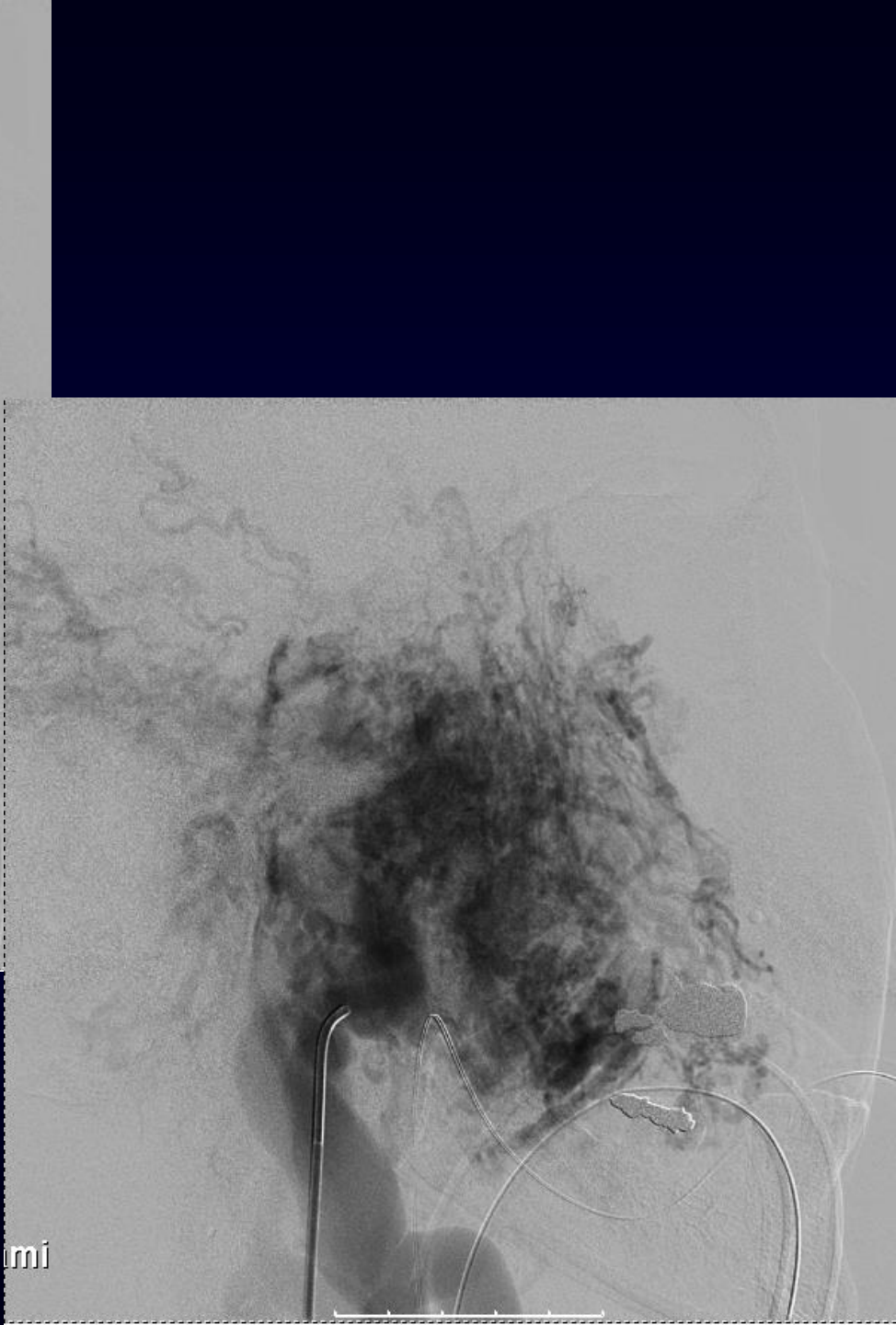




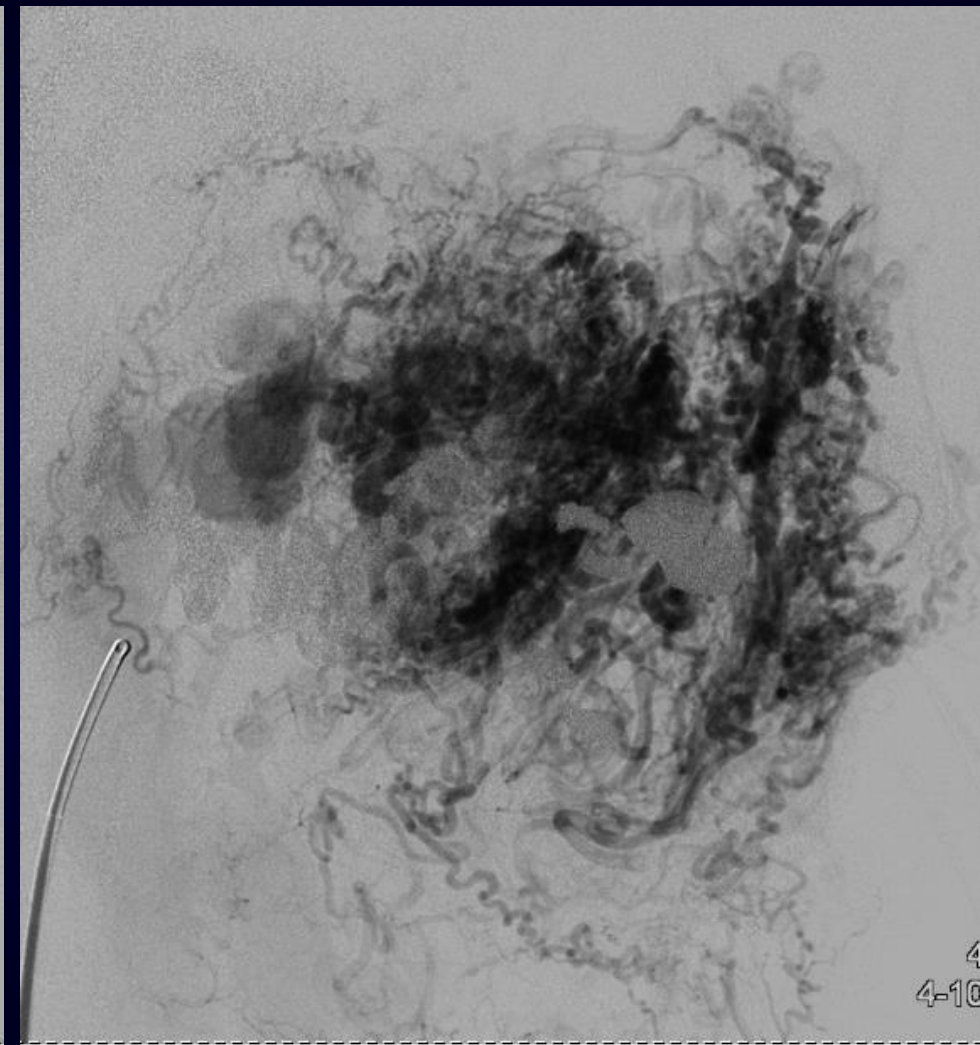
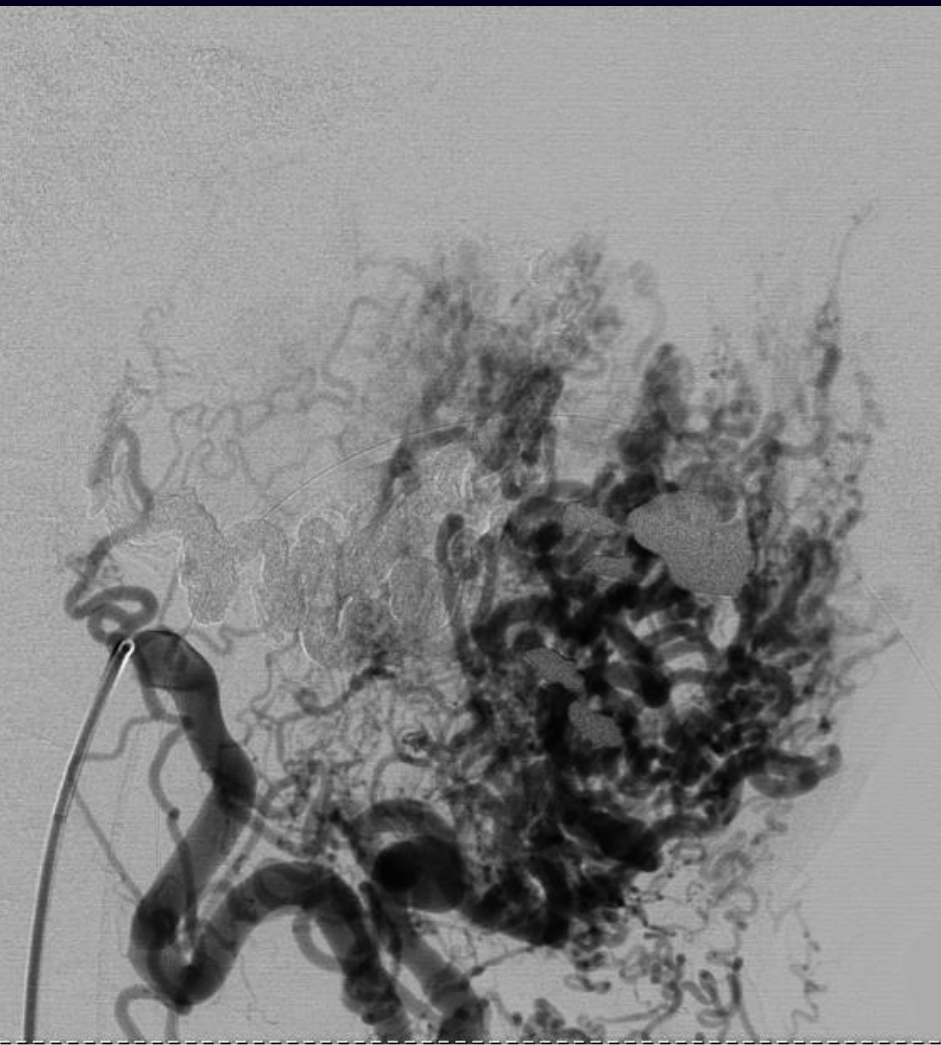




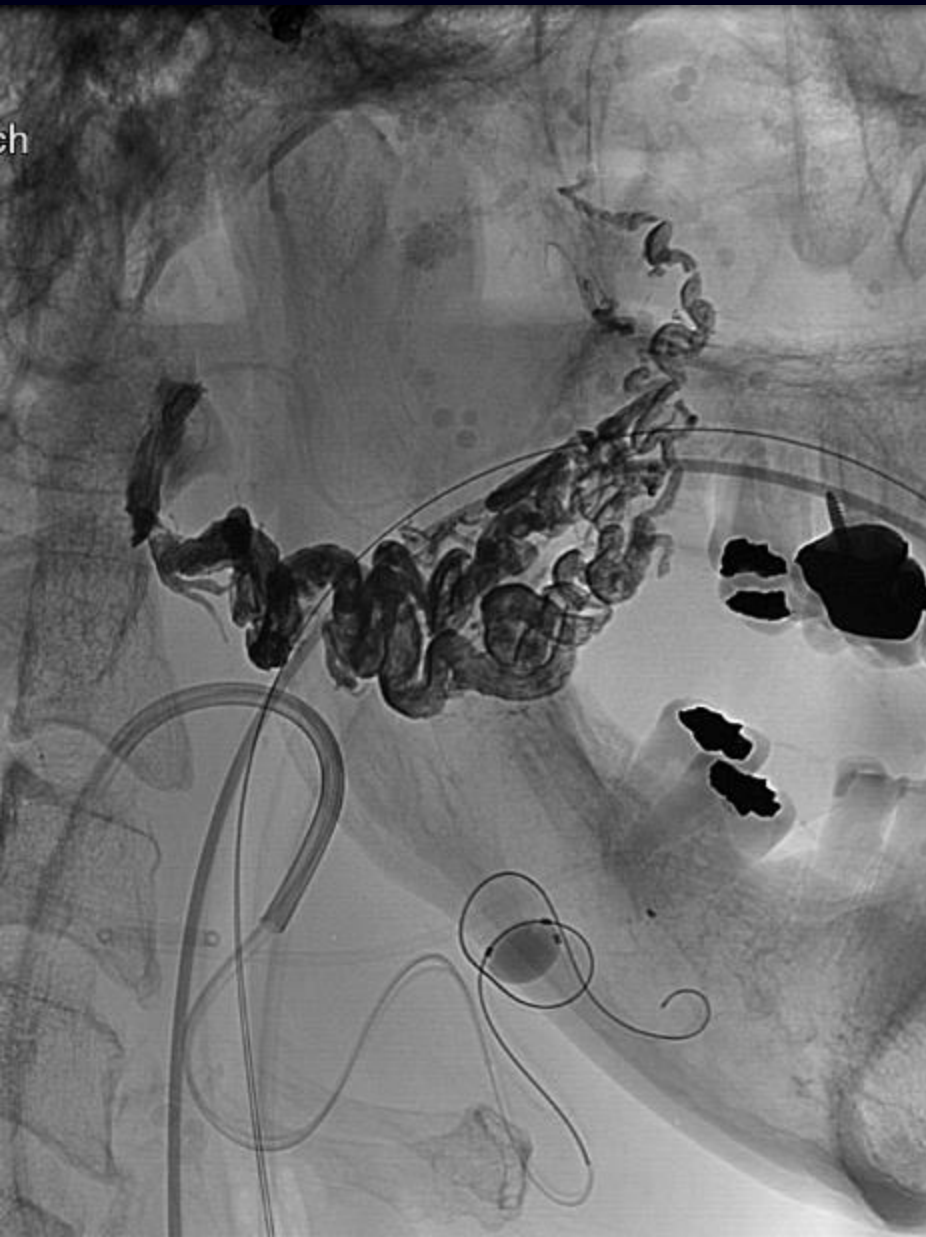mi



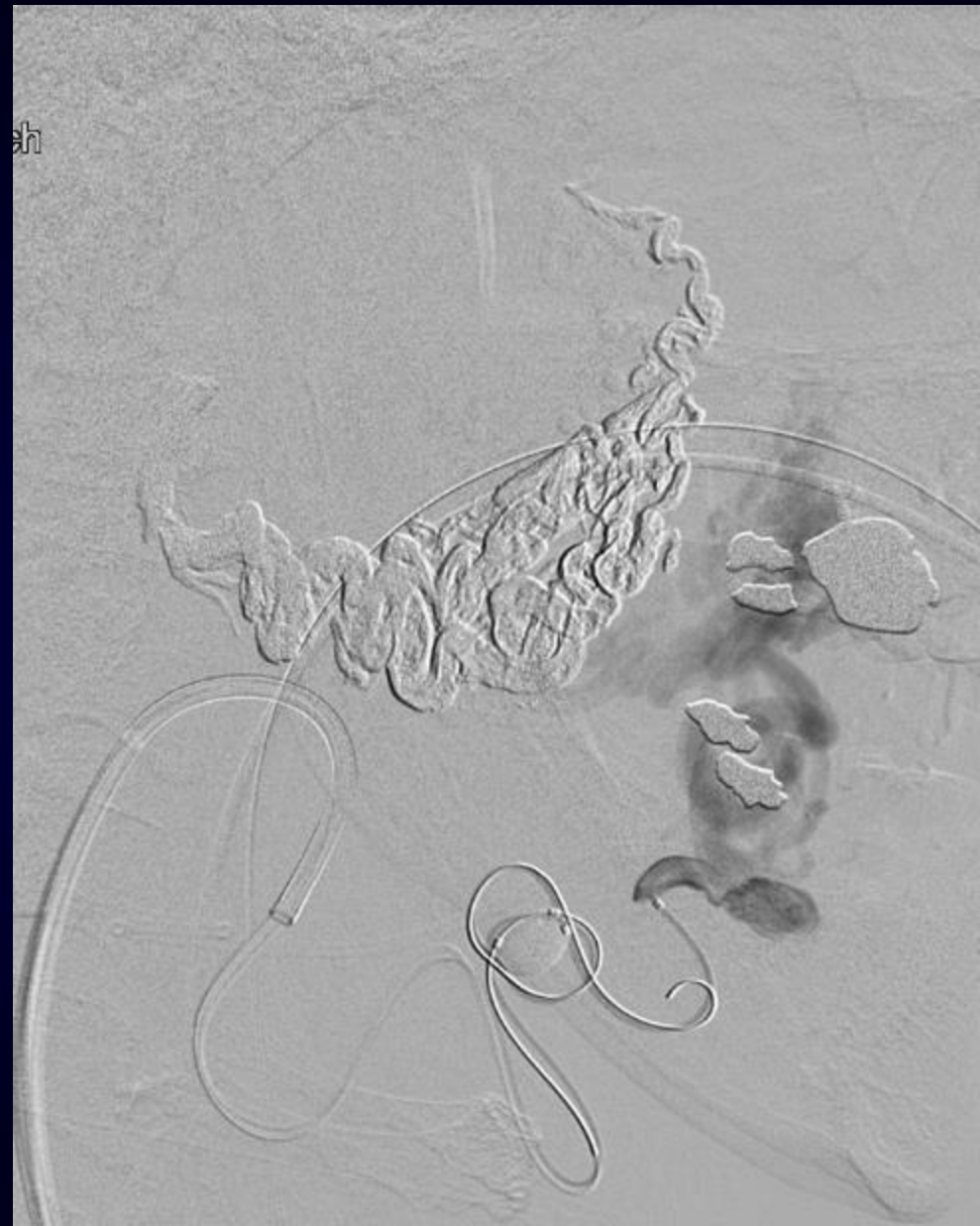
mi

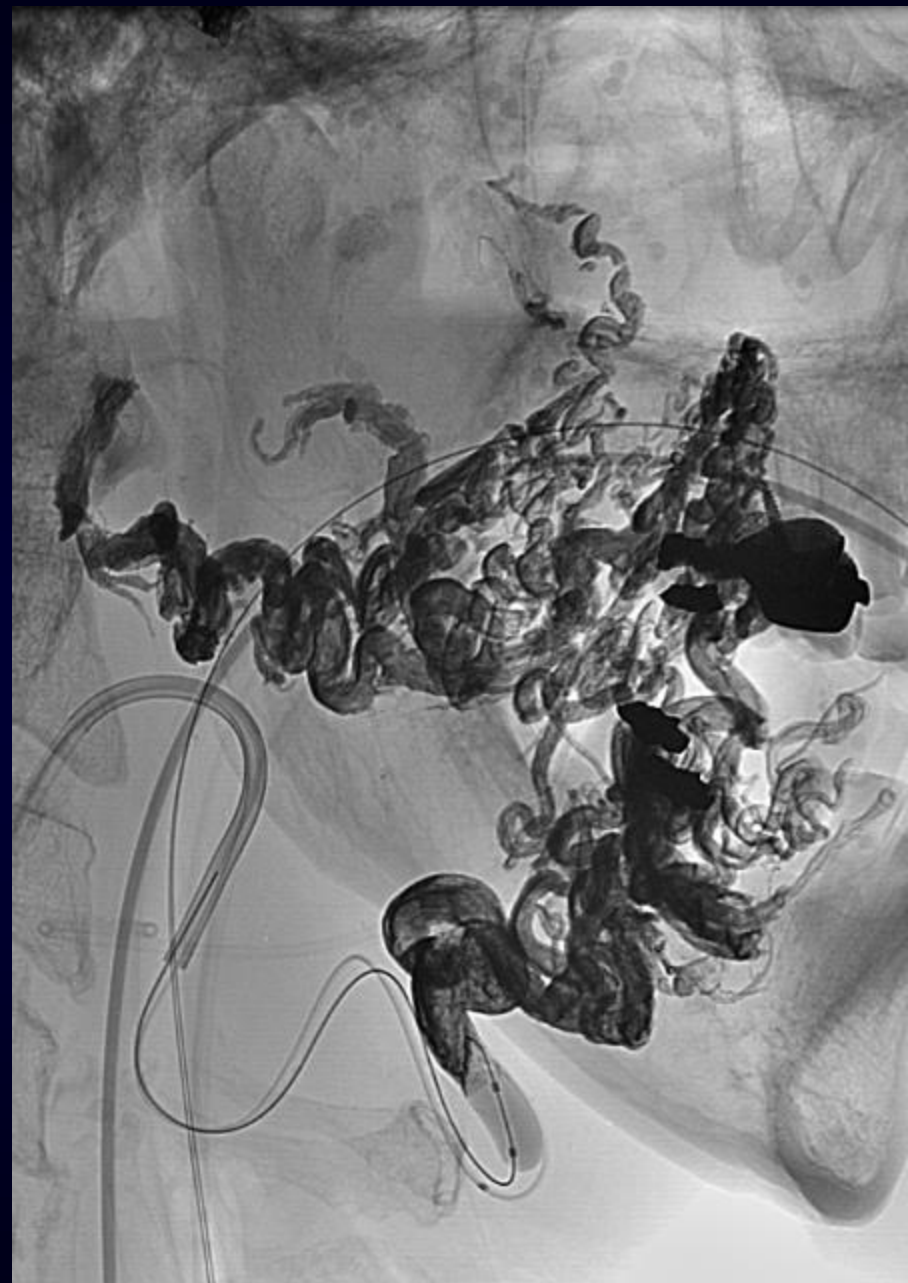
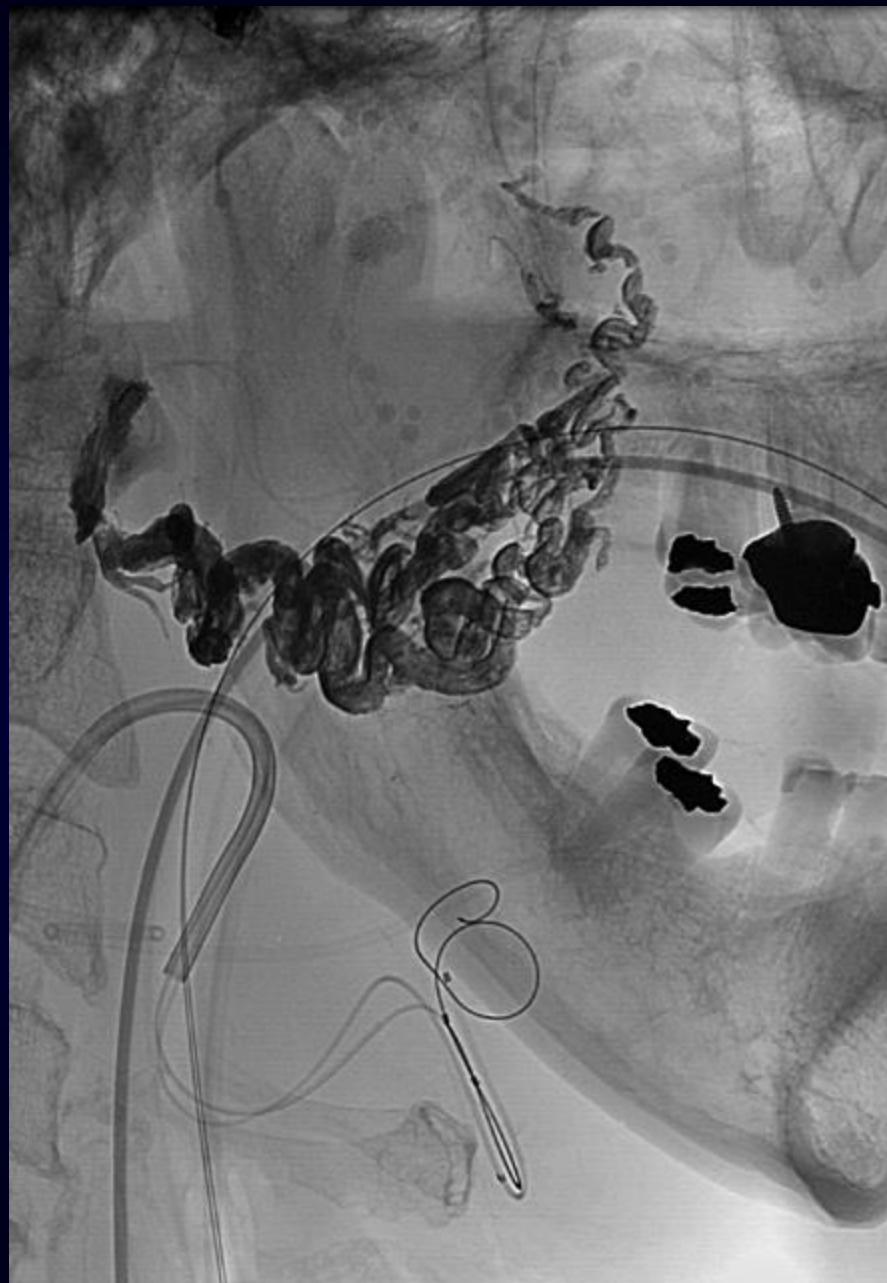


ch

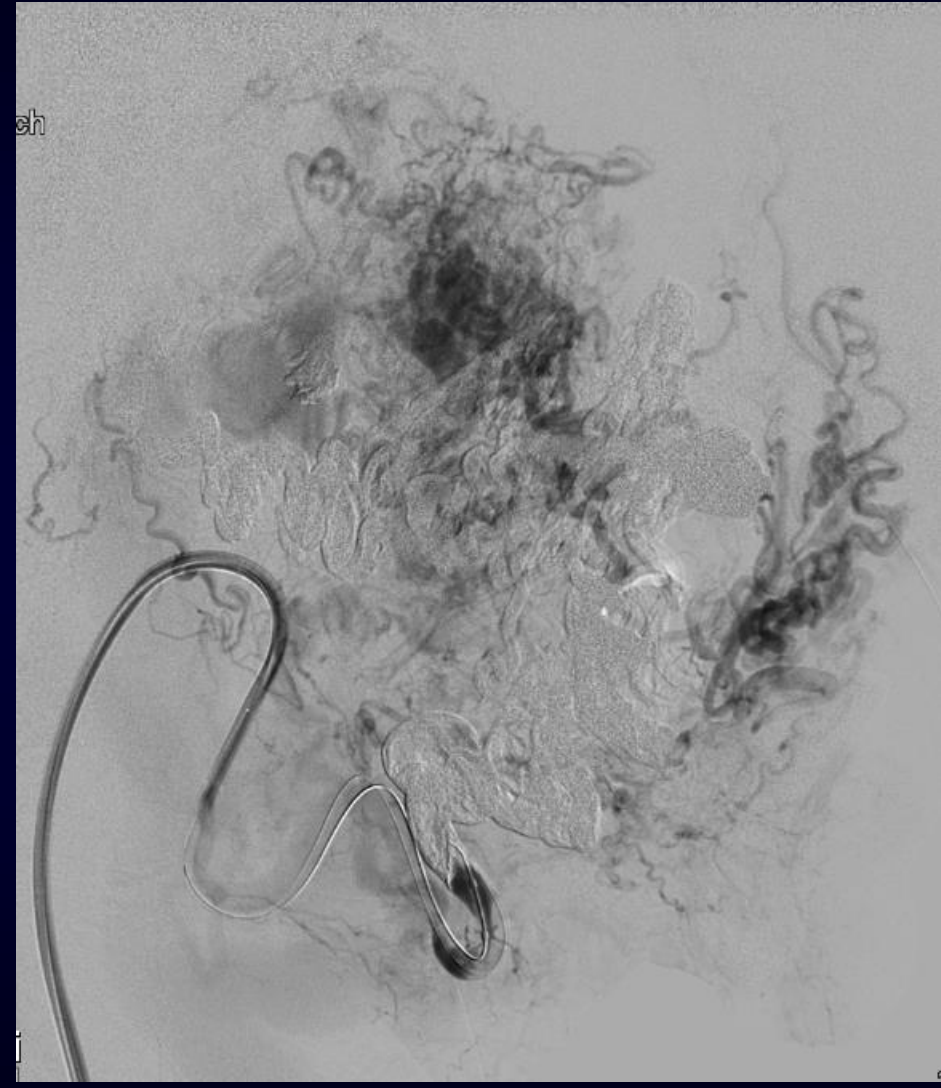
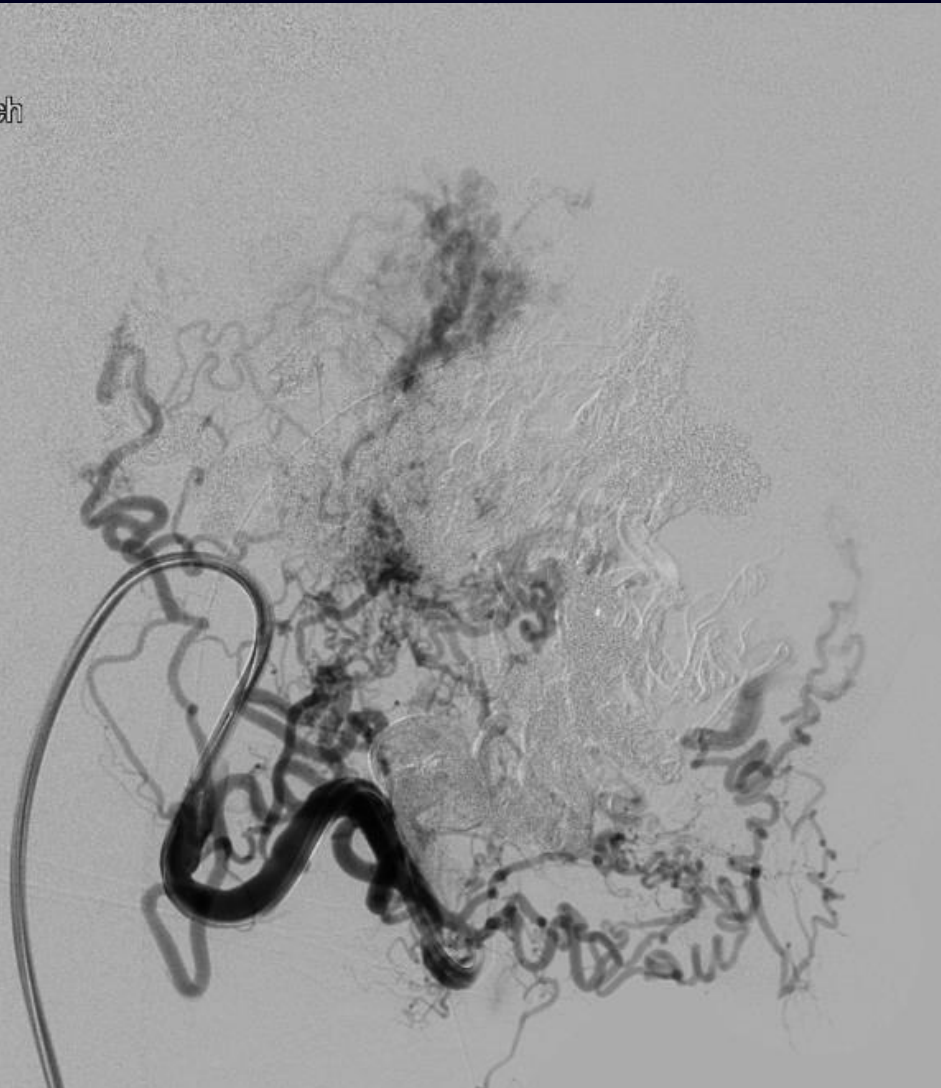


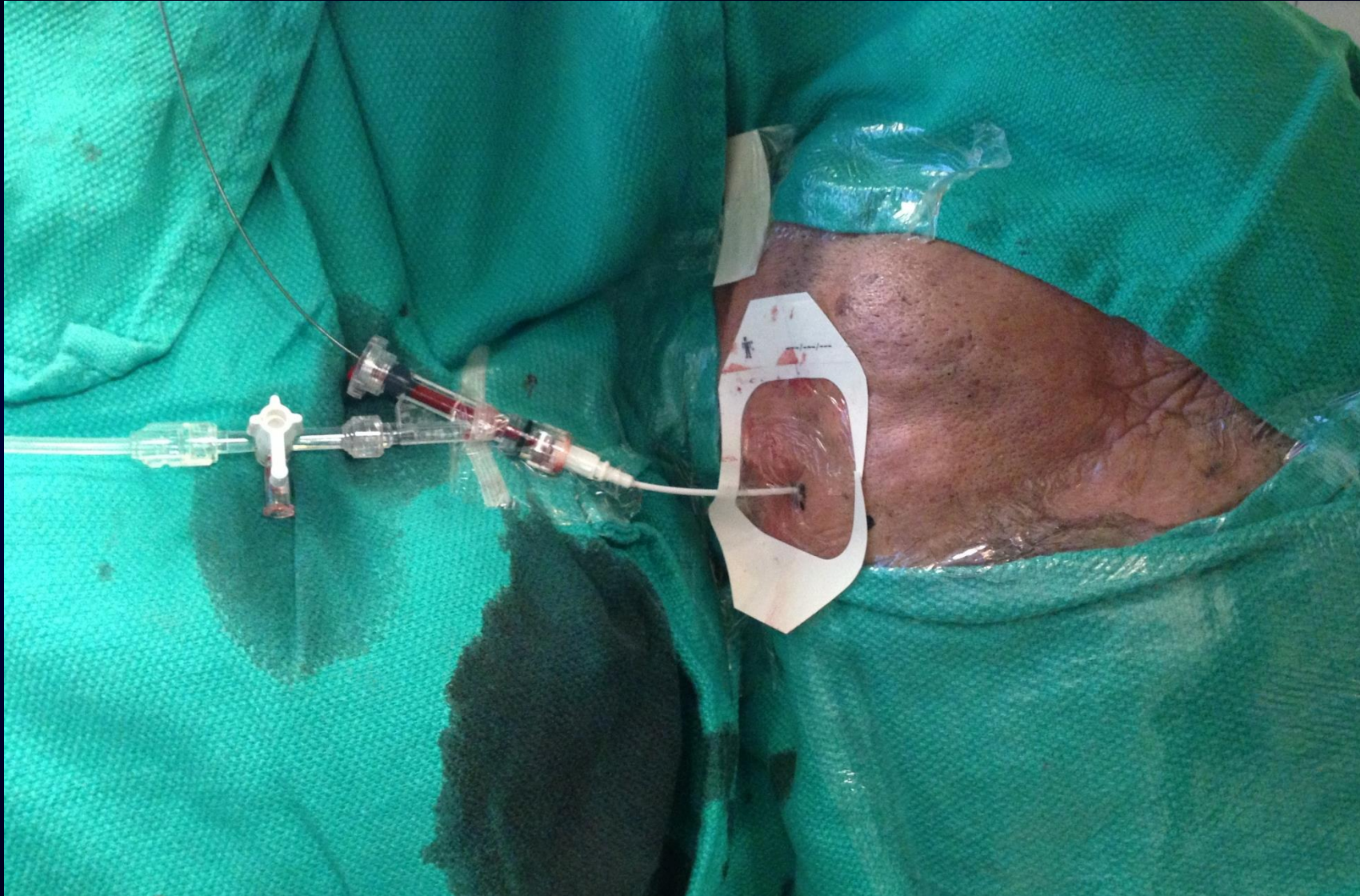
ch

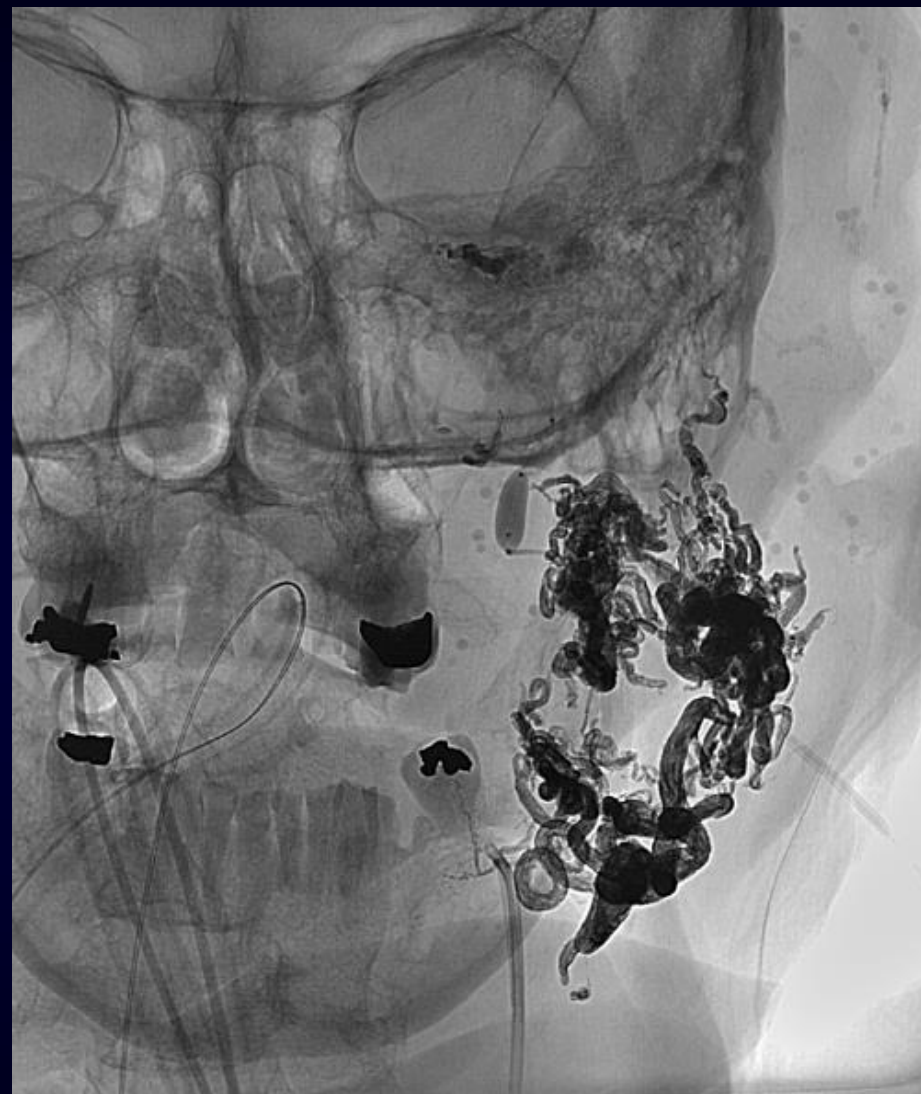
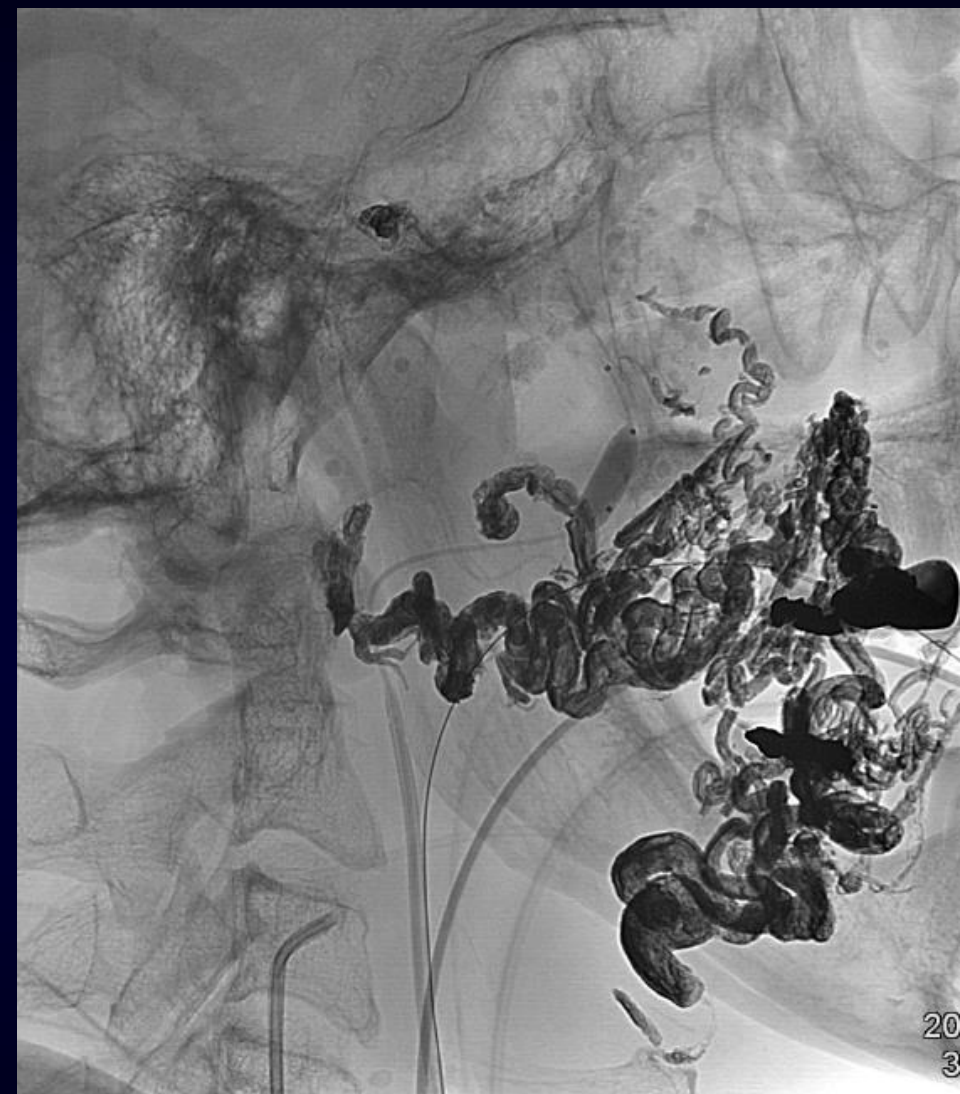


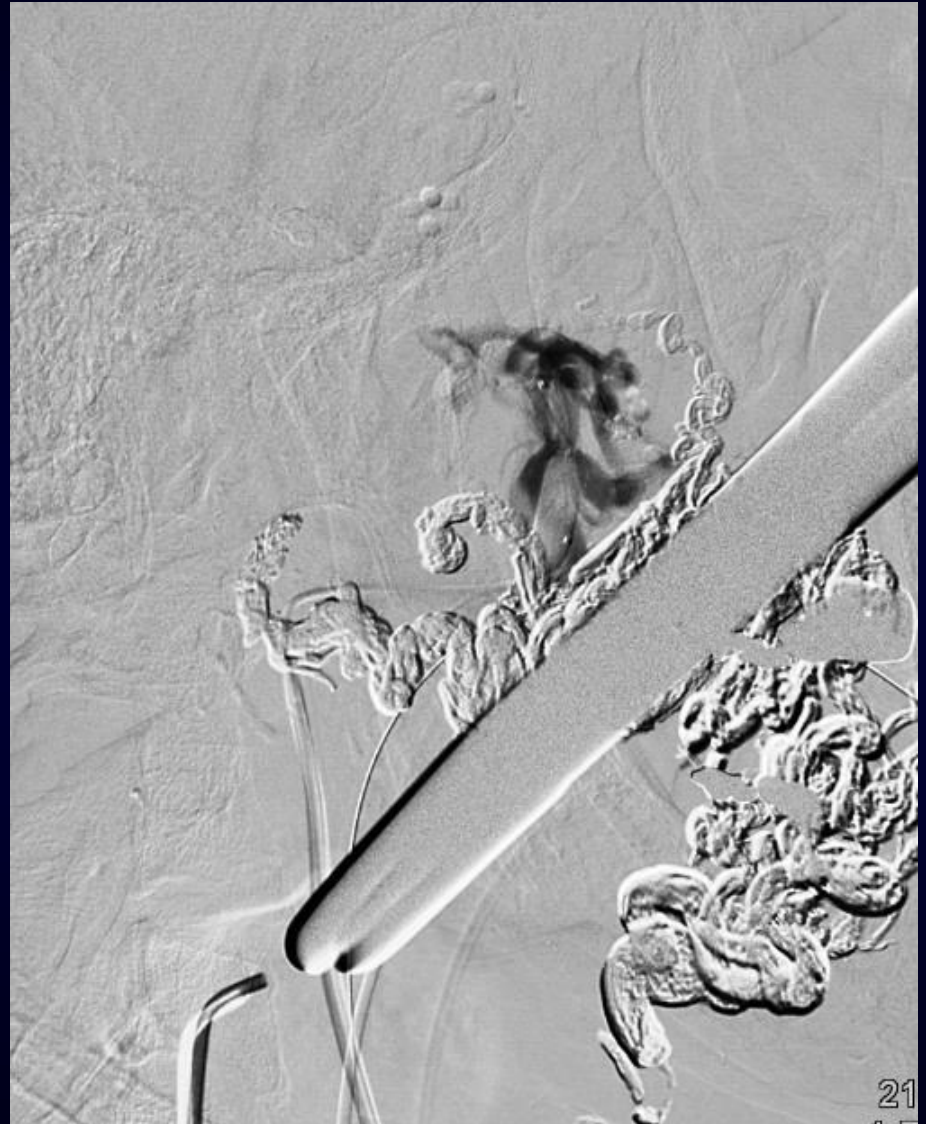
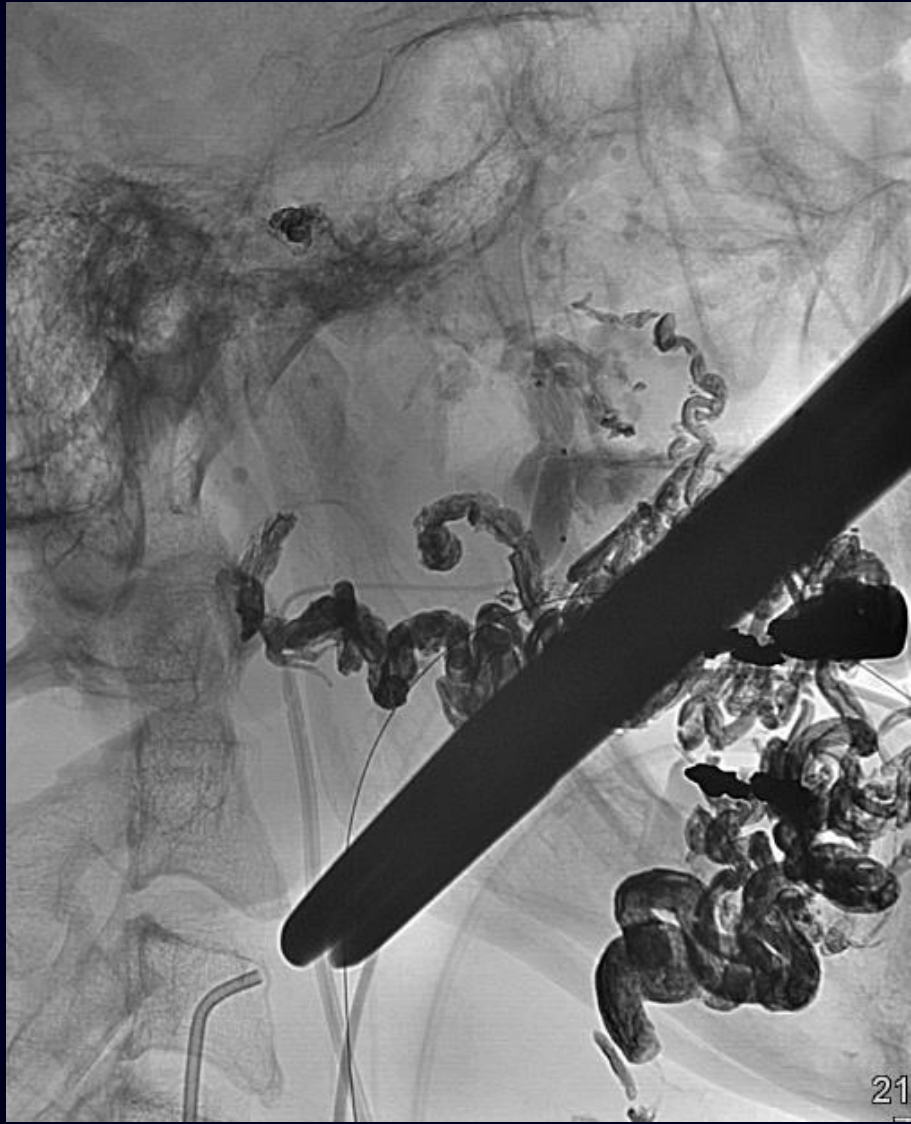
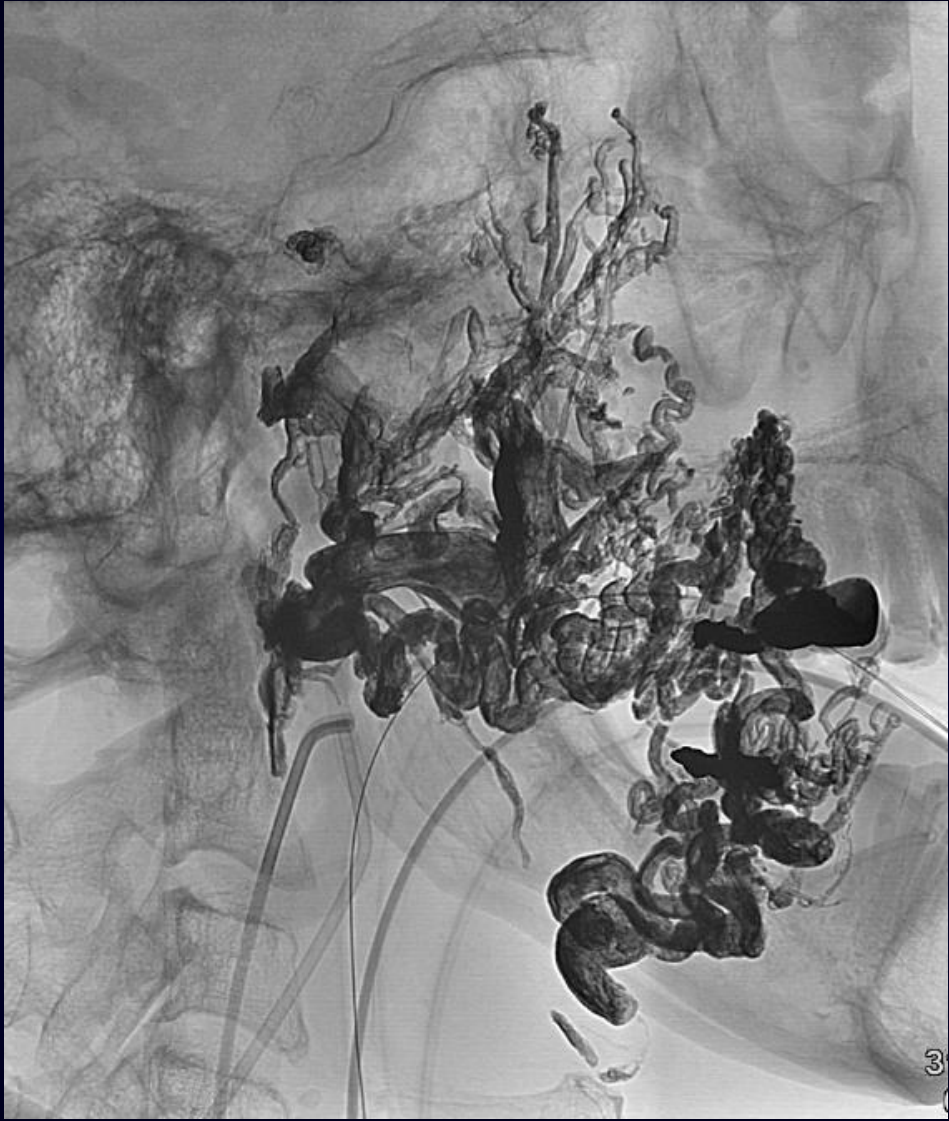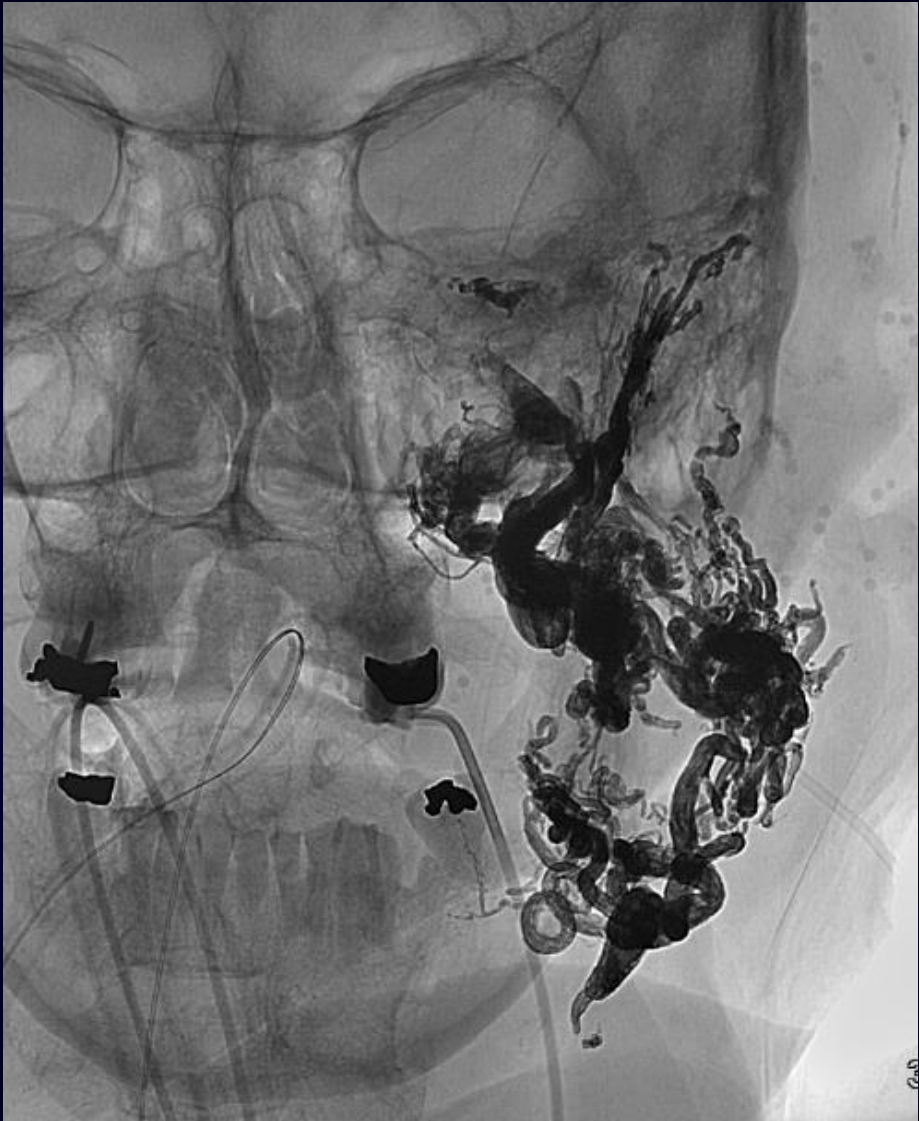Left Facial Artery

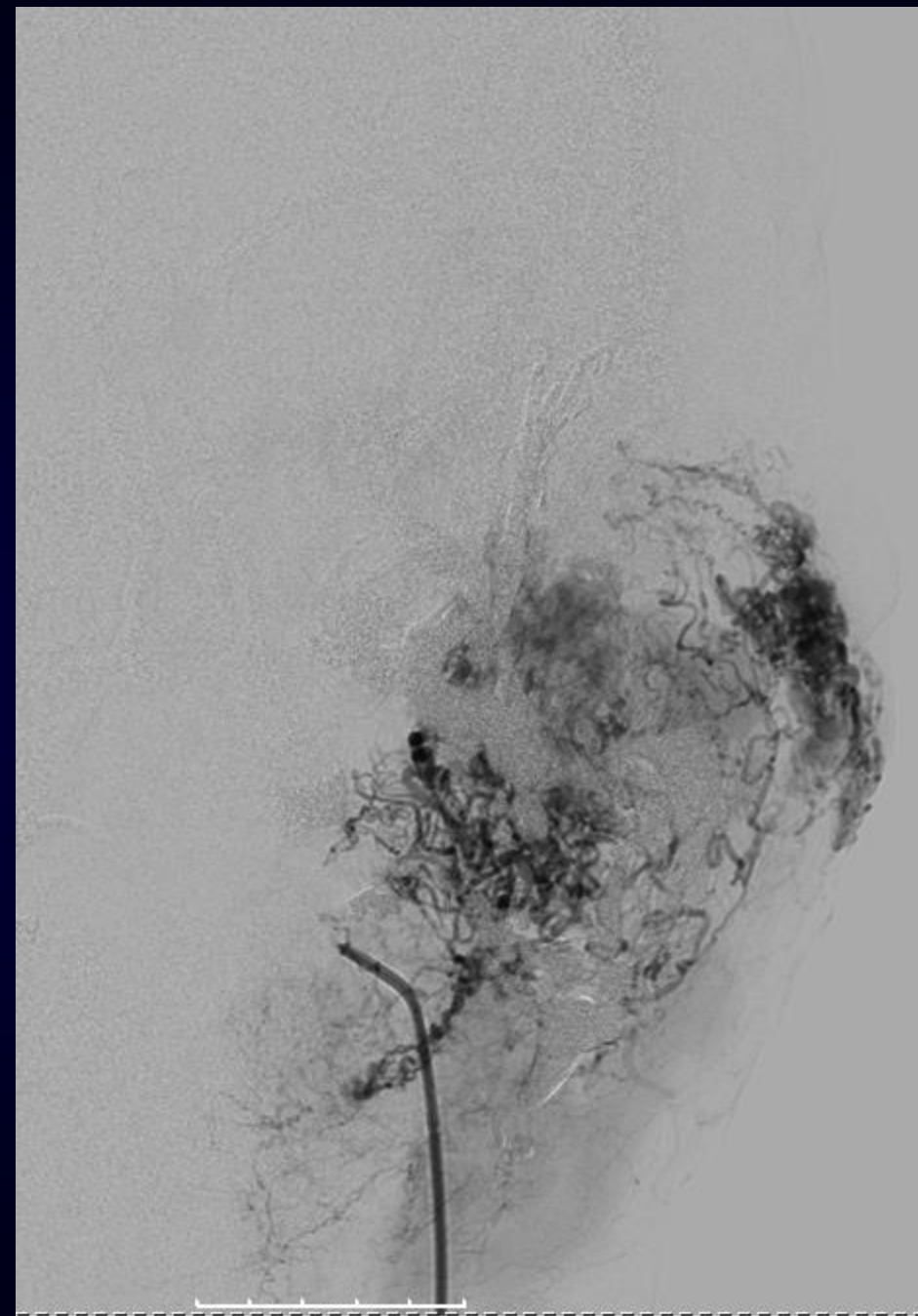
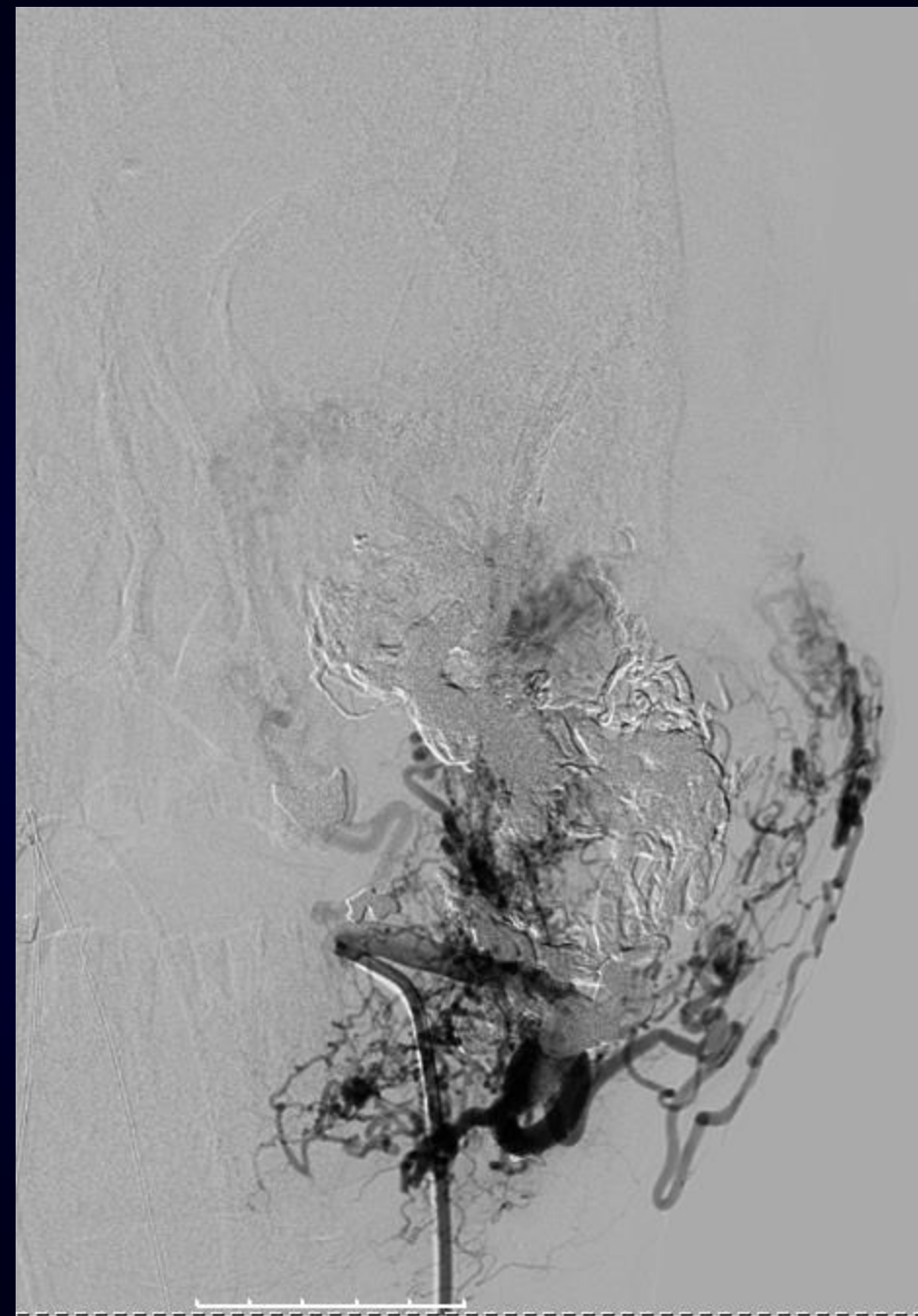


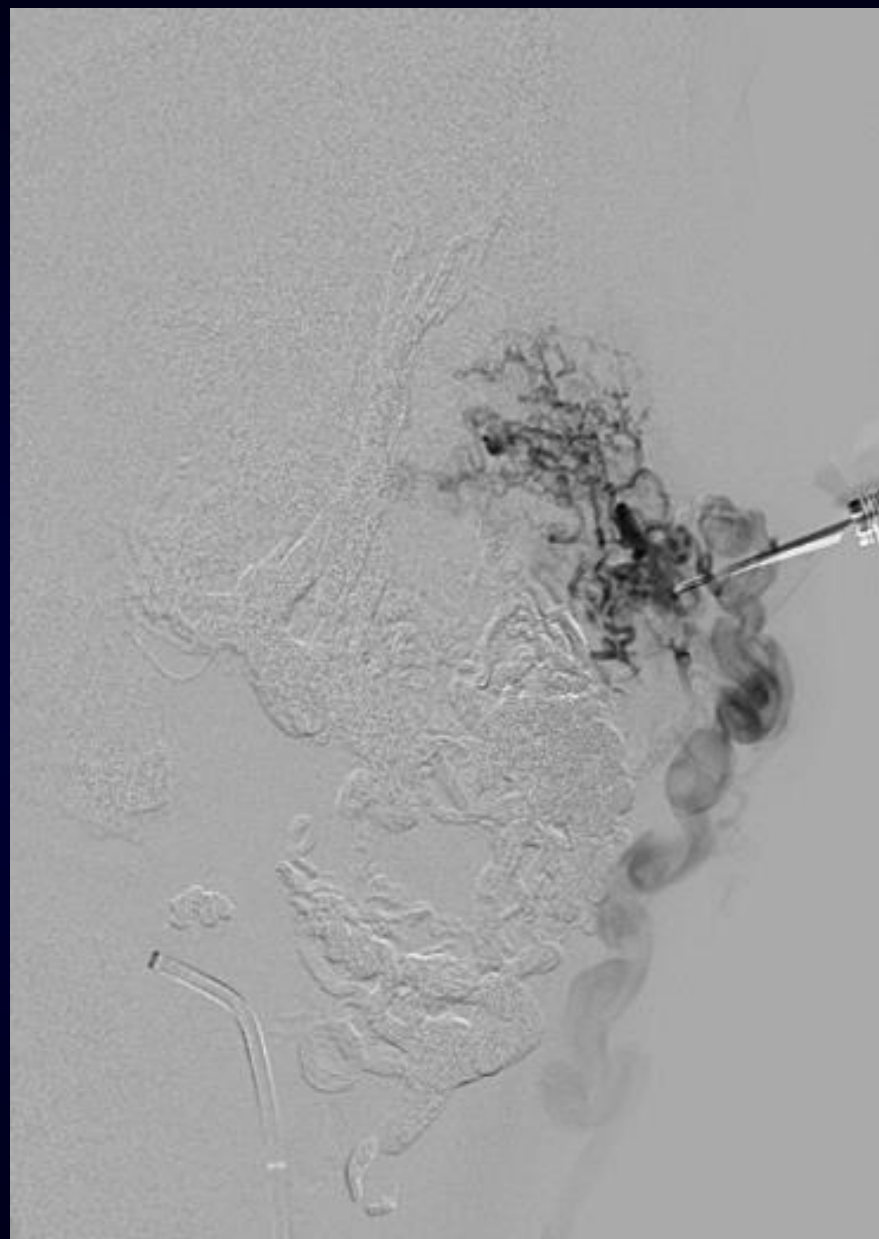
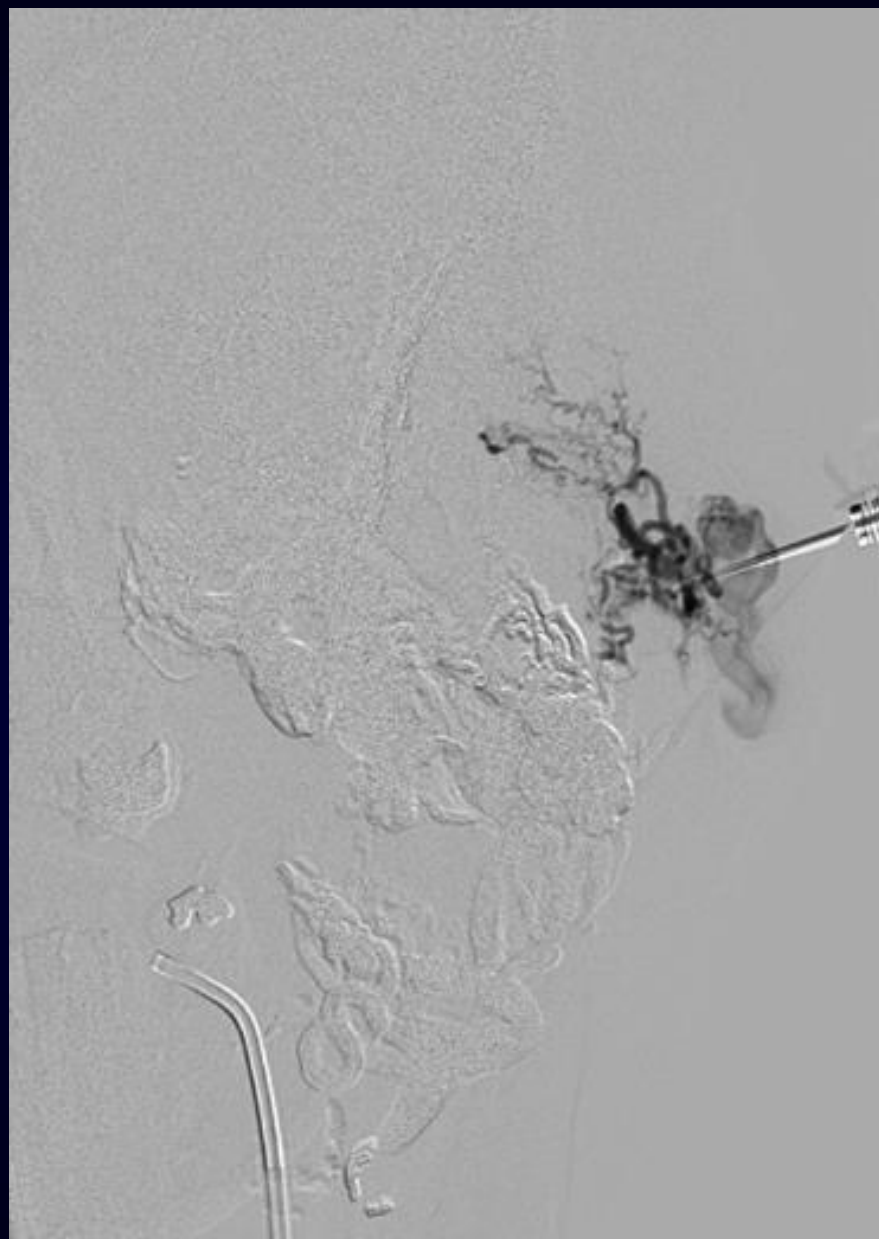


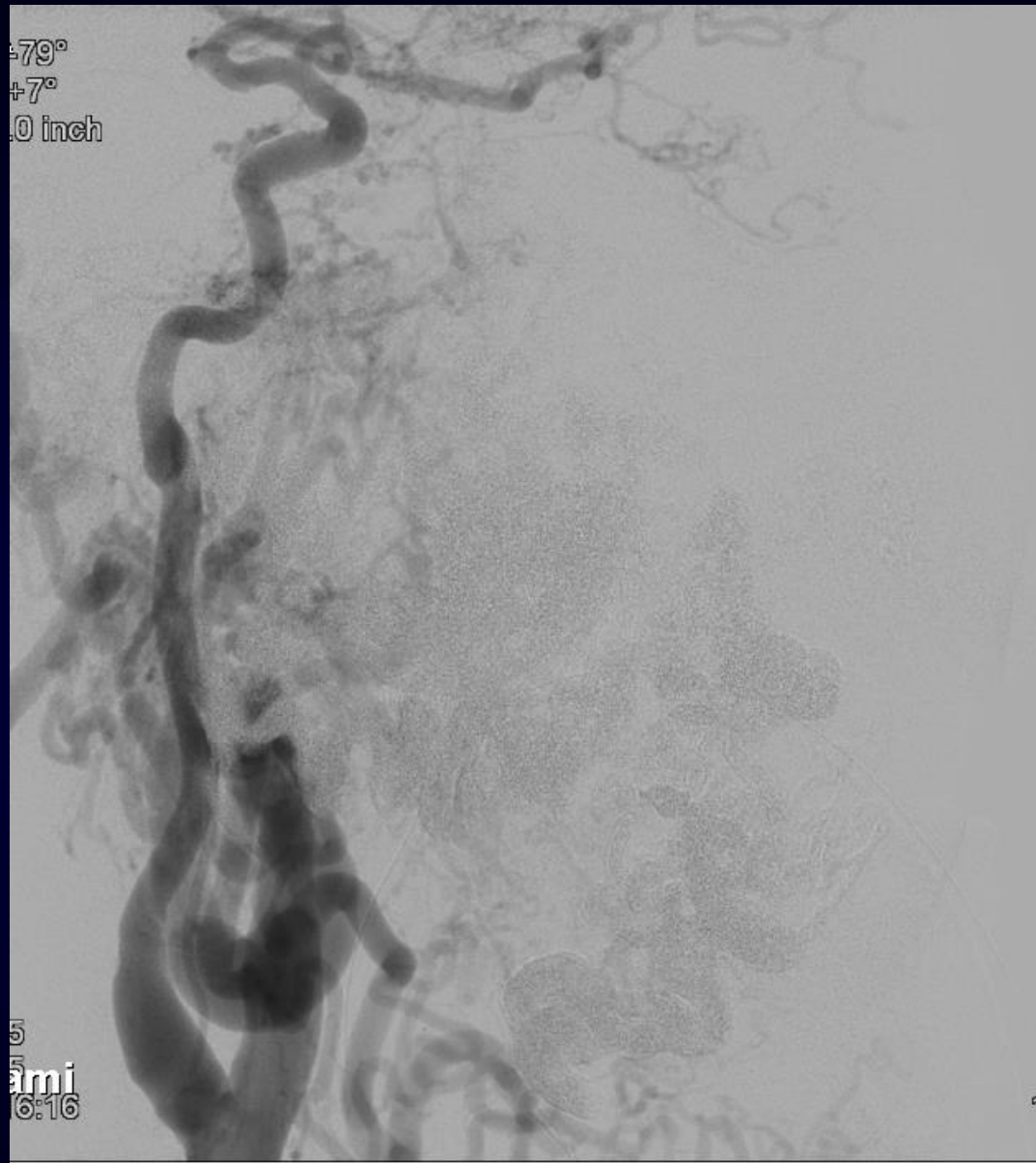
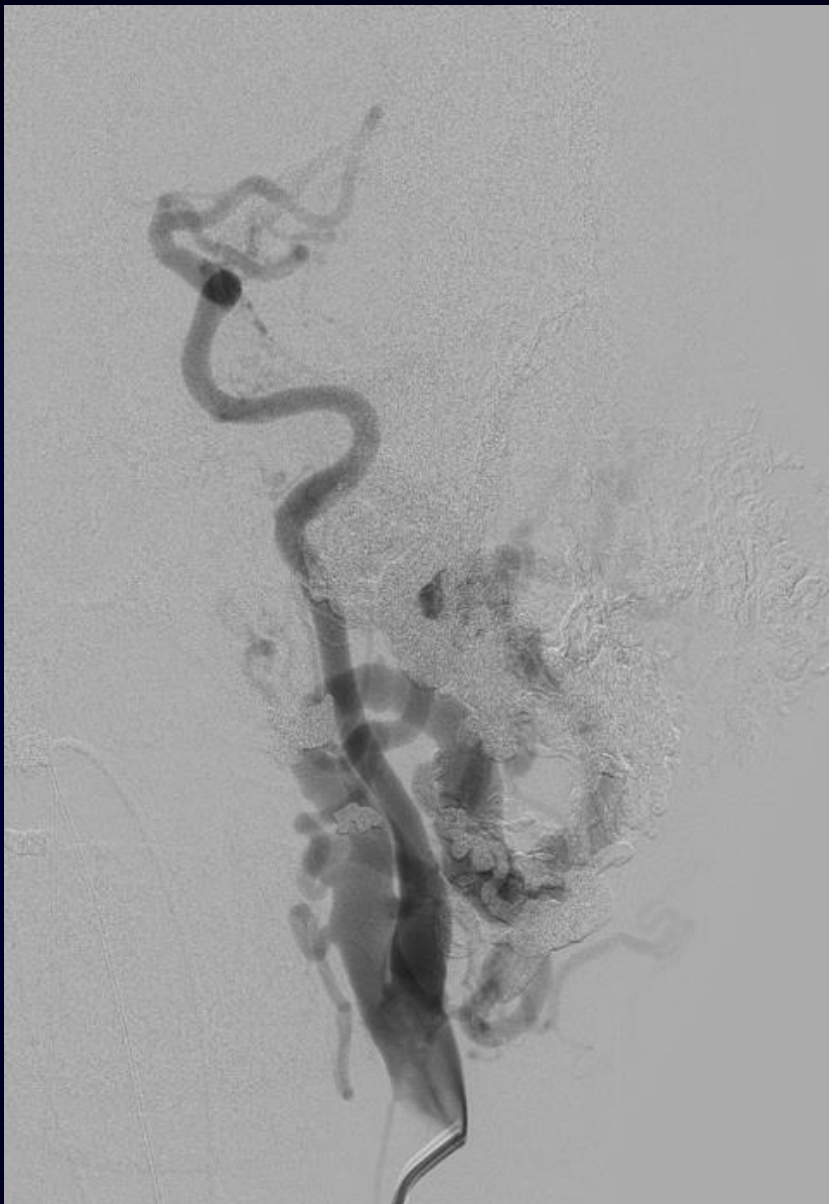






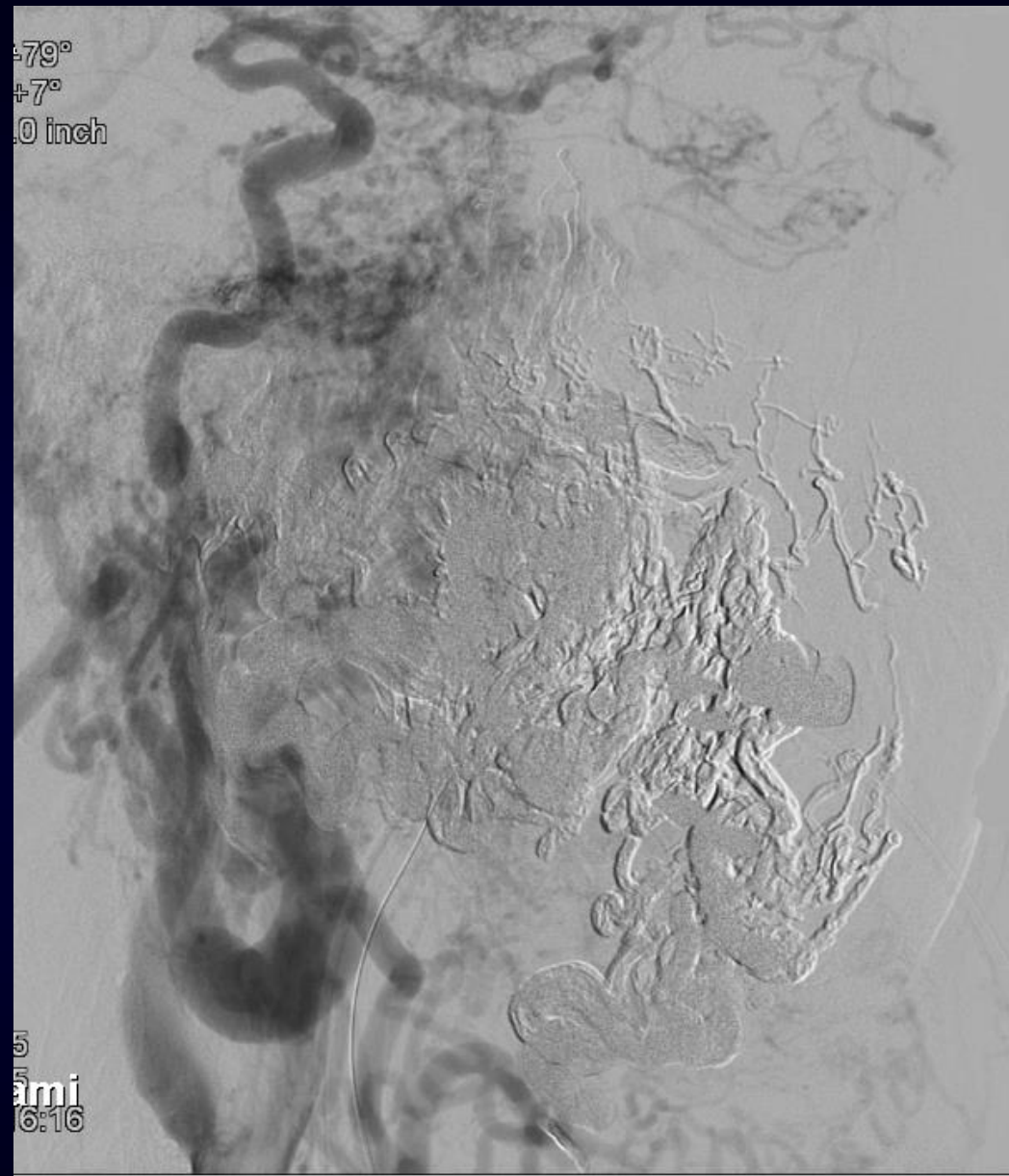
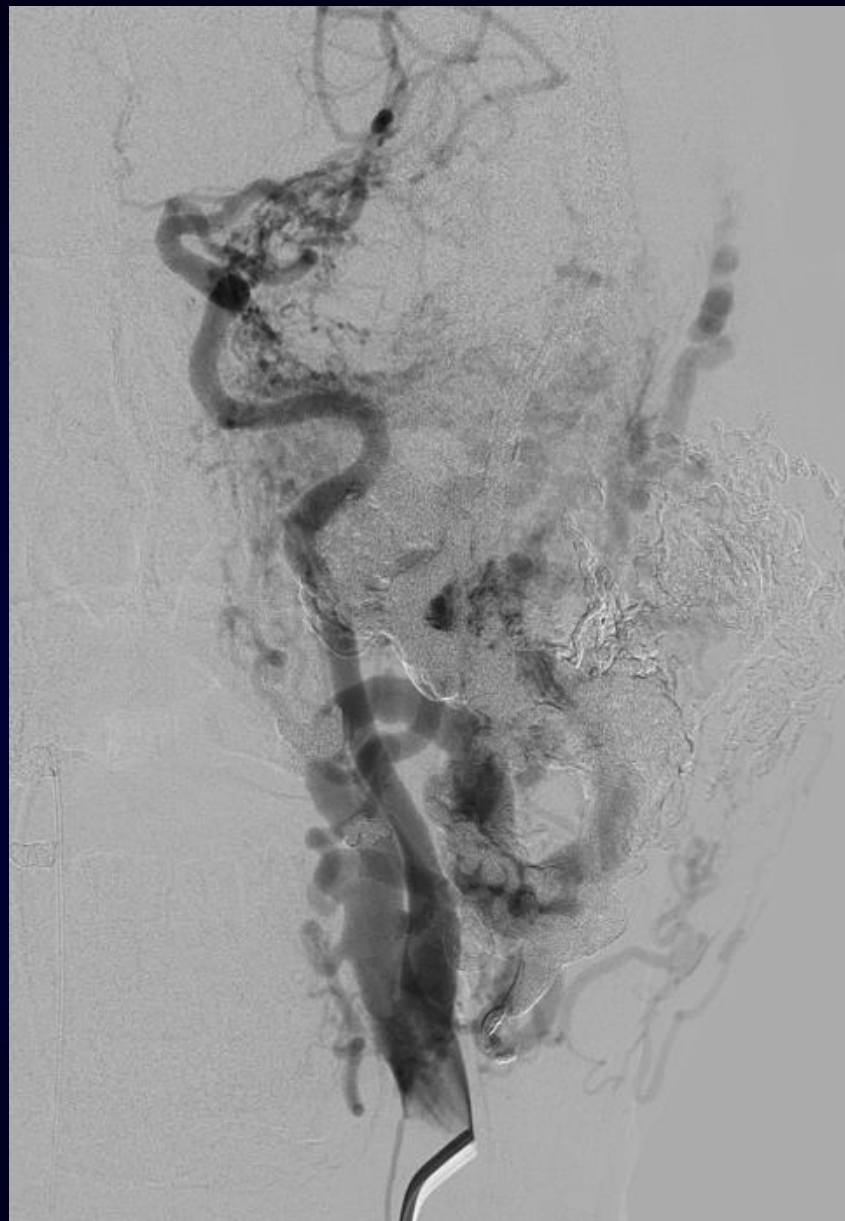


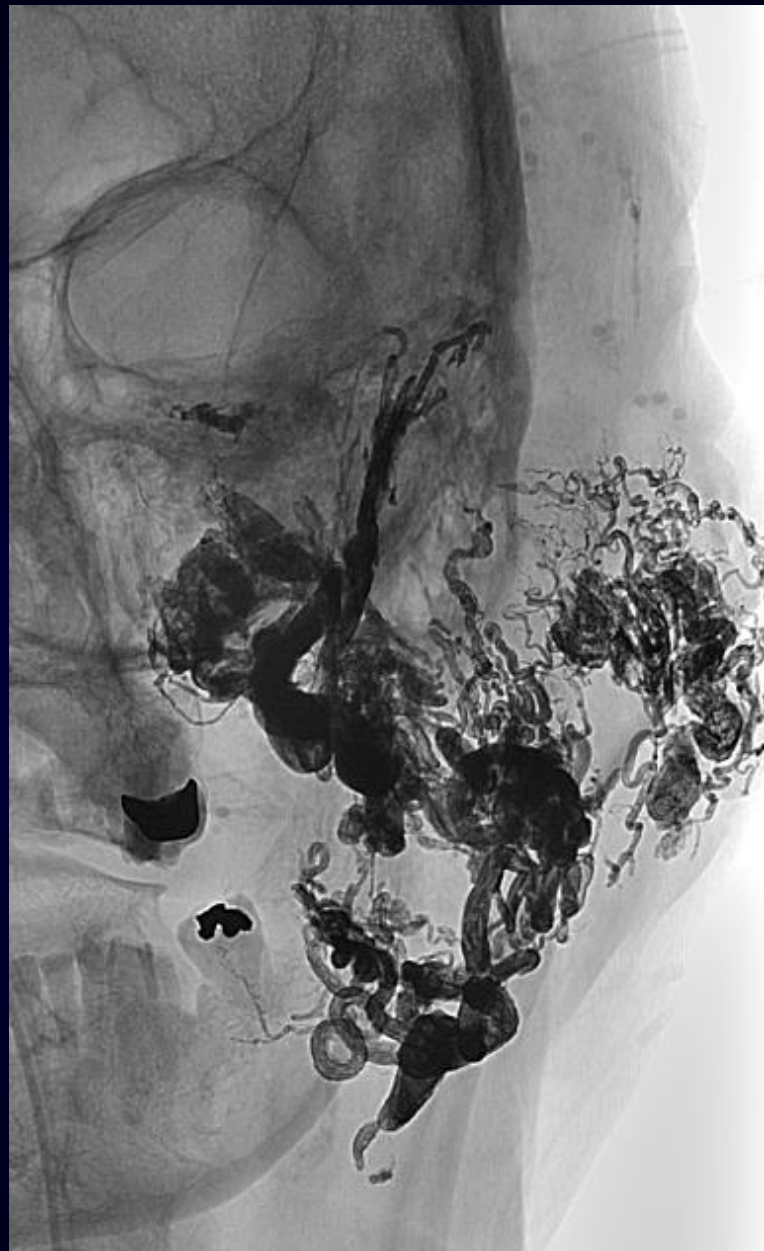




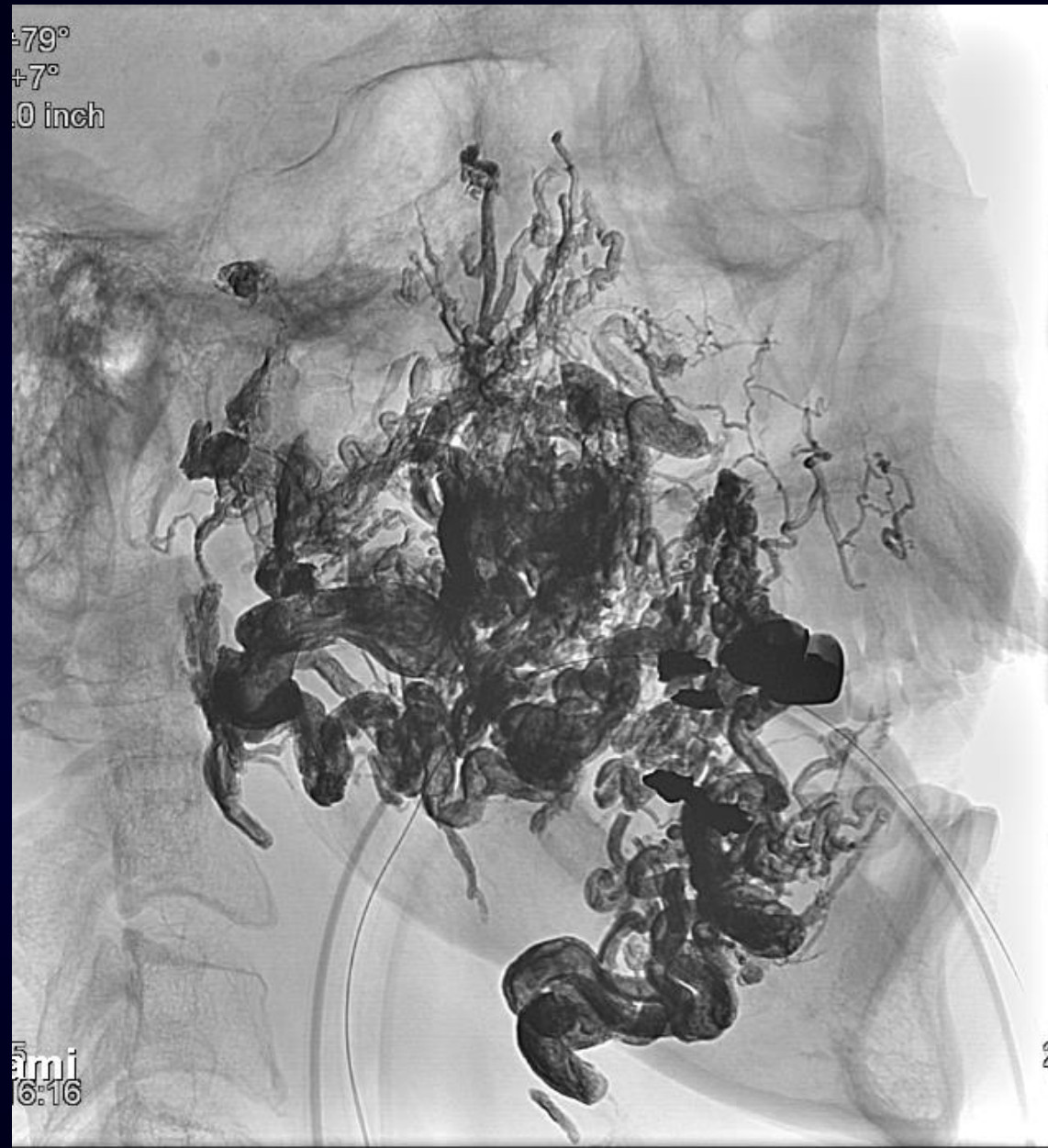
79°
+7°
1.0 inch

5
ami
16:16





-79°
+7°
.0 inch



5
ami
6:16