

# Treatment and Management of Venous Sinus Thrombosis

Sebastian Pollandt, MD

Neurocritical Care/Epilepsy

Rush University Medical Center

04/29/2016

# Disclosures

- No actual or potential conflict of interest in regards to this presentation
- The planners, editors, faculty and reviewers of this activity have no relevant financial relationships to disclose.
- This presentation was created without any commercial support.

# Learning Objectives

At the conclusion of this course participants will be able to

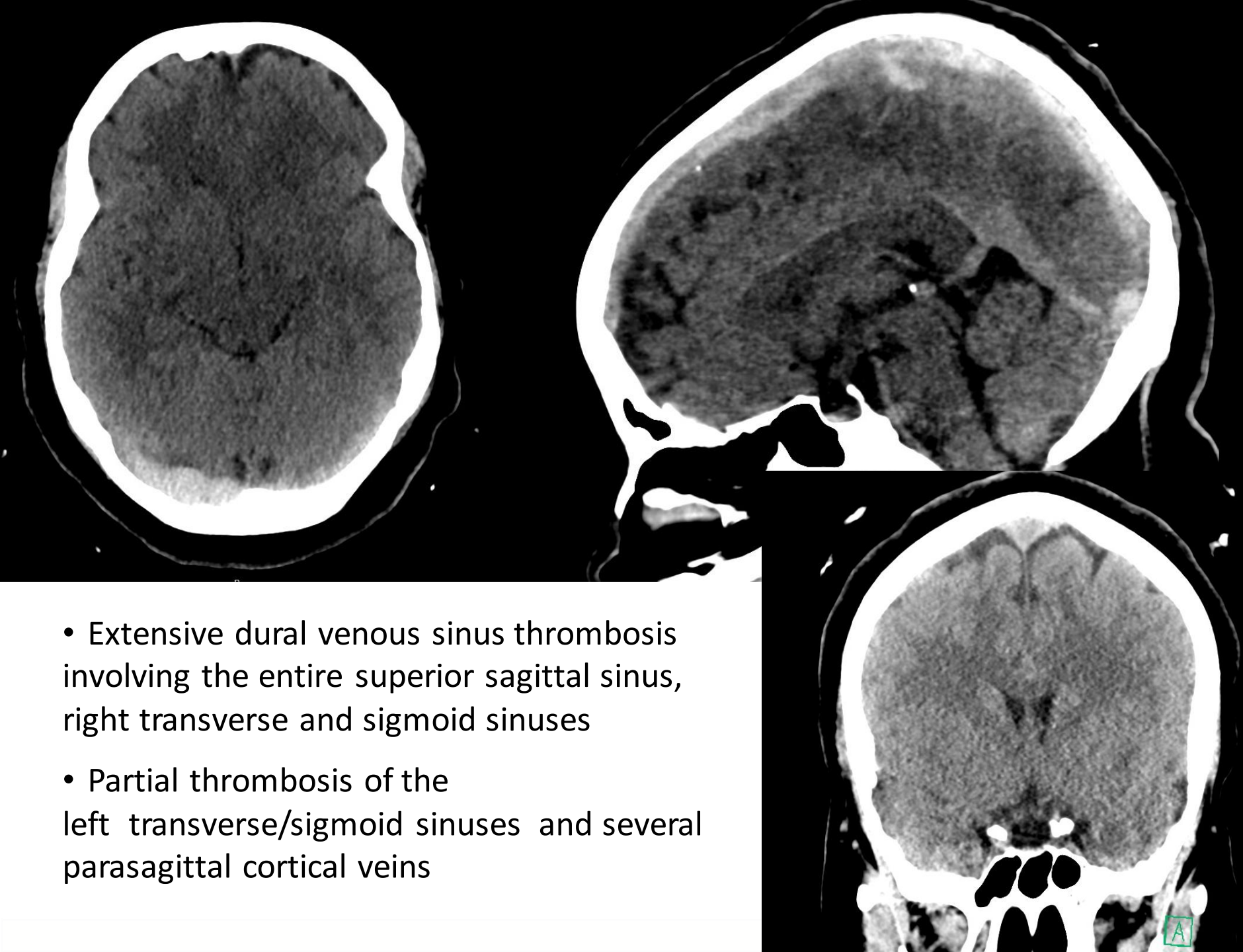
- Identify the epidemiology, pathophysiology and clinical features of cerebral venous sinus thrombosis (CVST)
- Analyze diagnostic modalities of CVST
- Evaluate principles of treatment of CVST

# Case

- 35 year old healthy Female delivered a healthy infant via C-section
- 3-4 days later, she developed headaches
- Another 3 days later, friends found her confused on the floor with her baby next to her
- Later in the day had a witnessed episode of generalized shaking

# Case

- Head CT at OSH shows cerebral sinus venous thrombosis
- Admitted, heparin drip started, transitioned to subcutaneous enoxaparin
- Had several odd episodes of generalized shaking while maintaining consciousness
- “Screaming in pain” with one of those episodes
- Repeat head imaging showed progression of CVST thrombosis despite anticoagulation
- Transfer to Rush



- Extensive dural venous sinus thrombosis involving the entire superior sagittal sinus, right transverse and sigmoid sinuses
- Partial thrombosis of the left transverse/sigmoid sinuses and several parasagittal cortical veins

Upon arrival to Rush:

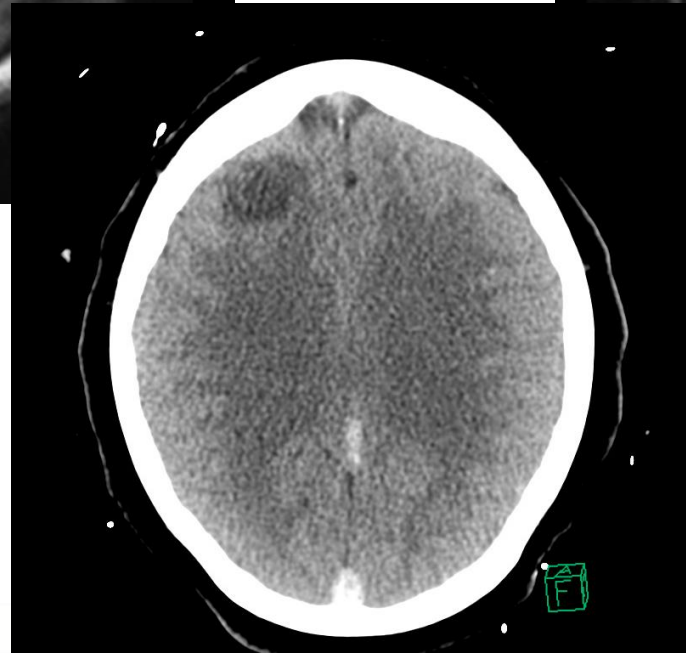
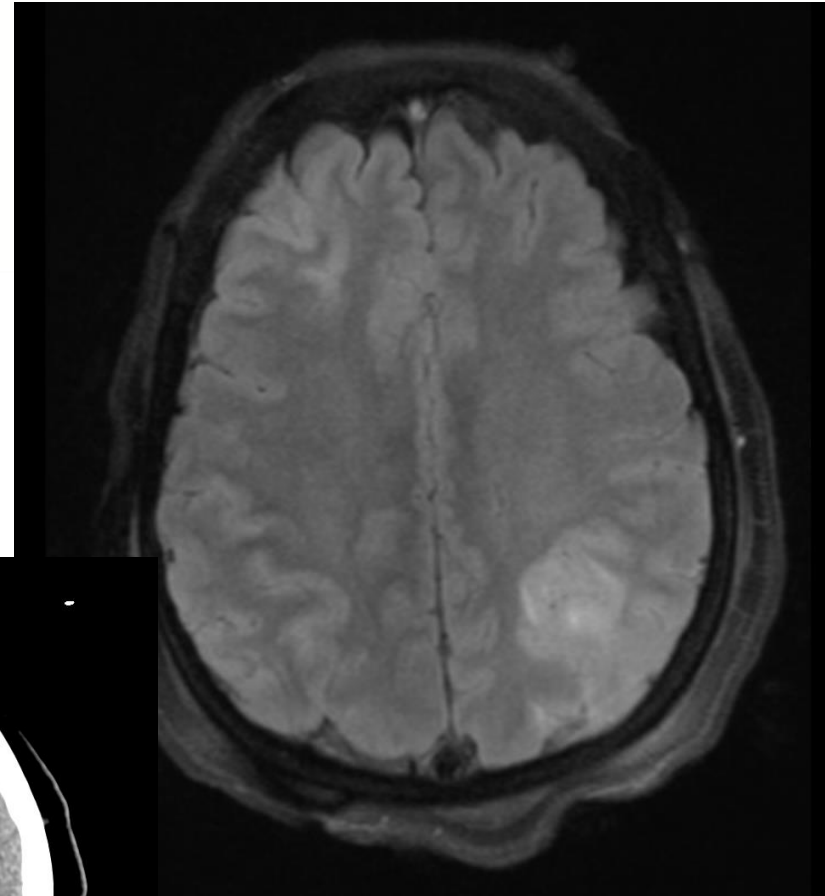
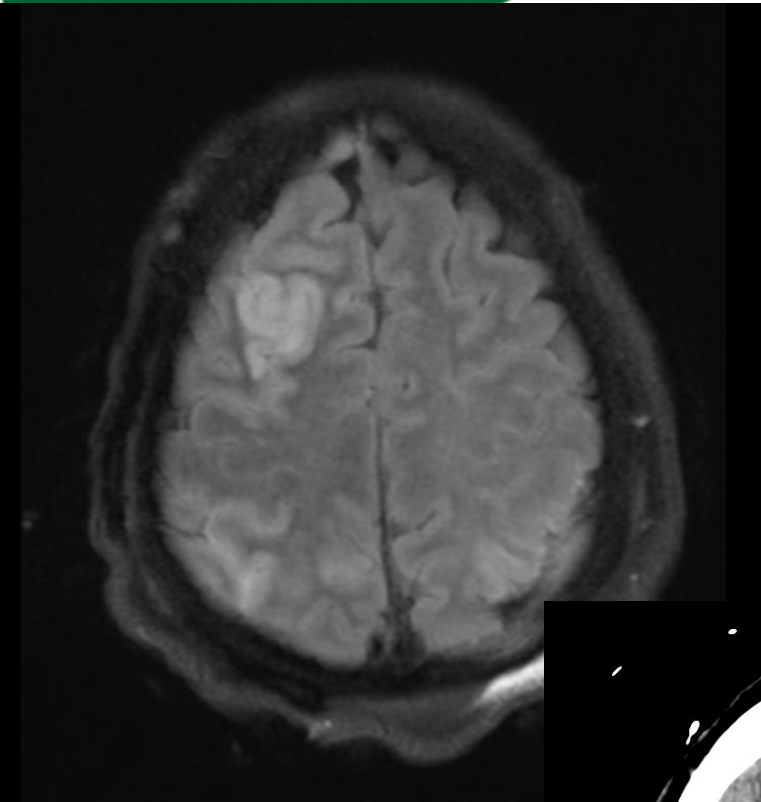
- Somnolent, but easily arousable
  - Complains of severe headache
  - Fully oriented
  - Intact cranial nerves
  - Fundoscopy shows blurred disc margins
  - Full motor strength throughout
  - No sensory deficit
- 
- Heparin gtt restarted

Next day:

- More somnolent, difficult to arouse, inattentive, non-verbal
- CN intact
- All 4 extremities drift to bed when she becomes inattentive, improves when stimulated
- Consulted endovascular team
  - Severe thrombosis of all the intracranial sinuses
  - Undergoes mechanical thrombectomy and partial recanalization of all sinuses



# Case – MRI brain/ HCT



# Case - Hospital Course

- Mental status and speech slowly improve over days
- Transitioned to coumadin
- Discharged to acute rehab

3 months later:

- Doing very well
- Neurologic exam is normal
- Headaches subsided 2-3 weeks after discharge
- Continues on warfarin, INR is therapeutic
- Levetiracetam for seizures, which have not recurred

## **Epidemiology, pathophysiology and clinical features of CVST**

# CVST - Epidemiology

- Cerebral venous thrombosis
  - Venous sinus thrombosis
  - Cortical vein thrombosis
- Relatively rare cause of stroke (<1%)
- Annual incidence estimated 3 - 7 cases per million
- Comparable incidence to acute bacterial meningitis in adults
- More common among young women and children
- Can cause devastating injury to the brain, but most patients have a good prognosis if it is recognized and treated early

# CVST - Pathophysiology

Cortical veins 17%

Posterior frontal vein

Trolar vein

Anterior frontal vein

Superior sagittal sinus  
62%

Deep venous system 11%

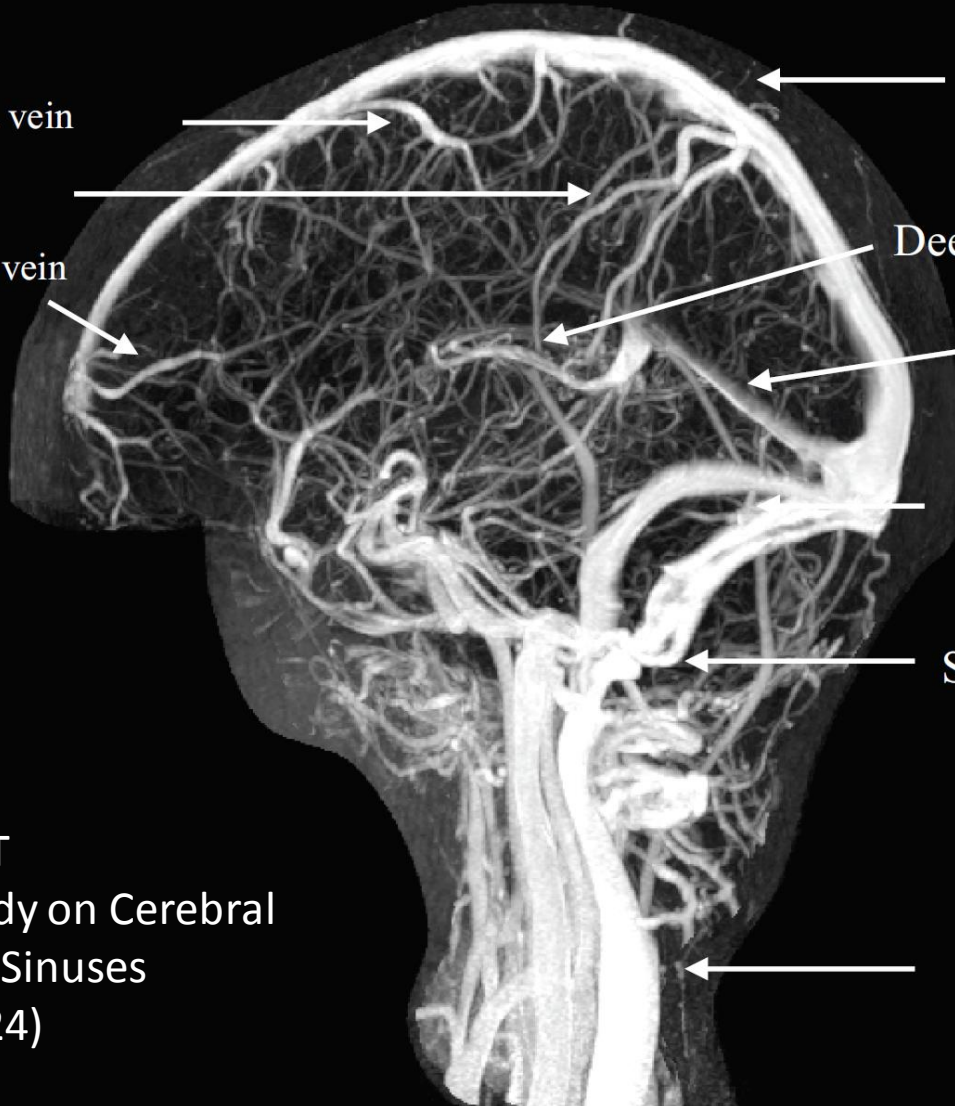
Straight sinus  
18%

Transverse (lateral)  
sinus 41-45%

Sigmoid sinus

Internal Jugular  
12%

% location of CVST  
(International Study on Cerebral  
Venous and Dural Sinuses  
Thrombosis, n= 624)



# CVST - Pathophysiology

Thrombosis of the cortical veins:

- Localized vasogenic edema
  - Venous infarction with cytotoxic edema
  - Hemorrhage
- 
- Symptoms:
    - Seizures
    - focal neurologic symptoms

# CVST - Pathophysiology

Thrombosis of the large venous sinuses:

- Obstructs venous drainage
  - Impaired CSF absorption through arachnoid villi
  - Intracranial hypertension without hydrocephalus
- Symptoms:
    - Elevated intracranial pressure
    - Bi-hemispheric symptoms (stupor, coma)

# CVST - Pathophysiology

- Multiple etiologic factors
- Usually one or more predisposing risk factors plus one inciting factor
- Thrombosis develops through common pathways of:
  - Hypercoagulability
  - Hemoconcentration
  - Direct injury or inflammation of the vessel
  - Venous stasis
- Transient and/or permanent risk factors raise suspicion for CVST and influence treatment duration



# CVST - Transient Risk Factors

- Infections
  - Central nervous system (empyema, meningitis)
  - Ear, sinus, mouth, face and neck (otitis, mastoiditis, tonsillitis, stomatitis, sinusitis, cellulitis)
  - Systemic infections (sepsis, endocarditis, tuberculosis, HIV, malaria)
- Pregnancy and puerperium
- Physical precipitants
  - Head trauma
  - Lumbar puncture, myelography, intrathecal medications, spinal anesthesia
  - Radical neck surgery
  - Neurosurgical procedures
  - Jugular and subclavian catheters

# CVST - Transient Risk Factors

- Drugs with prothrombotic action
  - Oral contraceptives
  - Hormone replacement therapy
  - Androgens
  - Medroxyprogesterone acetate
  - L- asparaginase
  - Cyclosporine
  - Tamoxifen
  - Steroids
  - Lithium
  - Thalidomide
  - Ecstasy
  - Sildenafil
- Other conditions
  - Dehydration
  - Diabetic ketoacidosis

# CVST - Permanent Risk Factors

## Prothrombotic conditions

### Genetic

- Protein S, C, antithrombin deficiencies
- Factor V Leiden
- Prothrombin mutations

### Acquired

- Antiphospholipid AB syndrome
- Nephrotic syndrome
- Cyanotic congenital heart disease

# CVST - Permanent Risk Factors

- Malignancy
  - Central nervous system (meningioma)
  - Solid tumors outside central nervous system
  - Hematological (leukemias, lymphomas)
- Hematological condition
  - Anemias (sickle cell disease and trait, iron deficiency, folic acid deficiency)
  - Paroxysmal nocturnal hemoglobinuria
  - Polycythemia (primary or secondary)
  - Thrombocythemia (primary or secondary)

# CVST - Permanent Risk Factors

- CNS disorders
  - Dural fistulae
- Inflammatory diseases
  - Behçet's disease
  - Systemic lupus erythematosus
  - Sjögren's syndrome
  - Wegener's granulomatosis
  - Temporal arteritis
  - Thromboangiitis obliterans
  - Inflammatory bowel disease
  - Sarcoidosis
- Other disorders
  - Thyroid disease
    - Hyperthyroidism
    - Hypothyroidism

# CVST - Clinical Features

- Onset acute, subacute or chronic
- Headache is most common, nearly 90% of patients
- Other common presenting symptoms:
  - Focal or generalized seizure (40%)
  - Focal motor weakness (37%)
  - Encephalopathy or change in mental status (22%)
  - Vision loss (13%)
  - Diplopia (13%)
  - Stupor or coma (13%)

# CVST - Clinical Features

- Papilledema in 25-30% of patients
- Thrombosis of the cavernous sinus produces a characteristic syndrome:
  - Orbital pain
  - Proptosis
  - Chemosis
  - Variable dysfunction of cranial nerves III, IV, V, and VI

# Learning Objectives

## **Diagnosis of CVST**



# CVST - Diagnosis

High degree of clinical suspicion is key to the diagnosis

- Head CT
- CT Venography (CTV)
- MRI/MRV
- Catheter Angiography (DSA)

# CVST Diagnosis

## Head CT

- Non-contrast head CT may be normal
- Cannot exclude a diagnosis of CVST
- Suspicious findings include:
  - Cerebral edema
  - Bilateral infarction
  - Infarction in a non-arterial distribution
  - Lobar intracerebral or subarachnoid hemorrhage
  - Hyperdense thrombosed cortical veins
  - Hyperdensities within the venous sinuses

## **CT Venography (CTV)**

- Sensitivity of 95% compared with digital subtraction angiography, widely available, quick
- Less expensive than MRI
- Less invasive than conventional angiography
- Provides good visualization of the major venous sinuses
- Suboptimal for thrombosis in deep venous structures and cortical veins
- Radiation exposure and administration of intravenous contrast

# CVST - Diagnosis

## MRI/MRV

- MRI in combination with time-of-flight or contrast enhanced MR venography (MRV) → highly sensitive for the diagnosis CVST
- Abnormal T1 and/T2 signal within the venous sinus and absence of normal flow through the venous sinus on MRV confirms the diagnosis
- Age of the thrombus determines T1 and T2 signal characteristics

## **Catheter Angiography (DSA)**

- CTV or MRI/MRV is usually adequate for the diagnosis or exclusion of CSVT
- DSA may be necessary for:
  - Identification of an isolated cortical vein thrombosis without venous sinus involvement
  - Diagnosis and characterization of dural arteriovenous fistula associated with a CVST

# Learning Objectives

## **Treatment of CVST**

## Anticoagulation

- Cornerstone of treatment for CVST
- Prevent extension of the thrombosis and support spontaneous thrombus resolution
- Indicated even in the presence of intracranial hemorrhage

# CVST - Treatment

## Original Contributions

### Randomized, Placebo-Controlled Trial of Anticoagulant Treatment With Low-Molecular-Weight Heparin for Cerebral Sinus Thrombosis

S.F.T.M. de Bruijn, MD; J. Stam, MD; for the Cerebral Venous Sinus Thrombosis Study Group

*“no new symptomatic cerebral hemorrhages. Anticoagulation proved safe, even in patients with cerebral hemorrhage”*

Lancet. 1991 Sep 7;338(8767):597-600.

### Heparin treatment in sinus venous thrombosis.

Einhäupl KM<sup>1</sup>, Villringer A, Meister W, Mehraein S, Garner C, Pellkofer M, Haberl RL, Pfister HW, Schmiedek P.

#### Author information

Patients with ICH and CVST:

27 treated with IV heparin, 4 died (mortality 15%)

13 not treated with heparin, 9 died (mortality 69%)

*“ICH is not a contraindication to heparin treatment”*



# CVST - Treatment

- American Heart Association recommendations:

*“...initial anticoagulation with adjusted-dose UFH or weight-based LMWH in full anticoagulant doses is reasonable, followed by vitamin K antagonists, regardless of the presence of ICH”*

*(Class IIa; Level of Evidence B)*

*“Continuation of oral anticoagulation with vitamin-K antagonists is reasonable for 3-6 months followed by antiplatelet therapy”*

*(Class IIa, Level B)*

- Essentially identical recommendations from (now defunct) European Federation of Neurological Societies

## Thrombolytics and Endovascular Treatment Options

- Numerous case reports using localized thrombolytics and mechanical clot disruption
- No controlled trials to establish efficacy or safety of these therapies
- Appropriate agent, dose, route of administration and clinical situation have yet to be defined
- Increased risk of intracranial hemorrhage is most commonly reported complication
- Thrombolytic and endovascular treatment should be limited to select patients who decline despite anticoagulation
- Should be performed only in centers with sufficient expertise in neuro-endovascular interventions

## Seizures

- Most common in patients with
  - Focal edema
  - Venous infarcts
  - Intracranial hemorrhage
- Prophylactic anticonvulsants may be considered
- Duration of treatment depends on:
  - Seizure recurrence (unprovoked, 5% to 32% of patients)
  - EEG findings in follow-up
  - Tolerability of antiseizure drugs

## Intracranial Pressure

- Intracranial hemorrhage, edema and infarction lead to localized mass effect
- Venous outflow impairment causes decreased CSF reabsorption, communicating hydrocephalus and intracranial hypertension
- Hyperosmolar therapy (mannitol, hypertonic saline) should be administered to patients at risk for cerebral herniation
- Acetazolamide is reasonable to reduce CSF production
- CSF diversion (lumbar puncture, ventriculostomy) or optic nerve decompression can be effective if there is progressive visual loss
- Resection of hemorrhagic infarction or decompressive craniectomy may be required
- Anticoagulation should be resumed as soon as possible following surgical intervention

- Recanalization
  - At 3 months → 84%
  - At 1 year → 85%
  - Highest recanalization rates in deep cerebral veins and cavernous sinus thrombosis, lowest in lateral sinus thrombosis
- In adults, recanalization of the occluded sinus is not related to outcome

# CVST - Outcome

- 3% to 15% of patients die in the acute phase
- Patients at risk:
  - Depressed consciousness
  - Altered mental status
  - Thrombosis of the deep venous system
  - Right hemisphere hemorrhage
  - Posterior fossa lesions.
- Main cause of acute death with CVT is transtentorial herniation due to large hemorrhagic lesion
- Second is herniation due to multiple lesions or to diffuse brain edema.
- Status epilepticus, medical complications, and PE are other causes

# CVST - Outcome

- 79% of patients will have complete recovery
- 9.7% are functionally dependent (mRS 3 or greater)
- 50% of survivors feel depressed or anxious, minor cognitive or language deficits may preclude them from resuming previous jobs
- Abulia, executive deficits, and amnesia → result from thrombosis of the deep venous system, with bilateral panthalamic infarcts
- Memory deficits, behavioral problems, or executive deficits may persist

Questions?