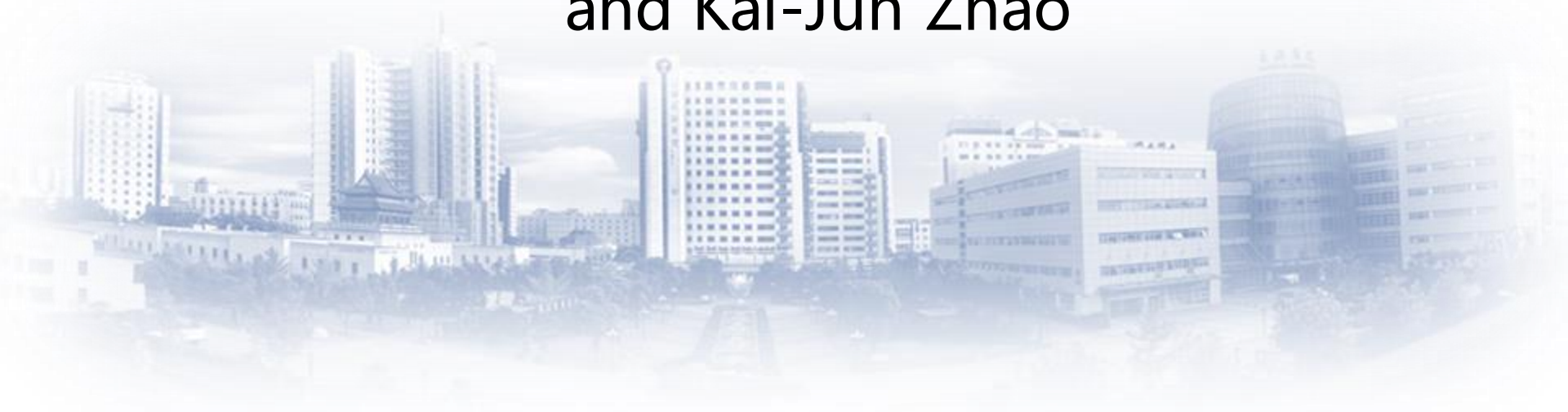



Changhai Hospital

Lvis Jr-assisted coiling for MCA-AN

Operator : Dr. Qing-hai Huang, Peng-Fei Yang,
and Kai-Jun Zhao



Clinical Data

Male , 76Y

CC : Dizziness for 1 week

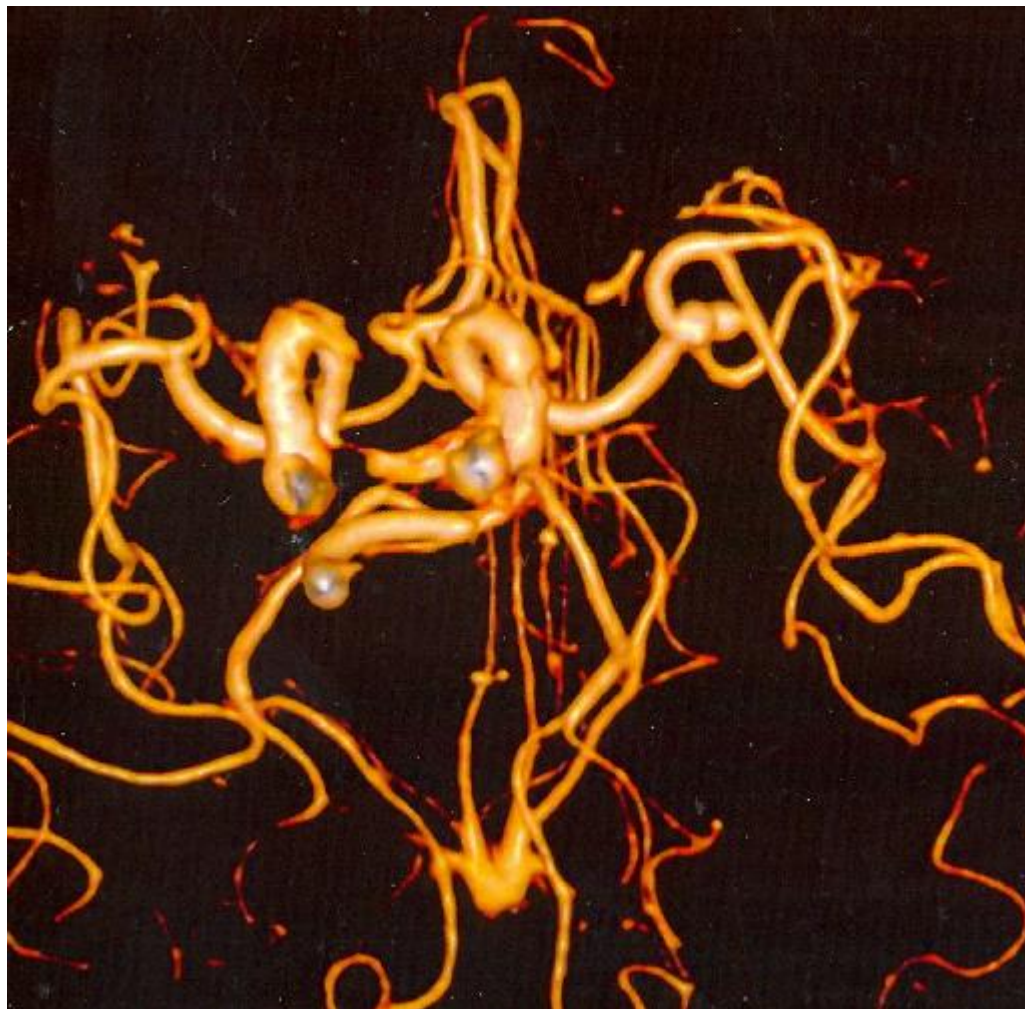
PE : negative

PH : negative

DX : MCA-AN

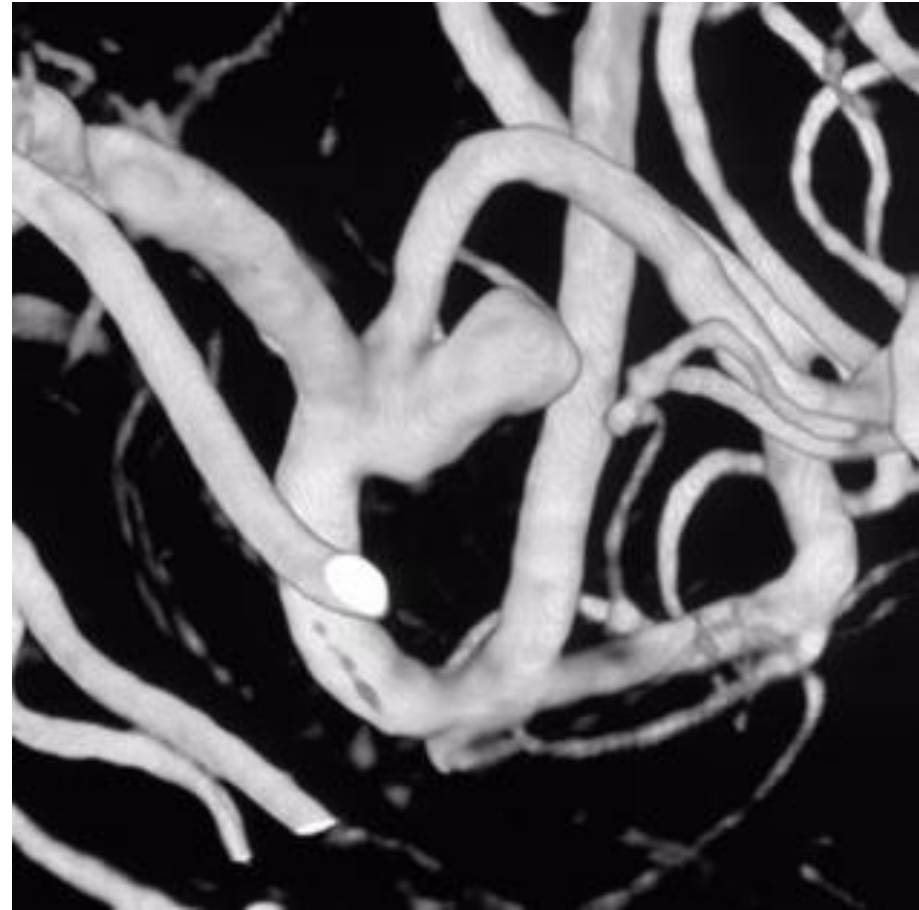
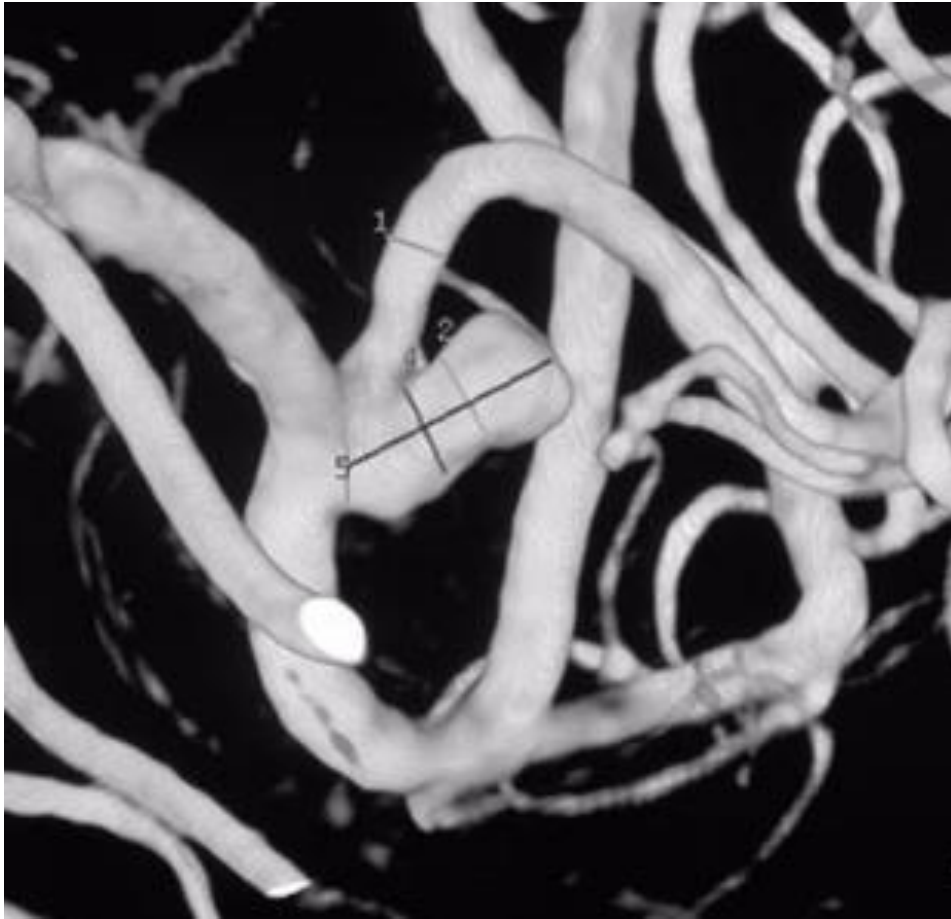


Local Hospital

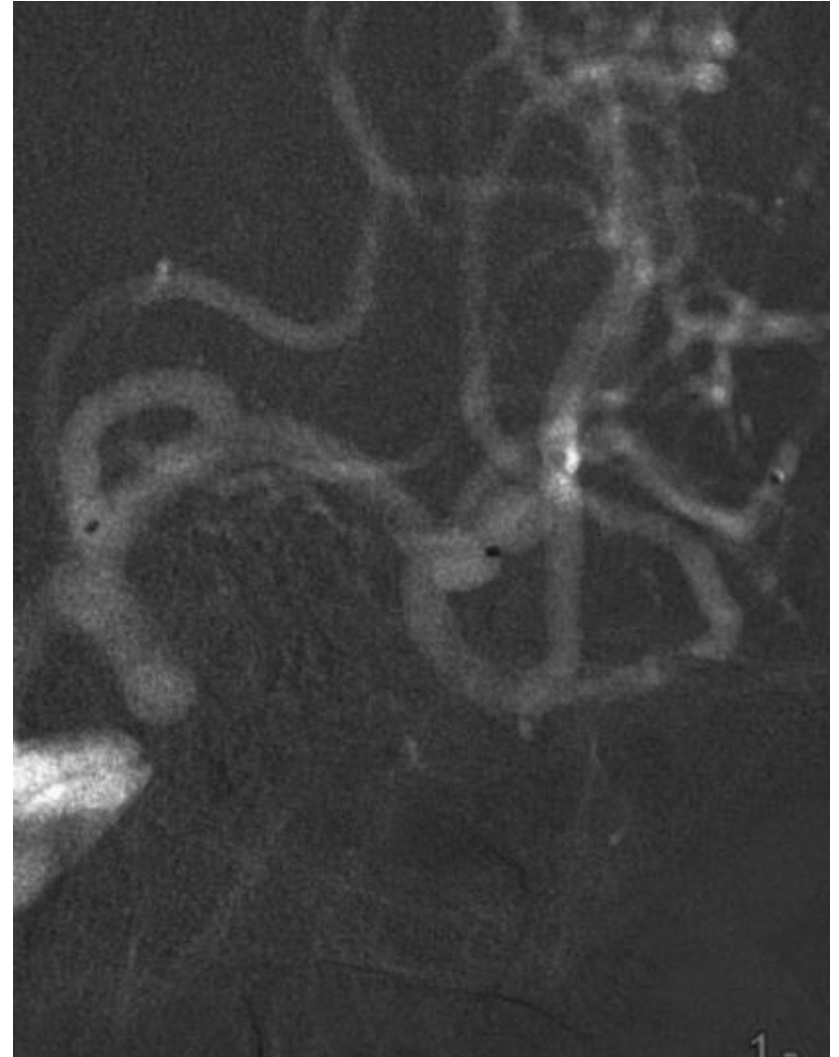
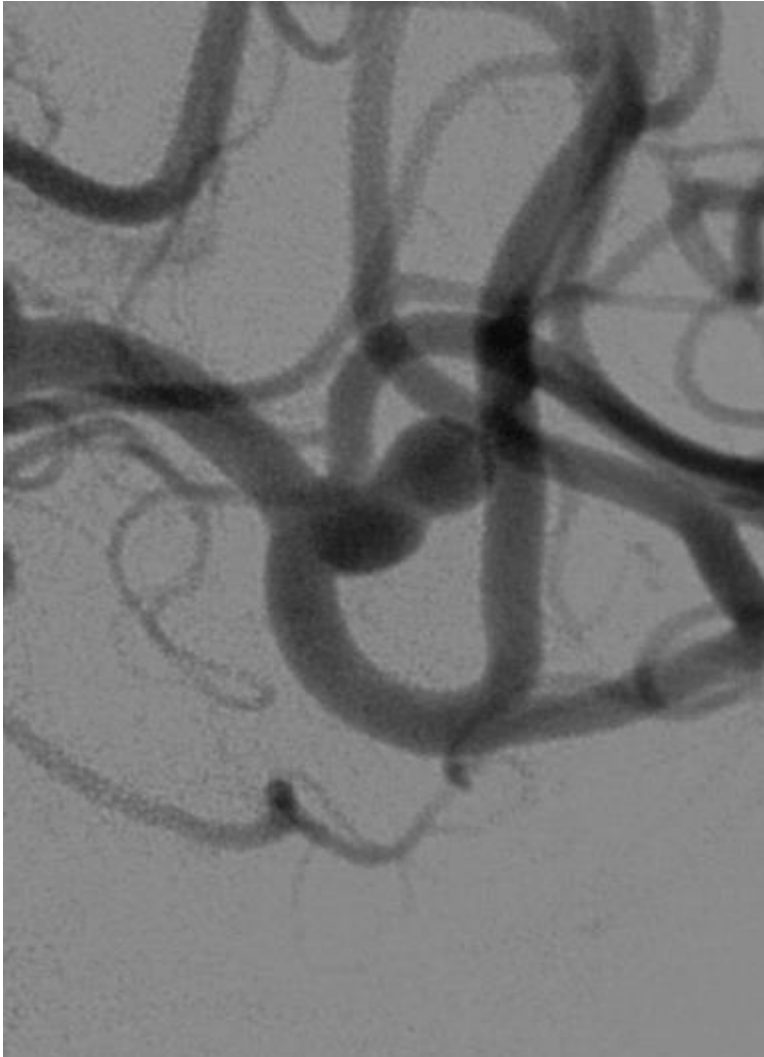


Changhai Hospital | Shanghai, China

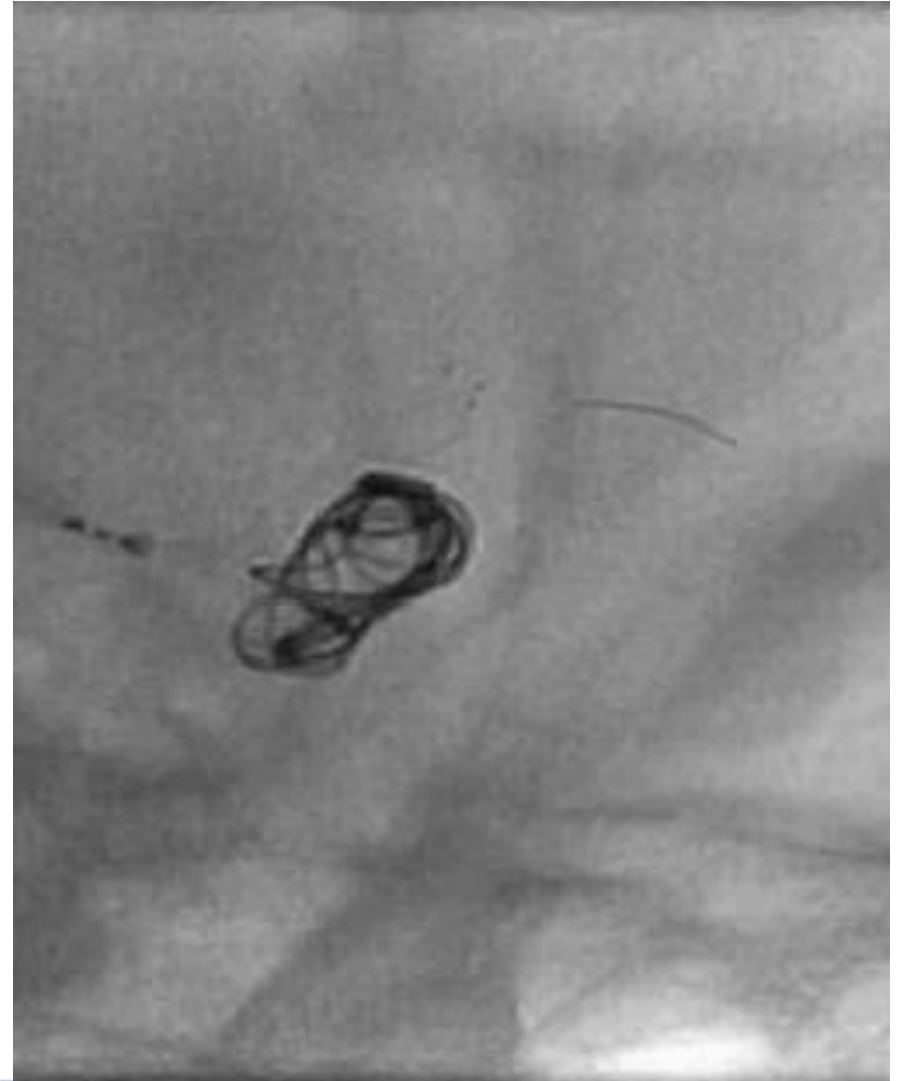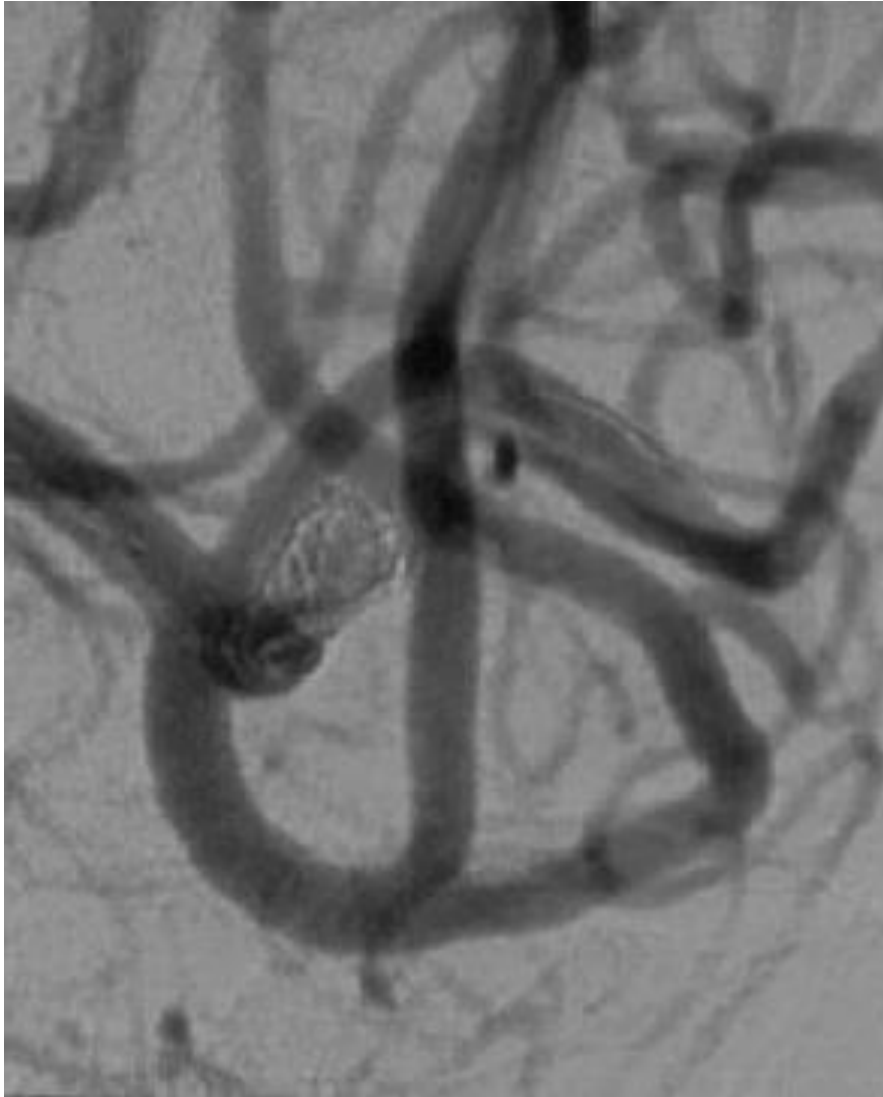
3D Reconstruction



L-MCA-AN and 2 microcathter location



Coiling followed by LVIS jr stent Release

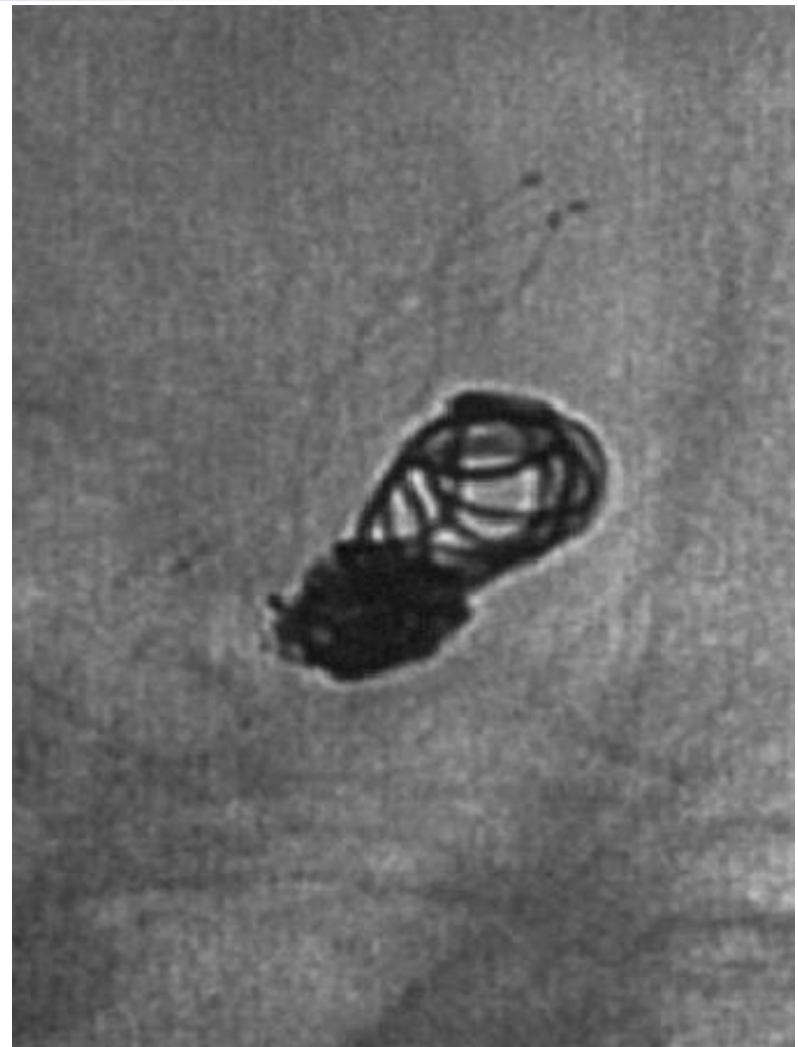
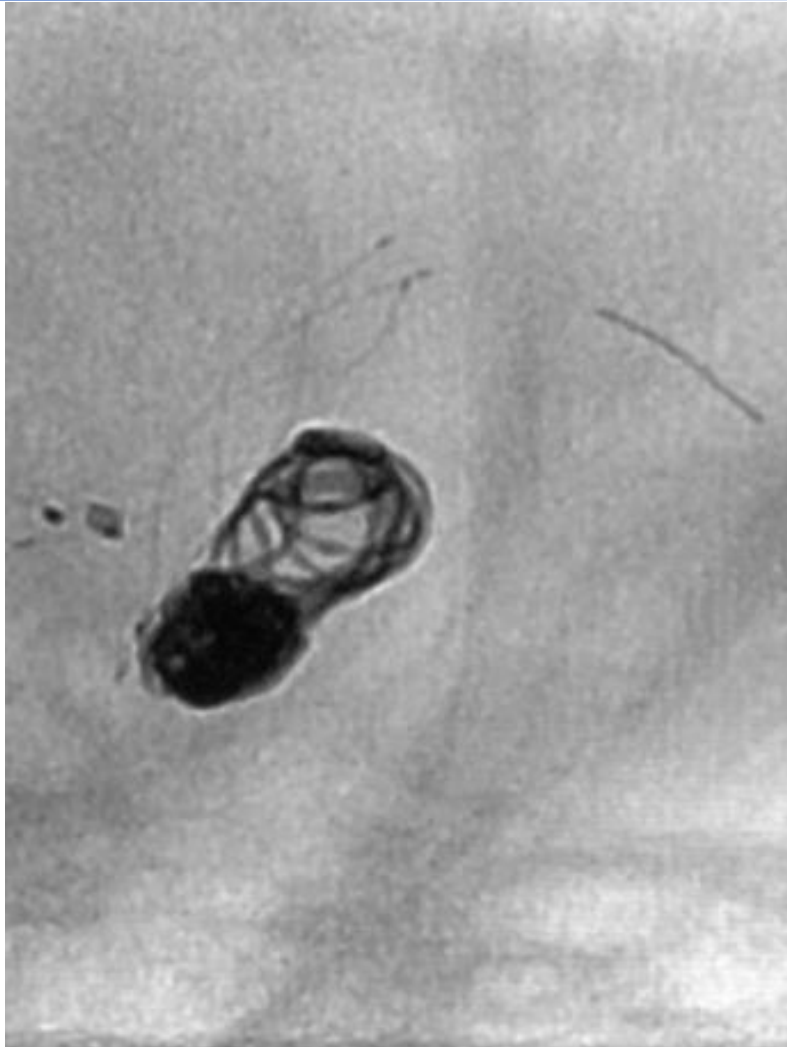

Stent Release

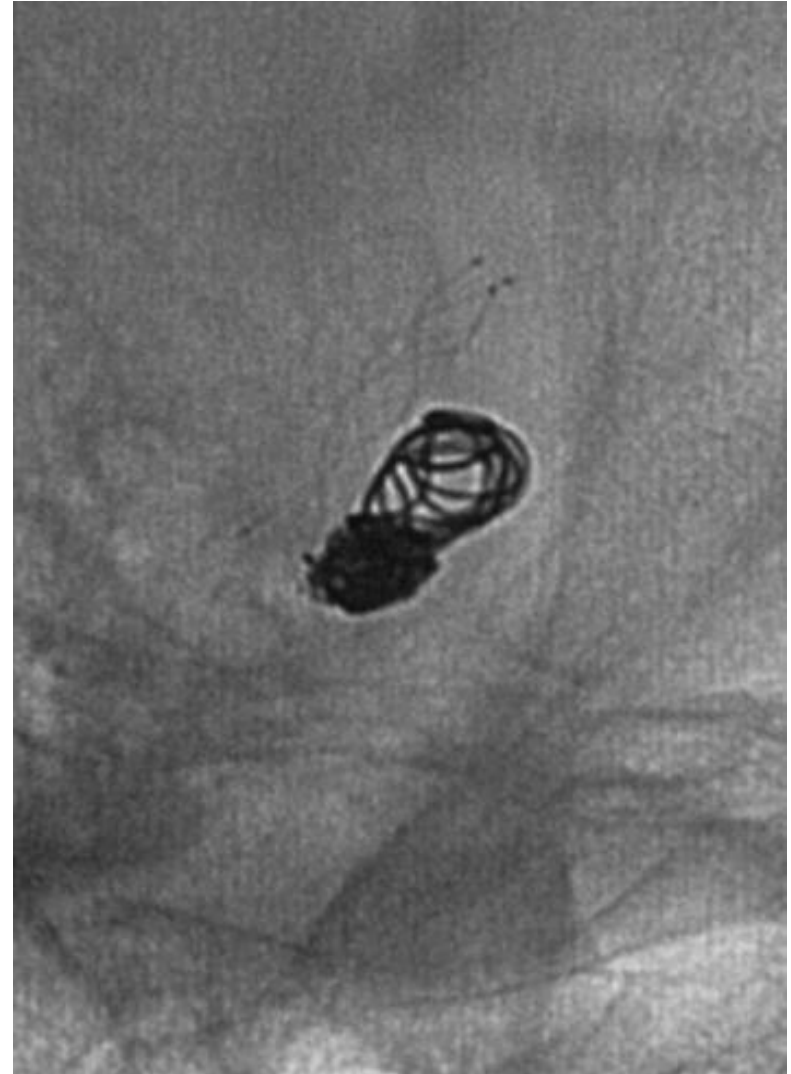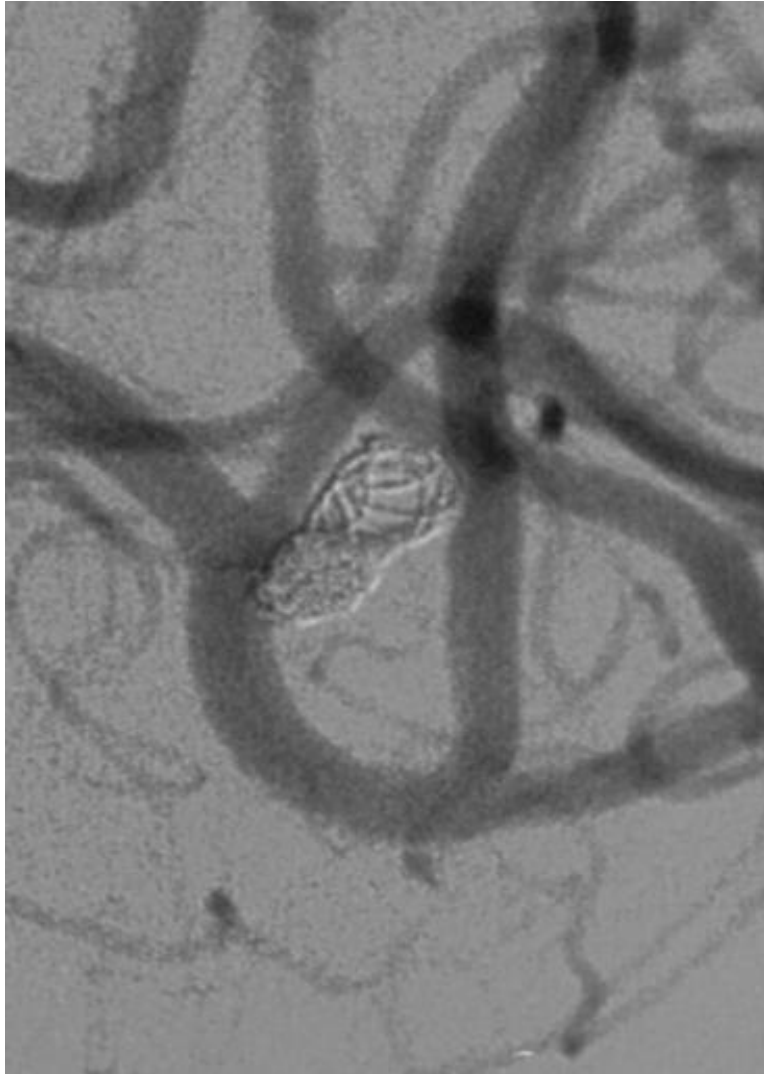


Changhai Hospital | Shanghai, China

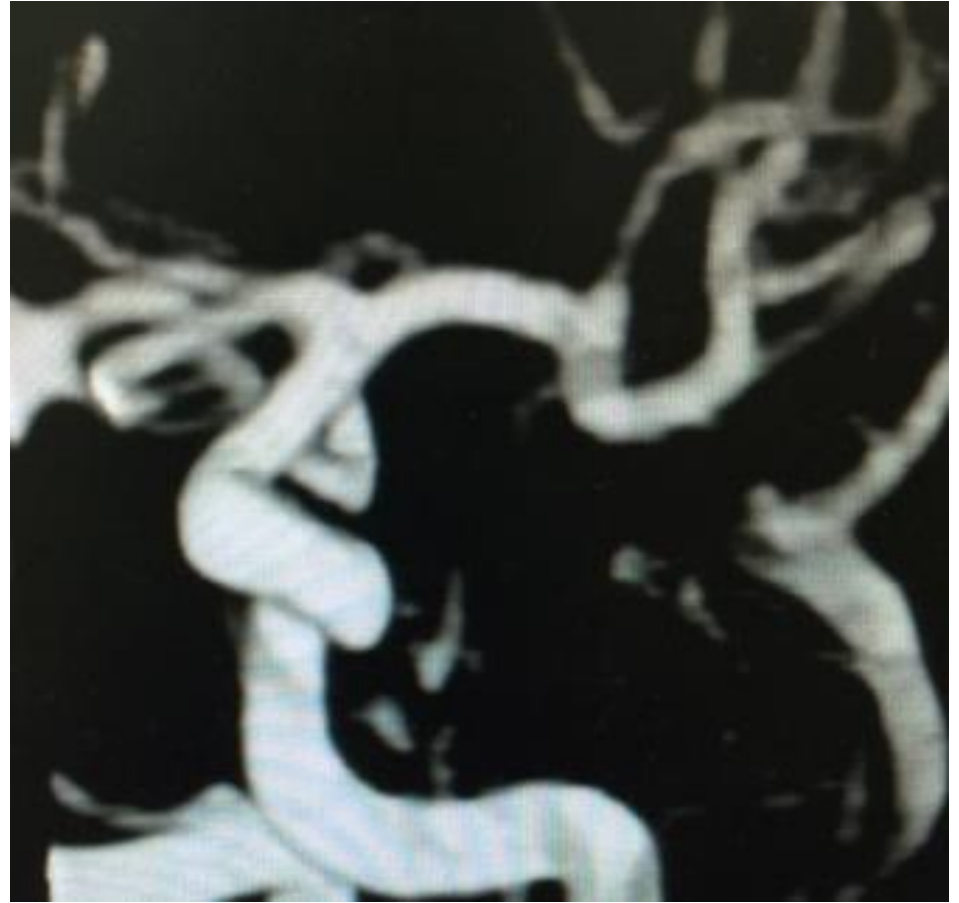
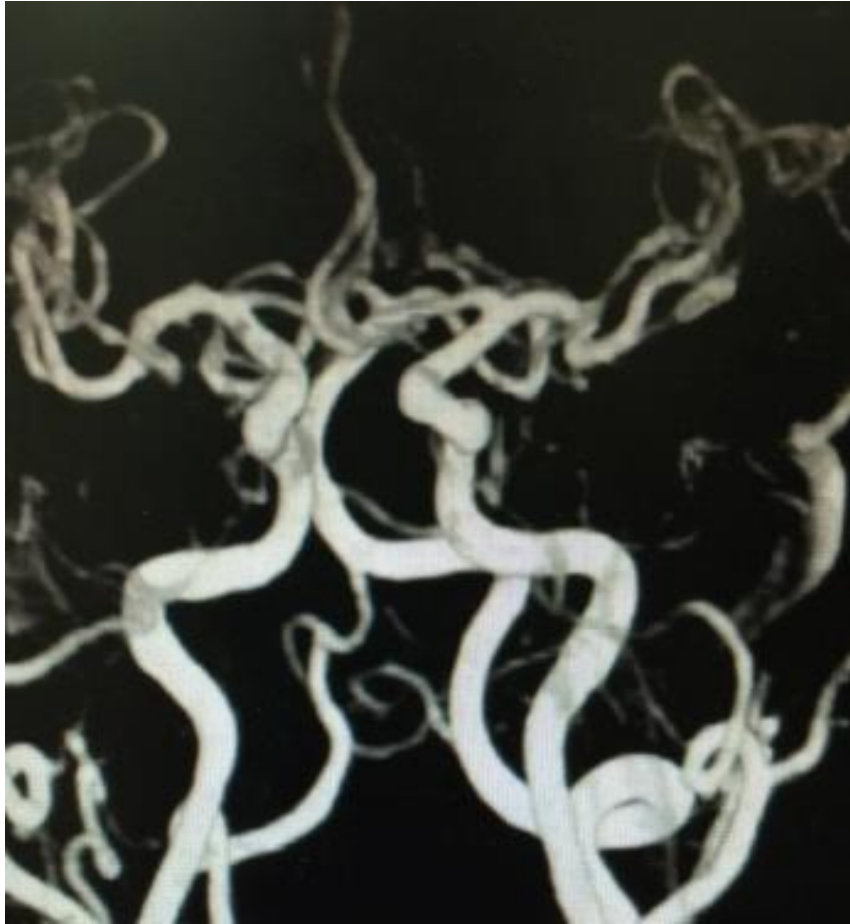
The Released LVIS jr stent location



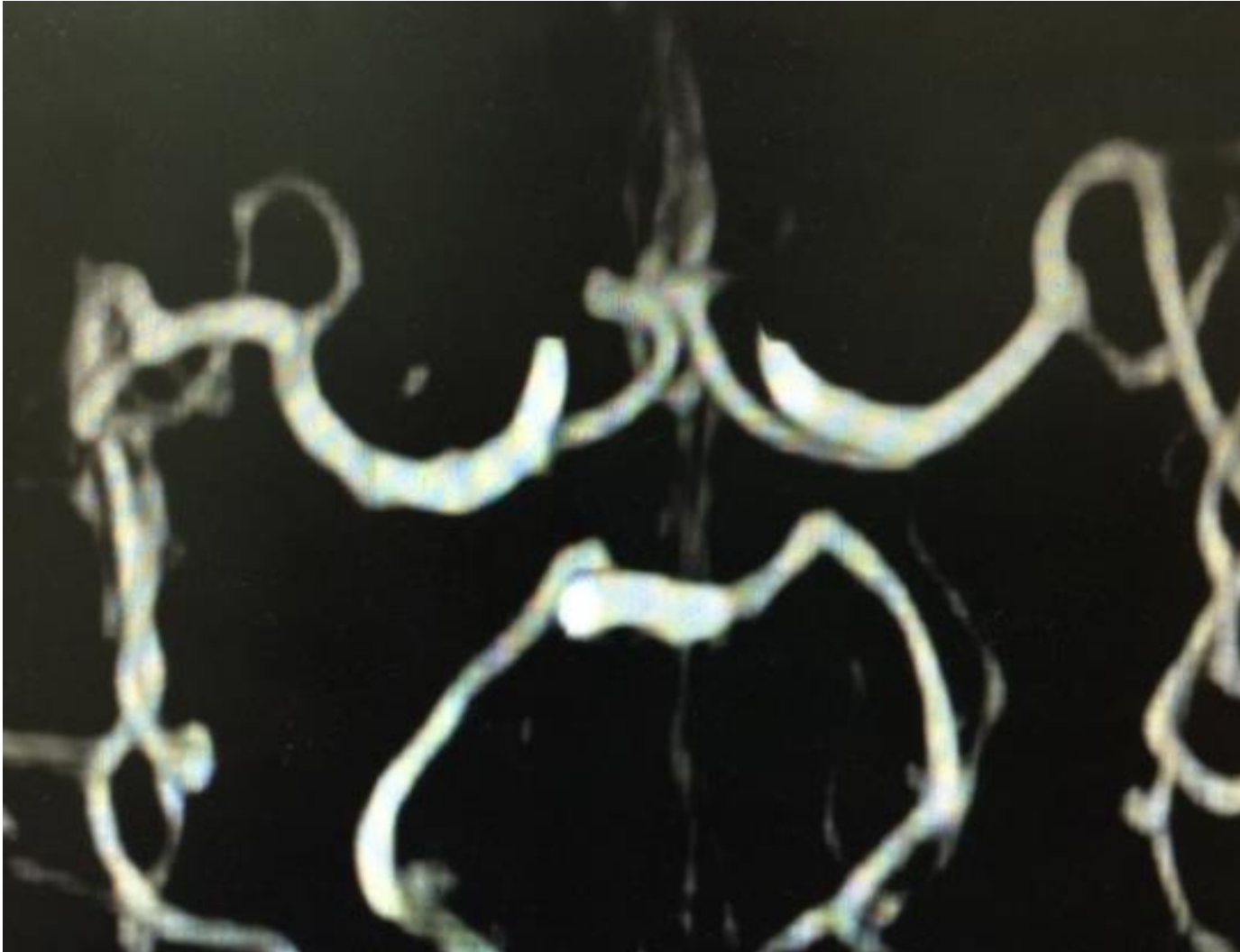
Immediate Result



2 Days Follow-up of MRA



2 Days Follow-up of MRA



Thanks !



Changhai Hospital | Shanghai, China