

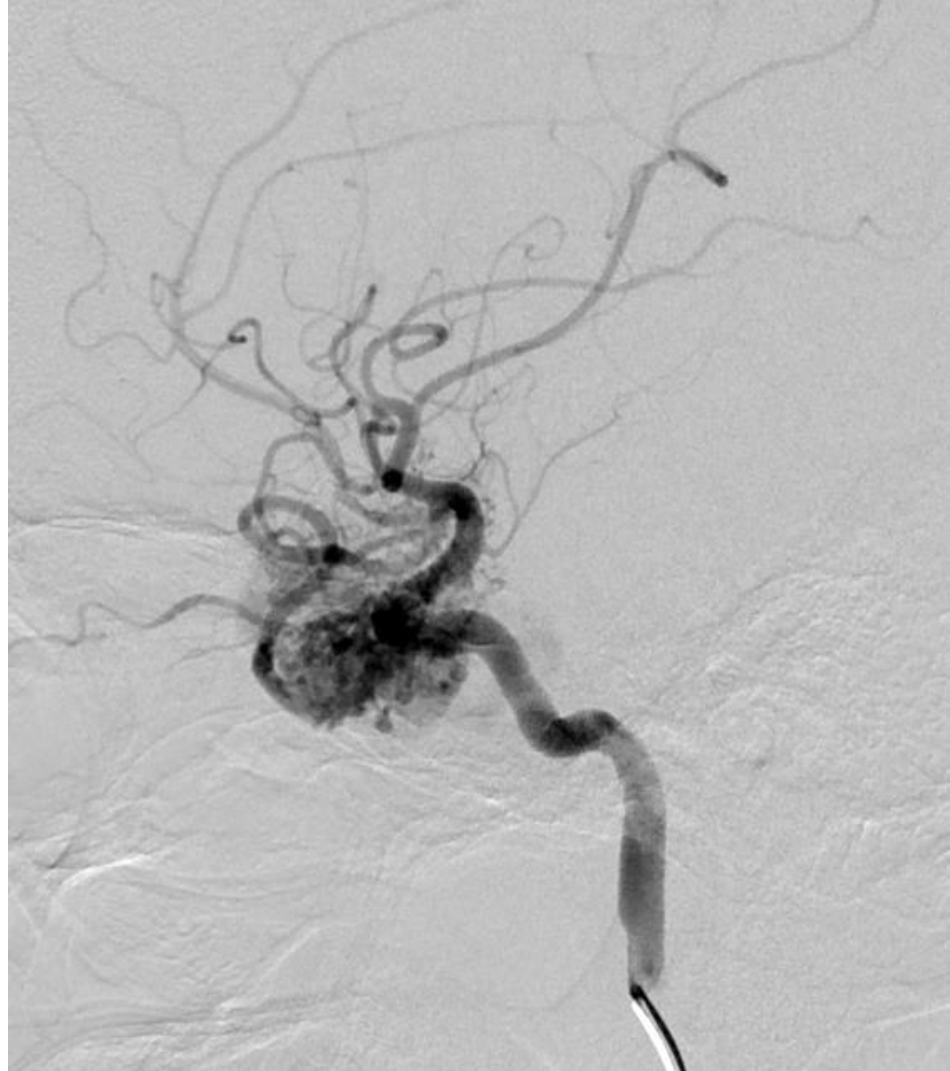
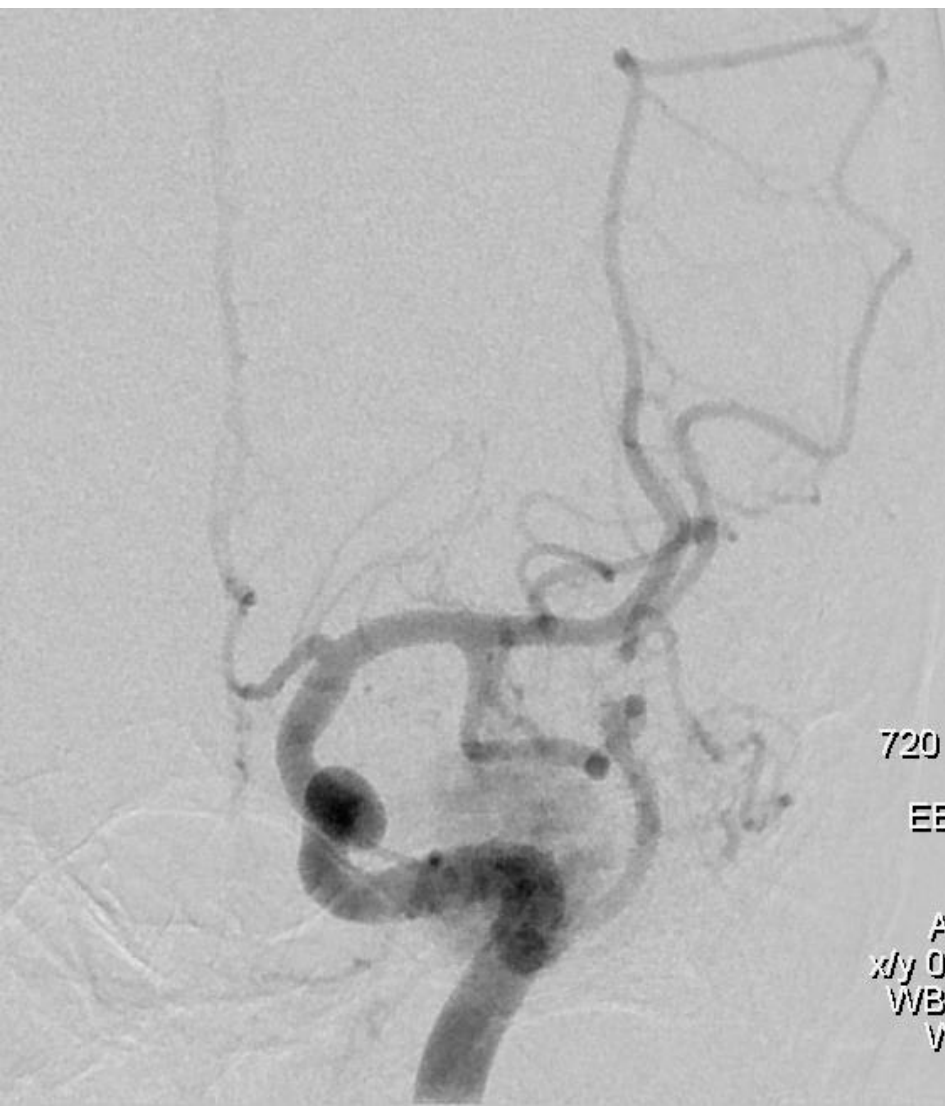
Pressure Cooker Technique in BAVM Treatment

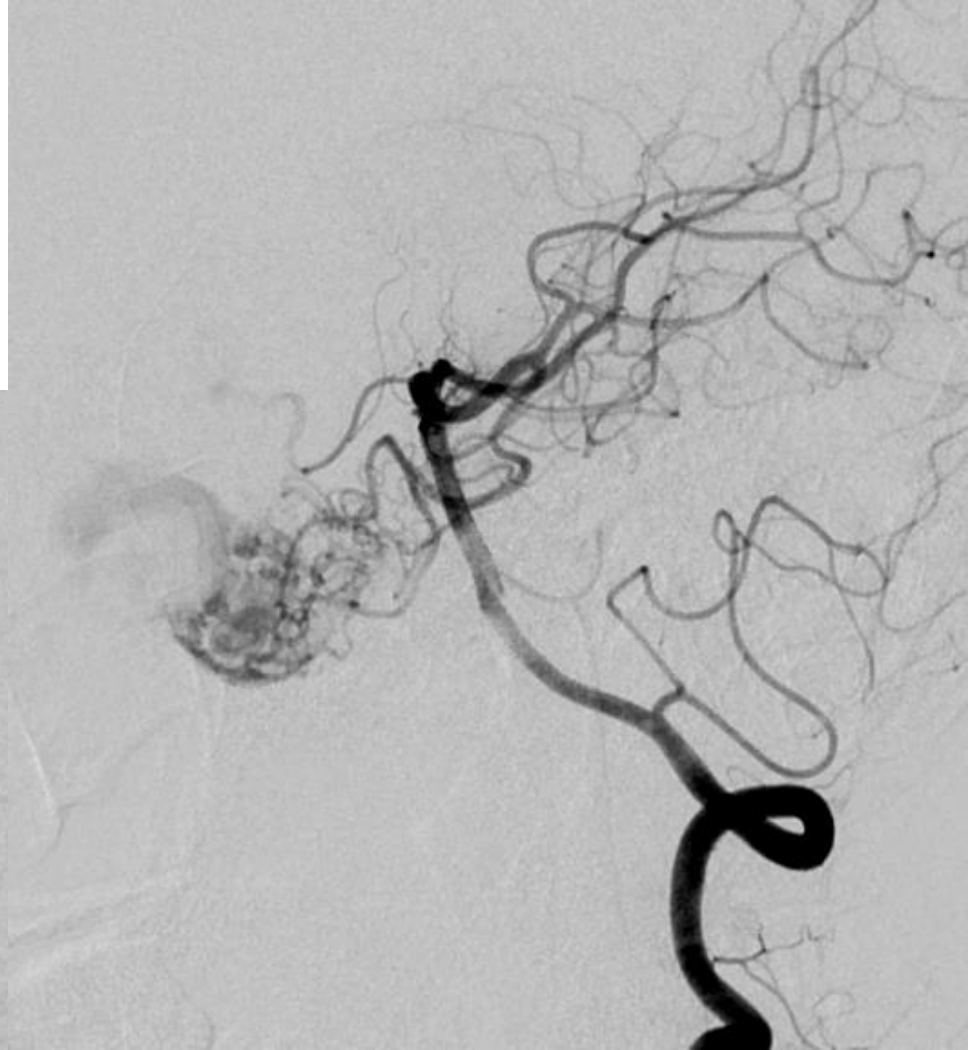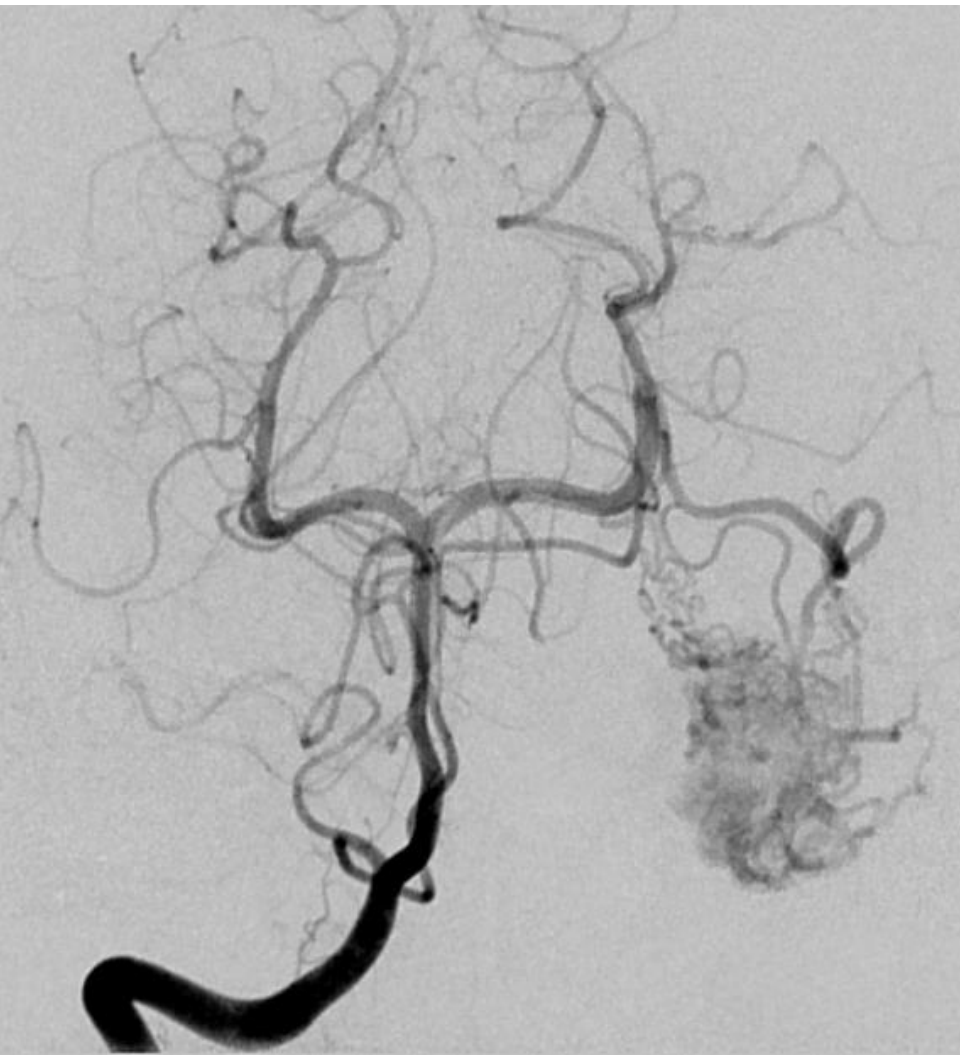Song Donglei, Gai Yanting, Wang wei,
Li Dongbo, Liu Mindi
Brain Doctor Group

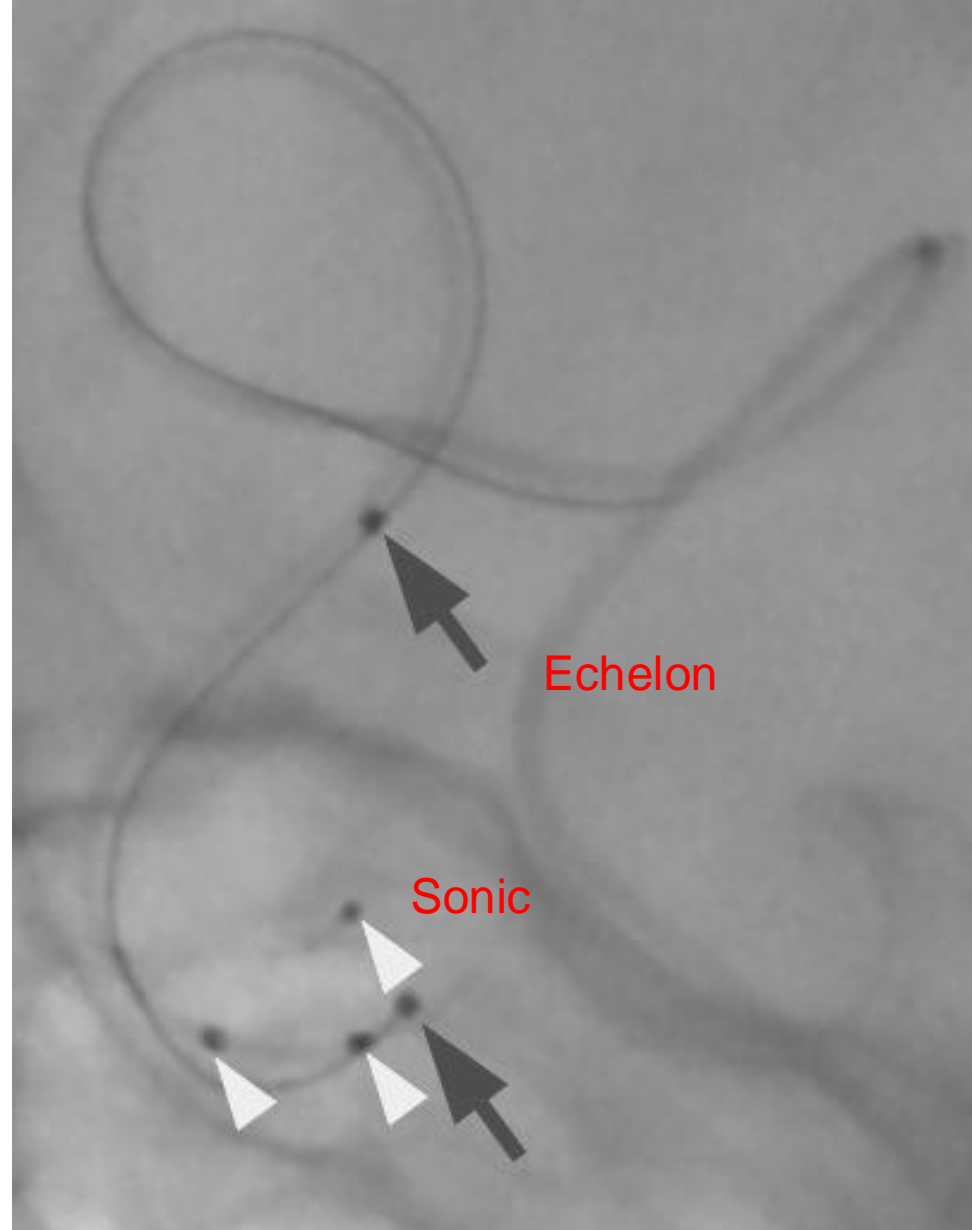
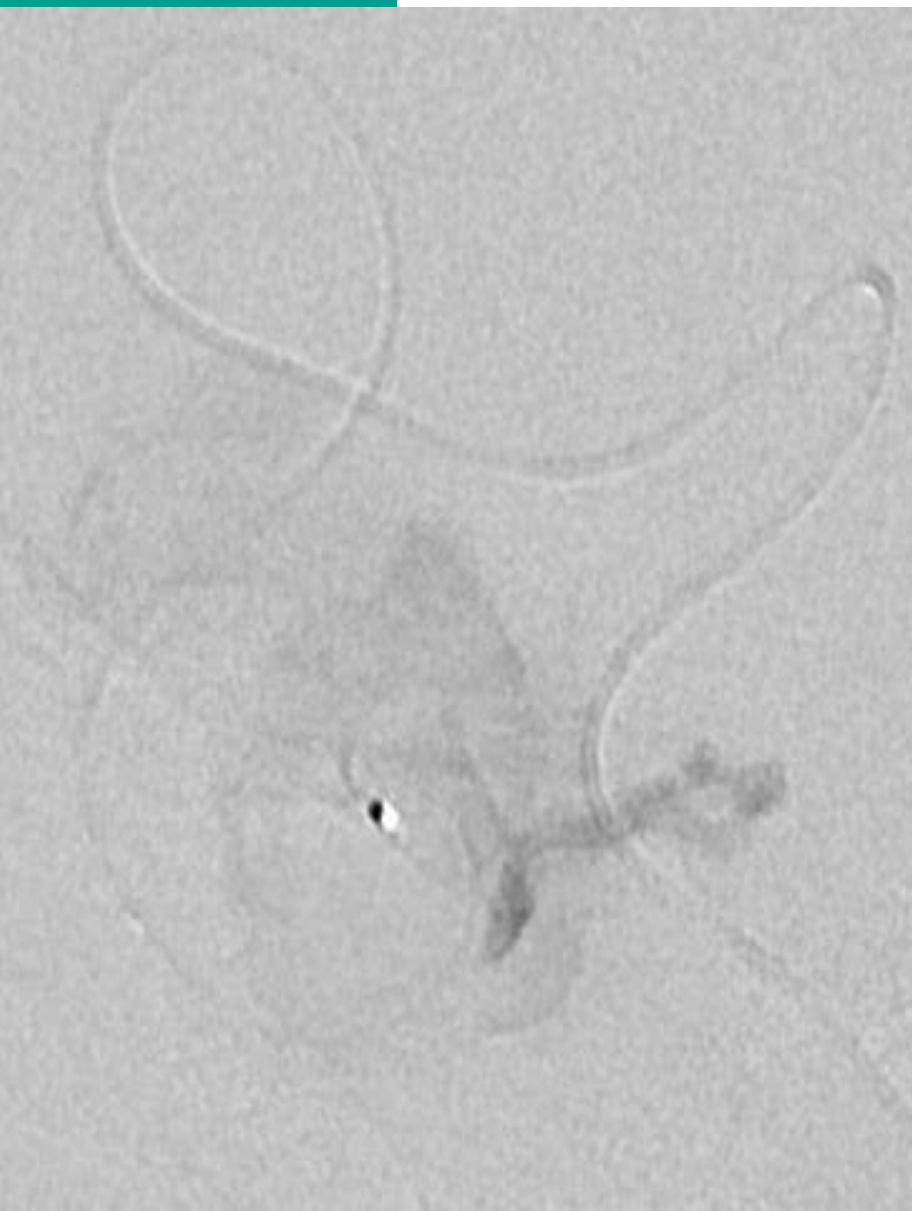
Case Data

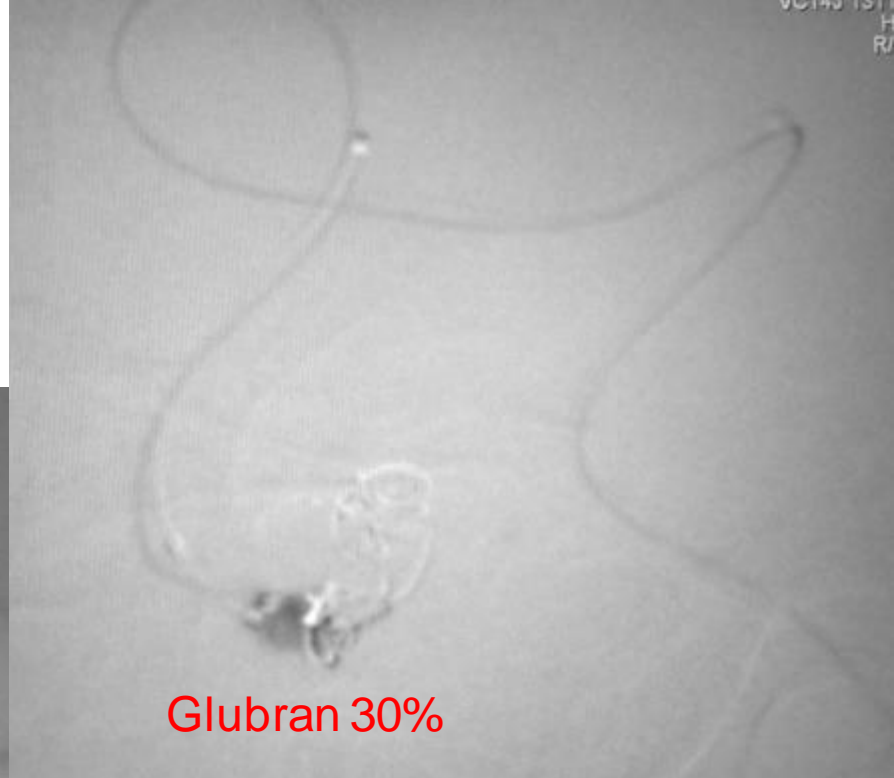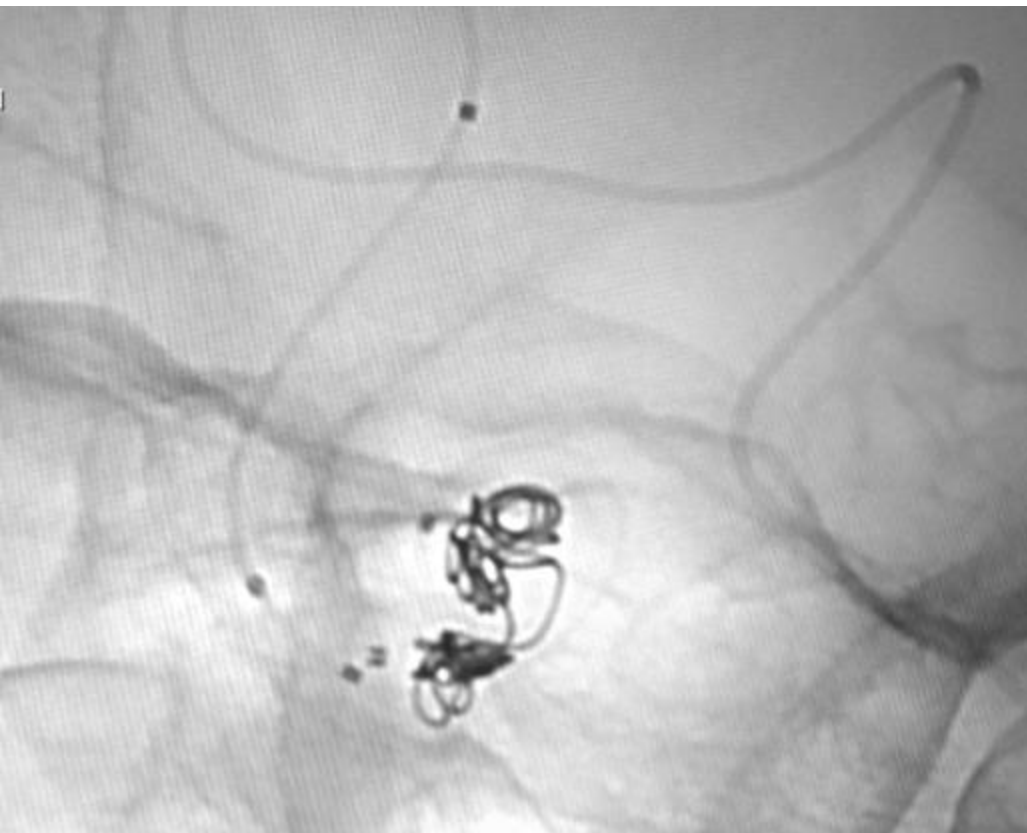
Male, 43y, headache for 2
months

PE (—)

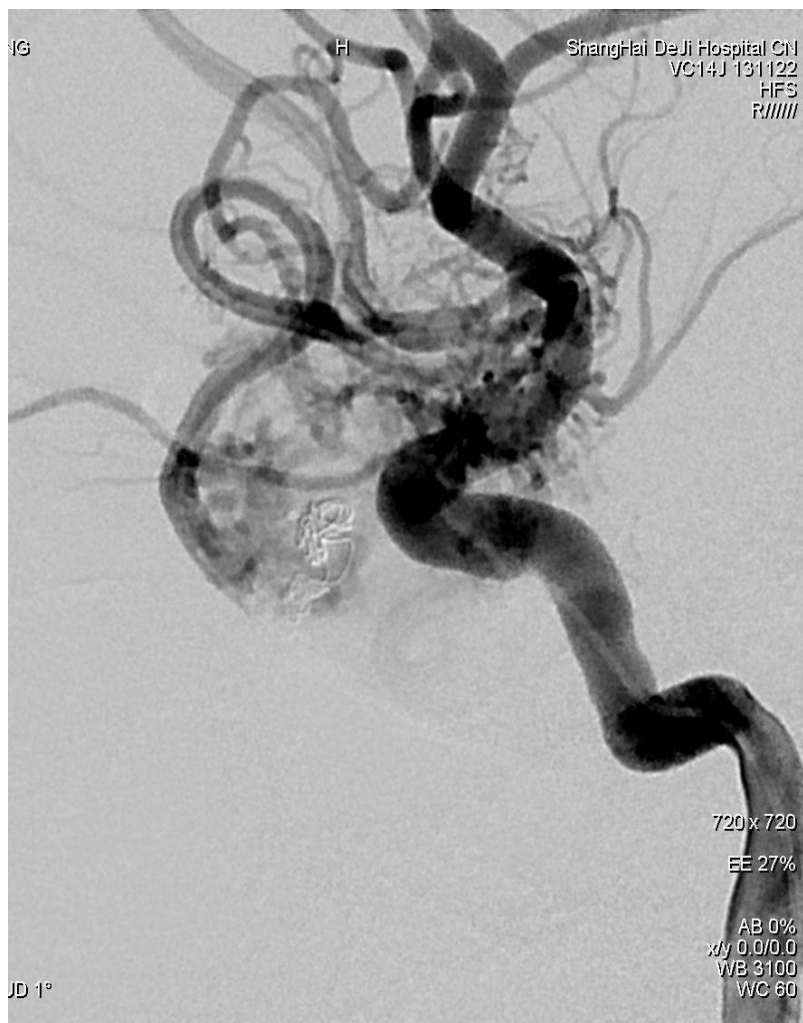







Glubran 30%



STUDY 1
4/14/2015
2:51:12 PM
24 - 56/125

5.50 sec

A

Carotid

cm 22
B
kV 102
mA 237
D 3341
LAO 86° / 0°

4/20/15
4:22 PM
511/513

RM Neuro
116

Study 1
4/14/2015
2:41:57 PM
22-230/245
M1

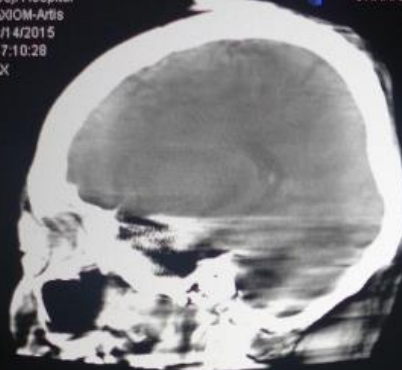
R

RM Neuro

2-230/245
1

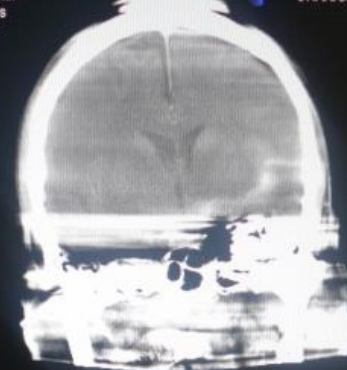
RM Neuro

AXIOM-Artis
4/14/2015
17:10:28
AX



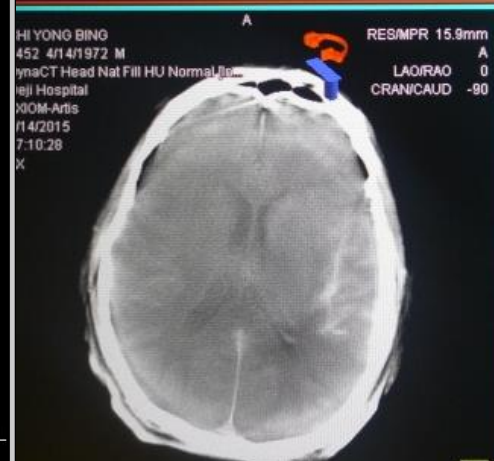
W 204
C 54

AXIOM-Artis
4/14/2015
17:10:28
AX



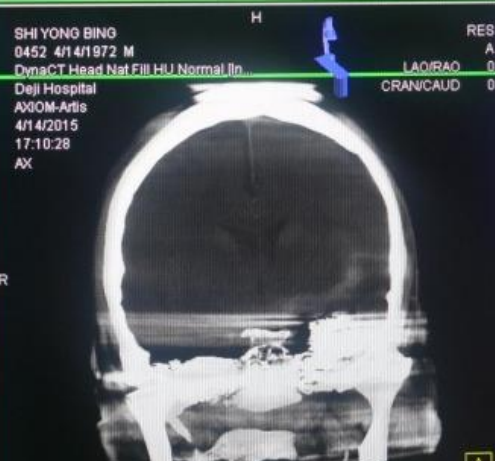W 204
C 54

SHI YONG BING
0452 4/14/1972 M
DynaCT Head Nat Fill HU Normal Iln...
Deji Hospital
AXIOM-Artis
4/14/2015
17:10:28
AX

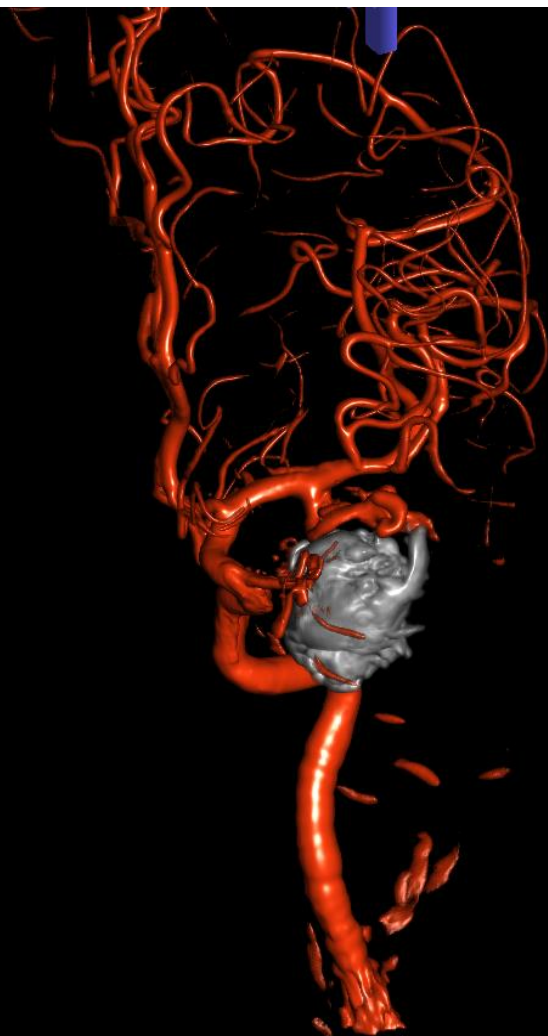


RES/MPR 15.9mm
A
LAO/RAO 0
CRAN/CAUD -90

SHI YONG BING
0452 4/14/1972 M
DynaCT Head Nat Fill HU Normal Iln...
Deji Hospital
AXIOM-Artis
4/14/2015
17:10:28
AX



RES
A
LAO/RAO 0
CRAN/CAUD 0



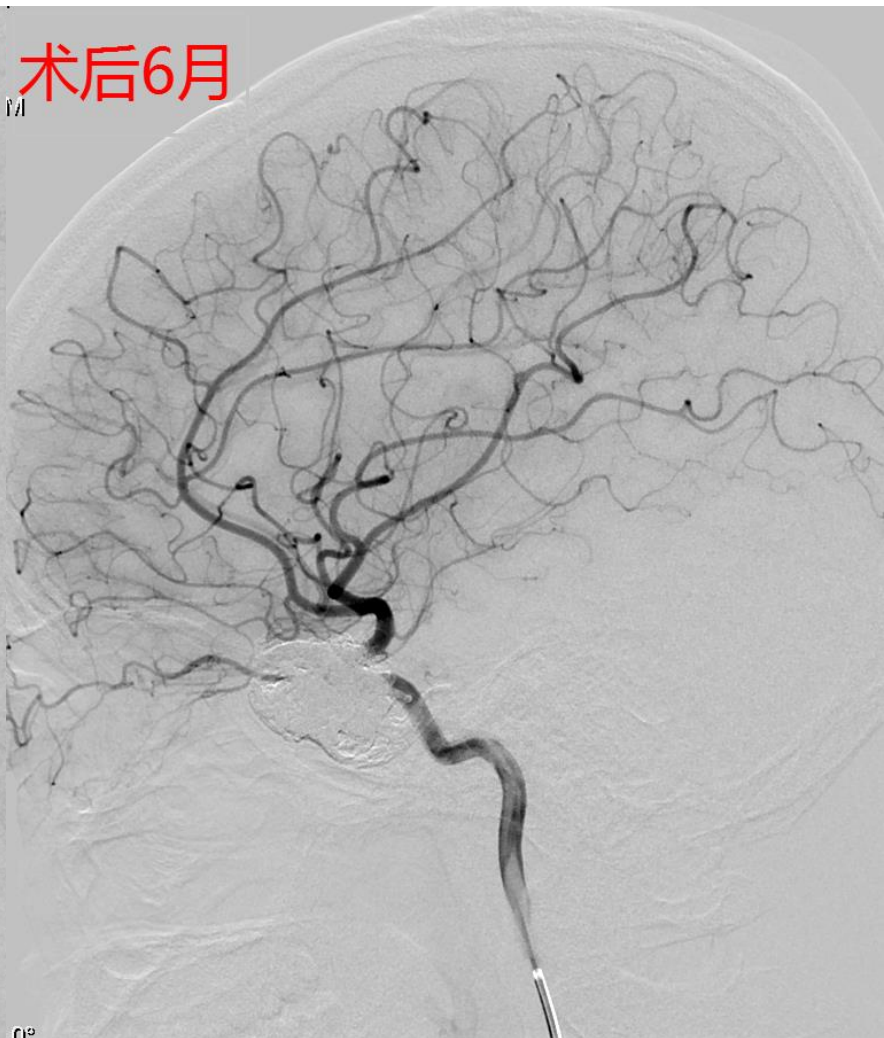
B 100 W 1
C 100 C 100

STUDY 1	UDY 1	JDY 1
4/14/2015	4/20/15	4/20/15
3:14:23 PM	14:23 PM	6:36 PM
31 - 28/122	- 28/122	- 45/116
M 4	4	
3.60 sec	30 sec	7 sec

术后6月 术后6月

R

Carotid	rotid	otid
cm 32	142	42
A		
kV 92	73	73
mA 267	1340	339
D 3437	3324	616
0° 162° 10°	0° 162° 10°	0° 162° 10°



Conclusion

Case selection: small to median size

Tip of microcatheter: nidus

No reflux, Quick injection

Occlusion of venous drainage

Postop.

sedation, analgesia, BP control, antiepilepsy

THANK YOU FOR ATTENTION